INTRAOPERATIVE NERUOPHYSIOLOGICAL MONITORING IN BRAIN SURGERY

DR. FARRUKH JAVEED
Neurosurgery resident



History

- Hans Berger (discoverer of the alpha waves rhythm known as "Berger's wave")in 1928-29 was the first to report EEG tracings from human brains.
- The first use of intraoperative EEG was by Foerster and Alternberger in 1935.
- In the late 1930s through the 1950s, Herbert Jasper and Wilder Penfield further developed this technique, for localization and surgical treatment of epilepsy.
- They also performed careful mapping of cortical function by direct electrical stimulation.

Introduction

- Generally, ION techniques can be divided in two groups: mapping and monitoring.
- Neurophysiologic mapping is a technique that, when applied intraoperatively, helps us to identify anatomically indistinct neural structures by their neurophysiologic function.
- This allows the surgeon to avoid injuring the critical structures in the course of the surgical procedure. In essence, the information gained from neurophysiologic mapping allows the surgeon to operate more safely.

- **Neurophysiologic monitoring** is a technique that continuously evaluates the functional integrity of nervous tissue and gives feedback to the (neuro)surgeon.
- This feedback can be instantaneous, as in a recently developed technique of monitoring motor-evoked potentials (MEPs) from the epidural space of the spinal cord or limb muscles.
- If the surgical procedure allows us to combine monitoring with mapping techniques, then optimal protection of nervous tissue can be achieved during neurosurgery.

ANATOMY

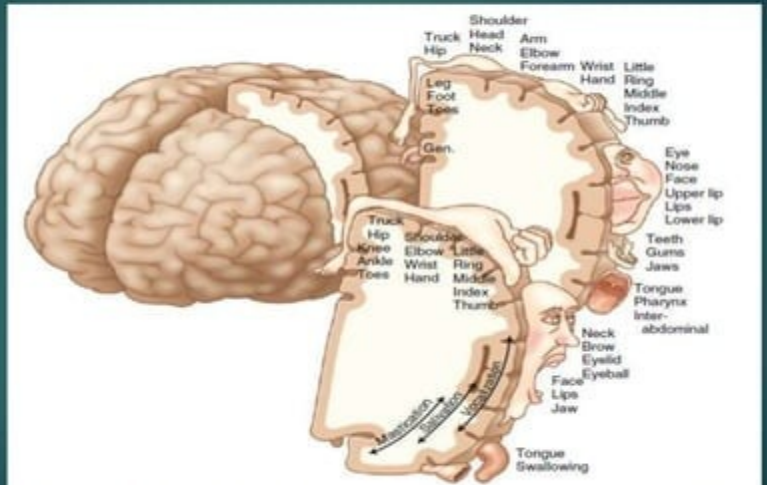

Fig. 2.15 Drawing of the motor and sensory homunculus. Notice that the face and upper extremity are represented laterally and the lower extremity and genitalia are represented medially

Cranial Nerves

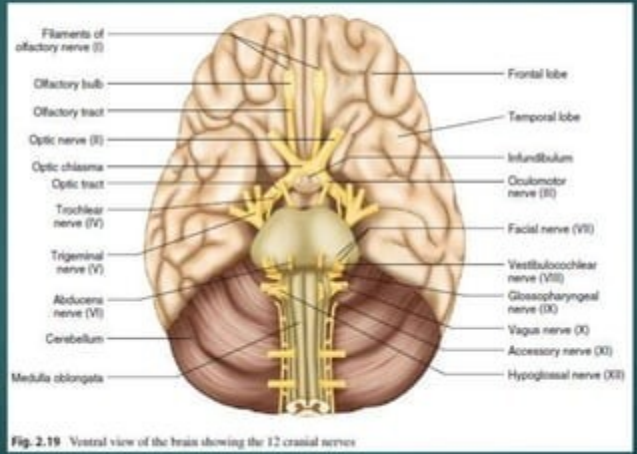

Fig. 2.19 Ventral view of the brain showing the 12 cranial nerves

Types of Intraoperative Neurophysiological Monitoring

- Depending on the surgical procedure, measures may be directly dependent on the functioning of the cortex
- electroencephalogram(EEG)
- somatosensory evoked potentials (SEPs)
- Visual evoked potentials (VEPs)
- direct cortical stimulation
- the brain stem brain stem auditory evoked potentials (BAEPs) and brain stem somatosensory evoked potentials (BSEPs)
- cranial nerves (CN) II, III, IV, V, VI, VII, VIII, IX, X, XI, and XII
- spontaneous and evoked electromyography (EMG).

Neuroanesthetic Considerations

- It is well known that the type of anesthesia, the patient's blood pressure, cerebral blood flow, body temperature, hematocrit, and blood gas tensions all affect the patient's CNS function and thus the observed intraoperative neurophysiological measures.
- Halogenated inhalational agents are favored by anesthesiologists for many procedures; however, they tend to significantly reduce the amplitude and shift the frequency components of the EEG, reduce the amplitude and increase the latencies of somatosensory and motor evoked potentials.

Ideal Anaesthetic

- Found the optimal anesthetic technique to be a balanced narcotic technique, usually fentanyl, nitrous oxide (50%), a low level of isoflurane (0.5%), and a short-acting muscle relaxant that can be rapidly reversed.
- Of the inhalation agents, isoflurane produces the weakest effects on cortical activity.

ANESTHETIC EFFECTS ON EPS

- Latency delay
- Amplitude reduction (except etomidate and ketamine)
- Variable among agents
- Worse in inhalational agents and dose dependant
- Additive effects of agents
- VEP>SEP>BAER

EEG

- It is one of the neurophysiological monitoring tool in which the electrical activity of the brain is monitored.
- It is a noninvasive procedure and electrodes are placed over the scalp.
- The EEG is valuable in almost all cerebrovascular procedures or tumor resections where significant risk for interruption of blood flow to the brain occurs.

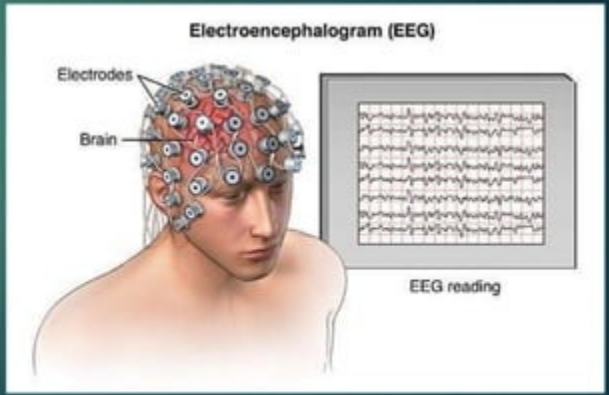

Band	Frequency (Hz)	Location	Normally	Pathologically
Delta	< 4	frontally in adults, posteriorly in children; high-amplitude waves	• adult slow-wave sleep • in babies • Has been found during some continuous-attention tasks[51]	• subcortical lesions • diffuse lesions • metabolic encephalopathy hydrocephalus • deep midline lesions
Theta	4–7	Found in locations not related to task at hand	• higher in young children • drowsiness in adults and teens • idling • Associated with inhibition of elicited responses (has been found to spike in situations where a person is actively trying to repress a response or action).[51]	• focal subcortical lesions • metabolic encephalopathy • deep midline disorders • some instances of hydrocephalus
Alpha	8–15	posterior regions of head, both sides, higher in amplitude on dominant side. Central sites (c3-c4) at rest	• relaxed/reflecting • closing the eyes • Also associated with inhibition control, seemingly with the purpose of timing inhibitory activity in different locations across the brain.	• coma
Beta	16–31	both sides, symmetrical distribution, most evident frontally; low-amplitude waves	• range span: active calm → intense → stressed → mild obsessive • active thinking, focus, high alert, anxious	• benzodiazepines • Dup15q syndrome [52]
Gamma	> 32	Somatosensory cortex	• Displays during cross-modal sensory processing (perception that combines two different senses, such as sound and sight)[53][54] • Also is shown during short-term memory matching of recognized objects, sounds, or tactile sensations	• A decrease in gamma-band activity may be associated with cognitive decline, especially when related to the theta band; however, this has not been proven for use as a clinical diagnostic measurement

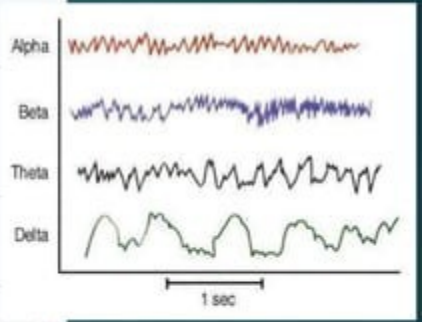

WHAT PATTERN IS SEEN ON EEG?

- The typical pattern seen in the EEG during cerebral hypoperfusion is a reduction or loss in high-frequency activity and the appearance of large-amplitude slow waves in the range of 1 to 4 Hz.
- Simple but useful summary of possible changes is that decreased frequency with increased amplitude implies an ischemic event to the cortex .
- widespread frequency slowing and decreased amplitude usually imply brain stem ischemia, whereas ischemic events affecting the thalamus and the internal capsule produce unremarkable changes in the EEG.

FACTORS AFFECTING EEG

- HYPOXIA
- HYPOTENSION, ISCHEMIA
- HYPOTHERMIA
- HYPO-AND HYPER-CARBIA
- BRAIN DEATH

EVOKED POTENTIALS

- Evoked potentials are averaged EEG waveforms recorded following repetitive stimulation.
- The process of averaging nulls-out EEG activity that is not time -locked to the stimulus.
- Resultant waveforms contain peaks that are named N (negative – upward deflection) or P (positive – downward deflection) followed by the latency in milliseconds to the onset of the peak.

EVOKED POTENTIALS (EPs)

- Somatosensory evoked potentials
- Motor evoked potentials
- Visual evoked potentials
- Brainstem auditory evoked potentials

CORTICAL MAPPING

- Cortical stimulation mapping is an invasive procedure.
- Electrode is placed on the brain to test motor, sensory, language, or visual function at a specific brain site.
- The electrode delivers an electric current lasting from 2 to 10 seconds on the surface of the brain, causing a reversible lesion in a particular brain location.
- This lesion can prevent or produce a testable response, such as the movement of a limb or the ability to identify an object.

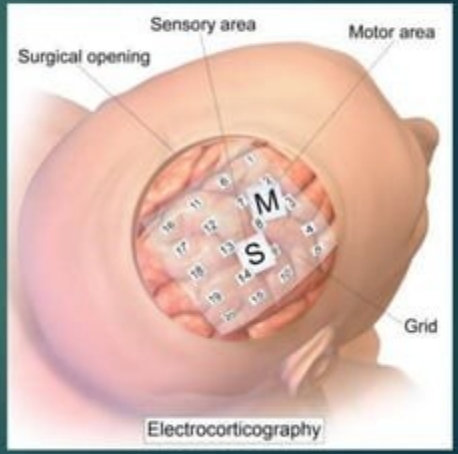

- Electrodes are usually made of stainless steel or platinum-iridium embedded in a silastic material, and are usually circular with diameters of 2 to 3 mm.
- Electrodes can either be placed directly on brain areas of interest or can be placed in the subdural space of the brain.



- Currents are kept at levels that have been determined safe and are only given as short bursts.
- Current intensity is usually set around bursts of 1 mA to begin and gradually increased by increments of 0.5 to 1 mA, and the current is applied for a few seconds.
- It can be used for somatosensory mapping from the precentral gyrus, motor mapping from the post-central gyrus, language mapping from the Broca's and Wernicke's areas.

Stimulation end points	
1. Symptoms	
Aura	Indicates ictal onset zone
Somato sensory	Suggests sensory area, but stimulate at 0.5-1.0 mA higher current to see if it is motor area, unless the sensation is intolerable or afterdischarge has already occurred.
Visual	Suggests visual areas.
Cognitive- affective	Uncommon, may suggest limbic areas, or may be a 'psychological reaction'
2. Signs	
Motor	Negative (loss of tone) or positive (twitch)
Speech	Suggests language area
3. After-discharge or seizure	Do not stimulate again at same strength same site.

Transcranial Magnetic Stimulation

- It is used to stimulate small regions of the brain.
- During a TMS procedure, a magnetic field generator, or "coil", is placed near the head of the person receiving the treatment.
- The coil produces small electric currents in the region of the brain just under the coil via electromagnetic induction. The coil is connected to a pulse generator, or stimulator, that delivers electric current to the coil

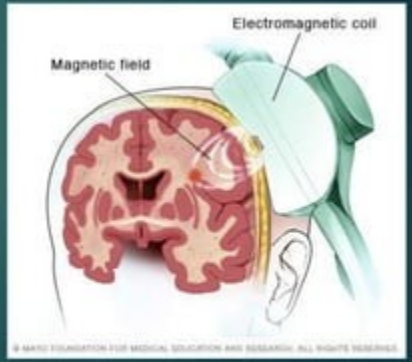

- TMS is used diagnostically to measure the connection between the brain and a muscle to evaluate damage from:
  - stroke,
  - multiple sclerosis,
  - amyotrophic lateral sclerosis,
  - movement disorders,
  - motor neuron disease,
  - and injuries and other disorders affecting the facial and other cranial nerves and the spinal cord.

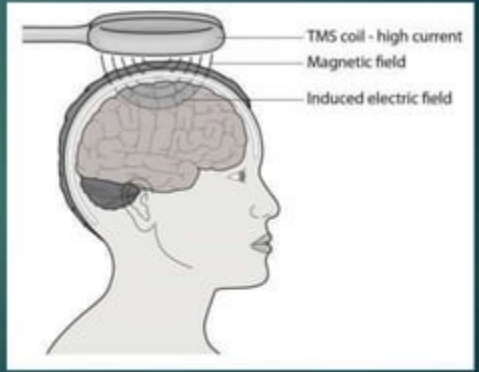

BRAIN STEM AUDITORY EVOKED POTENTIALS (BAEPS)

- The classic BAEP consists of a minimum of five and a maximum of seven peaks.
- The first five peaks, Jewett waves I through V, are the principal peaks used in clinical practice.

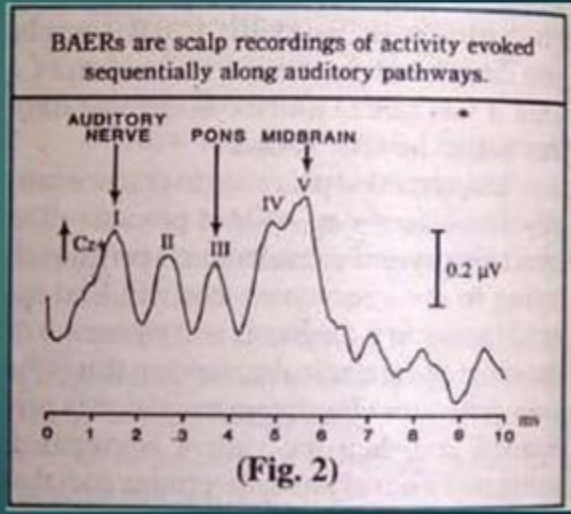

- Wave I is generated in the cochlear portion of the eighth nerve. Its latency is 1.5 to 2.1 msec in a normal adult.
- Wave I is present in recordings made on the ipsilateral side to the stimulus but is not usually seen on contralateral-side recordings.
- Wave II is generated bilaterally at or in the proximity of the cochlear nucleus. The latency between waves I and II is 0.8 to 1.0 msec.
- The amplitude of wave II on the contralateral side may be greater than on the ipsilateral side.

- Wave III is generated bilaterally from the lower pons near the superior olive and trapezoid body.
- Waves IV and V are probably generated in the upper pons or lower midbrain, near the lateral lemniscus or possibly near the inferior colliculus.
- Wave V tends to be the most robust peak and is typically the last to disappear when stimulus intensity is reduced.
- Wave V, being the most robust is most closely followed during intraoperative procedures.

- The intensity level of the click is set to 90 dB.
- Baseline responses for each ear are acquired prior to the beginning of surgery. These data are compared with the preoperative evaluation and used as baselines throughout the case.
- Waves I to V are relatively resistant to sedative medication and general anesthetics.
- Latency shifts of greater than 0.3 msec are reported to the surgeon.

VISUAL EVOKED POTENTIALS

- aid in determining the functional integrity of the visual system, primarily in the region of the optic nerves, chiasm, and optic radiations.
- The recorded activity is generated either at the retina (electroretinogram) or at the occipital cortex.
- Except in selected situations, stimulation of the visual system using a bright flash is not recommended for diagnostic purposes due to intersubject variability.
- however,in the operating room this is a very helpful and effective technique.

- Four waves are typically seen in the VEP
- P60 which is thought to be generated in subcortical structures.
- and N70, P100, and N120, which are all thought to be generated in the primary visual cortex.

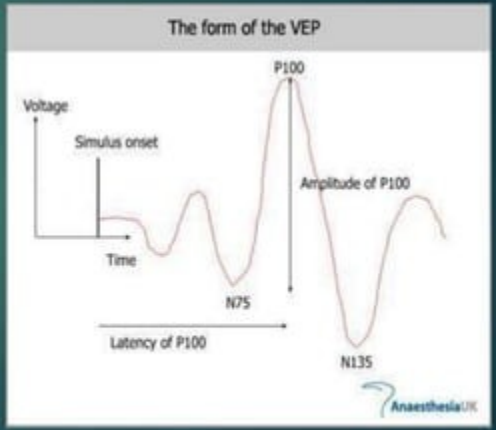

CRANIAL NERVE MONITORING

- Cranial nerve function is monitored continuously during many cases for two reasons:

1. to identify the location and orientation of the cranial nerves in the operative field;
2. to preserve functioning in the cranial nerves and their related brain stem nuclei

CRANIAL NERVE ELECTROMYOGRAPHY

- EMG is used to monitor all cranial nerves except I, II and VIII.
- II & VIII are monitored by evoked potentials.
- No current method for monitoring of cranial nerve I.

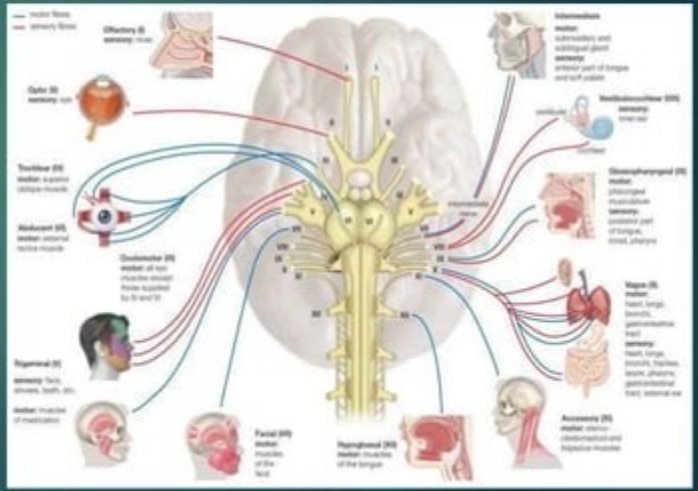

ELECTROMYOGRAPHY

- EMG is the recording of electrical activity of muscle.
- Free run EMG
  - Monitor for irritation or injury
- Direct Stimulation
  - Identify nerves
  - Test their integrity



THE MOTOR UNIT

- A single motor neuron and all the muscle fibers it innervates.
- Muscle fibers contract in response to action potentials from the neuron.
- When all the fibers contract this is called a motor unit action potential (MUAP).

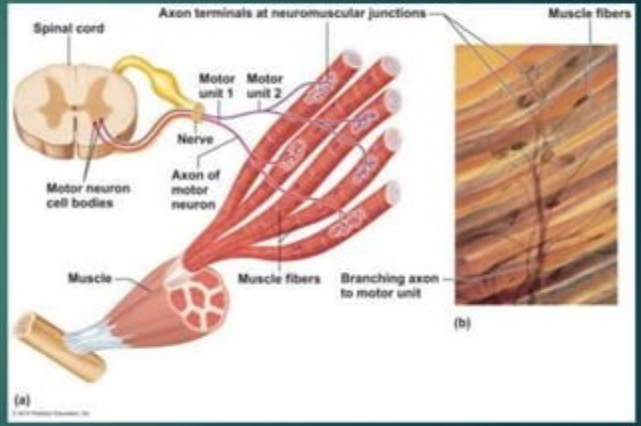

Compound Muscle Action Potential (CMAP)

- "The summation of nearly synchronous muscle fiber action potentials recorded from a muscle, commonly produced by stimulation of the nerve supplying the muscle either directly or indirectly."

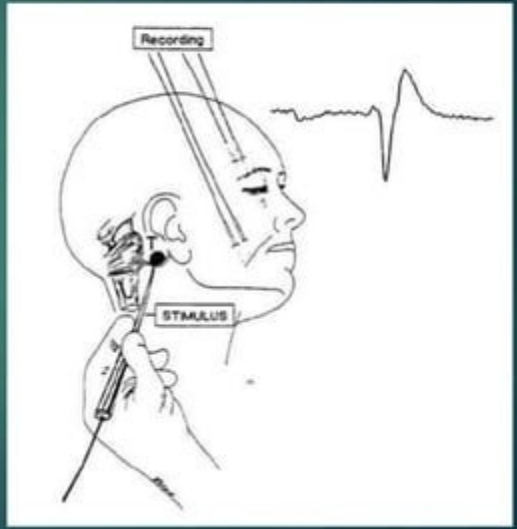

Recording Methods

- Surface needle electrodes (most common)
- Electrodes are placed subdermally over the muscle.
- Can be placed in a monopolar or bipolar manner.



EMG Parameter Settings

- Bandpass:
  - 5Hz - 5KHz
- Time base:
  - 250ms -1sec
- Sensitivity:
  - 50-100mV



Direct Nerve Stimulation

- Bandpass:
  - 5Hz – 5 KHz
- Analysis time:
  - 10 – 20ms
- Intensity: 0.1mA – 1mA
- A threshold can be determined also for stimulation intensity.

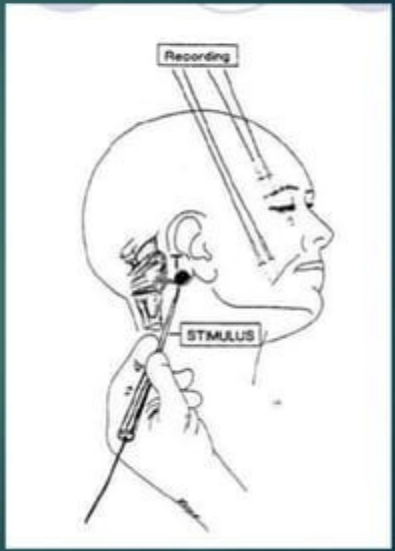

EMG Intraoperative Interpretation

- Based primarily on the presence of activity and partially on pattern.
- Free run EMG should be made audible for instant feedback to the Surgeon and Neurophysiologist.



EMG Examples

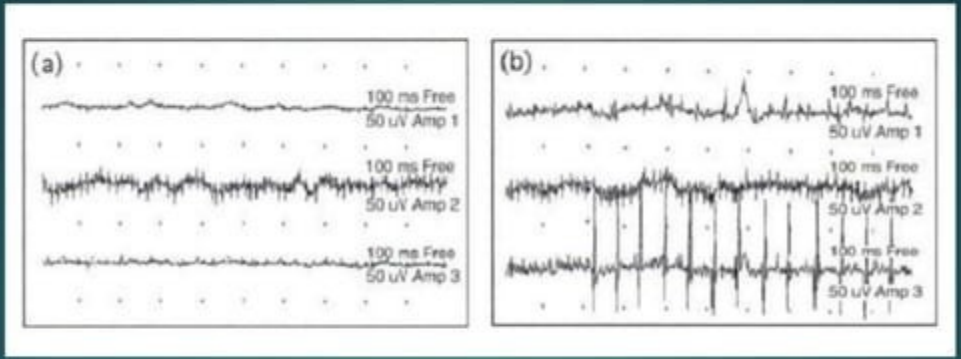

- Baseline EMG.
- Note the low amplitude background activity on ch3.
- High amplitude spikes are present on ch3 indicating irritation of the nerve corresponding to that channel.

- Four categories of EMG activity are observed:
- (1) no activity, which in an intact nerve is the best situation, but which also may be the case in a sharply dissected nerve.
- (2) irritation activity, which sounds like soft intermittent flutter and is consistent with working near the nerve.
- (3) injury activity, which sounds like a continuous, nonaccelerating tapping and can indicate permanent injury to the cranial nerve.
- (4) a "killed-end'' response, which sounds like an accelerating firing pattern and is an unequivocal indicator of nerve injury.

- In addition to monitoring the ongoing EMG activity, the various cranial nerves may be electrically stimulated.
- This is usually done to determine the location of the nerve in the operative field because many times the nerve is encased by tumor and may not be directly observable, or to determine the functional integrity of the nerve.

CN II (Optic)

- Flash VEPs are used intraoperatively.
- LED goggles used for stimulation.
- Typically 3 negative and 3 positive peaks.
- Responses do not reproduce well in surgery.
- Responses heavily affected by inhalational gases.
- Not commonly performed.

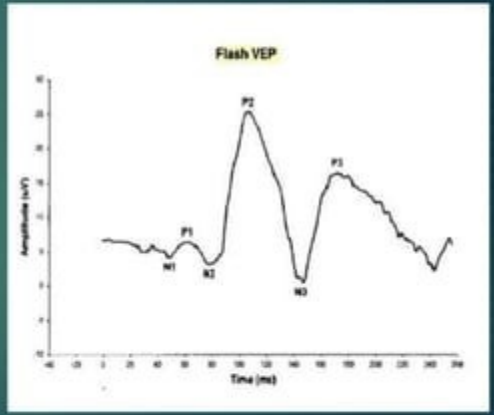

CN III, IV, VI

- Skull base tumor removal.
- Posterior fossa tumor removal.
- Clivus tumor removal.
- Use caution when placing needle electrodes near the eye.

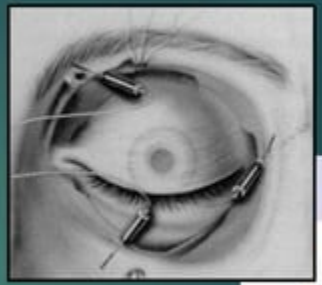

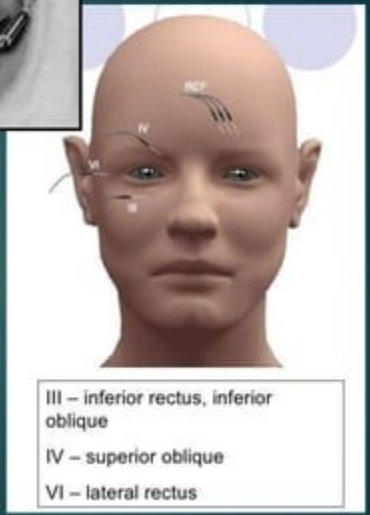

CN V (Trigeminal)

- Skull base tumor removal.
- Microvascular decompression for trigeminal neuralgia.
- Clivus tumor removal.
- Large posterior fossa tumor removal.
- Recorded from the masseter.



Masseter Muscle

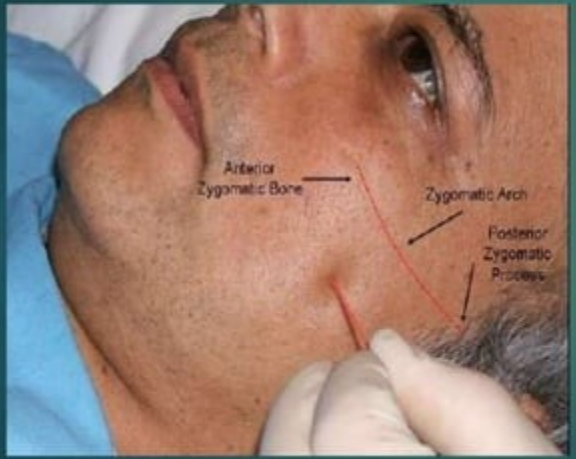

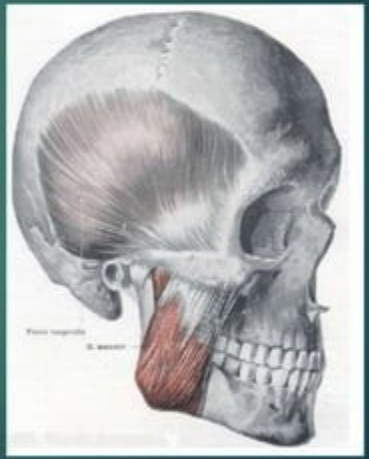

CN VII (Facial Nerve)

- Acoustic neuroma removal
- Skull base tumor removal
- Parotid gland tumor removal
- Recorded from Orbicularis Oris (lower branch) and Orbicularis Oculi (upper branch).



CV VIII (Vestibular Cochlear)

- Sensory nerve
- BAERs (Brainstem Auditory Evoked Potentials) used to test function of auditory nerve and pathways in the brain stem.



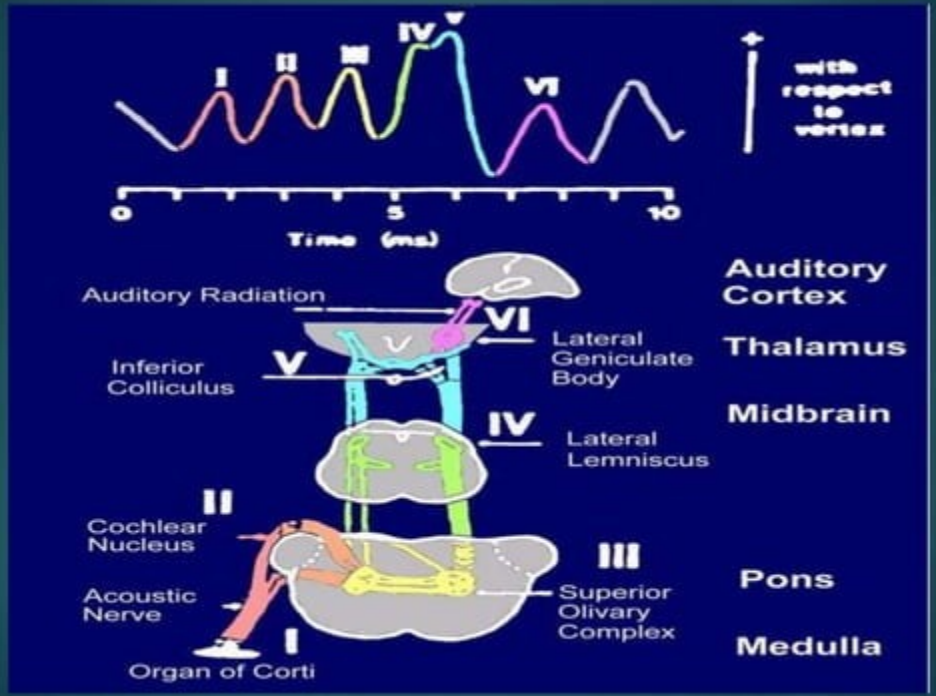
I
II
III
IV
V
VI
with respect to vertex
0
5
10
Time (ms)
Auditory Radiation
VI
Lateral Geniculate Body
Inferior Colliculus
V
IV
Lateral Lemniscus
II
Cochlear Nucleus
III
Acoustic Nerve
Superior Olivary Complex
I
Organ of Corti
Auditory Cortex
Thalamus
Midbrain
Pons
Medulla

CN VIII – Surgical Procedures

- Skull base procedures
- Acoustic neuromas
- Cerebello-pontine angle lesions
- Posterior fossa lesions

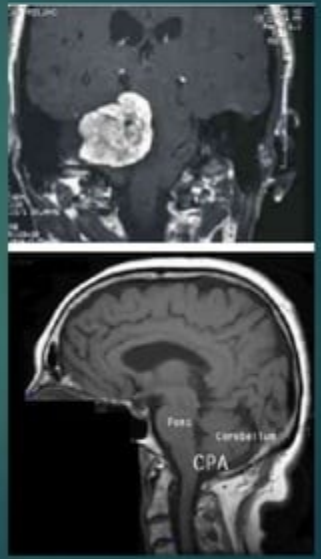

CN VIII – Anesthsia

- No requirements.
- Anesthetic agents generally have minimal or no effect on BAERs.

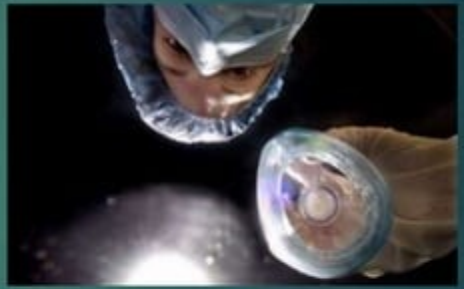

CN VIII – Stimulation

- Auditory clicks delivered through foam ear inserts attached to an air tube.
- Rarefaction is recommended for well defined peaks.
- Intensity: 80 dB – 1000 dB
- Rate: 11.1 Hz
- Duration: 0.03 – 0.1 msec
- Contralateral ear should be masked with a white noise 40 dB less than stimulated ear.

CN VIII – Generators

- I – Auditory nerve
- II – Cochlear nucleus
- III – Superior olive
- IV – Lateral lemnisci
- V – Inferior colliculus

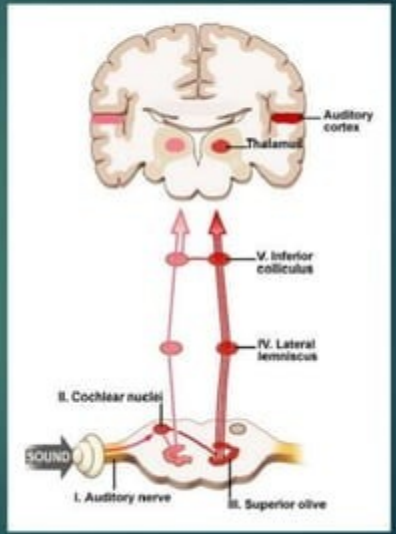

CN IX (Glossopharyngeal)

- Large posterior fossa tumor removal (acoustic neuroma)
- Radical neck dissection
- Recorded from soft palate or stylopharyngeus muscle (dilates the pharynx for swallowing)

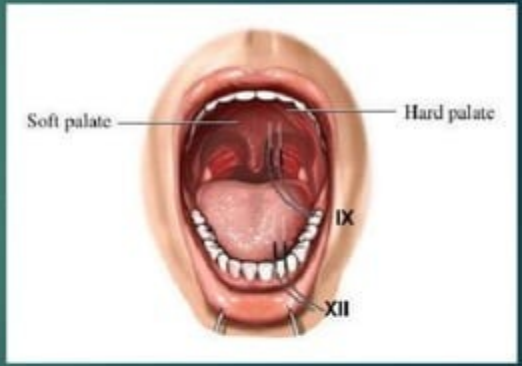

CN X (Vagus)

- Record from false vocal cords with needle electrodes
- Or record from vocal cords with special wired endotracheal tube.





CN XI (Spinal Accessory)

- Skull base tumor removal
- Jugular foramen tumor removal
- Record from Trapezius muscle.



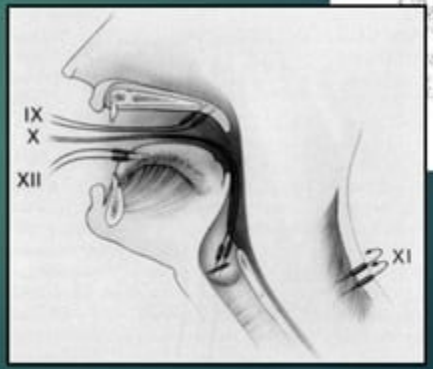

CN XII (Hypoglossal)

- Skull base tumor removal
- Jugular foramen tumor removal
- Large posterior fossa tumors
- Radical neck dissection
- Recorded from the tongue

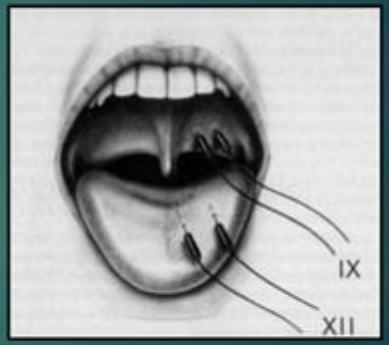

Comparison

MODALITIES	SSEPs	MEPs/CMAPs	EMG
Stimulation	Peripheral sensory nerves	Transcranial scalp electrodes	Free-running: none Triggered: bipolar stimulation of a specific structure
Recording	Cortical and cervicomedullary junction	Extremity muscles (e.g., thenar muscles, tibialis anterior)	Myotome specific
Alert threshold	50% reduction in amplitude 10% increase in latency	Disappearance of signal (all-or-none phenomenon)	Sustained activity (>2 sec)

MODALITIES	SSEPs	MEPs/CMAPs	EMG
Advantages	Specific and sensitive to sensory deficits Continuous monitoring, no interruption in surgical manoeuvres	Specific and sensitive to motor deficits Large signal amplitude, instantaneous feedback	Allows surgical correlation with specific nerve roots Continuous monitoring Instantaneous feedback
Disadvantages	False-negative results for motor deficits Low signal amplitude, multitrace averaging required, delayed response (seconds to minutes)	Total intravenous anaesthesia Intermittent monitoring, interruption in surgery required	No neuromuscular blockade Monitors only nerve roots


Thank
You