Embryology and Fetal Development

Fertilization

- Fertilization is also called conception/impregnation/fecundation.
- Is the fusion of the sperm with the ovum, to form the zygote

-The prerequisites for fertilization includes: -

- Adequate and matured sperm.
- Ability of sperm to reach and penetrate the zona pellucida and cell membrane of the ovum.
- Matured ovum.
- Patent genitalia.

- The fertilized cell continues its passage through the uterine tube & reaches the uterus 3 - 4 days later.
- During this time segmentation or cell division continues.
- Implantation is normally complete by the 11th day after ovulation.
- The fertilized ovum is called a zygote till it will be 3 weeks after conception.
- After 3 wks up to 8 wks we call it an ***embryo.***
- After 8 weeks up to delivery we call it a ***fetus*** which when born will be called ***a baby***.

The Fetal Development

1. The zygote: -

- The zygote is the beginning of the embryo.
- After the zygote formation, typical mitotic division of the segmentation nucleus occur producing two blastomeres.
- The blastomeres continue to divide by binary division through 4, 8, 16 cells stage until a cluster of cells called ***Morula*** is formed.

2. The Morula: -

- The Morula after spending about 3 days in the uterine tube enters the uterine cavity through the narrow uterine ostium (1mm) on the fourth day in the 16 - 64 cell stage.
- The transportation is controlled by muscular contraction and cilia in the fallopian tubes.
- The central cell of the Morula is known as ***inner cell mass***.
- The inner cell mass develop to form the ***embryo proper.***
- The peripheral cells of the Morula are called ***outer cell mass.***
- The outer cell mass develop to form ***protective*** and ***nutritive*** membrane of the embryo.

3. Blastocyst: -

- While the Morula remains free in the uterine cavity on the 4th and 5th day it is covered by a film of mucus.
- The fluid passes through the canaliculi of the zona pellucida which separates the cells of Morula and is now termed as ***Blastocyst***.
- The blastocyst consists two parts.

3.1 . The outer part ***Trophoblast –*** develop in to ***placenta and chorion.***

-The placenta provides nourishment to the fetus and the chorion covers the fetus.

3.2 . The inner part ***inner cell mass*** - develops into ***fetus, amnion & umbilical cord.***

-Embryonic stem cells of the inner cell mass differentiate in to three germ layers *(**ectoderm, mesoderm, & endoderm**)* which are able to produce mature somatic (body) cells.

Development of the fertilized ovum

Zygote

Morula

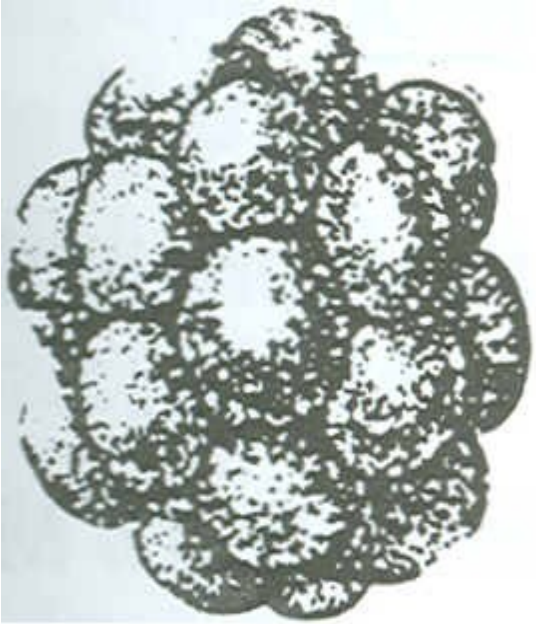

Blastocysts

Fetal development

- **0-4 weeks after conception**
  - Rapid growth, formation of the embryonic plate
  - Primitive central nervous system forms
  - Heart develops and begins to beat
  - Covered with a layer of skin
  - Limb buds form
- **4-8 weeks**
  - Very rapid cell division
  - Head and facial features develop
  - All major organs laid down in primitive form
  - External genitalia present but sex not distinguishable
  - Early movements visible on ultrasound from 6 weeks

Fetal dev't…

- **8-12 weeks**
  - Eye lids fuse
  - Kidneys begin to function and the fetus passes urine from 10 weeks
  - Fetal circulation functioning properly
  - Sucking and swallowing begin
  - Sex apparent
  - Moves freely (not felt by the mother)
  - Some primitive reflexes present

Fetal dev't…

- **12-16 weeks**
  - Rapid skeletal development – visible on x-ray
  - Meconium present in gut
  - Lanugo appears
  - Nasal septum and palate fuse
- **16-20 weeks**
  - Quickening – mother feels fetal movements
  - Fetal heart heard on auscultation
  - Fingernails can be seen
  - Skin cells begin to be renewed

Fetal dev't…

- **20-24 weeks**
  - Most organs become capable of functioning
  - Periods of sleep and activity
  - Responds to sound
  - Skin red and wrinkled
- **24-28 weeks**
  - Survival may expected if born
  - Eyelids reopen
  - Respiratory movements

Feta dev't…

- **28-32 weeks**
- Begins to store fat and iron
- Testes descend in to scrotum
- Lanugo disappears from face
- Skin becomes paler and less wrinkled
- **32-36 weeks**
- Increased fat makes the baby more rounded
- Lanugo disappears from body
- Head hair lengthens
- Nails reach tips of fingers
- Ear cartilage soft
- Plantar creases visible

Fetal dev't…

- **37-40 weeks**
- Term is reached and birth is due/expected
- Contour rounded
- Skull firm

Summary of fetal development based on trimester

First trimester (conception -12wk)

- Period of organogenesis
- Susceptible to teratogenic
- Heart functions at 3-4wks
- Eye formation at 4-5wks
- Arm and leg buds at 4-5wks
- Recognizable face and external genitalia at 8wk
- Placenta formed at 12wk
- Rapid growth of brain
- Bone ossified at 12wk

Fetus at 8 Weeks

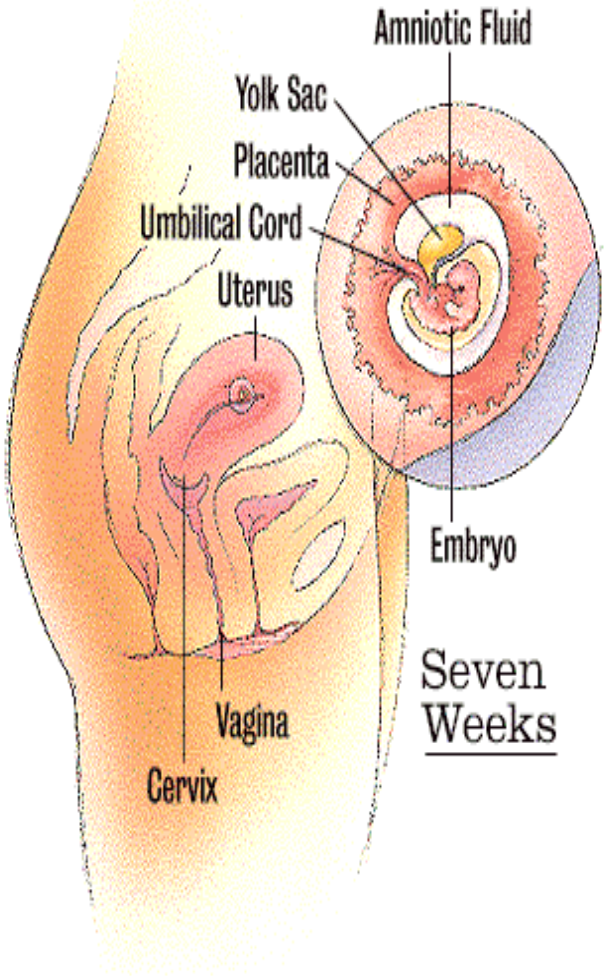

Second trimester (13-24wk)

- Less susceptible for teratogens after 12wks
- Facial feature are formed at 16wk
- FHB heard by 16-20wks with fetoscope/Doppler
- Vernix present
- Size of fetus is around 25cm

20 weeks (5 Months)

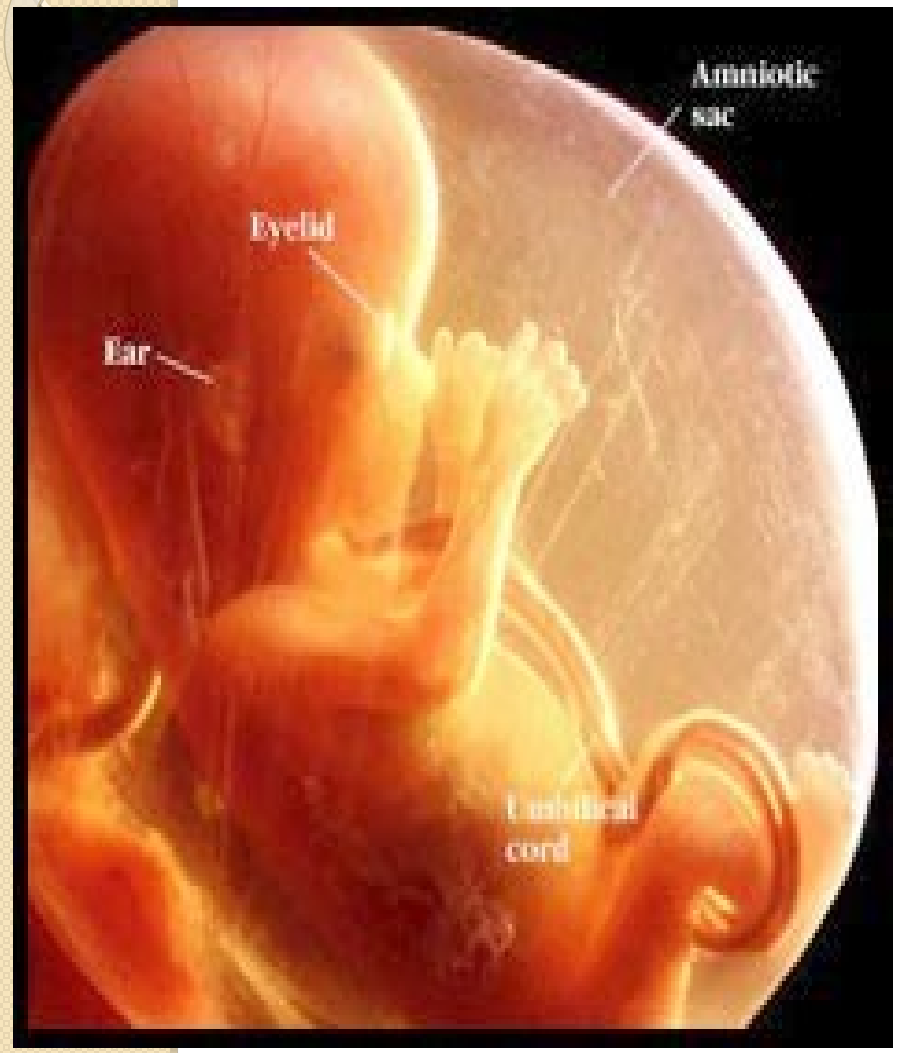

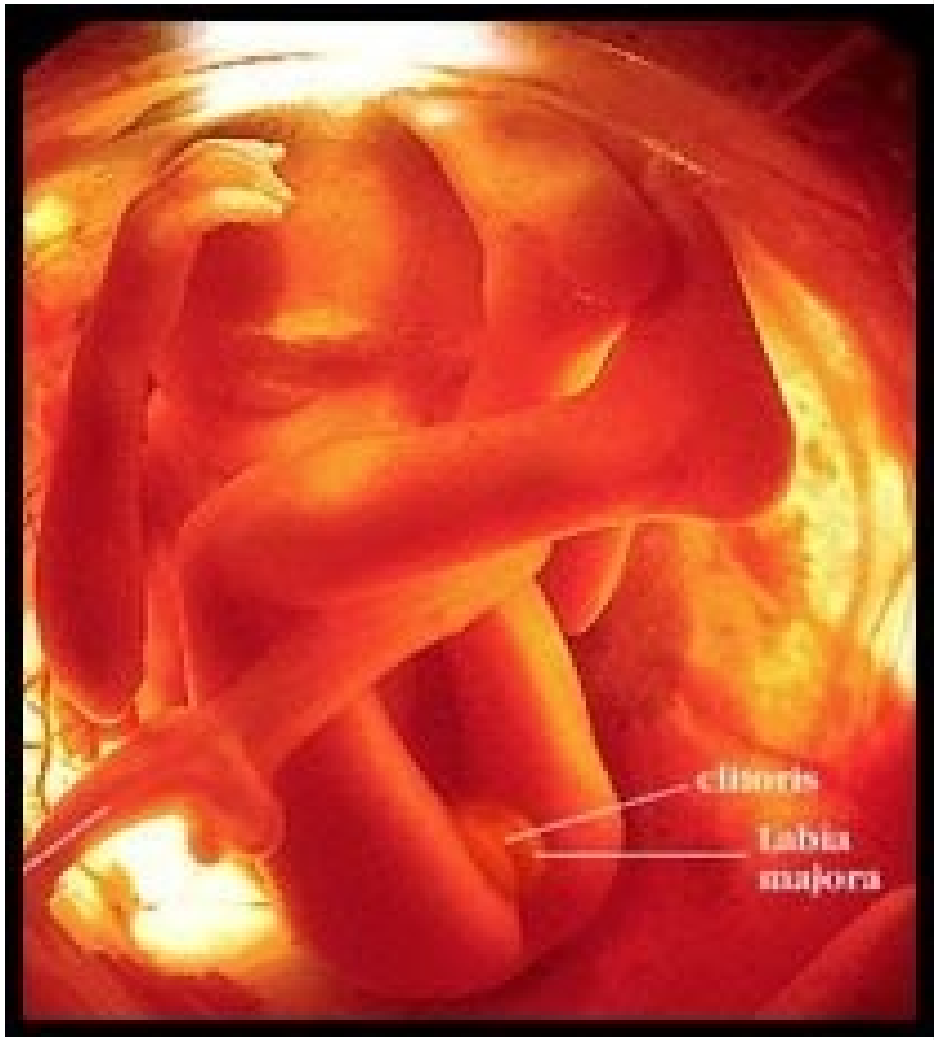

Third trimester (25-36wks)

- Surfactant production begins in increasing amount
- Iron is stored
- Calcium stored at 28-32wks
- Fetal reflex at 28-32wks
- Subcutaneous fat deposits at 36wk
- Size of the fetus 45-55cm at 38-40wks

Seven Months

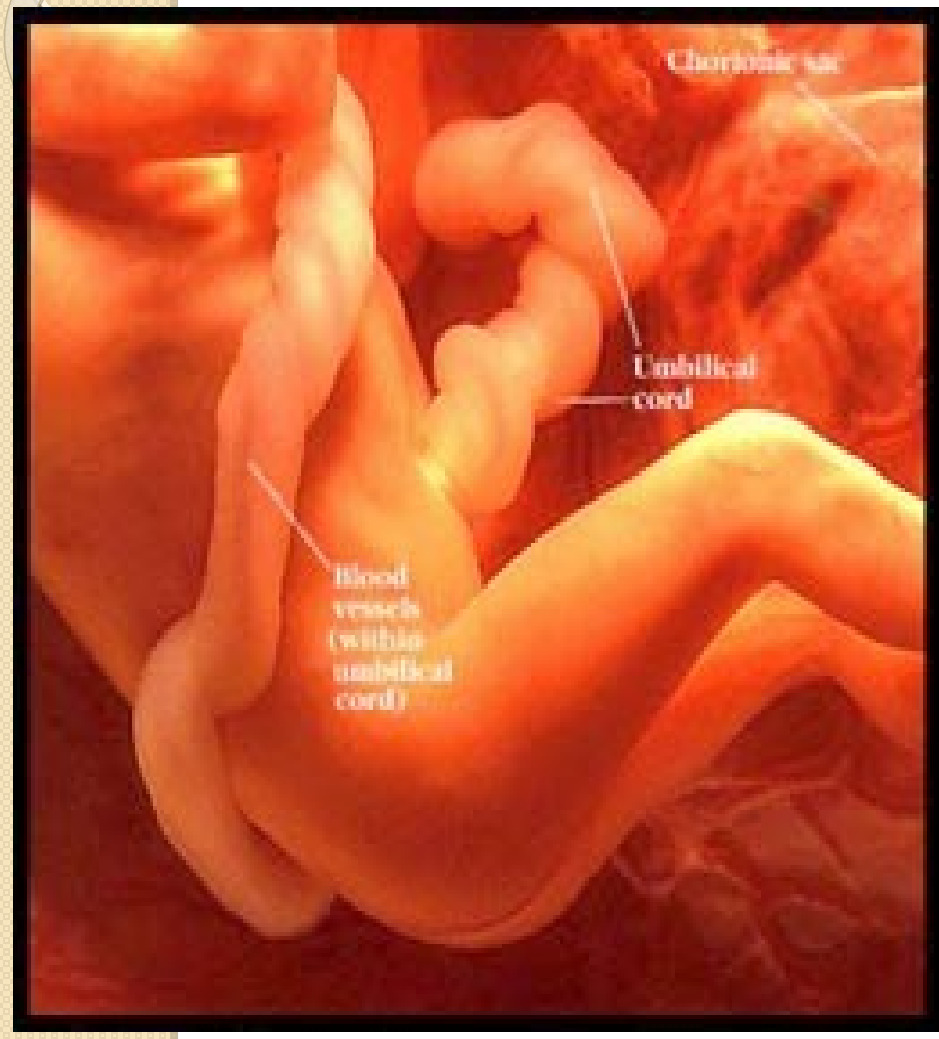

Eight Months

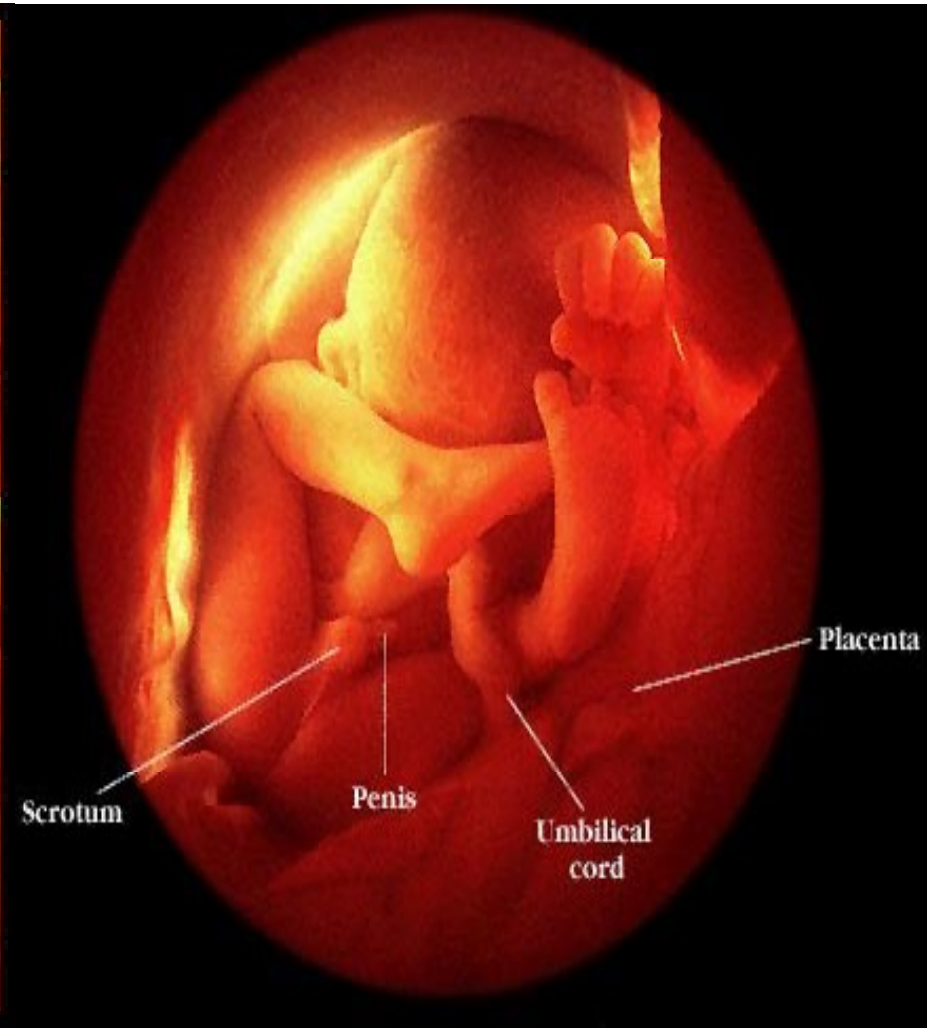

Nine Months

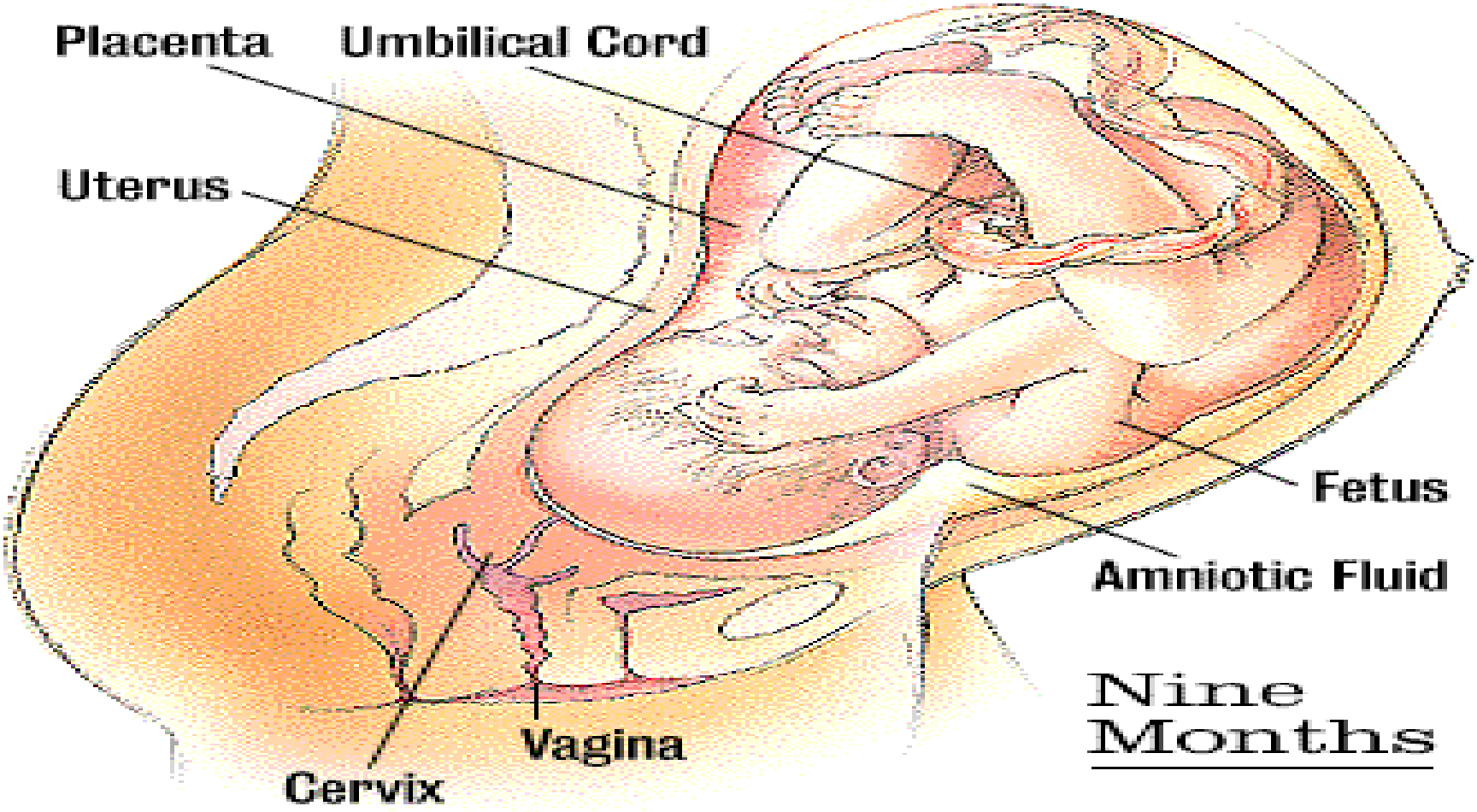
Placenta
Umbilical Cord
Uterus
Fetus
Amniotic Fluid
Nine Months
Vagina
Cervix

Summary of the fetal development based on gestational age

- A gestational age is the age of pregnancy counted in weeks.
- During the first 3 weeks of life the fertilized ovum is called a ***zygote***.
- During this time cells have multiplied until Blastocyst has been formed and it has implanted itself in the walls of the uterus.
- During this time primitive trophoblastic villi have been formed to reach down into the thick endometrium thus giving contact with maternal blood.
- Starting from week 3 up to 8th week it is called Embryo.
- After 8th week up to delivery we call it a Fetus and after birth it is called a baby.

The Placenta

- **The placenta** is a round flat mass which is bluish red in color. It is about 20 cm in diameter and 2.5 cm in thickness from the center.
- It measures about 1/6 part of the baby’s weight at birth.
- It links closely the fetus with the mother’s circulation to carry out functions which the fetus is unable to perform itself during intrauterine life.

The placenta has two surfaces: -

The maternal surface

- Is made up of chorionic villi arranged in 18 – 20 lobes or cotyledons.
- The maternal blood gives it a bluish red color

The fetal surface

- The amnion covering the fetal surface of the placenta gives it a whitish, shiny appearance.
- Branches of umbilical vein and arteries are visible and spreading

There are two membranes on the placenta.

The chorion: -

- It is the outer membrane of the placenta which is opaque, friable and adherent to the uterine wall until 3rd stage of labor.
- During the 3rd stage of labor, it detaches and expelled with the placenta.

The amnion: -

- It is the smooth, tough and translucent inner membrane of the placenta.
- The fetus and the liquor are in it.
- It rupture during labor in order to expel the fetus.

Functions of the placenta

1.Nutrition: -

- The fetus gets the required nutrient from the mother through placenta.

2.Endocrine: -

- The placenta secrets different hormones by the cytotrophoblastic layer of the chorionic villi.

A. Human Chorionic Gonadotrophic hormone (HCG)

- helps to maintain suitable condition within the uterus as the fetus develops.
- It also gives the basis for pregnancy test.

B/ Progesterone

- Its level rises from the 12th week and lasts throughout until the placenta is expelled
- It is used to prevent premature uterine contraction.

C/ Estrogen

- Its production rises from the 6th week until term and fail after the expulsion of the placenta.
- It is used to enhance the mammary gland and enlargements of uterus.

D/ Human placental lactogens (HPL)

- Is a hormone w/c have a role in glucose metabolism in pregnancy
- It help to promote milk production and growth

3.Respiratory: -

- The fetal lung is not functional in the uterus so that the exchange of gas (CO_2 & O_2) is carried out by placenta.
- Oxygen from the mother's hemoglobin passes into fetal blood vessels by simple diffusion and similarly the fetus gives off CO_2 into the maternal blood vessels.

4.Barrier (protection): -

- It provides a limited protection against infection.
- But few bacterial infections like syphilis and tubercle bacillus can penetrate.
- Some viruses, however, can cross freely and cause congenital abnormalities as in the case of the rubella and HIV virus.

5.Excretion: -

- The main substances excreted from the fetus is CO_2 and bilirubin

6.Storage: -

- It metabolizes glucose, stores it in the form of glycogen & reconverts it back to glucose when needed.
- The placenta can also store iron & the fat soluble vitamin

The umbilical cord

-Extends from the fetal umbilicus to the fetal surface of the placenta.

-The umbilical cord encloses: -

- One umbilical vein - carrying oxygenated blood from the mother to the fetus
- Two umbilical arteries - carrying back deoxygenated blood from fetus to the placenta villi

-Warthon`s jelly – a sticky jelly like substance.

-Its average length is about 50 cm and it is about 2 cm thick.

Types of umbilical cord insertion

- ***Central insertion***: - is a normal type of the cord insertion w/c is in the middle of the placenta.
- ***Battledore insertion***: - It is a type of cord insertion at the edge of placenta like tennis table bat.
- ***Velamentous insertion***: - Here the cord is inserted in to the membranes some distance from the edge of the placenta.
- The umbilical vessels run through the membrane from the cord to the placenta.
- It is the dangerous type of cord insertion.
- Its major complication is detachment and tear of the blood vessels during active third stage of labor.
- As a result sudden blood lose will happen.

Velamentous cord insertion

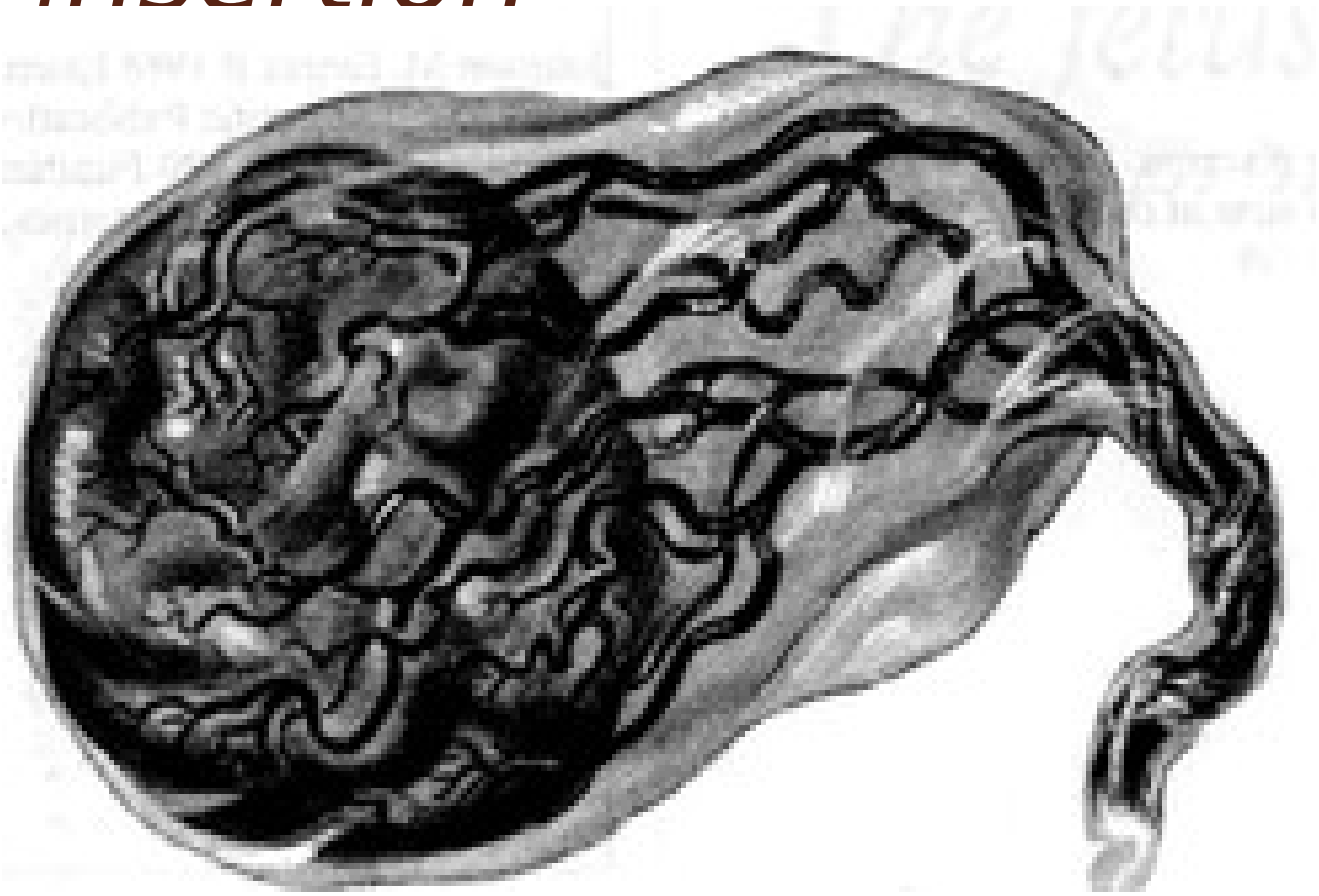

Placenta circumvallate: -

- An opaque ring is seen on the fetal surface; w/c means the chorion is attached on the fetal surface at some distance away from the edge.

Placenta bipartite or tripartite: -

- When the placenta is divided in to two or three complete lobes each with a cord leaving it.
- The bipartite cord joins a short distance from the two parts of the placenta.
- As a result there may be retentions of the extra lobe during delivery.

Abnormal placenta (bipartite)

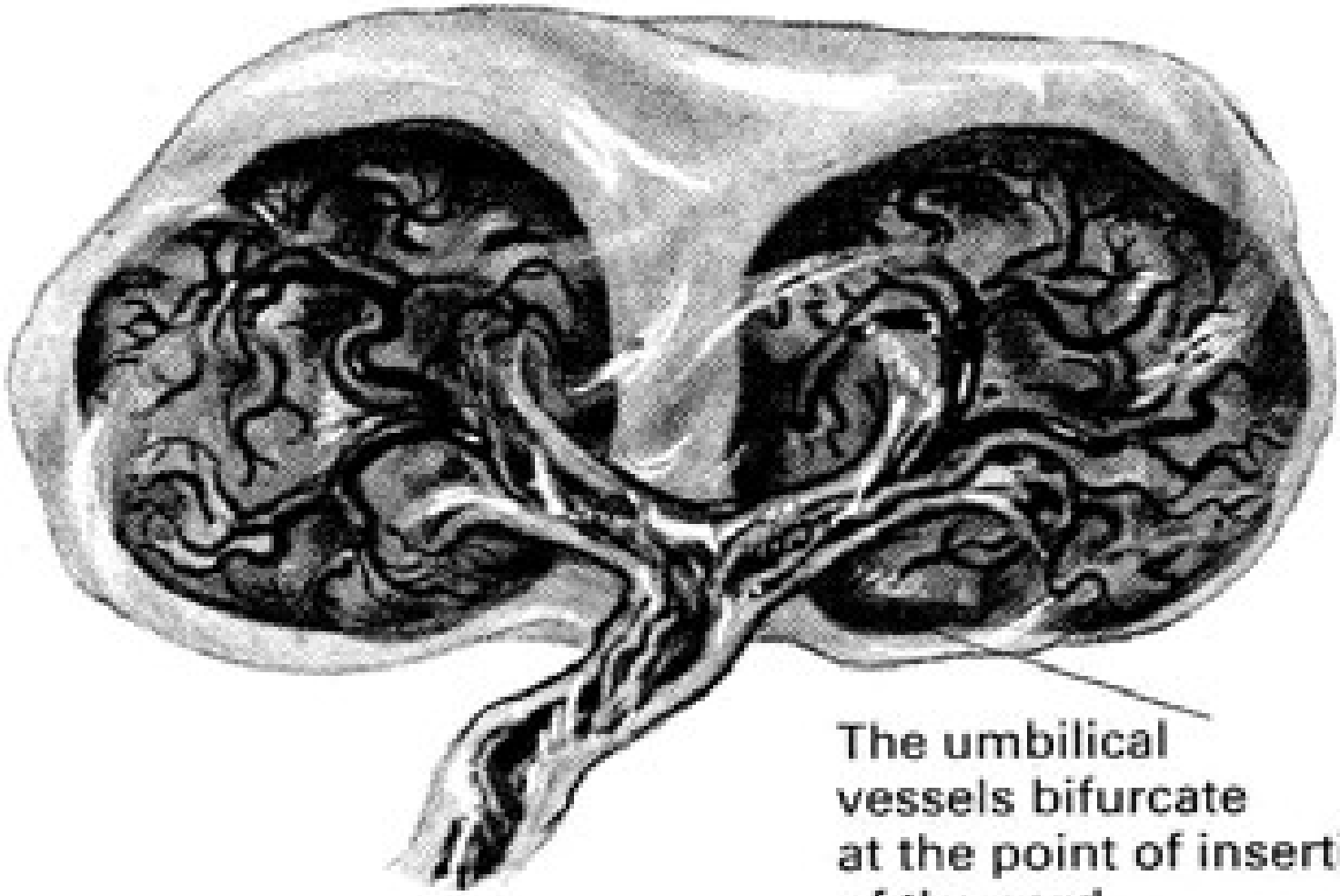

The umbilical vessels bifurcate at the point of insertion of the cord.

Abnormal placenta

Placenta succentureta:-

- A small extra lobe is present separated from the main placenta.
- It is joined to the main placenta by small blood vessels w/c run through the membranes to reach the placenta.
- It has a danger that this small lobe may be retained during delivery preventing uterine contraction resulting in PPH and infection

The amniotic fluid

- It is clear, pale straw colored liquor in w/c the fetus floats.
- The normal amount is from 500 ml – 1500 ml
- It has 99% water, and 1% dissolved organic matters including: -

  -Food substances (protein, glucose, minerals, lipids),

  -Waste products (salt, urea, uric acid, creatinine) and

  -Hormones(insulin, prolactin,and rennin)
- It is slightly alkaline in PH (7.2)

Functions of the amniotic fluid

- Acts as a shock absorber to the fetus and prevents from injury
- Allow for the growth and free movement of the fetus
- It protects the fetus from change in temperature, because liquid changes temperature more slowly than air.
- It aids muscular development, because it allows the fetus freedom to move
- During labor it protects the placenta and umbilical cord from the pressure of uterine contraction
- Facilitate cervical effacement and dilation

Thank you!!!

FETAL CIRCULATION

Objective

At the end of this session students are expected to :

Recognize physiology of fetal circulation.

Recognize the changes under goes after delivery

Identify the regions on the fetal skull.

Show important land marks on the fetal skull

The feotal circulation

- ✓There is no mixture between the maternal and fetal blood.
- ✓The fetus although in utero has its own circulatory system which is quite rudimentary *i.e.* immature, different from an adult circulation.

- ✓Fetal blood has begun to exchange nutrients with the maternal circulation across the chorionic villi as early as 3rd weeks of intrauterine life.

- During intrauterine life the fetal gastro-intestinal and respiratory systems are not functioning.
- So it obtains the necessary nutrient and oxygen from the mother through the placenta.
- There are several temporary structures in addition to the placenta itself and the umbilical cord.
- These enable the fetal circulation to take place but undergo changes after birth.

There are five temporary structures in the fetal circulation:

- ***The umbilical vein:-***leads from the umbilical cord to the underside of the liver and carries blood rich in oxygen and nutrient to the fetus.

- ***The ductusvenosus***: - vein to vein.

  -It connects the umbilical vein to the inferior vena cava.

  -At this point the oxygenated blood from the umbilical vein mixes with the deoxygenated blood returning back through the vena cava

- ***The foramen ovale***: - an oval opening.

  -Temporary opening between the atria w/c allows the majority of blood entering from the inferior vena cava to the right atrium to pass directly in to the left atrium.

- ***The ductusarteriosus: -*** artery to artery.

  - An opening w/c allows the mixture of the blood in the pulmonary artery to the blood in the aorta.

  -It is at a point where the pulmonary artery comes in to contact with the descending arch of the aorta.

- ***The hypogastric arteries***:

  -These are the branches of the internal iliac artery.

  - Become the umbilical artery when they enter the umbilical cord.

  -They return the deoxygenated blood from the fetus to the placenta.

Physiology of the fetal circulation

Fetal circulation

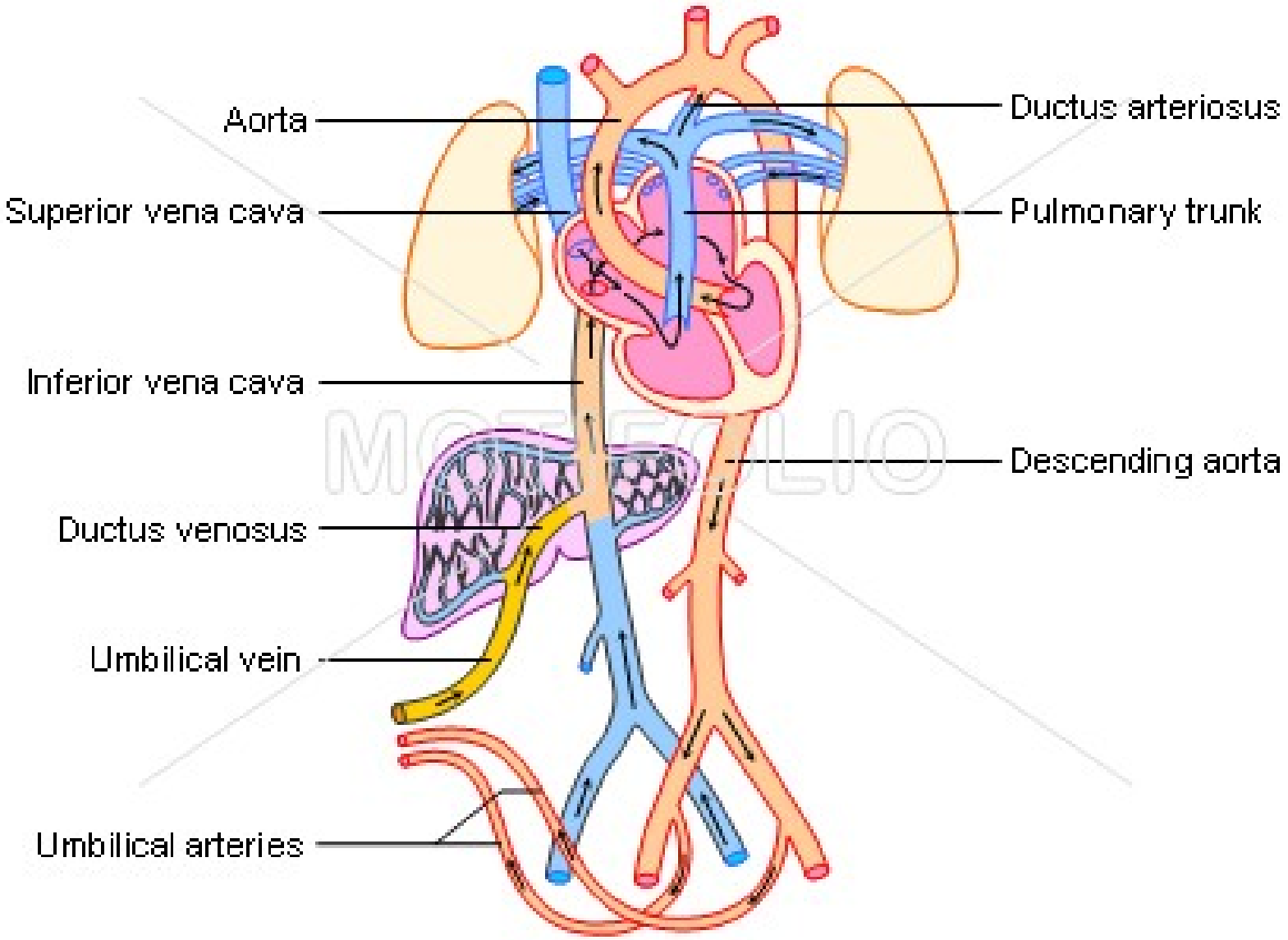

1011181

Copyright © mottfolio.com

Physiologic changes at birth

- The main factor which helps the physiologic changes at birth is the establishment of respiration.

On inspiration: -

- When the infant cries immediately after the birth, it means that the baby has taken the first breath.
- At this time the lungs expand and their field is increased.
- So the blood capillaries suck the blood in to the pulmonary circulation from the right ventricles.

- The pulmonary veins now returns blood back to the left atrium and this causes the pressure in the left side of the heart to rise and become more than the pressure on the right side of the heart.
- This is responsible for the closure of the foramen ovale.
- The blood from the right ventricles finds its easiest way to the lung and so now flows directly to the lung.
- So this is responsible for the closure of the ductus arteriosus.

The cutting of the umbilical vein: -

- The clumping of the umbilical vein stops the flow of the blood in the umbilical vein, the hypogastric arteries, and this is responsible for the closure of the ductus venosus.

- This is also responsible for the reduction of pressure in the inferior vena cava and in the right side of the heart as well.

Changes on fetal circulation at birth

1. Ductus venous – becomes the ligamentumvenosum
2. Foramen ovale – becomes the fossa ovalis
3. Ductus arteries – becomes the ligamentumarteriosum
4. Umbilical vein – becomes the ligamentumteres

The Fetal Skull

- The Fetal skull is a bony box like cavity which contains and protects the delicate brain tissues.
- These delicate brain tissues may be injured during the birth process as they are subjected to great pressure.
- The feotal head is large in comparison to the true pelvis and it is the most difficult part to deliver whether it comes first or last.

- For a feotal head to be delivered without trauma to the mother and the fetus, some adaptation between the fetal skull and maternal pelvis must take place during labor.

- Therefore; an understanding of the land marks and measurements of the fetal skull enables to recognize normal presentation and positions and facilitate delivery with least possible trauma to mother and child.

Divisions of the feotal skull

- The fetal skull if divided in to 3: the face, the base, the vault

The face- Is composed of 14 small bones w/c are firmly united and non compressible

The base - Is composed of bones w/c are firmly united to protect vital center in the medulla

The vault -

- The vault is large dome shaped parts above the imaginary lines drown between the orbital ridge and the nape of the neck.
- They are separated by sutures, and this allows the head to mould during delivery, and makes delivery easier.

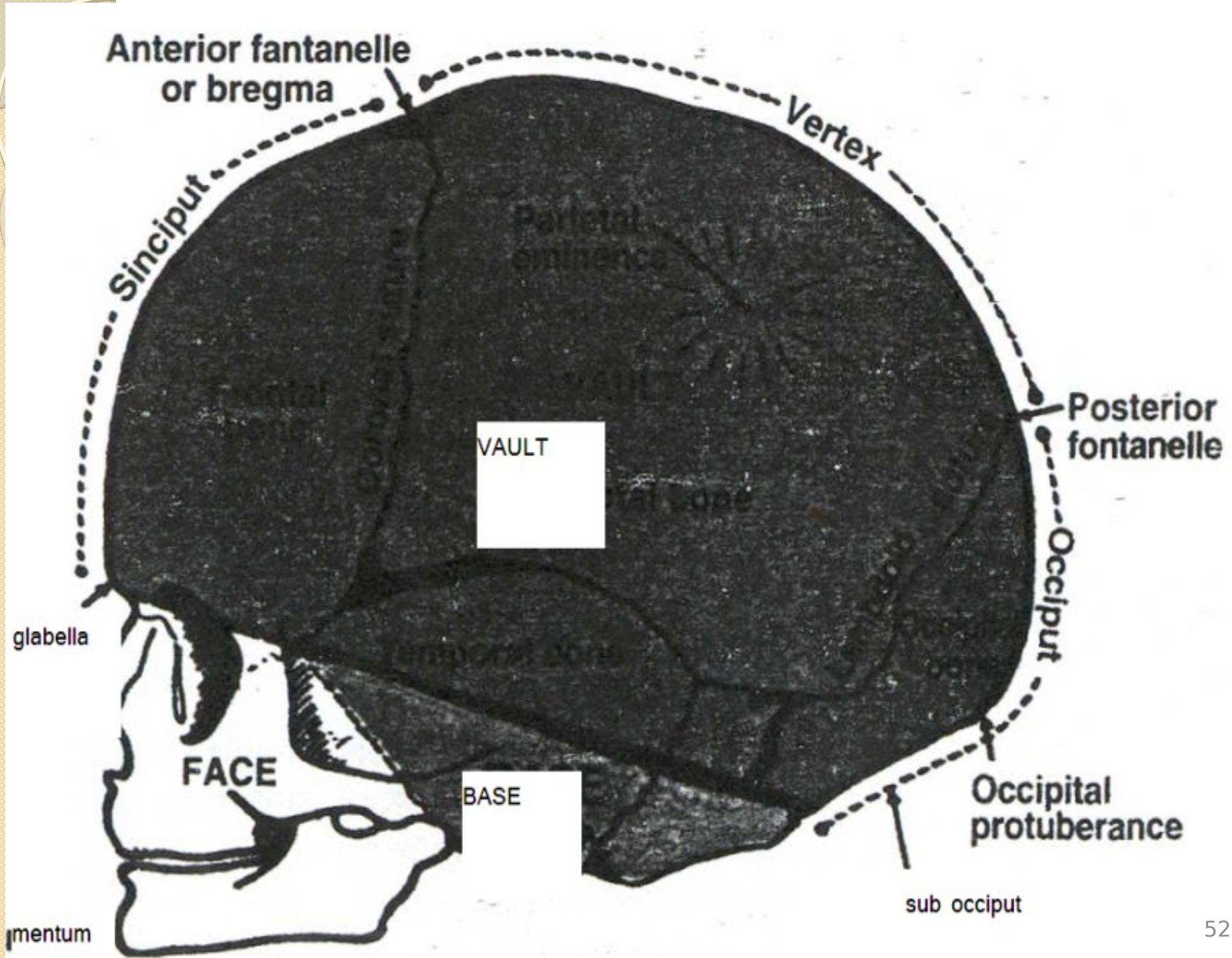
Anterior fantanelle
or bregma
Vertex
Sinciput
Posterior
fontanelle
Occiput
VAULT
glabella
FACE
BASE
Occipital
protuberance
sub occiput
mentum

Bones of the Vault

2 Frontal - which lie at the front

2 Parietal - which are at the sides

2 Temporal -

1 Occiput - which is at the back

- Each bone has an ossification centre, where growth started.
- The most important one is on the parietal bones and is known as the ***parietal eminences.***
- The Frontal bones fuse at 8 years old.

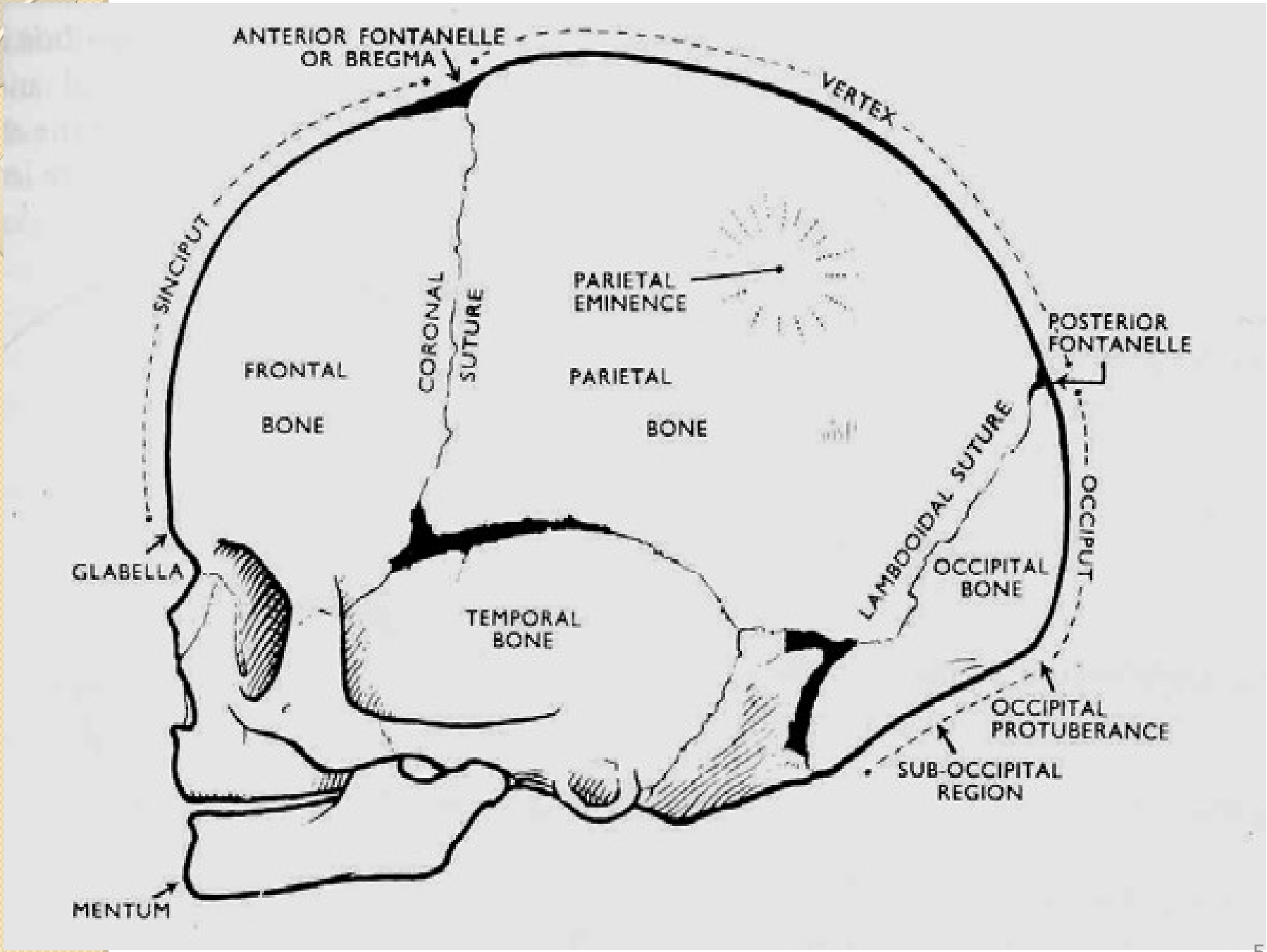
ANTERIOR FONTANELLE
OR BREGMA
VERTEX
SINCIPUT
CORONAL
SUTURE
PARIETAL
EMINENCE
POSTERIOR
FONTANELLE
FRONTAL
BONE
PARIETAL
BONE
LAMBDOIDAL SUTURE
OCCIPUT
GLABELLA
OCCIPITAL
BONE
TEMPORAL
BONE
OCCIPITAL
PROTUBERANCE
SUB-OCCIPITAL
REGION
MENTUM

Sutures and fontanels

- ***A suture***- is a membranous space between two bones of the skull. They are the cranial joints. There are 8 sutures on the fetal skull

  1 Frontal suture - between the Frontal bones

  1 Sagital suture - between the parietal bones

  2 Coronal sutures - between the frontal and parietal bones on each side.

  2 Temporal sutures - between the parietal and temporal bones.

  2 Lambdoidal sutures - between the parietal bones and the occiput.

Importance of sutures

- It permits gliding movement of one bone over the other during moulding of the head.

- Digital palpation of sagittal suture during internal examination in labor gives an idea of the manner of engagement of the head, degree of internal rotation of the head and degree of moulding of the head.

A Fontanel-is the area where two or more sutures meet. There are 6 fontanel's in the fetal skull; but only two are important.

- ***The Anterior Fontanel or Bregma -*** This is found at the junction of the sagital, coronal, and frontal sutures. It is 3 cm long, 1.5 cm wide and diamond shaped. It normally closes by the time the child is 18 months old. Pulsation of the cerebral vessels can be felt through it. Failure to ossify even after 24 month is pathological.

Importance of anterior fontanel

- Its palpation through the internal examination denotes the degree of flexion of the head
- It facilitate moulding of the head
- Palpation of the floor reflects intracranial status - depressed in dehydration, elevated in raised intracranial tension

The Posterior Fontanel or Lambda

- This is situated at the junction of the Lambdoidal and sagital sutures.
- It is small, triangular in shape and normally closes by the age when the child is 6 wks.

-The main function of posterior fontanel is to denote the ***position*** of head in relation to maternal pelvis.

Regions or land marks of the feotal skull

The vertex: -is the area on the fetal head w/c is bounded by the anterior fontanel, posterior fontanel and the two parietal eminences.

The sinciput or brow:- is the area on the fetal head covering the frontal bones.

- It extends from the anterior fontanel& the coronal suture to the orbital ridge.

The occiput: -is the area covering the occipital bone.

- It lies between the foramen magnum and the posterior fontanel.

  -The part below the occipital protuberance is called the sub- occipital region.

The face: - it extends from orbital ridges and the root of the nose (glabella) to the junction of the chin and the neck.

The chin: -is also termed as a mentum and is an important land mark

Diameters of the feotal skull

A diameter of the fetal skull is a measurement from one point to another. There are two types:

Longitudinal

- ***Sub Occipito Bregmatic - 9.5 cm.***

  Is from below the occipital protuberance to the center of the Bregma.

- ***Sub Occipito Frontal - 10 cm.***

  From below the occipital protuberance to the center of the frontal suture

- ***Occipito Frontal - 11. 5 cm.***

  Is from the occipital protuberance to the glabella

- ***Sub Mento Bregmatic - 9.5 cm***

  Is from the point where the chin joins the neck to the center of the bregma.

- ***Sub Mento Vertical - 11.5 cm***

  Is from the point where the chin join the neck to the highest point on the vertex

- ***Mento Vertical - l3. 5 cm.***

  Is from the point of the chin to the highest point of the vertex.

Transverse

- ***Bi Parietals - 9.5 cm.***

  -Is measured between the two parietal eminences.

- ***Bi Temporal - 8.2 cm.***

  -Is measured between the furthest points of the coronal sutures at the temples

Presenting Diameters

- ***Sub Occipito – Bregmatic - 9.5cm*** - engages in a ***well flexed vertex*** presentation.
- ***Sub Occipito - Frontal - 10 cm*** - engages in a ***moderately flexed vertex*** presentation
- ***Occipito – Frontal - 11. 5 cm*** - engages in a ***badly flexed vertex*** presentation
- ***Sub Mento - Bregmatic - 9.5 cm*** - engages in a ***well extended face*** presentation.
- ***SubMento Vertical - 11.5 cm*** - engages in ***a badly extended face*** presentation
- ***Mento vertical – 13.5 cm*** – engage in ***partial extension brow*** presentation

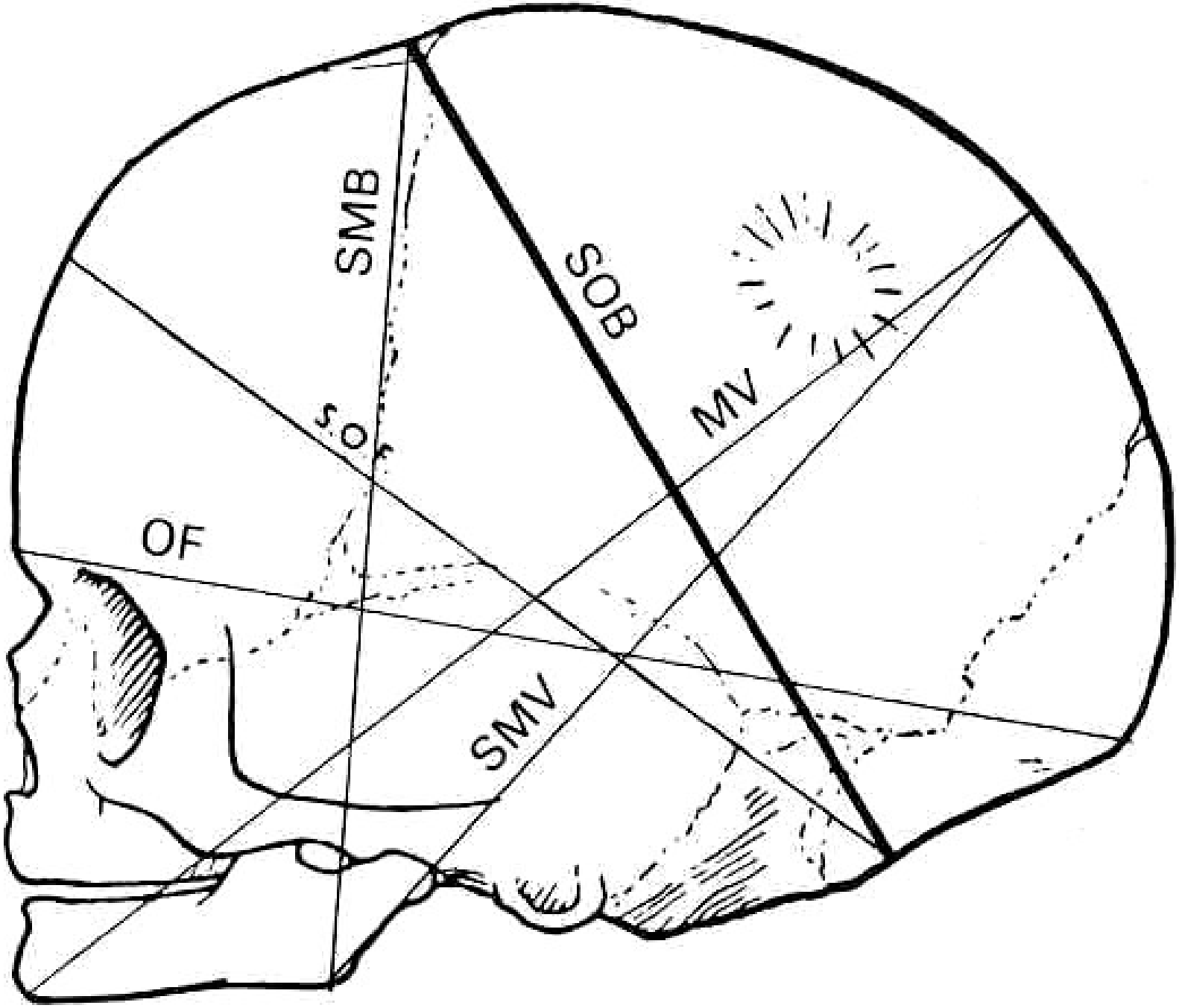
SMB
SOB
MV
S.O.
OF
SMV