Erector Spinae Plane Block For Pain Management

By
Mohamed Abuelnaga
Lecturer Of Anesthesia
Suez Canal University

Introduction

In 2016 Erector spinae plane block (ESB) was first described by **Mauricio Forero, et al** as an ultrasound-guided interfascial plane block to successfully treat severe thoracic neuropathic pain.

In 2017 and 2018, ESB has been described in case reports in multiple clinical scenarios including cervical ,thoracic ,abdominal and pelvic pain conditions .

CHRONIC AND INTERVENTIONAL PAIN

BRIEF TECHNICAL REPORT

The Erector Spinae Plane Block

A Novel Analgesic Technique in Thoracic Neuropathic Pain

Mauricio Forero, MD, FIPP, Sanjib D. Adhikary, MD,† Hector Lopez, MD,‡ Calvin Tsui, BMSc,§ and Ki Jinn Chin, MBBS (Hons), MMed, FRCPC||*

Regional Anesthesia and Pain Medicine • Volume 41, Number 5, September-October 2016

Anaesthesia 2017 doi:10.1111/anae.13814

Original Article

The analgesic efficacy of pre-operative bilateral erector spinae plane (ESP) blocks in patients having ventral hernia repair

K. J. Chin,[1] S. Adhikary,[2] N. Sarwani[3] and M. Forero[4]

1 Associate Professor, Department of Anaesthesia, Toronto Western Hospital, University of Toronto, Toronto, Ontario, Canada
2 Associate Professor, Department of Anesthesiology and Perioperative Medicine, 3 Associate Professor, Department of Radiology, Penn State Hershey College of Medicine, Hershey, Pennsylvania, USA
4 Associate Professor, Department of Anaesthesia, McMaster University, Hamilton, Ontario, Canada

Correspondence to: K. J. Chin
Email: gasgenie@gmail.com
Accepted: 19 December 2016
Keywords: laparoscopy; nerve block; pain management; regional anaesthesia
This article is accompanied by an editorial by El-Boghdadly and Pawa, Anaesthesia 2017; 72: doi:10.1111/anae.13830.

BJA
British Journal of Anaesthesia



Volume 118, Issue 3

Erector spinae plane block for pain relief in rib fractures

D. L. Hamilton ✉, B. Manickam

BJA: British Journal of Anaesthesia, Volume 118, Issue 3, 1 March 2017, Pages 474–475,
https://doi.org/10.1093/bja/aex013
Published: 16 February 2017

Can J Anesth/J Can Anesth (2017) 64:880–882
DOI 10.1007/s12630-017-0894-0

CORRESPONDENCE

Erector spinae plane block for postoperative analgesia in pediatric oncological thoracic surgery

Felipe Muñoz, MD · Javier Cubillos, MD · Antonio J. Bonilla, MD · Ki Jinn Chin, MBBS, MMED, FRCPC

Received: 23 February 2017 / Revised: 18 April 2017 / Accepted: 21 April 2017 / Published online: 26 April 2017
© Canadian Anesthesiologists' Society 2017

CASE REPORT

Continuous Erector Spinae Plane Block for Rescue Analgesia in Thoracotomy After Epidural Failure: A Case Report

Mauricio Forero, MD, FIPP,* Manikandan Rajarathinam, MD,* Sanjib Adhikary, MD,† and Ki Jinn Chin, MBBS (Hons), MMed, FRCPC‡

cases-anesthesia-analgesia.org May 15, 2017

REGIONAL ANESTHESIA AND ACUTE PAIN

CASE REPORT

The Erector Spinae Plane Block Provides Visceral Abdominal Analgesia in Bariatric Surgery

A Report of 3 Cases

Ki Jinn Chin, MBBS(Hons), FRCPC, Laith Malhas, MBChB, FRCA, and Anahi Perlas, MD, FRCPC

Regional Anesthesia and Pain Medicine • Volume 42, Number 3, May-June 2017

regional anesthesia & pain medicine

Welcome Ovid Subscriber!

Your institution's Ovid subscription entitles you to view the full text of articles on the Regional Anesthesia and Pain Medicine journal website.

< Previous Article | Next Article >

The Ultrasound-Guided Continuous Erector Spinae Plane Block for Postoperative Analgesia in Video-Assisted Thoracoscopic Lobectomy

Scimia, Paolo MD; Basso Ricci, Erika MD; Droghetti, Andrea MD; Fusco, Pierfrancesco MD

Regional Anesthesia and Pain Medicine: July/August 2017 - Volume 42 - Issue 4 - p 537

Journal of Clinical Anesthesia 44 (2018) 1–2



Contents lists available at ScienceDirect

Journal of Clinical Anesthesia

Correspondence

Continuous erector spinae plane block provides effective perioperative analgesia for breast reconstruction using tissue expanders: A report of two cases

Keywords:
Erector spinae plane block
Breast cancer
Breast reconstruction surgery
Expander
Analgesia

1 September 2017

Journal of Clinical Anesthesia 44 (2018) 68



Contents lists available at ScienceDirect

Journal of Clinical Anesthesia

Correspondence

Ultrasound guided Erector Spinae Plane block at L-4 transverse process level provides effective postoperative analgesia for total hip arthroplasty



23 October 2017

Can J Anesth/J Can Anesth (2018) 65:288–293
DOI 10.1007/s12630-017-1010-1

CASE REPORTS / CASE SERIES

Erector spinae plane block for the management of chronic shoulder pain: a case report

Bloc du plan des muscles érecteurs du rachis pour la prise en charge de la douleur chronique à l'épaule : une présentation de cas

Mauricio Forero, MD, FIPP · Manikandan Rajarathinam, MD, FIPP · Sanjib Das Adhikary, MD · Ki Jinn Chin, MBBS (Hons), MMed, FRCPC

Received: 28 September 2017 / Accepted: 2 November 2017 / Published online: 13 November 2017
© Canadian Anesthesiologists' Society 2017

CASE REPORT

Bilateral Continuous Erector Spinae Plane Block Contributes to Effective Postoperative Analgesia After Major Open Abdominal Surgery: A Case Report

Carlos Eduardo Restrepo-Garces, MD,* Ki Jinn Chin, MBBS (Hons), MMed, FRCPC,† Patricia Suarez, MD,‡ and Alejandro Diaz, MD§

December 1, 2017 cases-anesthesia-analgesia.org

Journal of Clinical Anesthesia 46 (2018) 63–64

Contents lists available at ScienceDirect

Journal of Clinical Anesthesia

journal homepage: www.elsevier.com/locate/jclinane

Correspondence

Ultrasound guided continuous erector spinae plane block for pain management in pulmonary malignancy☆

https://doi.org/10.1016/j.jclinane.2018.01.023
Received 8 January 2018; Received in revised form 16 January 2018; Accepted 18 January 2018
0952-8180/ © 2018 Elsevier Inc. All rights reserved.

Journal of Clinical Anesthesia
Volume 45, March 2018, Pages 35-36



Correspondence

Ultrasound guided erector spinae block for postoperative analgesia in pediatric nephrectomy surgeries

Can Aksu (Asistant Professor), Yavuz Gürkan (Professor)

Contents lists available at ScienceDirect

Journal of Clinical Anesthesia

journal homepage: www.elsevier.com/locate/jclinane

Correspondence

Erector spinae plane block for carotid endarterectomy

ARTICLE INFO

Keywords:
Carotid artery endarterectomy
Nerve block
Erector spinae muscle

* Corresponding author at: Department of Anesthesiology, Showa University Hospital, 142-8666, Hatanodai Shinagawa-ku, Tokyo, Japan.

https://doi.org/10.1016/j.jclinane.2018.04.004
Received 29 March 2018; Accepted 14 April 2018
0952-8180/ © 2018 Elsevier Inc. All rights reserved.

Journal of Clinical Anesthesia

Ultrasound guided low thoracic erector spinae plane block for postoperative analgesia in radical retropubic prostatectomy, a new indication

Serkan Tulgar, Ozgur Senturk

Maltepe University Faculty of Medicine, Department of Anesthesiology and Reanimation, Istanbul, Turkey

Anatomy of back muscles



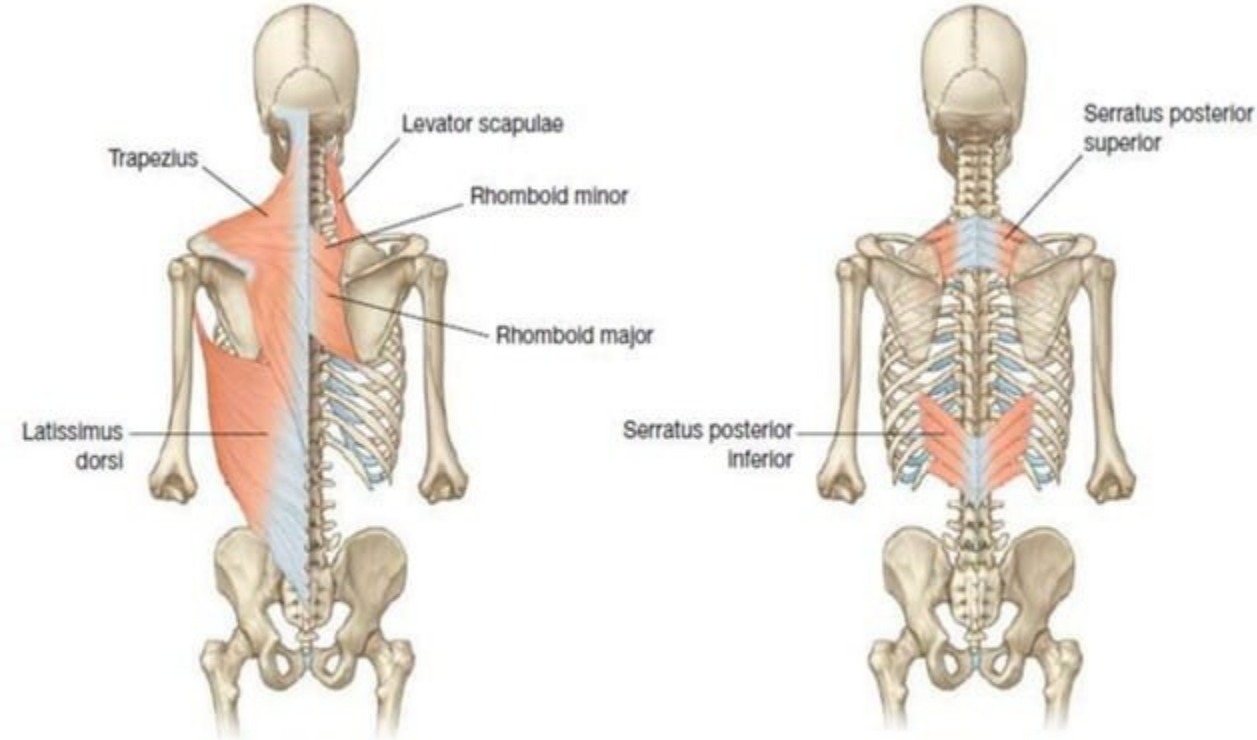
Trapezius
Levator scapulae
Rhomboid minor
Rhomboid major
Latissimus dorsi
Serratus posterior superior
Serratus posterior inferior
Superficial group
Intermediate group
Extrinsic muscles
Innervated by anterior rami of spinal nerves or cranial nerve XI (trapezius)

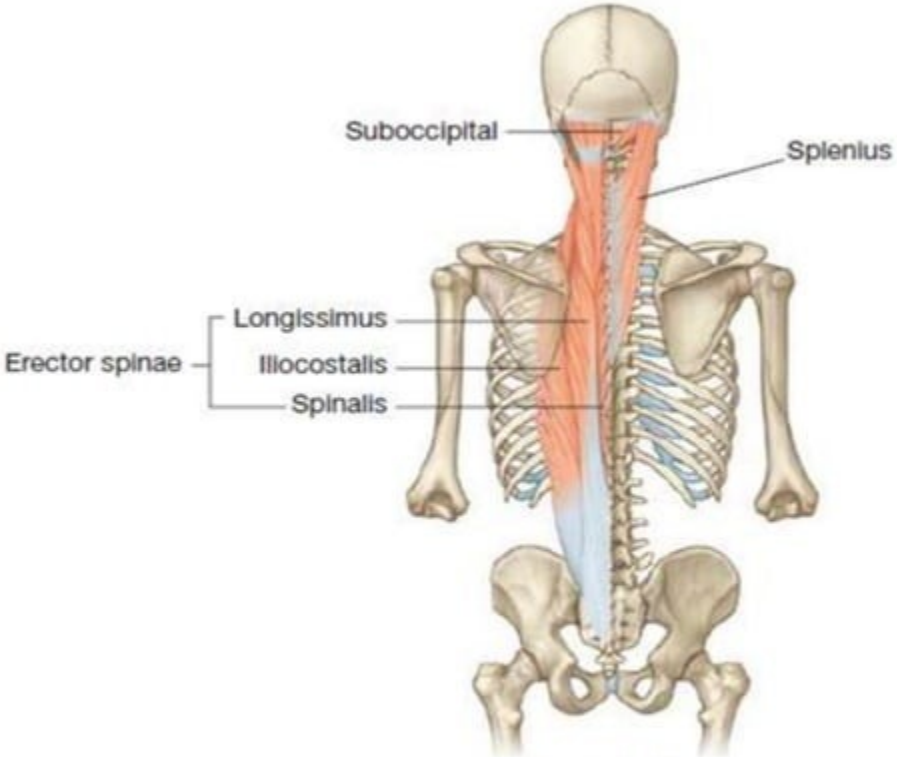

Deep group

↓

Intrinsic muscles

True back muscles innervated by posterior rami of spinal nerves

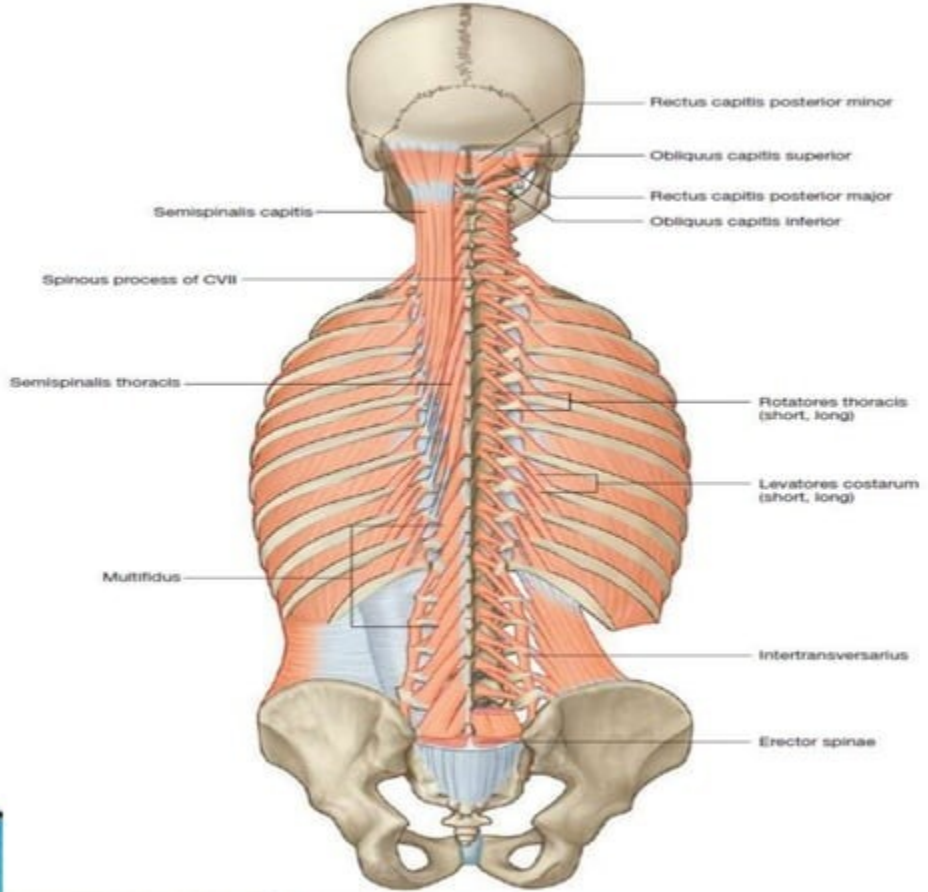
Rectus capitis posterior minor
Obliquus capitis superior
Rectus capitis posterior major
Obliquus capitis inferior
Semispinalis capitis
Spinous process of CVII
Semispinalis thoracis
Rotatores thoracis (short, long)
Levatores costarum (short, long)
Multifidus
Intertransversarius
Erector spinae

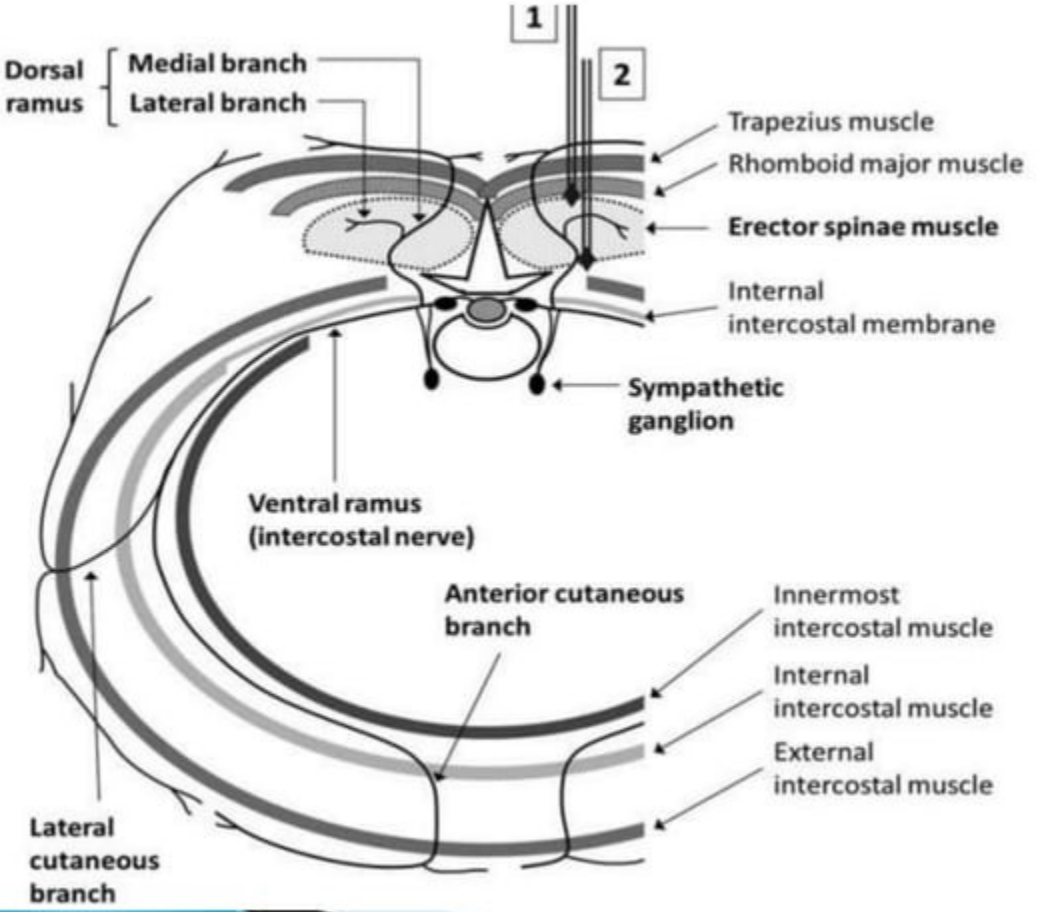
1
2
Dorsal ramus
Medial branch
Lateral branch
Trapezius muscle
Rhomboid major muscle
Erector spinae muscle
Internal intercostal membrane
Sympathetic ganglion
Ventral ramus (intercostal nerve)
Anterior cutaneous branch
Innermost intercostal muscle
Internal intercostal muscle
External intercostal muscle
Lateral cutaneous branch

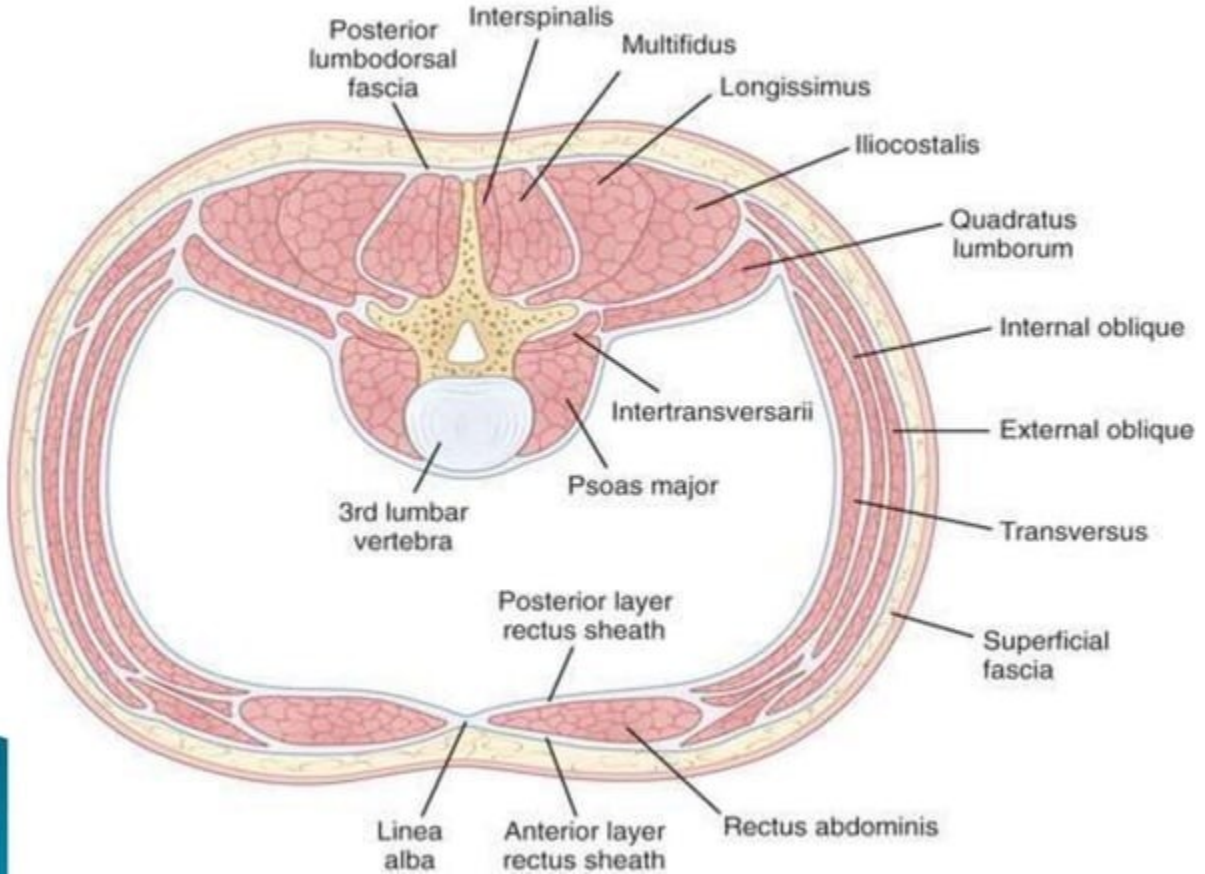
Posterior lumbodorsal fascia
Interspinalis
Multifidus
Longissimus
Iliocostalis
Quadratus lumborum
Internal oblique
External oblique
Transversus
Superficial fascia
Intertransversarii
Psoas major
3rd lumbar vertebra
Posterior layer rectus sheath
Linea alba
Anterior layer rectus sheath
Rectus abdominis

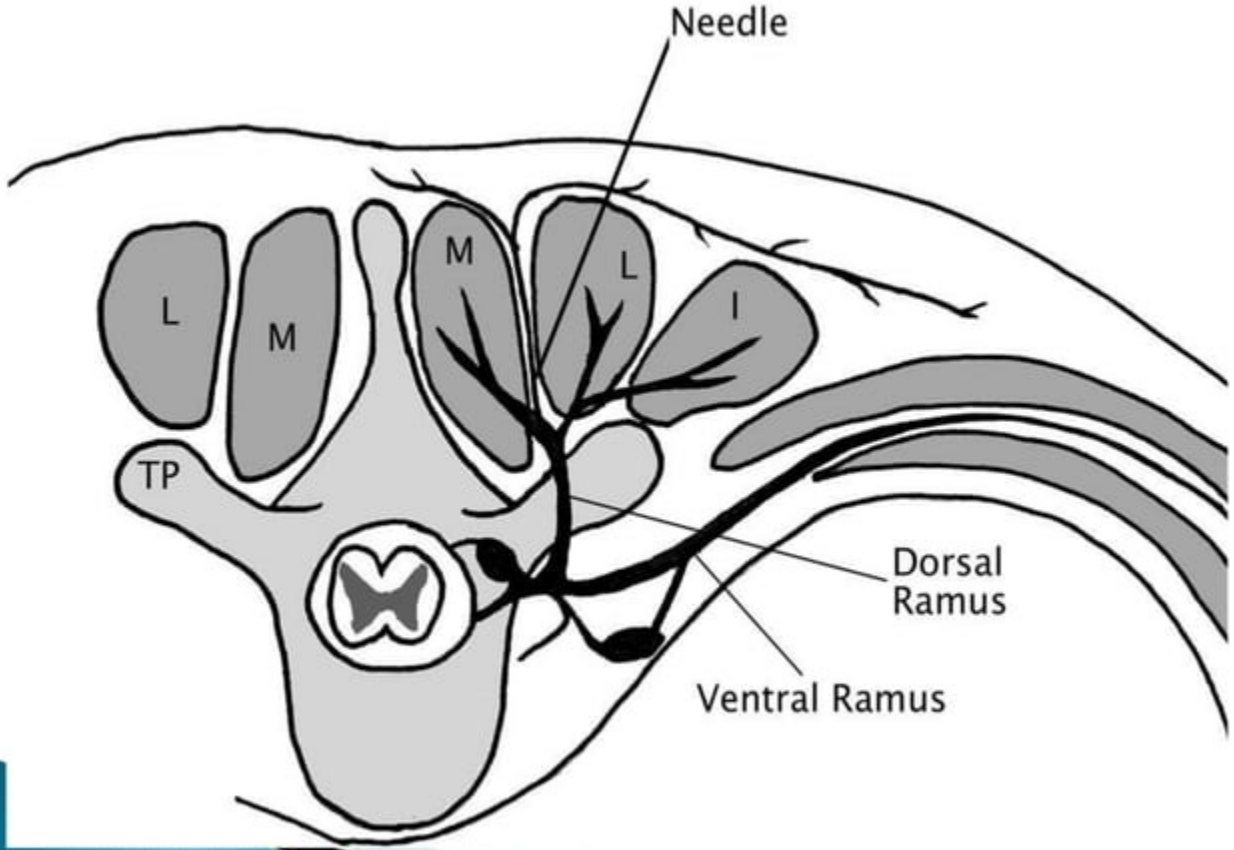
Needle
L
M
M
L
I
TP
Dorsal
Ramus
Ventral Ramus

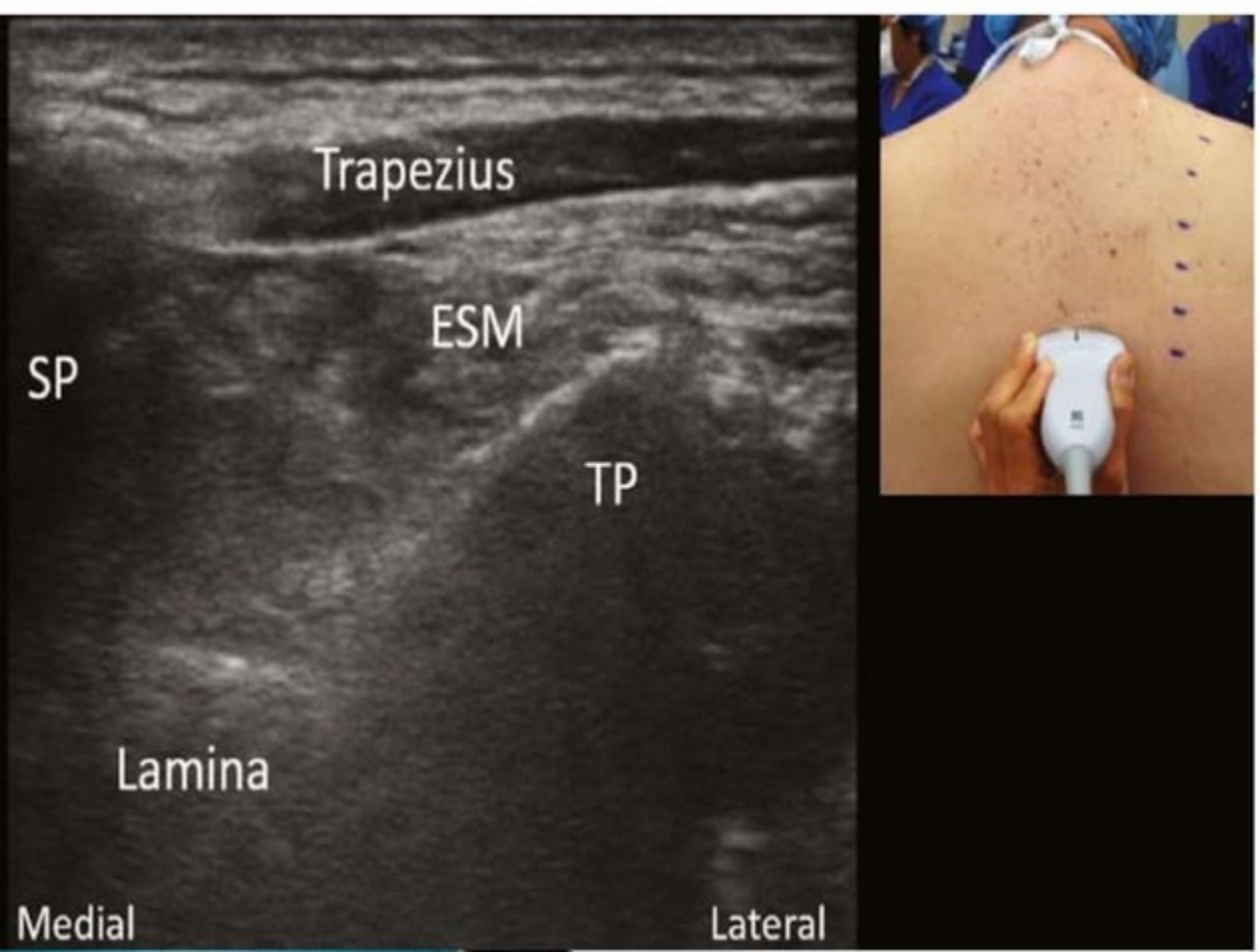
Trapezius
ESM
SP
TP
Lamina
Medial
Lateral


Trapezius
ESM
TP
Cranial
Caudad

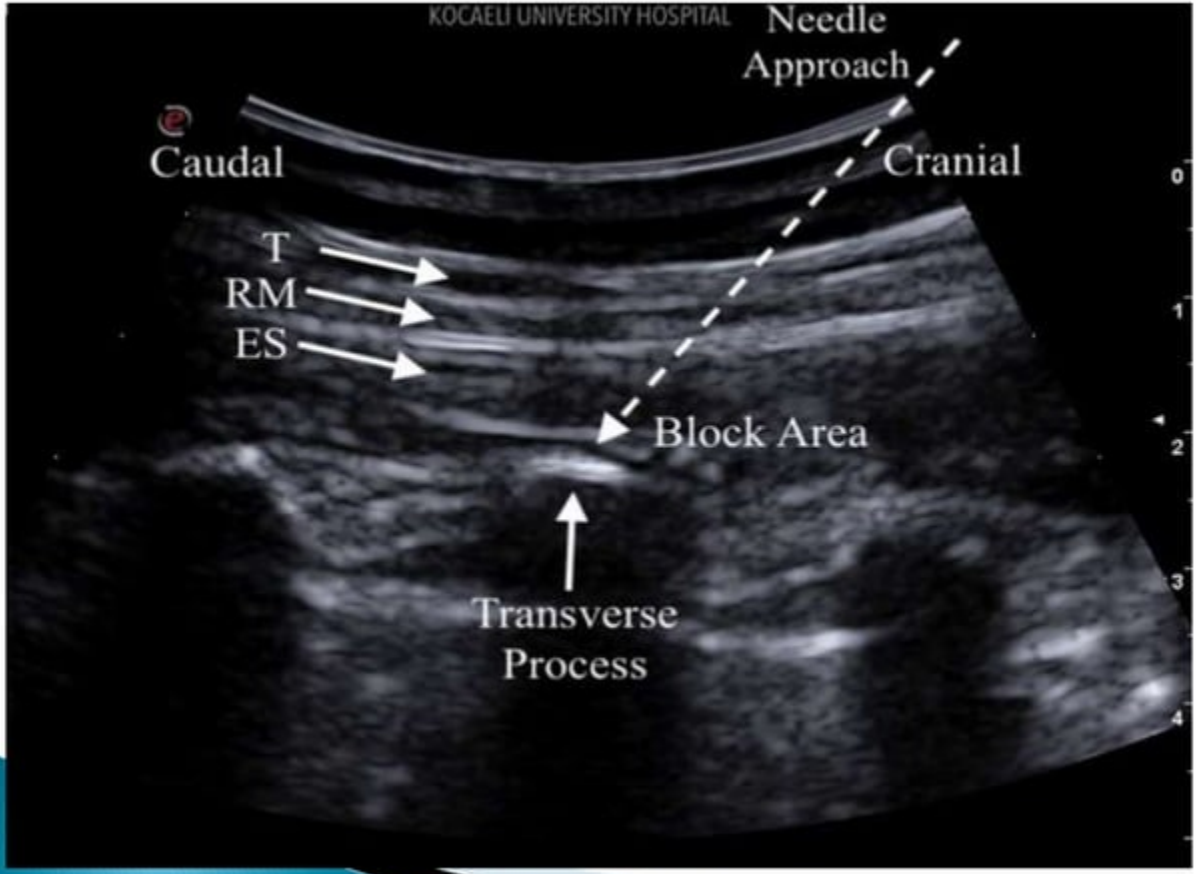
KOCAELI UNIVERSITY HOSPITAL
Needle
Approach
Caudal
Cranial
T
RM
ES
Block Area
Transverse
Process

Block Technique

Described by Forero et al,

1st approach:

Patient complaint: burning and stabbing neuropathic pain of 10/10 severity on the NRS radiating from his spine into the anterior chest wall, mainly at T5 and extending several dermatomes inferiorly

Position :sitting position

Level :transverse process of T5

US probe: high frequency linear

Plane :parasagittal 3 cm lateral to the midline

Land marks : Three muscles were identified superficial to the hyperechoic transverse process shadow as follows: trapezius, rhomboid major, and erector spinae

Needle :8-cm 22-gauge block needle inserted in a cephalad to caudad direction

Drug :20 mL of 0.25% bupivacaine injected in the interfascial plane between rhomboid major and erector spinae muscles

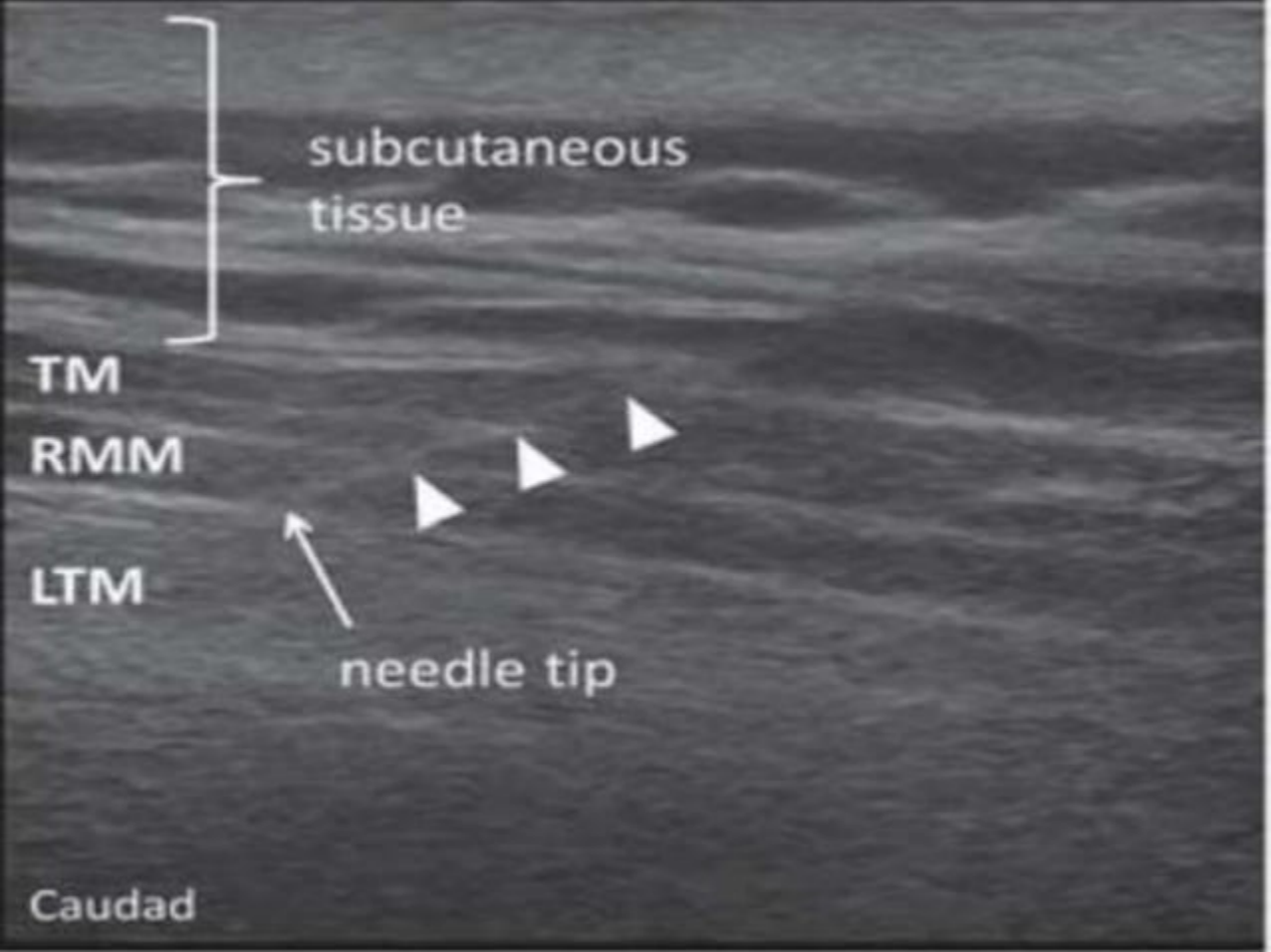
subcutaneous
tissue
TM
RMM
LTM
needle tip
Caudad

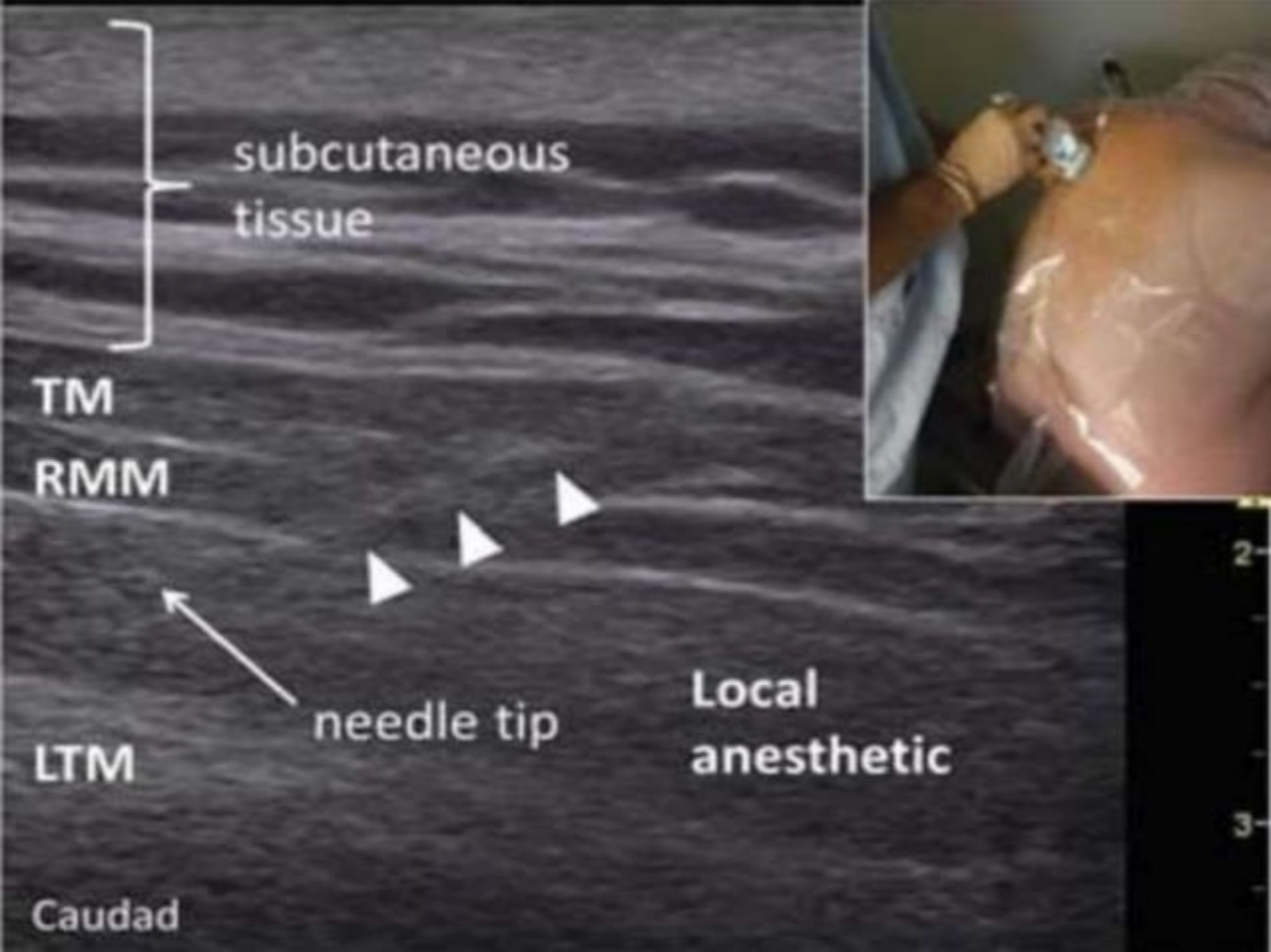
subcutaneous
tissue
TM
RMM
needle tip
LTM
Local
anesthetic
Caudad
2
3

Results :

Within several minutes pain had diminished significantly. NRS became 0/10 over 2 hours

There was an area of diminished sensation to pinprick extending from T2 to T9 in a cephalo-caudad direction, and from a line 3 cm lateral to the thoracic spine to the midclavicular line in an anterior-posterior direction . The axilla and medial aspect of the upper arm also exhibited sensory blockade.

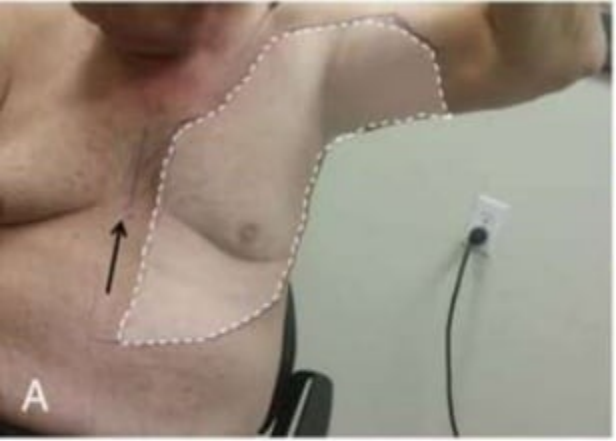
A


B


SRA
C

2nd approach:




12/08/18 22:47:37
MI 0.5
TIs 0.5
12L-RS
Small Parts
B
CHI
Frq
12.0 MHz
Gn
44
E/A
3/2
Map
L/0
D
3.5 cm
DR
87
FR
24 Hz
AO
100 %
XBeam On
BStr
+ Off
2
3
(19.6:19.6 s)
eric Worksheet

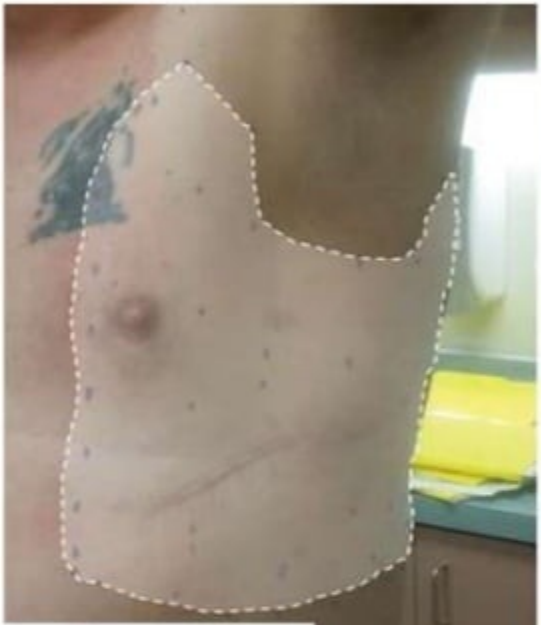

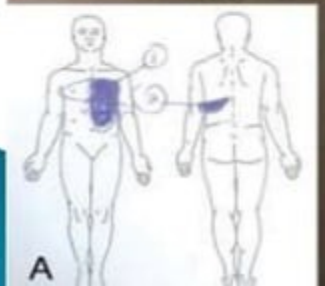
A

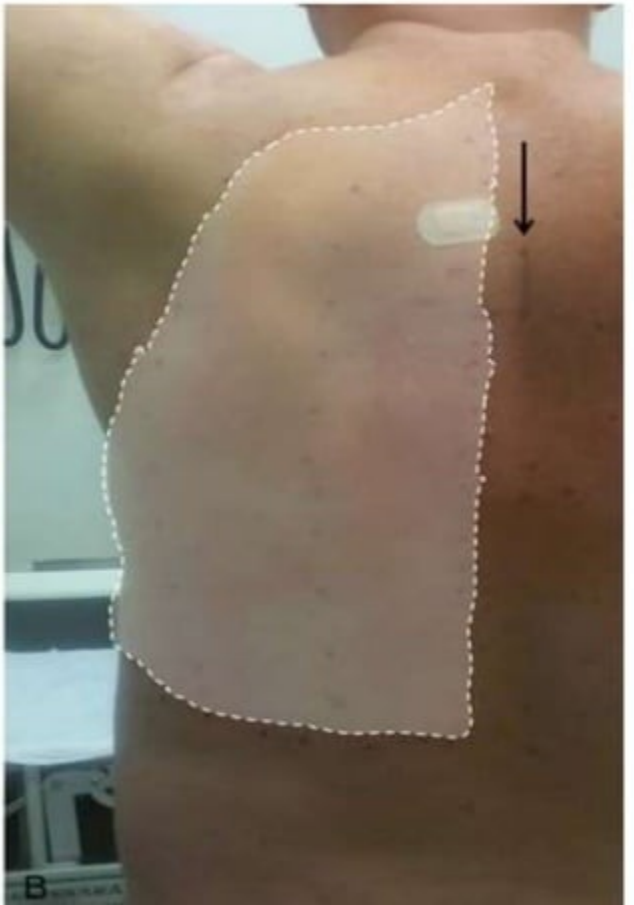
B

Cadaveric study for LA spread in ESP :

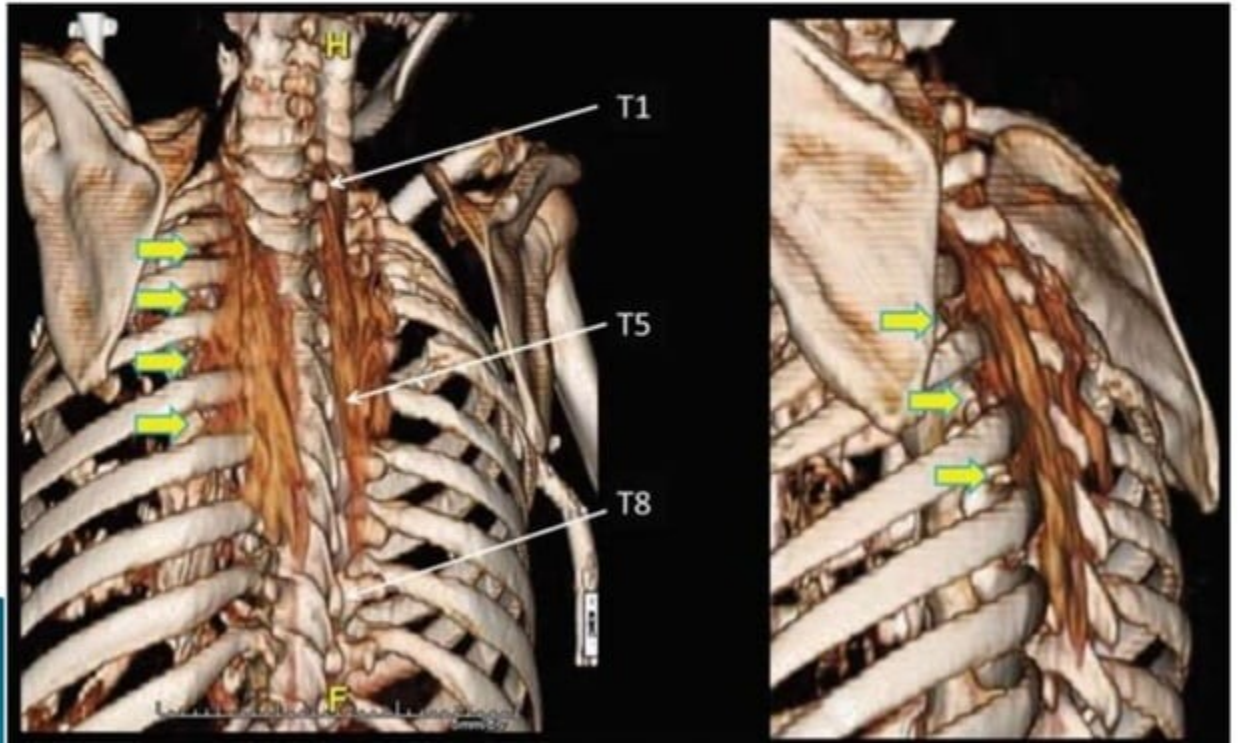

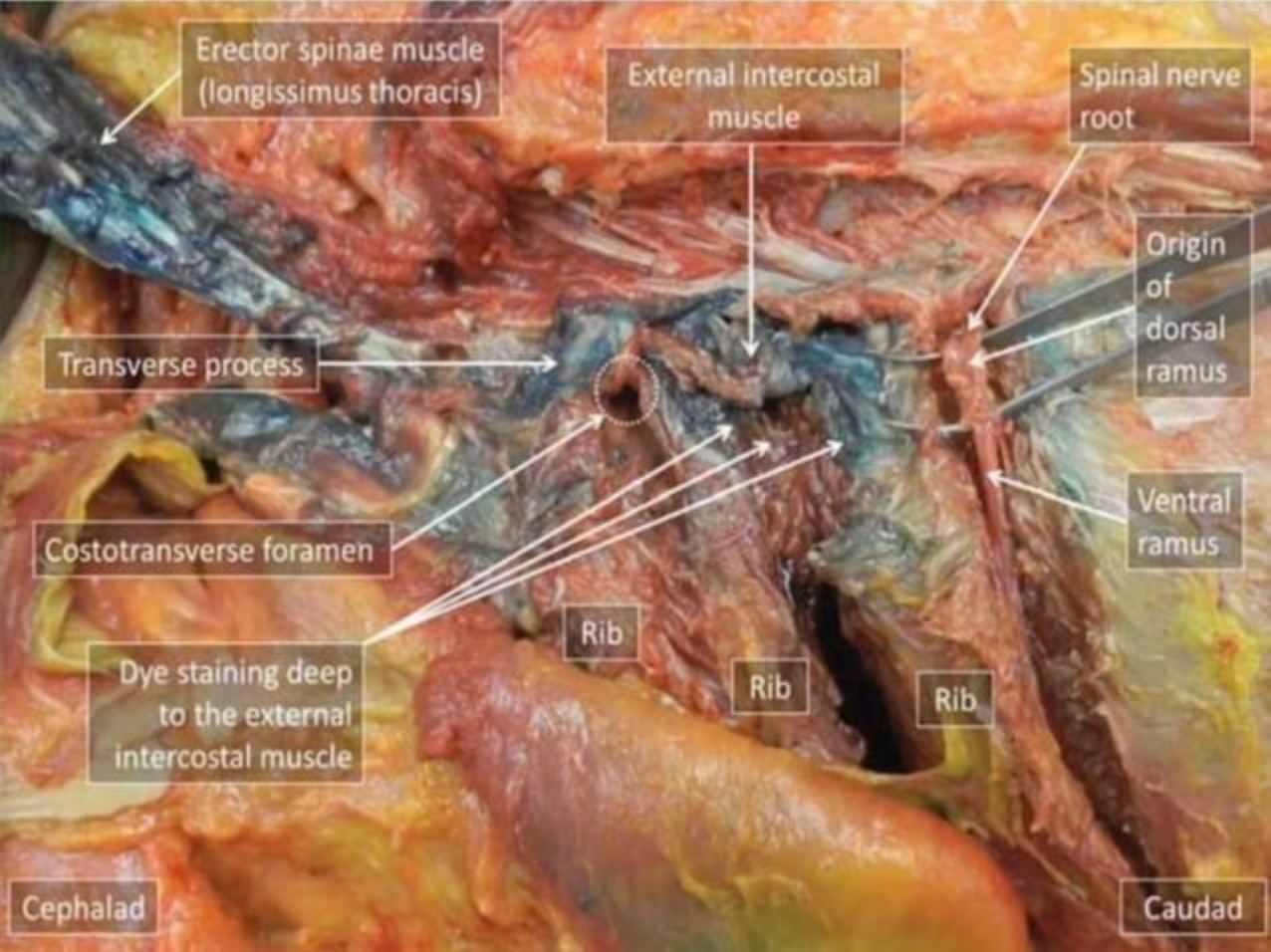
Erector spinae muscle (longissimus thoracis)
External intercostal muscle
Spinal nerve root
Origin of dorsal ramus
Transverse process
Costotransverse foramen
Ventral ramus
Dye staining deep to the external intercostal muscle
Rib
Rib
Rib
Cephalad
Caudad

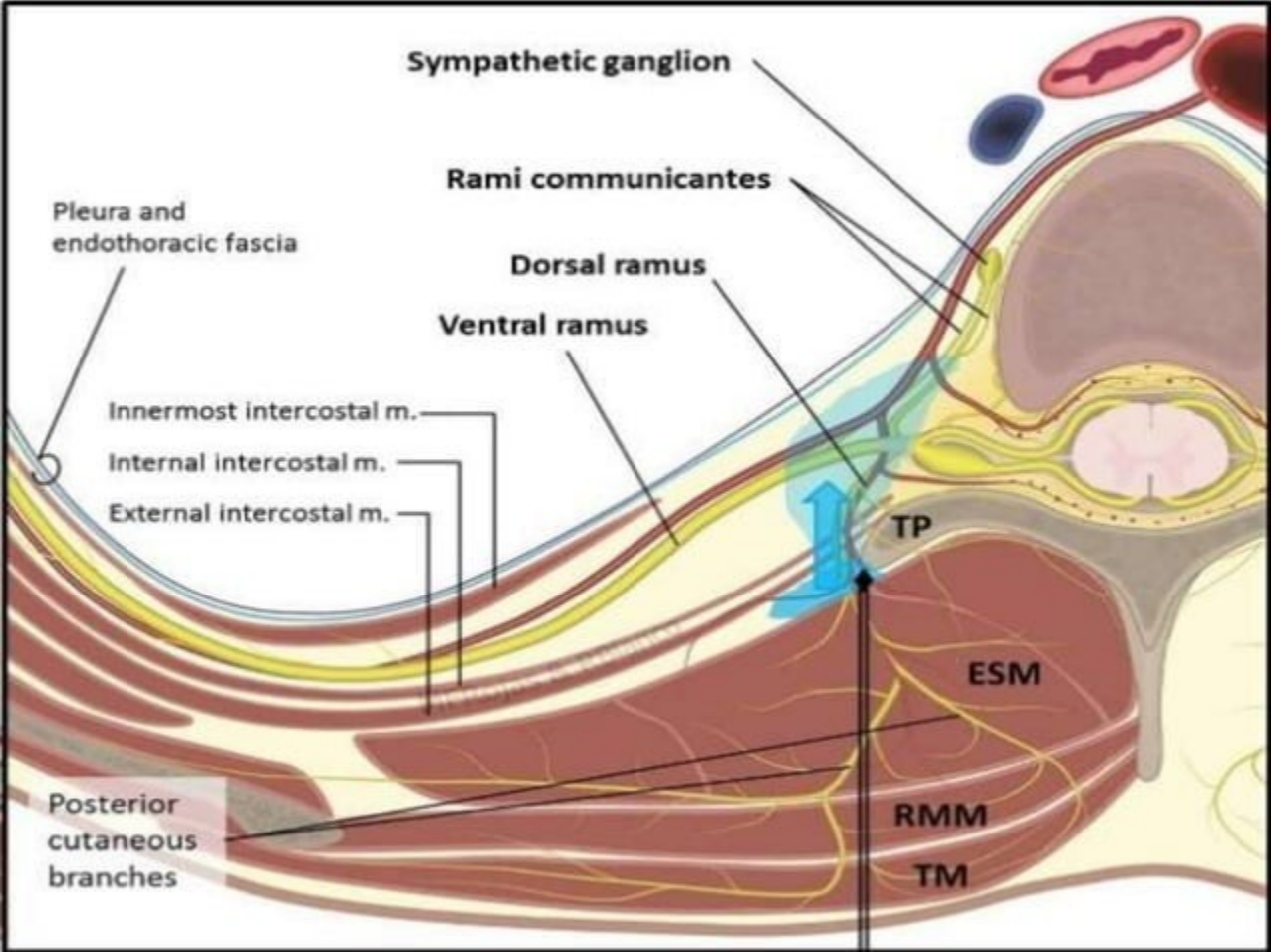
Sympathetic ganglion
Rami communicantes
Pleura and endothoracic fascia
Dorsal ramus
Ventral ramus
Innermost intercostal m.
Internal intercostal m.
External intercostal m.
TP
ESM
Posterior cutaneous branches
RMM
TM

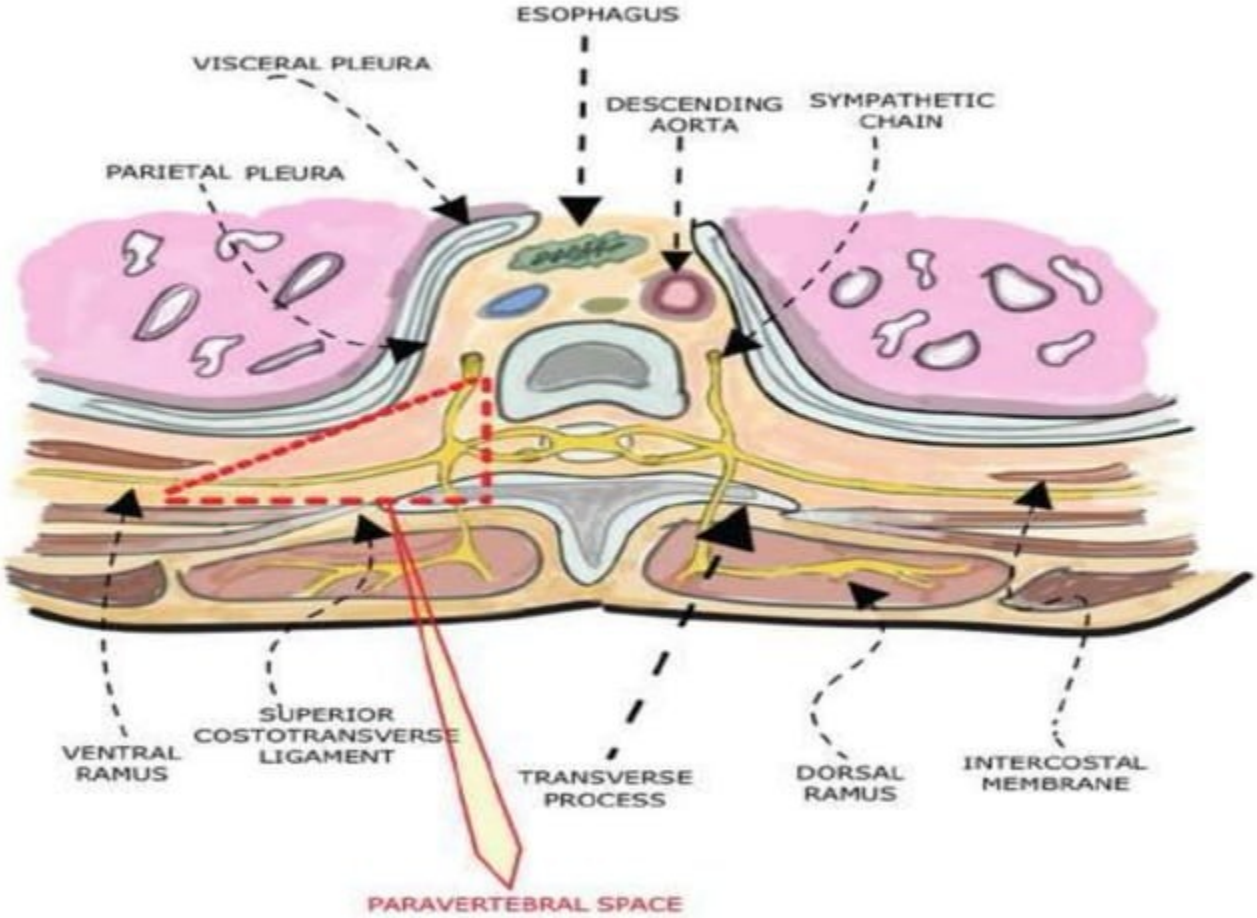
ESOPHAGUS
VISCERAL PLEURA
DESCENDING AORTA
SYMPATHETIC CHAIN
PARIETAL PLEURA
VENTRAL RAMUS
SUPERIOR COSTOTRANSVERSE LIGAMENT
TRANSVERSE PROCESS
DORSAL RAMUS
INTERCOSTAL MEMBRANE
PARAVERTEBRAL SPACE

ESP block for abdominal surgery

Anaesthesia 2017 doi:10.1111/anae.13814

Original Article

The analgesic efficacy of pre-operative bilateral erector spinae plane (ESP) blocks in patients having ventral hernia repair

K. J. Chin,[1] S. Adhikary,[2] N. Sarwani[3] and M. Forero[4]

1 Associate Professor, Department of Anaesthesia, Toronto Western Hospital, University of Toronto, Toronto, Ontario, Canada
2 Associate Professor, Department of Anesthesiology and Perioperative Medicine, 3 Associate Professor, Department of Radiology, Penn State Hershey College of Medicine, Hershey, Pennsylvania, USA
4 Associate Professor, Department of Anaesthesia, McMaster University, Hamilton, Ontario, Canada

Correspondence to: K. J. Chin
Email: gasgenie@gmail.com

Accepted: 19 December 2016
Keywords: laparoscopy; nerve block; pain management; regional anaesthesia
This article is accompanied by an editorial by El-Boghdadly and Pawa, Anaesthesia 2017; 72: doi:10.1111/anae.13830.

Ingection at T7 TP

Sensory loss between C5 and L2

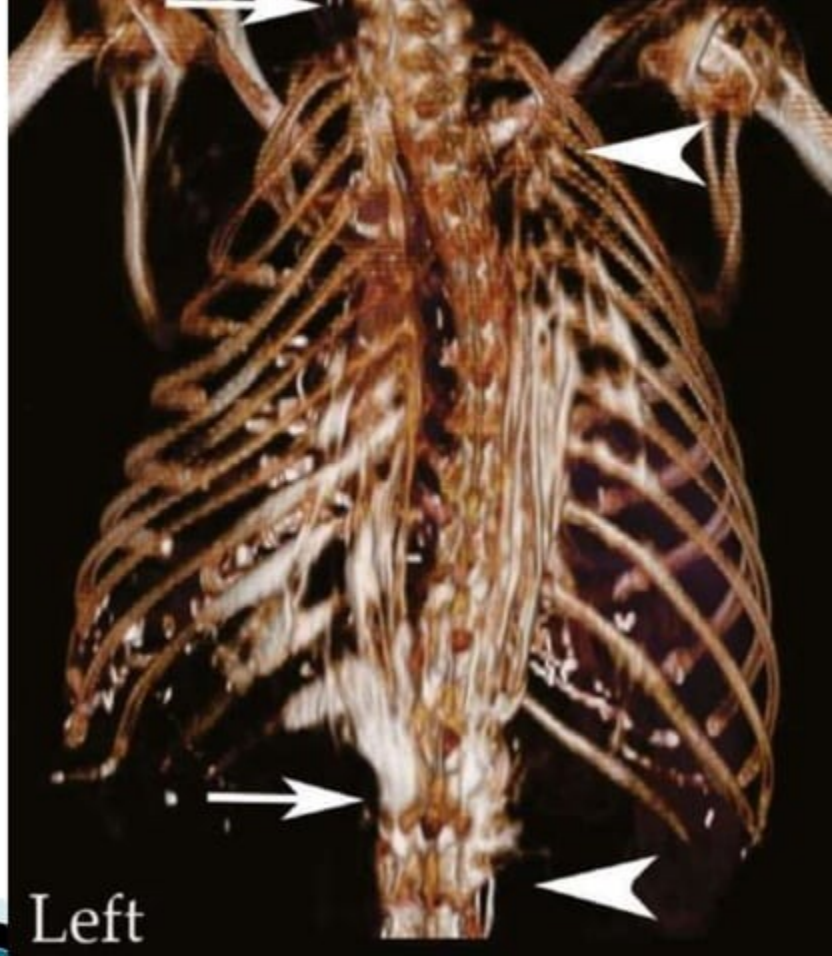

Journal of Clinical Anesthesia 48 (2018) 11

Contents lists available at ScienceDirect

Journal of Clinical Anesthesia

journal homepage: www.elsevier.com/locate/jclinane

Correspondence

Erector spinae plane block for carotid endarterectomy

ARTICLE INFO

Keywords:
Carotid artery endarterectomy
Nerve block
Erector spinae muscle



Can J Anesth/J Can Anesth (2018) 65:288–293
DOI 10.1007/s12630-017-1010-1

CASE REPORTS / CASE SERIES

Erector spinae plane block for the management of chronic shoulder pain: a case report

Bloc du plan des muscles érecteurs du rachis pour la prise en charge de la douleur chronique à l'épaule : une présentation de cas

Mauricio Forero, MD, FIPP · Manikandan Rajarathinam, MD, FIPP · Sanjib Das Adhikary, MD · Ki Jinn Chin, MBBS (Hons), MMed, FRCPC

Received: 28 September 2017 / Accepted: 2 November 2017 / Published online: 13 November 2017
© Canadian Anesthesiologists' Society 2017

20 ml Injection at T3 TP





Journal of Clinical Anesthesia 49 (2018) 101–106

Contents lists available at ScienceDirect

Journal of Clinical Anesthesia

journal homepage: www.elsevier.com/locate/jclinane

Original Contribution

Evaluation of ultrasound-guided erector spinae plane block for postoperative analgesia in laparoscopic cholecystectomy: A prospective, randomized, controlled clinical trial

Serkan Tulgar[a,*], Mahmut Sertan Kapakli[b], Ozgur Senturk[a], Onur Selvi[a], Talat Ercan Serifsoy[a], Zeliha Ozer[a]

[a] Maltepe University Faculty of Medicine, Department of Anesthesiology and Reanimation, Istanbul, Turkey
[b] Maltepe University Faculty of Medicine, Department of General Surgery, Istanbul, Turkey

8 June 2018

Journal of Clinical Anesthesia 50 (2018) 65–68

Contents lists available at ScienceDirect

Journal of Clinical Anesthesia

journal homepage: www.elsevier.com/locate/jclinane

Original Contribution

Ultrasound guided erector spinae plane block reduces postoperative opioid consumption following breast surgery: A randomized controlled study

Yavuz Gürkan, Can Aksu*, Alparslan Kuş, Ufuk H. Yörükoğlu, Cennet T. Kılıç

Department of Anesthesiology and Reanimation, School of Medicine, Kocaeli University, Kocaeli, Turkey

15 June 2018

Original Article: Janak Mehta Award

Comparison of Continuous Thoracic Epidural Analgesia with Bilateral Erector Spinae Plane Block for Perioperative Pain Management in Cardiac Surgery

Abstract

Objective: Continuous thoracic epidural analgesia (TEA) is compared with erector spinae plane (ESP) block for the perioperative pain management in patients undergoing cardiac surgery for the quality of analgesia, incentive spirometry, ventilator duration, and intensive care unit (ICU) duration. **Methodology:** A prospective, randomized comparative clinical study was conducted. A total of 50 patients were enrolled, who were randomized to either Group A: TEA ($n = 25$) or Group B: ESP block ($n = 25$). Visual analog scale (VAS) was recorded in both the groups during rest and cough at the various time intervals postextubation. Both the groups were also compared for incentive spirometry, ventilator, and ICU duration. Statistical analysis was performed using the independent Student's *t*-test. A value of $P < 0.05$ was considered statistically significant. **Results:** Comparable VAS scores were revealed at 0 h, 3 h, 6 h, and 12 h ($P > 0.05$) at rest and during cough in both the groups. Group A had a statistically significant VAS score than Group B ($P \leq 0.05$) at 24 h, 36 h, and 48 h but mean VAS in either of the Group was ≤4 both at rest and during cough. Incentive spirometry, ventilator, and ICU duration were comparable between the groups. **Conclusion:** ESP

PS Nagaraja, S Ragavendran, Naveen G Singh, Omshubham Asai, G Bhavya, N Manjunath, K Rajesh[1]

Departments of Cardiac Anaesthesiology and [1]CTVS, Sri Jayadeva Institute of Cardiovascular Sciences and Research, Bengaluru, Karnataka, India

July 25, 2018: Annals of Cardiac Anaesthesia

Can J Anesth/J Can Anesth
https://doi.org/10.1007/s12630-018-1187-y

CORRESPONDENCE

Mechanism of the erector spinae plane block: insights from a magnetic resonance imaging study

Ana Schwartzmann, MD · Philip Peng, MD, MBBS, FRCPC · Mariano Antunez Maciel, MD · Mauricio Forero, MD, FIPP

Received: 30 April 2018 / Revised: 21 June 2018 / Accepted: 26 June 2018
© Canadian Anesthesiologists' Society 2018

Methods:29.7 mL of 0.25% bupivacaine with 0.3 mL gadolinium was injected. The MRI images were taken 45 and 90 min after injection to evaluate potential further spread over time

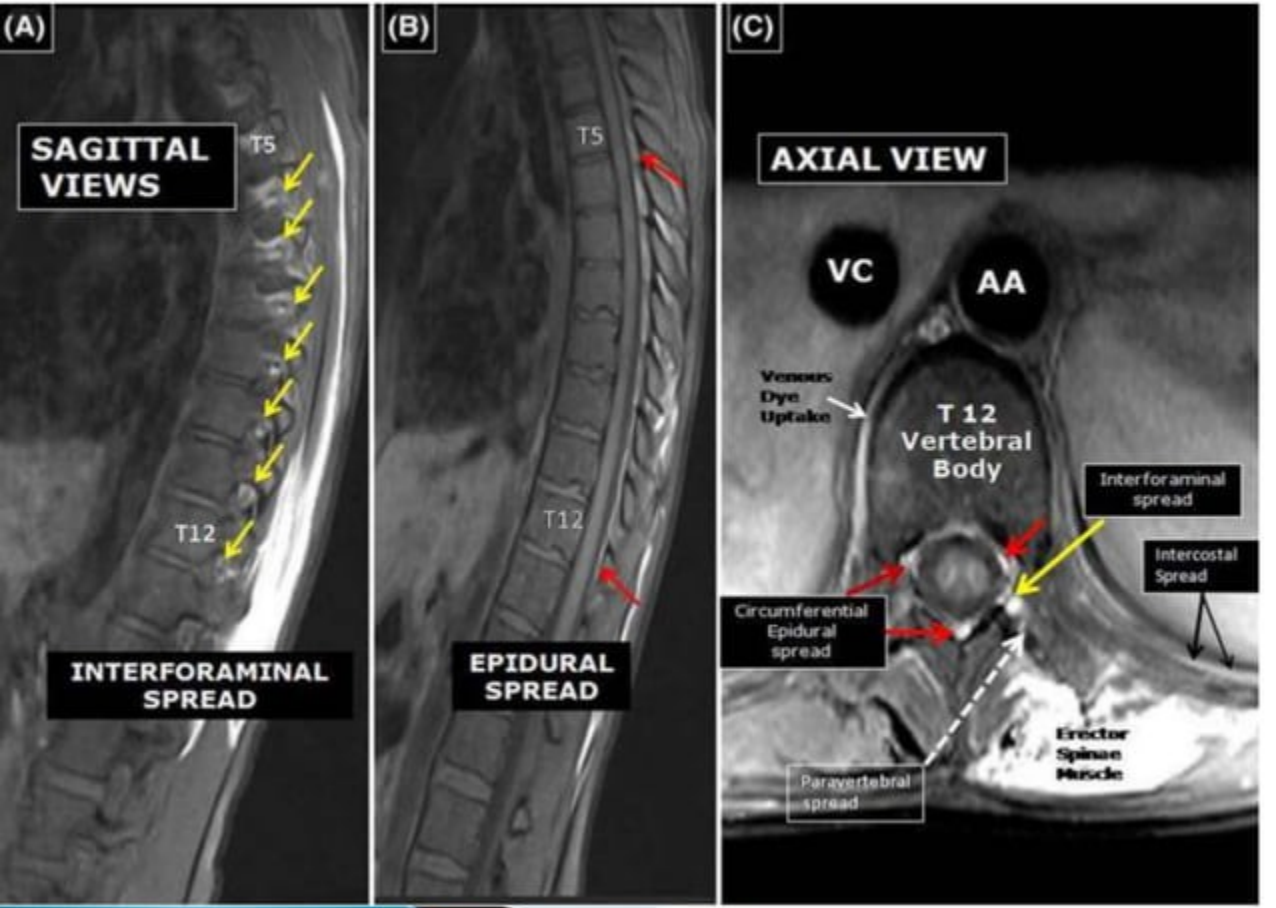
(A)
SAGITTAL VIEWS
T5
T12
INTERFORAMINAL SPREAD
(B)
T5
T12
EPIDURAL SPREAD
(C)
AXIAL VIEW
VC
AA
Venous Dye Uptake
T 12 Vertebral Body
Interforaminal spread
Intercostal Spread
Circumferential Epidural spread
Erector Spinae Muscle
Paravertebral spread

conclusion

1-These MRI images suggest that ESP mechanism of action is likely linked to the transforaminal and epidural spread which may be a potential advantage over other thoracic interfascial plane blocks

2-Further MRI studies with a larger sample size and a systematic approach to correlate clinical presentation and spread of contrast are required to better elucidate the more detailed anatomical mechanisms of the ESPB

REGIONAL ANESTHESIA AND ACUTE PAIN

BRIEF TECHNICAL REPORT

Erector Spinae Plane Block Versus Retrolaminar Block

A Magnetic Resonance Imaging and Anatomical Study

Sanjib Das Adhikary, MD, Stephanie Bernard, MD,† Hector Lopez, MD,‡ and Ki Jinn Chin, FRCPC§*

Regional Anesthesia and Pain Medicine , August 2018

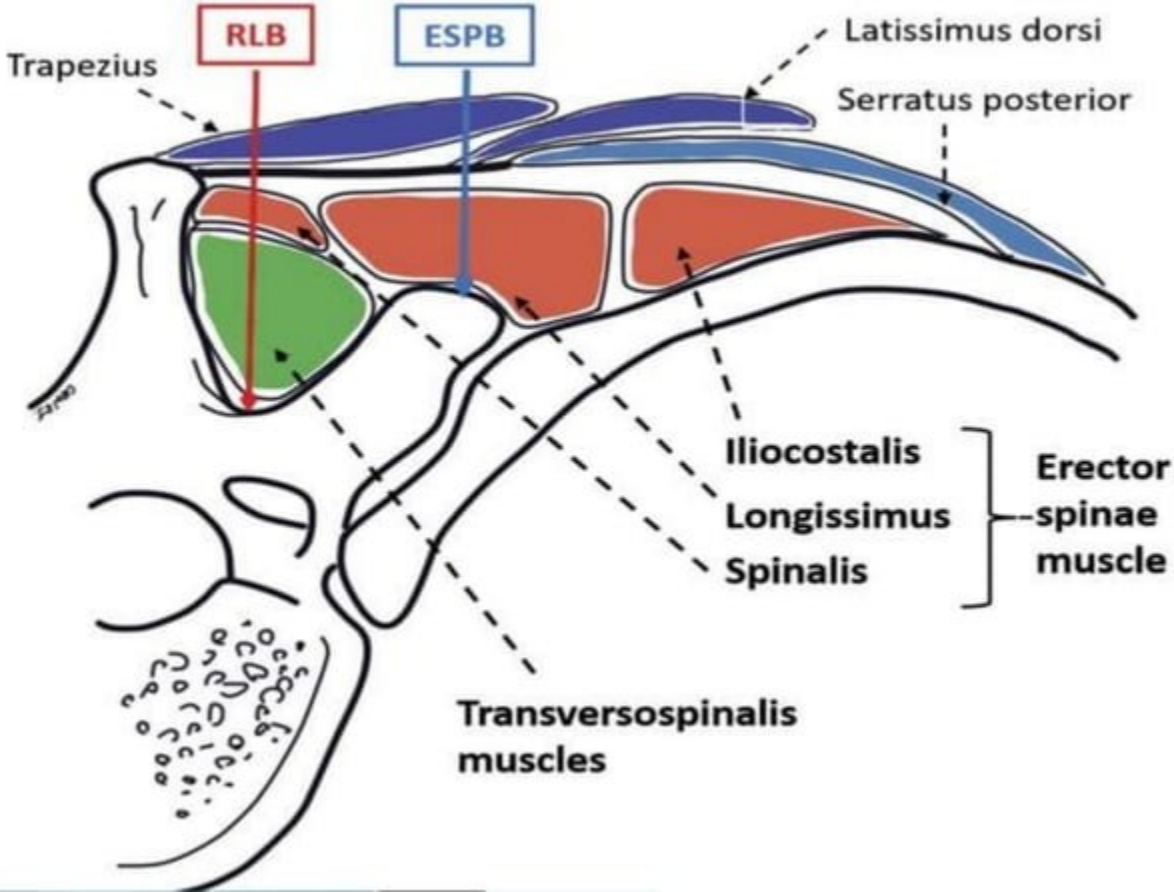
RLB
ESPB
Trapezius
Latissimus dorsi
Serratus posterior
Iliocostalis
Longissimus
Spinalis
Erector spinae muscle
Transversospinalis muscles

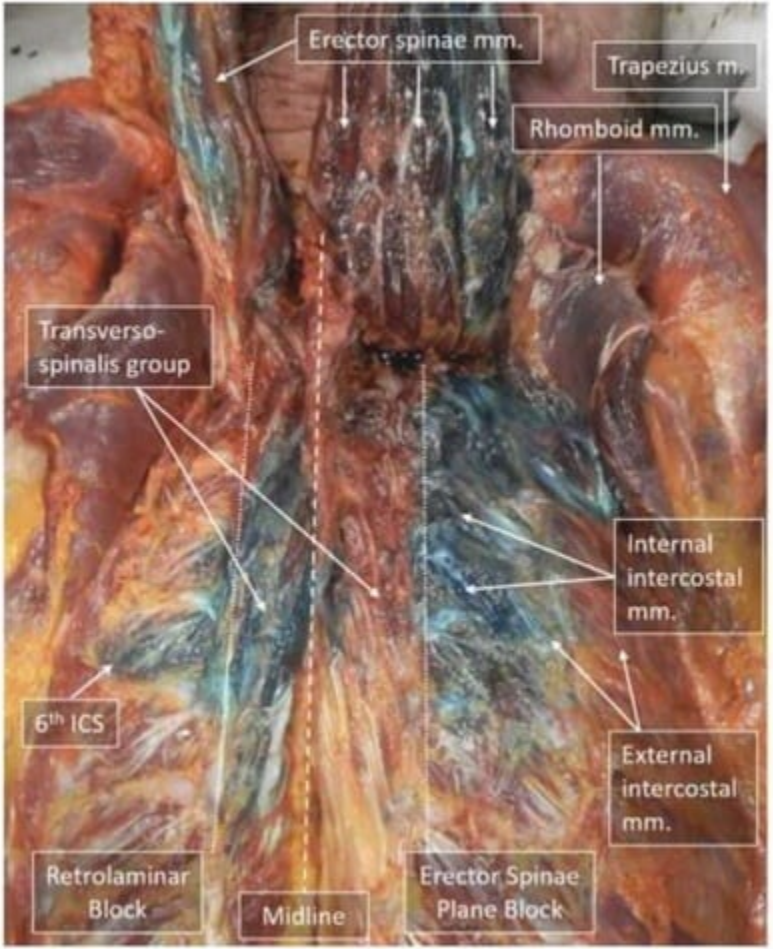

Level	Retrolaminar Block			ESP Block		
	#1	#2	#3	#1	#2	#3
C6						
C7						
T1						
T2						
T3						
T4						
T5						
T6						
T7						
T8						
T9						
T10						
T11						
T12						
L1						

Extent of visible muscle staining

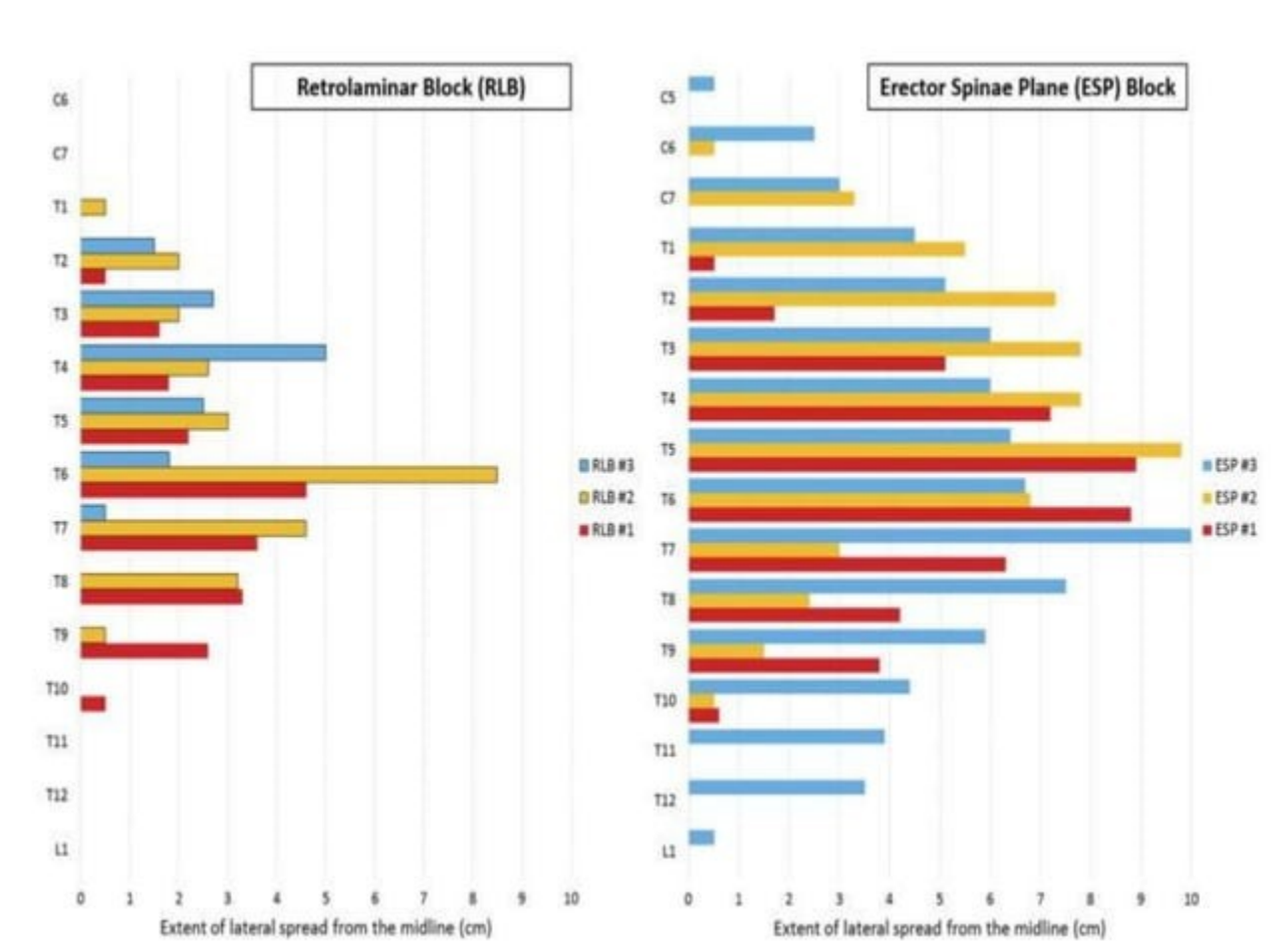
Retrolaminar Block (RLB)
C6
C7
T1
T2
T3
T4
T5
T6
T7
T8
T9
T10
T11
T12
L1
0 1 2 3 4 5 6 7 8 9 10
Extent of lateral spread from the midline (cm)
RLB #3
RLB #2
RLB #1
Erector Spinae Plane (ESP) Block
C5
C6
C7
T1
T2
T3
T4
T5
T6
T7
T8
T9
T10
T11
T12
L1
0 1 2 3 4 5 6 7 8 9 10
Extent of lateral spread from the midline (cm)
ESP #3
ESP #2
ESP #1

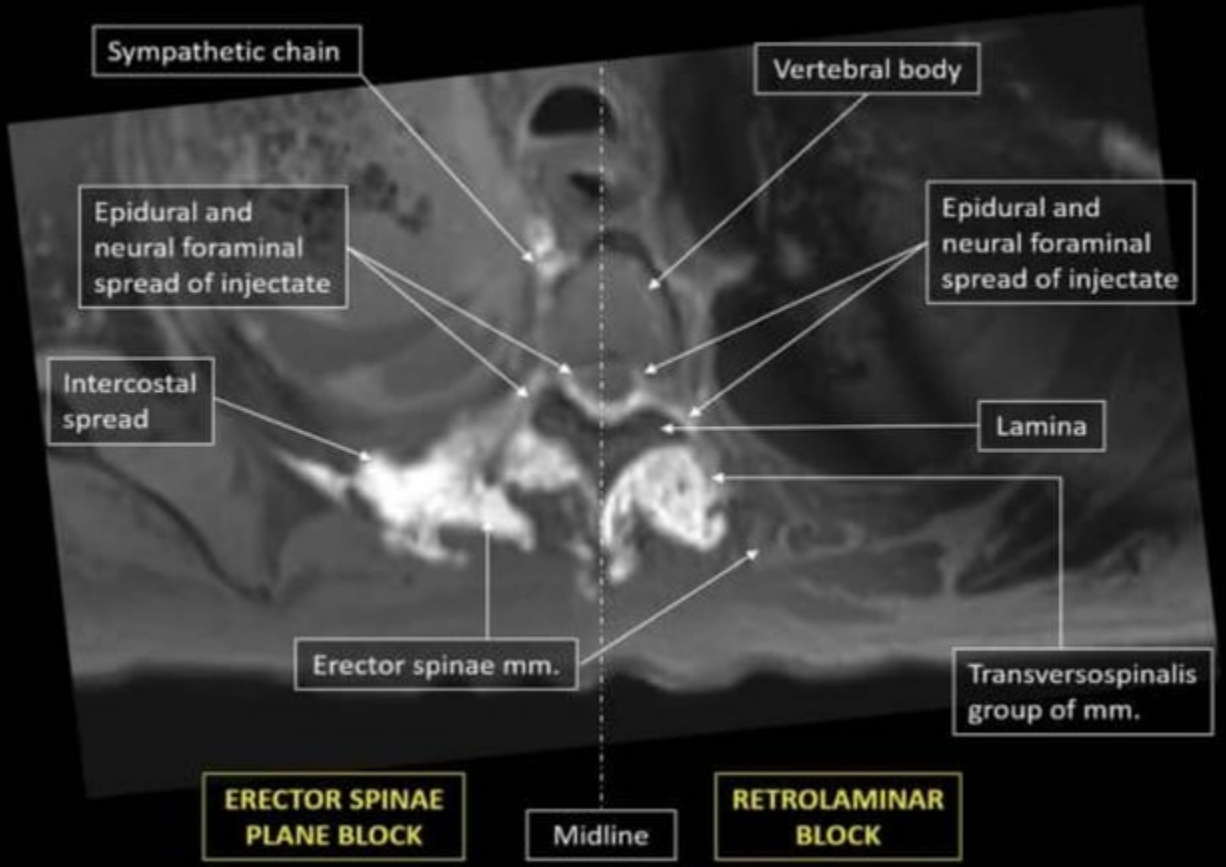
Sympathetic chain
Vertebral body
Epidural and neural foraminal spread of injectate
Epidural and neural foraminal spread of injectate
Intercostal spread
Lamina
Erector spinae mm.
Transversospinalis group of mm.
ERECTOR SPINAE PLANE BLOCK
Midline
RETROLAMINAR BLOCK

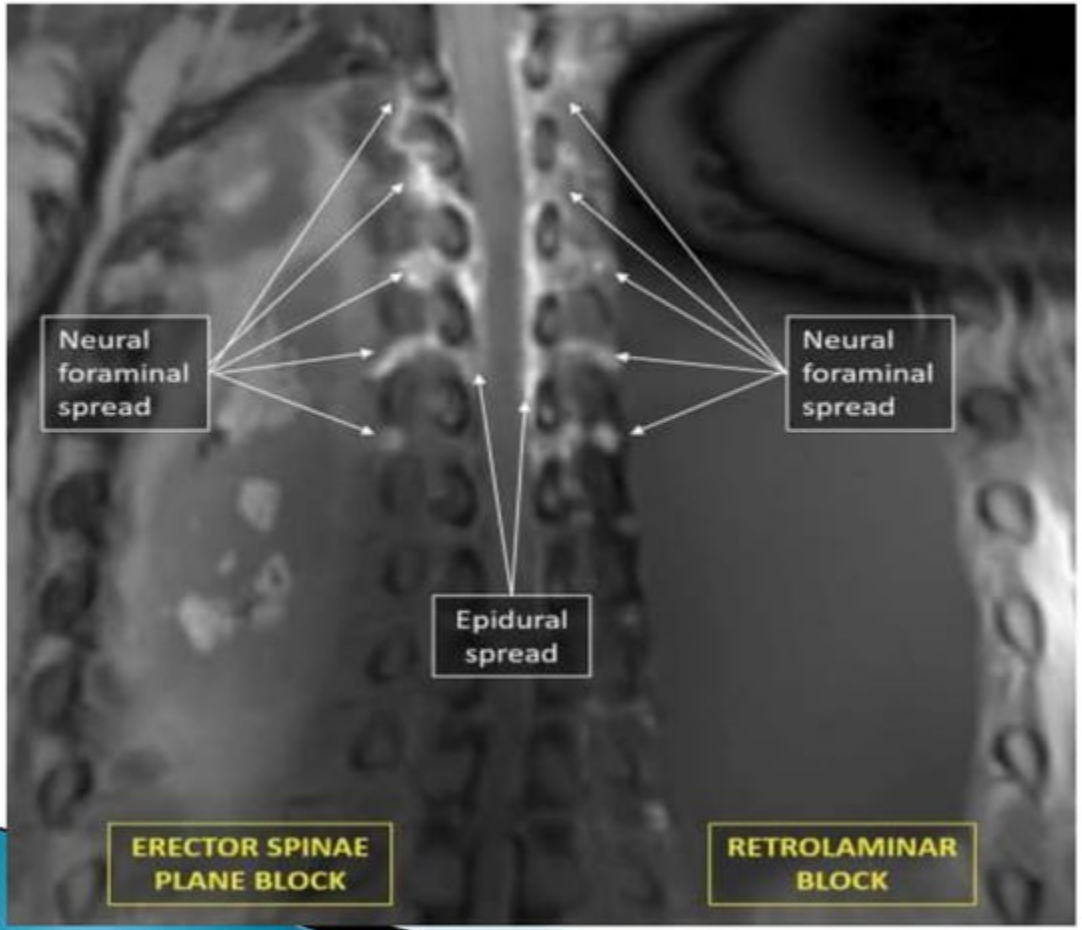
Neural foraminal spread
Neural foraminal spread
Epidural spread
ERECTOR SPINAE PLANE BLOCK
RETROLAMINAR BLOCK

conclusion

1-Single-injection retrolaminar and ESP blocks in fresh cadavers both produce epidural and neural foraminal spread and thus can be expected to have clinical effects similar to thoracic paravertebral blockade.

2-The ESP block exhibits additional intercostal spread that may contribute to wider analgesic coverage than the retrolaminar block.

Take home message:

- ESP block is successful alternative technique to thoracic epidural anesthesia with a minimal risk of serious complications such as epidural hematoma or epidural abscess.

- further research is still required to standardize doses and concentration of local anesthetics and to compare ESP block with other regional techniques.


Thank You So Much
Everyone
ThanksImages.com