BMC Musculoskeletal Disorders

RESEARCH

Open Access

Clinical and radiographic outcomes of posterior cervical arthrodesis and stabilization via lateral mass screwing and rod fixation: a retrospective study at a tertiary hospital in Addis Ababa, Ethiopia

Surafel Mekonnen Mendere[1], Mikiyas G. Teferi[2*], Michael A. Negussie[2], Azarias Kassahun Admasu[1] and Samuel Getahun Mengistu[1]

Abstract

Background Lateral mass screw and rod fixation is widely used for posterior cervical arthrodesis and stabilization in cases of cervical instability, trauma, neoplasm, decompression, and deformity correction. However, clinical and radiological data on its outcomes, especially in our setting, remain limited.

Objective Clinical and radiographic evaluation of posterior cervical arthrodesis and stabilization using lateral mass screws and rod fixation.

Methods A retrospective cross-sectional study of lateral mass screw and rod fixation from September 2019 to September 2024 was performed, and the clinical and radiographic parameters were evaluated. Sixty-six patients were assessed via a structured questionnaire. Clinical parameters were assessed by the ASIA score, functional assessment in degenerative conditions (mJOA), and radiographic evaluation (computed tomography and dynamic X-ray) of 325 lateral mass screws inserted into the evaluated patients. Complications were assessed from a patient chart and radiology archive.

Results Patients ranged from 16 to 75 years in age (40.1), and 84.9% of the patients were between the ages of 20 and 60. Trauma accounted for 92.4% of the indications, with fracture dislocations being C4/C5 (28.8%), C5/C6 (25.8%), C6/C7 (16%), and C4/5 (10.8%)—unilateral locked facets in 4.5% and floating lateral masses in 6% of patients. A total of 325 screws were placed, with C5 being the most common (110 screws). There was no postoperative change in the ASIA score. The complications included dural tear (3%), joint violation (1.9%), hardware failure (1 patient), and postoperative surgical site infection (6%). The postoperative follow-up ASIA score was significantly associated with the preoperative score, with a likelihood ratio and Fisher's exact test P value < 0.001. The mean postoperative follow-up mJOA score was 13.3 ± 0.58, which was greater than the preoperative mean mJOA score, which was 8.67 ± 1.16.

*Correspondence:
Mikiyas G. Teferi
micah.mesay@gmail.com

Full list of author information is available at the end of the article

© The Author(s) 2025. **Open Access** This article is licensed under a Creative Commons Attribution-NonCommercial-NoDerivatives 4.0 International License, which permits any non-commercial use, sharing, distribution and reproduction in any medium or format, as long as you give appropriate credit to the original author(s) and the source, provide a link to the Creative Commons licence, and indicate if you modified the licensed material. You do not have permission under this licence to share adapted material derived from this article or parts of it. The images or other third party material in this article are included in the article's Creative Commons licence, unless indicated otherwise in a credit line to the material. If material is not included in the article's Creative Commons licence and your intended use is not permitted by statutory regulation or exceeds the permitted use, you will need to obtain permission directly from the copyright holder. To view a copy of this licence, visit http://creativecommons.org/licenses/by-nc-nd/4.0/.

Conclusion Lateral mass screw and rod fixation is an effective method of cervical stabilization in our setting.

Clinical trial number Not applicable.

Keywords Cervical vertebrae, Arthrodesis, Spinal fusion, Internal fixators, Postoperative complications

Background

Cervical spine stabilization plays a critical role in managing cervical disorders, with anterior and posterior approaches being commonly utilized. The posterior approach is particularly favored for addressing posterior pathologies, long-segment constructs, and cases requiring upper cervical spine stabilization [1, 2]. Among the available techniques for posterior instrumentation, lateral mass screw and rod fixation are the most widely used techniques because of their adaptability and effectiveness. Screw-rod systems are preferred over plate systems, especially in cases involving deformities, as plates have fixed holes that can limit optimal instrumentation [3].

Since its introduction by Roy-Camille in 1979, lateral mass screw fixation has undergone significant advancements, with various techniques described, including those by Magerl, Anderson, and An, each differing in screw insertion points and angulation [3–5]. These constructs are widely used globally to treat conditions such as cervical instability, trauma, neoplasms, decompression, and deformity correction [6, 7]. Despite the growing body of evidence on the safety and efficacy of lateral mass screw constructs, local data on their clinical and radiographic outcomes remain scarce in resource-limited settings.

In Ethiopia, where cervical spine disorders are common, there is limited local research on the outcomes of these procedures. This retrospective study evaluated the specific clinical outcomes including neurologic improvement, pain reduction, and complication rates, as well as radiographic parameters such as fusion rates, screw placement accuracy, and alignment correction following posterior cervical arthrodesis and stabilization via lateral mass screw and rod constructs in patients treated at a tertiary hospital in Addis Ababa. The findings aim to improve patient care and provide insights for similar resource-limited settings.

Materials and methods

This study was conducted at the All African Leprosy, Tuberculosis Rehabilitation, and Training Center (ALERT), a major institution performing spine procedures in Ethiopia. Data were collected retrospectively from all patients who underwent lateral mass screw insertion between September 2019 and September 2024. The inclusion criteria consisted of adult patients (age ≥ 18 years) who had undergone posterior cervical arthrodesis and stabilization using lateral mass screws, including those with trauma, degenerative conditions, and cervical spine tumors requiring spinal stabilization. Exclusion criteria were patients with missing medical records, those who had undergone anterior cervical procedures, those who received care outside the study period, and those who lost to follow-up, but no patient was excluded with other comorbidities. The total required sample size was 422, based on study design and estimated nonresponse rates, though all eligible patients during the study period were included due to a smaller-than-expected number of eligible cases.

Data were collected by trained neurosurgical residents using a structured questionnaire, which included sociodemographic data, clinical presentation, imaging findings, surgical details, and clinical outcomes. Clinical outcomes were assessed using the ASIA score for trauma cases and the Modified Japanese Orthopedic Association (MJOA) score for degenerative cervical spine cases. Radiographic outcomes focused on the accuracy of lateral mass screw and rod placement. The data were manually reviewed by a senior radiologist and a neurosurgeon for completeness and consistency before being entered into SPSS for analysis. Descriptive statistics (frequencies and percentages) were used to summarize demographic data, while binary logistic regression was employed to identify associations between categorical variables (such as age, sex, and surgical indications) and clinical outcomes. Multivariable logistic regression was used to control for confounders, providing adjusted odds ratios (AORs) with 95% confidence intervals (CIs) to evaluate the combined effects of multiple variables on the outcomes. Statistical significance was set at $P < 0.05$.

The radiographic assessments were conducted by trained specialists who ensured proper screw placement and alignment. To ensure data quality, data collectors and supervisors underwent one-day training sessions, and the project coordinator supervised the process, reviewing completed forms for consistency. Ethical approval was granted by the Addis Ababa University Institutional Review Board, and confidentiality of patient records was strictly maintained.

Results

Sociodemographic status

Of the 66 patients for whom lateral mass screw and rod fixation was performed, 56 (84.8%) were male, and 10 (15.2%) were female. Patients aged 16 years to 75 years were operated on. The mean age was 40 years, and 84.9%

of the patients were 20–60 years of age. A total of 72.7% of the patients were from Amhara, Oromia, or South Nations (Figs. 1, 2 and 3).

Preoperative clinical evaluation

Indications for surgery

Post-traumatic indications accounted for 61 (92.4%) of all patients who underwent surgery, followed by postlaminectomy for degenerative cervical spine disease (5%), and one patient underwent resection of an intradural extramedullary cervical spine tumor (Fig. 4).

Preoperative ASIA score of patients with cervical spine trauma

Incomplete SCI occurred in 65% of the patients, with 34.8% ASIA D, 19.7% ASIA C, and 10.6% ASIA B patients. 25% of the patients were ASIA E, and only 3% were ASIA ASIA A (Fig. 5).

Specific level of trauma

The charts show the cervical injury classification scores according to fracture pathology type. Fracture dislocation is the most common type of fracture. The percentage of C4/C5 fracture dislocations is 28.8%, followed by C5/C6, at 25.8%. 16% had C6/C7 fracture dislocation. The unilateral locked facet was 4.5%, and the floating lateral mass was 6%(Fig. 6).

Indications for degenerative spine disorders

Lateral mass screws with rod fixation were used for 5% of the patients. All but one patient underwent standard laminectomy for multilevel degenerative cervical spondylosis. One patient underwent surgery for post-ACDF spnodylolitshesis for posterior stabilization.

All patients' preoperative mJOA functional assessment results were severe (< 11).

Tumors

For one patient, lateral mass fixation was performed after long-segment laminectomy for the cervical intradural extramedullary mass.

Intraoperative evaluation

Level of screw insertion

A total of 325 screws are inserted from C3 to C7—the highest number of screws inserted at C5, which is 110 screws, followed by C4 with 79 screws. The number of screw insertions at C6 and C3 is 75 and 57, respectively (Table 1).

Intraoperative complications

Documented intraoperative complications were reported in 4 (6.1%) of the patients. Two patients (3%) had inadvertent dural tears, one had a breach to the foramen transversarum, and one had lateral breakage of the lateral mass. No cases of intraoperative nerve root injury or vascular incident were documented.

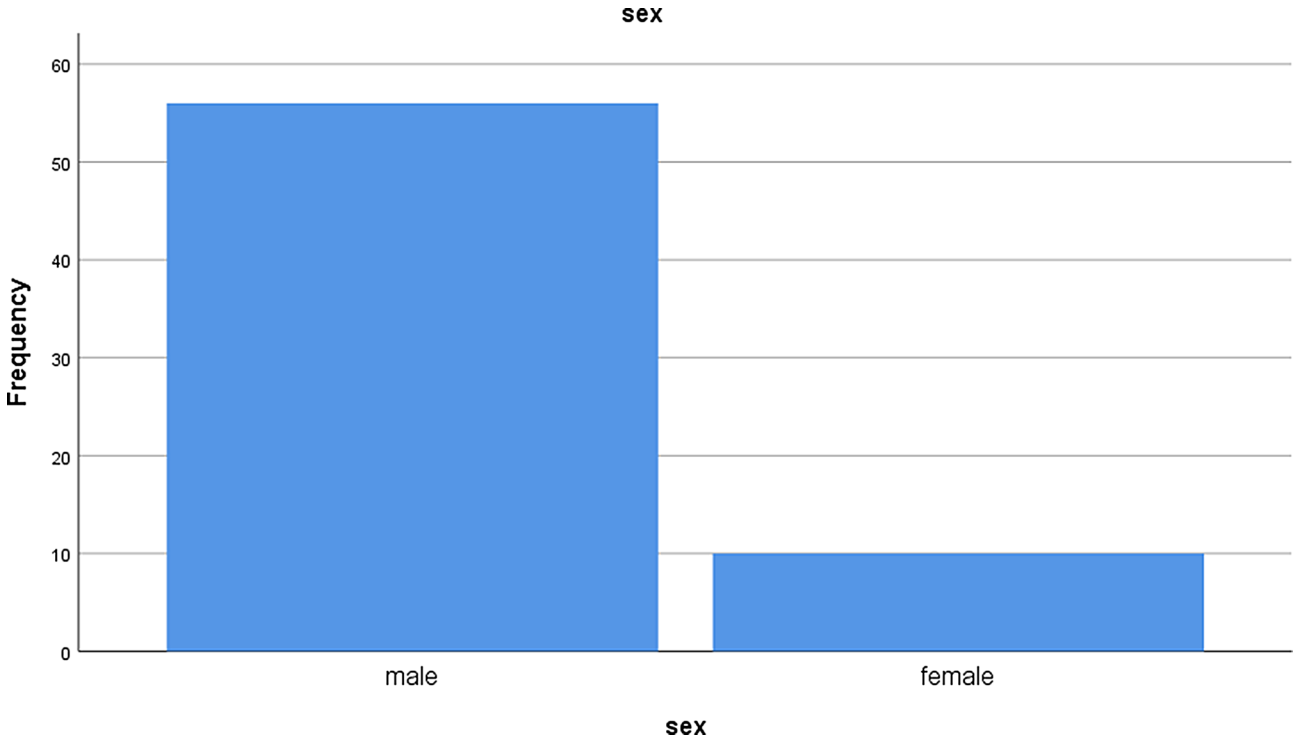

Fig. 1 Sex of patients for whom LMSF was performed

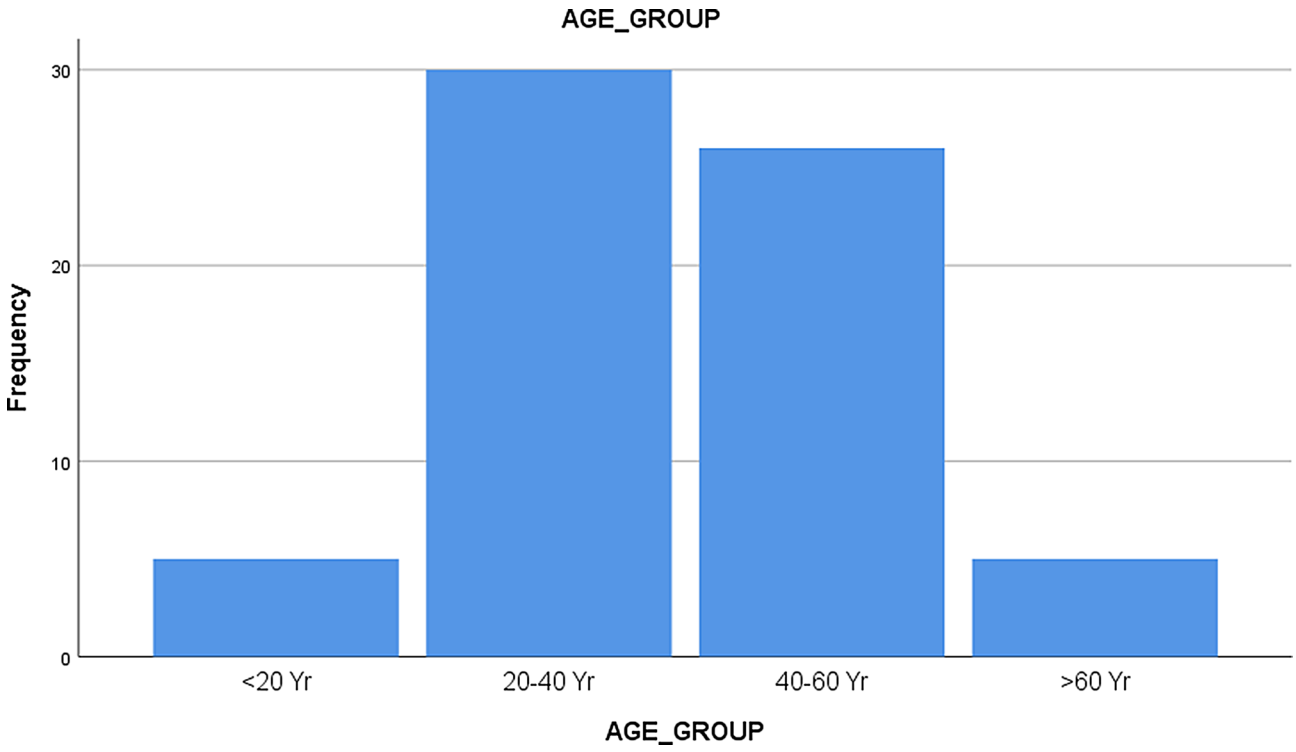

Fig. 2 The age range of patients for whom LMSF was performed

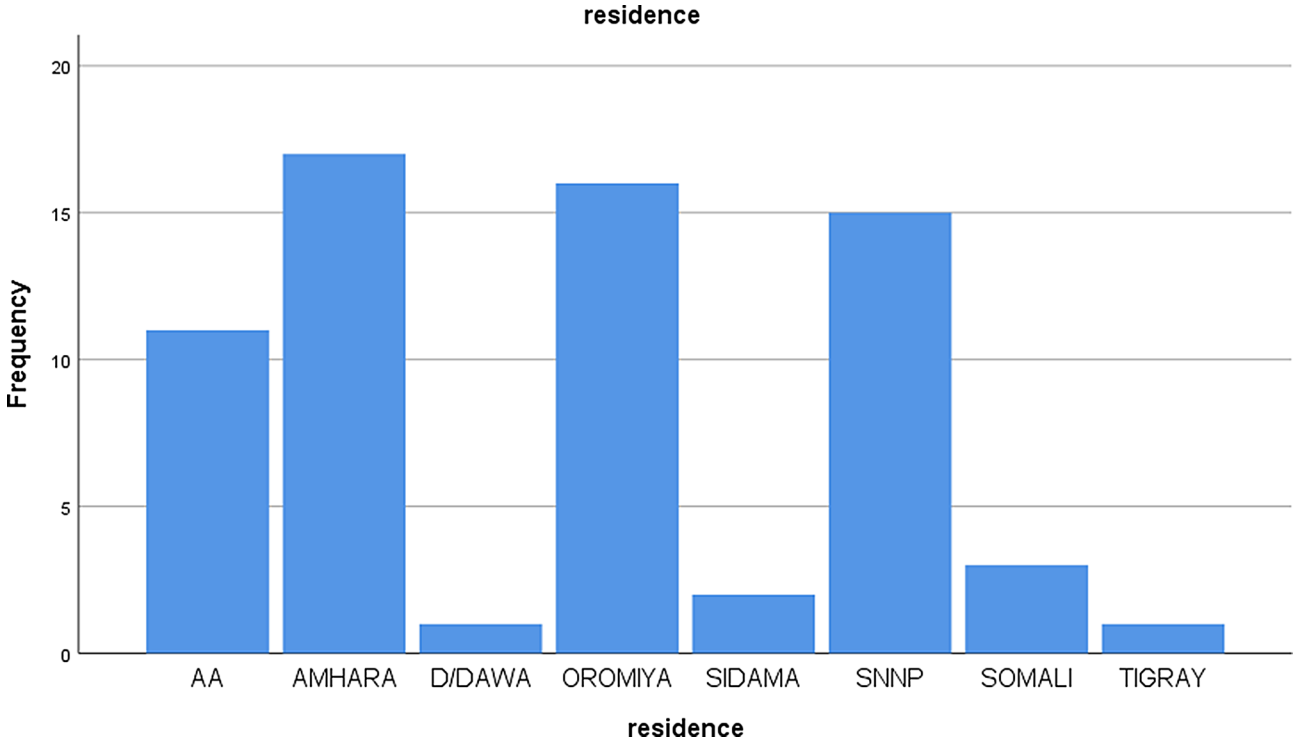

Fig. 3 State of residence of patients for whom LMSF was performed

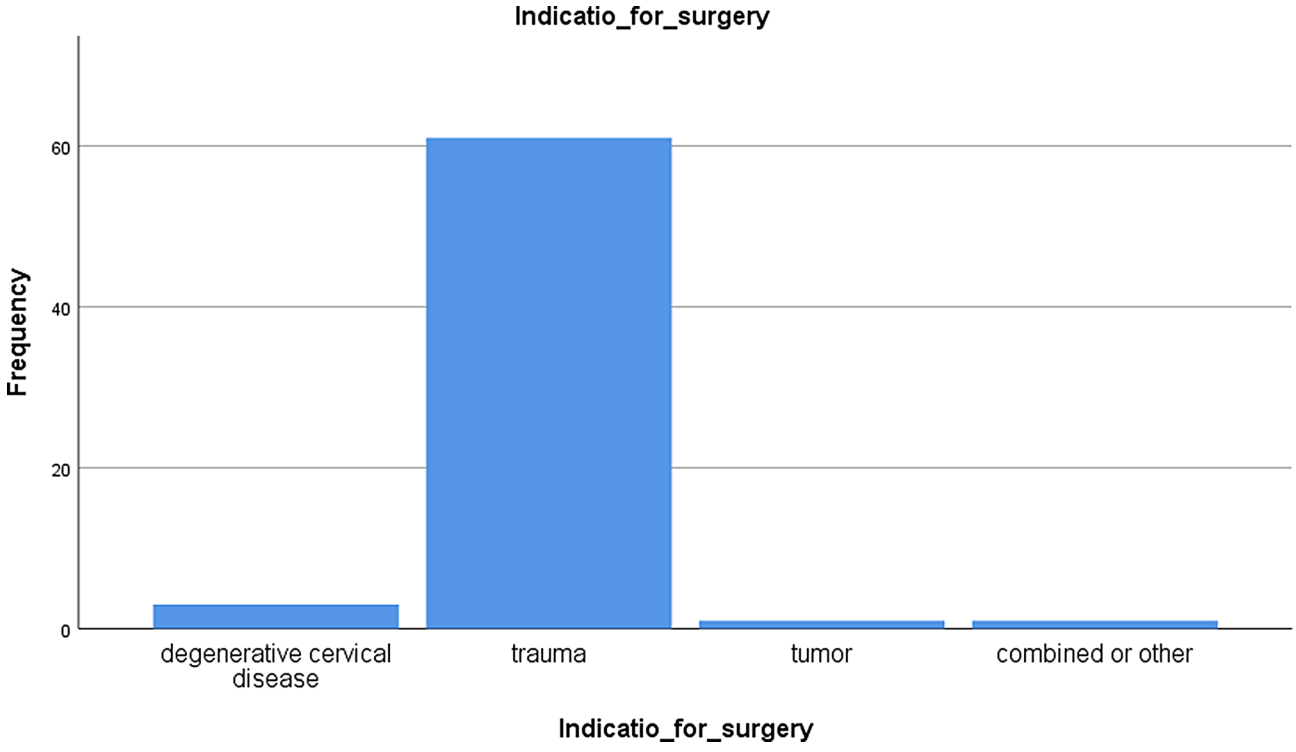

Fig. 4 Indications for LMSF

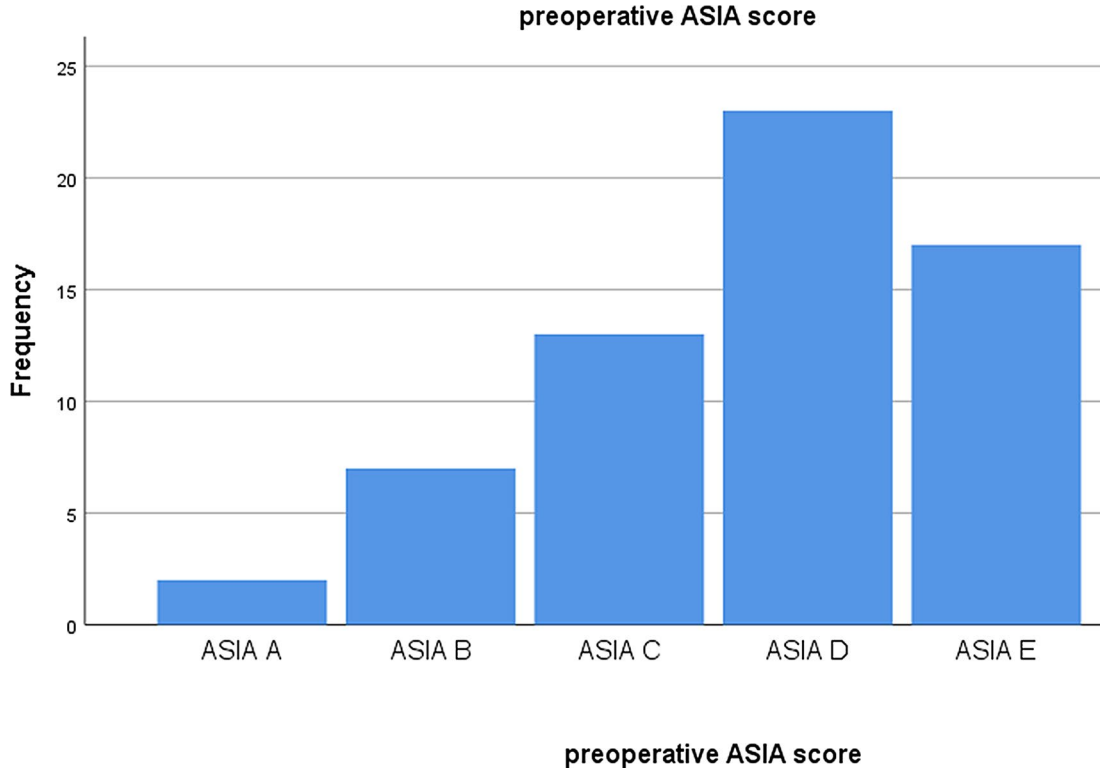

Fig. 5 Preoperative ASIA score for traumatic indications of LMSF

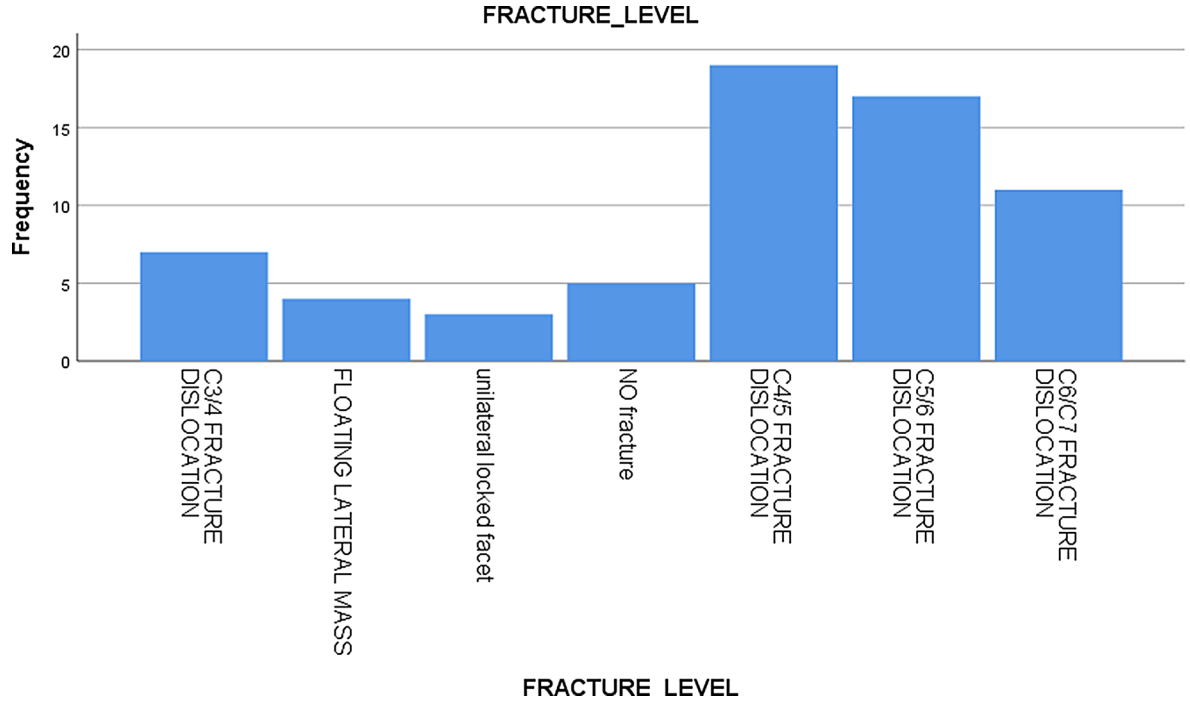

Fig. 6 Fracture level for the operated LMSF

Table 1 Number of screws inserted at each cervical spinal level

	C3	C4	C5	C6	C7	total
Number of Screws	57	79	110	75	4	325

Postoperative evaluation

Postoperative clinical evaluation

The postoperative ASIA score during the immediate postoperative period was similar to that during the preoperative period.

Objective parameters did not measure postoperative pain status, but 54% of the patients reported mild surgical site pain controlled with NSAIDs and opioids as needed, and 3% reported persistent pain that continued during the follow-up period (Fig. 7).

Superficial surgical site infection occurred in 4 (6.1%) patients and was managed nonsurgically with wound care and antibiotics. Pus culture was not performed in any of the patients.

No delayed vascular incident occurred in any of the patients. No new motor or sensory deficits occurred postoperatively.

Postoperative radiologic evaluation

All of the patients who underwent surgery had postoperative AP and lateral cervical radiographs.

Radiographic evaluation of the proper placement of the screws revealed hindrance and poor penetration of the X-ray, and 14 of the images were not accurate lateral cervical spine X-rays.

There was an articular joint violation in six (1.9%) of the 325 screws inserted. Three screws were placed only partly in the lateral mass (Figs. 8 and 9).

One patient experienced a hardware failure on the immediate postoperative radiograph with a dislodged nut and displaced rod, which required revision surgery (Figs. 10 and 11).

Postoperative clinical and radiological follow-up data at 3 and 12 months were not available because the data were incomplete enough to evaluate the fusion status and long-term clinical and radiologic outcomes.

Postoperative clinical outcome

The final follow-up time ranged from 2 months to 38 months, with a mean of 15.3 ± 7.6 months.

Outcome analysis

Assuming that the goal of lateral mass screw fixation was to prevent worsening of neurologic status, as measured by the ASIA score for trauma and the mJOA score for the degenerative spine, the Pearson chi-square test was used to determine the relationship between preoperative and postoperative ASIA scores for patients after lateral mass screw fixation.

Bivariate analysis between the postoperative ASIA score and age, sex, level of c-spine fusion, duration of surgery, presence of screw malposition, and level of fracture revealed no significant associations.

Because 83.3% of the cells had a value less than the expected 20%, Fisher's exact test and the likelihood ratio

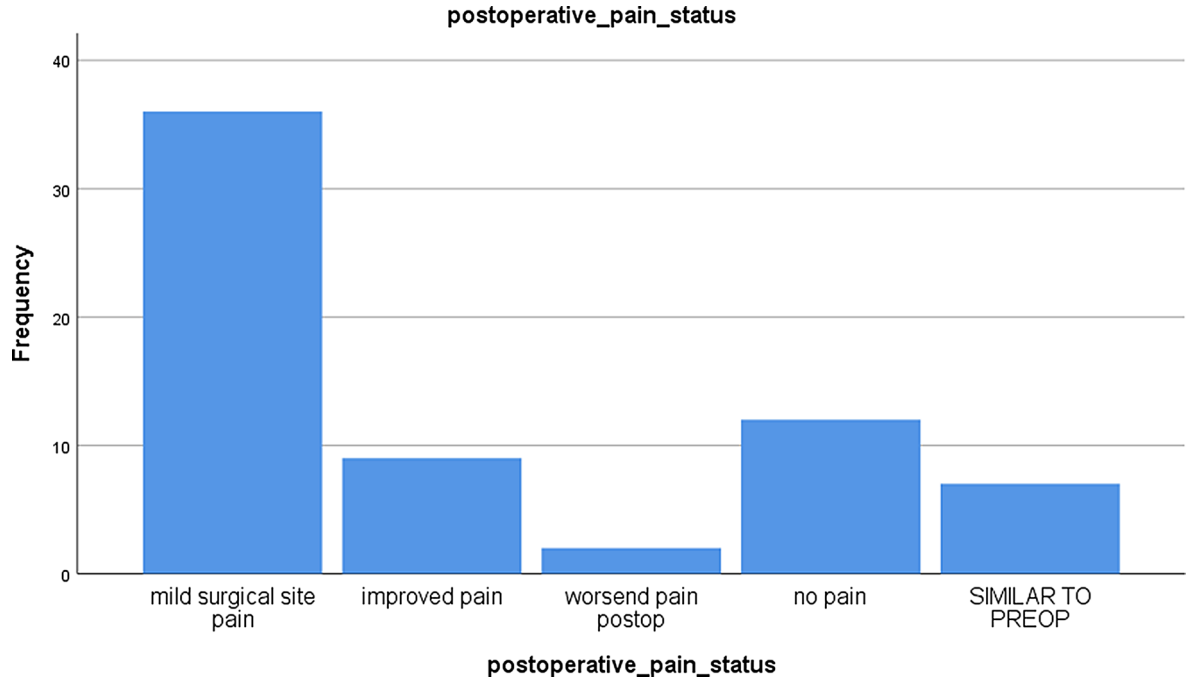

Fig. 7 Comparison of pain during the immediate postoperative period

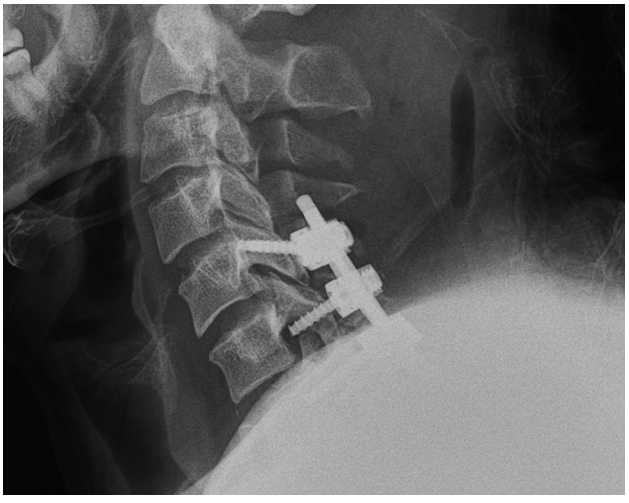

Fig. 8 Screw tips that violated the articular space

were used to evaluate the associations. The p-value is < 0.001, which is significant at < 0.005. Therefore, there is a significant association between the preoperative ASIA score and the ASIA score at follow-up.

A significant transfer was found from ASIA C to ASIA D 9 (69%). ASIA A patients were not identified during the postoperative follow-up. 0% of preoperative ASIA E patients were grouped with ASIA D patients at the postoperative follow-up.

The mean postoperative mJOA score was 13.3 ± 0.58, which was greater than the preoperative mean mJOA score of 8.67 ± 1.16 (Table 2).

Chi-square tests

Discussion

Many techniques for cervical stabilization have been evaluated in the management of cervical disorders. Anterior and posterior approaches are commonly applied. The posterior approach is the choice for posterior pathologies and long segment constructions and stabilization requiring the upper cervical spine [1, 2]. Options for posterior instrumentation of the cervical spine include lateral mass screws with rods or plates, pedicle screws, and translaminar screws. The most commonly used approach for posterior stabilization is the use of lateral mass screws with a plate or rod system. Screw rod systems are preferred over plates for conditions with associated deformities because the plates have fixed holes, which makes the instrumentation suboptimal. In our setup, due to the economic burden and unavailability of plates, screw rod fixation was used [3].

Posterior cervical fixation with lateral mass screws was first introduced in 1979 and has been increasingly used since that time to treat a variety of cervical spine disorders. Several screw instrumentation techniques have been described since Roy-Camille introduced the procedure. Anatomic insertion of the insertion point inferiorly and medially to the center of the lateral mass trajectory toward the superior lateral tip of the rectangle is the main technique used in our setup. They all have similar protocols except for the insertion point and angulation of the

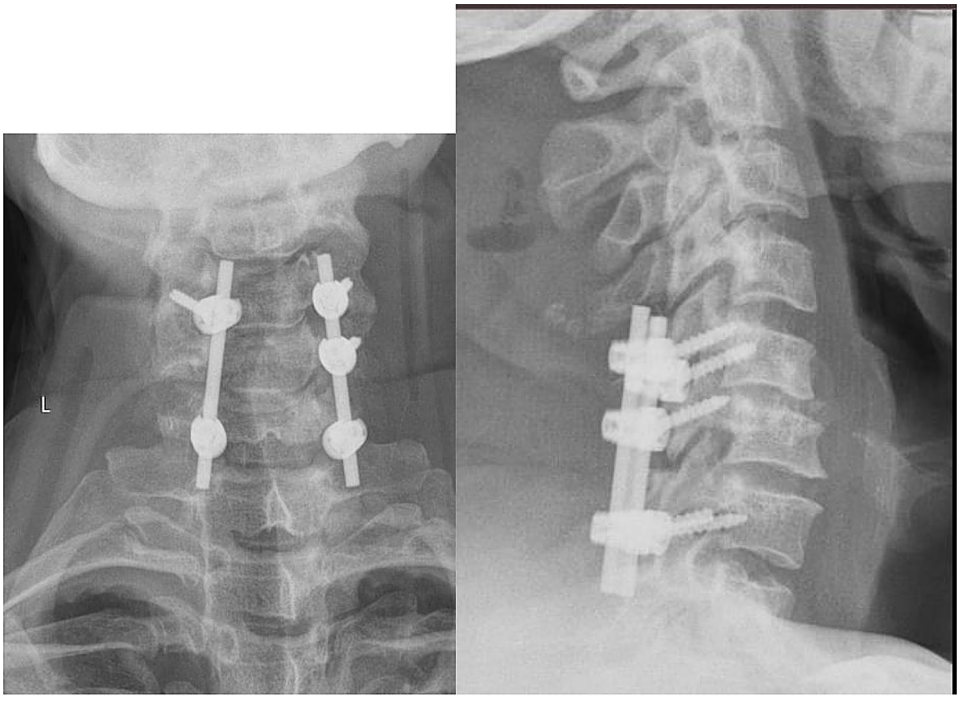

A. *AP view* **B.** *Lateral view*

Fig. 9 Screws outside the lateral mass or pedicle

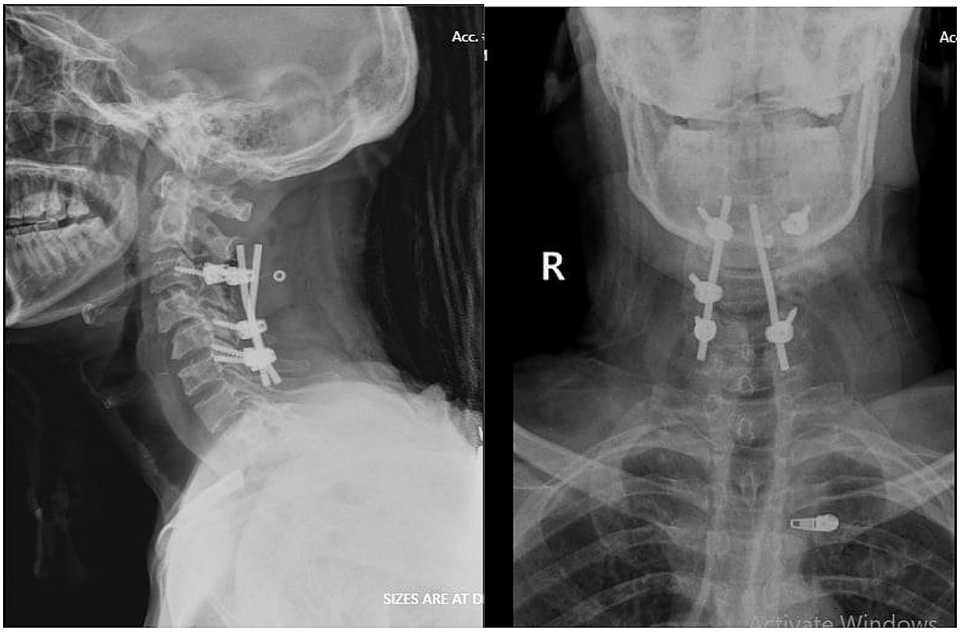

Fig. 10 Immediately after hardware failure in two of the patients, the foramen transverse to the vertebral artery was violated, but there was no vascular incident, as described above

screw. The Roy-camille screw lengths varied from a minimum of 8.8 mm to a maximum of 14 to 15 mm [3, 4].

In a review of techniques for posterior subaxial cervical spine screw fixation, Andrei et al. described screw insertion techniques by Roy-Camille, Louis, Magerl, Anderson, An, and Riew [5]. John G et al. performed an anatomic study comparing 3 techniques for lateral mass screws: Magerl, Anderson, and An. For each technique, 1 specimen received 20 screws from C3 to C7 via 20-mm screws to purposefully over-penetrate the lateral masses.



Fig. 11 Breach-in-foramen transversarum

Table 2 Chi-Square test of preoperative ASIA and postoperative ASIA scores

	Value	df(degrees of freedom)	*p*-value
Pearson Chi-Square	129.284	20	< 0.001
Likelihood Ratio	119.519	20	< 0.001
Fisher's Exact Test	96.805	-	< 0.001
Number of Valid cases	66	-	-

The nerve violations obtained were 95% (Magerl technique), 90% (Anderson technique), and 60% (An technique) ($P < 0.05$). In this study, we plan to identify specific techniques that apply the relative frequency of complications [6].

Globally lateral mass screw insertion is used for several indications, including cervical instability, trauma, neoplasm, decompression, and deformity correction [7–9]. Posterior lateral mass screw–rod fixation was performed after multilevel cervical spine laminectomy by Mohammed et al. At the 4-month to 8-yr follow-up, 430 patients and 2500 screws were inserted. Twelve patients had wound infections, of whom 6 had deep infections. Twenty patients had C5 radicular pain that subsided over time; 2 required C5 screw modification; and another 3 required screw repositioning at different levels. Two patients had asymptomatic screw pull-outs evident only on radiographs and required no treatment. Iatrogenic dural tears occurred in 12 patients with severe spondylosis, whereas CSF leakage from tears was observed in 3 patients. Symptomatic adjacent segment disease was noted in 4 patients within the follow-up period and was treated with surveillance [1].

Lateral mass screws were inserted for traumatic cervical spine indications in 88 patients, with cervical injury confirmed radiologically excluding patients less than 12 years or greater than 70 years, with traumatic discs, with cord compression without subluxation, and previously operated on the cervical spine. The most common level of injury was C5–C6 in 46 (52%) patients. On admission, 35 (39.8%) patients were classified as Grade A, 15 (17.05%) as Grade B, 22 (25%) as Grade C, 12 (13.6%) as Grade D, and four (4.5%) as Grade E. Postoperatively, 16 (18.2%) patients were placed in Grade A, 23 (26.1%) in Grade B, eight (9.1%) in Grade C, nine (10.2%) in Grade D and 26 (29.6%) in Grade E, with an overall improvement in neurological function in 51 (58%) patients and power in 37 (42%) patients. The major complications encountered were respiratory infections in 10 (11.36%) patients and wound infections in four (4.5%) patients, whereas eight (9.1%) patients died [10].

In a prospective study of 200 lateral mass screws that were placed in 25 (eight women and 17 men) patients aged 20–76 years over a mean follow-up of 1.5 years, no patients experienced iatrogenic neural or vascular injury. Four patients experienced superficial wound infection. Three patients experienced pain around the shoulder of the C5 distribution, which subsided over time. No patients developed screw pullouts or symptomatic adjacent segment disease within the follow-up period [11]. In terms of complications and efficacy in maintaining sagittal balance via lateral mass screw fixation for the treatment of cervical spine trauma, instrument failure (e.g., screw breakage, rod breakage, or the decoupling of rods and screws) was judged on plain radiographs [12]. Loss of fixation was defined as radiographic evidence of screw pullout from the lateral mass or a change greater than 5 degrees in sagittal plane alignment on successive radiographs. Fusion was assessed at 6 months and subsequent visits via radiographic and clinical examinations (pain, tenderness, clinical alignment of the head and neck, etc.). For 28 of the 29 patients, the mean change in sagittal alignment from the immediate postoperative examination to the most recent follow-up radiographic examination was 2 degrees (range, 0–6). Radiographically, there was one case of instrumentation/fixation failure and loss of sagittal alignment 3 months postoperatively. Other complications included one case of C5 nerve root injury and four cases of wound infection [13].

The clinical indicators used by Hugh Deen et al. included surgical indications, postoperative neurological status, and wound healing. Radiographic indicators included early postoperative CT scans to check for screw placement and plain radiographs at subsequent visits. Postoperative radiographs were analyzed for evidence of loss of alignment, pseudarthrosis, and adjacent segment degeneration. Among a total of 888 screws implanted in 100 patients, acute complications included radiculopathy (4, 0.45% per screw placed), infection, other wound healing problems, and CSF leakage. There were no examples of spinal cord injury or vertebral artery injury [14].

Lateral mass screw fixation in 30 children aged 3 to 16 years was performed by Hedquest et al. for indications of ten instability, 11 deformities, seven trauma, five tumors, and three congenital abnormalities. There were no revisions due to screw failure or dislodgement. There were no vascular or neurologic complications [15, 16].

Lateral mass screw and rod fixation is the gold standard technique for posterior cervical stabilization and fusion globally and in Ethiopia. However, no study in Ethiopia has evaluated surgical cases clinically or radiographically, and we assessed patients who underwent surgery at ALERT Hospital, which is the dominant spine center in the country. Mohammed M. Al Barbarawi reported a sex difference, with 65% male and 35% female predominance in operated patients [12]. Ahmed S.A. Elfattah reported that 68% of operated patients were male, and 32% were female. In our study, **84.8%** of the participants were male, and **15.2%** were female, indicating a wide age gap compared with other studies.

Our patients' ages ranged from 20 to 60 years, accounting for 84.9% of the cases. The mean age is 40.1 years, with the youngest being 16 years old and the oldest being 75 years old. This result is comparable with that of Sang HyunKimm et al., whose 65 patients evaluated ranged from 19 to 83.

Unlike global references, the standard indication for LMSF in our study was trauma, which accounted for 92.4% of the cases. In a retrospective cohort study from Dare Es Salaam, 95% of patients with cervical spine trauma require surgery [17]. In Mohammed M. Al Barbarawi's evaluation of 2500 screws, only 17.2% were for traumatic indications, and 74% were for degenerative cervical spine disorders [12]. H. Gordon Deen et al. reported that 66% of cases were indications of degenerative cervical spine disorders. This comparison is also valid for other studies and indicates that traumatic indications are significant in our study. Among these cases, fracture dislocations at C/5 and C5/6 accounted for 54.6% of the operated cases, and open reduction and fixation via lateral mass screws for the unilateral locked facet were performed in 6% of the cases.

Although there are different techniques for screw insertion, our study group used an individualized anatomic technique in which the insertion starting point is inferomedial to the center of the lateral mass, aiming at the lateral superior edge of the rectangle of the lateral mass. This technique is suitable for individualized intraoperative decisions.

The procedures took less than 120 min in 34.8% of the cases, and 53% of the procedures took between 120 and 180 min. Overall, fewer than 87.8% of patients underwent surgery in less than 180 min, with the mean duration of surgery being 154 min. Those that lasted more than 180 min were considered spine tumors, and few of the degenerative spine indications were considered. To the best of our knowledge, no global study has assessed the duration of surgery for the anatomic technique of insertion. Therefore, our study provides insight for further evaluation.

The level of the screw insertion span in our study was primarily 3 levels. For C5, 33.8% of the screws were inserted. In most other studies, the screws were inserted from C3–C6, which can be attributed to the indications in those studies being degenerative cervical spine disorders [1, 5, 8, 12].

Blood loss was less than 1000 ml in 98.4% of the patients, and there was no need for transfusion, which reduced the incidence of transfusion-related complications. No single-level radiculopathy was identified, and no C5 radiculopathy was identified, whereas 0–1.4% of patients with postoperative radiculopathy even required revision surgery.

The incidence of inadvertent durotomy and CSF leakage is 3%, which is slightly higher than the range of 0–2.1% [1, 5, 8]. Trauma is a primary indication and can have an effect on this, which needs further study. And, the incidence of postoperative surgical site infection is 6.1%, which is comparable to that reported in multiple studies. Compared with other studies, all of the patients had superficial surgical site infections, which included infected seromas requiring surgical management [1, 7, 8, 12]. No intraoperative vascular incident was identified.

Potential confounders, including surgeon experience and intraoperative complications, were not systematically evaluated. Surgeon expertise can play a significant role in surgical outcomes, and intraoperative complications such as excessive blood loss or unexpected fractures may impact the final results. Future studies could consider controlling for these variables or including them as stratification factors in the analysis. Incomplete follow-up data represents another limitation. Patients who were lost to follow-up or unable to attend their postoperative visits may have had different outcomes, which introduces a risk of bias. It would be valuable to explore the reasons behind lost follow-up and assess whether these patients differ significantly from those who completed the study.

Intraoperative complications such as inadvertent soft tissue damage or poor fracture fixation may have influenced patient outcomes. To minimize these risks, surgeons could consider more advanced fixation techniques, enhanced training, and preoperative planning to reduce the likelihood of complications during the procedure. Another limitation of our study is the absence of a standardized pain assessment tool, such as the Visual Analog Scale (VAS). Instead, we evaluated postoperative pain qualitatively by categorizing patient-reported pain as mild, moderate, or severe. While this approach provided a general assessment, it lacks the precision and

reproducibility of validated pain measurement tools. Future studies should incorporate standardized pain assessment methods like the VAS to ensure more objective and comparable results.

Postoperative radiographic evaluation of the screws revealed that the majority of the screws were in the optimum position, but there was an articular joint violation in 1.9% of the patients, and one patient experienced hardware failure immediately after the loosening of the screw nuts with dislodged rods. This has been revised. Two patients experienced screw breach to the foramen transversarum, but no 2cular complications were identified. Compared with global studies, the rate of complications is comparable but needs further follow-up to assess long-term outcomes. The clinical outcome assessed by the follow-up ASIA score was significantly associated with the preoperative ASIA score, with a P value < 0.001. The heterogeneity in patient age and trauma patterns could have influenced the overall outcomes. Older patients with multiple comorbidities or complex fractures may experience different recovery trajectories compared to younger, otherwise healthy patients. Further stratification based on these factors could provide more insights into specific patient subgroups.

Key risk factors include patient-specific variables such as advanced age, pre-existing comorbidities (e.g., diabetes, hypertension, cardiovascular disease), poor nutritional status, and immune suppression. Procedure-related factors, including prolonged operative time, excessive intraoperative blood loss, and suboptimal surgical technique, also contribute to increased complication rates. To mitigate these risks, a multifaceted approach should be adopted. Preoperatively, comprehensive risk assessments, optimized management of comorbidities, nutritional supplementation, and infection control measures can enhance patient resilience. Intraoperative strategies should focus on meticulous surgical technique, minimizing tissue trauma, maintaining hemostasis, and reducing operative duration where feasible. Postoperatively, early mobilization, stringent infection prevention protocols, and close patient monitoring can facilitate early complication detection and intervention. By incorporating these evidence-based preventive measures, surgical outcomes can be improved, and complication rates minimized. Future research should further investigate targeted interventions tailored to high-risk patient populations to enhance postoperative recovery and long-term prognosis.

To enhance the robustness of our conclusions and mitigate beta errors, we are currently conducting a prospective study as the second phase of our research, which will not only improve the statistical power of the study but also provide a more comprehensive assessment of risk factors, building upon the initial findings presented in this first study.

Conclusion

Lateral mass screw and rod fixation is a key surgical technique in our management of cervical spine disorders, particularly traumatic cervical spine injuries. Clinically and radiographically, the complication rate observed in this study is within an acceptable range. The findings provide a foundation for future research, including quality-of-life scores, long-term outcome assessments, and prospective studies.

However, as this study was based on a retrospective review of patient records and case cards, limitations arose due to incomplete, missing, or illegible documentation. The study may not fully account for unmeasured variables, such as the influence of postoperative care protocols and variations in clinical practice. Additionally, inadequate radiologic follow-up data and poor X-ray penetration hindered the comprehensive evaluation of fusion and clinical outcomes.

Recommendations for future studies include the use of more comprehensive imaging techniques such as CT scans and MRIs, consideration of surgeon experience, and improved patient follow-up protocols. Additionally, expanding research to include a broader range of patient demographics and regional data will further refine our understanding of postoperative outcomes.

Abbreviations

ACDF	Anterior cervical discectomy and fusion
ALERT	All Africa Leprosy, Tuberculosis And Rehabilitation Training Centre
ASIA	American Spinal Injury Association (Asia) Impairment Scale
AAU	Addis Ababa University
CT	Computed Tomography
HTN	Hypertension
LMSF	Lateral Mass Screw Fixation
MJOA	Modified Japan Orthopedic Association Score For Cervical Myelopathy
SD	Standard Deviation

Supplementary Information

The online version contains supplementary material available at https://doi.org/10.1186/s12891-025-08653-5.

Supplementary Material 1

Supplementary Material 2

Acknowledgements

we would like to express our deepest appreciation to Addis Ababa University, College of Sciences, and ALERT Hospital for allowing us to conduct this research. This work has not been submitted for publication in any other journal, and all the references are acknowledged.

Author contributions

S.M.M. is the lead author who coordinated data collection, analyzed the data and wrote the manuscript. M.G.T. and M.A.N. edited and reviewed the manuscript. A.K.A. and S.G.M, supervised and reviewed the manuscript.

Funding
None received.

Data availability
The datasets generated and/or analyzed during the current study are available from the corresponding author upon reasonable request.

Declarations

Ethics approval and consent to participate
This study was conducted by the Declaration of Helsinki. Ethical approval was obtained from Addis Ababa University, College of Health Sciences, School of Medicine review board and ethics committee, Addis Ababa, Ethiopia. Written informed consent was obtained from all participants before their inclusion in the study. Ethical approval number: Dos/REC/89/2024/2016.

Consent for publication
Written informed consent for publication was not required from participants included in the study, but patient confidenciality is strictly maintained.

Competing interests
The authors declare no competing interests.

Author details
[1]Department of Neurosurgery, College of Health Sciences, Addis Ababa University, Addis Ababa, Ethiopia
[2]School of Medicine, College of Health Sciences, Addis Ababa University, Addis Ababa, Ethiopia

Received: 5 February 2025 / Accepted: 14 April 2025
Published online: 25 April 2025

References

1. Al Barbarawi MM, Allouh MZ. Cervical lateral mass screw-rod fixation: surgical experience with 2500 consecutive screws, an analytical review, and long-term outcomes. Br J Neurosurg. 2015;29(5):699–704.
2. Coe JD, Vaccaro AR, Dailey AT, Skolasky RL Jr, Sasso RC, Ludwig SC, Brodt ED, Dettori JR. Lateral mass screw fixation in the cervical spine: a systematic literature review. JBJS. 2013;95(23):2136–43.
3. Roy-Camille R. Early management of spinal injuries. Recent advances in orthopedics. 1979.
4. Merola AA, Castro BA, Alongi PR, Mathur S, Brkaric M, Vigna F, Riina JP, Gorup J, Haher TR. Anatomic considerations for standard and modified techniques of cervical lateral mass screw placement. Spine J. 2002;2(6):430–5.
5. Joaquim AF, Mudo ML, Tan LA, Riew KD. Posterior subaxial cervical spine screw fixation: a review of techniques. Global Spine J. 2018;8(7):751–60.
6. HELLER JG, CARLSON GD, ABITBOL JJ, GARFIN SR. Anatomic comparison of the Roy-Camille and Magerl techniques for screw placement in the lower cervical spine. Spine. 1991;16:S552–7.
7. Kim HS, Suk KS, Moon SH, Lee HM, Kang KC, Lee SH, Kim JS. Safety evaluation of freehand lateral mass screw fixation in the subaxial cervical spine: evaluation of 1256 screws. Spine. 2015;40(1):2–5.
8. Al Barbarawi MD, Audat ZA, Obeidat MM, Qudsieh TM, Dabbas WF, Obaidat MH, Malkawi AA. Decompressive cervical laminectomy and lateral mass screw-rod arthrodesis. Surg Anal Outcome Scoliosis. 2011;6:1–6.
9. Kelleher MO, McEvoy L, Yang JP, Kamel MH, Bolger C. Lateral mass screw fixation of complex spine cases: a prospective clinical study. Br J Neurosurg. 2008;22(5):663–8.
10. Rehman L, Bukhari I, Afzal A, Rizvi R. Lateral mass screw fixation in cervical spine injury. Pakistan J Med Sci. 2017;33(6):1355.
11. Elfattah AS. Evaluation of lateral mass fixation of the cervical spine. Egypt Orthop J. 2019;54(3):249–56.
12. Aydogan M, Enercan M, Hamzaoglu A, Alanay A. Reconstruction of the subaxial cervical spine using lateral mass and facet screw instrumentation. Spine. 2012;37(5):E335–41.
13. Pateder DB, Carbone JJ. Lateral mass screw fixation for cervical spine trauma: associated complications and efficacy in maintaining alignment. Spine J. 2006;6(1):40–3.
14. Deen HG, Birch BD, Wharen RE, Reimer R. Lateral mass screw–rod fixation of the cervical spine: a prospective clinical series with 1-year follow-up. Spine J. 2003;3(6):489–95.
15. Hedequist D, Proctor M, Hresko T. Lateral mass screw fixation in children. J Child Orthop. 2010;4(3):197–201.
16. Yoon SH, Park HC, Park HS, Kim EY, Ha Y, Chong CK, Kim SM, Rim DC. Radiological considerations of posterior cervical lateral mass fixation using plate and screw. Yonsei Med J. 2004;45(3):406–12.
17. Zuckerman SL, Haghdel A, Lessing NL, Carnevale J, Cheserem B, Lazaro A, Leidinger A, Rutabasibwa N, Shabani HK, Mangat H, Härtl R. Cervical spine trauma in East Africa: presentation, treatment, and mortality. Int J Spine Surg. 2021;15(5):879–89.

Publisher's note

Springer Nature remains neutral with regard to jurisdictional claims in published maps and institutional affiliations.