BMC Nephrology

CASE REPORT Open Access

Unilateral global renal infarction in a patient with ischemic stroke and hypertensive heart disease in a resource limited setting: a case report

Tesfaye Birhanu Abebe[1,4*], Getahun Jiru Bedada[2*], Yakob Tadesse Fantu[3*], Diriba Shiferaw Negese[3], Biniyam Bona Tasi[3], Henok Dessie Wubneh[4], Fraol Zeleke Desta[1] and Solomon Kebede Adugna[2]

Abstract

Introduction Renal infarction is a rare ischemic event, occurring in 0.004–0.007% of emergency room admissions, with global renal infarction being extremely rare and caused by the blockage of the main renal artery or its branches, often due to emboli from the heart or in situ thrombosis, leading to renal ischemia. We present a rare case of complete renal infarction, highlighted not only by its coincidence with ischemic stroke and hypertensive heart disease, but also by its rapid progression to acute renal failure and cardiac arrest, despite aggressive medical management.

Case presentation A 72-year-old female patient, known to be hypertensive with a history of hypertensive heart disease and ischemic stroke, discontinued her follow-up two months prior to her presentation at the emergency department. She presented with a dry, intermittent cough and shortness of breath of five days' duration. She was admitted with a diagnosis of severe community-acquired pneumonia and started on antibiotics, intranasal oxygen, and analgesics. Subsequently, she developed severe right-sided loin pain and vomiting, along with persistent shortness of breath. A contrast-enhanced chest computed tomography scan was performed to rule out acute pulmonary thromboembolism due to her persistent shortness of breath, which incidentally revealed a globally unilateral right renal infarction secondary to renal artery thrombosis. Despite initiating unfractionated heparin, warfarin, and supportive therapies, the patient unfortunately passed away 19 days after admission.

Conclusion Unilateral global renal infarction in a patient with hypertensive heart disease and ischemic stroke, though rare, can present with pronounced symptoms of acute renal failure and ultimately cardiac arrest. Prompt recognition and management of risk factors, including hypertension and previous thromboembolic events, are crucial for preventing fatal outcomes.

*Correspondence:
Tesfaye Birhanu Abebe
tesfu13b21@gmail.com
Getahun Jiru Bedada
getahunjirubedada@gmail.com
Yakob Tadesse Fantu
ebirhan21@gmail.com

Full list of author information is available at the end of the article

© The Author(s) 2025. **Open Access** This article is licensed under a Creative Commons Attribution-NonCommercial-NoDerivatives 4.0 International License, which permits any non-commercial use, sharing, distribution and reproduction in any medium or format, as long as you give appropriate credit to the original author(s) and the source, provide a link to the Creative Commons licence, and indicate if you modified the licensed material. You do not have permission under this licence to share adapted material derived from this article or parts of it. The images or other third party material in this article are included in the article's Creative Commons licence, unless indicated otherwise in a credit line to the material. If material is not included in the article's Creative Commons licence and your intended use is not permitted by statutory regulation or exceeds the permitted use, you will need to obtain permission directly from the copyright holder. To view a copy of this licence, visit http://creativecommons.org/licenses/by-nc-nd/4.0/.

Keywords Acute kidney injury, Global renal infarction, Hypertension, Hypertensive heart disease, Ischemic stroke

Introduction

Renal infarction is a rare ischemic event, with studies showing an incidence of 0.004–0.007% in emergency room admissions, with global renal infarction being even more extremely rare [1]. This condition arises from the complete or partial blockage of the main renal artery or its branches, leading to renal ischemia, which in turn results from an embolus originating in the heart or an in situ thrombosis [2]. Renal artery thrombosis can occur due to atherosclerotic occlusions in the aorta or renal artery, and thrombus formation in thoracic or suprarenal abdominal aortic aneurysms, associated with risk factors such as hyperlipidemia and hypertension [3]. Other causes include aortic thromboembolism, trauma, renal artery dissection, coagulation disorders, and other atheroembolic diseases [4]. Patients with acute renal infarctions often present with sudden abdominal or flank pain, nausea, vomiting, hematuria, and sometimes fever [2]. The condition can mimic other disorders, causing delayed diagnosis, or it may be asymptomatic and incidentally discovered during imaging for other reasons, as was the case when the patient was sent for a contrast-enhanced chest CT scan to rule out acute pulmonary thromboembolism. This case report highlights a rare instance of unilateral complete renal infarction in a 72-year-old female with a history of hypertensive heart disease and ischemic stroke. The rarity is underscored not only by its coincidence with ischemic stroke and hypertensive heart disease but also by its rapid progression to acute renal failure and cardiac arrest despite aggressive medical management.

Case presentation

A 72-year-old known hypertensive female with a history of hypertensive heart disease and ischemic stroke for the past 2 years and 6 months, respectively, had been on regular follow-up until she discontinued her medication two months prior to her current presentation. Her medications included aspirin, atorvastatin, hydrochlorothiazide, and enalapril for the treatment of ischemic stroke and hypertension. She presented with a dry, intermittent cough and shortness of breath of five days' duration. There was no history of abdominal aortic aneurysm in the patient or her family, no prior surgical history, and no history of malignancy, recurrent pregnancy loss, smoking, alcohol use, or intravenous drug abuse. On physical examination, she appeared acutely sick-looking, tachypneic, and in respiratory distress, with an oxygen saturation of 84% on room air. Other vital signs were within normal limits. Her body mass index was 22.8, within normal limits. Chest examination revealed coarse crepitation over the right lower third of the lung field. Neurologic examination showed a Glasgow Coma Scale score of 15/15. Motor examination showed power of 2/5, reflexes of 3/4, and hypertonicity in the left upper and lower extremities, and power of 5/5, reflexes of 2/4, and normal tone in the contralateral extremities, leading to a conclusion of left-sided spastic hemiparesis.

The patient's complete blood count, serum electrolyte, liver function tests, renal function tests, coagulation and lipid profile, lactate dehydrogenase level, and urinalysis were in the normal range at the time of presentation. Chest x-ray revealed patchy opacities in the right lower lobe (Fig. 1). Electrocardiogram indicated left axis deviation with left ventricular hypertrophy. Echocardiography revealed increased left ventricular mass and relative wall thickness indicating concentric left ventricular hypertrophy and grade 3 left ventricular diastolic dysfunction (Fig. 2). Non-contrast brain CT scan done six months back demonstrated a hypoattenuating lesion with loss of gray-white differentiation involving the right middle cerebral artery territory, indicating an acute infarct with no mass effect on adjacent structures (Fig. 3). Besides resumption of oral medications (aspirin, atorvastatin, hydrochlorothiazide, and enalapril), the patient was treated with antibiotics, intranasal oxygen, and analgesics, considering severe community-acquired pneumonia. On the fourth day of admission, the patient developed severe right-sided flank pain and vomiting, in addition to the persistent shortness of breath. Repeat laboratory investigations (complete blood count, renal/liver function tests, electrolytes, and coagulation profile) were normal except for elevated lactate dehydrogenase. Advanced thrombophilia testing, including antiphospholipid antibody assessment, was clinically indicated but unavailable due to resource constraints. A contrast-enhanced chest CT scan was performed to assess for acute pulmonary thromboembolism. While no signs of pulmonary embolism were detected, the scan incidentally revealed complete infarction of the right kidney secondary to renal artery thrombosis. Axial contrast-enhanced CT images demonstrated a non-enhancing right kidney, with a hypodense thrombus occluding the right renal artery and absence of contrast flow distal to the obstruction (Fig. 4). The abdominal aorta appeared normal in caliber, measuring approximately 21 mm, with no evidence of thrombus or aneurysm. The left renal artery was also normal in diameter and demonstrated a typical contrast enhancement pattern without any thrombus. The left kidney measured 10.2 × 5.1 cm, while the right kidney was slightly larger at 10.8 × 5.6 cm.

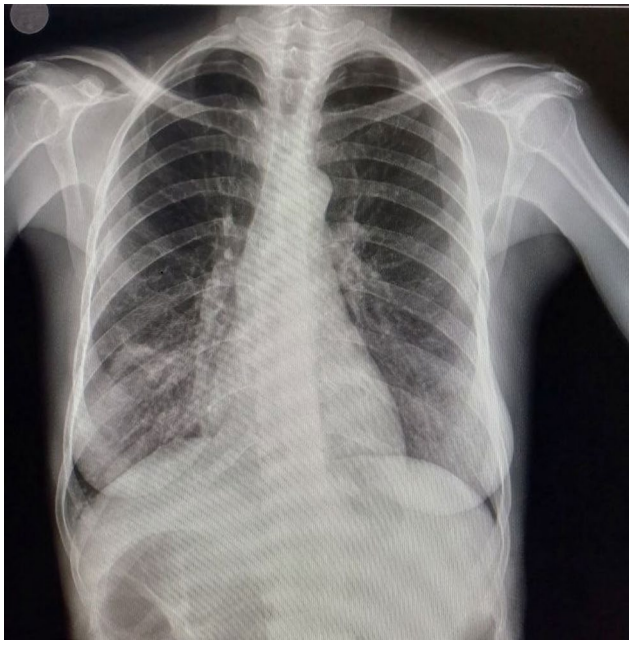

Fig. 1 Chest X-ray depicted right basal lung patchy opacities

Unfractionated heparin and warfarin were initiated in addition to aspirin and atorvastatin, along with analgesics, oxygen, and other supportive therapies, but enalapril was discontinued. Despite anticoagulant therapy, serial creatinine levels started to rise from the 5th day onwards and continued rising with LDH subsequently (Table 1). The patient developed bilateral leg swelling, decreased urine output, hematuria, confusion, and hypotension within 10 days of admission, consistent with acute kidney injury (AKI) secondary to cardio renal syndrome superimposed renal infarction. Management included cautious initiation of intravenous furosemide (20–40 mg daily) for volume overload, judicious fluid restriction (1000–1500 mL/day), and close monitoring of electrolytes, urine output, and hemodynamic status. The patient's persistent hypotension, necessitating vasopressor infusion to sustain adequate perfusion pressure, created a clear indication for continuous renal replacement therapy (CRRT). Unfortunately, the required CRRT setup was not available. Further laboratory investigation revealed leukocytosis (14,200 white cells/μL), elevated C-reactive protein levels ((15.8 mg/dL)), and negative blood culture results. Urinalysis findings were consistent with renal infarction,

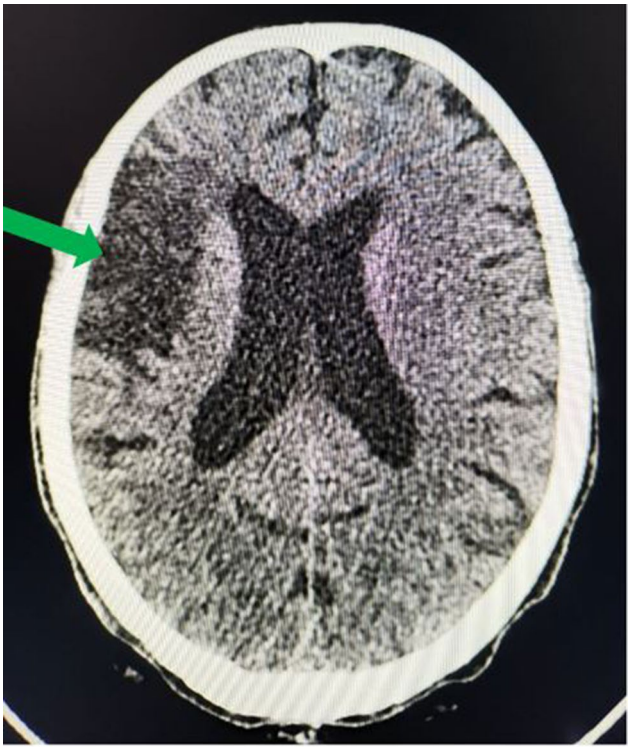

Fig. 3 Brain CT without contrast taken 6 months ago demonstrating hypoattenuating lesion with loss of gray-white differentiation involving the right middle cerebral artery territory indicating acute infarct (green arrow)

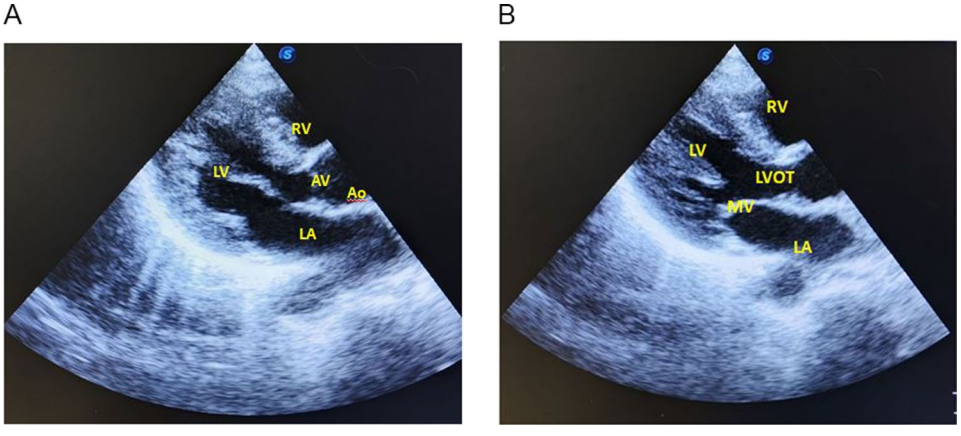

Fig. 2 Echocardiography parasternal long axis during diastole (**A**) and systole (**B**) demonstrating increased LV mass and relative left ventricular relative wall thickness indicating concentric left ventricular hypertrophy. (Ao- Aortic root, AV- Aortic valve, LA- Left atrium, LV- Left ventricle, LVOT- Left ventricular out flow tract, and MV-Mitral valve)

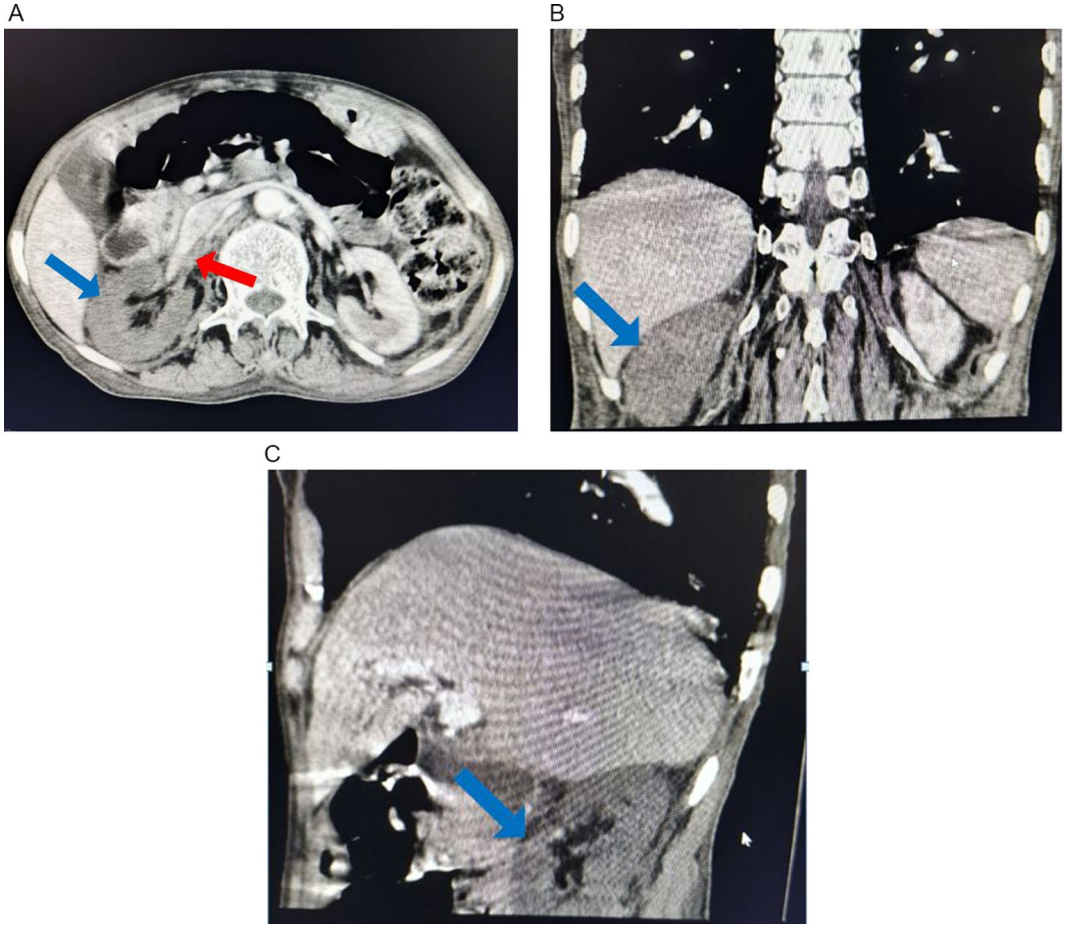

Fig. 4 (**A**) Axial contrast-enhanced CT showed a completely non-enhancing right kidney (blue arrow), with a hypodense thrombus visualized within the right renal artery and no contrast enhancement distal to it (red arrow). (**B**) and (**C**) Coronal and sagittal views, respectively, demonstrated a globally non-enhanced right kidney (blue arrows)

Table 1 Urine output and investigation summary during the course of treatment

	1st day of admission	5th day of admission	10th day of admission	14th day of admission	16th day of admission	19th day of admission
Urine output (ml/kg/hr)	1.1	0.8	0.4	0.7	0.5	0.2
White blood cells (3.0–11.0(10^6/ul))	9.28	8.47	8.18	10.6	14.2	13.4
Hemoglobin (12–21 g/dl)	13.6	13.4	10.89	9.9	8.5	8.2
Platelet (140–460(10^3/ul))	135	149	128	106	134	145
Creatinine (0.6-1.2 mg/dL)	0.81	3.48	7.18	9.37	9.86	10.69
Urea	32.6	163	187.3	216.8	252	331.2
Lactate dehydrogenase(100–220 U/L)	113	1610	1887	1723	1852	1904

showing gross hematuria (3 + blood on dipstick, > 50 RBCs/hpf), mild proteinuria (1 + on dipstick), without RBC casts. The presence of leukocytosis and raised CRP but negative blood cultures suggested ongoing systemic inflammation due to hypoperfusion resulting from progressive diastolic and subsequent systolic dysfunction, secondary to underlying hypertensive heart disease and complete renal infarction. By the 19th day of admission, the patient's condition deteriorated, culminating in cardiogenic shock and acute kidney injury secondary to complete renal infarction. The patient required dual vasopressors (norepinephrine and vasopressin) and intensive care unit support but unfortunately succumbed to cardiac arrest.

Discussion

Renal infarction is an uncommon but serious condition characterized by the sudden loss of blood supply to a segment or complete part of the kidney, leading to ischemia and tissue necrosis [5]. Autopsy studies suggest

the incidence of renal infarction is 14 per 1000, or 1.4%. Other retrospective studies of emergency room admissions found an incidence of 0.004–0.007% [6]. A study of over 600 patients with peripheral arterial thromboembolism found the renal arteries to be affected in just 2% of cases [7]. In a case series of 27 patients, 41% had identifiable cardiac disease, predominantly atrial fibrillation, while idiopathic cases generally involved younger patients with fewer risk factors [8]. The two major causes of renal infarction are thromboemboli and in situ thrombosis [1, 4]. Thromboemboli usually originate from a thrombus in the heart or aorta, and in situ thrombosis is usually due to an underlying hypercoagulable condition or injury to or dissection of a renal artery. Either thromboemboli or in situ thrombi may cause complete occlusion of the main renal artery or smaller segmental branch arteries. Because atheroemboli are small and typically lead to incomplete arterial occlusion of more distal vessels, atheroemboli often lead to secondary ischemic atrophy rather than renal infarction. Renal artery thrombosis, resulting from atherosclerotic occlusions within the aorta or renal artery and thoracic or suprarenal abdominal aortic aneurysms promoting thrombus formation, is associated with risk factors such as male gender, smoking, hypertension, hypercholesterolemia, diabetes, older age [3, 9]. In this case, hypertension, older age, and a previous ischemic insult - along with drug discontinuation - could have contributed to the development of renal artery thrombosis, leading to complete renal infarction. While this atherothrombotic mechanism appears predominant in our patient, clinicians should remain vigilant for alternative etiologies in similar high-risk patients with stroke history and hypertensive heart disease. Paroxysmal atrial fibrillation requires particular exclusion through prolonged cardiac monitoring (implantable loop recorder or Holter monitoring) [10], given its potential to evade detection despite suggestive features like prior embolic stroke and left ventricular hypertrophy. Antiphospholipid syndrome warrants thrombophilia evaluation when resources permit, as recurrent arterial thrombosis - even without classic obstetric manifestations - may indicate this condition. Other hypercoagulable states should also be considered, especially when arterial thrombosis occurs without classic risk factors. Importantly, medication non-adherence may serve both as a precipitant of acute events and an obstacle to identifying underlying predispositions, highlighting the need for comprehensive evaluation in these complex cases.

Patients with acute renal infarctions usually present with sudden abdominal or flank pain, nausea, vomiting, hematuria, and sometimes fever [11]. Skin color changes are seen in about one-third of cases [12]. The condition can mimic other disorders, leading to delayed diagnosis [11]. Some patients may be asymptomatic, contributing to underdiagnosis, and may be discovered incidentally during imaging for other reasons, as in this case where the patient was sent to have a contrast-enhanced chest CT scan to rule out acute pulmonary thromboembolism.

Renal thromboembolism should always be considered in the differential diagnosis for patients presenting with acute flank or abdominal pain, particularly when accompanied by elevated lactate dehydrogenase (LDH) and/or hematuria [13]. Laboratory findings typically reveal elevated LDH levels in nearly all cases [14], making this a key diagnostic indicator. Urinalysis often demonstrates hematuria (though not universally), while proteinuria is observed in approximately 45% of patients [14]. Although serum creatinine levels usually show a slight increase without being significantly elevated initially [7], this case was different, marked by a sudden rapid increase in both creatinine and LDH levels, coinciding with the detection of complete renal infarction in previously normal lab results, highlighting the rarity of this occurrence. Imaging plays a crucial role in accurately diagnosing renal infarction, with angiography yielding positive results in all cases and renal isotope exams showing abnormalities in 97% of cases [7]. CT scans are diagnostic in 80% of cases, while ultrasound is positive in only 3% of cases [7]. Contrast-enhanced CT scans are the preferred diagnostic tool, as they reveal wedge-shaped, peripheral, non-enhancing areas, hypoattenuated regions with a mass effect, and occasionally a cortical rim sign, which helps differentiate between ischemia and pyelonephritis [15]. Given the often vague presentation of renal infarction, maintaining a high degree of clinical suspicion is essential for diagnosis.

The optimal treatment for renal infarction is controversial. Some recommend anticoagulation alone, particularly for unilateral embolisms with limited potential for renal salvage [16]. This usually starts with a heparin bolus followed by continuous infusion and long-term coumadin administration. Open surgical revascularization is advised for embolic occlusions but is generally restricted to trauma scenarios. While surgical embolectomy can help reduce hypertension, it often fails to restore renal function and is primarily used for acute occlusions of significant renal arteries or branches [16]. Catheter-directed thrombolysis (CDT) was also employed as the primary revascularization modality in select cases involving acute occlusion of the main renal artery trunk, provided patients had no contraindications to thrombolytics (e.g., active bleeding, recent surgery) and were medically stable to undergo the procedure. The thrombolytic regimen consisted of a bolus dose of tPA followed by continuous urokinase infusion [16, 17]. In this case, due to resource constraints, thrombolysis or thrombectomy was not pursued; treatment focused on anticoagulants consisting of unfractionated heparin

and warfarin in addition to aspirin and atorvastatin, and blood pressure monitoring along with analgesics, and supportive therapies. Despite therapeutic anticoagulation, the patient progressed to stage 3 AKI with oliguric renal failure, manifesting as generalized edema, confusion, gross hematuria, and hypotension requiring diuretics, fluid restriction, and vasopressor. Although complete unilateral renal infarction rarely leads to oliguric AKI in patients with prior normal renal function (due to compensatory hyperfiltration in the contralateral kidney), this patient's rapid progression to stage 3 AKI reflects the compounding effects of acute hemodynamic collapse and systemic inflammation. Despite the absence of baseline CKD (normal pre-admission creatinine) or sepsis (negative cultures, no fever), two synergistic mechanisms likely drove the fulminant course: [1] type 1 cardiorenal syndrome from refractory hypotension and hypertensive cardiomyopathy, causing critical renal hypoperfusion [18], and [2] infarction-induced systemic inflammation (elevated CRP 15.8 mg/dL, LDH 1904 U/L) that may have exacerbated tubular injury independent of infection [19]. The concurrence of complete vascular occlusion with globally reduced perfusion pressure created a unique 'two-hit' scenario, where compensatory mechanisms were overwhelmed despite unilateral involvement [20]. The rapid AKI progression observed in this hemodynamically unstable patient, despite absent sepsis or baseline renal impairment, implies that the confluence of vascular occlusion and circulatory collapse may constitute a unique clinical entity warranting heightened surveillance. This patient developed clear indications for renal replacement therapy (RRT), including volume overload refractory to diuretics and uremic encephalopathy with altered mental status. Her clinical course was further complicated by persistent hemodynamic instability requiring multiple vasopressors, ultimately progressing to cardiogenic shock. In this critical context, continuous renal replacement therapy (CRRT) represented the most physiologically appropriate renal support modality, as it permits gradual fluid removal and solute clearance while minimizing hemodynamic perturbations - a particular advantage in vasopressor-dependent acute kidney injury (AKI) [21, 22]. Current critical care guidelines strongly recommend CRRT for such cases of circulatory instability in the ICU setting [23]. Despite these compelling indications and after multidisciplinary consultation, CRRT could not be initiated due to unavailability of the required setup. The patient's clinical trajectory reflected progressive multiorgan failure stemming from three interrelated pathological processes: [1] a primary vascular insult from renal artery thrombosis causing complete parenchymal infarction [2], a secondary systemic inflammatory response evidenced by markedly elevated C-reactive protein (15.8 mg/dL) and LDH (peak 1904 U/L), and [3] tertiary cardiorenal syndrome due to exacerbation of underlying hypertensive heart disease. This pathophysiological cascade culminated in refractory circulatory collapse despite maximal intensive care measures, including dual vasopressor therapy with norepinephrine and vasopressin. The patient's refractory hypotension arose from two primary mechanisms: [1] cardiogenic shock due to decompensated hypertensive heart disease, independent of the renal artery thrombosis causing infarction; [2] inflammatory-mediated vasodilation evidenced by elevated CRP (15.8 mg/dL), potentially exacerbated by ischemic tissue injury from the infarction. While renal infarction secondary to thromboembolism typically induces hypertension via renin-angiotensin activation [24], the coexisting cardio renal syndrome and systemic inflammation instead drove refractory circulatory failure. This dichotomy between structural occlusion (thrombosis) and functional hemodynamic collapse (cardiogenic/inflammatory) illustrates how competing pathologies can distort classical clinical paradigms.

Conclusion

Unilateral complete renal infarction in a patient with hypertensive heart disease and ischemic stroke, though rare, can present with pronounced symptoms of acute renal failure and ultimately cardiac arrest. It is crucial for healthcare providers to recognize this often underdiagnosed but fatal condition and to improve follow-up and drug adherence to minimize renal infarction risk factors, such as hypertension and previous thromboembolic events.

Supplementary Information

The online version contains supplementary material available at https://doi.org/10.1186/s12882-025-04289-8.

Supplementary Material 1

Acknowledgements

We express our gratitude to all hospital staff involved in the patient's management and extend our appreciation to the patient and their family for their cooperation and consent.

Author contributions

TBA conceptualized, managed the patient, wrote original draft of the manuscript, reviewed, edited, and visualized the final manuscript. GJB conceptualized, reviewed and edited the manuscript, and prepared the figures. YTF managed the patient, wrote original draft of the case presentation, assisted in manuscript revision and data curation. DSN managed the patient and assisted in literature revision and supervised. BBT assisted in data curation and manuscript revision. FZD assisted in data curation and manuscript revision and edition. SKA prepared the radiologic images and assisted in manuscript revision. All authors read and approved the final manuscript.

Funding

No funding was received.

Data availability
All data supporting the findings of this study are available within the paper and its Supplementary Information.

Declarations

Ethics approval and consent to participate
The family of the patient has provided written informed consent for the publication of their case details and any related images. The study was conducted in accordance with the ethical principles outlined in the Declaration of Helsinki. Approval for this case report was not required to secure from the Ethics Committee of the institution.

Consent for publication
Written informed consent was obtained from the family of the patient for publication and any accompanying images. A copy of the written consent is available for review by the Editor-in-Chief of this journal on request.

Competing interests
The authors declare no competing interests.

Author details
[1]Department of Surgery, School of Medicine, Collage of Health Sciences, Salale University, P.O. BOX: 245, Fitche, Ethiopia
[2]Department of Radiology, School of Medicine, Collage of Health Sciences, Salale University, Fitche, Ethiopia
[3]Department of Internal Medicine, School of Medicine, Collage of Health Sciences, Salale University, Fitche, Ethiopia
[4]School of Medicine, Collage of Medicine and Health Sciences, University of Gondar, Gondar, Ethiopia

Received: 1 January 2025 / Accepted: 26 June 2025
Published online: 03 July 2025

References

1. Gürger M. A rare diagnosis in the emergency department: renal infarction. Genel Tıp Dergisi. 2022;32(3):293–7.
2. Mesiano P, Rollino C, Beltrame G, Ferro M, Quattrocchio G, Fenoglio R, et al. Acute renal infarction: a single center experience. J Nephrol. 2017;30:103–7.
3. Lyaker MR, Tulman DB, Dimitrova GT, Pin RH, Papadimos TJ. Arterial embolism. Int J Crit Illn Inj Sci. 2013;3(1):77–87.
4. Faucon A-L, Bobrie G, Jannot A-S, Azarine A, Plouin P-F, Azizi M, et al. Cause of renal infarction: a retrospective analysis of 186 consecutive cases. J Hypertens. 2018;36(3):634–40.
5. Brezis M, Rosen S, Silva P, Epstein FH. Renal ischemia: a new perspective. Kidney Int. 1984;26(4):375–83.
6. Yang J, Lee JY, Na YJ, Lim SY, Kim M-G, Jo S-K, et al. Risk factors and outcomes of acute renal infarction. Kidney Res Clin Pract. 2016;35(2):90–5.
7. Hazanov N, Somin M, Attali M, Beilinson N, Thaler M, Mouallem M, et al. Acute renal embolism: forty-four cases of renal infarction in patients with atrial fibrillation. Medicine. 2004;83(5):292–9.
8. García-García A, Demelo-Rodríguez P, Ordieres-Ortega L, Cervilla-Muñoz E, García-Fernández-Bravo I, Pulfer MD, et al. Idiopathic versus provoked renal infarction: characteristics and long-term follow-up of a cohort of patients in a tertiary hospital. Kidney Blood Press Res. 2019;44(6):1432–40.
9. Piechocki M, Przewłocki T, Pieniążek P, Trystuła M, Podolec J, Kabłak-Ziembicka A. A non-coronary, peripheral arterial atherosclerotic disease (carotid, renal, lower limb) in elderly patients—A review: part I—Epidemiology, risk factors, and atherosclerosis-related diversities in elderly patients. J Clin Med. 2024;13(5):1471.
10. Galli A, Ambrosini F, Lombardi F. Holter monitoring and loop recorders: from research to clinical practice. Arrhythmia Electrophysiol Rev. 2016;5(2):136.
11. Huang C-C, Lo H-C, Huang H-H, Kao W-F, Yen DH-T, Wang L-M, et al. ED presentations of acute renal infarction. Am J Emerg Med. 2007;25(2):164–9.
12. Saju JM, Leslie SW. Renal infarction. StatPearls [Internet]: StatPearls Publishing; 2024.
13. Poggiali E, Ferrari MG, Botti C, Michieletti E, Vercelli A. Renal artery thrombosis. A case of acute flank pain in a patient with a new onset of renal failure and atrial fibrillation. Acta Bio-medica: Atenei Parmensis. 2023;94(3):e2023140–e.
14. Lopez VM, Glauser J. A case of renal artery thrombosis with renal infarction. J Emerg Trauma Shock. 2010;3(3):302.
15. Parmar N, Langdon J, Kaliannan K, Mathur M, Guo Y, Mahalingam S. Wunderlich syndrome: Wonder what it is. Curr Probl Diagn Radiol. 2022;51(2):270–81.
16. Silverberg D, Menes T, Rimon U, Salomon O, Halak M. Acute renal artery occlusion: presentation, treatment, and outcome. J Vasc Surg. 2016;64(4):1026–32.
17. Patel N, Patel NJ, Agnihotri K, Panaich SS, Thakkar B, Patel A, et al. Utilization of catheter-directed thrombolysis in pulmonary embolism and outcome difference between systemic thrombolysis and catheter-directed thrombolysis. Catheter Cardiovasc Interv. 2015;86(7):1219–27.
18. Ronco C, Cicoira M, McCullough PA. Cardiorenal syndrome type 1: pathophysiological crosstalk leading to combined heart and kidney dysfunction in the setting of acutely decompensated heart failure. J Am Coll Cardiol. 2012;60(12):1031–42.
19. Kashani K, Al-Khafaji A, Ardiles T, Artigas A, Bagshaw SM, Bell M, et al. Discovery and validation of cell cycle arrest biomarkers in human acute kidney injury. Crit Care. 2013;17:1–12.
20. Abello PA, Buchman TG, Bulkley GB. Shock and multiple organ failure. Free radicals in diagnostic medicine: a systems approach to laboratory technology, clinical correlations, and antioxidant therapy. 1994:253–68.
21. Levey AS, Eckardt K-U, Dorman NM, Christiansen SL, Hoorn EJ, Ingelfinger JR et al. Nomenclature for kidney function and disease: report of a Kidney Disease: Improving Global Outcomes (KDIGO) Consensus Conference. Kidney international. 2020;97(6):1117-29.
22. Soni SS, Nagarik AP, Adikey GK, Raman A. Using continuous renal replacement therapy to manage patients of shock and acute renal failure. J Emerg Trauma Shock. 2009;2(1):19–22.
23. Prowle JR, Bellomo R. Continuous renal replacement therapy: recent advances and future research. Nat Rev Nephrol. 2010;6(9):521–9.
24. Paris B, Bobrie G, Rossignol P, Le Coz S, Chedid A, Plouin P-F. Blood pressure and renal outcomes in patients with kidney infarction and hypertension. J Hypertens. 2006;24(8):1649–54.

Publisher's note

Springer Nature remains neutral with regard to jurisdictional claims in published maps and institutional affiliations.