ANATOMY

Musculoskeletal System

For post basic nursing & midwifery

Dr. Genale
(MD)

Objectives

- Describe the anatomy of the bones, muscles, and joints.
- Discuss the directional movements of the joints.
- Develop questions to be used when completing the focused interview.
- Describe the techniques required for assessment of the musculoskeletal system.
- Differentiate normal from abnormal findings of the musculoskeletal system.

Musculoskeletal System

- Provides structure and movement for the body
- Consists of bones, skeletal muscles, and joints
- Allows the body to stand erect and move

- Supports and protects organs

- Produces red blood cells

Musculoskeletal System

- Stores fat and minerals
- Generates heat

Skeleton

- Consists of 206 bones
- Provides support for the soft tissue and organs of the body

Bones of the human skeleton.

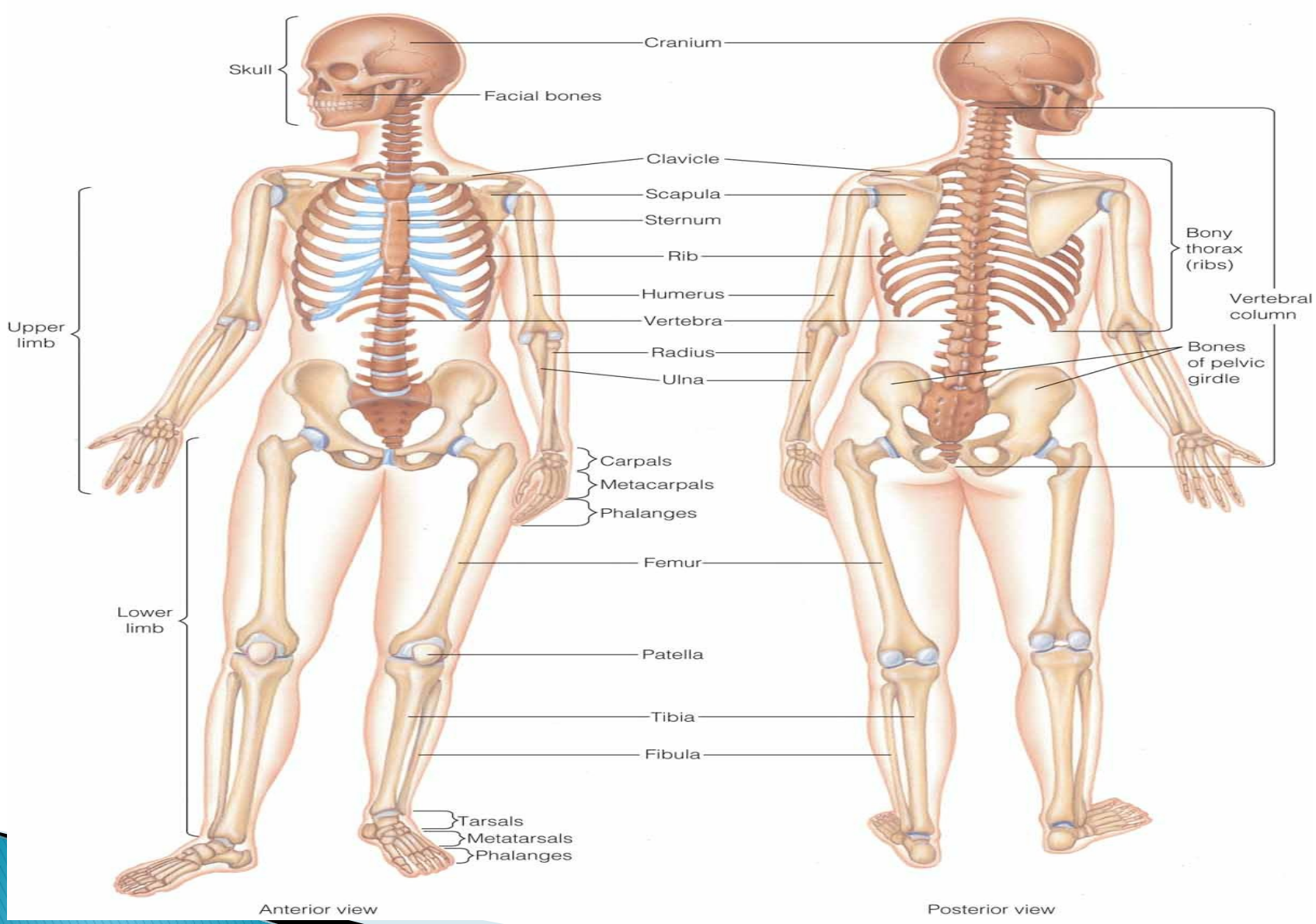

Skeleton

- Classification
  - Long
  - Short
  - Flat
  - Irregular
- Composition

Classification of bones according to shape.

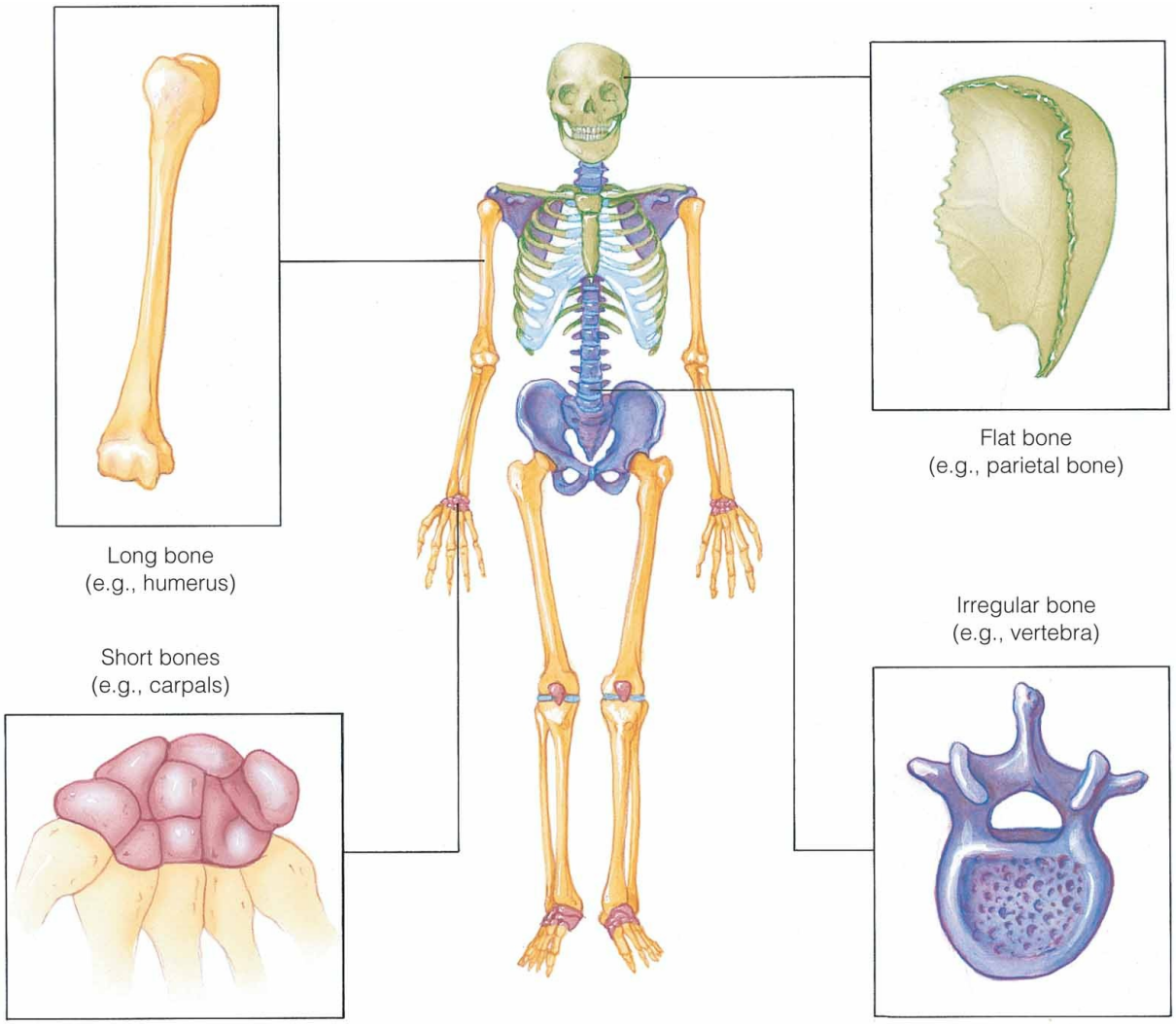

Skeleton

- Major functions
  - Framework for the body
  - Protect structures
  - Act as levers for movement
  - Store fat and minerals
  - Produce blood cells

Anterior view of muscles of the human body.

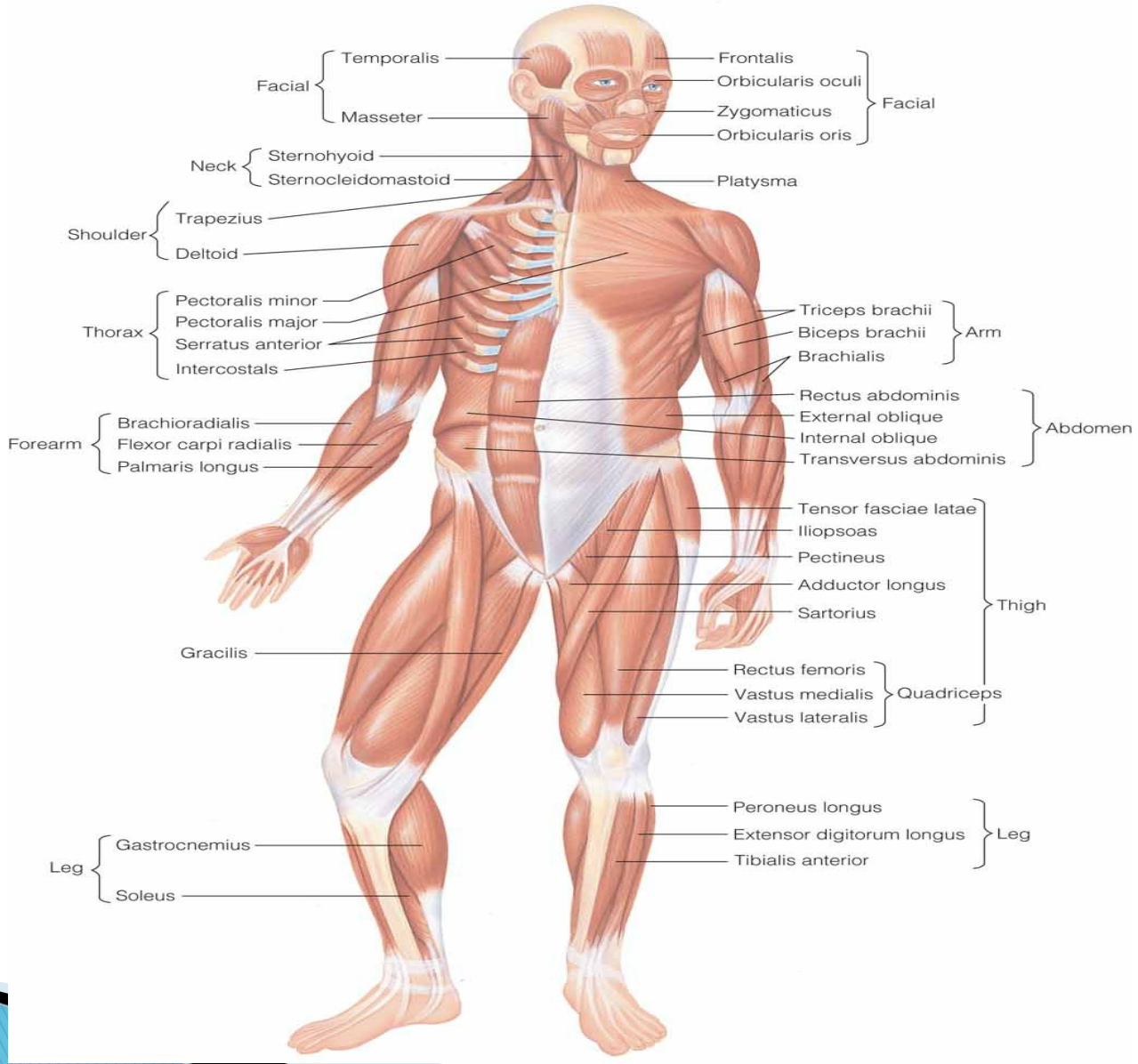

Posterior view of muscles of the human body.

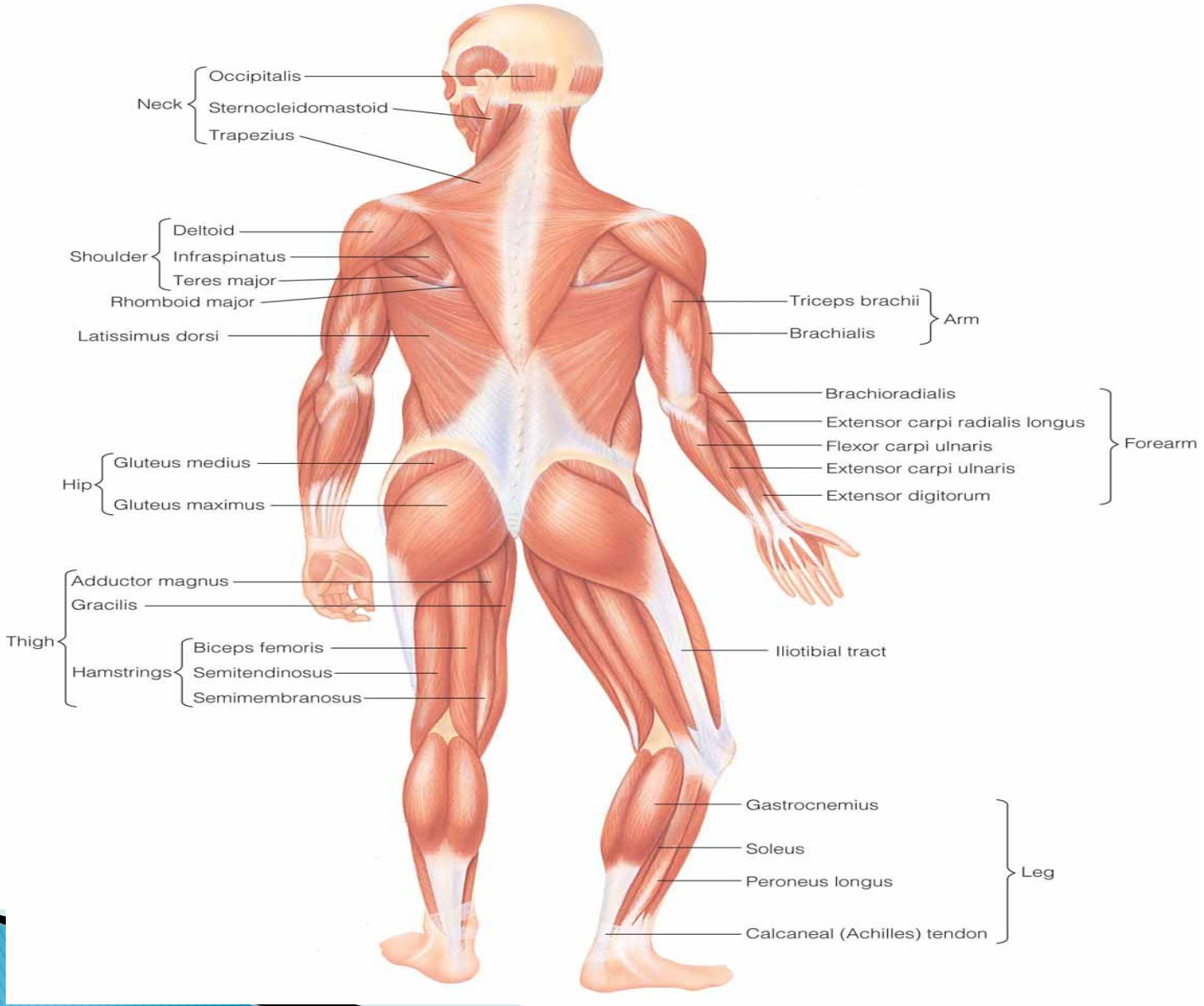

Skeletal Muscles

- Major functions
  - Movement
  - Posture
  - Body heat

Joints

- Fibrous
- Cartilaginous
- Synovial

Major Joints

- Ankle
- Spine

Temporomandibular Joint

- Permits Articulation Between the Temporal Bone and the Mandible

Temporomandibular joint. The enlargement shows a sagittal section through the joint.

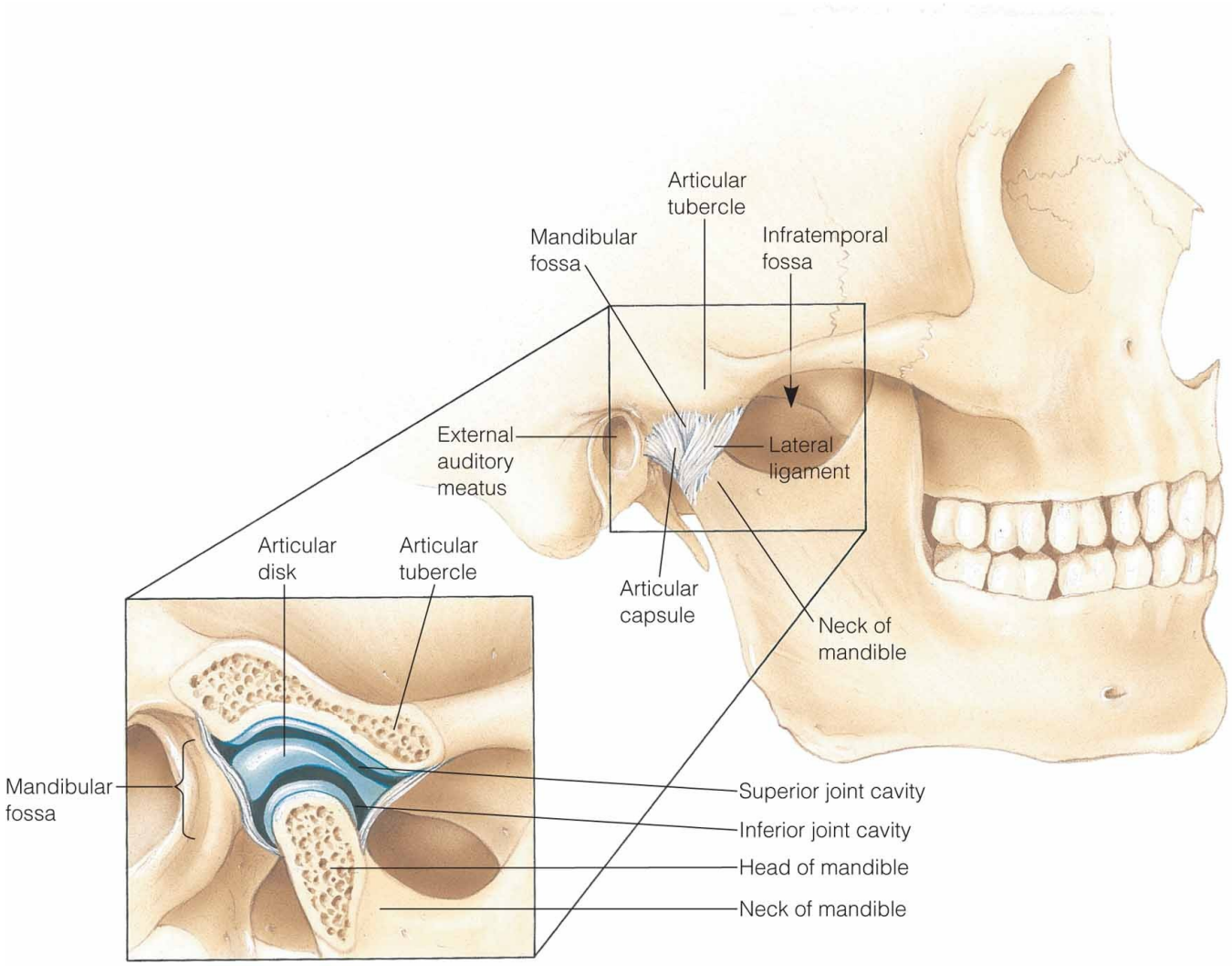

Shoulder Joint

- Ball-and-Socket Joint in Which the Head of the Humerus Articulates With the Glenoid Capsule of the Scapula

Shoulder joint.

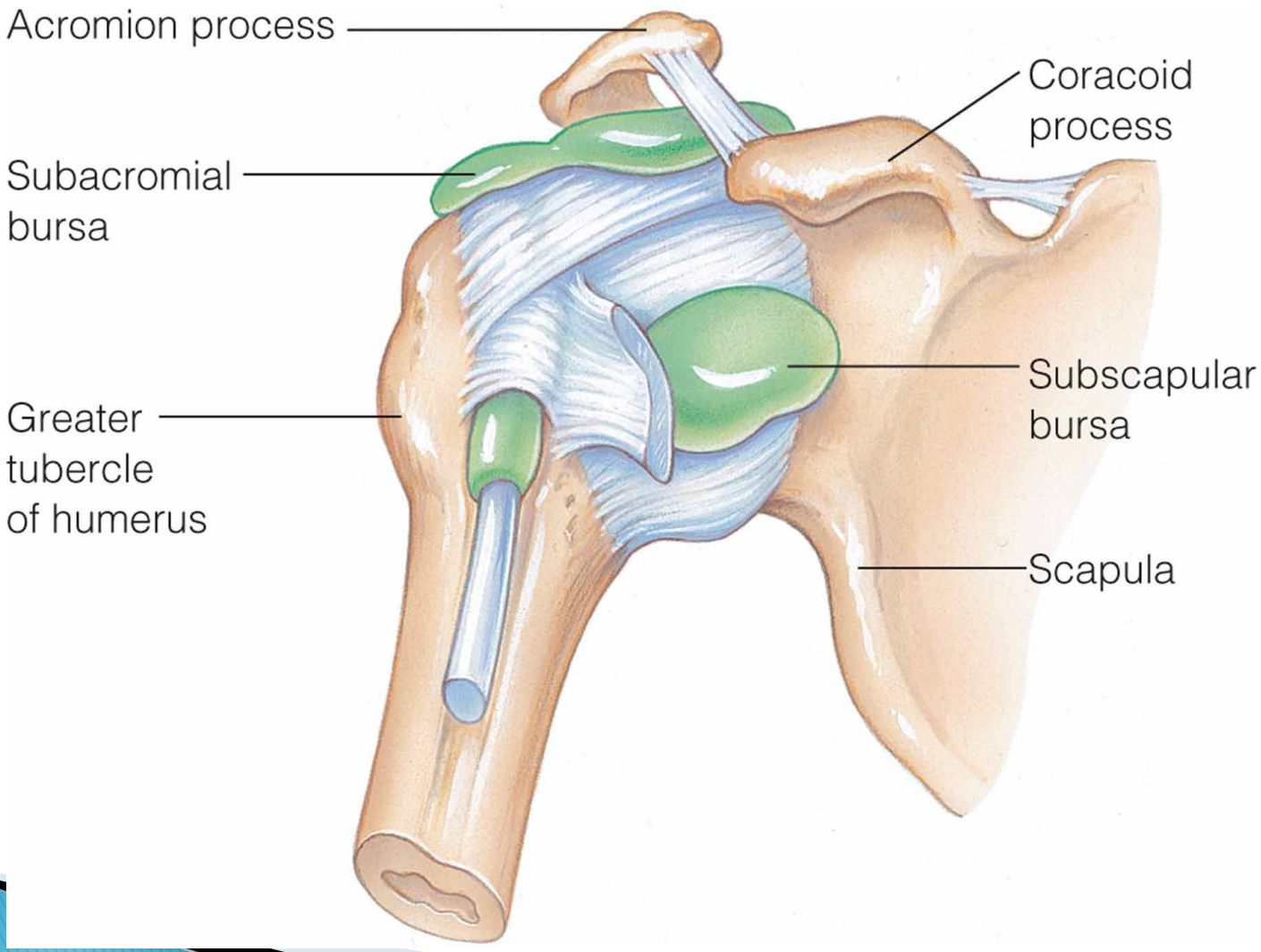

Elbow

- Hinge Joint That Allows Articulation of the Humerus, the Radius, and the Ulna

Elbow joint. Lateral view of the right elbow.

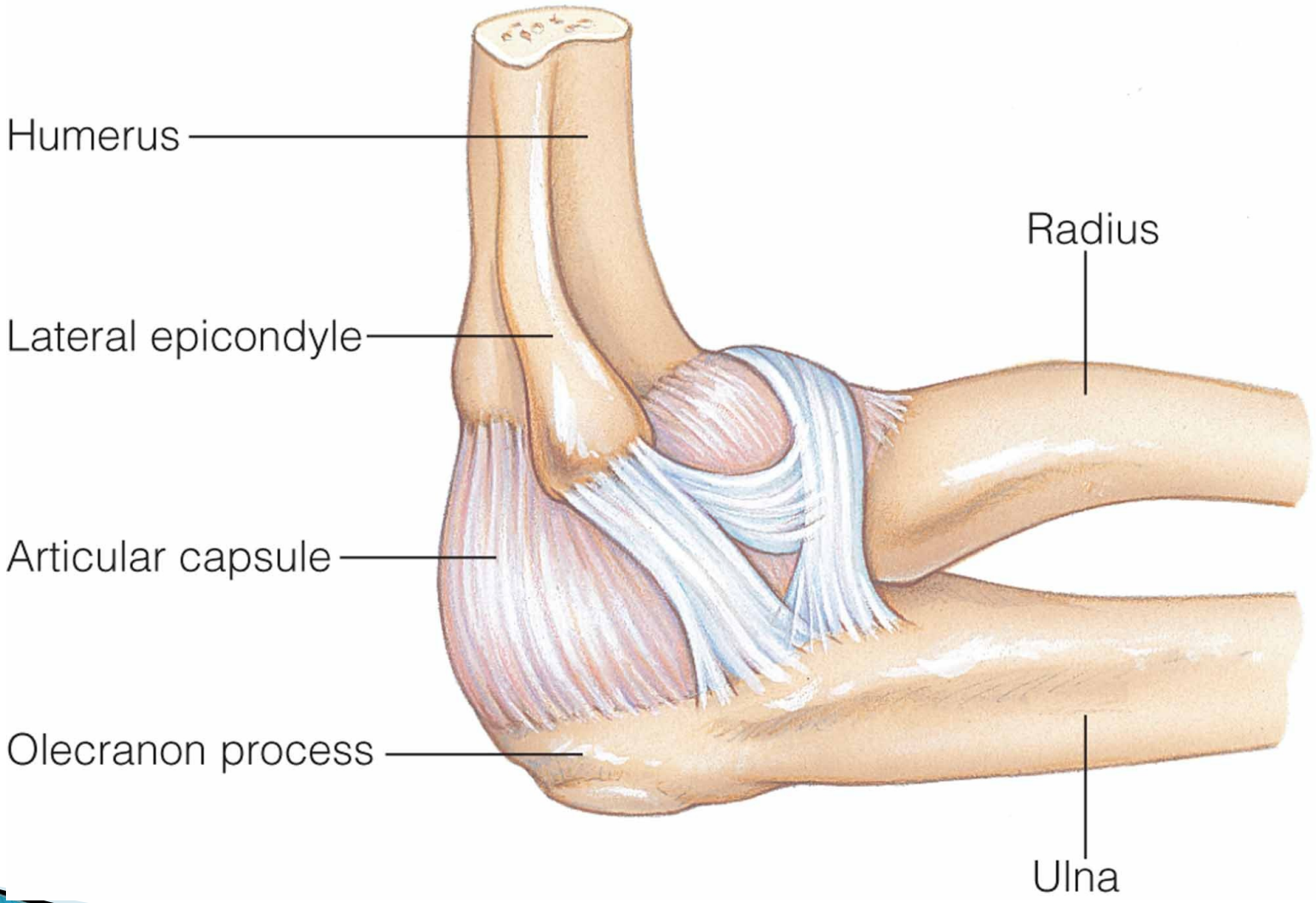

Wrist

- Two Rows of Carpal Bones

Bones of the wrist, hand, and phalanges.

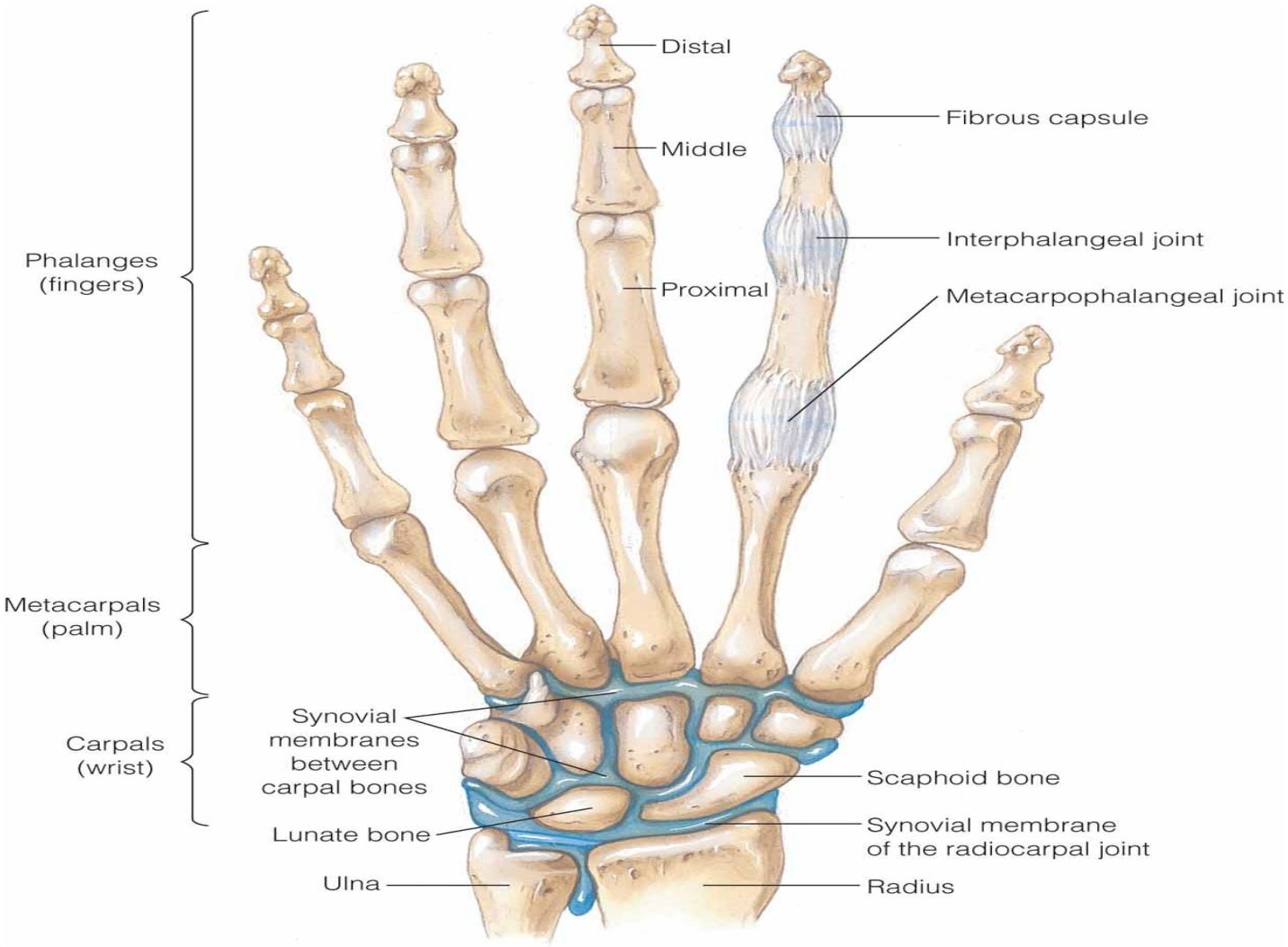

Hand

- Metacarpophalangeal and Interphalangeal Joints

Bones of the wrist, hand, and phalanges.

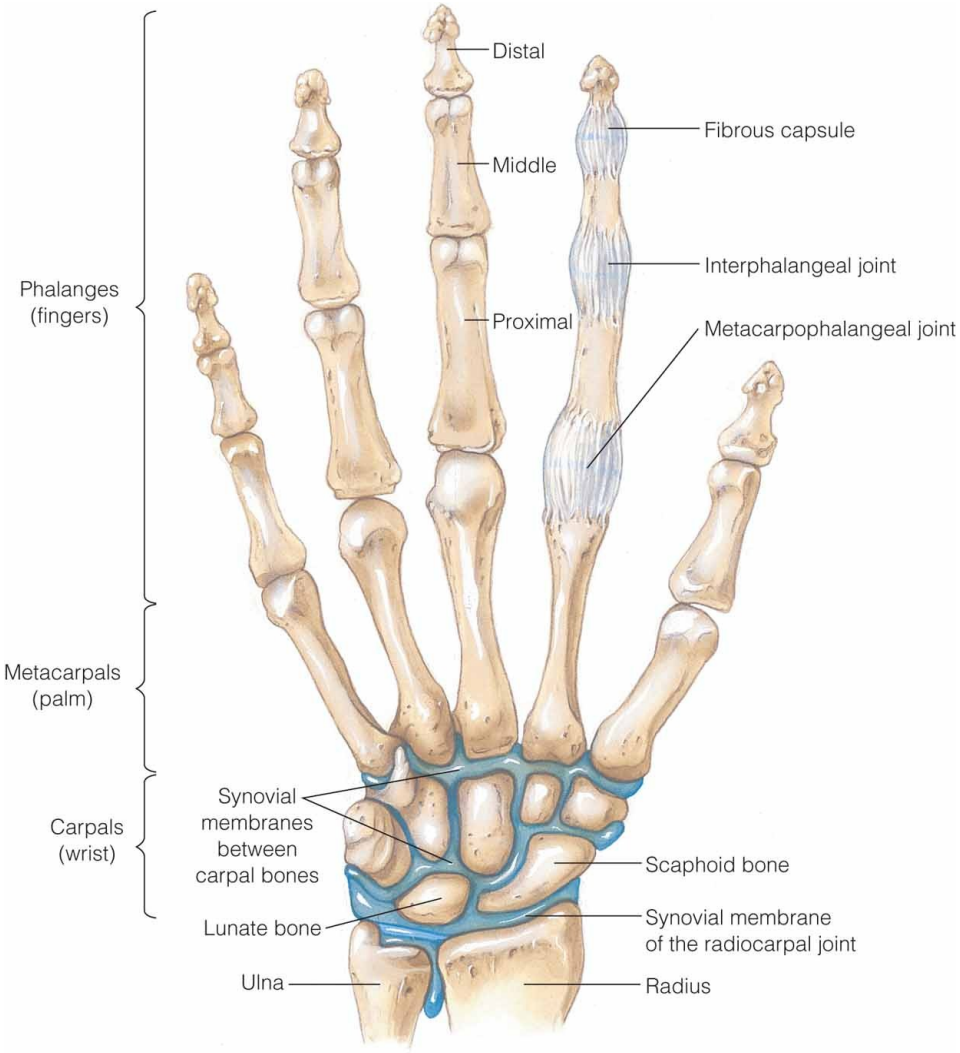

Hip Joint

- Ball-and-Socket Joint Composed of the Head of the Femur as It Fits Into the Acetabulum

Hip joint. A. Cross section. B. Anterior view.

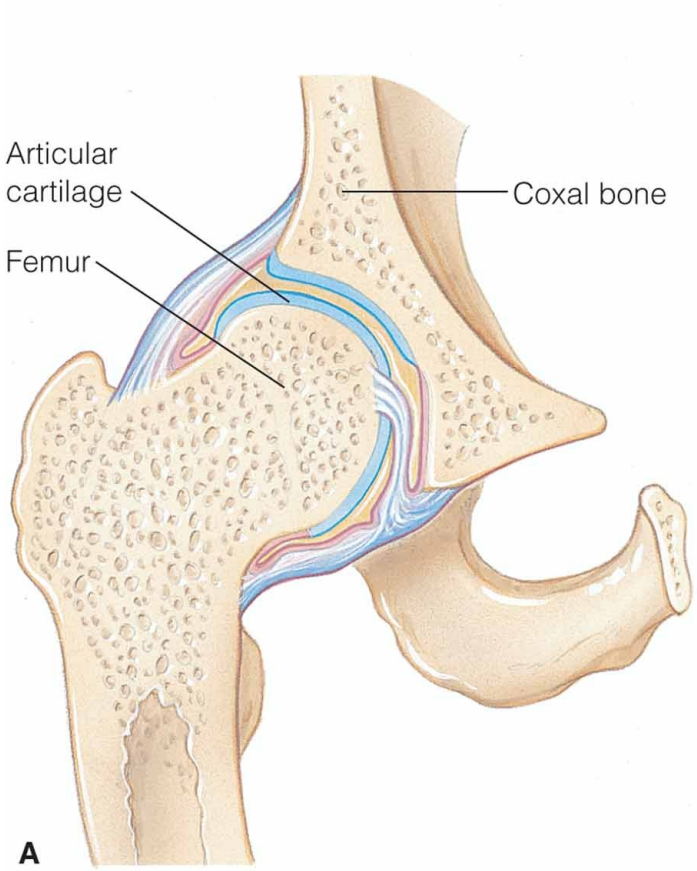

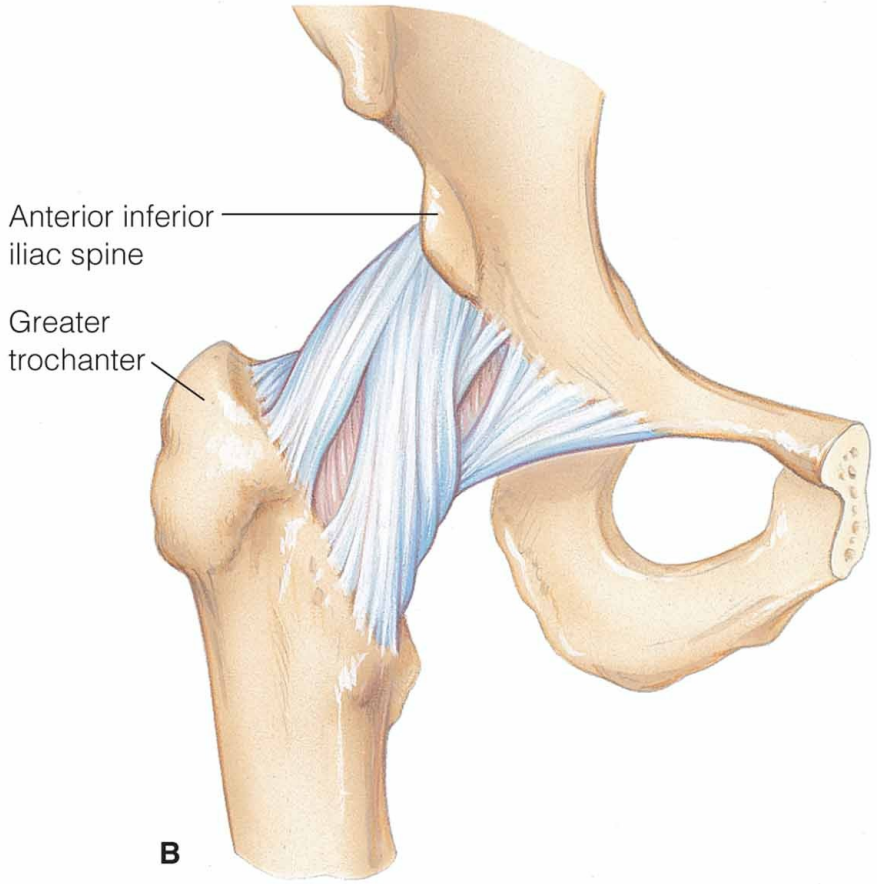

Knee Joint

- Patella
- Femur
- Tibia

Knee joint. A. Sagittal section through the right knee.

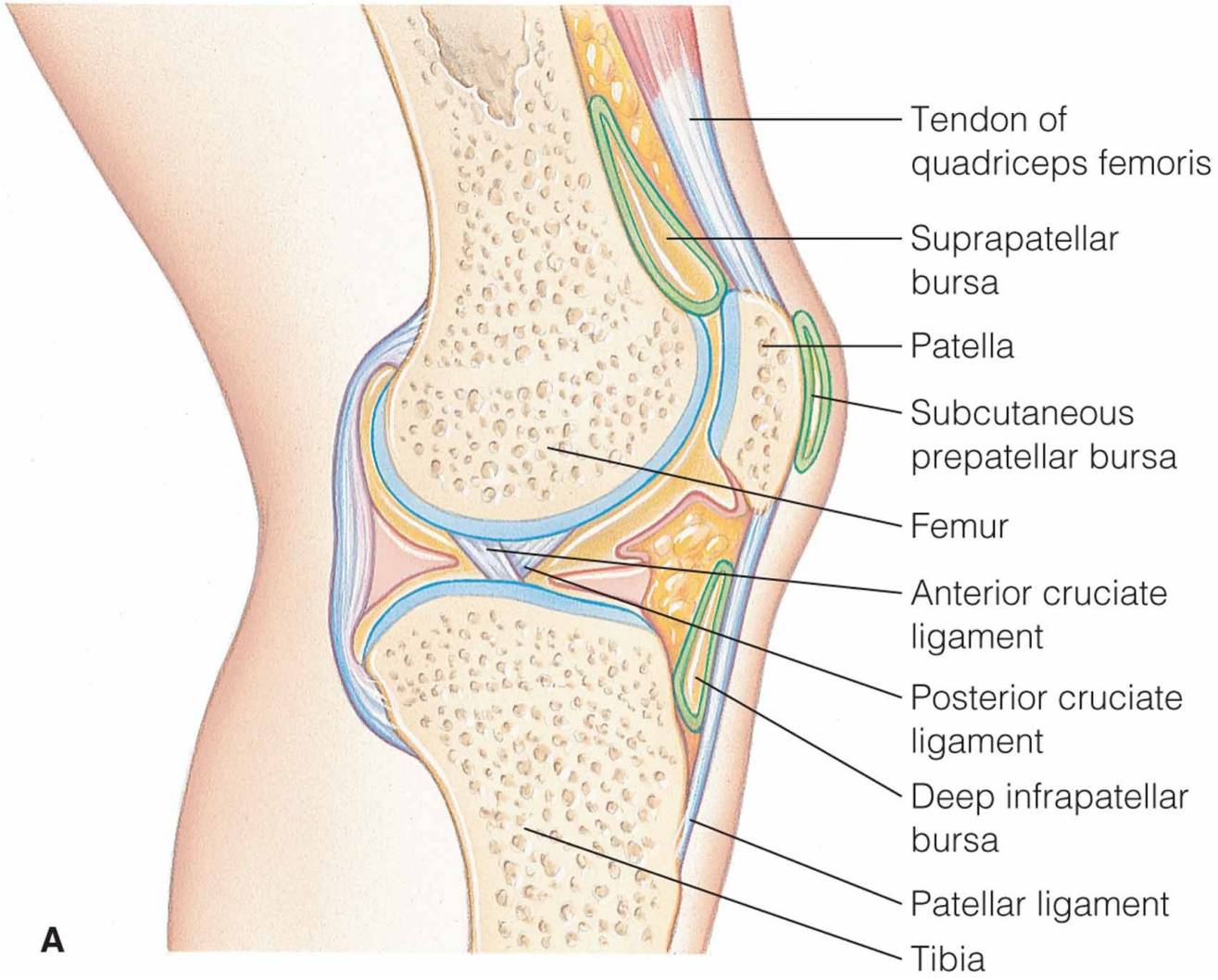

(continued) Knee joint. B. Anterior view.

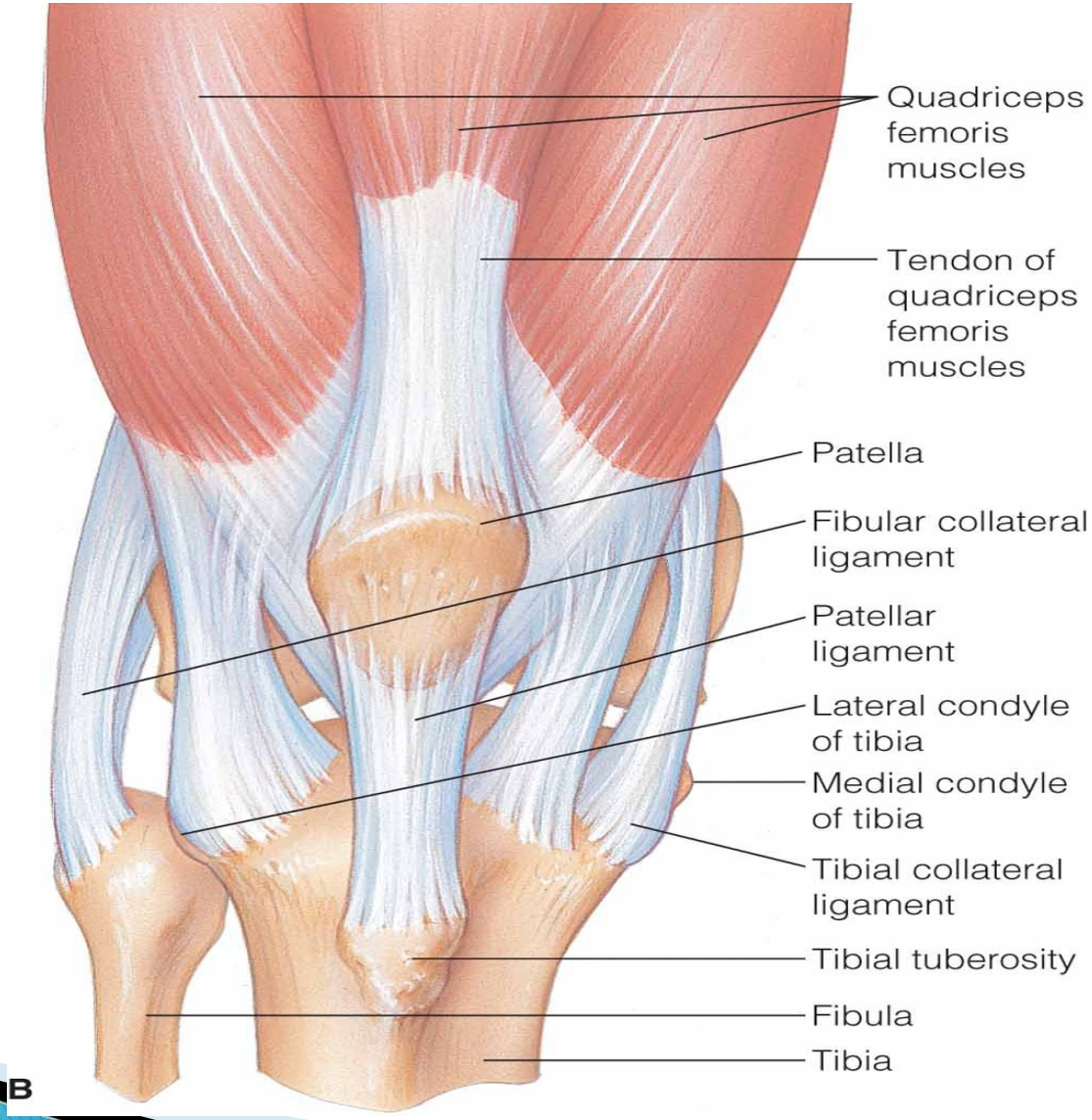

Ankle Joint

- Tibia
- Fibula
- Talus

Medial view of joints of right ankle and foot.

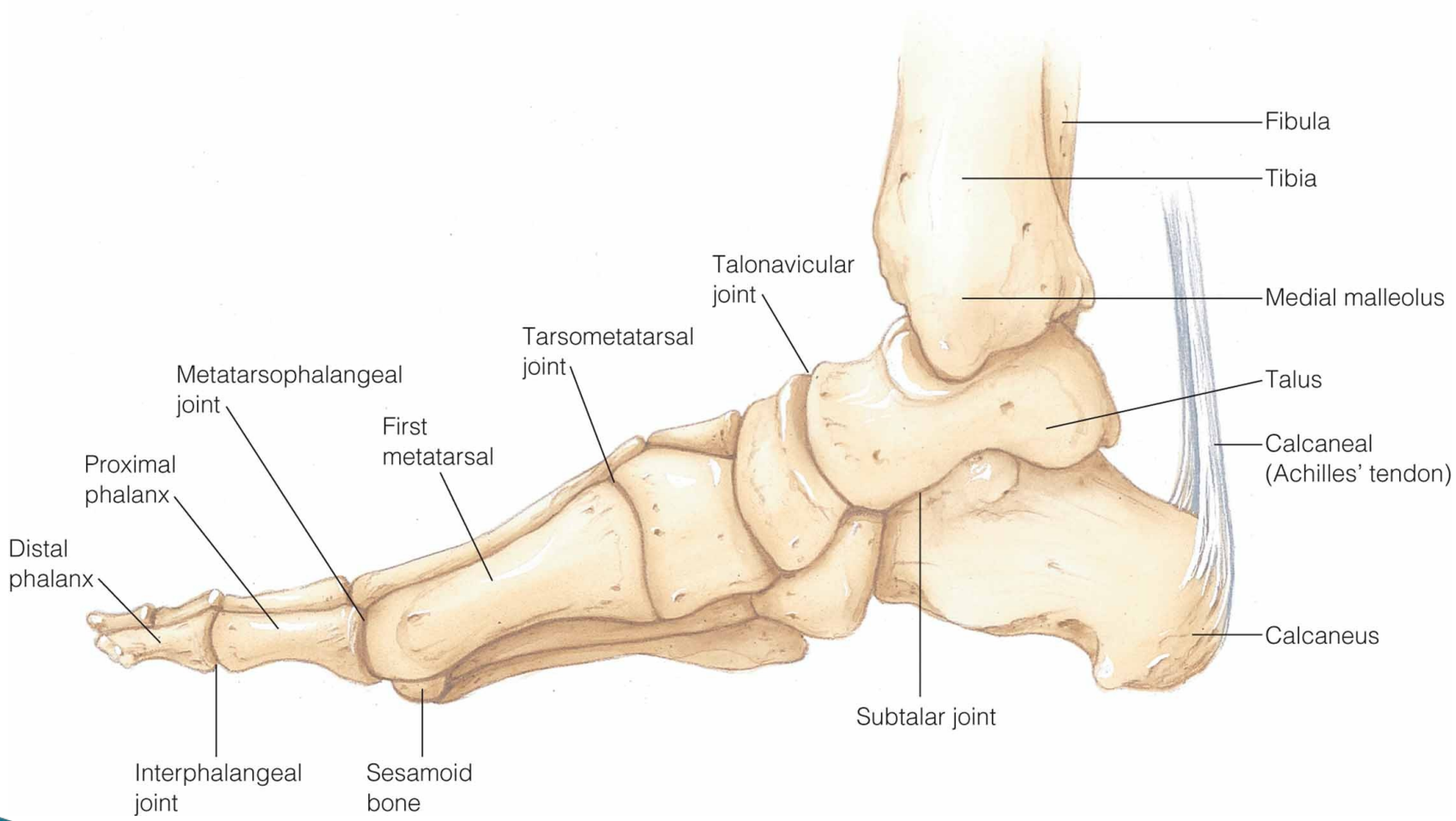

Spine

- 7 cervical vertebrae
- 12 thoracic vertebrae
- 5 lumbar vertebrae
- Sacrum

The spine

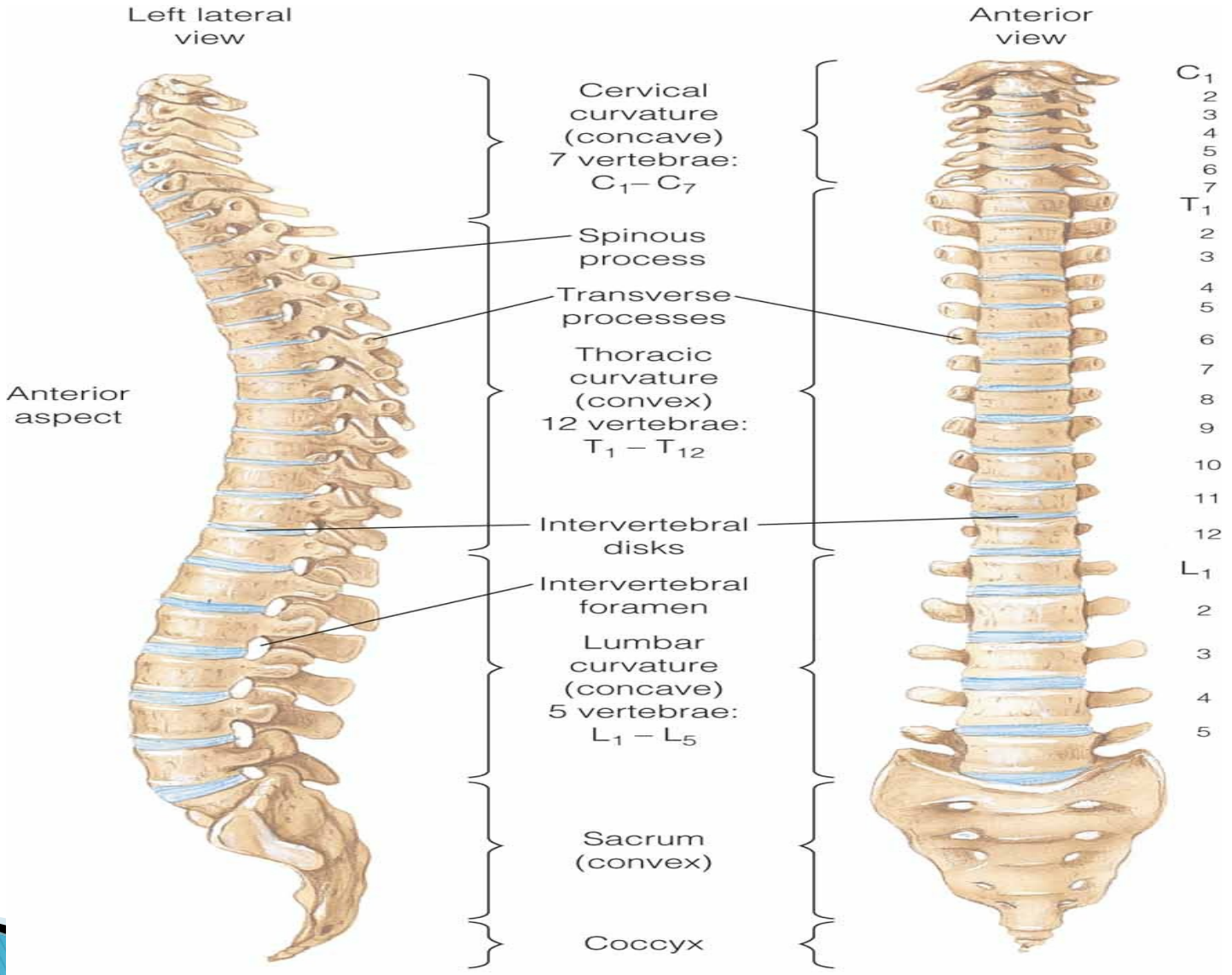
Left lateral view
Anterior view
Anterior aspect
Cervical curvature (concave) 7 vertebrae: C1 – C7
Spinous process
Transverse processes
Thoracic curvature (convex) 12 vertebrae: T1 – T12
Intervertebral disks
Intervertebral foramen
Lumbar curvature (concave) 5 vertebrae: L1 – L5
Sacrum (convex)
Coccyx
C1
2
3
4
5
6
7
T1
2
3
4
5
6
7
8
9
10
11
12
L1
2
3
4
5

Joint Movements

- Flexion
- Extension
- Rotation
- Circumduction
- Elevation
- Protrusion
- Retraction
- Abduction

Joint Movements

- Adduction
- Pronation
- Supination
- Inversion
- Eversion
- Gliding

Table Joint Movement

Table 23.2 Joint Movement

TYPE OF MOVEMENT	
	**Gliding** movements are the simplest type of joint movements. One flat bone surface glides or slips over another similar surface. The bones are merely displaced in relation to one another.
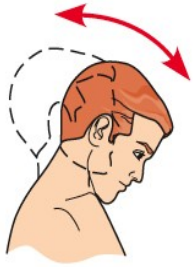	**Flexion** is a bending movement that decreases the angle of the joint and brings the articulating bones closer together. **Extension** increases the angle between the articulating bones. (**Hyperextension** is a bending of a joint beyond 180 degrees.)
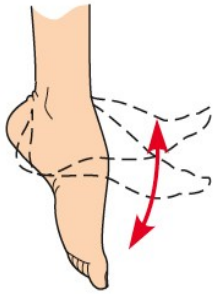	Flexion of the ankle so that the superior aspect of the foot approaches the shin is called **dorsiflexion.** Extension of the ankle (pointing the toes) is called **plantar flexion.**

Table Joint Movement (continued)

Table 23.2 Joint Movement (*continued*)

TYPE OF MOVEMENT	
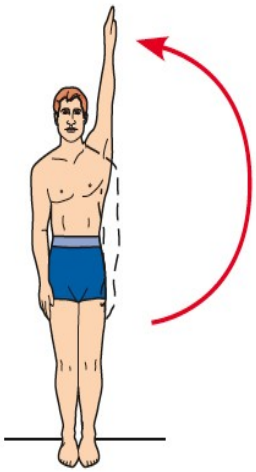	**Abduction** is movement of a limb away from the midline or median plane of the body, along the frontal plane. When the term is used to describe movement of the fingers or toes, it means spreading them apart. **Adduction** is the movement of a limb toward the body midline. Bringing the fingers close together is adduction.
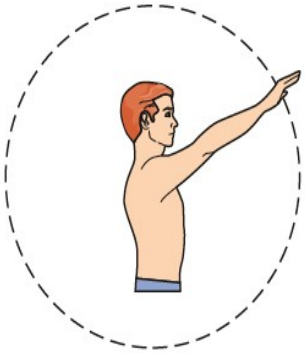	**Circumduction** is the movement in which the limb describes a cone in space: While the distal end of the limb moves in a circle, the joint itself moves only slightly in the joint cavity.

Table 23.2 Joint Movement (*continued*)

TYPE OF MOVEMENT

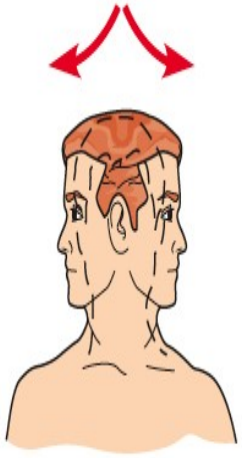

Rotation is the turning movement of a bone around its own long axis. Rotation may occur toward the body midline or away from it.

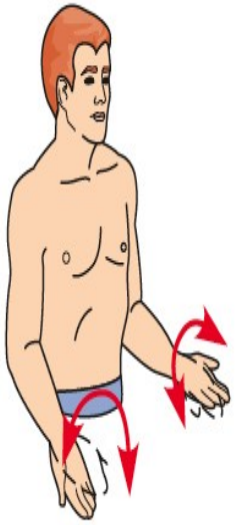

The terms **supination** and **pronation** refer only to the movements of the radius around the ulna. Movement of the forearm so that the palm faces anteriorly or superiorly is called *supination*. In *pronation*, the palm moves to face posteriorly or inferiorly.

Table 23.2 Joint Movement (*continued*)

TYPE OF MOVEMENT



The terms **inversion** and **eversion** refer to movements of the foot. In *inversion*, the sole of the foot is turned medially. In *eversion*, the sole faces laterally.

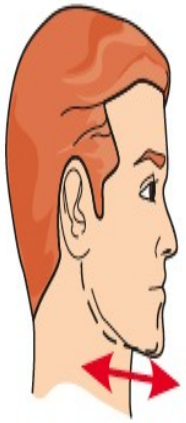

Protraction is a nonangular anterior movement in a transverse plane.

Retraction is a nonangular posterior movement in a transverse plane.

Table 23.2 Joint Movement (*continued*)

TYPE OF MOVEMENT	
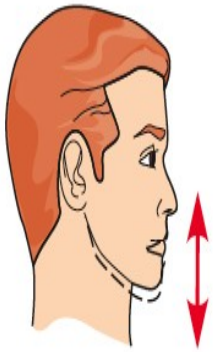	**Elevation** is a lifting or moving superiorly along a frontal plane. When the elevated part is moved downward to its original position, the movement is called **depression.** Shrugging the shoulders and chewing are examples of alternating elevation and depression.
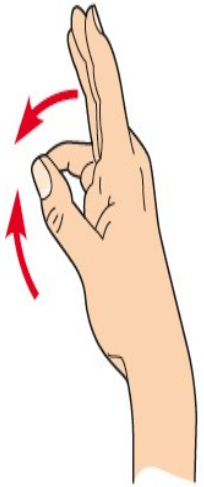	**Opposition** *of the thumb* is only allowed at the saddle joint between metacarpal 1 and the carpals. It is the movement of touching the thumb to the tips of the other fingers of the same hand.

Focused Interview

- Specific questions
  - Illness, infection, or injury
  - Symptoms
  - Pain
  - Behaviors

Physical Assessment of the Musculoskeletal System

- Techniques
  - Inspection
  - Palpation

Areas of the Musculoskeletal System Assessment

- Inspection and palpation of the temporomandibular joints
- Palpation of the jaw muscles
- Testing the range of motion of the temporomandibular joints
- Inspection and palpation of the shoulders
- Testing the range of motion of the shoulders

Areas of the Musculoskeletal System Assessment

- Testing for muscle strength of the shoulders
- Inspection and palpation of the elbows
- Testing the range of motion of the elbows
- Testing for muscle strength of the elbows
- Inspection and palpation of the wrists and hands

Areas of the Musculoskeletal System Assessment

- Testing the range of motion of the wrists and hands, including Phalen's test and Tinel's sign
- Testing for muscle strength of the wrists and hands
- Inspection and palpation of the hips
- Testing the range of motion of the hips
- Testing for muscle strength of the hips

Areas of the Musculoskeletal System Assessment

- Inspection and palpation of the knees, including the bulge sign and ballottement
- Testing the range of motion of the knees
- Testing for muscle strength of the knees
- Inspection and palpation of the ankles and feet
- Testing the range of motion of the ankles and feet

Areas of the Musculoskeletal System Assessment

- Testing for muscle strength of the ankles and feet
- Inspection and palpation of the spine
- Testing the range of motion of the spine

Palpating the temporomandibular joints.



Flexion and extension of the shoulders.

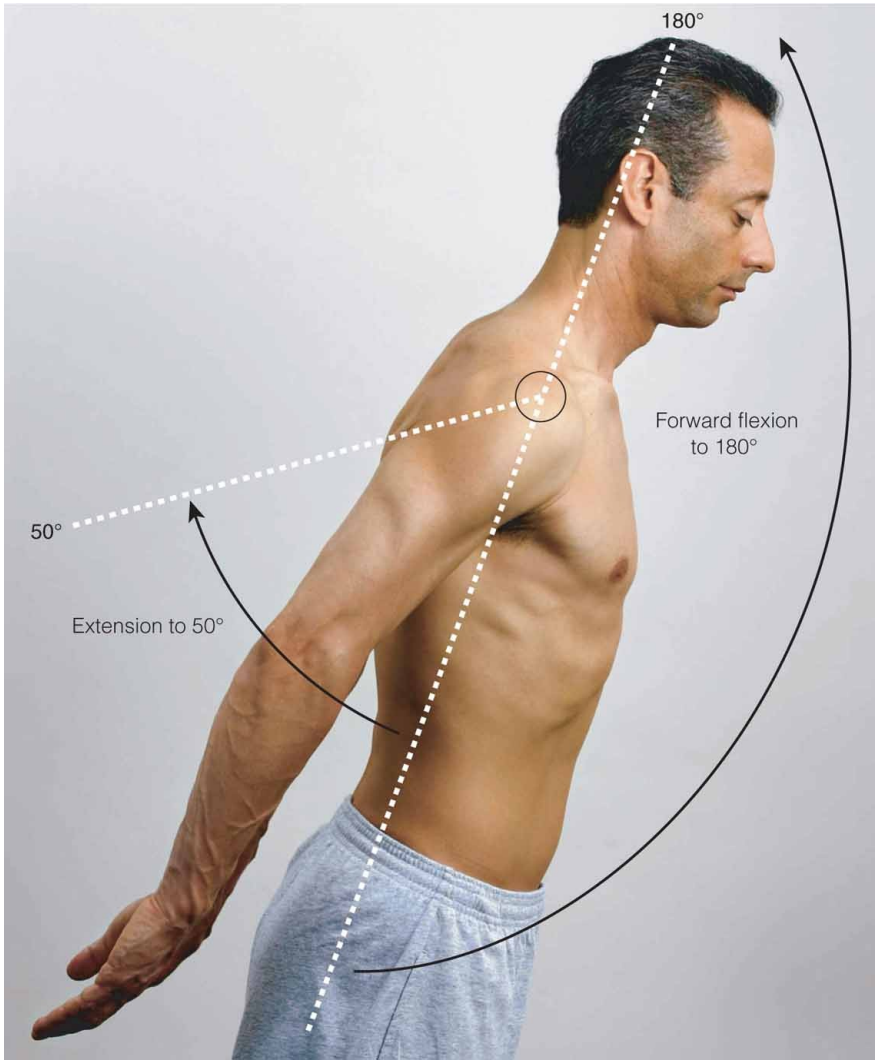

Internal rotation of the shoulders.

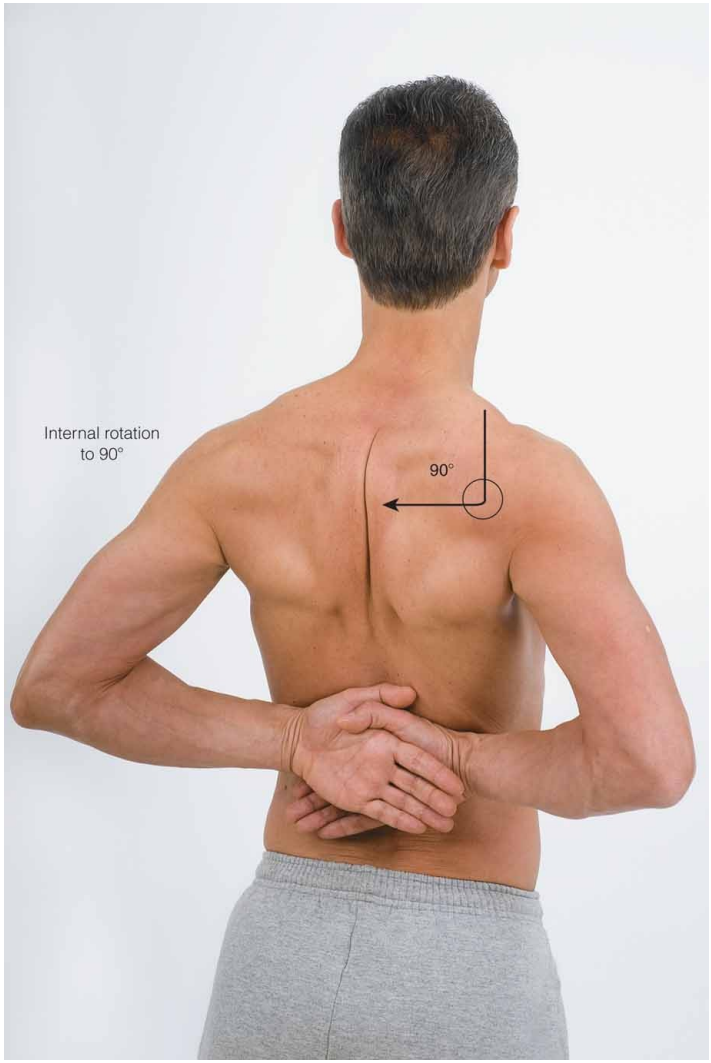

External rotation of the shoulders.



Abduction and adduction of the shoulder.

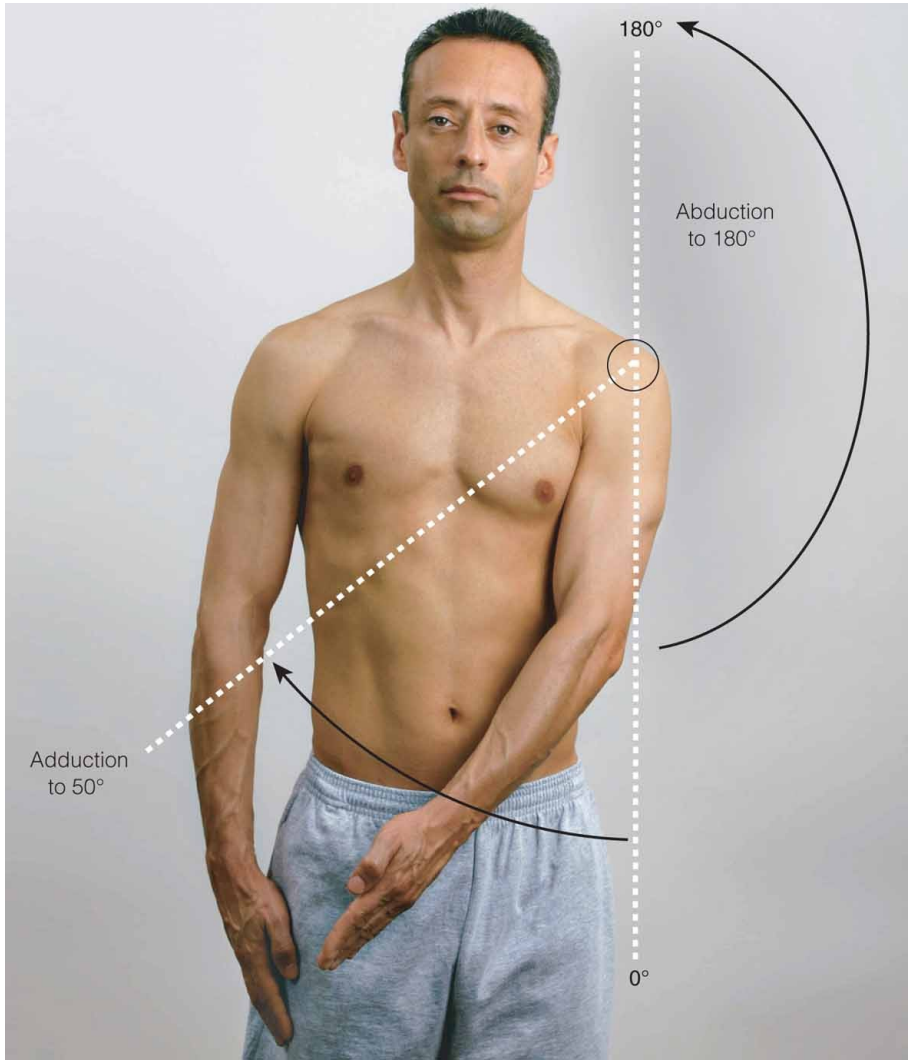

Table 23.4 Rating Muscle Strength

RATING	DESCRIPTION OF FUNCTION	CLASSIFICATION
5	Full range of motion against gravity with full resistance	Normal
4	Full range of motion against gravity with moderate resistance	Good
3	Full range of motion with gravity	Fair
2	Full range of motion without gravity (passive motion)	Poor
1	Palpable muscle contraction but no movement	Trace
0	No muscle contraction	Zero

Flexion and extension of the elbow.

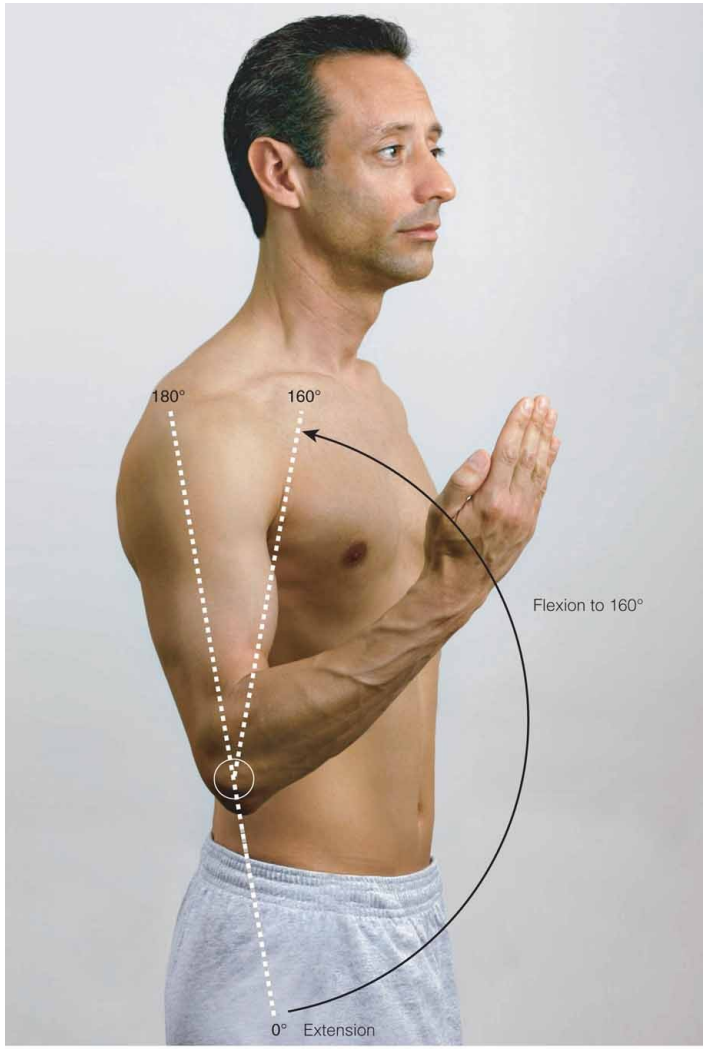

Goniometer measure of joint range of motion.

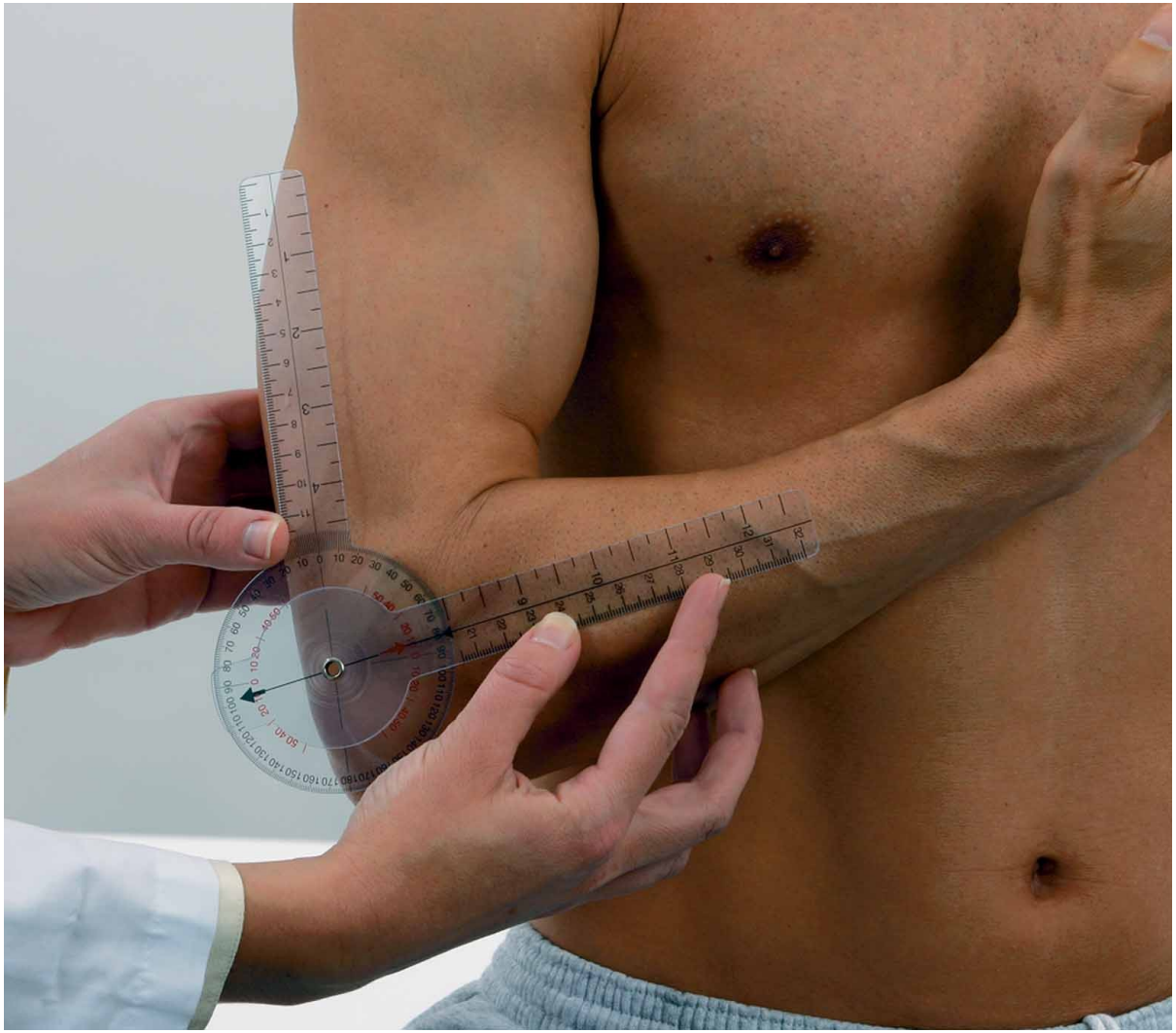

Supination and pronation of the elbow.

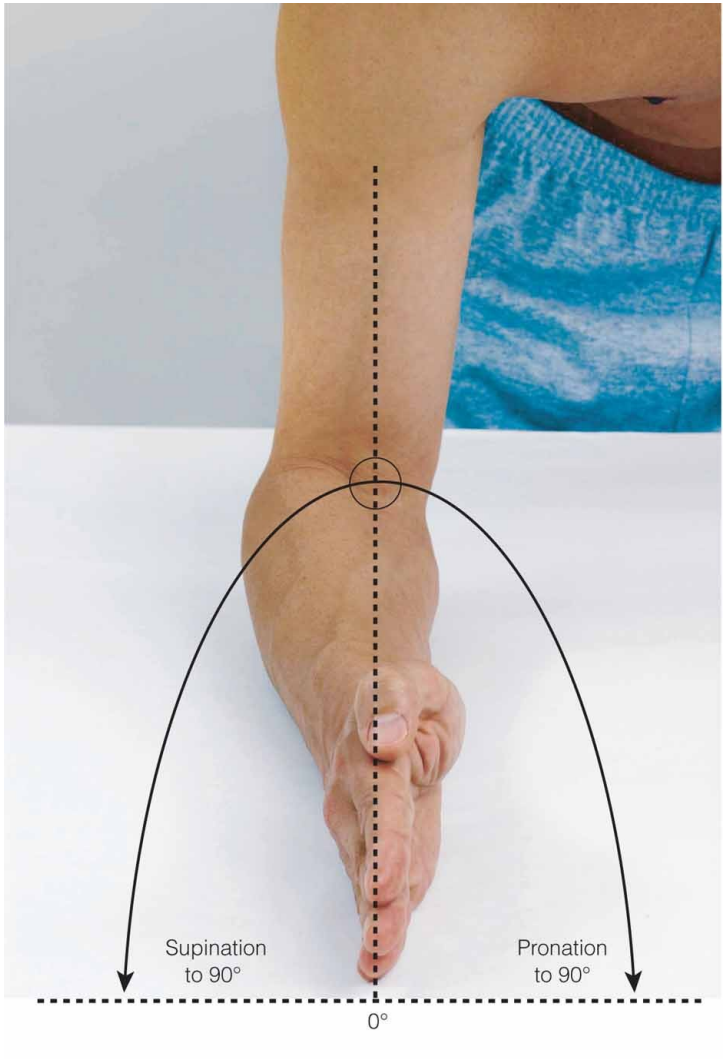

Testing muscle strength using opposing force.



Palpating the wrist



Palpating the hand



Palpating the fingers



Hyperextension and flexion of the wrist

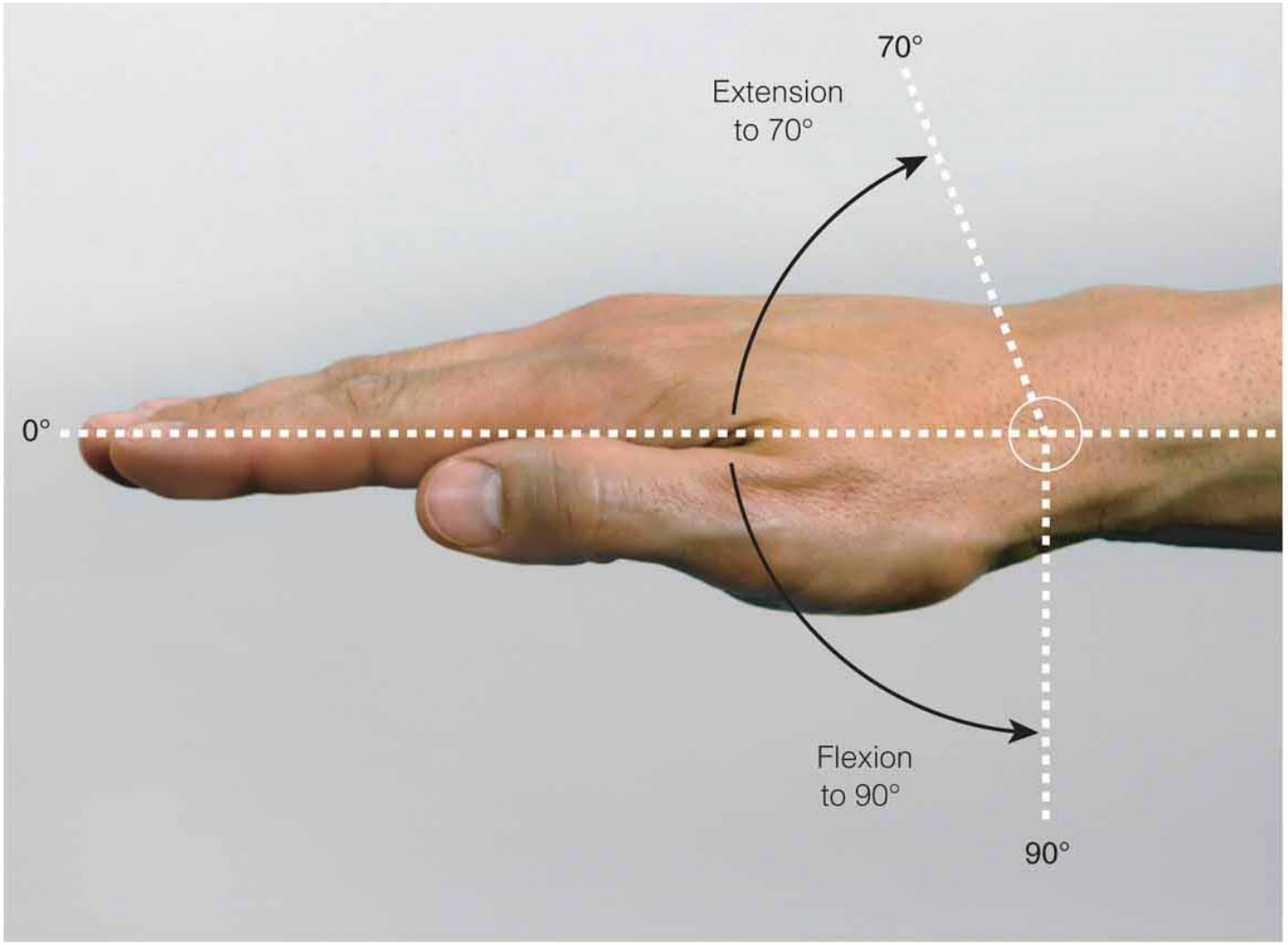

Ulnar and radial deviation of the wrist

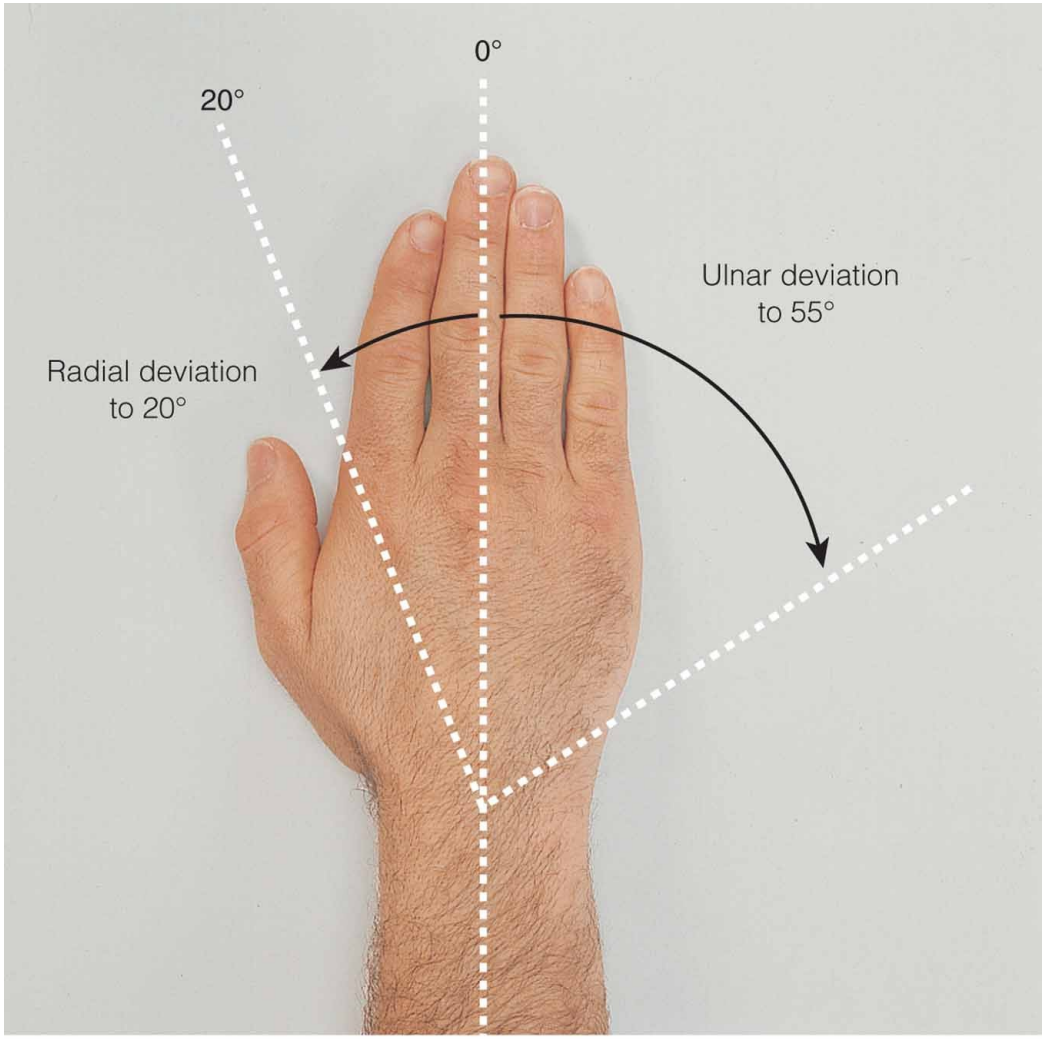

Phalen's test

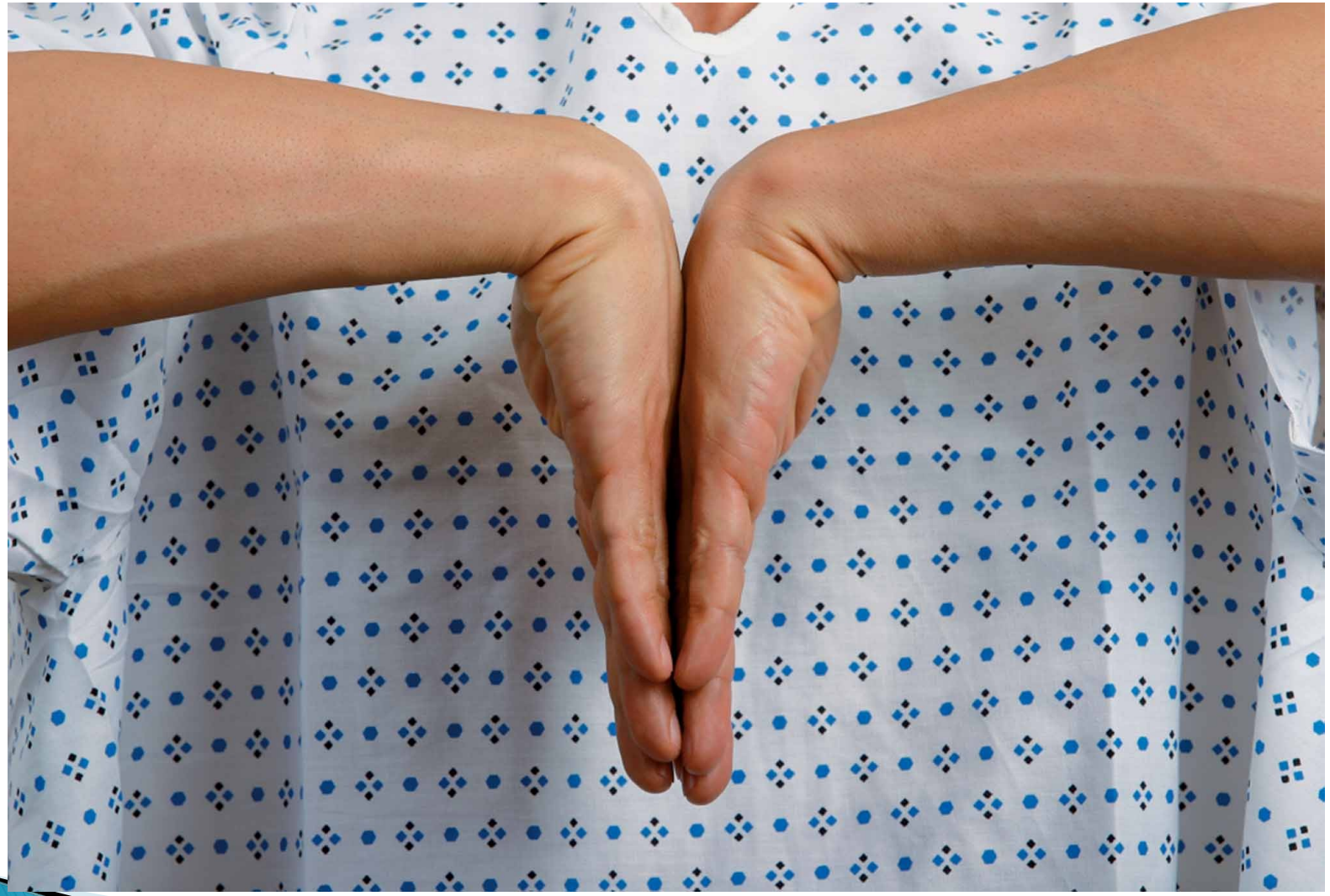

Tinel's sign

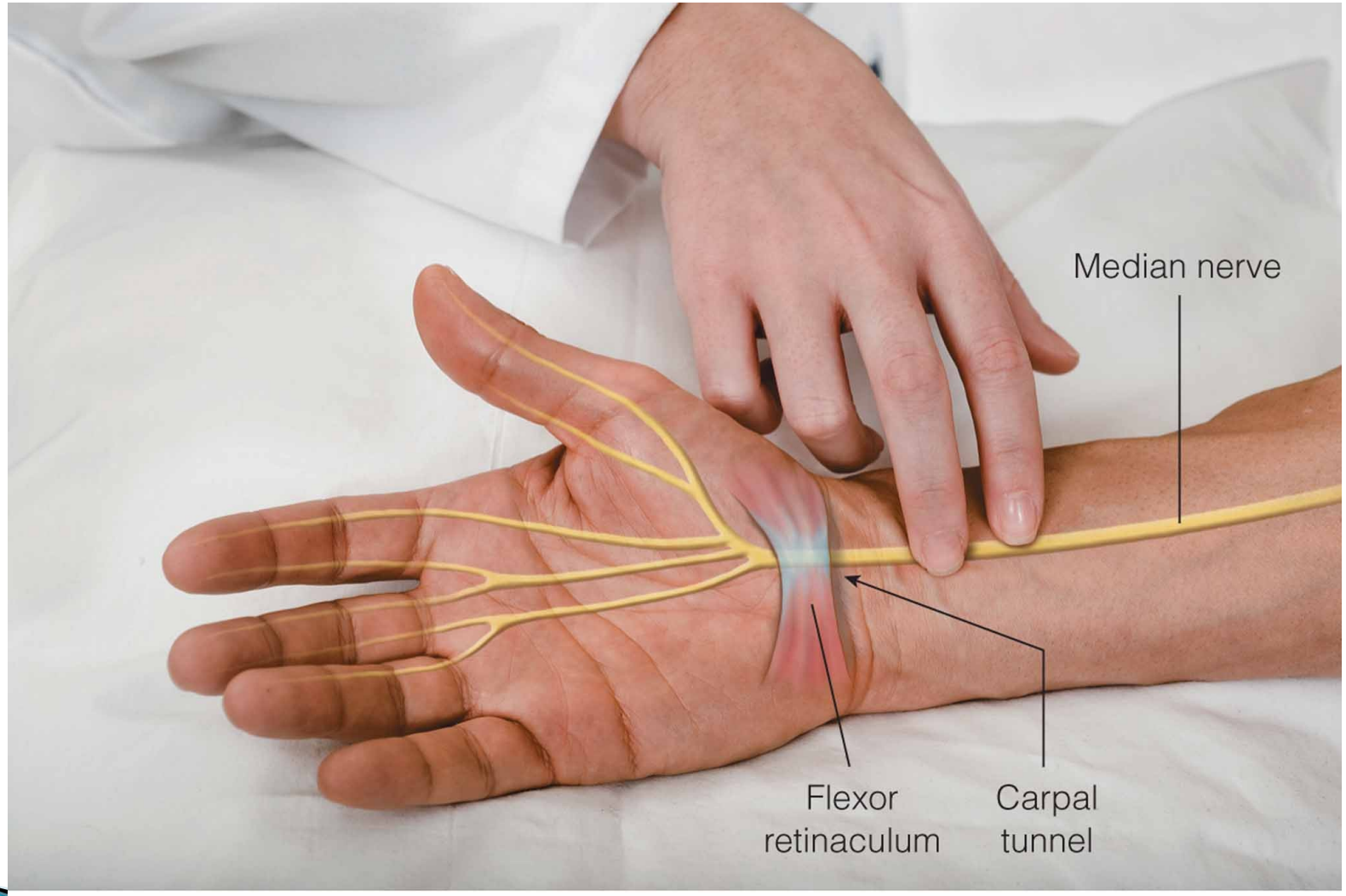

Flexion and extension of the fingers

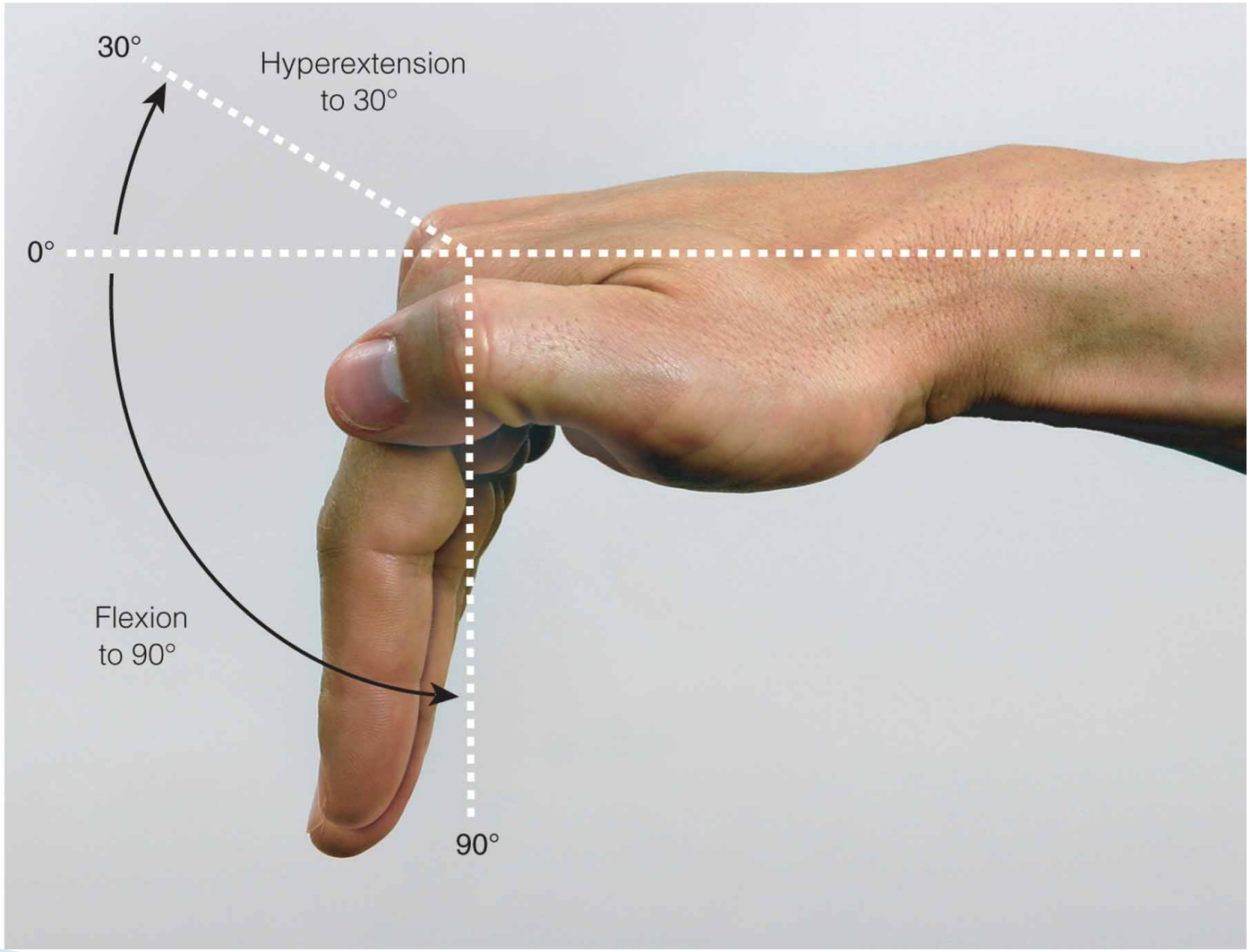

Testing the muscle strength of the wrist



Flexion of the hip with straight knee

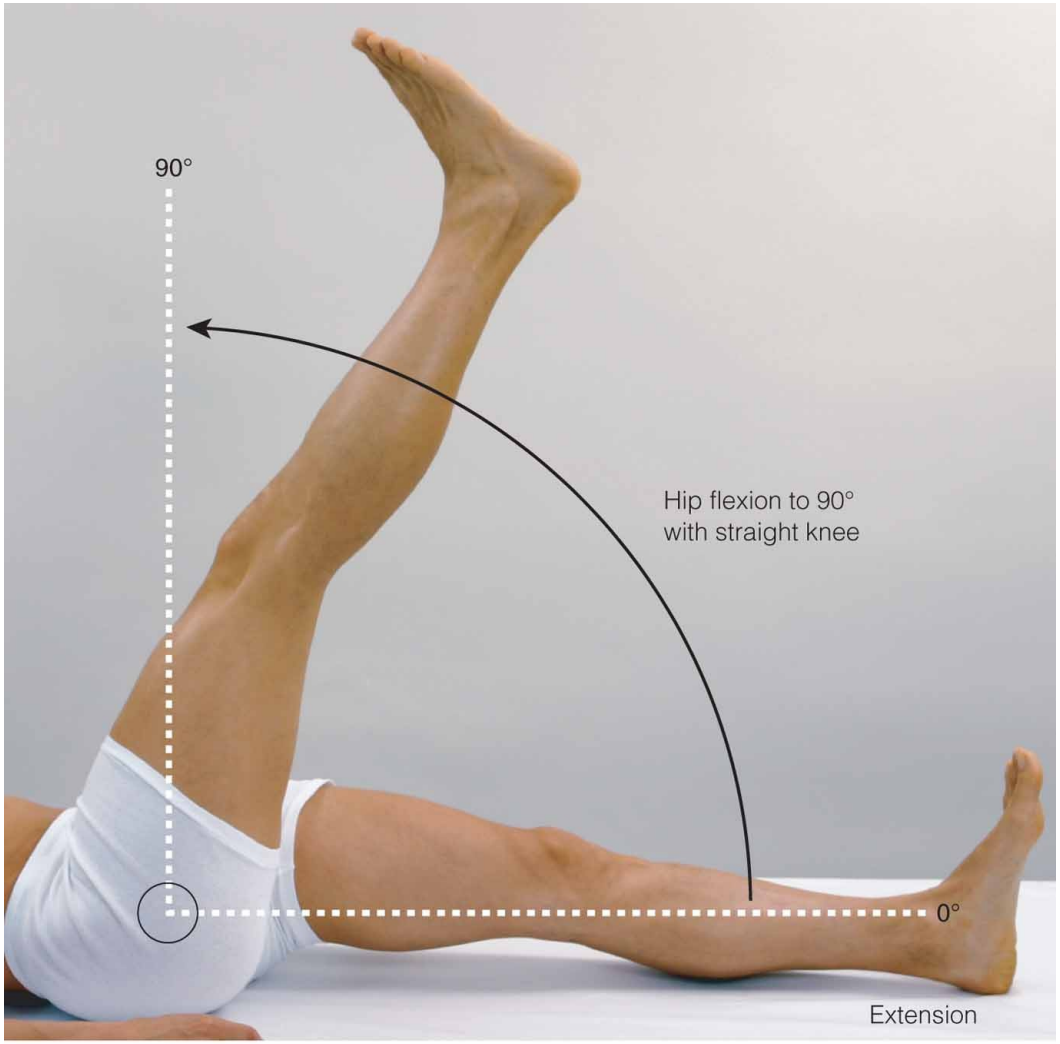

Flexion of the hip with flexed knee

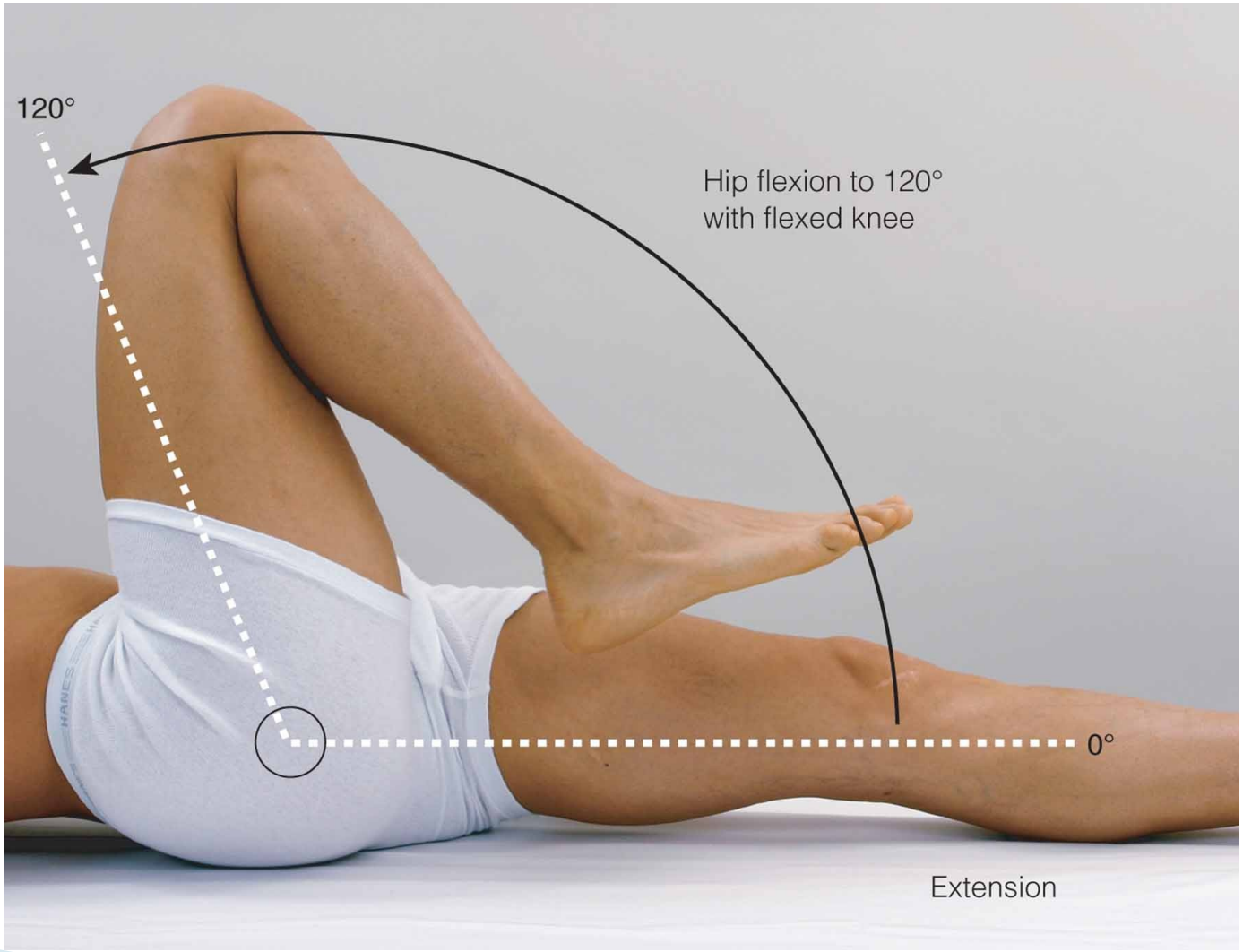

Internal and external hip rotation

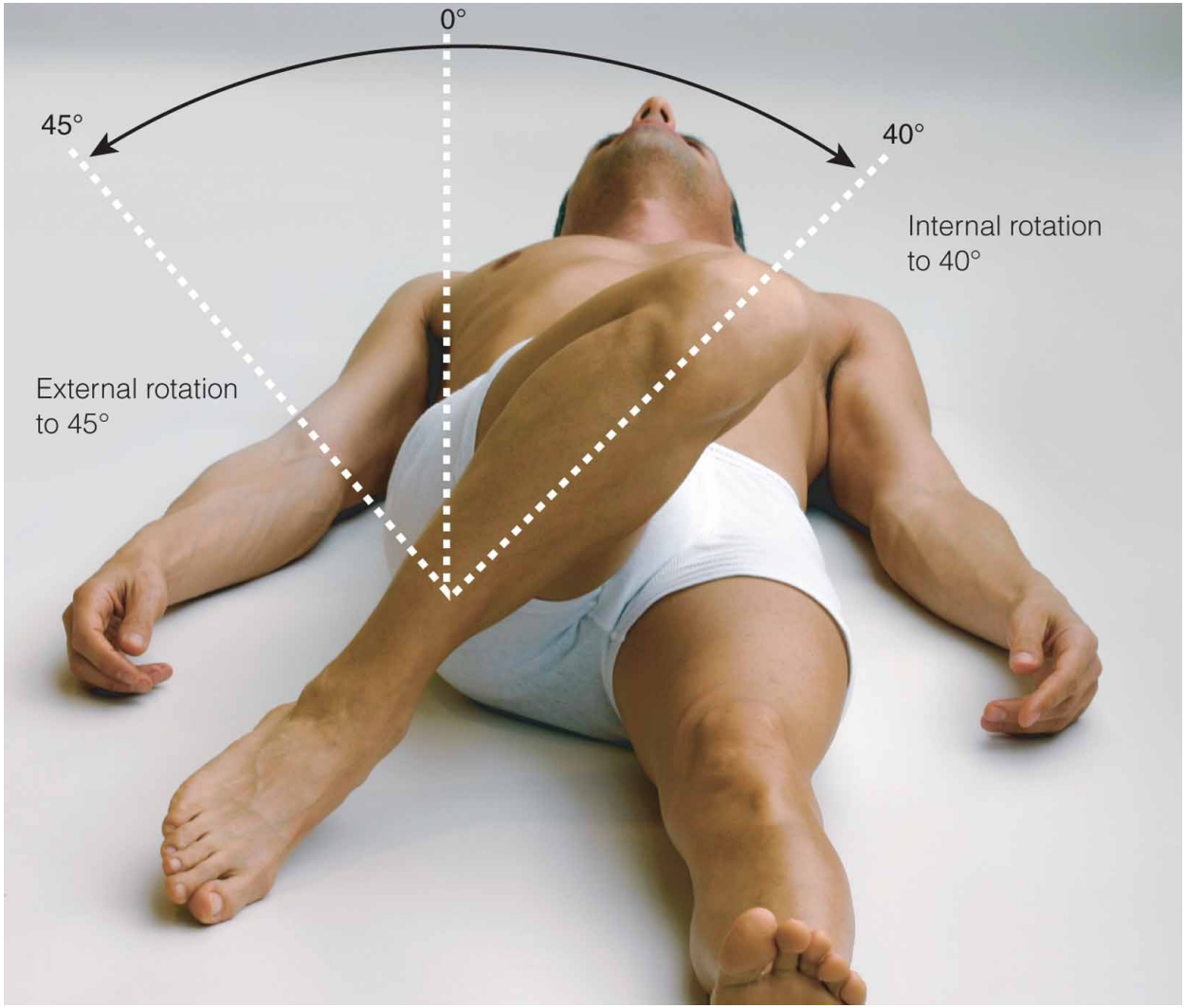

Abduction and adduction of the hip

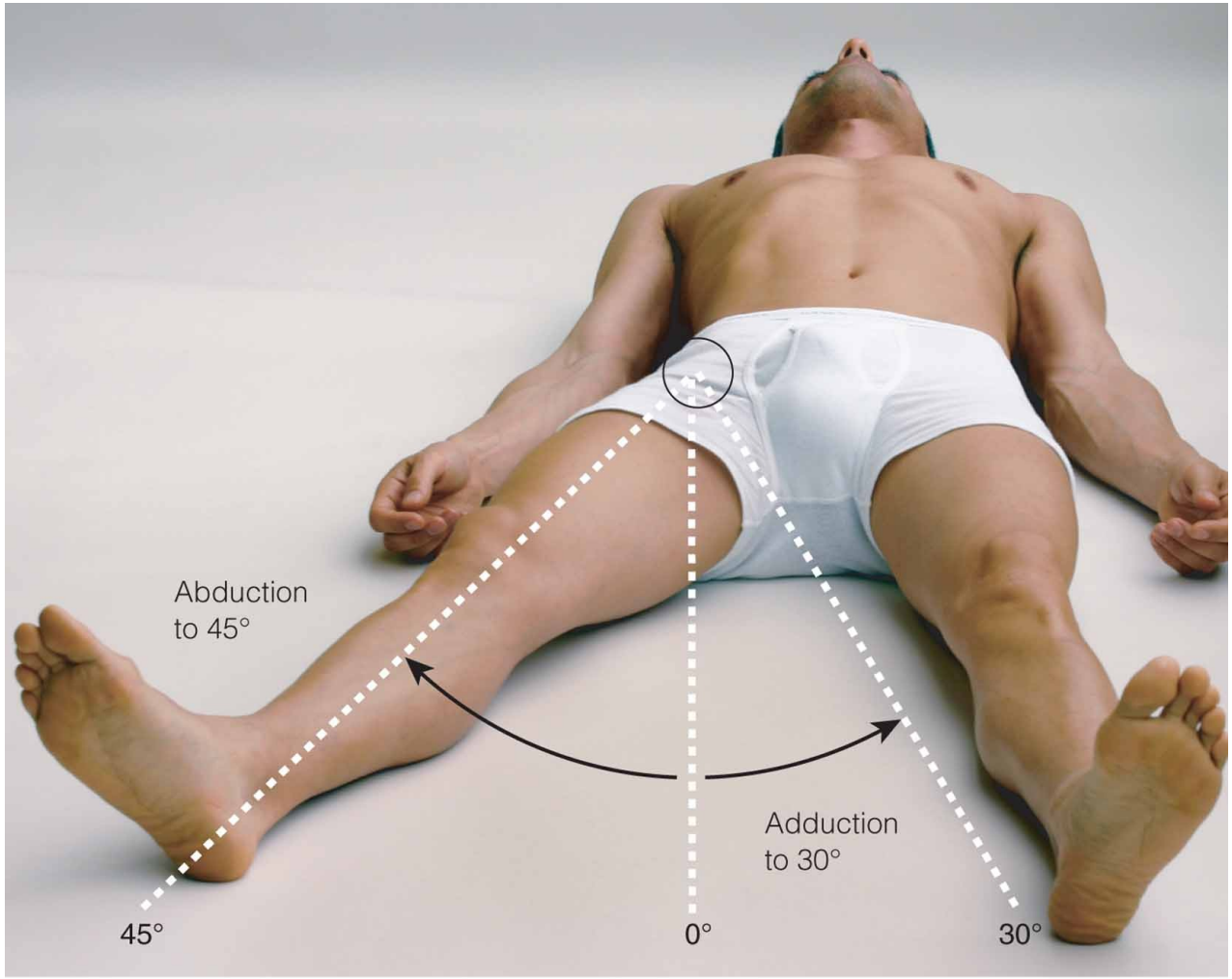

Hyperextension of the hip

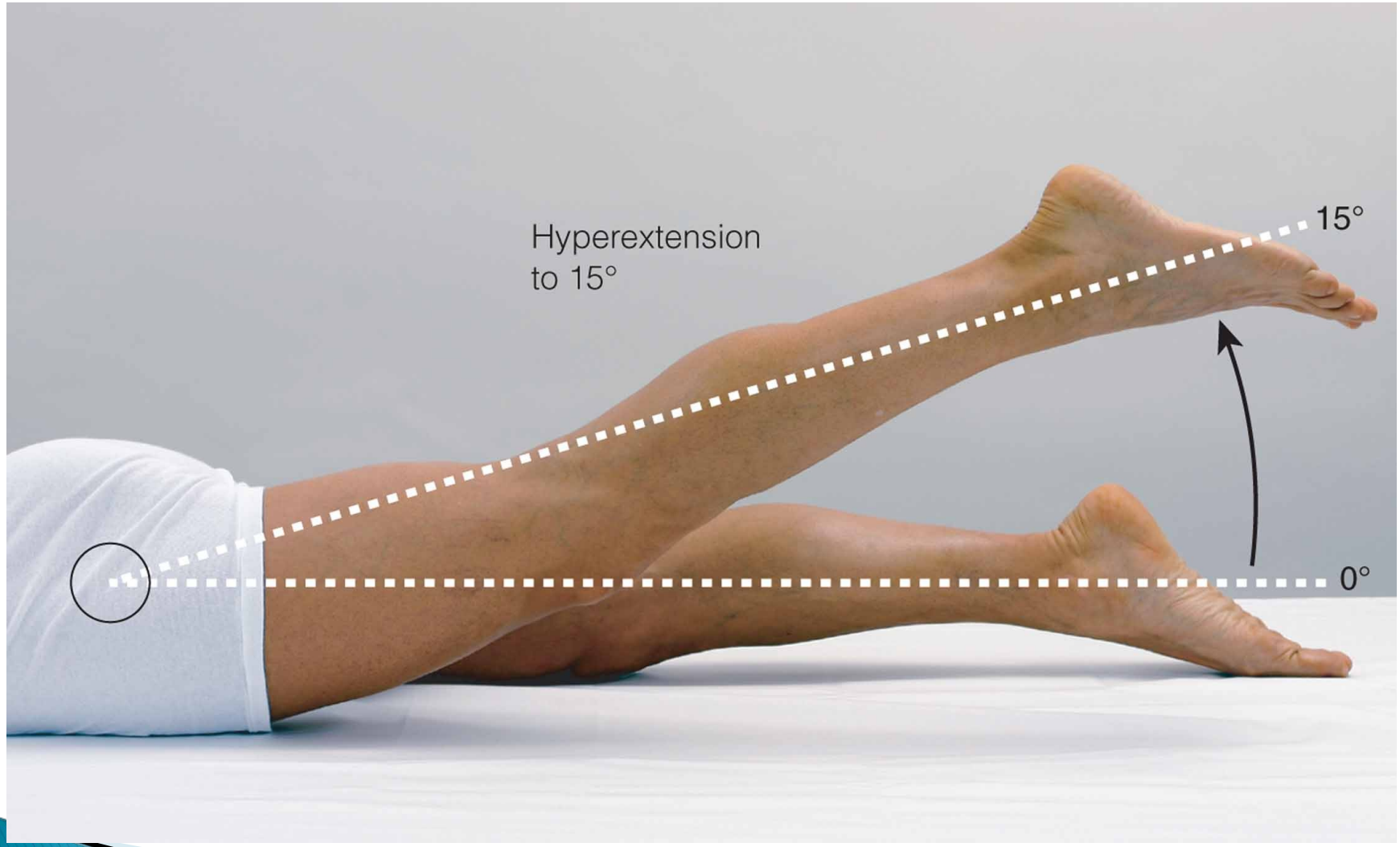

Palpating the knee



Testing for the bulge sign

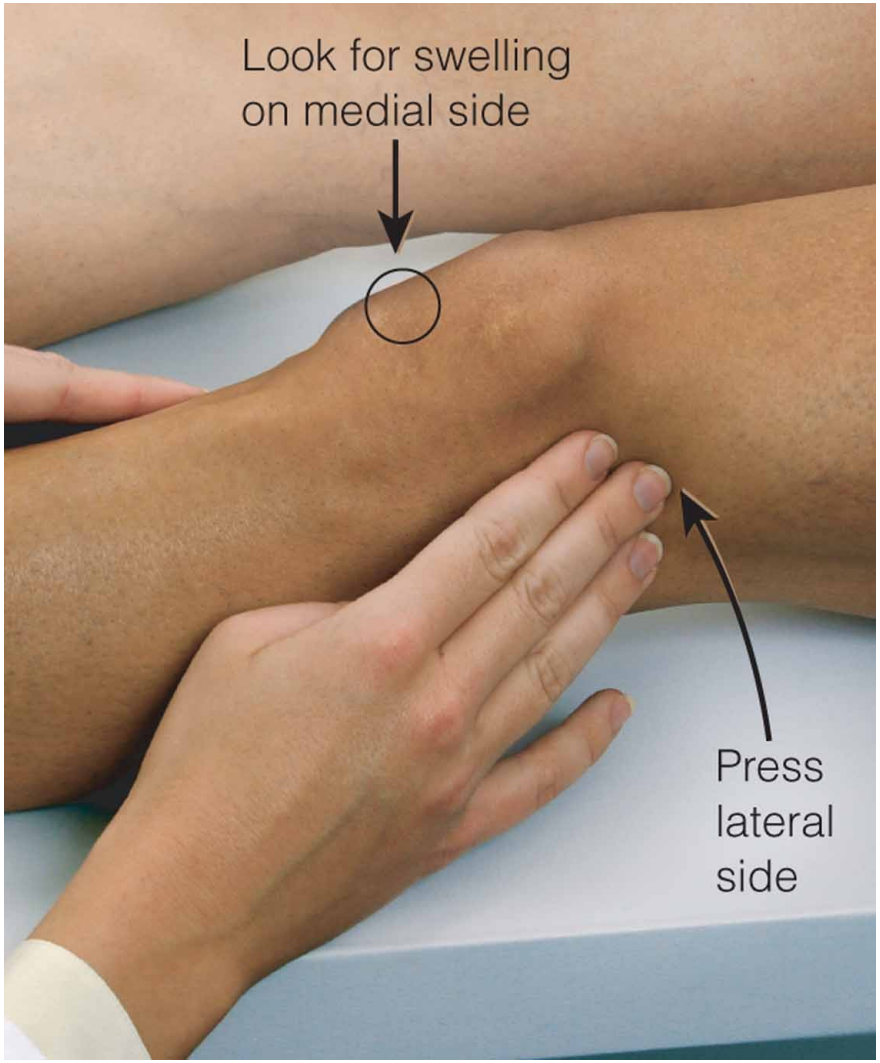

Testing for ballottement

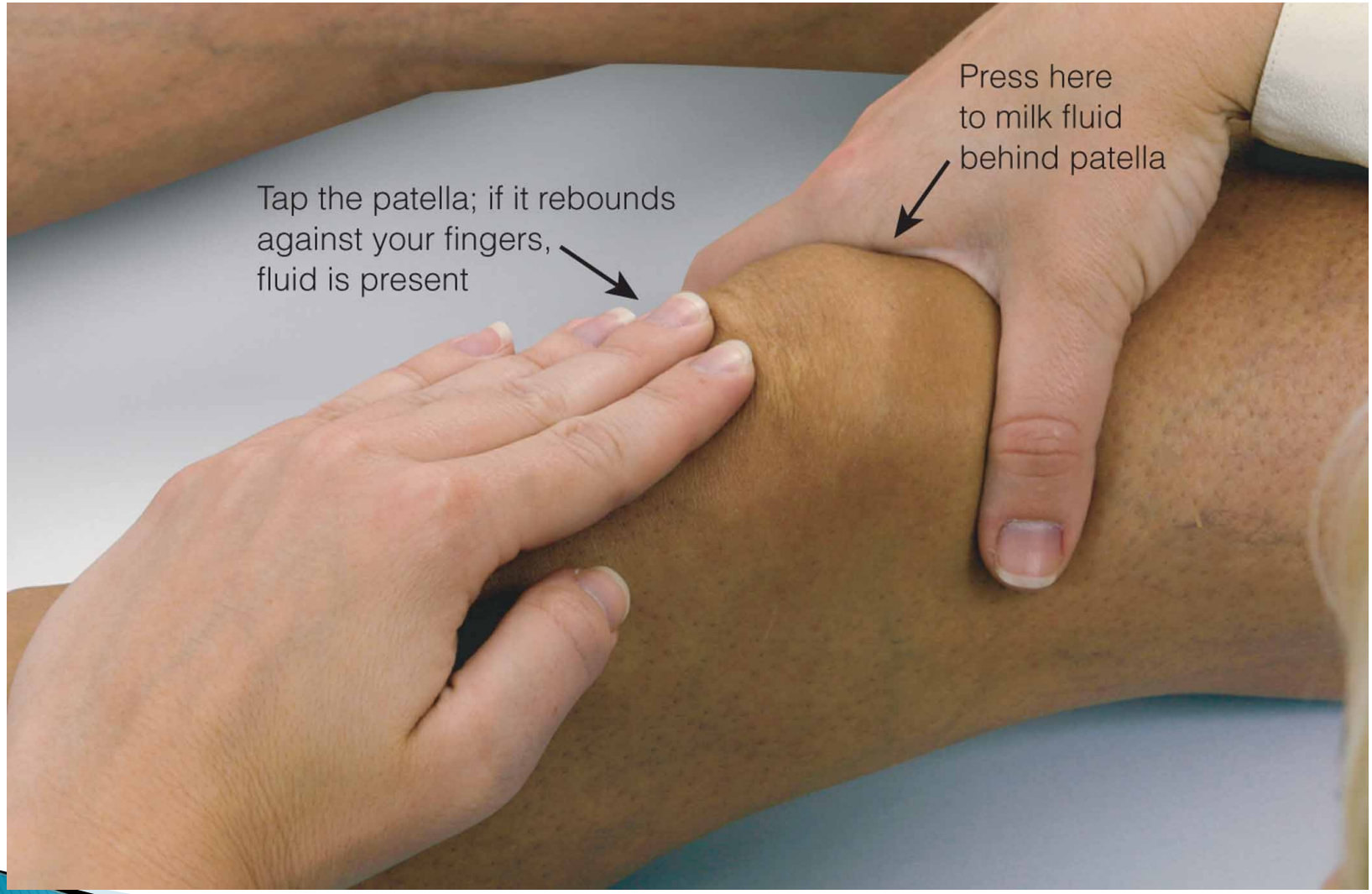

Flexion of the knee



Palpating the ankle

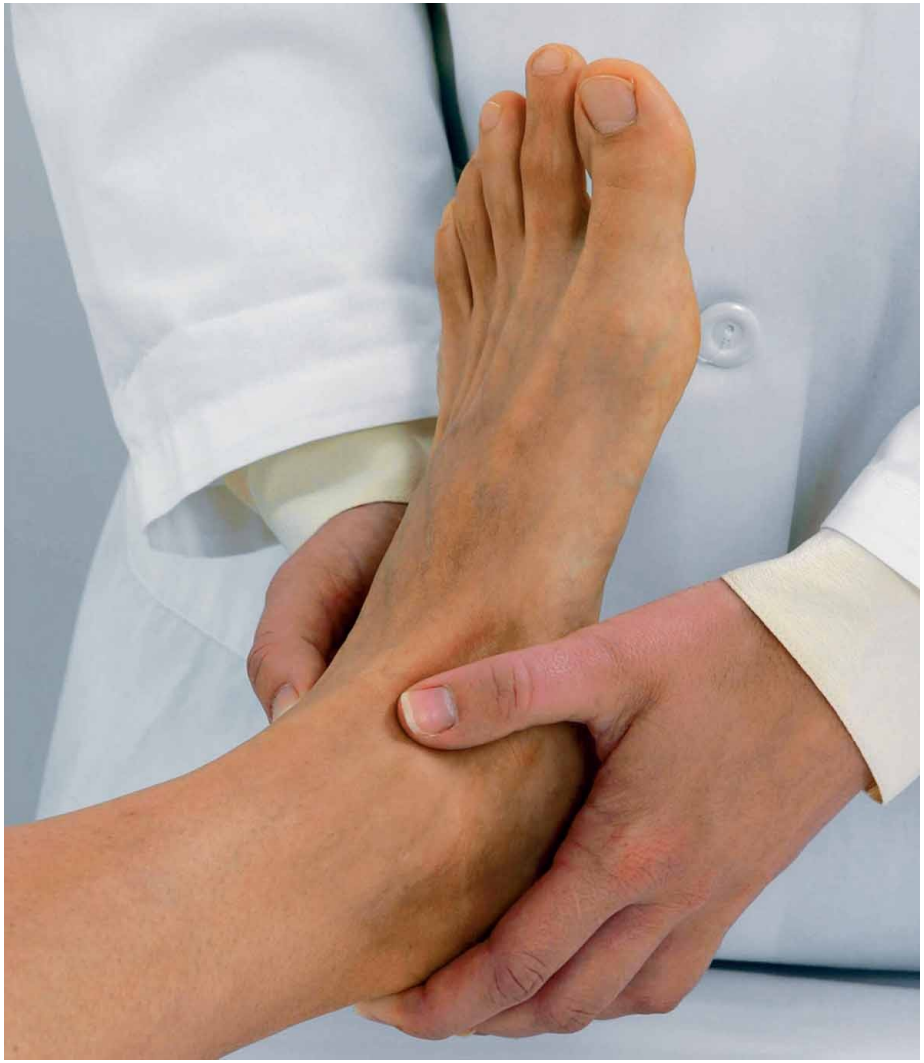

Eversion and inversion of the ankles

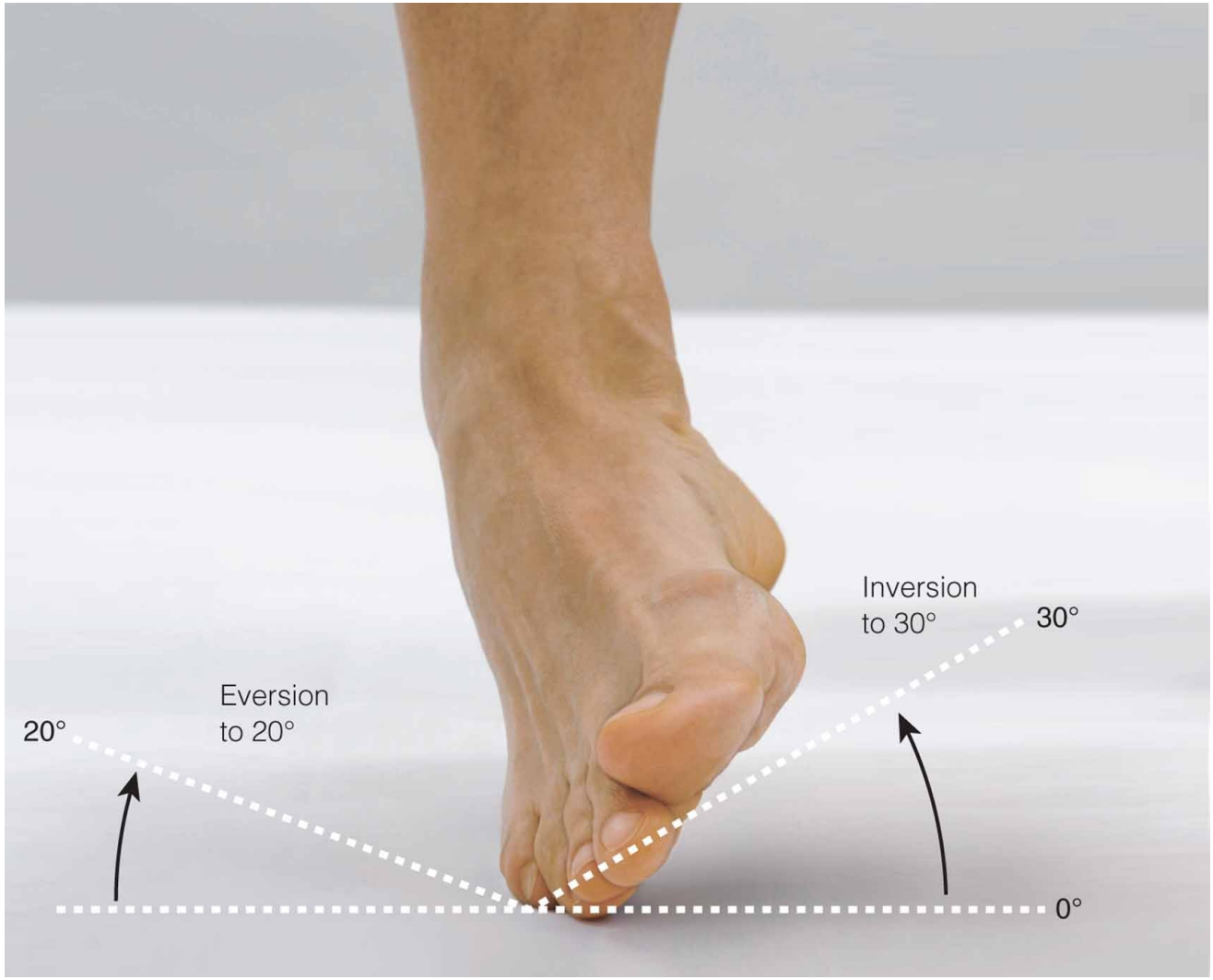

Lateral view of spine

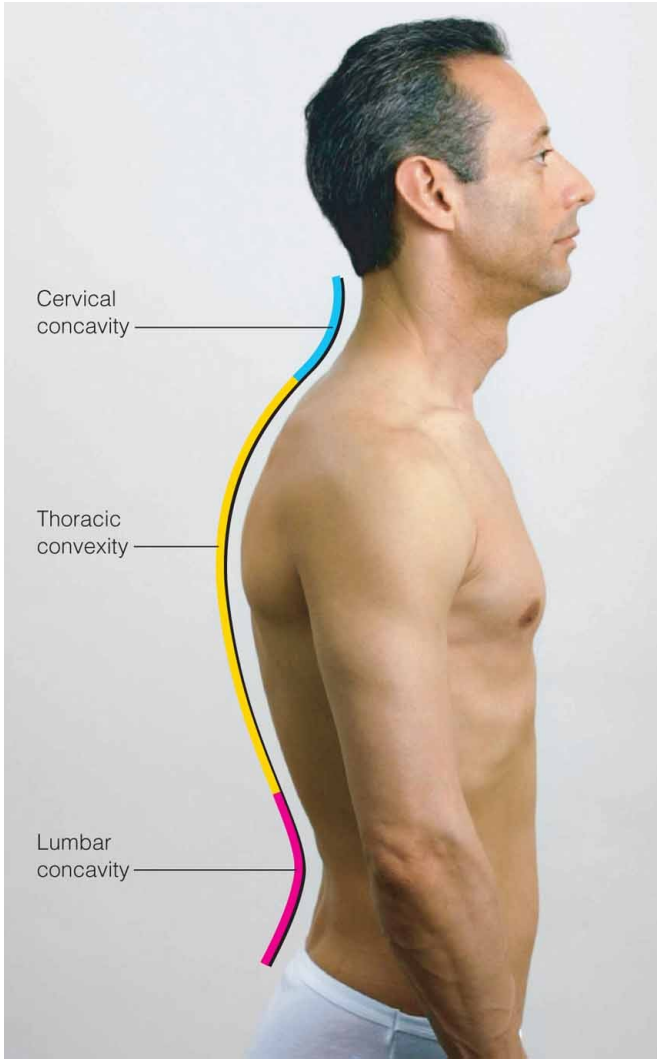

Posterior view of spine



Lateral flexion of the spine

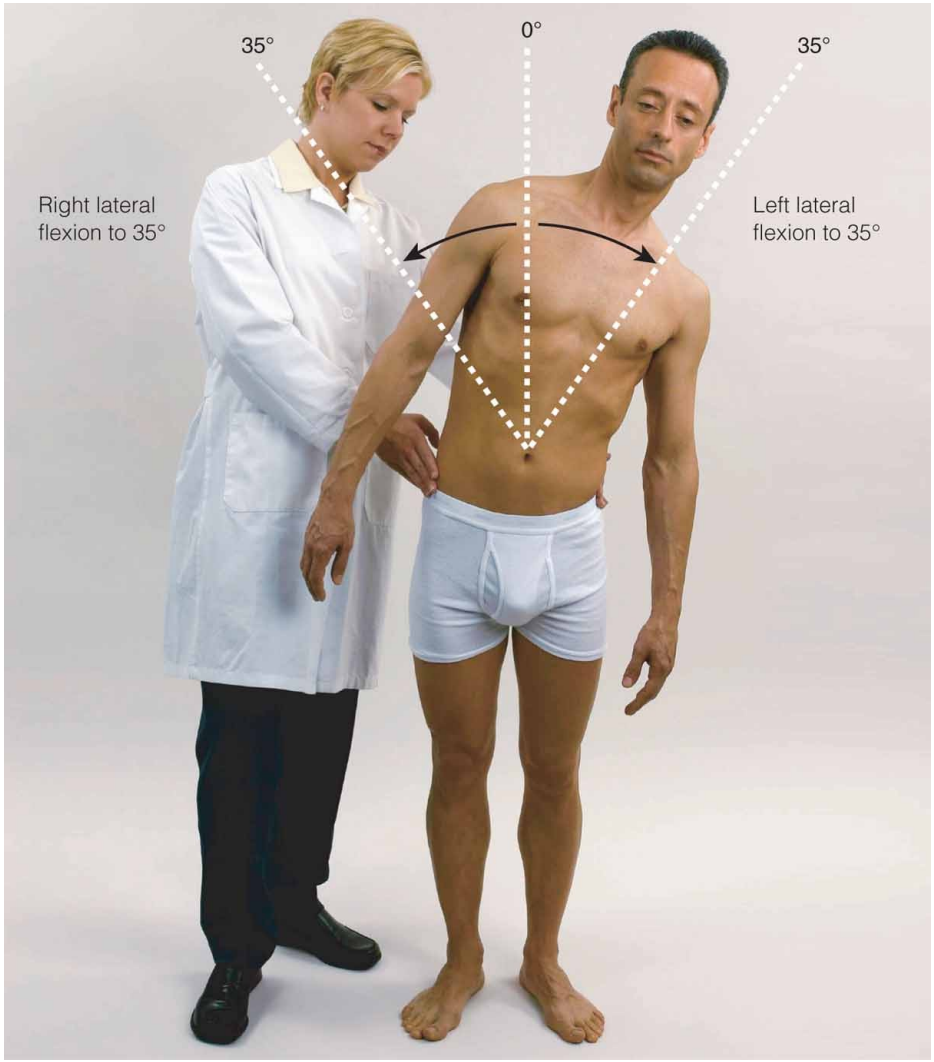

Forward flexion of the spine

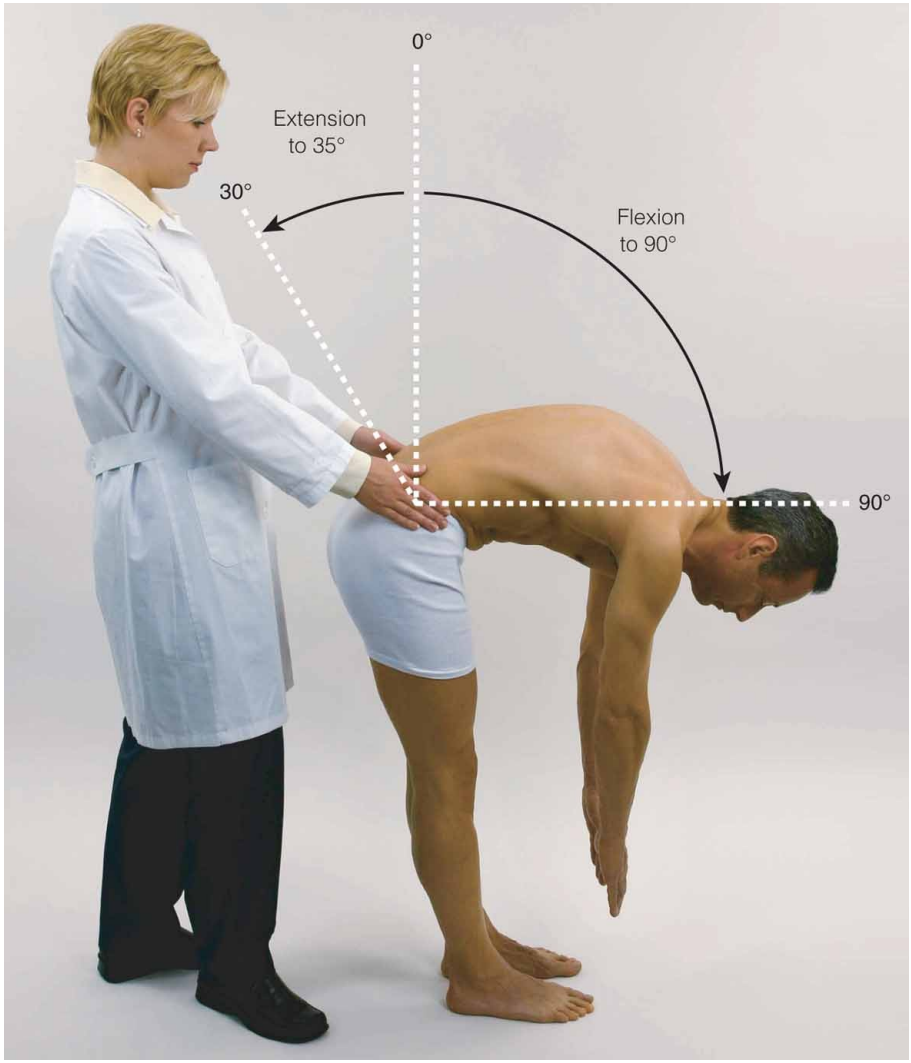

Rotation of the spine

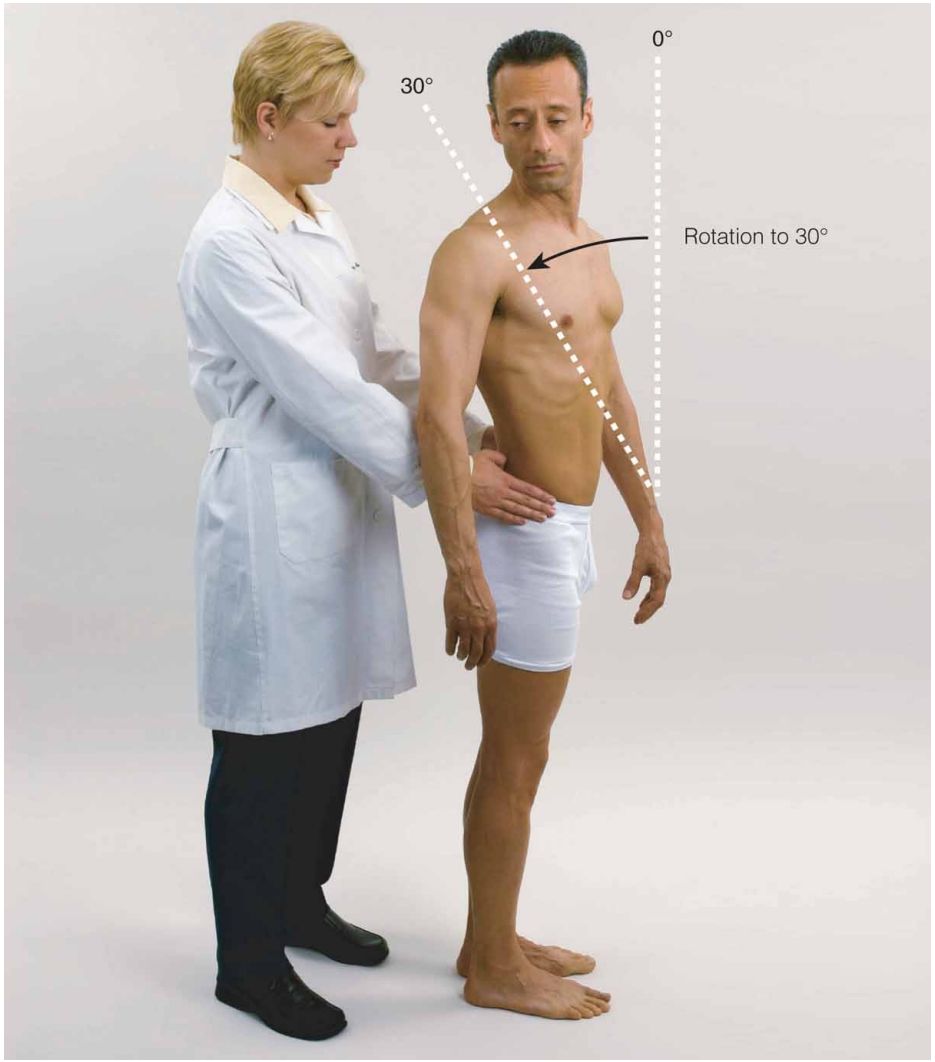

Abnormal Findings of the Musculoskeletal System

- Inflammatory disorders
- Trauma-induced disorders
- Abnormalities of the spine
- Joint disorders

Trauma Induced Disorders

- Dislocations
- Sprains
- Fractures
- Strains

Trauma-Induced Disorders

Table 23.6 Trauma-Induced Disorders

DISORDER	DESCRIPTION
Dislocation	A displacement of the bone from its usual anatomic location in the joint.
Joint Sprain	A stretching or tearing of the capsule or ligament of a joint due to forced movement beyond the joint's normal range.
Fracture	A partial or complete break in the continuity of the bone from trauma.
Muscle Strain	A partial muscle tear resulting from overstretching or overuse of the muscle.

Abnormalities of the Spine

- Kyphosis
- Scoliosis
- Lordosis

Glossary

- abduction A movement of a limb away from the midline or median plane of the body, along the frontal plane.
- acetabulum A rounded cavity on the right and left lateral sides of the pelvic bone.
- adduction The movement of a limb toward the body midline.
- ballottement A technique used to detect fluid, or to examine or detect floating body structures.
- bursae Small, synovial-fluid-filled sacs that protect ligaments from friction.
- calcaneous Heel bone.
- cartilaginous joint Bones joined by cartilage.
- circumduction The movement in which the limb describes a cone in space: while the distal end of the limb moves in a circle, the joint itself moves only slightly in the joint cavity.

- depression The movement in which the elevated part is moved downward to its original position.
- dislocation A displacement of the bone from its usual anatomical location in the joint.
- dorsiflexion Flexion of the ankle so that the superior aspect of the foot approaches the shin.
- elevation A lifting or moving superiorly along a frontal plane.
- eversion A movement in which the sole of the foot is turned laterally.
- extension A movement that increases the angle between the articulating bones.
- fibrous joint Bones joined by fibrous tissue.
- flexion A bending movement that decreases the angle of the joint and brings the articulating bones closer together.
- fracture A partial or complete break in the continuity of the bone from trauma.

- gliding The simplest type of joint movements. One flat bone surface glides or slips over another similar surface. The bones are merely displaced in relation to one another.
- hallux valgus The great toe is abnormally adducted at the metatarsophalangeal joint.
- hyperextension A bending of a joint beyond 180 degrees.
- inversion A movement in which the sole of the foot is turned medially.
- joint (Articulation) is the point where two or more bones in the body meet.
- kyphosis An exaggerated thoracic dorsal curve that causes asymmetry between the sides of the posterior thorax.
- lordosis An exaggerated lumbar curve that compensates for pregnancy, obesity, or other skeletal changes.

- opposition The movement of touching the thumb to the tips of the other fingers of the same hand.
- plantar flexion Extension of the ankle (pointing the toes).
- pronation Movement of the forearm so that the palm faces posteriorly or inferiorly.
- protraction A nonangular anterior movement in a transverse plane.
- retraction A nonangular posterior movement in a transverse plane.
- rotation The turning movement of a bone around its own long axis.
- scoliosis The spine curves to the right or left, causing an exaggerated thoracic convexity on that side.
- sprain A stretching or tearing of the capsule or ligament of a joint due to forced movement beyond the joint’s normal range.
- strain A partial muscle tear resulting from overstretching or overuse of the muscle.
- subluxation A partial dislocation of the head of the radius which occurs commonly when adults dangle children from their hands or remove their clothing forcibly.

- supination Movement of the forearm so that the palm faces anteriorly or superiorly.
- synovial joint Bones separated by a fluid-filled joint cavity.
- tendon Tough fibrous bands that attach muscle to bone, or muscle to muscle.
- tophi Gout related hard nodules that may appear over the joint.