Acute glomerulonephritis

Sanjeev Sethi, An S De Vriese, Fernando C Fervenza

Lancet 2022; 399: 1646–63

Department of Laboratory Medicine and Pathology (S Sethi MD) **and Division of Nephrology and Hypertension** (F C Fervenza MD), **Mayo Clinic, Rochester, MN, USA; Division of Nephrology and Infectious Diseases, AZ Sint-Jan Brugge, Brugge, Belgium** (An S De Vriese MD); **Department of Internal Medicine, Ghent University, Ghent, Belgium** (An S De Vriese)

Correspondence to: Dr Fernando C Fervenza, Division of Nephrology and Hypertension, Mayo Clinic, Rochester, MN 55905, USA
fervenza.fernando@mayo.edu

Glomerulonephritis is a heterogeneous group of disorders that present with a combination of haematuria, proteinuria, hypertension, and reduction in kidney function to a variable degree. Acute presentation with full blown nephritic syndrome or rapidly progressive glomerulonephritis is uncommon and is mainly restricted to patients with post-infectious glomerulonephritis, anti-neutrophil cytoplasmic antibodies-associated vasculitis, and anti-glomerular basement membrane disease. Most frequently, patients present with asymptomatic haematuria and proteinuria with or without reduced kidney function. All glomerulonephritis disorders can show periods of exacerbation, but disease flairs characteristically occur in patients with IgA nephropathy or C3 glomerulopathy. The gold standard for the diagnosis of a glomerulonephritis is a kidney biopsy, with a hallmark glomerular inflammation that translates into various histopathological patterns depending on the location and severity of the glomerular injury. Traditionally, glomerulonephritis was classified on the basis of the different histopathological patterns of injury. In the last few years, substantial progress has been made in unravelling the underlying causes and pathogenetic mechanisms of glomerulonephritis and a causal approach to the classification of glomerulonephritis is now favoured over a pattern-based approach. As such, glomerulonephritis can be broadly classified as immune-complex glomerulonephritis (including infection-related glomerulonephritis, IgA nephropathy, lupus nephritis, and cryoglobulinaemic glomerulonephritis), anti-neutrophil cytoplasmic antibodies-associated (pauci-immune) glomerulonephritis, anti-glomerular basement membrane glomerulonephritis, C3 glomerulopathy, and monoclonal immunoglobulin-associated glomerulonephritis. We provide an overview of the clinical presentation, pathology, and the current therapeutic approach of the main representative disorders in the spectrum of glomerulonephritis.

Introduction

Glomerulonephritis is a heterogeneous group of disorders. Sometimes the kidney is the sole or major organ affected, for example by kidney-restricted autoimmunity or a genetic disorder. Glomerulonephritis might also occur as part of a multisystemic disease, as a manifestation of a malignancy or monoclonal gammopathy, or as a consequence of external factors such as infections or drugs.

Glomerular diseases might present as many different clinical patterns or syndromes (table 1), characterised by a variable intensity, combination, and time course of haematuria, proteinuria, fluid retention, hypertension, and reduction in the glomerular filtration rate (GFR). Acute presentation with a full-blown nephritic syndrome (haematuria and red blood cell casts, proteinuria, oliguria, hypertension, and oedema) or rapidly progressive glomerulonephritis (loss of kidney function in days, weeks, or months, presumed to be due to acute glomerulonephritis) is uncommon. Most frequently, patients present with asymptomatic haematuria and proteinuria with or without reduced kidney function. Recognition of these patterns can be useful to create a tentative differential diagnosis. The initial approach to a patient with suspected glomerulonephritis includes a microscopic analysis of the urinary sediment, biochemical testing of serum and urine and a serological analysis (panel). We favour a full laboratory and immunological evaluation from the start. As such, diagnosis can often be established before a kidney biopsy result is available, for example in patients with positivity for anti-neutrophil cytoplasmic antibodies (ANCA) or anti-glomerular basement membrane (GBM) serology. Calculation of the Chronic Kidney Disease Epidemiology Collaboration formula is the favoured way to assess estimated GFR (eGFR). To establish urinary protein excretion, a 24-h urine collection is preferred to examining urinary protein–creatinine ratio on a random spot urine sample, but a reasonable compromise is the measurement of a urinary protein–creatinine ratio on a spot sample of an intended 24-h urine collection.[1]

However, the gold standard for the diagnosis of a glomerulonephritis is a kidney biopsy, with hallmark glomerular inflammation, characterised by increased glomerular cellularity.[2,3] The glomerular hypercellularity manifests in various histopathological patterns depending on the location and severity of the glomerular injury. The patterns of injury include mesangial proliferative glomerulonephritis, diffuse endocapillary glomerulonephritis, exudative glomerulonephritis, necrotising and crescentic glomerulonephritis, membranoproliferative glomerulonephritis (MPGN), or even a combination of patterns. The traditional pattern-based classification of

Search strategy and selection criteria

We searched PubMed for articles in English using the search terms "glomerulonephritis", "infection-related", "IgA nephropathy", "lupus nephritis", "ANCA", "anti-GBM", "C3 glomerulopathy", "monoclonal Ig", "cryoglobulin", "pathology", "presentation", "therapy", "treatment", or "management" for studies in humans, in particular randomised controlled trials, systematic reviews, and large observational studies. We focused on articles published between Jan 1, 2016, and Dec 31, 2021. Relevant older articles were retrieved by a manual search of the reference lists of identified articles.

Descargado para Anonymous User (n/a) en University El Bosque de ClinicalKey.es por Elsevier en mayo 26, 2022. Para uso personal exclusivamente. No se permiten otros usos sin autorización. Copyright ©2022. Elsevier Inc. Todos los derechos reservados.

glomerulonephritis is helpful to understand the acuteness, severity, and extent of the disease process. However, different causes can result in the same pattern of injury. For example, glomerulonephritis caused by chronic hepatitis C or by abnormalities of the alternative complement pathway might have an identical MPGN pattern of injury.[4] Similarly, a diffuse proliferative glomerulonephritis can be caused by an acute infection, lupus nephritis, or cryoglobulinemia, in all of which immunoglobulins accumulate in the glomerulus with ensuing inflammation. Furthermore, almost all causes of glomerulonephritis can lead to a scarring pattern of injury, such as sclerosing glomerulonephritis. Finally, although most glomerulonephritis are associated with a characteristic pattern of injury, they can present with more than one histopathological pattern on a kidney biopsy.

Substantial progress has been made in unravelling the underlying causes and pathogenetic mechanisms of glomerulonephritis and more effective and targeted therapies have become available. Therefore, a causal approach to the classification of glomerulonephritis is now favoured over a pattern-based approach. The causes of glomerulonephritis can generally be inferred from the findings of immunofluorescence studies.[5] As such, glomerulonephritis can be broadly classified as immune-complex glomerulonephritis (including infection-related glomerulonephritis, IgA nephropathy, lupus nephritis, and cryoglobulinaemic glomerulonephritis), ANCA-associated (pauci-immune) glomerulonephritis, anti-GBM glomerulonephritis, C3 glomerulopathy, and monoclonal immunoglobulin-associated glomerulonephritis (figure 1, table 2). Minimal change disease, focal segmental glomerulosclerosis, and membranous nephropathy are not characterised by glomerular inflammation and therefore fall outside the scope of this Seminar.

	Definition
Asymptomatic proteinuria or microscopic haematuria	Active urinary sediment (dysmorphic red blood cells and red blood cell casts), with or without proteinuria in a sub-nephrotic range, healthy kidney function variables, and a healthy blood pressure
Nephrotic syndrome	A persistent urinary total protein excretion of >3·5 g per 24 h and a serum albumin concentration of <3·5 g/dL if measured by bromocresol green methods or <3 g/dL if measured by bromocresol purple or immunonephelometric methods; oedema, hyperlipidaemia, and lipiduria (ie, doubly refractile fat bodies) are common but are not required for the diagnosis
Nephritic syndrome	Active urinary sediment, proteinuria (usually <3·5 g per 24 h), oliguria, oedema, and hypertension
Rapidly progressive glomerulonephritis	Active urinary sediment, a progressive loss of kidney function within days to months; oliguria might be present
Chronic glomerulonephritis	Hypertension, kidney impairment, proteinuria, and small kidneys with increased echogenicity

Table 1: **Clinical presentations characteristic of glomerular disease**

The general management of glomerulonephritis includes a low salt (<2 g per day) diet and an optimisation of blood pressure control (the target systolic blood pressure is <120 mm Hg) with an renin–angiotensin–aldosterone system (RAAS) blockade at maximally tolerated or allowed doses. Dietary protein intake should be based on the degree of proteinuria with the replacement of nephrotic losses, and the amount of kidney function.[6] Lifestyle modifications, including smoking cessation, weight loss, and regular physical activity should be encouraged in all patients with glomerulonephritis as a method to improve blood pressure control and reduce cardiovascular risk. When kidney function deteriorates despite active treatment, a timely preparation for the start of renal replacement therapy is essential, with a focus on patient empowerment and life participation.[7]

Infection-related glomerulonephritis

Viral, bacterial, and fungal infections can all be associated with infection-related glomerulonephritis. Two different types can be distinguished on the basis of the temporal relation between the infection and the onset of the glomerular disease: post-infectious glomerulonephritis (PIGN) and glomerulonephritis associated with an active infection.[8–10] The incidence of PIGN has declined particularly in high-income countries, whereas the incidence of glomerulonephritis associated with an active infection has increased over the past few decades.

Clinical presentation

PIGN generally presents 1–6 weeks after the resolution of the infectious episode. [9,11,12] The prototypical example of PIGN is poststreptococcal glomerulonephritis caused by

Panel: **Initial laboratory evaluation in patients suspected as having glomerulonephritis**

- Complete blood count
- Urinalysis with a careful search for red blood cell casts
- Proteinuria quantification (on a 24 h urine sample)
- Complete metabolic panel
- C3 and C4 complement concentrations
- Anti-double stranded DNA antibody
- Anti-neutrophil cytoplasmic antibodies and anti-glomerular basement membrane serology
- Hepatitis B, hepatitis C, and HIV serology
- Monoclonal protein studies and plasma free light chains (in patients aged >50 years)
- C-reactive protein
- Cryoglobulins and rheumatoid factor (in patients presenting with palpable purpura, arthralgia, or arthritis; peripheral neuropathy; and hypocomplementemia [low C4 concentration] or both)
- Anti-streptolysin O titre, anti-deoxyribonuclease B, and blood cultures (when infection-related glomerulonephritis is suspected)

Descargado para Anonymous User (n/a) en University El Bosque de ClinicalKey.es por Elsevier en mayo 26, 2022. Para uso personal exclusivamente. No se permiten otros usos sin autorización. Copyright ©2022. Elsevier Inc. Todos los derechos reservados.

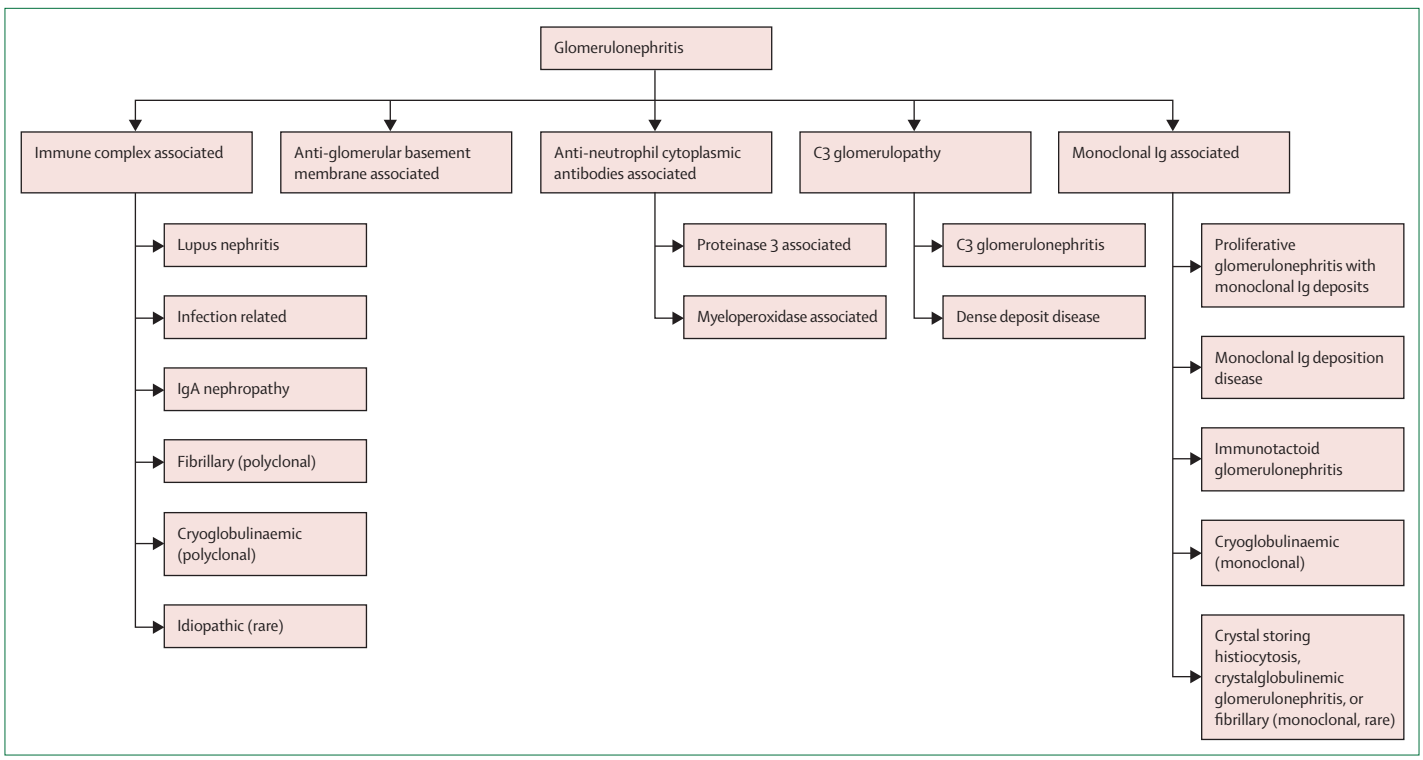

Figure 1: **Classification of glomerulonephritis based on cause**

specific nephritogenic strains of group A β-haemolytic streptococci in the context of an infection of the pharynx or skin. PIGN is typically a childhood disease but can occur in adults, mostly in patients aged older than 60 years.[13] Although most cases of PIGN are subclinical, a small proportion of patients present with the nephritic syndrome. Further non-invasive clues to the diagnosis are a positive anti-streptolysin O test (positive in 95% of patients with pharyngitis and 80% of patients with a skin infection), presence of anti-DNase B antibodies, and low C3 concentrations. In children, the diagnosis is made on a clinical basis and a kidney biopsy is usually not performed. In adults and in patients with persistently low C3 concentration (>3 months), a kidney biopsy is recommended to rule out the other causes of nephritic syndrome.

In contrast, glomerulonephritis associated with an active infection occurs in the setting of an ongoing infectious process. This type includes staphylococcus-associated glomerulonephritis (SAGN) that develops in people with a subacute or chronic infection with methicillin-sensitive or methicillin-resistant *Staphylococcus aureus* (including sepsis, soft tissue and skin infection, osteomyelitis, lung abscess, and pneumonia), as well as glomerulonephritis associated with bacterial endocarditis (mainly caused by *S aureus*, viridans group streptococci, and *Streptococcus mutans*, and the HACEK group of fastidious Gram-negative bacilli including *Haemophilus* spp, *Aggregatibacter* spp, *Cardiobacterium hominis*, *Eikenella corrodens*, and *Kingella* spp), shunt nephritis, deep-seated abscesses, and central venous catheter infections.[9] SAGN typically affects older male patients (50–70 years), who often have diabetes, or younger patients in the setting of intravenous drug abuse and associated endocarditis. These patients present with the nephritic syndrome or rapidly progressive glomerulonephritis. A low C3 concentration is present in 30–50% of patients. Blood cultures are positive for the causative microorganism in approximately 50% of patients.

Infection-related glomerulonephritis is thought to result from immune-complex deposition along the capillary walls with secondary complement activation as shown by bright C3 staining on immunofluorescence microscopy. The antigens probably include intracellular, membrane, and extracellular secretory bacterial proteins. One study revealed antibodies to complement factor B in patients with PIGN, contributing to the activation of the alternative complement pathway.[14] A genetic predisposition is suggested by familial clusters of PIGN.[15]

Pathology

Both PIGN and glomerulonephritis associated with an active infection are characterised on light microscopy by a diffuse proliferative pattern of injury with endocapillary hypercellularity and leukocyte infiltration including neutrophils (figure 2A–C). The term exudative glomerulonephritis is sometimes used to describe the extensive neutrophil infiltration of the capillary loops. Crescents

Descargado para Anonymous User (n/a) en University El Bosque de ClinicalKey.es por Elsevier en mayo 26, 2022. Para uso personal exclusivamente. No se permiten otros usos sin autorización. Copyright ©2022. Elsevier Inc. Todos los derechos reservados.

are more likely present in SAGN than in PIGN. Immunofluorescence microscopy in PIGN features bright staining for C3, often along with lesser degrees of IgG. The staining pattern of C3 and IgG can be coarse granular along the capillary walls (garland pattern) or scattered and randomly distributed fine granular deposits (starry sky pattern). Occasionally, only mesangial staining is present. Immunofluorescence microscopy in SAGN typically shows IgA that is either dominant or codominant with IgG and often accompanied by C3 in the mesangium and along the capillary walls, resembling primary IgA nephropathy. Hence, the term IgA-dominant infection-associated glomerulonephritis is sometimes used to identify SAGN. The classic finding on electron microscopy is subepithelial hump-shaped electron dense deposits. A few subendothelial and mesangial electron dense deposits might also be present. Subepithelial humps are more likely found in PIGN than in SAGN.

Treatment

The treatment of infection-related glomerulonephritis is supportive and directed at controlling hypertension, fluid retention, and oedema. Sometimes temporary dialysis is required. Antibiotics might be used in PIGN if there is evidence of an ongoing streptococcal infection, which also prevents infection spreading to other people the patient is in contact with. The use of glucocorticoids in the treatment of crescentic PIGN is controversial.[16–18] In children the prognosis is usually excellent, with serum creatinine returning to baseline within 4 weeks and haematuria resolving within 3–6 months. However, in some (primarily adult) patients, reduced eGFR, haematuria, and proteinuria persist longer than 6 months, increasing the possibility of an underlying disorder in the alternative complement pathway, requiring further exploration.[19–21] The treatment of glomerulonephritis associated with an active infection should be aimed at eradication of the ongoing infection. The role of immunosuppression is unproven and might even have catastrophic consequences, especially in patients at an older age and with comorbid diseases.[22] The prognosis of IgA-dominant infection-associated glomerulonephritis is generally poor, especially in patients with diabetes.[10] Other forms of glomerulonephritis associated with an active infection have a better prognosis, provided there is the early recognition and swift eradication of the infection.

	Extrarenal manifestations	Laboratory markers	Key pathological features
Infection-related glomerulonephritis*	Impetigo, pharyngitis, endocarditis, and abscess	Positive blood cultures and low C3	Diffuse proliferation; immunofluorescence: IgG and C3
IgA nephropathy*	Synpharyngitic haematuria, skin rash, and abdominal pain (IgA vasculitis)	Galactose-deficient IgA1	Mesangial, endocapillary proliferation, and crescentic; immunofluorescence: mesangial IgA
Lupus nephritis*	Skin rash, arthralgias, and serositis	Antinuclear antibody, anti-double stranded DNA antibody, low C3 or C4, and anti-phospholipid antibodies	Mesangial, endocapillary proliferation, and crescentic; immunofluorescence: so-called full house
Anti-neutrophil cytoplasmic antibodies-associated glomerulonephritis	Pulmonary nodules or infiltrates; ear, nose, or throat involvement; arthralgias; leukocytoclastic vasculitis; and neuropathy	Positive anti-neutrophil cytoplasmic antibodies (proteinase 3 or myeloperoxidase)	Necrotising crescentic; immunofluorescence: negative or trace Ig
Anti-glomerular basement membrane glomerulonephritis	Pulmonary haemorrhage	Anti-glomerular basement membrane antibody (with or without anti-neutrophil cytoplasmic antibodies)	Necrotising crescentic; immunofluorescence: linear IgG along glomerular basement membrane
C3 glomerulopathy	Synpharyngitic haematuria, drusen, and autoimmune disease	Low C3 or C4 and monoclonal Ig C3 nephritic factor	Mesangial, endocapillary proliferation, membranoproliferative, and crescentic; immunofluorescence: C3 dominant
Monoclonal Ig-associated glomerulonephritis	Haematological malignancy and monoclonal gammopathy of renal significance	Low C3 or C4 and monoclonal Ig	Membranoproliferative; immunofluorescence: IgG (monotypic), κ or λ light chain restriction
Cryoglobulinaemic glomerulonephritis*	Purpura, skin ulcers, arthralgias, and peripheral neuropathy	Hepatitis serology, low C4, monoclonal Ig, haematological or autoimmune disease biomarkers, or seronegative	Membranoproliferative; immunofluorescence: depends on type of cryoglobulin, IgM or IgG, and light chain restriction

*Immune-complex glomerulonephritis.

Table 2: **Overview of the different forms of glomerulonephritis**

IgA nephropathy

IgA nephropathy is the most common form of primary glomerulopathy, with the highest prevalence globally in east Asia.[23] Galactose-deficient IgA1 molecules that are thought to originate in mucosal tissue or from polymeric IgA1 produced in the bone marrow lead to the formation of anti–galactose-deficient IgA1 autoantibodies, with the deposition of IgG or IgA anti–galactose-deficient IgA1 immune complexes in the mesangium and resulting in the activation of complement and cytokine cascades.[24] Increased IgA1 concentrations occur in 30–40% of the patients with IgA nephropathy, but are not associated with the prognosis or response to immunosuppressive therapy.[25] Secondary causes of IgA nephropathy include chronic liver disease, coeliac disease, dermatitis herpetiformis, and ankylosing spondylitis. Genome-wide association studies have identified many susceptibility loci for IgA nephropathy.[26]

Clinical presentation

Patients generally present during the second or third decades of life with asymptomatic haematuria with or without proteinuria, or with an episode of macroscopic haematuria accompanying an intercurrent upper respiratory tract infection (synpharyngitic).[27] Nephrotic syndrome is seen in less than 10% of patients and raises the possibility of a podocytopathy (eg, minimal change disease) superimposed on the IgA nephropathy. Acute

Descargado para Anonymous User (n/a) en University El Bosque de ClinicalKey.es por Elsevier en mayo 26, 2022. Para uso personal exclusivamente. No se permiten otros usos sin autorización. Copyright ©2022. Elsevier Inc. Todos los derechos reservados.

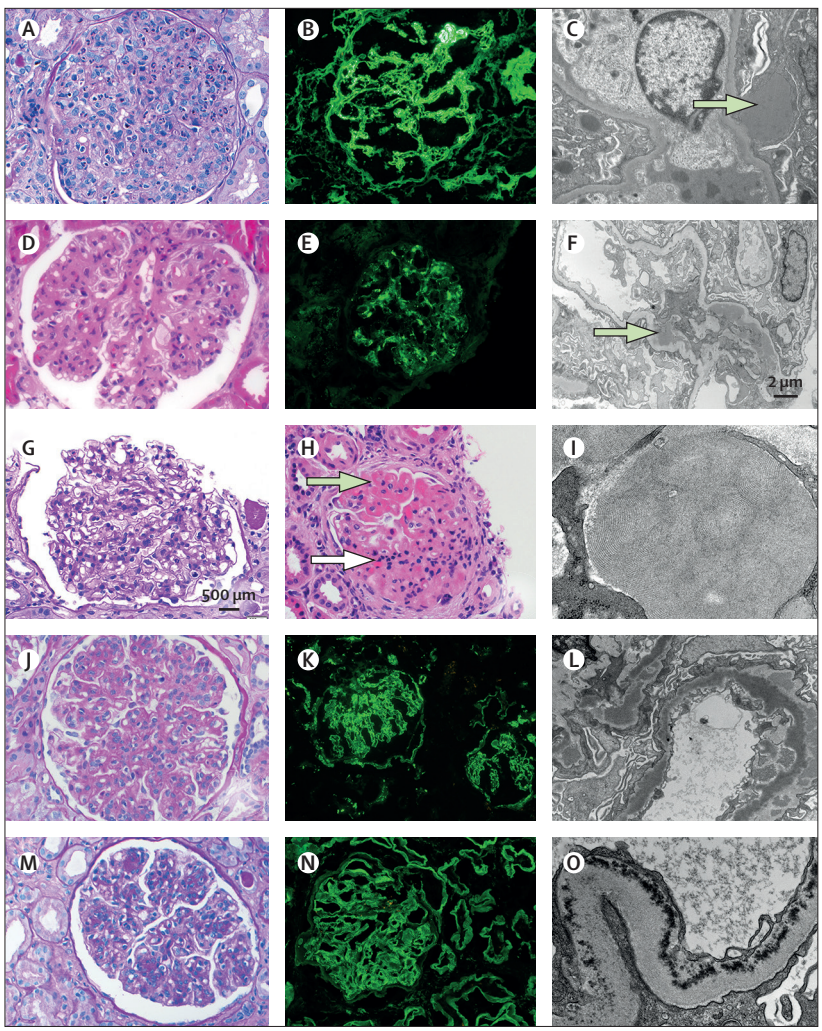

Figure 2: **Kidney biopsy findings on microscopy in acute glomerulonephritis**
Each panel represents a disease entity. (A–C) Post-infectious glomerulonephritis. (A) Light microscopy showing endocapillary hypercellularity with many neutrophils (periodic acid-Schiff stain, x40). (B) Immunofluorescence microscopy showing granular IgG along the capillary walls (x40). (C) Electron microscopy showing a subepithelial electron dense deposit (arrow, subepithelial hump; x9300). (D–F) IgA nephropathy. (D) Light microscopy showing mesangial hypercellularity (haemotoxylin and eosin stain, x40). (E) Immunofluorescence microscopy showing bright mesangial IgA (x20). (F) Electron microscopy showing many mesangial electron dense deposits (arrow; x4800). (G–I) Lupus nephritis. (G–H) Lupus nephritis. (G) Light microscopy showing mesangial proliferative lupus nephritis (class 2; periodic acid–Schiff stain, x40). (H) Wire loops (green arrow) and endocapillary hypercellularity (white arrow; can be either class 3 or 4 depending on the number of glomeruli involved; haemotoxylin and eosin stain, x40). (I) Electron microscopy showing fingerprint substructure of electron dense deposits (x50 000). (J–L) Dense deposit disease. (J) Light microscopy showing a membranoproliferative pattern of injury (periodic acid–Schiff stain, x40). (K) Immunofluorescence microscopy showing bright staining for C3 (x20; negative staining for immunoglobulins, not shown). (L) Electron microscopy showing large intramembranous electron dense deposits (x8000). (M–O) Light chain deposition disease. (M) Light microscopy showing a both a nodular and membranoproliferative pattern of injury (periodic acid–Schiff stain, x40). (N) Immunofluorescence microscopy showing bright linear staining λ light chains both along the glomerular and tubular basement membranes (x40; with negative staining for κ light chains, not shown). (O) Electron microscopy showing powdery punctate electron dense deposits along the tubular basement membranes (x4000).

kidney injury occurs in less than 5% of patients, either secondary to an episode of macroscopic haematuria with usually reversible acute tubular damage because of red blood cell casts,[28] or because of rapidly progressive glomerulonephritis that generally has a bad prognosis.[29]

In up to 60% of patients, IgA nephropathy has a benign clinical course, with stable proteinuria of less than 500 mg per 24 h and preserved kidney function. However, the progression to end-stage kidney disease (ESKD) occurs in up to 40% of patients older than 10–25 years.[30] Superimposed conditions, such as Alport syndrome or thrombotic microangiopathy, can markedly affect the prognosis.[31] Clinical predictors of progression include proteinuria of more than 1 g per 24 h, hypertension, the presence of crescents on a kidney biopsy, and impaired kidney function at diagnosis. Any degree of proteinuria carries a worse prognosis in IgA nephropathy than in other forms of glomerular disease. The International IgA Nephropathy Network[32] has developed a risk-prediction tool that combines clinical and histological variables, including: (1) age; (2) eGFR, mean blood pressure, and proteinuria at biopsy; (3) Oxford-MEST score; (4) the use of RAAS blockade; and (5) immunosuppression at biopsy, which can predict a 50% decline in kidney function or ESKD with good accuracy and can be calculated using the decision support app International IgAN prediction tool at biopsy QxMD. Use of this prediction tool to decide on the use of immunosuppressive therapy has improved outcomes compared with the use of proteinuria alone as a prediction marker.[33] The tool does not include crescents and haematuria, both of which have been shown to be associated with outcome, and cannot be used to establish the effect of a particular immunosuppressive treatment.[34–36]

The systemic form of IgA nephropathy is called IgA vasculitis (formerly Henoch-Schönlein purpura). This form is more common in children and manifests with leukocytoclastic vasculitis (more prominent below the waist), arthralgias, abdominal pain, and kidney involvement in 30–50% of patients. The prognosis is generally good for children but varies in adults.[37]

Pathology

On light microscopy, the prominent pattern is that of mesangial proliferative glomerulonephritis. However, endocapillary proliferative and crescentic and necrotising glomerulonephritis might also be seen. Sclerosing patterns varying from focal segmental glomerulosclerosis to extensive global glomerulosclerosis might be present. Immunofluorescence microscopy characteristically shows mesangial IgA immune deposits. Electron microscopy typically reveals mesangial electron-dense deposits, although less commonly, a few capillary wall deposits might be present (figure 2D–F).

The Oxford classification of IgA nephropathy, often called the MEST-C score, is based on five variables: mesangial hypercellularity (M score), endocapillary hypercellularity (E score), segmental sclerosis (S score), extent of tubular atrophy and interstitial fibrosis (T score), and crescents (C score). The specific score for each pathological feature has an independent prognostic value.[34,38,39]

Descargado para Anonymous User (n/a) en University El Bosque de ClinicalKey.es por Elsevier en mayo 26, 2022. Para uso personal exclusivamente. No se permiten otros usos sin autorización. Copyright ©2022. Elsevier Inc. Todos los derechos reservados.

Treatment

In patients with healthy kidney function and proteinuria of less than 0·75–1·00 g per 24 h, treatment is supportive as discussed in the general management of glomerulonephritis.[40] The use of an SGLT2 inhibitor has been shown to strongly reduce the risk of kidney failure or death in patients with IgA nephropathy.[41] Thus, the addition of an SGLT2 inhibitor to RAAS blockade should be considered in all patients with persistent proteinuria despite optimal blood pressure control. The 2021 Kidney Disease Improving Global Outcomes (KDIGO) guidelines state that patients with persistent proteinuria of more than 0·75–1·00 g per 24 h despite optimised supportive care for at least 3 months or who are at a high risk of a progressive loss of kidney function might be considered for treatment with glucocorticoids or referred to a clinical trial of novel therapeutic agents.[1] However, the clinical benefit of glucocorticoids in IgA nephropathy has not been established.[42,43] Although studies and large meta-analyses have suggested a beneficial effect of glucocorticoids in patients with proteinuria of more than 1 g per 24 h,[44] the STOP IgA nephropathy trial done in western European patients with an eGFR of 60 mL per min per 1·73 m² or more and proteinuria of 1·6±0·8 g per 24 h found no short-term or long-term benefit of glucocorticoid monotherapy.[45–47] On the other hand, the Therapeutic Evaluation of Steroids in IgA Nephropathy Global Study (TESTING) study[48] (NCT number 01560052), done in 503 mainly Chinese patients with an eGFR of more than 20 mL per min per 1·73 m² and proteinuria of more than 1 g per 24 h, showed that 6–9 months of oral methylprednisolone reduced the risk of major kidney outcomes and kidney failure in people with IgA nephropathy (257 patients vs 246 on placebo). The protective effect for the kidney of methylprednisolone was similar across subgroups, including the full and reduced dose regimen groups. The incidence of serious adverse events increased, particularly with high-dose steroid therapy. The TESTING study will also evaluate the predictive value of histopathology (using the MEST-C Oxford scoring system) on steroid responsiveness.[49] Preliminary studies also showed a benefit of budesonide designed to release the active steroid in the ileum, and a phase 3 trial (NEFIGARD; NCT number 03643965) is ongoing.[50] The use of mycophenolic acid salts has shown positive results in Chinese patients and in a retrospective study.[51–53] Early favourable effects with the use of cyclophosphamide followed by azathioprine for patients with an eGFR of less than 60 mL per min could not be confirmed by the STOP-IgA nephropathy trial.[45,54] One pilot study showed no effect of rituximab in IgA nephropathy but another study suggested benefit in IgA vasculitis.[55,56] Patients presenting with rapidly progressive glomerulonephritis with crescents can be administered intravenous methylprednisolone, followed by oral prednisone and cyclophosphamide, mycophenolate mofetil, or rituximab.[57] The use of plasma exchange in these patients is debatable. Patients with superimposed minimal change disease on a background of IgA nephropathy should be treated the same as patients with only minimal change disease. Patients with an eGFR of less than 30 mL per min per 1·73 m² and advanced chronic changes on a kidney biopsy should be treated conservatively and referred for renal replacement therapy.

Lupus nephritis

Lupus nephritis occurs in up to 50–70% of patients with systemic lupus erythematosus (SLE), generally within 5 years of diagnosis, and more frequently in individuals of African American, Hispanic, and Asian ethnicity, a younger age, and male sex.[58,59] Similar to patients with SLE, there is a genetic predisposition, supported by disease clustering in families, twin concordance, and racial differences in susceptibility. The occurrence of lupus nephritis is associated with an adverse prognosis.[60,61]

Clinical presentation

Patients with lupus nephritis generally have proteinuria and microscopic haematuria, and frequently also leukocyturia. However, the urinalysis does not always reflect the severity of the glomerular lesion, and the presentation can range from a healthy urinary sediment, healthy kidney function, and absence of proteinuria, to nephrotic syndrome, acute nephritic syndrome, or rapidly progressive glomerulonephritis. Less frequently, patients might present with tubulointerstitial disease manifested as renal tubular acidosis or isolated interstitial nephritis. Hypertension is common and can be severe. Typically, patients with proliferative lupus nephritis will have positive anti-nuclear antibodies and anti-double stranded DNA antibodies, along with low C3 and C4 complement concentrations. Anti-C1q and anti-Sm antibodies might also be present. Anti-phospholipid antibodies are common, and patients might present with a thrombotic microangiopathy.[62] Other conditions that can mimic the extrarenal manifestations of SLE and can be associated with kidney involvement include Sjögren syndrome, primary antiphospholipid syndrome, and mixed connective tissue disease.

Pathology

A kidney biopsy is the gold standard to diagnose lupus nephritis and characterise the histological patterns of injury, which can range from minimal or mild mesangial proliferative glomerulonephritis to diffuse endocapillary proliferative glomerulonephritis with crescentic and necrotising lesions. In addition, tubulointerstitial and vascular lesions might also be present. Based on light microscopy findings, the International Society of Nephrology and Renal Pathology Society classification of lupus nephritis recognises six morphological classes of kidney involvement: minimal mesangial (class 1), mesangial proliferative (class 2), focal (class 3), diffuse (class 4), membranous (class 5), and advanced sclerosing

Descargado para Anonymous User (n/a) en University El Bosque de ClinicalKey.es por Elsevier en mayo 26, 2022. Para uso personal exclusivamente. No se permiten otros usos sin autorización. Copyright ©2022. Elsevier Inc. Todos los derechos reservados.

(class 6).[63,64] In the first two classes, the involvement is restricted to the mesangium, with class 1 having no proliferative features and class 2 having mesangial proliferation. Class 3 and class 4 are both characterised by endocapillary hypercellularity, with or without crescents, necrosis, immune microthrombi and wire loops, and neutrophils in the capillary loops, but are distinguished from each other by the extent of glomerular involvement by any of the aforementioned findings (<50% of the glomeruli for class 3 and ≥50% of the glomeruli for class 4). Class 5 is defined by a membranous nephropathy pattern of injury, either as an isolated finding or in coexistence with either class 3 or 4 lupus nephritis. Class 6 shows extensive chronic changes, with more than 90% of glomeruli undergoing global sclerosis.

On the basis of the extent of the lesions, an activity and chronicity score are also established. Patients might migrate from one class to another spontaneously or after treatment. Immunofluorescence microscopy typically shows the glomerular deposition of IgG, IgM, IgA, C1q, and C3 (ie, a full house pattern). The location of immune deposits is dictated by the lupus nephritis class: mesangial in class 1 and 2, and along the capillary wall in class 3, 4, and 5. On electron microscopy, mesangial and subendothelial deposits are present depending on the lupus nephritis class. In class 5, subepithelial deposits are present. Tubuloreticular inclusions are common within glomerular and vascular endothelial cells. Electron-dense deposits sometimes show fingerprint-like substructures (figure 2 G–I). Histological lesions correlate with outcome, with class 3 and 4 (with or without class 5) having the worst prognosis. Other manifestations include acute and chronic tubulointerstitial nephritis, glomerular capillary thrombi in patients with antiphospholipid antibodies, and lupus podocytopathy.[65]

Treatment

The prognosis of class 1 and 2 lupus nephritis is excellent, and immunosuppression should be guided by extrarenal disease manifestations. Patients with nephrotic syndrome due to lupus podocytopathy should be managed as having minimal change disease. Patients with class 3 and 4 lupus nephritis, with and without class 5, should undergo induction therapy with corticosteroids plus cyclophosphamide or mycophenolate mofetil (MMF). Both treatment methods are considered equivalent. The Joint European League Against Rheumatism and European Renal Association–European Dialysis and Transplant Association[66] and 2021 KDIGO guidelines recommend induction therapy with intravenous methylprednisolone, 0·5–2·5 g over 1–3 days, followed by oral prednisolone, 0·3–1·0 mg/kg per day, plus intravenous cyclophosphamide, 500 mg every 2 weeks for six doses in total (Euro-Lupus regimen) or oral MMF, 2–3 g per day for 6 months.[1] Both guidelines suggest that prednisone should be tapered to 7·5 mg per day or less by 3–6 months. A more intense immunosuppressive regimen (the National Institutes of Health regimen) can be used for patients with severe disease, such as those with necrotising crescentic glomerulonephritis on biopsy or rapidly deteriorating kidney function, or both. A multitarget regimen combining glucocorticoids, MMF, and a calcineurin inhibitor has shown good efficacy compared with cyclophosphamide in Chinese patients.[67] The beneficial effects of this multitarget approach were confirmed using voclosporin as the calcineurin inhibitor added to low-dose prednisone and MMF in a more diverse patient population.[68] The addition of belimumab, a monoclonal antibody that blocks B cell activating factor, to a background of glucocorticoids, MMF, or low-dose cyclophosphamide significantly increased the proportion of patients achieving the primary efficacy endpoint in their renal response at 2 years.[69] Based on the results of these two trials, belimumab and voclosporin received US Food and Drug Administration approval for the treatment of lupus nephritis. However, voclosporin has not been compared directly with tacrolimus or cyclosporine in lupus nephritis. Obinutuzumab, a new humanised anti-CD20+ B cell monoclonal antibody, has shown promising preliminary results and is currently being evaluated in a phase 3 trial.[70] Patients with pure class 5 lupus nephritis and low amounts of proteinuria should be treated initially with supportive therapy only.[1] However, the development of progressive proteinuria or nephrotic syndrome should result in the use of corticosteroids plus an additional immunosuppressive agent (eg, cyclosporine, tacrolimus, MMF, or rituximab). Patients with lupus nephritis that are in remission should receive maintenance immunosuppression. The duration of the maintenance therapy is debatable. We recommend the continuation of maintenance therapy as long as there is evidence of SLE immunological activity (ie, positive for anti-double stranded DNA antibodies and low complement concentrations). A repeat kidney biopsy should be considered when the clinical and laboratory data do not match; for example, when a patient is negative for anti-double strand DNA antibodies and serum C3 and C4 complement concentrations within the normal range but with increasing proteinuria or decreasing kidney function, or both (eg, to rule out pure class 5 lupus nephritis) despite adequate immunosuppression. Repeating a kidney biopsy in the presence of active immunological activity does not seem justifiable; treatment should be optimised to induce immunological remission first. Also, redoing a biopsy when a patient is close to being in immunological remission (<6 months) might give misleading information because of the typical delay between immunological remission and the improvement of histological changes. Despite advances in therapy, a significant proportion of patients do not reach remission and progress to ESKD.[58] Patients with ESKD should be considered for kidney transplantation because there is a low rate of recurrence in the transplanted kidney.

Descargado para Anonymous User (n/a) en University El Bosque de ClinicalKey.es por Elsevier en mayo 26, 2022. Para uso personal exclusivamente. No se permiten otros usos sin autorización. Copyright ©2022. Elsevier Inc. Todos los derechos reservados.

ANCA-associated glomerulonephritis

ANCA are antibodies against proteins within the granules of neutrophils and lysosomes of monocytes. Indirect immunofluorescence microscopy of a patient's serum on ethanol-fixed neutrophils reveals two distinct patterns of neutrophil staining that distinguish between the two major subtypes of ANCA: cytoplasmic ANCA and perinuclear ANCA staining. Most cytoplasmic ANCA are specific for proteinase 3, whereas most perinuclear ANCA are specific for myeloperoxidase. ANCA-associated vasculitis (AAV) is classified according to the Chapel Hill Consensus as a microscopic polyangiitis, granulomatosis with polyangiitis, or eosinophilic granulomatosis with polyangiitis.[71] Approximately 85% of the patients with granulomatosis with polyangiitis are proteinase 3 ANCA positive and approximately 15% are myeloperoxidase ANCA positive, whereas approximately 85% of patients with microscopic polyangiitis are myeloperoxidase ANCA positive and approximately 15% are proteinase 3 ANCA positive.[72] Global variations exist with myeloperoxidase ANCA being more common in Japanese, Chinese, and southern European populations, whereas proteinase 3 ANCA is more common in all other populations.[73] Myeloperoxidase ANCA occurs more frequently in older patients (>65 years).[74] ANCA-associated glomerulonephritis is a frequent presentation of AAV and occurs in approximately 70% of patients, more commonly in patients with myeloperoxidase ANCA and in older patients.[75–78] Severe kidney involvement and an older age are associated with a higher mortality within the first year of diagnosis.[79,80]

Clinical presentation

ANCA specificity is the major determinant of clinical presentation. Patients with myeloperoxidase ANCA most often present with predominant kidney involvement, whereas patients with proteinase 3 ANCA are more likely to present with lung cavities or destructive ear, nose, and throat involvement.[81] ANCA-associated glomerulonephritis is the most frequent cause of rapidly progressive glomerulonephritis in patients older than 60 years.[76]

Pathology

Light microscopy reveals necrotising and crescentic lesions (figure 3) with a variable extent that can involve a few glomeruli (focal) to more than 50% of glomeruli (diffuse). A characteristic feature is the concomitant presence of lesions in different stages of the disease process: glomeruli might be healthy or affected by cellular, fibrocellular, or fibrous crescents of varying sizes. Immunofluorescence microscopy is negative or shows minimal immunoglobulin or complement deposits (pauci-immune), although crescents and areas of necrosis might reveal segmental coarse deposits of immunoglobulin and complement.[76,82]

Electron microscopy is negative or might show a few small electron dense deposits in the mesangium and along the capillary walls. The Berden classification stratifies ANCA-associated glomerulonephritis into focal, crescentic, mixed, and sclerotic classes and has prognostic relevance, but it does not predict outcomes when the eGFR is less than 15 mL per min per 1·73 m².[83,84]

Treatment

Patients with newly diagnosed or relapsing ANCA-associated glomerulonephritis have traditionally been administered intravenous methylprednisolone (1–3 g) followed by high-dose oral glucocorticoids (prednisone 1 mg/kg per day for 2 weeks, tapered to approximately 20 mg per day by week 12) combined with either cyclophosphamide or rituximab.[85,86] Therapy should be initiated as soon as the diagnosis is made (even if a kidney biopsy has not yet been performed) and potential contraindications (eg, an active infection) are ruled out, since delayed treatment is associated with worse outcomes.[77] A reduced dose and rapid oral glucocorticoid taper (prednisone 1 mg/kg per day for 1 week, tapered to approximately 7·5 mg per day by week 12) is as effective and safer than traditional high-dose regimens and should become the new standard of care.[87] Cyclophosphamide can be administered as daily oral or intermittent intravenous pulsed therapy for 3–6 months (appendix p 1). Both regimens are equally effective in inducing remission.[88] Intravenous pulsed cyclophosphamide

See Online for appendix

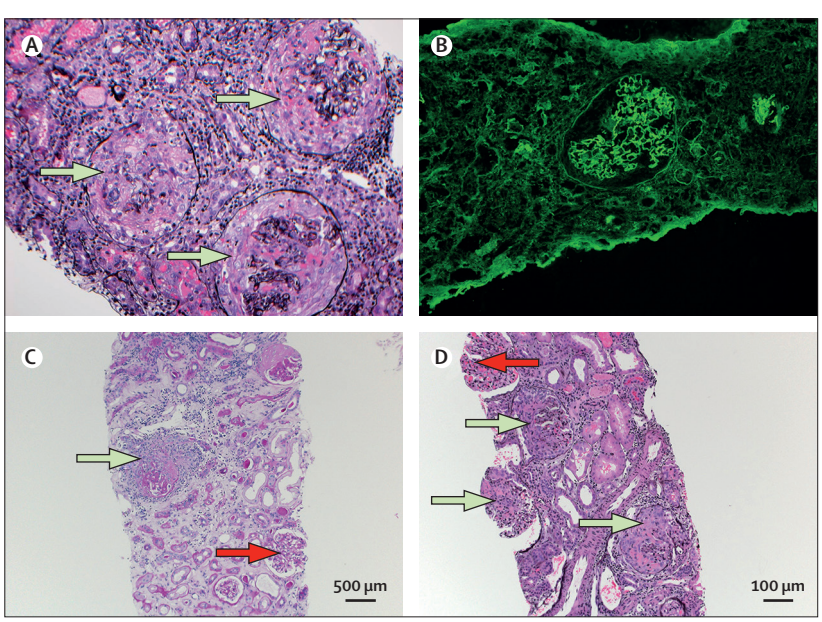

Figure 3: **Anti-glomerular basement membrane and anti-neutrophil cytoplasmic antibodies glomerulonephritis**

Top row: anti-glomerular basement membrane glomerulonephritis. (A) Light microscopy showing a severe necrotising and crescentic glomerulonephritis involving all three glomeruli with circumferential crescents (silver methenamine stain, x20). (B) Immunofluorescence microscopy showing bright linear IgG staining along the glomerular basement membranes (x20). Bottom row: anti-neutrophil cytoplasmic antibodies glomerulonephritis. (C) Myeloperoxidase anti-neutrophil cytoplasmic antibodies glomerulonephritis showing a crescentic glomerulonephritis with a cellular crescent involving one glomerulus, along with a globally sclerosed glomerulus, and few normal appearing glomeruli (periodic acid–Schiff stain, x10). (D) Proteinase 3 anti-neutrophil cytoplasmic antibodies glomerulonephritis showing more severe crescentic glomerulonephritis with cellular crescents involving three glomeruli and one normal appearing glomerulus (silver methenamine stain, x10). Green arrows point to crescents. Red arrows point to normal appearing glomeruli.

Descargado para Anonymous User (n/a) en University El Bosque de ClinicalKey.es por Elsevier en mayo 26, 2022. Para uso personal exclusivamente. No se permiten otros usos sin autorización. Copyright ©2022. Elsevier Inc. Todos los derechos reservados.

therapy allows the reduction of the cumulative dose and subsequent reduction in toxicity, but it is associated with an increased risk of relapses.[89] We consider intravenous pulsed cyclophosphamide for patients who have been previously administered cyclophosphamide to reduce the total cumulative dose, for patients who are intolerant to oral cyclophosphamide, or for patients in whom fertility or compliance are an issue. Compared with cyclophosphamide, rituximab is equally effective in patients with severe kidney disease[90–92] and superior in patients with proteinase 3 ANCA and relapsing disease.[93] One uncontrolled study in 64 patients with severe AAV reported that a combination of rituximab, low-dose intravenous cyclophosphamide, oral glucocorticoids, and plasma exchange resulted in disease remission at 6 months in 94% of patients, whereas 67% of patients who required dialysis recovered their kidney function.[94] However, the use of rituximab in combination with cyclophosphamide and glucocorticoids versus rituximab and glucocorticoids alone has not been evaluated for efficacy and safety in randomised controlled studies. A single small retrospective comparison study suggests no difference in efficacy.[95]

Patients with myeloperoxidase ANCA that is not severe and is restricted to the kidneys might benefit from glucocorticoids with MMF.[96,97] The C5a receptor inhibitor avacopan with reduced glucocorticoids dose is noninferior to a prednisone taper with respect to remission at week 26 and superior to a prednisone taper with respect to sustained remission at week 52.[98] The use of complement blockade is likely to herald a new era of minimal or no glucocorticoid remission-induction protocols, and avacopan has been approved by the US Food and Drug Administration and the European Medicines Agency as an add-on to standard treatment for patients with severe AAV. Although earlier studies suggested that the addition of plasma exchange reduced the risk of ESKD in patients with a serum creatinine of more than 5·7 mg/dL at diagnosis, the PEXIVAS trial showed no benefit of plasma exchange in patients with pulmonary haemorrhage, respiratory compromise, or serum creatinine of more than 5·5 mg/dL.[87] Whether plasma exchange could be of value in a subgroup of patients requiring dialysis at presentation is still debated.[99–101] One meta-analysis analysed the results of nine trials of plasma exchange treatment in AAV that were done over a 40-year period (1980–2020). The authors concluded that plasma exchange: (1) had no effect on all-cause mortality at 12 months (risk ratio 0·90 [95% CI 0·64–1·27], moderate certainty); (2) probably reduced the risk of ESKD at 12 months (risk ratio 0·62 [95% CI 0·39–0·98]); and (3) increased the risk of serious infections at 12 months (risk ratio 1·27 [95% CI 1·08–1·49], moderate certainty).[102] With modern therapies, complete remission can be reached in 70–90% of patients.[103]

A relapse after a successful remission occurs in 30–50% of patients within the first 5 years and is predicted by granulomatosis with polyangiitis phenotype, proteinase 3 ANCA, a history of previous relapses, and rising ANCA titers.[104] Treatment follows the same initial approach, although rituximab is preferred in view of the superior response observed in the RAVE trial.[85,86] Patients with granulomatosis with polyangiitis presenting with relapsing disease or with persistently positive myeloperoxidase ANCA or proteinase 3 ANCA are at a higher risk for future relapses and should be given maintenance therapy, preferentially with rituximab.[105,106] The optimal duration of maintenance therapy is uncertain. Our approach to maintenance therapy in patients who are positive for myeloperoxidase ANCA or proteinase 3 ANCA is to reschedule rituximab guided by B cell recovery and rising ANCA titers.[107] The efficacy of this approach has been confirmed in a randomised trial.[108] In our experience, newly diagnosed patients with myeloperoxidase ANCA who become and stay ANCA negative could be maintained without immunosuppression provided they are closely monitored for haematuria with a dipstick every 2 weeks and for ANCA reappearance every 3–4 months.[104] However, patients with proteinase 3 ANCA have a higher risk of relapse, particularly those with a history of relapse, and should still be administered long-term immunosuppression. This treatment method is especially important for patients with lung or upper respiratory tract involvement and older individuals with reduced eGFR who are less likely to tolerate a relapse than younger patients with a healthy GFR. The 5-year survival of AAV has steadily improved to 70–80%.[79]

Anti-GBM glomerulonephritis

Anti-GBM disease is caused by autoantibodies directed at the non-collagenous 1 domain of the α3 chain of type 4 collagen (classic Goodpasture antigen) that are only found in specialised basement membranes such as those of the kidney and lung, explaining the involvement of the kidney or lung, or both.[109–111] The term anti-GBM glomerulonephritis specifically refers to glomerular involvement, the terms anti-GBM disease or Goodpasture's disease cover the glomerular and pulmonary involvement caused by anti-GBM antibodies, and the term Goodpasture syndrome describes a pulmonary–renal syndrome that can occur secondary to many diseases (most commonly, AAV).

Clinical presentation

Anti-GBM disease has a bimodal age distribution, with peak incidences in the third, sixth, and seventh decades of life.[112] During the sixth and seventh decades of life, kidney-restricted disease is more common. Most patients present with rapidly progressive glomerulonephritis and up to 60% have concurrent lung haemorrhage. Patients are frequently oliguric or anuric at presentation, testifying to the suddenness and severity of the glomerular injury. Anti-GBM antibodies are the hallmark of the disease, although up to 10% patients do not have detectable anti-GBM antibodies when examined by conventional

Descargado para Anonymous User (n/a) en University El Bosque de ClinicalKey.es por Elsevier en mayo 26, 2022. Para uso personal exclusivamente. No se permiten otros usos sin autorización. Copyright ©2022. Elsevier Inc. Todos los derechos reservados.

methods.[113] In these patients, the target of the autoreactive antibodies is usually a collagenous basement membrane component distinct from the classic Goodpasture antigen.[114] Patients with atypical anti-GBM glomerulonephritis clinically characterised by an indolent course (haematuria, proteinuria, and mild renal insufficiency) without pulmonary haemorrhage have also been described.[115] A significant proportion of patients with anti-GBM glomerulonephritis also have circulating (usually myeloperoxidase) ANCA, suggesting more than a fortuitous coexistence of these two rare diseases in a single patient.[116–118] ANCA detection might precede the onset of anti-GBM glomerulonephritis, suggesting that ANCA might induce glomerular inflammation, modifying or exposing the sequestered epitopes in the GBM that subsequently trigger the development of anti-GBM antibodies.[119] Patients with a double-positive phenotype present with severe kidney and lung disease, showing the early morbidity and mortality of anti-GBM disease, and should be treated as patients with single-positive anti-GBM glomerulonephritis (discussed later).[120] Patients who are double positive have a tendency to relapse, similar to patients with AAV, and should be considered for maintenance immunosuppression as in patients with AAV.[120]

Pathology

Light microscopy reveals the involvement of more than 50% of glomeruli by necrotising and crescentic lesions in most patients (figure 3).[112] The crescents of anti-GBM glomerulonephritis are generally large and synchronous; namely, in the same phase and cellular, in contrast with the non-synchronous crescents of varying sizes in ANCA-associated glomerulonephritis. Immunofluorescence microscopy characteristically shows the linear deposition of polyclonal IgG and frequently C3 along the GBM, as opposed to the granular capillary wall deposits in immune-complex glomerulonephritis and the linear GBM (and tubular basement membrane) monotypic deposits in monoclonal immunoglobulin deposition disease. Identical patterns are found in patients who are double-positive for anti-GBM antibodies and ANCA. Electron microscopy shows the disruption of the glomerular capillary walls and fibrin in the Bowman spaces and is negative for electron dense deposits along the capillary walls.

Treatment

The early diagnosis and prompt initiation of treatment (even before a kidney biopsy) are key determinants of short-term and long-term prognosis.[109,121] Treatment consists of the rapid removal of the pathogenic autoantibody with plasma exchange, and high-dose glucocorticoids (oral prednisolone, 1 mg/kg per day, up to a maximum of 60 mg per day, tapered once per week to 20 mg per day by 6 weeks, and subsequently to a complete discontinuation by 6–9 months) and oral cyclophosphamide (2–3 mg/kg per day for 2–3 months) to prevent or reduce new autoantibody formation. Plasma exchange is usually performed once per day for 2–3 weeks and might need to be continued in persistent active alveolar haemorrhage and when anti-GBM concentrations do not decrease significantly or rebound after the withdrawal of plasma exchange.[109] The use of rituximab as an alternative to cyclophosphamide in the initial therapy of anti-GBM disease is not supported by evidence. IgG-degrading enzyme of Streptococcus pyogenes, an endopeptidase that can degrade circulating IgG, rapidly decreased circulating anti-GBM antibodies in three patients with refractory anti-GBM glomerulonephritis that was dialysis dependent,[122] although kidney function did not recover. The potential role of this endopeptidase in the treatment of anti-GBM disease has yet to be established. Patients who present with a serum creatinine of less than 5·7 mg/dL have a good prognosis, with 95% kidney survival at 1 year and 91% kidney survival at 5 years.[123] Patients presenting with serum creatinine of more than 5·7 mg/dL, but not requiring dialysis, have corresponding kidney survival rates of 82% at 1 year and 50% at 5 years. Patients presenting with oliguria, a high proportion of circumferential crescents on biopsy, or kidney failure requiring dialysis, or a combination, are unlikely to recover kidney function, unless the kidney failure is secondary to a superimposed disease (eg, acute interstitial nephritis).[109] Whether patients presenting with dialysis-dependent kidney failure without pulmonary haemorrhage should receive active treatment is debatable.[123] Anti-GBM disease is a single-hit disease and maintenance therapy is not necessary.

C3 glomerulopathy

C3 glomerulopathy is a rare disease caused by the dysregulation of the alternative complement pathway with the ensuing glomerular deposition of complement factors. The overactivation of the alternative complement pathway results from acquired or genetic abnormalities involving the complement regulating proteins,[124] which might be uncovered by triggers such as infections, autoimmune diseases, and monoclonal immunoglobulins.[125] The deposition of complement factors then drives glomerular inflammation resulting in a proliferative glomerulonephritis.[126,127] The defining feature of C3 glomerulopathy is the presence of bright C3 staining with minimal or no immunoglobulin staining on immunofluorescence studies.[128] C3 glomerulopathy is subdivided into C3 glomerulonephritis and dense deposit disease, differentiated from each other by the location and appearance of the glomerular deposits on electron microscopy. Whether these differences correspond with a distinct underlying pathophysiology is not yet clear.

Clinical presentation

Haematuria and proteinuria are present in most patients and proteinuria is often in the nephrotic range.[125,129]

Descargado para Anonymous User (n/a) en University El Bosque de ClinicalKey.es por Elsevier en mayo 26, 2022. Para uso personal exclusivamente. No se permiten otros usos sin autorización. Copyright ©2022. Elsevier Inc. Todos los derechos reservados.

Despite the presence of an underlying complement disorder, low C3 concentrations occur in only 47–65% of patients and low C4 in 12–14% of patients. A recent infection, an autoimmune disease, and a monoclonal gammopathy can each be identified as the triggering condition in approximately a third of the patients. A monoclonal immunoglobulin is identified in 65% of patients older than 50 years.[130] The monoclonal immunoglobulin most likely functions as an autoantibody to a complement regulatory protein, thereby indirectly activating the alternative complement pathway. A genetic variant in the alternative complement pathways factors or auto-antibodies (C3 nephritic factor, anti-factor H antibody, and anti-factor B antibody) can be detected in approximately a third of the cases each.[125,129] Rates of progression vary widely and some patients maintain a healthy kidney function for decades.[131] Predictors of poor prognosis are an increased serum creatinine, proteinuria of more than 3 g per 24 h at presentation, and extensive chronic damage on kidney biopsy, with an overall median kidney survival (doubling of serum creatinine or ESKD) of 91 months.[125] Some patients with presumed post-infectious glomerulonephritis have persistent haematuria and proteinuria or even progression to ESKD in the absence of any evidence of a preceding infection. Most of these patients with atypical post-infectious glomerulonephritis have an underlying defect in the regulation of the alternative complement pathway and probably represent undiagnosed C3 glomerulonephritis.[19]

Pathology

Light microscopy most commonly reveals a MPGN, although mesangial proliferative and crescentic patterns of injury might also occur. Immunofluorescence studies, by definition, show bright C3 (2–3+) with no or minimal (0–1+) immunoglobulin staining. On electron microscopy, C3 glomerulonephritis is characterised by electron-dense deposits in the mesangial cells and capillary wall, whereas dense deposit disease is identified by dense sausage-shaped osmiophilic intramembranous and mesangial deposits (figure 2J–L).[128,132] The capillary wall deposits in C3 glomerulonephritis can be subepithelial, intramembranous, and subendothelial in location. Subepithelial hump-like deposits can be found in approximately half of C3 glomerulonephritis biopsies. Proteomic analysis reveals that the deposits mainly consist of C3 and C3 breakdown products with little amounts of other complement factors.[133]

Treatment

There are no randomized trials to inform treatment decisions in patients with C3 glomerulonephritis. Recommendations are largely based on clinical experience and account for the severity of kidney dysfunction, degree of proteinuria, presence or absence of haematuria, and the kidney biopsy findings. Patients with mild disease, characterised by a healthy kidney function, low grade proteinuria (<1·5 g per 24 h), and no clinically significant haematuria (arbitrarily defined as more than ten red blood cells per high power field) can be managed conservatively. Patients with proteinuria at more than 1·5 g per 24 h and with more abnormalities in various combinations are candidates for treatment with immunosuppressive agents. We suggest a trial of MMF combined with oral glucocorticoids, in line with the KDIGO 2017 controversies conference.[134] This approach was particularly effective in patients with complement autoantibodies, whereas patients with pathogenic variants in complement genes only reached partial remission.[135,136] Conversely, other studies observed lower response rates to MMF.[125,137] Relapses occurred after treatment discontinuation in 33% of the patients who were in remission and longer treatment of MMF was associated with a lower risk of relapse. As such, we recommend that patients with persistent haematuria and proteinuria of more than 1·5 g per 24 h be on treatment indefinitely. Eculizumab might be considered in patients who do not respond to this approach, as suggested by its efficacy in some,[138–141] but not all patients.[141,142] In patients with a rapidly progressive crescentic glomerulonephritis, aggressive immunosuppression with pulse intravenous methylprednisolone followed by daily oral prednisone and either cyclophosphamide (oral or intravenous) or MMF is warranted. Eculizumab might also be effective in these cases.[143] Anecdotal reports suggest that plasma exchange might be of use in patients with C3 glomerulopathy with a genetic mutation.[144,145] Therapeutic trials of drugs aiming at controlling the overactive C3 convertase (anti-C3, anti-factor B, and anti-factor D) are currently ongoing.[146] In patients with an underlying monoclonal gammopathy, treatment should be directed at the clonal disorder (see later).

Monoclonal Ig-associated glomerulonephritis

Monoclonal Ig-associated kidney diseases encompass a wide spectrum of conditions (appendix pp 2–3). The phenotypical expression of these diseases depends on the compartment of the kidney that is involved, the physicochemical properties of the monoclonal Ig, and the mechanism through which it causes kidney damage.[147,148] Monoclonal immunoglobulin might directly cause injury via deposition in the glomeruli, tubules, or blood vessels. In these cases, immunofluorescence microscopy reveals the culprit monoclonal Ig. Conversely, the monoclonal immunoglobulin might indirectly inflict damage through complement activation, as occurs in C3 glomerulonephritis and thrombotic microangiopathy, in which the immunofluorescence will be negative for monoclonal immunoglobulin.[130,149] Further subclassification depends on the ultrastructural characteristics of the deposits that can be either organised (fibrillar, microtubular, or crystal) or non-organised. Monoclonal immunoglobulin deposition disease (MIDD) results from non-organised deposits of monoclonal immuno-

Descargado para Anonymous User (n/a) en University El Bosque de ClinicalKey.es por Elsevier en mayo 26, 2022. Para uso personal exclusivamente. No se permiten otros usos sin autorización. Copyright ©2022. Elsevier Inc. Todos los derechos reservados.

globulin along the glomerular and tubular basement membranes and can be subdivided into three types: light chain deposition disease, heavy chain deposition disease, and light heavy chain deposition disease, depending on whether the deposits are composed of light chains, heavy chains, or both. Other glomerulonephritis resulting from monoclonal immunoglobulin deposits include proliferative glomerulonephritis with monoclonal immunoglobulin deposits (PGNMID), cryoglobulinaemic glomerulonephritis, and immunotactoid glomerulopathy (appendix pp 2–3).

Monoclonal immunoglobulin in the serum or urine can be traced to a clonal proliferation of immunoglobulin-producing plasma cells or B lymphocytes.[150,151] The cause of monoclonal immunoglobulin can vary from a haematological malignancy such as multiple myeloma, Waldenström macroglobulinaemia, or B cell lymphoproliferative neoplasm,[152] to a non-malignant small clonal proliferation of plasma cells or B lymphocytes. Monoclonal gammopathy of undetermined significance refers to the presence of monoclonal immunoglobulin without a plasma cell or B lymphocyte malignancy or end organ damage and implies a benign condition.[150,152] The term monoclonal gammopathy of renal significance has been introduced to acknowledge a non-malignant yet clonal plasma cell or B lymphocyte proliferative disorder (such as monoclonal gammopathy of undetermined significance or smouldering myeloma) that results in monoclonal immunoglobulin-associated renal disease.[153] Conceptually, monoclonal gammopathy of renal significance is neither a specific kidney disease nor a specific haematological disorder, and instead points to a condition that might not require immediate therapy from a purely haematological perspective, but that should be treated because it causes kidney injury.

Clinical presentation

Kidney involvement is manifested by haematuria, proteinuria that can be more than 3·5 g per 24 h, hypertension, and variable degrees of kidney insufficiency.[154] C3 and C4 concentrations can be low, particularly in cryoglobulinaemic glomerulonephritis. Serum protein electrophoresis in combination with serum immunofixation confirms the presence of monoclonal immunoglobulin and allows for the identification of the heavy chain and light chain class. Urine protein electrophoresis is less sensitive for monoclonal immunoglobulin detection. The serum free light chain assay can detect low concentrations of monoclonal κ or λ light chains in the serum, which is of particular use for clones that produce only a Bence Jones protein (free light chain not bound to a heavy chain). When kidney function is impaired, the concentrations of the free light chain increase because of reduced kidney clearance, but an abnormal ratio of κ-to-λ free light chain points to the presence of a κ or λ clone. In more than two thirds of patients with PGNMID, no monoclonal immunoglobulin can be identified by serum or urine protein electrophoresis and immunofixation, the serum free light chain ratio is normal, and no clone can be identified on a bone marrow biopsy.[155] By contrast, in one series of 73 patients with immunotactoid glomerulopathy, haematological disorders were present in 66% of patients, including lymphoma in 41% of patients, monoclonal gammopathy in 20% of patients, and multiple myeloma in 6% of patients.[156] Similarly, MIDD most commonly occurs in the context of a plasma cell disorder, meeting the criteria for multiple myeloma in approximately 30–50% of patients and of monoclonal gammopathy of renal significance in 60–70% of cases.[157,158] An abnormal serum free light chain ratio has been present in all patients tested.[157]

Pathology

Light microscopy in PGNMID, cryoglobulinaemic glomerulonephritis, and immunotactoid glomerulopathy most often reveals a MPGN pattern of injury, whereas MIDD is associated with a nodular sclerosing glomerulopathy often with MPGN features (figure 2M–O). PGNMID, cryoglobulinaemic glomerulonephritis, and immunotactoid glomerulopathy result from the deposition of monoclonal immunoglobulin along the subendothelial region of capillary walls, most commonly IgG with κ and λ light chain restriction. Thus, the complete immunoglobulin (light chains attached to heavy chain) accumulates in the subendothelial region resulting in an inflammatory reaction (appendix p 4). In MIDD, most commonly there are only light chains that interact with matrix proteins, and less commonly there are only heavy chains that interact with matrix proteins. Thus, in MIDD, fine punctate deposits of monoclonal immunoglobulin are seen all along the GBM, tubular basement membrane, and in the mesangium. This pattern does not normally result in an inflammatory response, but in a sclerosing glomerulopathy.

Immunofluorescence studies typically reveal the monoclonal immunoglobulin deposits, that appear linear along the glomerular and tubular basement membranes in MIDD, granular in the mesangium and along the GBM and most often include IgG3 in PGNMID, large and within the lumen of the glomerular capillaries in cryoglobulinaemic glomerulonephritis, and along the glomerular capillaries in immunotactoid glomerulopathy. Electron microscopy findings help to further distinguish the various patterns: punctate granular deposits in the mesangium and along the GBM and tubular basement membrane in MIDD, non-organised electron dense deposits in the mesangium and along the capillary walls in PGNMID, intraluminal deposits with substructures (such as microtubular, fibrillary, curvilinear, or even fingerprint) in cryoglobulinaemic glomerulonephritis, and electron dense deposits that show hollow microtubular substructures measuring 10–60 nm in diameter in immunotactoid glomerulopathy.

Descargado para Anonymous User (n/a) en University El Bosque de ClinicalKey.es por Elsevier en mayo 26, 2022. Para uso personal exclusivamente. No se permiten otros usos sin autorización. Copyright ©2022. Elsevier Inc. Todos los derechos reservados.

Treatment

Plasma cell-targeted therapy and autologous stem cell transplantation have substantially improved the prognosis of MIDD. In a series of 169 patients, chemotherapy (using bortezomib-based therapy in 58% of patients) resulted in a very good partial haematological response in at least 52% of the patients.[158] A kidney response occurred in 62 patients (36%), all of whom had a haematological response. Unless haematological remission is reached after chemotherapy, the disease will recur in the kidney allograft.[159]

Most patients with PGNMID progress to ESKD without treatment.[160–163] The disease often recurs after kidney transplantation with a high rate of allograft failure.[164] Currently, there is no standard of care for patients with PGNMID. When a pathological clone is detected, the treatment should be directed towards the pathological clone.[161,162] When no pathological clone can be identified, the consensus practice is to treat patients similarly to those with multiple myeloma or lymphocytic or lymphoplasmacytic lymphoma, with a combination of cyclophosphamide, bortezomib, and dexamethasone (known as CyBorD), or with rituximab.[165] Additionally, monotherapy with the human IgGκ monoclonal anti-CD38 antibody daratumumab significantly improved proteinuria and stabilised kidney function in a series of patients with PGNMID.[166]

Patients with monoclonal immunotactoid glomerulopathy and an identifiable haematological disorder should be administered clone-directed therapy similar to in patients with PGNMID.[166–168] The kidney prognosis in these patients is favourable provided a complete haematological response is produced.[156,169] Although the treatment of clone-negative monoclonal immunotactoid glomerulopathy has not been established, rituximab is an attractive option, considering the high incidence of underlying B cell clones.[168,169] Patients with proteinuria in the subnephrotic range and healthy kidney function might benefit from a RAAS blockade alone. Immunotactoid glomerulopathy might recur in the kidney allograft, resulting in the loss of the allograft.[156,169]

Cryoglobulinaemic glomerulonephritis

Cryoglobulins are immunoglobulins that precipitate at cold temperatures and dissolve when rewarmed. Three types of cryoglobulins can be distinguished on the basis of the clonality and class of the immunoglobulin involved, each with particular disease associations (appendix p 2). Type 1 is a monoclonal immunoglobulin-associated kidney disease (typically IgG or IgM), usually seen in association with lymphoproliferative disorders as described earlier. Types 2 and 3 are referred to as mixed cryoglobulinaemias because they consist of both IgG and IgM components. Types 2 and 3 account for 85–90% of all cryoglobulinaemia cases.[170] Hepatitis C virus is the leading cause of mixed cryoglobulinemia worldwide. Other causes include autoimmune disease (eg, Sjögren syndrome), infections other than hepatitis C virus (eg, hepatitis B virus), and lymphoproliferative disorders.[171] The underlying causes of type 2 and 3 cryoglobulins overlap substantially. Approximately 45% of mixed cryoglobulinemia cases that are unrelated to hepatitis C virus are not associated with any known cause and are called essential cryoglobulinaemia.[172]

Clinical presentation

The clinical syndrome of cryoglobulinemia is caused by the deposition of immune complexes in the capillaries and arterioles with resultant end-organ damage. Kidney involvement occurs in 20–60% of patients and covers the entire spectrum of microscopic haematuria, subnephrotic range proteinuria, nephrotic syndrome, nephritic syndrome, severe hypertension, and rapidly progressive glomerulonephritis. Extrarenal manifestations most commonly occur with the mixed cryoglobulinaemias and include purpura, skin ulcers, arthralgias, peripheral neuropathy, and signs of myocardial ischaemia. C3 and particularly C4 concentrations are usually notably low. The cryocrit is the percentage of precipitated cryoglobulins in the total serum volume after centrifugation at 4°C (≥1% is abnormal). The components of the cryoprecipitate are established by electrophoresis and immunofixation.

Pathology

Cryoglobulinaemic glomerulonephritis shows an MPGN pattern with abundant infiltrating macrophages and intraluminal periodic acid–Schiff stain positive deposits (pseudothrombi) on light microscopy, intraluminal deposits of immunoglobulins, C3, and C1q on immunofluorescence, and many intraluminal and capillary wall deposits with substructures (microtubules, fibrils, curvilinear, and fingerprint) on electron microscopy. The immunoglobulins most often consist of IgM, and less commonly IgG. Deposits might sometimes be scant because of effective phagocytosis by macrophages.

Treatment

Patients with a rapidly progressive, organ-threatening or life-threatening cryoglobulinaemic syndrome, such as rapidly progressive glomerulonephritis, should be administered immunosuppressive therapy, regardless of the origin of the cryoglobulins,[171] using a short course of glucocorticoids combined with rituximab. If rituximab is unavailable or does not produce a response, cyclophosphamide can be used. After the kidney disease is stabilised, therapy should be directed at the underlying condition. Patients with hepatitis C infection but without decompensated cirrhosis should receive antiviral therapy. In mixed cryoglobulinemia secondary to HIV or hepatitis B, antiviral therapy should be initiated before or concomitantly with the immunosuppressive therapy, particularly rituximab. Patients with a lymphoproliferative disorder should receive disease-specific therapy. Patients

Descargado para Anonymous User (n/a) en University El Bosque de ClinicalKey.es por Elsevier en mayo 26, 2022. Para uso personal exclusivamente. No se permiten otros usos sin autorización. Copyright ©2022. Elsevier Inc. Todos los derechos reservados.

with life-threatening disease (eg, acute respiratory failure with pulmonary haemorrhage), cryoglobulinaemia-associated hyperviscosity syndrome, or a high cryocrit concentration (ie, ≥10%) should be administered plasma exchange in addition to immunosuppressive therapy.

Biopsy reporting of glomerulonephritis

Kidney biopsy findings are key to informing the diagnosis and management of glomerulonephritis and should be reported in a systematic manner.[3,5] First, the cause (primary diagnosis) of glomerulonephritis should be reported, such as infection-related glomerulonephritis, lupus nephritis, or fibrillary glomerulonephritis (all examples of immune-complex glomerulonephritis); ANCA-associated glomerulonephritis, anti-GBM glomerulonephritis, C3 glomerulonephritis, or dense deposit disease; or PGNMID, MIDD, or immunotactoid glomerulopathy (all examples of monoclonal Ig-associated glomerulonephritis). Second, the biopsy report should include the severity and pattern of injury; for example, diffuse proliferative glomerulonephritis, crescentic and necrotising glomerulonephritis, membranoproliferative glomerulonephritis, mesangial proliferative glomerulonephritis, or sclerosing glomerulonephritis. Multiple patterns of injury might be present in the same kidney biopsy. Third, the classification and grading of specific diseases (if present) should be given, such as the MEST-C score for IgA nephropathy or the International Society of Nephrology and Renal Pathology Society classification of lupus nephritis.[38,64] Fourth, additional findings related to the glomerulonephritis, such as acute tubular injury, or unrelated, such as diabetic glomerulosclerosis, should be listed. Finally, the extent of chronic changes should be graded since they have a bearing on the management and prognosis of the disease. The extent of glomerulosclerosis, interstitial fibrosis and tubular atrophy, and arteriosclerosis should be graded as minimal, mild, moderate, or severe using a systematic scoring system.[173]

Immunostaining and mass spectrometry

Since the immunostaining of the kidney biopsy is essential in unravelling the cause of glomerulonephritis, the importance of correct tissue preparation, interpretation, awareness of pitfalls, and smart use of ancillary techniques cannot be overstated. Immunofluorescence on frozen tissue is more sensitive and reliable than immunoperoxidase on formalin-fixed, paraffin-embedded tissue.[174]

Immunofluorescence on formalin-fixed, paraffin-embedded tissue is sometimes used as a salvage technique when fresh tissue is unavailable or not representative.[175] Because formalin fixation induces protein crosslinking, thus preventing the epitope binding of the diagnostic antibodies, an antigen-retrieval step is performed, often with the proteolytic enzyme pronase. Somewhat unexpectedly, this pronase digestion step appears to unmask immune complexes or monoclonal deposits that were not discovered by immunofluorescence staining on frozen tissue. As such, pronase digestion has become a valuable ancillary tool in difficult cases, particularly in the setting of Monoclonal Ig-mediated glomerular diseases or C3 glomerulopathy with a circulating Monoclonal Ig to enable the detection of masked Monoclonal Ig deposits.[147,175] IgG subtyping is another valuable ancillary technique to confirm the Monoclonal IgG subtype and is recommended in all patients with suspected Monoclonal Ig.[148]

Finally, C4d staining might aid the differential diagnosis of proliferative glomerulonephritis.[176] C4d is a split product of C4 activation and reveals activation of the classical or lectin complement pathways. A positive C4d staining serves as a marker for immune complex glomerulonephritis, whereas a negative C4d staining confirms the diagnosis of C3 glomerulonephritis with the exclusive activation of the alternative complement pathway. Bright C3 and positive C4d staining with negative routine immunofluorescence studies for immunoglobulins suggests the presence of masked immune deposits that might subsequently be revealed by pronase digestion.

Laser microdissection and mass spectrometry is a specialised technique that is helpful in unravelling the cause of glomerulonephritis by establishing the glomerular proteomic profile and identifying unique proteins that are the cause of the glomerulonephritis.[177,178]

Conclusion: moving from a pattern-based to a cause-based classification

The diagnostic evaluation and treatment of glomerulonephritis can be challenging. Many glomerulonephritis can manifest with more than one constellation of signs and symptoms, and show more than one histological pattern on a kidney biopsy. In addition, a particular clinical presentation or histological pattern can be caused by different underlying disease processes. Substantial progress has been made in unravelling the molecular causes of glomerular diseases. The causal approach to the classification of glomerulonephritis is progressively replacing the traditional pattern-based classification and will undoubtedly be expanded in the future. We state that a condition can be most accurately described by combining the different approaches. A few prototypical examples of informative classification are: C3 glomerulopathy with an MPGN pattern of injury caused by a complement factor H mutation, IgA-dominant infection-related glomerulonephritis with a diffuse exudative glomerulonephritis pattern of injury caused by *S aureus* endocarditis, and PGNMID with an MPGN pattern of injury caused by IgG3 κ monoclonal gammopathy of renal significance. This systematic approach provides clinicians with the essential information necessary to understand the underlying pathophysiology and direct treatment to the causative factors. A better understanding of the underlying mechanisms of disease has already resulted in substantial advances in the therapeutic approach to glomerulonephritis, with more targeted and individualised treatments being used. A collaborative effort of the

Descargado para Anonymous User (n/a) en University El Bosque de ClinicalKey.es por Elsevier en mayo 26, 2022. Para uso personal exclusivamente. No se permiten otros usos sin autorización. Copyright ©2022. Elsevier Inc. Todos los derechos reservados.

nephrological community to include patients in rationally designed therapeutic trials might further optimise the treatment of patients with glomerulonephritis.

Contributors

SS wrote the first draft of the manuscript. ASDV and FCF revised the introduction, examined the clinical presentation, wrote the treatment section, and added the sections on diagnosis and the conclusion. All authors reviewed the final version of the manuscript.

Declaration of interests

FCF received unrestricted research grants from Genentech, Hoffman La Roche, Janssen Pharmaceutical, Morphosys, and Retrophin; and consulting fees from Alexion Pharmaceuticals, Biocryst, Galapagos, GlaxoSmithKline, Novartis, Otsuka, and Takeda. All other authors declare no competing interests.

Acknowledgments

SS acknowledges the Department of Laboratory Medicine and Pathology at the Mayo Clinic for the INNOV award 2021.

References

1 Rovin BH, Adler SG, Barratt J, et al. Executive summary of the KDIGO 2021 Guideline for the Management of Glomerular Diseases. *Kidney Int* 2021; **100:** 753–79.
2 Sethi S. Etiology-based diagnostic approach to proliferative glomerulonephritis. *Am J Kidney Dis* 2014; **63:** 561–66.
3 Sethi S, Fervenza FC. Standardized classification and reporting of glomerulonephritis. *Nephrol Dial Transplant* 2019; **34:** 193–99.
4 Sethi S, Fervenza FC. Membranoproliferative glomerulonephritis--a new look at an old entity. *N Engl J Med* 2012; **366:** 1119–31.
5 Sethi S, Haas M, Markowitz GS, et al. Mayo clinic/renal pathology society consensus report on pathologic classification, diagnosis, and reporting of GN. *J Am Soc Nephrol* 2016; **27:** 1278–87.
6 Kalantar-Zadeh K, Rhee CM, Joshi S, Brown-Tortorici A, Kramer HM. Medical nutrition therapy using plant-focused low-protein meal plans for management of chronic kidney disease in diabetes. *Curr Opin Nephrol Hypertens* 2022; **31:** 26–35.
7 Kalantar-Zadeh K, Kam-Tao Li P, Tantisattamo E, et al. Living well with kidney disease by patient and care partner empowerment: kidney health for everyone everywhere. *J Ren Nutr* 2021; **31:** 554–59.
8 Nadasdy T, Hebert LA. Infection-related glomerulonephritis: understanding mechanisms. *Semin Nephrol* 2011; **31:** 369–75.
9 Satoskar AA, Parikh SV, Nadasdy T. Epidemiology, pathogenesis, treatment and outcomes of infection-associated glomerulonephritis. *Nat Rev Nephrol* 2020; **16:** 32–50.
10 Nasr SH, Radhakrishnan J, D'Agati VD. Bacterial infection-related glomerulonephritis in adults. *Kidney Int* 2013; **83:** 792–803.
11 Rodríguez-Iturbe B. Postinfectious glomerulonephritis. *Am J Kidney Dis* 2000; **35:** Xlvi–xlviii.
12 Satoskar AA, Suleiman S, Ayoub I, et al. Staphylococcus infection-associated GN - spectrum of IgA staining and prevalence of ANCA in a single-center cohort. *Clin J Am Soc Nephrol* 2017; **12:** 39–49.
13 Nasr SH, Markowitz GS, Stokes MB, Said SM, Valeri AM, D'Agati VD. Acute postinfectious glomerulonephritis in the modern era: experience with 86 adults and review of the literature. *Medicine (Baltimore)* 2008; **87:** 21–32.
14 Chauvet S, Berthaud R, Devriese M, et al. Anti-factor B antibodies and acute postinfectious GN in children. *J Am Soc Nephrol* 2020; **31:** 829–40.
15 Rodriguez-Iturbe B. Autoimmunity in acute poststreptococcal GN: a neglected aspect of the disease. *J Am Soc Nephrol* 2021; **32:** 534–42.
16 Baikunje S, Vankalakunti M, Nikith A, Srivatsa A, Alva S, Kamath J. Post-infectious glomerulonephritis with crescents in adults: a retrospective study. *Clin Kidney J* 2016; **9:** 222–26.
17 Ferrario F, Kourilsky O, Morel-Maroger L. Acute endocapillary glomerulonephritis in adults: a histologic and clinical comparison between patients with and without initial acute renal failure. *Clin Nephrol* 1983; **19:** 17–23.
18 Roy S 3rd, Murphy WM, Arant BS Jr. Poststreptococcal crescenteric glomerulonephritis in children: comparison of quintuple therapy versus supportive care. *J Pediatr* 1981; **98:** 403–10.
19 Sethi S, Fervenza FC, Zhang Y, et al. Atypical postinfectious glomerulonephritis is associated with abnormalities in the alternative pathway of complement. *Kidney Int* 2013; **83:** 293–99.
20 De Vriese AS, Sethi S, Van Praet J, Nath KA, Fervenza FC. Kidney disease caused by dysregulation of the complement alternative pathway: an etiologic approach. *J Am Soc Nephrol* 2015; **26:** 2917–29.
21 Angioi A, Fervenza FC, Sethi S, et al. Diagnosis of complement alternative pathway disorders. *Kidney Int* 2016; **89:** 278–88.
22 Nasr SH, Fidler ME, Valeri AM, et al. Postinfectious glomerulonephritis in the elderly. *J Am Soc Nephrol* 2011; **22:** 187–95.
23 Rajasekaran A, Julian BA, Rizk DV. IgA nephropathy: an interesting autoimmune kidney disease. *Am J Med Sci* 2021; **361:** 176–94.
24 Gutiérrez E, Carvaca-Fontán F, Luzardo L, Morales E, Alonso M, Praga M. A personalized update on IgA nephropathy: a new vision and new future challenges. *Nephron* 2020; **144:** 555–71.
25 Camilla R, Suzuki H, Daprà V, et al. Oxidative stress and galactose-deficient IgA1 as markers of progression in IgA nephropathy. *Clin J Am Soc Nephrol* 2011; **6:** 1903–11.
26 Feehally J, Barratt J. The genetics of IgA nephropathy: an overview from western countries. *Kidney Dis* 2015; **1:** 33–41.
27 Wyatt RJ, Julian BA. IgA nephropathy. *N Engl J Med* 2013; **368:** 2402–14.
28 Kincaid-Smith P, Bennett WM, Dowling JP, Ryan GB. Acute renal failure and tubular necrosis associated with hematuria due to glomerulonephritis. *Clin Nephrol* 1983; **19:** 206–10.
29 Abuelo JG, Esparza AR, Matarese RA, Endreny RG, Carvalho JS, Allegra SR. Crescentic IgA nephropathy. *Medicine (Baltimore)* 1984; **63:** 396–406.
30 Rodrigues JC, Haas M, Reich HN. IgA nephropathy. *Clin J Am Soc Nephrol* 2017; **12:** 677–86.
31 Cai Q, Shi S, Wang S, et al. Microangiopathic lesions in IgA nephropathy: a cohort study. *Am J Kidney Dis* 2019; **74:** 629–39.
32 Barbour SJ, Coppo R, Zhang H, et al. Evaluating a new international risk-prediction tool in IgA nephropathy. *JAMA Intern Med* 2019; **179:** 942–52.
33 Barbour SJ, Canney M, Coppo R, et al. Improving treatment decisions using personalized risk assessment from the international IgA nephropathy prediction tool. *Kidney Int* 2020; **98:** 1009–19.
34 Haas M, Verhave JC, Liu ZH, et al. A multicenter study of the predictive value of crescents in IgA nephropathy. *J Am Soc Nephrol* 2017; **28:** 691–701.
35 Bobart SA, Alexander MP, Shawwa K, et al. The association of microhematuria with mesangial hypercellularity, endocapillary hypercellularity, crescent score and renal outcomes in immunoglobulin A nephropathy. *Nephrol Dial Transplant* 2021; **36:** 840–47.
36 Sevillano AM, Gutiérrez E, Yuste C, et al. Remission of hematuria improves renal survival in IgA nephropathy. *J Am Soc Nephrol* 2017; **28:** 3089–99.
37 Davin JC, Coppo R. Henoch-Schönlein purpura nephritis in children. *Nat Rev Nephrol* 2014; **10:** 563–73.
38 Cattran DC, Coppo R, Cook HT, et al. The Oxford classification of IgA nephropathy: rationale, clinicopathological correlations, and classification. *Kidney Int* 2009; **76:** 534–45.
39 Roberts IS, Cook HT, Troyanov S, et al. The Oxford classification of IgA nephropathy: pathology definitions, correlations, and reproducibility. *Kidney Int* 2009; **76:** 546–56.
40 Praga M, Gutiérrez E, González E, Morales E, Hernández E. Treatment of IgA nephropathy with ACE inhibitors: a randomized and controlled trial. *J Am Soc Nephrol* 2003; **14:** 1578–83.
41 Wheeler DC, Toto RD, Stefánsson BV, et al. A pre-specified analysis of the DAPA-CKD trial demonstrates the effects of dapagliflozin on major adverse kidney events in patients with IgA nephropathy. *Kidney Int* 2021; **100:** 215–24.
42 Pozzi C, Andrulli S, Del Vecchio L, et al. Corticosteroid effectiveness in IgA nephropathy: long-term results of a randomized, controlled trial. *J Am Soc Nephrol* 2004; **15:** 157–63.
43 Tesar V, Troyanov S, Bellur S, et al. Corticosteroids in IgA nephropathy: a retrospective analysis from the VALIGA Study. *J Am Soc Nephrol* 2015; **26:** 2248–58.
44 Natale P, Palmer SC, Ruospo M, et al. Immunosuppressive agents for treating IgA nephropathy. *Cochrane Database Syst Rev* 2020; **3:** CD003965.

Descargado para Anonymous User (n/a) en University El Bosque de ClinicalKey.es por Elsevier en mayo 26, 2022. Para uso personal exclusivamente. No se permiten otros usos sin autorización. Copyright ©2022. Elsevier Inc. Todos los derechos reservados.

45 Rauen T, Eitner F, Fitzner C, et al. Intensive supportive care plus immunosuppression in IgA nephropathy. *N Engl J Med* 2015; **373:** 2225–36.

46 Schimpf JI, Klein T, Fitzner C, et al. Renal outcomes of STOP-IgAN trial patients in relation to baseline histology (MEST-C scores). *BMC Nephrol* 2018; **19:** 328.

47 Rauen T, Wied S, Fitzner C, et al. After ten years of follow-up, no difference between supportive care plus immunosuppression and supportive care alone in IgA nephropathy. *Kidney Int* 2020; **98:** 1044–52.

48 Zhang H, Lv JC, Wong MG, et al. TESTING: Therapeutic Evaluation of STeroids in IgA Nephropathy Global Study. American Society of Nephrology Kidney Week 2021; November 4–7 (abstr FR-OR61).

49 Wong MG, Lv J, Hladunewich MA, et al. The Therapeutic Evaluation of Steroids in IgA Nephropathy Global (TESTING) study: trial design and baseline characteristics. *Am J Nephrol* 2021; **52:** 827–36.

50 Fellström BC, Barratt J, Cook H, et al. Targeted-release budesonide versus placebo in patients with IgA nephropathy (NEFIGAN): a double-blind, randomised, placebo-controlled phase 2b trial. *Lancet* 2017; **389:** 2117–27.

51 Baraldi O, Comai G, Cuna V, et al. Mycophenolate mofetil: a possible alternative treatment for IgA nephropathy. *Contrib Nephrol* 2017; **190:** 108–16.

52 Tang SC, Tang AW, Wong SS, Leung JC, Ho YW, Lai KN. Long-term study of mycophenolate mofetil treatment in IgA nephropathy. *Kidney Int* 2010; **77:** 543–49.

53 Beckwith H, Medjeral-Thomas N, Galliford J, et al. Mycophenolate mofetil therapy in immunoglobulin A nephropathy: histological changes after treatment. *Nephrol Dial Transplant* 2017; **32** (suppl 1)**:** i123–28.

54 Ballardie FW, Roberts ISD. Controlled prospective trial of prednisolone and cytotoxics in progressive IgA nephropathy. *J Am Soc Nephrol* 2002; **13:** 142–48.

55 Lafayette RA, Canetta PA, Rovin BH, et al. A randomized, controlled trial of rituximab in IgA nephropathy with proteinuria and renal dysfunction. *J Am Soc Nephrol* 2017; **28:** 1306–13.

56 Maritati F, Fenoglio R, Pillebout E, et al. Brief report: rituximab for the treatment of adult-onset IgA vasculitis (Henoch-Schönlein). *Arthritis Rheumatol* 2018; **70:** 109–14.

57 Tumlin JA, Lohavichan V, Hennigar R. Crescentic, proliferative IgA nephropathy: clinical and histological response to methylprednisolone and intravenous cyclophosphamide. *Nephrol Dial Transplant* 2003; **18:** 1321–29.

58 Anders HJ, Saxena R, Zhao MH, Parodis I, Salmon JE, Mohan C. Lupus nephritis. *Nat Rev Dis Primers* 2020; **6:** 7.

59 Tamirou F, Houssiau FA. Management of lupus nephritis. *J Clin Med* 2021; **10:** 670.

60 Goulielmos GN, Zervou MI, Vazgiourakis VM, Ghodke-Puranik Y, Garyfallos A, Niewold TB. The genetics and molecular pathogenesis of systemic lupus erythematosus (SLE) in populations of different ancestry. *Gene* 2018; **668:** 59–72.

61 Munroe ME, James JA. Genetics of lupus nephritis: clinical implications. *Semin Nephrol* 2015; **35:** 396–409.

62 Tektonidou MG, Sotsiou F, Nakopoulou L, Vlachoyiannopoulos PG, Moutsopoulos HM. Antiphospholipid syndrome nephropathy in patients with systemic lupus erythematosus and antiphospholipid antibodies: prevalence, clinical associations, and long-term outcome. *Arthritis Rheum* 2004; **50:** 2569–79.

63 Weening JJ, D'Agati VD, Schwartz MM, et al. The classification of glomerulonephritis in systemic lupus erythematosus revisited. *J Am Soc Nephrol* 2004; **15:** 241–50.

64 Bajema IM, Wilhelmus S, Alpers CE, et al. Revision of the International Society of Nephrology/Renal Pathology Society classification for lupus nephritis: clarification of definitions, and modified National Institutes of Health activity and chronicity indices. *Kidney Int* 2018; **93:** 789–96.

65 Bomback AS, Markowitz GS. Lupus podocytopathy: a distinct entity. *Clin J Am Soc Nephrol* 2016; **11:** 547–48.

66 Fanouriakis A, Kostopoulou M, Cheema K, et al. 2019 update of the Joint European League Against Rheumatism and European Renal Association-European Dialysis and Transplant Association (EULAR/ERA-EDTA) recommendations for the management of lupus nephritis. *Ann Rheum Dis* 2020; **79:** 713–23.

67 Liu Z, Zhang H, Liu Z, et al. Multitarget therapy for induction treatment of lupus nephritis: a randomized trial. *Ann Intern Med* 2015; **162:** 18–26.

68 Rovin BH, Teng YKO, Ginzler EM, et al. Efficacy and safety of voclosporin versus placebo for lupus nephritis (AURORA 1): a double-blind, randomised, multicentre, placebo-controlled, phase 3 trial. *Lancet* 2021; **397:** 2070–80.

69 Furie R, Rovin BH, Houssiau F, et al. Two-year, randomized, controlled trial of belimumab in lupus nephritis. *N Engl J Med* 2020; **383:** 1117–28.

70 Mejia-Vilet JM, Malvar A, Arazi A, Rovin BH. The lupus nephritis management renaissance. *Kidney Int* 2022; **101:** 242–55.

71 Jennette JC, Falk RJ, Bacon PA, et al. 2012 revised International Chapel Hill Consensus Conference Nomenclature of Vasculitides. *Arthritis Rheum* 2013; **65:** 1–11.

72 Guillevin L, Durand-Gasselin B, Cevallos R, et al. Microscopic polyangiitis: clinical and laboratory findings in eighty-five patients. *Arthritis Rheum* 1999; **42:** 421–30.

73 Pearce FA, Craven A, Merkel PA, Luqmani RA, Watts RA. Global ethnic and geographic differences in the clinical presentations of anti-neutrophil cytoplasm antibody-associated vasculitis. *Rheumatology (Oxford)* 2017; **56:** 1962–69.

74 Monti S, Craven A, Klersy C, et al. Association between age at disease onset of anti-neutrophil cytoplasmic antibody-associated vasculitis and clinical presentation and short-term outcomes. *Rheumatology (Oxford)* 2021; **60:** 617–28.

75 Berti A, Cornec-Le Gall E, Cornec D, et al. Incidence, prevalence, mortality and chronic renal damage of anti-neutrophil cytoplasmic antibody-associated glomerulonephritis in a 20-year population-based cohort. *Nephrol Dial Transplant* 2019; **34:** 1508–17.

76 Jennette JC. Rapidly progressive crescentic glomerulonephritis. *Kidney Int* 2003; **63:** 1164–77.

77 Kitching AR, Anders HJ, Basu N, et al. ANCA-associated vasculitis. *Nat Rev Dis Primers* 2020; **6:** 71.

78 Sinico RA, Di Toma L, Radice A. Renal involvement in anti-neutrophil cytoplasmic autoantibody associated vasculitis. *Autoimmun Rev* 2013; **12:** 477–82.

79 Flossmann O, Berden A, de Groot K, et al. Long-term patient survival in ANCA-associated vasculitis. *Ann Rheum Dis* 2011; **70:** 488–94.

80 de Joode AA, Sanders JS, Stegeman CA. Renal survival in proteinase 3 and myeloperoxidase ANCA-associated systemic vasculitis. *Clin J Am Soc Nephrol* 2013; **8:** 1709–17.

81 Lionaki S, Blyth ER, Hogan SL, et al. Classification of antineutrophil cytoplasmic autoantibody vasculitides: the role of antineutrophil cytoplasmic autoantibody specificity for myeloperoxidase or proteinase 3 in disease recognition and prognosis. *Arthritis Rheum* 2012; **64:** 3452–62.

82 Sethi S, Zand L, De Vriese AS, et al. Complement activation in pauci-immune necrotizing and crescentic glomerulonephritis: results of a proteomic analysis. *Nephrol Dial Transplant* 2017; **32** (suppl 1)**:** i139–45.

83 Berden AE, Ferrario F, Hagen EC, et al. Histopathologic classification of ANCA-associated glomerulonephritis. *J Am Soc Nephrol* 2010; **21:** 1628–36.

84 Lee T, Gasim A, Derebail VK, et al. Predictors of treatment outcomes in ANCA-associated vasculitis with severe kidney failure. *Clin J Am Soc Nephrol* 2014; **9:** 905–13.

85 Stone JH, Merkel PA, Spiera R, et al. Rituximab versus cyclophosphamide for ANCA-associated vasculitis. *N Engl J Med* 2010; **363:** 221–32.

86 Specks U, Merkel PA, Seo P, et al. Efficacy of remission-induction regimens for ANCA-associated vasculitis. *N Engl J Med* 2013; **369:** 417–27.

87 Walsh M, Merkel PA, Peh CA, et al. Plasma exchange and glucocorticoids in severe ANCA-associated vasculitis. *N Engl J Med* 2020; **382:** 622–31.

88 de Groot K, Harper L, Jayne DR, et al. Pulse versus daily oral cyclophosphamide for induction of remission in antineutrophil cytoplasmic antibody-associated vasculitis: a randomized trial. *Ann Intern Med* 2009; **150:** 670–80.

89 Harper L, Morgan MD, Walsh M, et al. Pulse versus daily oral cyclophosphamide for induction of remission in ANCA-associated vasculitis: long-term follow-up. *Ann Rheum Dis* 2012; **71:** 955–60.

Descargado para Anonymous User (n/a) en University El Bosque de ClinicalKey.es por Elsevier en mayo 26, 2022. Para uso personal exclusivamente. No se permiten otros usos sin autorización. Copyright ©2022. Elsevier Inc. Todos los derechos reservados.

90 Jones RB, Tervaert JW, Hauser T, et al. Rituximab versus cyclophosphamide in ANCA-associated renal vasculitis. *N Engl J Med* 2010; **363:** 211–20.

91 Geetha D, Specks U, Stone JH, et al. Rituximab versus cyclophosphamide for ANCA-associated vasculitis with renal involvement. *J Am Soc Nephrol* 2015; **26:** 976–85.

92 Casal Moura M, Irazabal MV, Eirin A, et al. Efficacy of rituximab and plasma exchange in antineutrophil cytoplasmic antibody-associated vasculitis with severe kidney disease. *J Am Soc Nephrol* 2020; **31:** 2688–704.

93 Unizony S, Villarreal M, Miloslavsky EM, et al. Clinical outcomes of treatment of anti-neutrophil cytoplasmic antibody (ANCA)-associated vasculitis based on ANCA type. *Ann Rheum Dis* 2016; **75:** 1166–69.

94 Gulati K, Edwards H, Prendecki M, et al. Combination treatment with rituximab, low-dose cyclophosphamide and plasma exchange for severe antineutrophil cytoplasmic antibody-associated vasculitis. *Kidney Int* 2021; **100:** 1316–24.

95 Geetha D, Hruskova Z, Segelmark M, et al. Rituximab for treatment of severe renal disease in ANCA associated vasculitis. *J Nephrol* 2016; **29:** 195–201.

96 Silva F, Specks U, Kalra S, et al. Mycophenolate mofetil for induction and maintenance of remission in microscopic polyangiitis with mild to moderate renal involvement--a prospective, open-label pilot trial. *Clin J Am Soc Nephrol* 2010; **5:** 445–53.

97 Jones RB, Hiemstra TF, Ballarin J, et al. Mycophenolate mofetil versus cyclophosphamide for remission induction in ANCA-associated vasculitis: a randomised, non-inferiority trial. *Ann Rheum Dis* 2019; **78:** 399–405.

98 Jayne DRW, Merkel PA, Schall TJ, Bekker P. Avacopan for the treatment of ANCA-associated vasculitis. *N Engl J Med* 2021; **384:** 599–609.

99 De Vriese AS, Fervenza FC. PEXIVAS: the end of plasmapheresis for ANCA-associated vasculitis? *Clin J Am Soc Nephrol* 2021; **16:** 307–09.

100 Specks U, Fussner LA, Cartin-Ceba R, Casal Moura M, Zand L, Fervenza FC. Plasma exchange for the management of ANCA-associated vasculitis: the con position. *Nephrol Dial Transplant* 2021; **36:** 231–36.

101 Kronbichler A, Shin JI, Wang CS, Szpirt WM, Segelmark M, Tesar V. Plasma exchange in ANCA-associated vasculitis: the pro position. *Nephrol Dial Transplant* 2021; **36:** 227–31.

102 Walsh M, Collister D, Zeng L, et al. The effects of plasma exchange in patients with ANCA-associated vasculitis: an updated systematic review and meta-analysis. *BMJ* 2022; **376:** e064604.

103 Cornec D, Cornec-Le Gall E, Fervenza FC, Specks U. ANCA-associated vasculitis - clinical utility of using ANCA specificity to classify patients. *Nat Rev Rheumatol* 2016; **12:** 570–79.

104 Kemna MJ, Damoiseaux J, Austen J, et al. ANCA as a predictor of relapse: useful in patients with renal involvement but not in patients with nonrenal disease. *J Am Soc Nephrol* 2015; **26:** 537–42.

105 Guillevin L, Pagnoux C, Karras A, et al. Rituximab versus azathioprine for maintenance in ANCA-associated vasculitis. *N Engl J Med* 2014; **371:** 1771–80.

106 Charles P, Perrodeau É, Samson M, et al. Long-term rituximab use to maintain remission of antineutrophil cytoplasmic antibody-associated vasculitis: a randomized trial. *Ann Intern Med* 2020; **173:** 179–87.

107 Cartin-Ceba R, Golbin JM, Keogh KA, et al. Rituximab for remission induction and maintenance in refractory granulomatosis with polyangiitis (Wegener's): ten-year experience at a single center. *Arthritis Rheum* 2012; **64:** 3770–78.

108 Charles P, Terrier B, Perrodeau É, et al. Comparison of individually tailored versus fixed-schedule rituximab regimen to maintain ANCA-associated vasculitis remission: results of a multicentre, randomised controlled, phase III trial (MAINRITSAN2). *Ann Rheum Dis* 2018; **77:** 1143–49.

109 McAdoo SP, Pusey CD. Anti-glomerular basement membrane disease. *Clin J Am Soc Nephrol* 2017; **12:** 1162–72.

110 Saus J, Wieslander J, Langeveld JP, Quinones S, Hudson BG. Identification of the Goodpasture antigen as the alpha 3(IV) chain of collagen IV. *J Biol Chem* 1988; **263:** 13374–80.

111 Turner N, Mason PJ, Brown R, et al. Molecular cloning of the human Goodpasture antigen demonstrates it to be the alpha 3 chain of type IV collagen. *J Clin Invest* 1992; **89:** 592–601.

112 Fischer EG, Lager DJ. Anti-glomerular basement membrane glomerulonephritis: a morphologic study of 80 cases. *Am J Clin Pathol* 2006; **125:** 445–50.

113 Fervenza FC, Terreros D, Boutaud A, et al. Recurrent Goodpasture's disease due to a monoclonal IgA-kappa circulating antibody. *Am J Kidney Dis* 1999; **34:** 549–55.

114 Borza DB, Chedid MF, Colon S, Lager DJ, Leung N, Fervenza FC. Recurrent Goodpasture's disease secondary to a monoclonal IgA1-kappa antibody autoreactive with the alpha1/alpha2 chains of type IV collagen. *Am J Kidney Dis* 2005; **45:** 397–406.

115 Nasr SH, Collins AB, Alexander MP, et al. The clinicopathologic characteristics and outcome of atypical anti-glomerular basement membrane nephritis. *Kidney Int* 2016; **89:** 897–908.

116 Levy JB, Hammad T, Coulthart A, Dougan T, Pusey CD. Clinical features and outcome of patients with both ANCA and anti-GBM antibodies. *Kidney Int* 2004; **66:** 1535–40.

117 Rutgers A, Slot M, van Paassen P, van Breda Vriesman P, Heeringa P, Tervaert JWC. Coexistence of anti-glomerular basement membrane antibodies and myeloperoxidase-ANCAs in crescentic glomerulonephritis. *Am J Kidney Dis* 2005; **46:** 253–62.

118 Hellmark T, Niles JL, Collins AB, McCluskey RT, Brunmark C. Comparison of anti-GBM antibodies in sera with or without ANCA. *J Am Soc Nephrol* 1997; **8:** 376–85.

119 Olson SW, Arbogast CB, Baker TP, et al. Asymptomatic autoantibodies associate with future anti-glomerular basement membrane disease. *J Am Soc Nephrol* 2011; **22:** 1946–52.

120 McAdoo SP, Tanna A, Hrušková Z, et al. Patients double-seropositive for ANCA and anti-GBM antibodies have varied renal survival, frequency of relapse, and outcomes compared to single-seropositive patients. *Kidney Int* 2017; **92:** 693–702.

121 Henderson SR, Salama AD. Diagnostic and management challenges in Goodpasture's (anti-glomerular basement membrane) disease. *Nephrol Dial Transplant* 2018; **33:** 196–202.

122 Soveri I, Mölne J, Uhlin F, et al. The IgG-degrading enzyme of Streptococcus pyogenes causes rapid clearance of anti-glomerular basement membrane antibodies in patients with refractory anti-glomerular basement membrane disease. *Kidney Int* 2019; **96:** 1234–38.

123 Levy JB, Turner AN, Rees AJ, Pusey CD. Long-term outcome of anti-glomerular basement membrane antibody disease treated with plasma exchange and immunosuppression. *Ann Intern Med* 2001; **134:** 1033–42.

124 Lemaire M, Noone D, Lapeyraque AL, Licht C, Frémeaux-Bacchi V. Inherited kidney complement diseases. *Clin J Am Soc Nephrol* 2021; **16:** 942–56.

125 Ravindran A, Fervenza FC, Smith RJH, De Vriese AS, Sethi S. C3 glomerulopathy: ten years' experience at Mayo Clinic. *Mayo Clin Proc* 2018; **93:** 991–1008.

126 Servais A, Noël L-H, Roumenina LT, et al. Acquired and genetic complement abnormalities play a critical role in dense deposit disease and other C3 glomerulopathies. *Kidney Int* 2012; **82:** 454–64.

127 Appel GB, Cook HT, Hageman G, et al. Membranoproliferative glomerulonephritis type II (dense deposit disease): an update. *J Am Soc Nephrol* 2005; **16:** 1392–403.

128 Pickering MC, D'Agati VD, Nester CM, et al. C3 glomerulopathy: consensus report. *Kidney Int* 2013; **84:** 1079–89.

129 Bomback AS, Santoriello D, Avasare RS, et al. C3 glomerulonephritis and dense deposit disease share a similar disease course in a large United States cohort of patients with C3 glomerulopathy. *Kidney Int* 2018; **93:** 977–85.

130 Ravindran A, Fervenza FC, Smith RJH, Sethi S. C3 glomerulopathy associated with monoclonal Ig is a distinct subtype. *Kidney Int* 2018; **94:** 178–86.

131 Sethi S, Fervenza FC, Zhang Y, et al. C3 glomerulonephritis: clinicopathological findings, complement abnormalities, glomerular proteomic profile, treatment, and follow-up. *Kidney Int* 2012; **82:** 465–73.

132 Sethi S, Nester CM, Smith RJH. Membranoproliferative glomerulonephritis and C3 glomerulopathy: resolving the confusion. *Kidney Int* 2012; **81:** 434–41.

133 Sethi S, Vrana JA, Fervenza FC, et al. Characterization of C3 in C3 glomerulopathy. *Nephrol Dial Transplant* 2017; **32:** 459–65.

Descargado para Anonymous User (n/a) en University El Bosque de ClinicalKey.es por Elsevier en mayo 26, 2022. Para uso personal exclusivamente. No se permiten otros usos sin autorización. Copyright ©2022. Elsevier Inc. Todos los derechos reservados.

134 Goodship TH, Cook HT, Fakhouri F, et al. Atypical hemolytic uremic syndrome and C3 glomerulopathy: conclusions from a "Kidney Disease: Improving Global Outcomes" (KDIGO) controversies conference. *Kidney Int* 2017; **91:** 539–51.

135 Caravaca-Fontán F, Díaz-Encarnación MM, Lucientes L, et al. Mycophenolate mofetil in C3 glomerulopathy and pathogenic drivers of the disease. *Clin J Am Soc Nephrol* 2020; **15:** 1287–98.

136 Rabasco C, Cavero T, Román E, et al. Effectiveness of mycophenolate mofetil in C3 glomerulonephritis. *Kidney Int* 2015; **88:** 1153–60.

137 Caliskan Y, Torun ES, Tiryaki TO, et al. Immunosuppressive treatment in C3 glomerulopathy: is it really effective? *Am J Nephrol* 2017; **46:** 96–107.

138 Bomback AS, Smith RJ, Barile GR, et al. Eculizumab for dense deposit disease and C3 glomerulonephritis. *Clin J Am Soc Nephrol* 2012; **7:** 748–56.

139 Daina E, Noris M, Remuzzi G. Eculizumab in a patient with dense-deposit disease. *N Engl J Med* 2012; **366:** 1161–63.

140 Vivarelli M, Pasini A, Emma F. Eculizumab for the treatment of dense-deposit disease. *N Engl J Med* 2012; **366:** 1163–65.

141 Le Quintrec M, Lionet A, Kandel C, et al. Eculizumab for treatment of rapidly progressive C3 glomerulopathy. *Am J Kidney Dis* 2015; **65:** 484–89.

142 Gurkan S, Fyfe B, Weiss L, Xiao X, Zhang Y, Smith RJ. Eculizumab and recurrent C3 glomerulonephritis. *Pediatr Nephrol* 2013; **28:** 1975–81.

143 Le Quintrec M, Lapeyraque AL, Lionet A, et al. Patterns of clinical response to eculizumab in patients with C3 glomerulopathy. *Am J Kidney Dis* 2018; **72:** 84–92.

144 Smith RJH, Appel GB, Blom AM, et al. C3 glomerulopathy understanding a rare complement-driven renal disease. *Nat Rev Nephrol* 2019; **15:** 129–43.

145 Chen Q, Wiesener M, Eberhardt HU, et al. Complement factor H-related hybrid protein deregulates complement in dense deposit disease. *J Clin Invest* 2014; **124:** 145–55.

146 Zipfel PF, Wiech T, Rudnick R, Afonso S, Person F, Skerka C. Complement inhibitors in clinical trials for glomerular diseases. *Front Immunol* 2019; **10:** 2166.

147 Sethi S, Rajkumar SV, D'Agati VD. The complexity and heterogeneity of monoclonal immunoglobulin-associated renal diseases. *J Am Soc Nephrol* 2018; **29:** 1810–23.

148 Sethi S, Nast CC, D'Agati VD, et al. Standardized reporting of monoclonal immunoglobulin-associated renal diseases: recommendations from a Mayo Clinic/Renal Pathology Society Working Group. *Kidney Int* 2020; **98:** 310–13.

149 Ravindran A, Go RS, Fervenza FC, Sethi S. Thrombotic microangiopathy associated with monoclonal gammopathy. *Kidney Int* 2017; **91:** 691–98.

150 Kyle RA, Therneau TM, Rajkumar SV, et al. A long-term study of prognosis in monoclonal gammopathy of undetermined significance. *N Engl J Med* 2002; **346:** 564–69.

151 Kyle RA, Rajkumar SV. Criteria for diagnosis, staging, risk stratification and response assessment of multiple myeloma. *Leukemia* 2009; **23:** 3–9.

152 Merlini G, Stone MJ. Dangerous small B-cell clones. *Blood* 2006; **108:** 2520–30.

153 Bridoux F, Leung N, Hutchison CA, et al. Diagnosis of monoclonal gammopathy of renal significance. *Kidney Int* 2015; **87:** 698–711.

154 Klomjit N, Leung N, Fervenza F, Sethi S, Zand L. Rate and predictors of finding Monoclonal Gammopathy of Renal Significance (MGRS) lesions on kidney biopsy in patients with monoclonal gammopathy. *J Am Soc Nephrol* 2020; **31:** 2400–11.

155 Bhutani G, Nasr SH, Said SM, et al. Hematologic characteristics of proliferative glomerulonephritides with nonorganized monoclonal immunoglobulin deposits. *Mayo Clin Proc* 2015; **90:** 587–96.

156 Nasr SH, Kudose SS, Said SM, et al. Immunotactoid glomerulopathy is a rare entity with monoclonal and polyclonal variants. *Kidney Int* 2021; **99:** 410–20.

157 Nasr SH, Valeri AM, Cornell LD, et al. Renal monoclonal immunoglobulin deposition disease: a report of 64 patients from a single institution. *Clin J Am Soc Nephrol* 2012; **7:** 231–39.

158 Joly F, Cohen C, Javaugue V, et al. Randall-type monoclonal immunoglobulin deposition disease: novel insights from a nationwide cohort study. *Blood* 2019; **133:** 576–87.

159 Leung N, Lager DJ, Gertz MA, Wilson K, Kanakiriya S, Fervenza FC. Long-term outcome of renal transplantation in light-chain deposition disease. *Am J Kidney Dis* 2004; **43:** 147–53.

160 Nasr SH, Satoskar A, Markowitz GS, et al. Proliferative glomerulonephritis with monoclonal IgG deposits. *J Am Soc Nephrol* 2009; **20:** 2055–64.

161 Gumber R, Cohen JB, Palmer MB, et al. A clone-directed approach may improve diagnosis and treatment of proliferative glomerulonephritis with monoclonal immunoglobulin deposits. *Kidney Int* 2018; **94:** 199–205.

162 Chauvet S, Frémeaux-Bacchi V, Petitprez F, et al. Treatment of B-cell disorder improves renal outcome of patients with monoclonal gammopathy-associated C3 glomerulopathy. *Blood* 2017; **129:** 1437–47.

163 Guiard E, Karras A, Plaisier E, et al. Patterns of noncryoglobulinemic glomerulonephritis with monoclonal Ig deposits: correlation with IgG subclass and response to rituximab. *Clin J Am Soc Nephrol* 2011; **6:** 1609–16.

164 Said SM, Cosio FG, Valeri AM, et al. Proliferative glomerulonephritis with monoclonal immunoglobulin G deposits is associated with high rate of early recurrence in the allograft. *Kidney Int* 2018; **94:** 159–69.

165 Sethi S, Fervenza FC, Rajkumar SV. Spectrum of manifestations of monoclonal gammopathy-associated renal lesions. *Curr Opin Nephrol Hypertens* 2016; **25:** 127–37.

166 Zand L, Rajkumar SV, Leung N, Sethi S, El Ters M, Fervenza FC. Safety and efficacy of daratumumab in patients with proliferative GN with monoclonal immunoglobulin deposits. *J Am Soc Nephrol* 2021; **32:** 1163–73.

167 Fermand J-P, Bridoux F, Kyle RA, et al. How I treat monoclonal gammopathy of renal significance (MGRS). *Blood* 2013; **122:** 3583–90.

168 Hogan JJ, Vogl DT. Untangling immunotactoid glomerulopathy in the MGRS era. *Kidney Int* 2021; **99:** 303–05.

169 Javaugue V, Dufour-Nourigat L, Desport E, et al. Results of a nation-wide cohort study suggest favorable long-term outcomes of clone-targeted chemotherapy in immunotactoid glomerulopathy. *Kidney Int* 2021; **99:** 421–30.

170 Kolopp-Sarda MN, Nombel A, Miossec P. Cryoglobulins today: detection and immunologic characteristics of 1,675 positive samples from 13,439 patients obtained over six years. *Arthritis Rheumatol* 2019; **71:** 1904–12.

171 Roccatello D, Saadoun D, Ramos-Casals M, et al. Cryoglobulinaemia. *Nat Rev Dis Primers* 2018; **4:** 11.

172 Zaidan M, Terrier B, Pozdzik A, et al. Spectrum and prognosis of noninfectious renal mixed cryoglobulinemic GN. *J Am Soc Nephrol* 2016; **27:** 1213–24.

173 Sethi S, D'Agati VD, Nast CC, et al. A proposal for standardized grading of chronic changes in native kidney biopsy specimens. *Kidney Int* 2017; **91:** 787–89.

174 Bouatou Y, Kers J, Chevalier-Florquin MSN, et al. Diagnostic accuracy of immunofluorescence versus immunoperoxidase staining to distinguish immune complex-mediated glomerulonephritis and C3 dominant glomerulopathy. *Histopathology* 2018; **72:** 601–08.

175 Nasr SH, Fidler ME, Said SM. Paraffin immunofluorescence: a valuable ancillary technique in renal pathology. *Kidney Int Rep* 2018; **3:** 1260–66.

176 Sethi S, Nasr SH, De Vriese AS, Fervenza FC. C4d as a diagnostic tool in proliferative GN. *J Am Soc Nephrol* 2015; **26:** 2852–59.

177 Sethi S, Debiec H, Madden B, et al. Neural epidermal growth factor-like 1 protein (NELL-1) associated membranous nephropathy. *Kidney Int* 2020; **97:** 163–74.

178 Sethi S, Debiec H, Madden B, et al. Semaphorin 3B-associated membranous nephropathy is a distinct type of disease predominantly present in pediatric patients. *Kidney Int* 2020; **98:** 1253–64.

Copyright ©2022 Elsevier Ltd. All rights reserved.

Descargado para Anonymous User (n/a) en University El Bosque de ClinicalKey.es por Elsevier en mayo 26, 2022. Para uso personal exclusivamente. No se permiten otros usos sin autorización. Copyright ©2022. Elsevier Inc. Todos los derechos reservados.