UNIT EIGHT

Management of Patient with Musculoskeletal System Disorders

By
Zinabu D

LEARNING OBJECTIVES

On completion of this session, the students will be able to:

- Describe the basic structure and function of the MSS.
- Discuss the significance of the health history to the assessment of MS health.
- Describe the significance of physical assessment to the diagnosis of MS dysfunction.
- Specify the diagnostic tests used for assessment of

Anatomic and Physiologic Overview of mss

Anatomic and Physiologic Overview

The musculoskeletal system includes:

- Bones,
- Joints,
- Muscles,
- Tendons,
- Ligaments, and
- Bursae of the body.

Anatomic and Physiologic Overview

The problems associated with these structures are common and affect all age groups.

Problems with the musculoskeletal system are generally not life-threatening, but they have a significant effect on the patient's normal activities and productivity.

FUNCTIONS OF MSS

The Musculoskeletal system provides:

- à Protection for vital organs, including the brain, heart, and lungs.
- à Support body structures.
- à Makes mobility possible
- à Bone matrix stores calcium, phosphorus, magnesium, and fluoride.

STRUCTURE AND FUNCTION OF THE SKELETAL SYSTEM

- Bone is composed of cells, protein matrix, and mineral deposits.
- The cells are of three basic types—**osteoblasts, osteocytes,** and **osteoclasts.**
- *Osteoblasts* function in bone formation by secreting bone matrix.

Con’t…

- ***Osteocytes*** are mature bone cells involved in bone-maintenance functions; they are located in **lacunae** (bone matrix units).
- ***Osteoclasts,*** located in shallow Howship’s lacunae (small pits in bones), are multinuclear cells involved in destroying, resorbing, and remolding bone.

Con’t…

- The microscopic functioning unit of mature cortical bone is the **osteon** (Haversian system).
- The center of the osteon, the Haversian canal, contains a capillary.
- Around the capillary are circles of mineralized bone matrix called **lamellae**.

Con’t…

There are 206 bones in the human body, divided into four categories:

- Long bones (e.g, femur)
- Short bones (e.g, metacarpals)
- Flat bones (e.g, sternum)
- Irregular bones (e.g, vertebrae)

- Bones are constructed of cancellous(trabecular) or cortical(compact) bone tissue.
- The shaft, known as the diaphysis,is primarily cortical bone.
- The ends of the long bones, called epiphyses, are primarily cancellous bone.

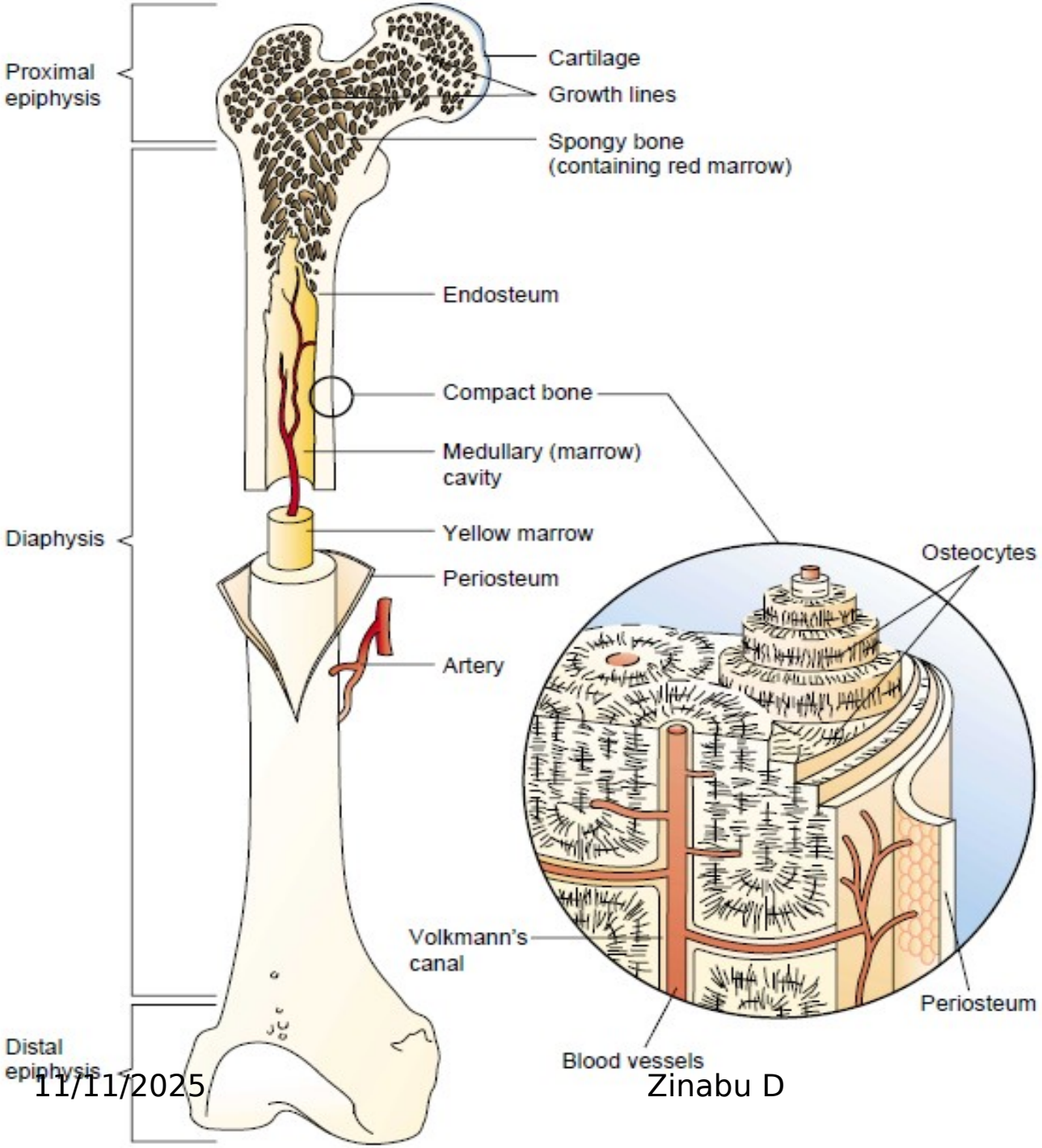

FIGURE 66-1 Structure of a long bone; composition of compact bone.

STRUCTURE AND FUNCTION OF THE ARTICULAR SYSTEM

- The junction of two or more bones is called a **joint** (articulation).
- There are three basic kinds of joints:
  - Synarthrosis(immovable),
  - Amphiarthrosis(partially movable) (pelvic bones), or, and
  - Diarthrosis joints (freely movable).

STRUCTURE AND FUNCTION OF THE ARTICULAR SYSTEM

- **Synarthrosis** joints are immovable, as exemplified by the skull sutures.
- **Amphiarthrosis** joints, such as the vertebral joints and the symphysis pubis, allow limited motion.
- The bones of amphiarthrosis joints are joined by fibrous cartilage. E.g. Vertebral bodies of the spine
- **Diarthrosis** joints are freely movable joints. E.g. Knee, shoulder

STRUCTURE AND FUNCTION OF THE ARTICULAR SYSTEM

There are several types of diarthrosis joints:

- **Ball-and-socket joints,** best exemplified by the hip and the shoulder, permit full freedom of movement.
- **Hinge joints** permit bending in one direction only and are best exemplified by the elbow and the knee.
- **Saddle joints** allow movement in two planes.

STRUCTURE AND FUNCTION OF THE SKELETAL MUSCLE SYSTEM

- Muscles are attached by **tendons** (cords of fibrous connective tissue) or aponeuroses (broad, flat sheets of connective tissue) to bones, connective tissue, other muscles, soft tissue, or skin.
- The muscles of the body are composed of parallel groups of muscle cells (fasciculi) encased in fibrous tissue called **fascia** or **epimysium**.

STRUCTURE AND FUNCTION OF THE SKELETAL MUSCLE SYSTEM

- The more fasciculi contained in a muscle, the more precise the movements.
- Muscles vary in shape and size according to the activities for which they are responsible.
- Skeletal (striated) muscles are involved in body movement, posture, and heat-production functions.

STRUCTURE AND FUNCTION OF THE SKELETAL MUSCLE SYSTEM

There are three types of muscles:

- Skeletal(striated) muscles (e.g. Muscles of thigh and arms)
- Cadiac (semi-striated) musles (e.g. Muscles of heart)
- Smooth (non-striated) muscles (muscles of internal organs like intestines, uterus, bladder,...)

assessment OF MUSCULOSKELETAL SYSTEM

COMMON TERMINOLOGIES

- **Atrophy:** shrinkage like decrease in the size of a muscle.
- **Clonus:** rhythmic contraction of muscle
- **Contracture:** abnormal shortening of muscle or joint, or both.
- **Crepitus:** grating or crackling sound or sensation; may occur with movement of ends of a broken bone or irregular joint surface.

- **Fasciculation:** involuntary twitch of muscle fibers
- **Flaccid**: limp; without muscle tone
- **Spastic:** having greater-than-normal muscle tone
- **Tone (tonus):** normal tension (resistance

ASSESSMENT

Health history

- ✓ Assessment of the patient with MSS dysfunction includes an evaluation of the effects of the MSS disorder on the patient.
- ✓ The patient with a MSS disorder may report pain, tenderness, tightness, and abnormal sensations.

PAIN

- Most patients with diseases and traumatic conditions or disorders of muscles, bones, and joints experience pain.
- Bone pain is characteristically described as a dull, deep ache that is “boring” in nature, whereas **muscular pain** is described as soreness or aching and is referred to as

- Fracture pain is sharp and piercing and is relieved by immobilization.
- Sharp pain may also result from bone infection with muscle spasm or pressure on a sensory nerve.

ALTERED SENSATIONS

- A patient having sensory altered sensation characterized by the following features: **paresthesias**, which are burning, tingling sensations or numbness.
- These sensations may be caused by pressure on nerves or by circulatory impairment.
- Soft tissue swelling or direct trauma to these structures can impair their function.

PHYSICAL ASSESSMENT/EXAMINATION

Inspection and palpation of MSS are used to evaluate the patient's:

- Posture, gait, bone integrity, joint function, and muscle strength and size
- Skin and neurovascular status

Diagnostic Evaluation IMAGING PROCEDURES

X-ray Studies

- ☑ Bone x-rays determine bone density, texture, erosion, and changes in bone relationships.
- ☑ X-ray study of the cortex of the bone reveals any widening, narrowing, or signs of irregularity.
- ☑ Joint x-rays reveal fluid, irregularity, narrowing, and changes in the joint structure

Computed Tomography

- CT scan shows in detail a specific plane of involved bone and can reveal tumors of the soft tissue or injuries to the ligaments or tendons.
- It is used to identify the location and extent of fractures in areas that are difficult to evaluate (e.g., acetabulum).

Magnetic Resonance Imaging (MRI)

- MRI uses tumors or narrowing of soft tissues such as muscle, tendon, cartilage, nerve, and fat.
- Because an electromagnet is used, patients with any metal implants, clips, or pacemakers are not candidates for MRI.

Bone Scan

- is performed to detect metastatic and primary bone tumors, osteomyelitis, certain fractures, and aseptic necrosis.
- A bone-seeking radioisotope is injected intravenously.
- The scan is performed 2 to 3 hours after the injection.
- Bone scan is contraindicated in pregnant

Arthroscopy

- Is a procedure that allows direct visualization of a joint to diagnose joint disorders.
- The procedure is carried out in the operating room under sterile conditions; injection of a local anesthetic into the joint or general anesthesia is used.
- A large-bore needle is inserted, and the joint is distended with saline.

- **Arthrocentesis**(joint aspiration) is carried out to obtain synovial fluid for purposes of examination or to relieve pain due to effusion(excessive fluid within the capsule).
- **Biopsy:** performed to determine the structure and composition of bone marrow, bone, muscle, or synovium to help diagnose specific diseases.

Electromyography

- Provides information about the electrical potential of the muscles and the nerves leading to them.
- The test is performed to evaluate muscle weakness, pain, and disability.
- Needle electrodes are inserted into selected muscles, and responses to electrical stimuli are recorded on an oscilloscope.

Blood Chemistry

- Serum calcium levels are altered in patients with osteomalacia, parathyroid function, Paget's disease, metastatic bone tumors, or prolonged immobilization.
- Serum phosphorus levels are diminished in osteomalacia associated with malabsorption syndrome.

- Acid phosphatase is elevated in Paget’s disease and metastatic cancer.
- Alkaline phosphatase is elevated during early fracture healing and in diseases with increased osteoblastic activity (e.g., metastatic bone tumors).

Lab investigations:

- Serum
  - calcium (NV: 9-10.5 mg/dl)
- * se Bone cancers, *multiple myeloma*
- * ses-in Rickets, V_D deficiency
- b. ALP (Alkaline phosphatase)-(NV=30-85 ImU/ml)
- * Bone tumers, #, rickets -se ALP
- c. Phosphorus (NV = 2.5-4.5 mg/dl) * Conditions that se calcium level will se serum phos
- phatase.
- d. ESR – (NV: men <15mm/ 1hr
- Women < 20 mm/hr)
- * Inflammatory processes se ESR
- e. HCt (NV=M: 45%-52%)
- F: /37%-48%/)

Trauma and Soft Tissue Injuries

Contusions, Strains, and Sprains

LEARNING OBJECTIVES

On completion of this session, the students will be able to:

- Differentiate between contusions, strains, sprains,
- Identify the difference between dislocations, and subluxations
- Describe the treatment procedures of fracture reduction, fracture immobilization, and management of open fractures.

Contusions, Strains, and Sprains

Contusion: is a soft tissue injury produced by blunt force, such as a blow, kick, or fall causing small blood vessels rupture and bleed into soft tissues (ecchymosis, or bruising).

- A hematoma develops when the bleeding is sufficient to cause an appreciable collection of blood.

- Local symptoms (pain, swelling, and discoloration) are controlled with intermittent application of cold.
- Most contusions resolve in 1 to 2

Strain: is a “muscle pull” caused by overuse, overstretching, or excessive stress.

- Strains are microscopic, incomplete muscle tears with some bleeding into the tissue.
- The patient experiences soreness or sudden pain, with local tenderness on

Sprain: is an injury to the ligaments surrounding a joint that is caused by a wrenching or twisting motion.

- A torn ligament loses its stabilizing ability.
- Blood vessels rupture and edema occurs; the joint is tender, and movement of the joint becomes

- The degree of disability and pain increases during the first 2 to 3 hours after the injury because of the associated swelling and bleeding.
- An x-ray should be obtained to rule out bone injury.
- Avulsion fracture (in which a bone fragmented is pulled away by a ligament or tendon) may be associated with a sprain.

Management

- Treatment of contusions, strains, and sprains consists of resting and elevating the affected part, applying cold, and using a compression bandage.
- (The acronym **RICE** *R*est, *I*ce, *C*ompression, *E*levation—is helpful for remembering treatment interventions.)

Management

- Rest prevents additional injury and promotes healing.
- Moist or dry cold applied intermittently for 20 to 30 minutes during the first 24 to 48 hours after injury produces vasoconstriction, which decreases bleeding, edema, and discomfort.

- An elastic compression bandage controls bleeding, reduces edema, and provides support for the injured tissues.
- Elevation controls the swelling.
- If the sprain is severe (torn muscle fibers and disrupted ligaments), surgical repair or cast immobilization

Joint Dislocations

- A dislocation of a joint is a condition in which the articular surfaces of the bones forming the joint are no longer in anatomic contact.
- The bones are literally “out of joint.”
- A **subluxation** is a partial dislocation of the articulating surfaces.

- Traumatic dislocations are orthopedic emergencies because the associated joint structures, blood supply, and nerves are distorted and severely stressed.
- If the dislocation is not treated on time, avascular necrosis (tissue death due to anoxia and diminished blood supply) and nerve palsy may occur.

Dislocations may be:

- Congenital, or present at birth (most often the hip);
- Spontaneous or pathologic, caused by disease of the articular or periarticular structures; or
- Traumatic, resulting from injury in which the joint is disrupted by force.

CLINICAL MANIFESTATION

A traumatic dislocation are:

- Pain,
- Change in contour of the joint,
- Change in the length of the extremity,
- Loss of normal mobility, and
- Change in the axis of the dislocated bones.

Medical Management

- The dislocation is rapidly reduced (i.e., displaced parts are brought into normal position) to preserve joint function.
- Analgesia, muscle relaxants, and possibly anesthesia are used to facilitate closed reduction.
- The joint is immobilized by bandages, splints, casts, or traction and is maintained in a stable position.

Medical Management

- After reduction, if the joint is stable, gentle, progressive, active and passive movement is begun to preserve range of motion (ROM) and restore strength.
- The joint is supported between exercise sessions.

Fractures

- A fracture is a break in the continuity of bone.
- Occur when the bone is subjected to stress greater than it can absorb.
- Caused by direct blows, crushing forces, sudden twisting motions, and even extreme muscle contractions.

- When the bone is broken, adjacent structures are also affected,
- Resulting in soft tissue edema, hemorrhage into the muscles and joints, joint dislocations, ruptured tendons, severed nerves, and damaged blood vessels.
- Body organs may be injured by the force that caused the fracture or by the fracture fragments.

Types of Fractures

Based on cross-section of the bone involved:

1. **Complete fracture:** involves a break across the entire cross-section of the bone and is frequently displaced (removed from normal position).
2. **Incomplete fracture** (e.g., greenstick fracture): the break occurs through only part of the cross-section of the bone.
3. **Comminuted fracture:** is one that produces several bone fragments.

Based on involvement of the skin:

1. Closed fracture (simple fracture): is one that does not cause a break in the skin.

2. Open fracture (compound, or complex, fracture): is one in which the skin or mucous membrane wound extends to the fractured bone.

Open fractures are graded according to the following criteria:

Grade I: is a clean wound less than 1 cm long.

Grade II: is a larger wound without extensive soft tissue damage.

Grade III: is highly contaminated, has extensive soft tissue damage, and is the most severe.

- Fractures may also be described according to the anatomic placement of fragments, particularly if they are displaced or non displaced.

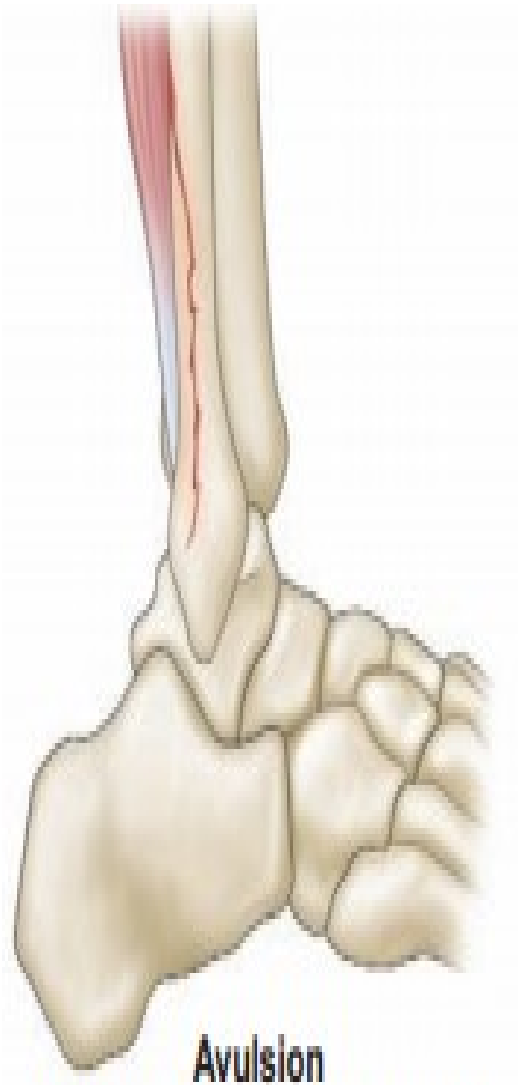

Avulsion

A fracture in which a fragment of bone has been pulled away by a tendon and its attachment



Comminuted

A fracture in which bone has splintered into several fragments

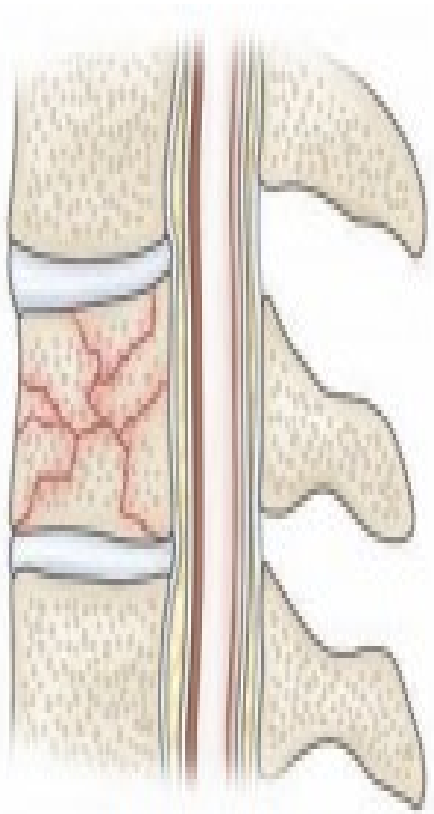

Compression

A fracture in which bone has been compressed (seen in vertebral fractures)



bone has been pulled away by a tendon and its attachment

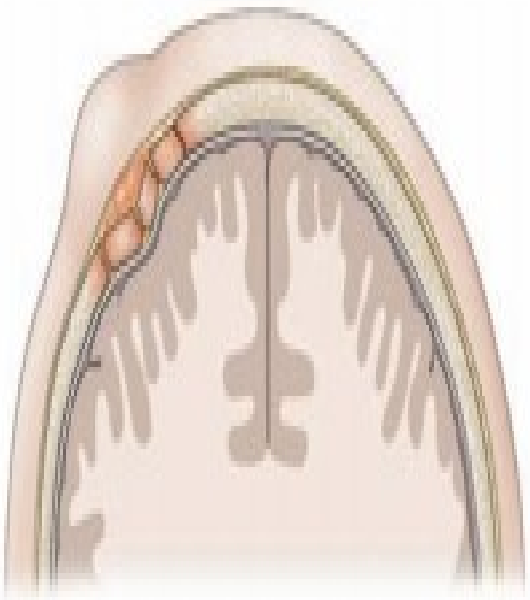

Depressed

A fracture in which fragments are driven inward (seen frequently in fractures of skull and facial bones)



Epiphyseal

A fracture through the epiphysis



Greenstick

A fracture in which one side of a bone is broken and the other side is bent

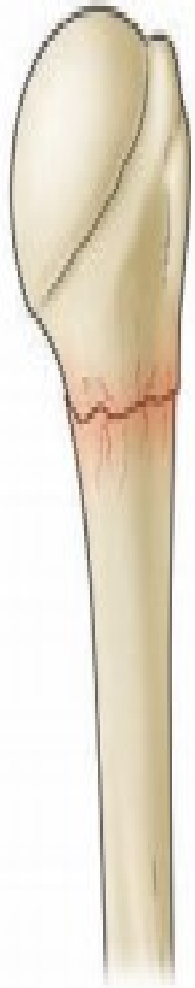

Impacted

A fracture in which a bone fragment is driven into another bone fragment

and the other side is bent

another bone fragment



Oblique

A fracture occurring at an angle across the bone (less stable than a transverse fracture)

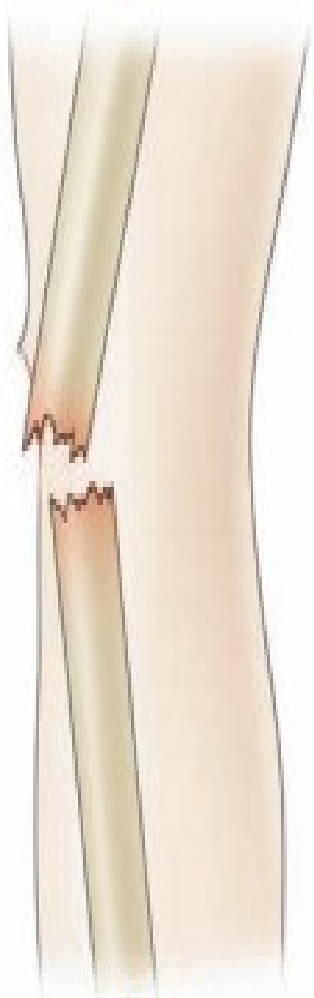

Open

A fracture in which damage also involves the skin or mucous membranes, also called a compound fracture

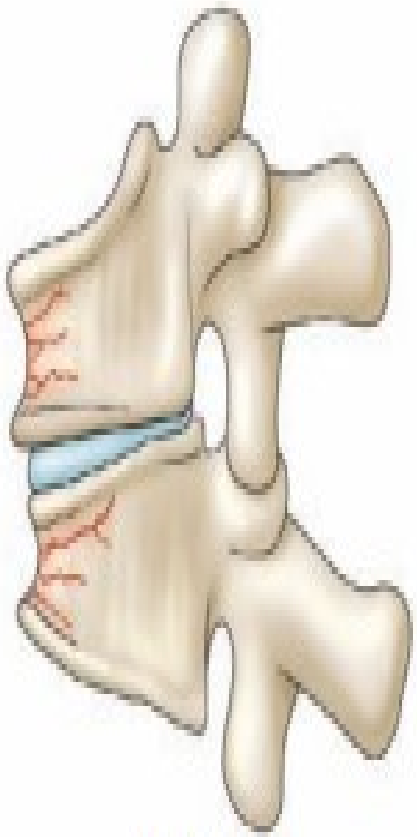

Pathologic

A fracture that occurs through an area of diseased bone (eg, osteoporosis, bone cyst, Paget's disease, bony metastasis, tumor); can occur without trauma or fall

occur without trauma or fall

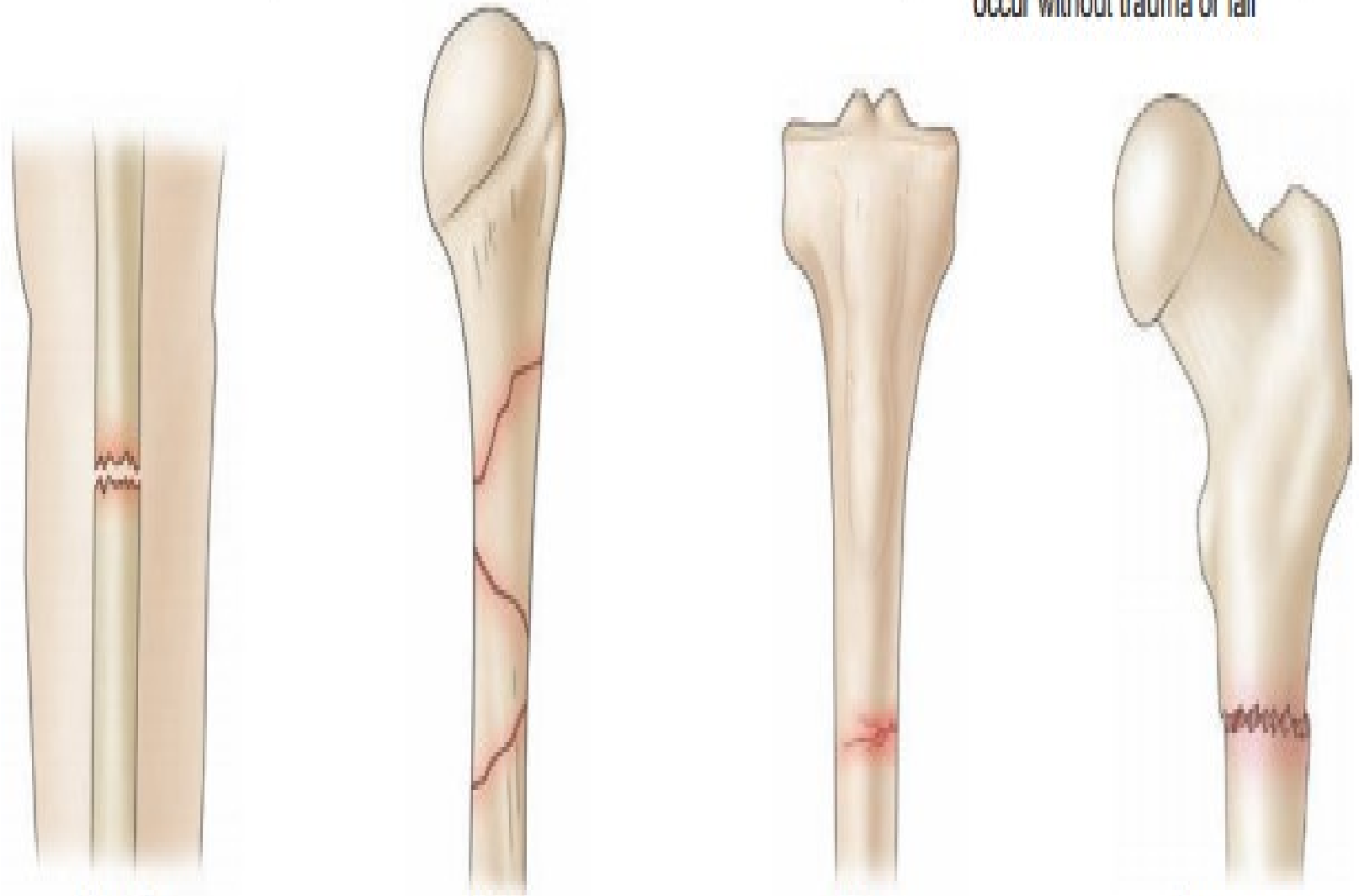

Simple
A fracture that remains contained, with no disruption of the skin integrity

Spiral
A fracture that twists around the shaft of the bone

Stress
A fracture that results from repeated loading of bone and muscle

Transverse
A fracture that is straight across the bone shaft

Fig. showing types of fracture

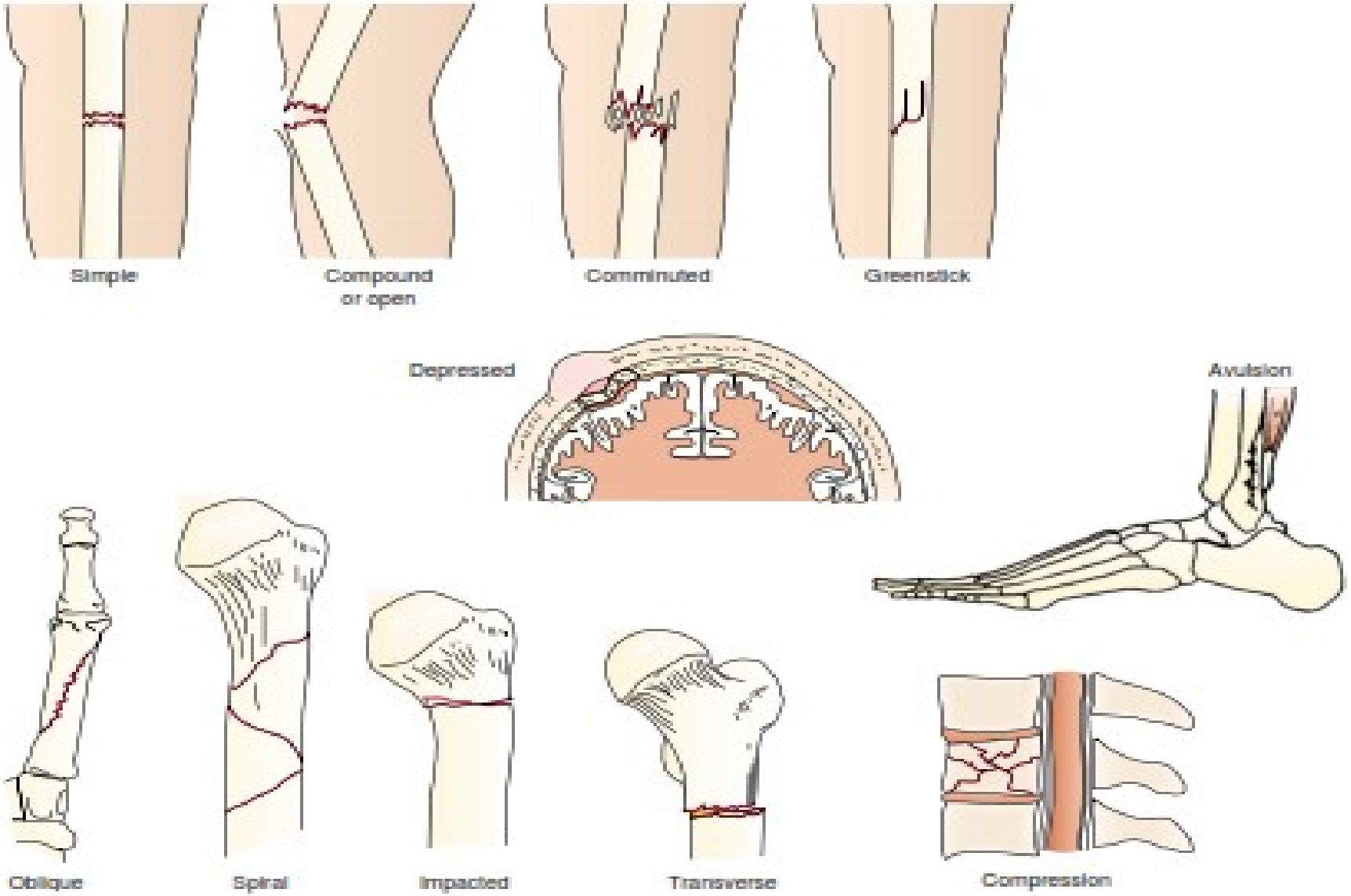

Fig. showing types of fracture

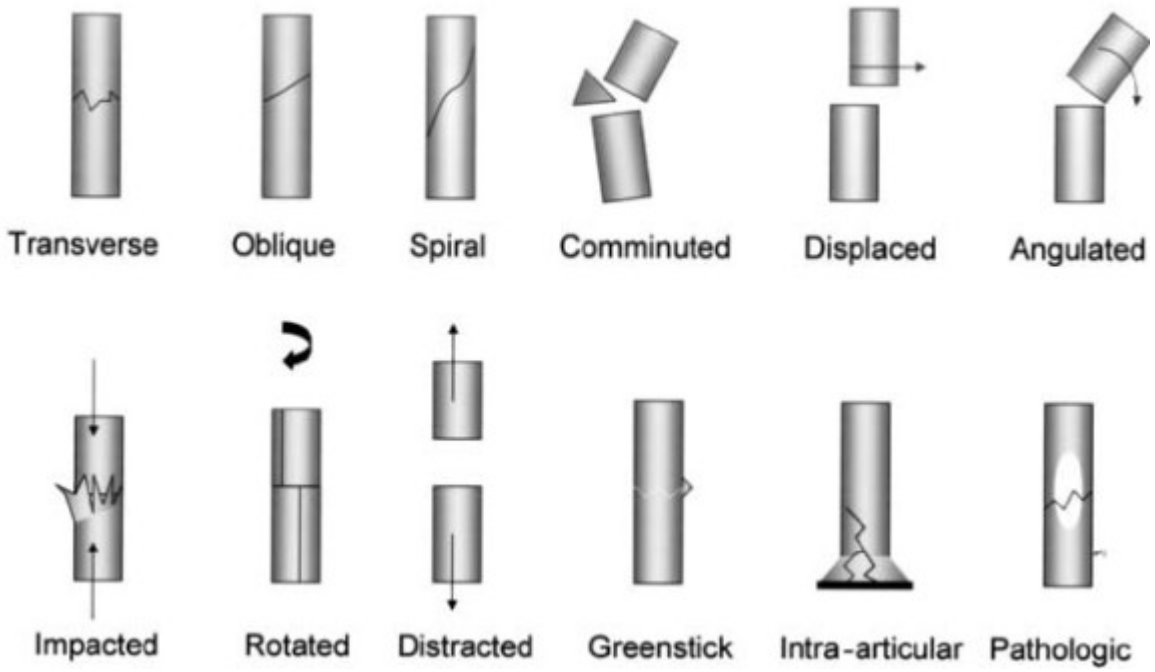

Clinical Manifestations

- Pain,
- Loss of function,
- Deformity,
- Shortening of the extremity,
- Crepitus (a grating sensation palpation), and
- Local swelling and discoloration.

- Not all of these clinical manifestations are present in every fracture.

Emergency Management of Fractures

- Immediately after injury, whenever a fracture is suspected, it is important to immobilize the body part before the patient is moved.
- If an injured patient must be removed from a vehicle before splints can be applied,
- The extremity is supported above and below the fracture site to prevent rotation as well as angular motion.

- With an open fracture, the wound is covered with a clean (sterile) dressing to prevent contamination of deeper tissues.
- No attempt is made to reduce the fracture, even if one of the bone fragments is protruding through the wound.
- Splints are applied for immobilization.

REDUCTION

- Reduction refers to restoration of the fracture fragments to anatomic alignment and rotation.

- **Closed Reduction:** is accomplished by bringing the bone fragments into a position (i.e., placing the ends in contact) through manipulation and manual traction.

Open Reduction

- Through *a surgical* approach, the fracture fragments are reduced.
- *Internal fixation devices* (metallic pins, wires, screws, plates, nails, or rods) may be used to hold the bone fragments in position

IMMOBILIZATION

After the fracture has been reduced,

- The bone fragments must be immobilized, or held in correct position and alignment, until union occurs.
- Immobilization may be accomplished by external or internal fixation.

MAINTAINING AND RESTORING FUNCTION

- Reduction and immobilization are maintained as prescribed to promote bone and soft tissue healing.
- Swelling is controlled by elevating the injured extremity and applying ice as prescribed.

- Neurovascular status (circulation, movement, sensation) is monitored, and the orthopedic surgeon is notified immediately if signs of neurovascular compromise are identified.

Complications of Fracture

Early complications include:

- Shock, Fat embolism,
- Compartment syndrome,
- Deep vein thrombosis,
- Thromboembolism (pulmonary embolism),
- Disseminated intravascular coagulopathy (DIC), and
- Infection.

Delayed complications

- Delayed union and nonunion,
- Avascular necrosis of bone,
- Reaction to internal fixation devices,
- Complex regional pain syndrome, and
- Heterotrophic ossification.

JOINT AND CONNECTIVE TISSUE DISORDERS

Degenerative Joint Disease(Osteoarthritis)

- OA, also known as degenerative joint disease or osteoarthrosis, is the most common and frequently disabling of the joint disorders.

CON'T…

- OA has been classified as *primary (idiopathic)*, with no prior event or disease related to the OA, and *secondary*, resulting from previous joint injury or inflammatory disease.
- The distinction between primary and secondary OA is not always clear.

CON'T…

- OA often begins in the third decade of life and peaks between the fifth and sixth decades.
- By age 75 years, 85% of the population has either x-ray or clinical evidence of OA, but only 15% to 25% of these people experience significant symptoms.

Risk factors

- Increased age
- Obesity
- Previous joint damage
- Repetitive use (occupational and recreational)
- Anatomic deformity
- Genetic susceptibility

Clinical Manifestations

- The primary clinical manifestations of OA are pain, stiffness, and functional impairment.
- **Stiffness,** which is most commonly experienced in the morning or after awakening, usually lasts less than 30 minutes and decreases with movement.
- **Functional impairment** is due to pain on movement and limited motion caused by structural changes in the joints.

Degenerative Joint Disease (Osteoarthritis)

- Characteristic *bony nodes* may be present; on inspection and palpation, these are usually painless, unless inflammation is present.
- *Tender and enlarged joints* are common.

Medical Management

- Although *no treatment* halts the degenerative process, certain preventive measures can slow the progress if undertaken early enough.
- These include weight reduction, prevention of injuries, perinatal screening for congenital hip disease,

Medical Management

Conservative treatment measures include:

- The use of heat, Weight reduction,
- Joint rest and avoidance of joint overuse,
- Orthotic devices to support inflamed joints (splints, braces),
- Isometric and postural exercises, and
- Aerobic exercise.

PHARMACOLOGIC THERAPY

- Pharmacologic management of OA is directed toward *symptom management* and *pain control*.
- Medications are used in conjunction with non pharmacologic strategies;
  - Acetaminophen.
  - nonselective NSAIDs,

- COX-2 inhibitors (cyclo-oxygenase-inflamatory enzyme).
- Opioids and
- Intra-articular corticosteroids

SURGICAL MANAGEMENT

Procedures most commonly used are:

- Osteotomy- to alter the force distribution in the joint and
- Arthroplasty- diseased joint components are replaced with artificial products.

SURGICAL MANAGEMENT

- Viscosupplimentation- the reconstitution of synovial fluid viscosity.
- Hyaluronic acid, that acts as a lubricant and shock absorbing fluid in the joint, may be used in this procedure.
- Tidal irrigation/ (lavage) of the knee- introduction and then removal of a large volume of saline into the joint through cannulas.

RHEUMATOID ARTHRITIS (RA)

- RA is commonly used as the prototype for inflammatory arthritis.
- The incidence rate is approximately 3%, with a 2-3 times greater incidence in women.
- In RA, the autoimmune reaction primarily occurs in the synovial tissue.
- Phagocytosis produces enzymes within the joint.

Rheumatoid Arthritis (RA)

- The enzymes break down collagen, causing edema, proliferation of the synovial membrane, and ultimately pannus formation. Pannus destroys cartilage and erode the bone.
- Loss of articular surfaces and joint motion.
- Muscle fibers undergo degenerative changes.
- Tendon and ligament elasticity and contractile power are lost.

Clinical Manifestations

Joint pain, swelling, warmth, erythema, joint stiffness and *lack of function* are classic.

Palpation of the joints reveals spongy or boggy tissue.

Often fluid can be aspirated from the inflamed joint.

Clinical Manifestations

- the pattern of joint involvement begins with the small joints in the hands, wrists, and feet.
- As the disease progresses, the knees, shoulders, hips, elbows, ankles, cervical spine, and temporomandibular joints are involved.

- The onset of symptoms is usually acute,

Clinical Manifestations

- *Joint stiffness*, especially in the morning, lasting for more than 30 minutes.
- Deformities of the hands and feet are common in RA.
- RA is a systemic disease with multiple extra-articular features.
- Most common are *fever, weight loss, fatigue, anemia, lymph node enlargement, Raynaud's phenomenon ect*

Medical Management

EARLY-STAGE RA

Begins with education, a balance of rest and exercise, and referral to community agencies for support.

Medical management begins with therapeutic doses of *salicylates* or *NSAIDs*.

Medical Management

EARLY-STAGE RA

- Several *COX-2 inhibitors*, another class of NSAIDs, have been approved for treatment of RA.
- COX (cyclo-oxygenase) is an enzyme involved in the inflammatory process.

Medical Management

Moderate, Erosive RA

- Formal program with *occupational* and *physical therapy* is prescribed
- Educate the patient about principles of joint protection, pacing activities, work simplification, ROM, and muscle-strengthening exercises.

Medical Management

Persistent, Erosive RA

- *Reconstructive surgery* and *corticosteroids* are often used.
- Reconstructive surgery is indicated when pain cannot be relieved by conservative measures.

Surgical procedures

- *Synovectomy* (excision of the synovial membrane),
- *Tenorrhaphy* (suturing a tendon),
- *Arthrodesis* (surgical fusion of the joint), and
- *Arthroplasty* (surgical repair and replacement of the joint).

Medical Management

Advanced, unremitting RA

- *Immunosuppressive agents* are prescribed.
- These include high-dose:
  - *Methotrexate*
  - *Cyclophosphamide* and
  - *Azathioprine*

Medical Management

- Through all stages of RA, depression and sleep deprivation may require the short-term use of *low-dose antidepressant* medications.
- They may include:
  - *Amitriptyline*,
  - *Paroxetine* , or *sertraline* ,

Nutrition Therapy

- Foods high in *vitamins, protein*, and *iron* for tissue building and repair are usually prescribed.
- For the extremely anorexic patient, small, frequent feedings with increased protein supplements may be prescribed.





FIGURE 54-4 Rheumatoid arthritis. (A) Early. (B) Advanced.

GOUT

- Gout is a heterogeneous group of conditions related to a genetic defect of purine metabolism resulting in hyperuricemia.
- Over secretion of uric acid or a renal defect resulting in decreased excretion of uric acid, or a combination of both.
- The prevalence is reported to be 1.6-13.6/1000

- The incidence increases with age and body mass index.
- It occurs more commonly in males than females
- Attacks of gout appear to be related to sudden increases or decreases of serum uric acid levels.

PRIMARY hyperuricemia

- In primary elevated serum urate levels or manifestations of urate deposition appear to be consequences of faulty uric acid metabolism.
- May be caused by severe dietary starvation, excessive intake of foods that are high in purines (shellfish,organ meats), or heredity.

secondary hyperuricemia

- Is a clinical feature secondary to any of a number of genetic or acquired processes, including:
- Conditions in which there is an increase in cell turnover (leukemia, multiple myeloma, some types of anemias, psoriasis) and an increase in cell breakdown.

PHATOPHYSIOLOGY

- When the urate crystals precipitate within a joint, an inflammatory response occurs and an attack of gout begins.
- With repeated attacks, accumulations of sodium urate crystals, called **tophi**, are deposited in peripheral areas of the body, such as the great toe, the hands, and the ear.

- Renal urate lithiasis (kidney stones) with chronic renal disease secondary to urate deposition may develop.

Clinical Manifestations

- Acute gouty arthritis (recurrent attacks of severe articular and periarticular inflammation),
- Tophi (crystalline deposits accumulating in articular tissue, soft tissue, and cartilage),
- Gouty nephropathy (renal impairment), and
- Uric acid urinary calculi

GOUT

Four stages of gout can be identified:

1. Asymptomatic hyperuricemia,
2. Acute gouty arthritis,
3. Intercritical gout, and
4. Chronic tophaceous gout.

GOUT

- The subsequent development of gout is directly related to the duration and magnitude of the hyperuricemia.
- Therefore, the commitment to lifelong pharmacologic treatment of hyperuricemia is deferred (delayed) until there is an initial attack.

Diagnosis & Medical Management

- A definitive diagnosis of gouty arthritis is established by *polarized light microscopy* of the synovial fluid of the involved joint.
- *Uric acid crystals* are seen within the polymorphonuclear leukocytes within the fluid.

- *Colchicine* (oral or parenteral) or an *NSAID* such as *indomethacin* is used to relieve an acute attack of gout.
- Other drugs used include probenced and allopurinol.

Nursing Management

- While severe dietary restriction is not necessary, patients should be encouraged to restrict consumption of *foods high in purines*, especially *organ meats*, and to limit *alcohol intake*.
- Maintenance of normal body weight should be encouraged.

Septic (Infectious) Arthritis

Joints can become infected through:

- Spread of infection from other parts of the body (hematogenous spread) or
- Directly through trauma or surgical instrumentation.

Predisposing factors for Septic (Infectious) Arthritis

- Previous trauma to joints,
- Joint replacement,
- Coexisting arthritis, and
- Diminished host resistance.

- S. aureuscauses at least 50% of all joint infections, and 80% of cases of septic arthritis in patients with rheumatoid arthritis and diabetes.
- The knee is the joint that is most commonly infected (50% of cases), followed by the hip and the shoulder, respectively.

Septic (Infectious) Arthritis

- Bacterial arthritis is the most rapidly destructive form of infectious arthritis.

Septic (Infectious) Arthritis

- There are two major classes of bacterial arthritis:
  - Arthritis caused by *neisseria gonorrhoeae* and
  - *Arthritis caused by non gonococcal bacterium*.
- The most prevalent of the non gonococcal organisms include *Staphylococcus aureus*

Clinical Manifestations

- The characteristic symptom is *acute onset of a warm*, *swollen joint*.
- Culture of the bacterium from the synovial fluid confirms the diagnosis.
- The patient often immobilizes the joint and elevates the affected extremity because of *pain* and *swelling*.

- *Fever* may be high or it may be absent.
- Signs of systemic infection may be lacking in *elderly* patients, those with *diabetes*, and those with *suppressed immune* systems.

Management

- *Parenteral antibiotics* and *drainage* of the joint.
- *Immobilization* of the joint and *repeated joint aspirations* may be necessary along with *intravenous antibiotics.*

Nursing Management

- ✓ Focuses on *providing pain relief*, *administering antibiotics*, and *assisting the patient* with self-care activities.
- ✓ The nurse arranges home care and instructs the patient and care providers in safe administration and changes to report to a health care provider.

ANKYLOSING SPONDYLITIS

- Ankylosing spondylitis affects the cartilaginous joints of the spine and surrounding tissues.
- Occasionally, the large synovial joints, such as hips, knees, or shoulders, may be involved.
- Ankylosing spondylitis is usually diagnosed in the *second* or *third decade*

Ankylosing Spondylitis

- Mainly affects men than women.
- *Back pain* is the characteristic feature.
- As the disease progresses, ankylosis (stiffness) of the entire spine may occur, leading to respiratory compromise and complications.

Medical Management of Spondylitis

- Focuses on *treating pain* and *maintaining mobility* by suppressing inflammation.
- Good body positioning and posture are essential.
- Maintaining range of motion with a regular exercise and muscle-strengthening program is especially important.

Ankylosing Spondylitis

Pharmacologic therapy

- Salicylates, NSAIDs, and corticosteroids often produce marked improvement in back, skin, and joint symptoms.

Surgical management

- May include total hip replacement.

ACUTE LOW BACK PAIN

Most low back pain is caused:

- Acute lumbosacral strain, Unstable lumbosacral ligaments and weak muscles,
- Osteoarthritis of the spine,
- Spinal stenosis, Intervertebral disk problems, and
- Unequal leg length

ACUTE LOW BACK PAIN

Other causes include:

- Kidney disorders,
- Pelvic problems,
- Retroperitoneal tumors,
- Abdominal aneurysms,
- Obesity and Stress

Clinical Manifestations

- Acute back pain or
- Chronic back pain (lasting more than 3 months without improvement) and
- Fatigue.
- Pain radiating down the leg, **which suggests nerve** root involvement.

Clinical Manifestations

- The patient’s gait, spinal mobility, reflexes, leg length, leg motor strength, and sensory perception may be altered.
- Paravertebral muscle spasm (greatly increased muscle tone of the back postural muscles) with a loss of the normal lumbar curve and spinal deformity.

Medical Management

- Most back pain is self-limited and resolves within 4 weeks with analgesics, rest, stress reduction, and relaxation.
- Management focuses on relief of pain and discomfort, activity modification, and patient education.
- Heat or cold therapy frequently provides temporary relief of symptoms.

OSTEOMALACIA

- is a metabolic bone disease characterized by Inadequate mineralization of bone.
  - Softening and weakening of the skeleton,
  - Causing pain, tenderness to touch, bowing of the bones, and pathologic

- Skeletal deformities (spinal kyphosis and bowed legs) give patients an unusual appearance and a waddle or limping gait.
- As a result of calcium deficiency, muscle weakness, there is an increased risk for falls and fractures, particularly pathologic fractures of

- The primary defect in osteomalacia is deficiency of activated vitamin D which cause:
  - Promotes absorption of Ca2 from GIT
  - Facilitates mineralization of the bone
  - The supply of Ca2 and phosphate is low in extracellular fluid
  - Ca2 and phosphate are not moved to calcification site in the bone

Causes

- Deficiency of activated vitamin D (calcitriol),
- Failed calcium absorption (e.g., malabsorption syndrome) or excessive loss of calcium from the body.
- GIT disorders (e.g., celiac disease, chronic biliary tract obstruction, chronic pancreatitis, small bowel resection)

- Severe renal insufficiency results in acidosis.
- During acidosis condition:
  - The body uses available calcium to combat the acidosis,
  - PTH stimulates the release of skeletal calcium in an attempt to reestablish a physiologic ph.
  - During this continual drain of skeletal

- Liver and kidney diseases can produce a lack of vitamin D because these are the organs that convert vitamin D to its active form.
- Hyperparathyroidism
- Deficiency in vitamin D often associated with poor intake of calcium (malnutrition)

Medical Management

- Correcting underlying cause of osteomalecia
- If osteomalacia is caused by malabsorption, increased doses of vitamin D, along with supplemental calcium.
- Exposure to sunlight for ultraviolet radiation to transform a cholesterol substance (7-dehydrocholesterol) present in the skin into vitamin

Medical Management

- If osteomalacia is dietary in origin, a diet with adequate protein and increased calcium and vitamin D is provided.
- Dietary sources of calcium and vitamin D (e.g., fortified milk and cereals, eggs, chicken livers) are recommended.

OSTEOMYELITIS

- Osteomyelitis is an infection of the bone that results in inflammation, necrosis, and formation of new bone.
- The bone becomes infected by one of three modes:
  - *Extension of soft tissue infection* (e.g., infected pressure or vascular ulcer, incisional infection)

- Direct bone contamination from bone surgery, open fracture, or traumatic injury (e.g., gunshot wound)
- Hematogenous (blood borne) spread from other sites of infection (e.g., infected tonsils, boils, infected teeth, upper respiratory infections).

OSTEOMYELITIS

Patients who are at high risk for osteomyelitis include:

- *Poorly nourished*, *Elderly*
- *Obese*
- *Impaired immune systems*,
- *Chronic illness* (e.g., diabetes, rheumatoid arthritis),
- *Long-term corticosteroid therapy*

OSTEOMYELITIS

- Bone infections are more difficult to eradicate than soft tissue infections because
  - The infected bone becomes walled off.
  - Natural body immune responses are blocked, and
  - There is less penetration by antibiotics.

- Over 50% of bone infections are caused by staphylococcus aureus.
- Other pathogen include gram-positive organisms that include streptococci and enterococci,
- Gram-negative bacteria that include pseudomonas species.

Pathophysiology

Infection



Inflammation, increased vascularity, edema



Thrombosis of local blood vessel(after 2-3days)



Ischemia with bone necrosis

Clinical Manifestations

- When the infection is blood borne the onset usually sudden occurring often with manifestations of sepsis (e.g., chills, high fever, rapid pulse, general malaise).
- The infected area becomes painful, swollen, and extremely tender.
- The patient may describe a constant, pulsating pain that intensifies with movement as a result of the pressure of the collecting purulent material

Clinical Manifestations

- When osteomyelitis occurs from spread of adjacent infection or from direct contamination, there are no symptoms of sepsis.
- The area is swollen, warm, painful, and tender to touch

Medical Management

- The initial goal of therapy is to control and halt the infective process.
- Antibiotic therapy depends on the results of blood and wound cultures.

- IV antibiotic therapy continues for 3 to 6 weeks.
- After the infection appears to be controlled, the antibiotic may be administered orally for up to 3 months.

Nursing Interventions

- Relieving pain
- Improving physical mobility
- Controlling the infectious process

SURGICAL MANAGEMENT

- If the patient does not respond to antibiotic therapy,
- The infected bone is surgically exposed, the purulent and necrotic material is removed, and
- The area is irrigated with sterile saline solution.

Care of the Patient in a Cast

- A **cast** is a rigid external immobilizing device that is molded to the contours of the body.
- It permit mobilization of the patient while restricting movement of a body part.

The purposes of a cast

- To immobilize a body part in a specific position,
- To correct a deformity,
- To immobilize a reduced fracture,
- To apply uniform pressure to underlying soft tissue, or
- To support and stabilize weakened joints.

Types of Cast

- ***Short arm cast****: e*xtends from below the elbow to the palmar crease, secured around the base of the thumb. If the thumb is included, it is known as a *thumb spica* or *gauntlet* cast.
- ***Long arm cast****:* extends from the upper level of the axillary fold to the proximal palmar crease. The elbow usually is

- ***Short leg cast:*** extends from below the knee to the base of the toes. The foot is flexed at a right angle in a neutral position

Types of Cast

- ***Long leg cast:*** extends from the junction of the upper and middle third of the thigh to the base of the toes. The knee may be slightly flexed.
- ***Walking cast:*** A short or long leg cast reinforced for strength.

- ***Body cast**:* encircles the trunk.
- ***Shoulder spica cast**:* A body jacket that encloses the trunk and the shoulder and elbow.
- ***Hip spica cast**:* encloses the trunk and a lower extremity. A double hip spica cast includes both legs.

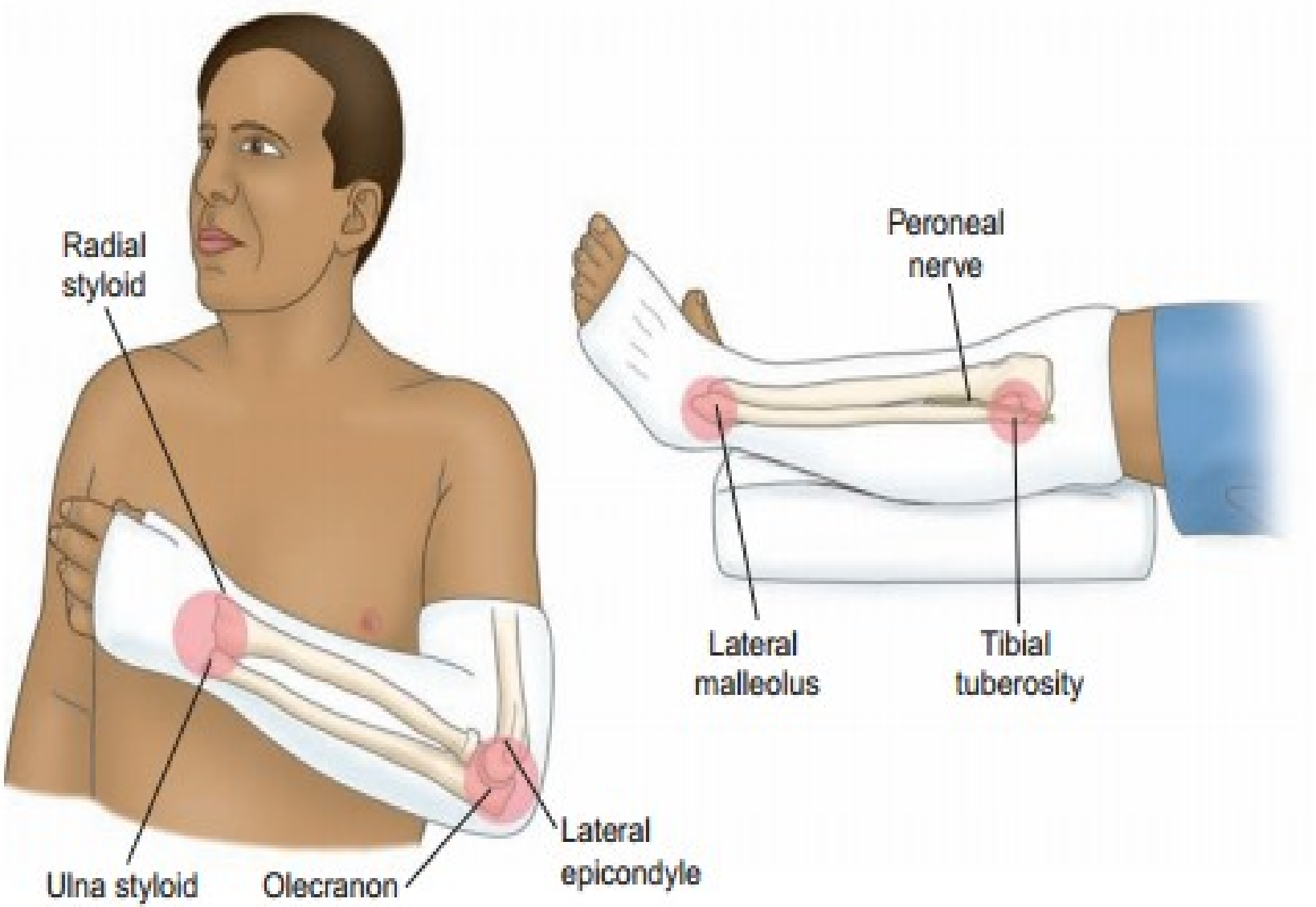
Radial styloid
Ulna styloid
Olecranon
Lateral epicondyle
Peroneal nerve
Lateral malleolus
Tibial tuberosity

CASTING MATERIALS

Fiberglass cast(non plaster)

→ Are composed of water-activated polyurethane materials and have the versatility of plaster but are lighter in weight, stronger, water resistant, and durable.

→ Consist of an open-weave, nonabsorbent fabric impregnated with cool water–activated hardeners that bond and reach full rigid strength in minutes.

- Some fiberglass casts use a waterproof lining which permits the patient to shower, swim, or engage in hydrotherapy (use of water for treatment).
- When the cast is wet, the patient is instructed to shake or drain water out of it; thorough drying is important to

Plaster casts

- Casts made of plaster are less costly and achieve a better mold than fiberglass casts; not as durable and take longer to dry.
- Plaster (pop): rolls of plaster bandage are wet in cool water and applied smoothly to the body.
- Requires 24 to 72 hours to dry completely, depending on its thickness and the environmental drying conditions.

Management of undried cast

While damp (wet), the cast can:

- It must be handled with the palms of the hand and
- Not allowed to rest on hard surfaces or sharp edges
- Should be exposed to circulating air to dry
- Should not be covered with clothing or bed

Management of undried cast

- A wet plaster cast appears dull and gray, sounds dull on percussion, feels damp, and smells musty.
- A dry plaster cast is white and shiny, resonant, odorless, and firm.

POTENTIAL COMPLICATIONS OF CAST

- Compartment Syndrome
- Disuse Syndrome
- Pressure Ulcers

Managing the Patient in Traction

- **Traction** is the application of a pulling force to a part of the body.
- Traction is used:
  - To minimize muscle spasms;
  - To reduce, align, and immobilize fractures;
  - To reduce deformity; and
  - To increase space between opposing surfaces.

- Traction is used primarily as a short-term intervention until other modalities, such as external or internal fixation, are possible.

PRINCIPLES OF EFFECTIVE TRACTION

1. Whenever traction is applied, counter-traction (forces in opposite direction) must be used to achieve effective traction.
2. Traction must be continuous to be effective in reducing and immobilizing fractures.

3. Skeletal traction is *never* interrupted.

4. Weights are not removed unless intermittent traction is prescribed.

5. Any factor that might reduce the effective pull or alter its resultant line of pull must be eliminated.

TYPES OF TRACTION

- ***Straight* or *running traction***: applies the pulling force in a straight line with the body part resting on the bed. E.g. Buck's extension traction
- ***Balanced suspension traction*** : supports the affected extremity off the bed and allows for some patient movement without disruption of the line of pull.
- ***Skin traction***: Traction applied to the skin.

TYPES OF TRACTION

- **_Skeletal traction_**_:_ traction directly applied to the bony skeleton.
- **_Manual traction_**_:_ traction applied with the hands.
- May be used when applying a cast, giving skin care under a buck’s extension foam boot, or adjusting the traction apparatus.

Skin Traction

- Is used to control muscle spasms and to immobilize an area before surgery.
- The amount of weight applied must not exceed the tolerance of the skin.
- No more than 2 to 3.5 kg of traction can be used on an extremity.

Types of skin traction used for adults include:

- Buck’s extension traction (applied to the lower leg),
- The cervical head halter (occasionally used to treat neck pain), and
- The pelvic belt (sometimes used to treat back pain).

Buck’s Extension Traction

- Buck’s extension traction is skin traction to the lower leg.
- The pull is exerted in one plane when partial or temporary immobilization is desired
- It is used to immobilize fractures of the proximal femur before surgical fixation.
- Before the traction is applied, the nurse inspects the skin for abrasions and circulatory disturbances.

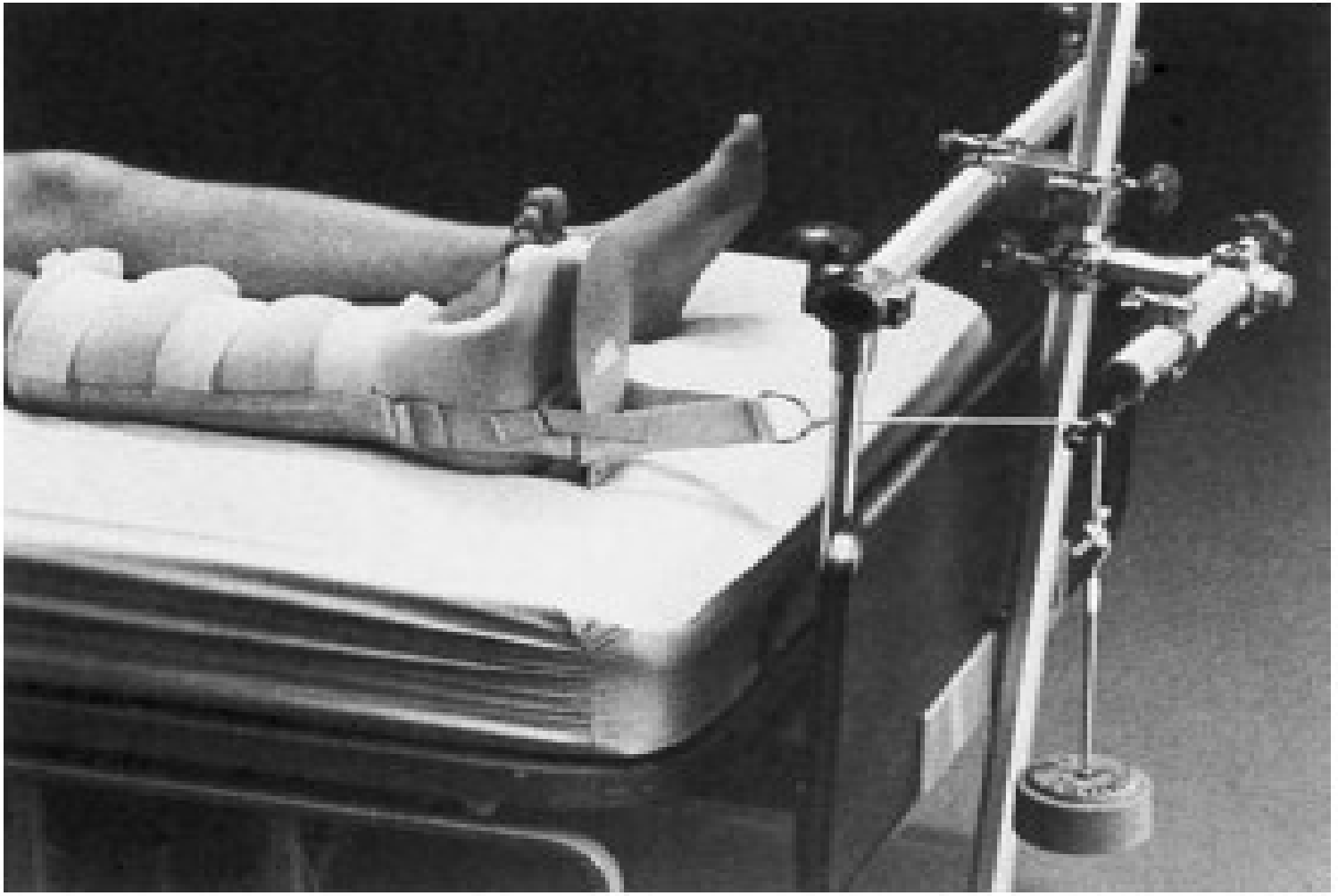

Figure 67-5 Buck's extension traction. Lower extremity in unilateral Buck's extension traction is aligned in a foam boot and traction applied by the free-hanging weight.

Skeletal Traction

- Skeletal traction is used occasionally to treat fractures of the femur, the tibia, and the cervical spine.
- The traction is applied directly to the bone by use of a metal pin or wire (e.g,Steinmann pin, Kirschner wire) that is inserted through the bone distal to the fracture, avoiding nerves, blood vessels, muscles, tendons, and joints.

- Skeletal traction frequently uses 7 to 12 kg to achieve the therapeutic effect.

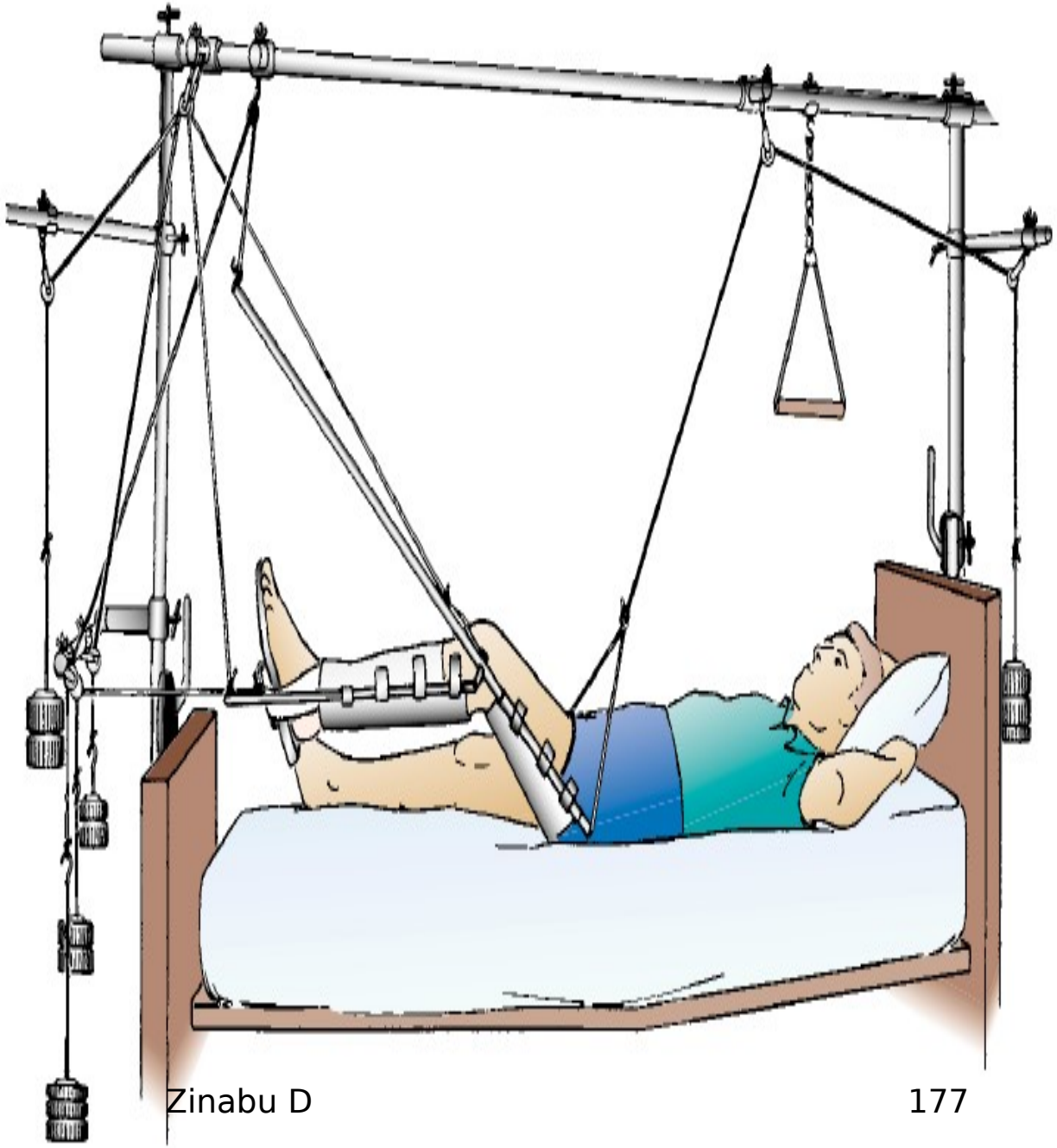

FIGURE 67-5 Balanced suspension skeletal traction with Thomas leg splint. The patient can move vertically as long as the resultant line of pull is maintained.

Potential Complications of Skin Traction

- Skin breakdown,
- Nerve pressure, and
- Circulatory impairment

Amputation

- **Amputation** is the removal of a body part, usually an extremity.
- Amputation of a lower extremity is often made necessary by:
  - Peripheral vascular disease (often a sequela of diabetes mellitus),
  - Fulminating gas gangrene,
  - Trauma (crushing injuries, burns, frostbite, and electrical burns),

- Congenital deformities,
- Chronic osteomyelitis, or malignant tumor.
- Of all these causes, *peripheral vascular disease* accounts for most amputations of lower extremities.

Purposes of Amputation

Amputation is used to:

- Relieve symptoms,
- Improve function, and
- Save or improve the patient's quality of life.

Levels of Amputation

- Amputation is performed at the most distal point that will heal successfully.
- The site of amputation is determined by two factors:
  1. Circulation in the part, and
  2. Functional usefulness (i.e., Meets the requirements for the use of the prosthesis).

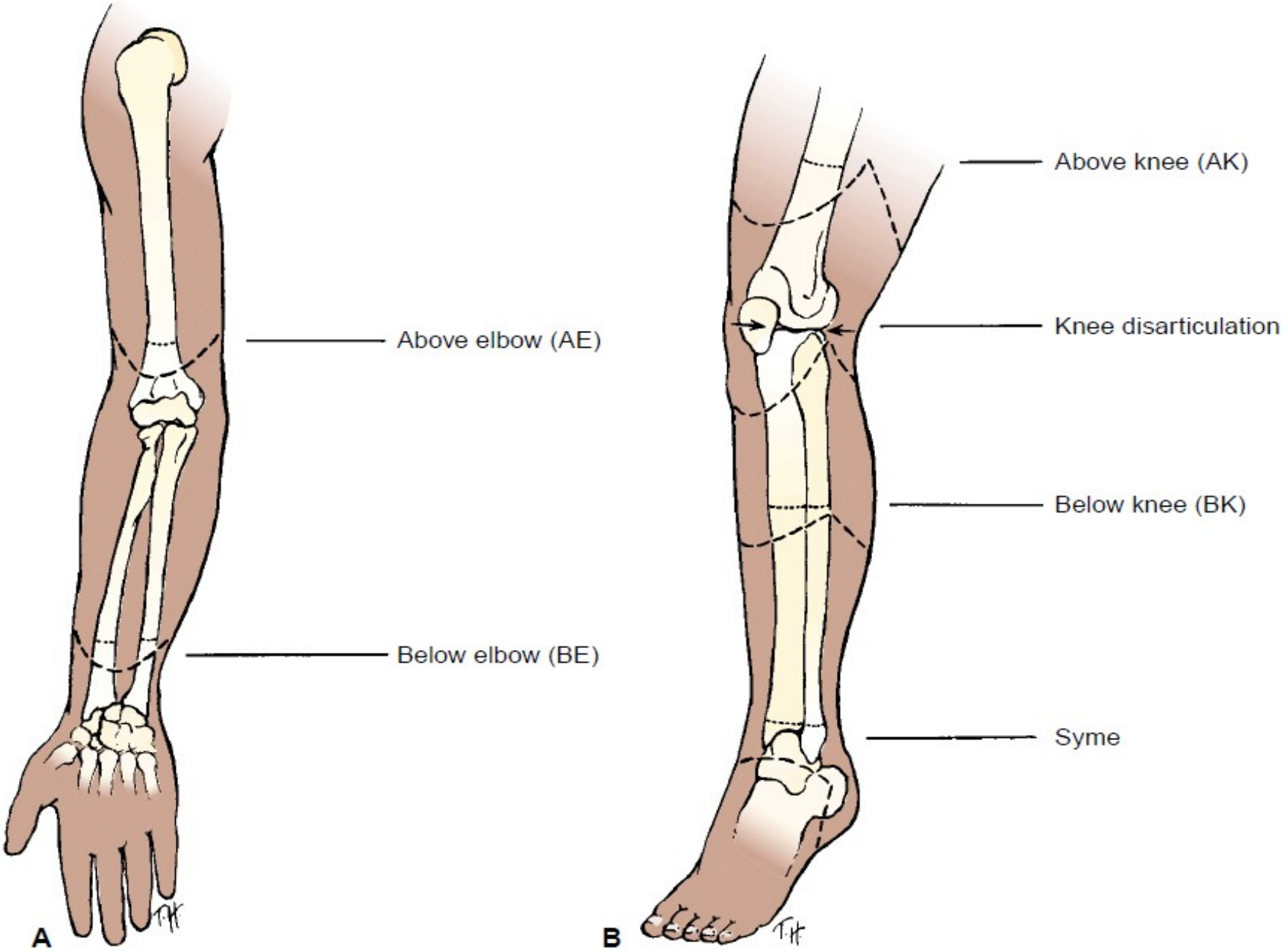

FIGURE 69-16 Levels of amputation are determined by circulatory adequacy, type of prosthesis, function of the part, and muscle balance. (**A**) Levels of amputation of upper extremity. (**B**) Levels of amputation of lower extremity.

- The wound is debrided and allowed to drain.
- Sepsis is treated with systemic antibiotics.
- After the infection has been controlled and the patient’s condition has stabilized, a definitive amputation with skin closure is performed.

Complications of Amputation

Complications that may occur with amputation include:

- Hemorrhage,
- Infection,
- Skin breakdown,
- Phantom limb pain, and
- Joint contracture

Medical Management

- A **closed rigid cast dressing** is frequently used to provide uniform, to support soft tissues, to control pain, and to prevent joint contractures.

Medical Management

- **A removable rigid dressing** may be placed over a soft dressing to control edema, to prevent joint flexion contracture, and to protect the residual limb from unintentional trauma during transfer activities.

Medical Management

Rehabilitation: Because the amputation is the result of an injury, the patient needs psychological support in accepting the sudden change in body image and in dealing with the stresses of hospitalization, long-term rehabilitation, and modification of lifestyle.

SOME REAL PHOTOS OF AMPUTATION



- Initially, a guillotine amputation is










Thank you!!!

unit 11

Neurologic DISORDER

By

Zinabu d

LEARNING OBJECTIVES

On completion of this session, students will be able to:

- Describe the structures and functions of the central and peripheral nervous systems.
- Compare the functioning of the sympathetic and parasympathetic nervous systems.
- Describe diagnostic tests used for assessment of suspected neurologic disorders
- Identify the common neurological disorders

ANATOMIC AND PHYSIOLOGIC OVERVIEW

The nervous system consists of two major parts:-

- The central nervous system (CNS), including the brain and spinal cord,
- The peripheral nervous system(PNS), which includes the cranial nerves, spinal nerves, and autonomic nervous system.

DIVISIONS OF NERVOUS SYSTEM

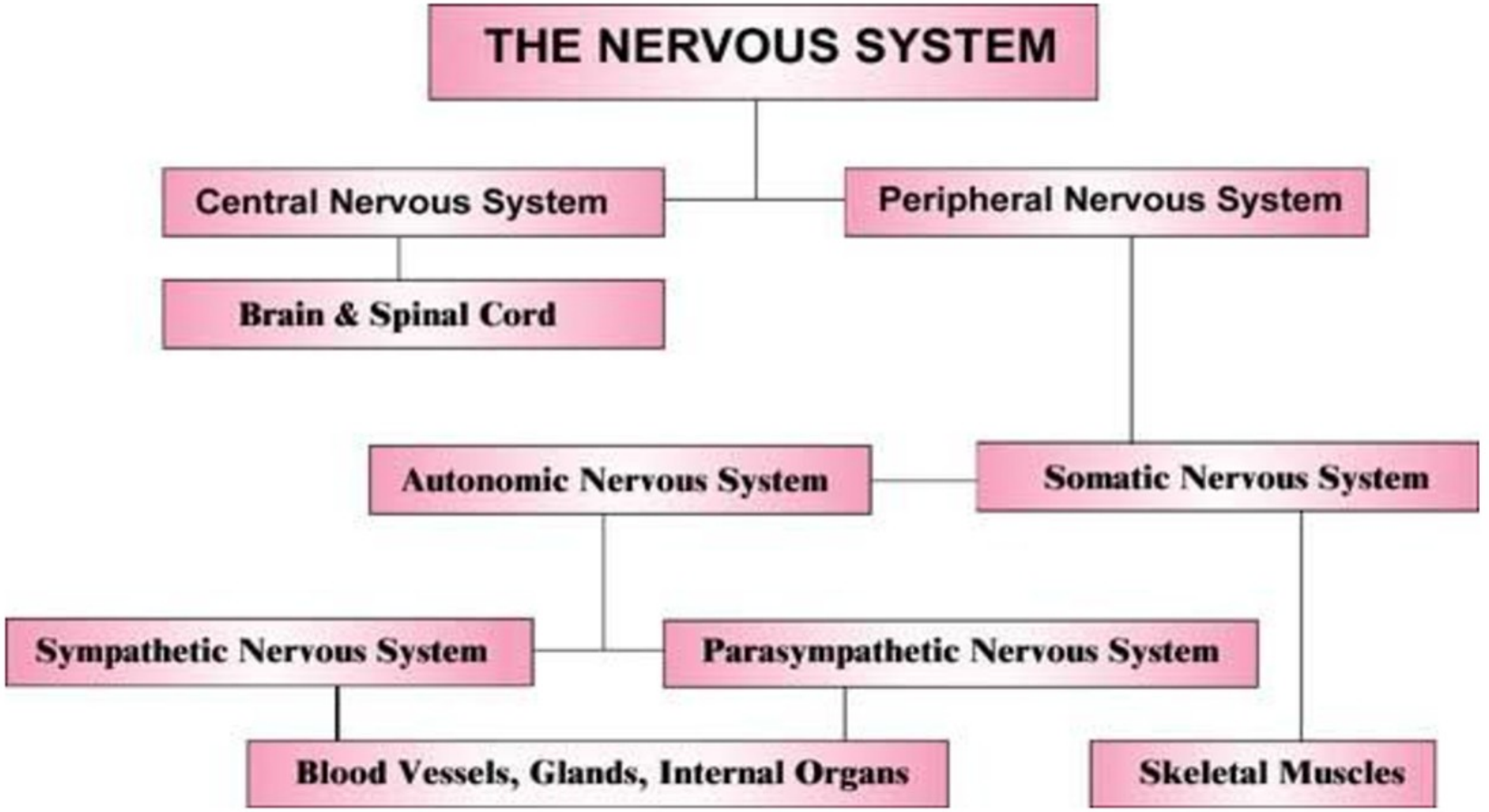

NERVOUS SYSTEM

is the master controlling and communicating system of the body.

- ✓ Every thought, action, and emotion reflects its activity.
- ✓ Its cells communicate by electrical and chemical signals, which are rapid and specific, and usually cause almost immediate responses.
- ✓ Along with the endocrine system it is responsible for regulating and maintaining body homeostasis

Functions

(1) It uses its millions of sensory receptors to monitor changes occurring both inside and outside the body.

✓ The gathered information is called **sensory input**.

(2) It processes and interprets sensory input and decides what should be done at each moment—a process called **integration**.

(3) It causes a response, called motor **output,** by activating effector organs.

The Brain

- The brain accounts for approximately 2% of the total body Weight.
- The brain is divided into three major areas: **the cerebrum, the brain stem, diencephalon and the cerebellum.**

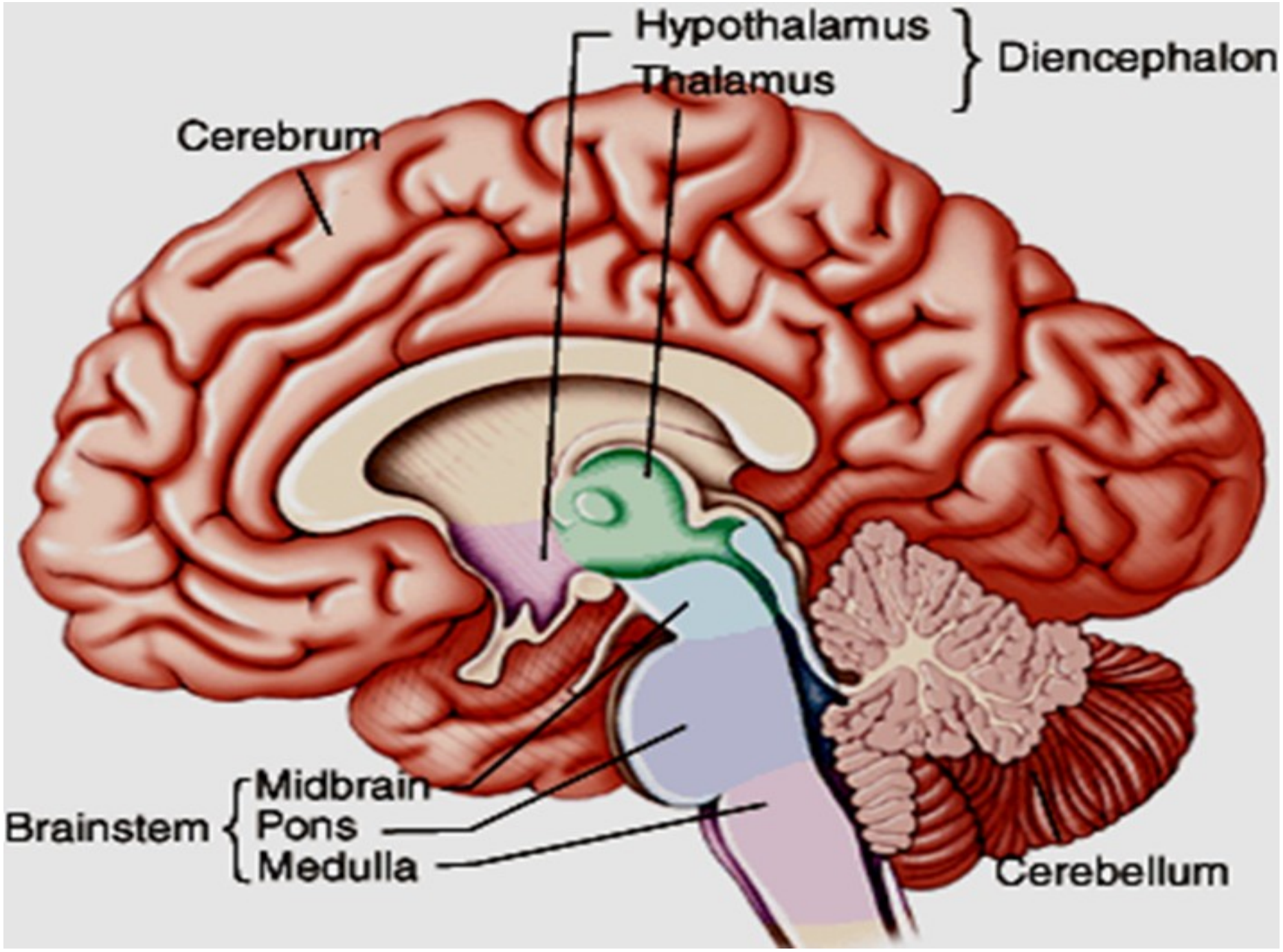
Hypothalamus
Thalamus
Diencephalon
Cerebrum
Midbrain
Brainstem
Pons
Medulla
Cerebellum

Cerebrum

- ✓ The cerebrum is composed of two hemispheres, it is connected by a bundle of nerve fibers, the corpus callosum.
- ✓ Responsible for an individual function and intelligence.
- ✓ The cerebral hemispheres are divided into four lobes: frontal, parietal, temporal, and occipital lobes.

Cont ,.....

- **Gray matter**: the external or outer portion of hemisphere.
  - 2 to 5 mm in depth;
  - It contains billions of neuron cell bodies, giving it a gray appearance.
- **White matter:** the innermost layer and is composed of myelinated nerve

Cont,....

Frontal lobe —the largest lobe.

- The major functions of this lobe are concentration, abstract thought, information storage or memory, and motor function.
- It is also responsible in large part for an individual's affect, judgment, personality, and inhibition.

Parietal

It is a predominantly sensory lobe.

- The primary sensory cortex, which analyzes sensory information and relays the interpretation of this information to the thalamus and other cortical areas.
- It is essential to a person's awareness of body position in space, size and shape discrimination, and right–left orientation.

Cont,....

Temporal—contains the auditory receptive areas.

- Contains a vital area called the interpretive area that provides integration of somatization, visual, and auditory areas.
- **Occipital**—the posterior lobe of the cerebral hemisphere is responsible for visual interpretation.

Cont,.....

- **The basal ganglia:** are responsible for control of motor movements, including those of the hands and lower extremities.
- **The thalamus** lies on either side of the third ventricle and acts primarily as a relay station for all sensation except smell.
- **The hypothalamus** is located anterior and inferior to the thalamus, and beneath and lateral to the third ventricle.

Cont,.....

- The hypothalamus is the site of the hunger center and is involved in appetite control.
- It contains centers that regulate the sleep–wake cycle, blood pressure, aggressive and sexual behavior, and emotional responses (i.e, blushing, rage, depression, panic, and fear).

A.Medulla oblongata - Transmits motor fibber from the brain to the spinal cord and sensory fibber from the spinal cord to the brain.

- Reflex centers for respiration, blood pressure, heart rate, coughing, vomiting, swallowing, and sneezing are located in the medulla.

Cont ,.....

B.Pons - Contain motor and sensory pathway and it is abridge b/n the medulla and the cerebrum.

ê Also contain centre for controlling heart, respiration.

C. Mid brain - It contains sensory and motor pathways and serves as a centre for auditory and visual reflexes.

Cerebellum

- Lies inferior to the cerebrum and occupies the posterior cranial fossa.
- 2nd largest region of the brain.
- 10% of the brain by volume, but it contains 50% of its neurons

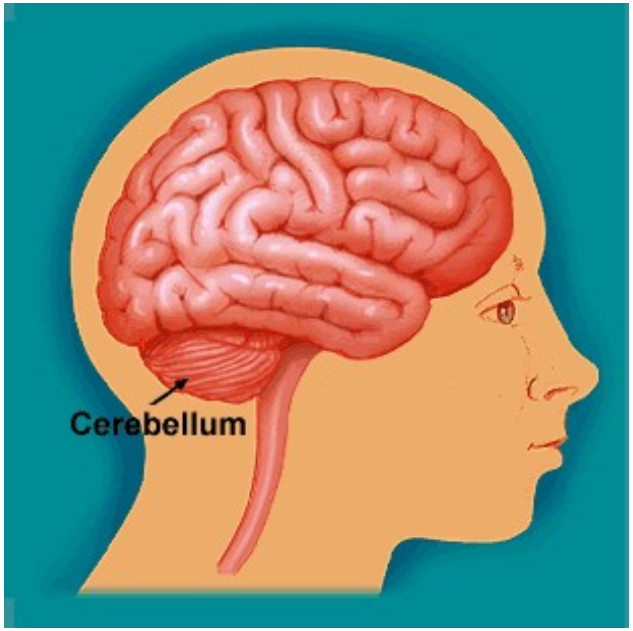

Cont,.....

- The cerebellum can be permanently damaged by trauma or stroke or temporarily affected by drugs such as alcohol.
- These alterations can pr disturbance in balance.



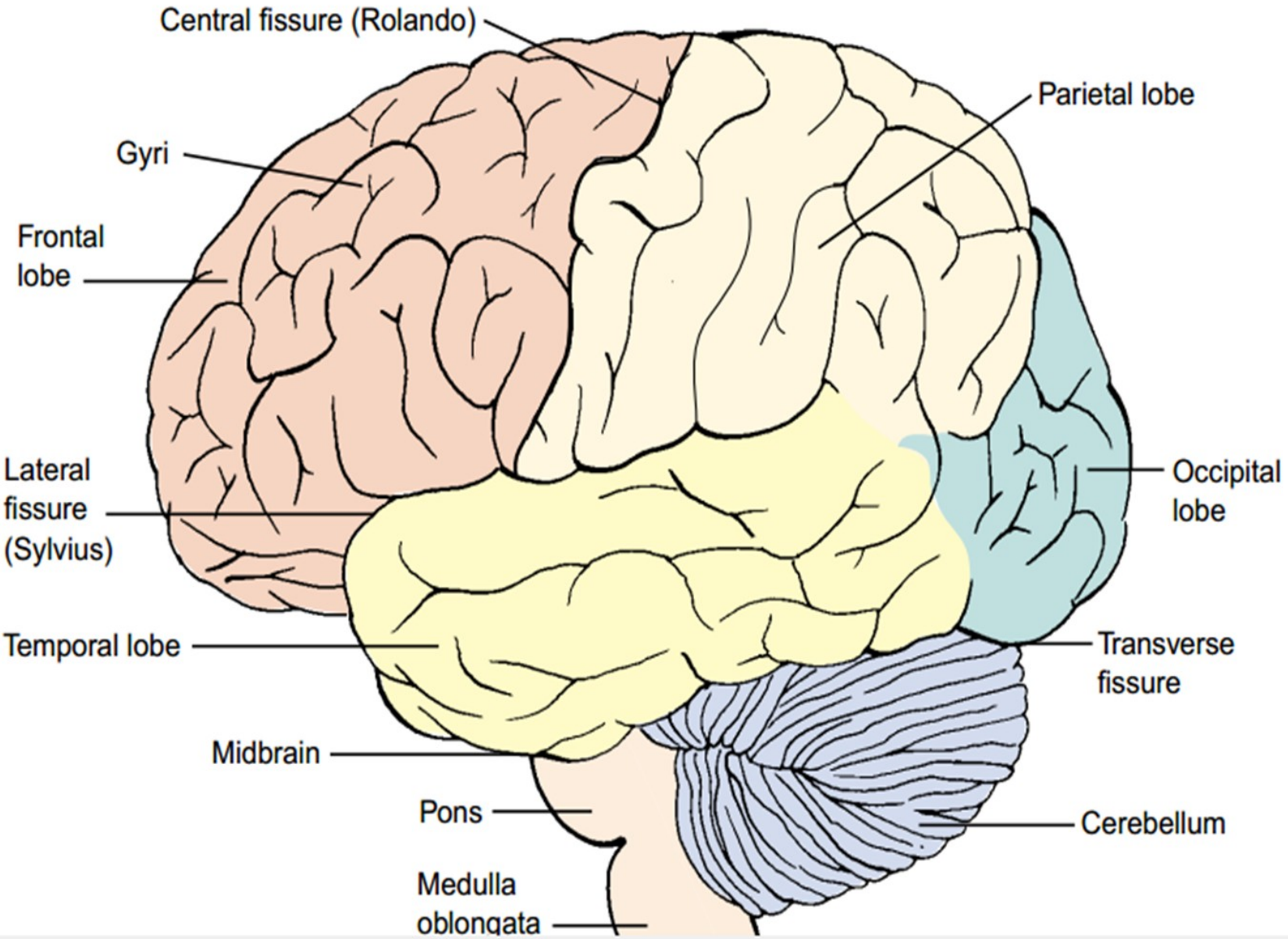
Central fissure (Rolando)
Parietal lobe
Gyri
Frontal lobe
Lateral fissure (Sylvius)
Occipital lobe
Temporal lobe
Transverse fissure
Midbrain
Pons
Cerebellum
Medulla oblongata

Cont,.....

Brain has two hemispheres

1. **Left side of the brain-** controls the functions of the right half of the body, and
2. **Right side of the brain** -controls the left half of the body.(Exceptions to this rule are the eye and the ear, which have bilateral cortical connections.)

The meninges

- The meninges, fibrous connective tissues that cover the brain and spinal cord, provide protection, support, and nourishment.
- The layers of the meninges are the dura mater, arachnoid, and pia mater.

Cont,.....

Dura mater —the outermost layer; covers the brain and the spinal cord.

- It is tough, thick, inelastic, fibrous, and gray.

Arachnoid —the middle membrane; an extremely thin, delicate membrane that closely resembles a spider web.

- It has CSF in the space below it, called the subarachnoid space.

Cont,…

- It has unique fingerlike projections, called arachnoid villi, that absorb CSF into the venous system.
- **Pia mater** —the innermost, thin, transparent layer that hugs the brain closely and extends into every fold of the brain’s surface.

CRANIAL NERVES

There are 12 pairs of cranial nerves that emerge from the lower surface of the brain and pass through the foramina in the skull.

- Three are sensory (i, ii, viii),
- Five are motor (iii, iv, vi, xi, and xii), and
- Four are mixed (v, vii, ix, and x) as they have both sensory and motor.

Cont,.....

- For example, cranial nerves I and II attach in the cerebral hemispheres, whereas cranial nerves IX, X, XI, and XII attach at the medulla.
- Most cranial nerves innervate the head, neck, and special sense structures.

No.	Cranial Nerve	Function
I	Olfactory	Sense of smell
II	Optic	Vision
III	Oculomotor	Pupillary constriction, opening the eye, and most extraocular movements
IV	Trochlear	Downward, inward movement of the eye
VI	Abducens	Lateral deviation of the eye
V	Trigeminal	*Motor*—temporal and masseter muscles (jaw clenching), also lateral movement of the jaw *Sensory*—facial. The nerve has three divisions: (1) ophthalmic, (2) maxillary, and (3) mandibular.

VII	**Facial**	*Motor*—facial movements, including those of facial expression, closing the eye, and closing the mouth *Sensory*—taste for salty, sweet, sour, and bitter substances on the anterior two thirds of the tongue
VIII	**Acoustic**	Hearing (cochlear division) and balance (vestibular division)
IX	**Glossopharyngeal**	*Motor*—pharynx *Sensory*—posterior portions of the eardrum and ear canal, the pharynx, and the posterior tongue, including taste (salty, sweet, sour, bitter)
X	**Vagus**	*Motor*—palate, pharynx, and larynx *Sensory*—pharynx and larynx
XI	**Spinal accessory**	*Motor*—the sternomastoid and upper portion of the trapezius
XII	**Hypoglossal**	*Motor*—tongue

The Spinal Nerves

The spinal cord communicates with the rest of the body by way of the spinal nerves.

Cont.....

- There are 31 pairs of spinal nerves: 8 cervical (C1–C8), 12 thoracic (T1–T12), 5 lumbar (L1–L5), 5 sacral (S1–S5), and 1 coccygeal (Co).
- The first cervical nerve emerges between the skull and atlas, and the others emerge through intervertebral foramina, including the anterior and

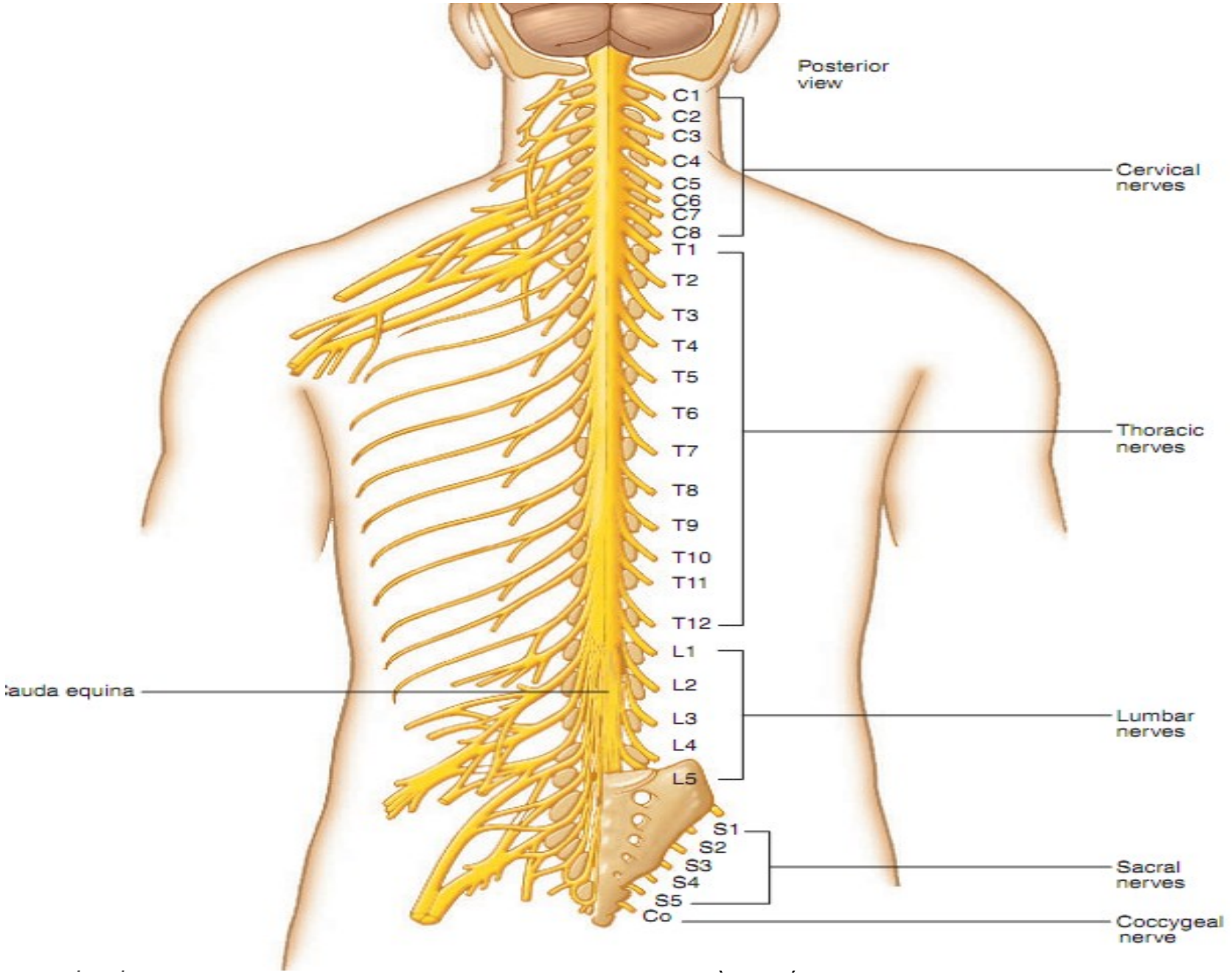
Posterior view
C1
C2
C3
C4
C5
C6
C7
C8
Cervical nerves
T1
T2
T3
T4
T5
T6
T7
T8
T9
T10
T11
T12
Thoracic nerves
L1
L2
L3
L4
L5
Lumbar nerves
Cauda equina
S1
S2
S3
S4
S5
Sacral nerves
Co
Coccygeal nerve

- The CNS is inaccessible to many substances that circulate in the blood (i.e. dyes, medications, antibiotics)
- After being injected in to the blood these substance do not teach the neurons of the CNS. This phenomenon is called blood brain barrier.
- Has implications in the Rx and medication selection for CNS disease processes.

Cerebrospinal fluid /CSF/

- A clear and colourless fluid with a specific gravity of 1.007
- Produced in the ventricles and circulates in the brain and the spinal cord, by the ventricular system.
- The organic and inorganic content of CSF are similar to those of plasma.
- Normally, CSF has a minimal number of

Peripheral Nervous System

SOMATIC NS

- ✓ Voluntary (generally)
- ✓ Somatic nerve fibers that conduct impulses from the CNS to skeletal muscles

AUTONOMOUS NS

- ➢ Involuntary (generally)
- ➢ Conducts impulses from the CNS to smooth muscle, cardiac muscle, and glands.

COMPARISON OF SoNS Vs ANS

SoNS

- Controls voluntary activities such as contraction of the **Sk/muscle**.
- Nerve fibres are originated from the **anterior horn of the GM** of the spinal cord.
- The motor nerve contains **single, long, thick and myelinated axon.**
- The NT is always **Ach** and the receptor is always **NR**

ANS

- Controls **involuntary** activities such as **CVS, GIT, glands**
- Nerve fibres are originated from the **lateral horn of the GM** of spinal cord.
- Autonomic fibres contain **two neurons (pre-&post-ganglionic neurons)**
- The NTs are both **Ach** and **nor epinephrine** and the receptors are **adrenergic** and **cholinergic**

Peripheral Nervous System

- ANNS has :-
- Two divisions:
  - Sympathetic
  - Parasympathetic

SYMPATHETIC NS

- Fight or flight” response
- Release adrenaline and nor adrenaline
- Increases heart rate and blood pressure
- Increases blood flow to skeletal muscles

- Inhibits digestive functions

PARASYMPATHETIC NS

- Rest and digest ” system
- Calms body to conserve and maintain energy
- Lowers heartbeat, breathing rate, blood pressure

Autonomic innervation

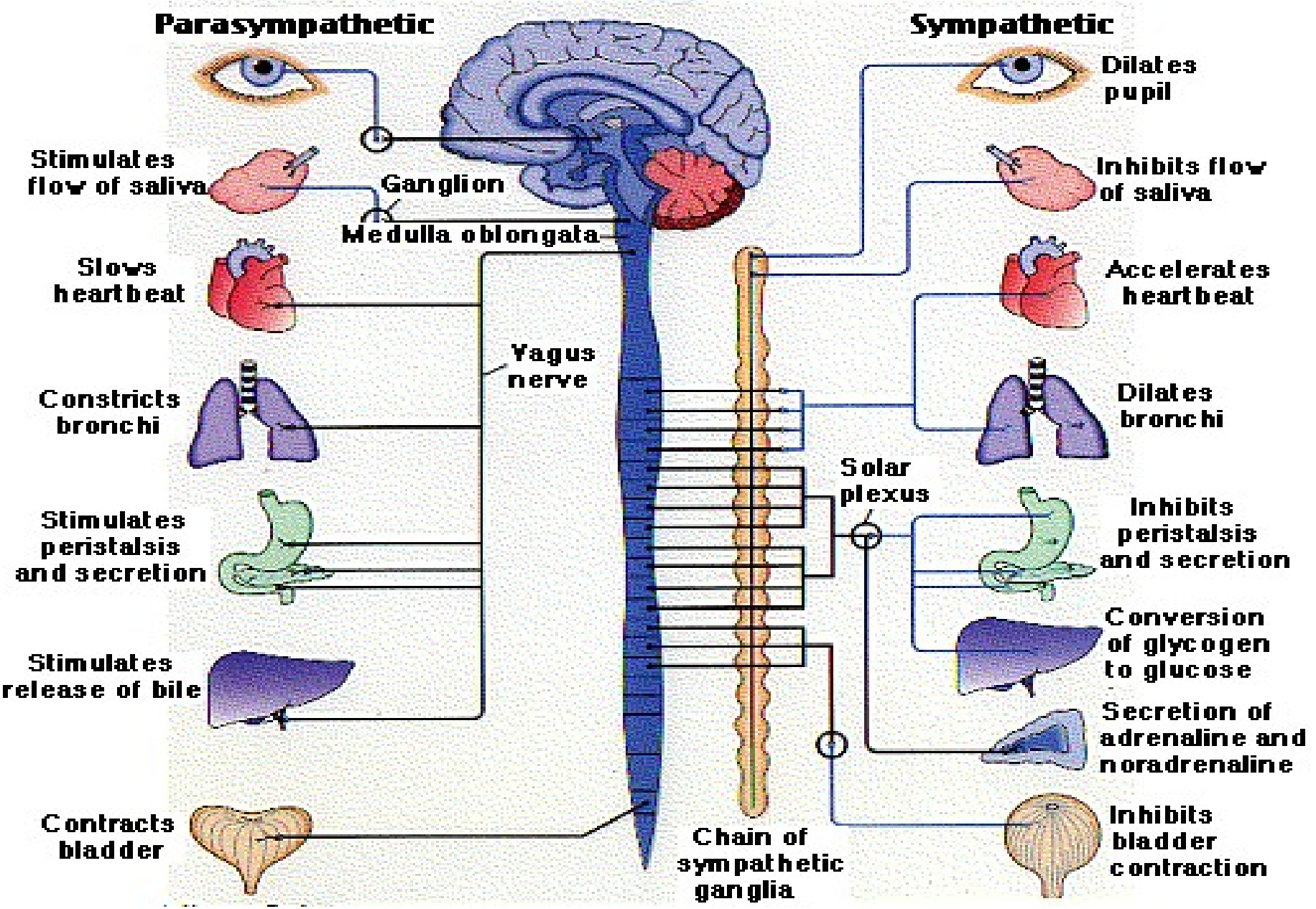

The Neuron

- ✓ **Neurons:** the building blocks of the nervous system
- ✓ **Sensory neurons:** send signals from the senses, skin, muscles, and internal organs to the CNS.
- ✓ **Motor neurons:** transmit commands from the CNS to the muscles, glands, and organs.

Cont,…

- **Interneuron:** located between sensory and motor neurons.
- Transmit signals from one part of the body to another.
- **Glial cells:** support and nutrition of neurons.
- Neurons are composed of a cell body, a dendrite, and an axon.

Cont,....

- **Dendrites**: Receive messages
- **Cell body:** Biochemical machinery
  - Sends signal
- **Axon:** Transmits messages
- **Myelin sheath**: Insulation and speed of signal transfer

The structure of a neuron

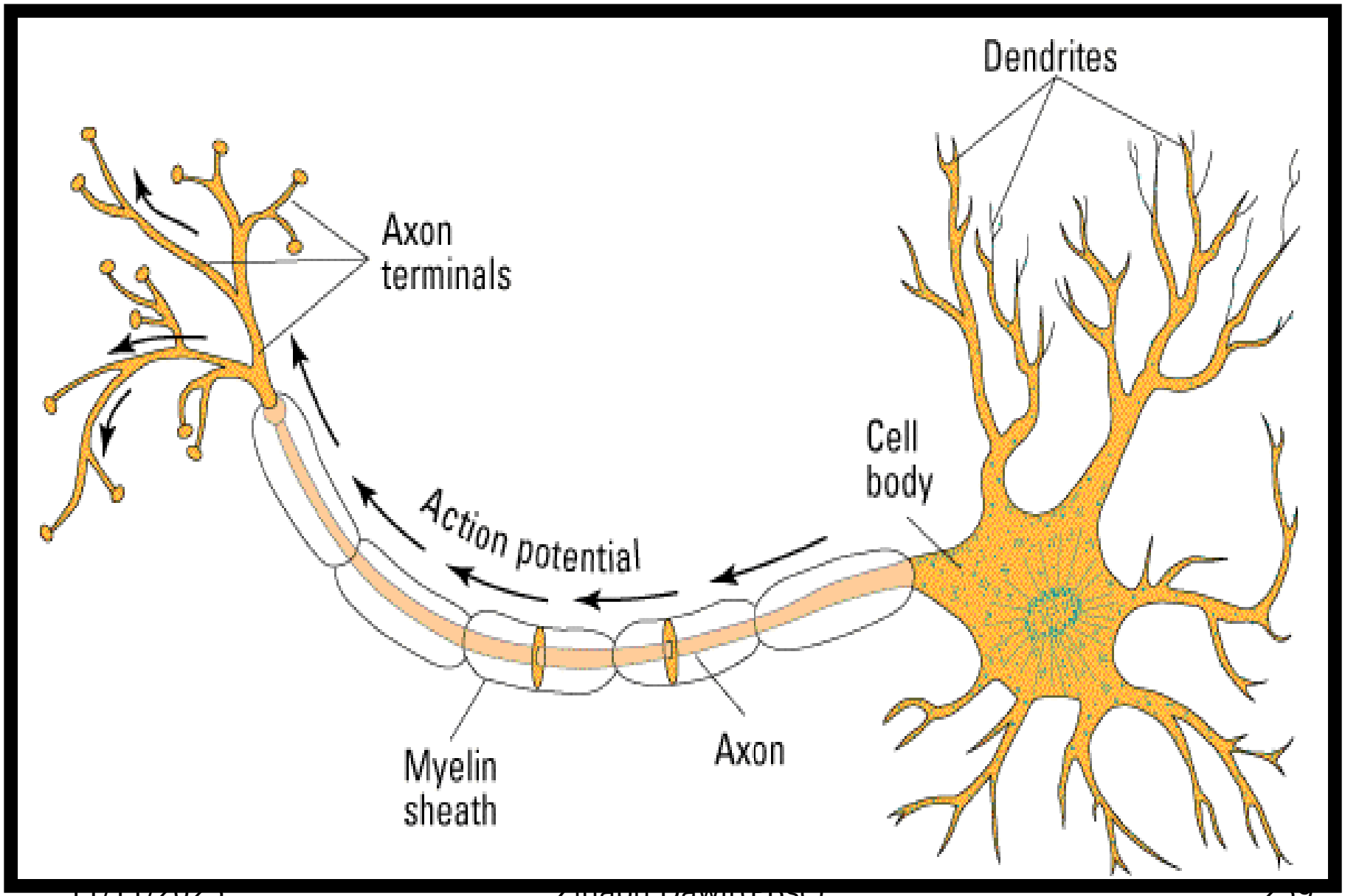

Neurotransmitters

- Neurotransmitters are manufactured and stored in synaptic vesicles.
- Axon terminals release neurotransmitter
- Enters synapse

Cont,....

- The neurotransmitter diffuses or is transported across the synapse, binding to receptors in the postsynaptic cell membrane.
- A neurotransmitter potentiates, terminates, or modulates a specific action, and it can either excite or inhibit activity of the target cell.

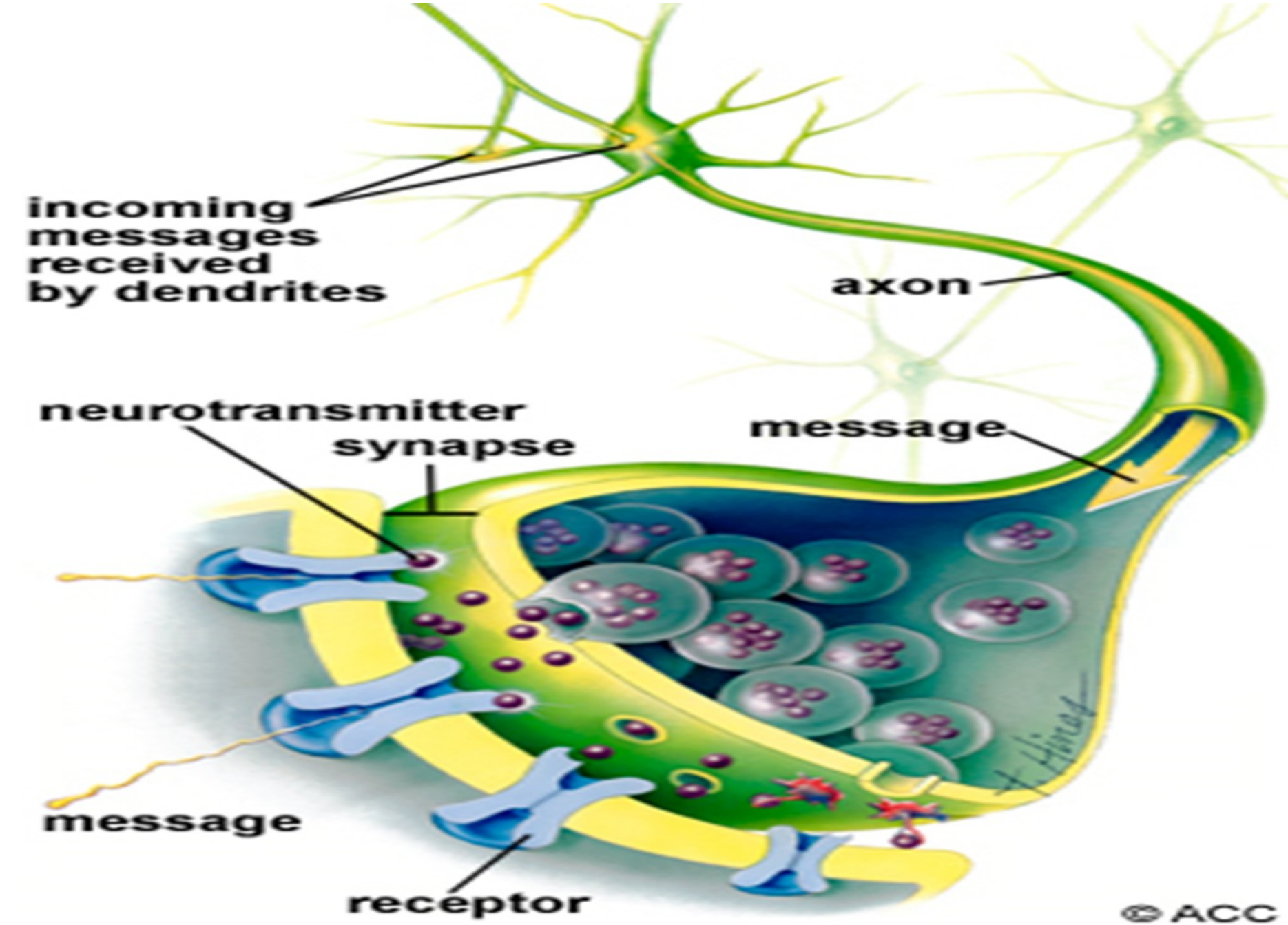
incoming
messages
received
by dendrites
axon
neurotransmitter
synapse
message
message
receptor
© ACC

Table 60-1 • Major Neurotransmitters

NEUROTRANSMITTER	SOURCE	ACTION
Acetylcholine (major transmitter of the parasympathetic nervous system)	Many areas of the brain; autonomic nervous system	Usually excitatory; parasympathetic effects sometimes restrain (stimulation of heart by vagal nerve)
Serotonin	Brain stem, hypothalamus, dorsal horn of the spinal cord	Restraining, helps control mood and sleep, inhibits pain pathways
Dopamine	Substantia nigra and basal ganglia	Usually restrains, affects behavior (attention, emotions) and fine movement
Norepinephrine (major transmitter of the sympathetic nervous system)	Brain stem, hypothalamus, postganglionic neurons of the sympathetic nervous system	Usually excitatory; affects mood and overall activity
Gamma-aminobutyric acid (GABA)	Spinal cord, cerebellum, basal ganglia, some cortical areas	Excitatory amino acid
Enkephalin, endorphin	Nerve terminals in the spine, brain stem, thalamus and hypothalamus, pituitary gland	Excitatory; pleasurable sensation, inhibits pain transmission

The Neurologic Examination

- Health history
- Clinical manifestations
  - ✓Pain
  - ✓Seizures
  - ✓Dizziness
  - ✓Visual Disturbances
  - ✓Weakness
  - ✓Abnormal Sensation

Cont,.....

Physical examination

- Examining the Cranial Nerves
- Examining the Motor System

Cont,…

NEUROLOGICL ASSESMENT

- Neurological assessment focus on:-
- Mental status: appearance and behavior, speech and language, mood, thoughts and perceptions, cognition
- Cranial Nerves I through XII

Cont,....

- **Motor system:** muscle bulk, tone, and strength; coordination, gait, and stance.
- **Sensory system:** pain and temperature, position and vibration, light touch, discrimination.
- Deep tendon, abdominal, and plantar reflexes

Cont,....

Three important questions govern neurologic examination:

1) Is the mental status intact?
2) Are right side and left side findings symmetric?
3) If findings are asymmetric or otherwise abnormal, does the causative lesion lie in the central nervous system

COMPONENTS OF EVALUATION :

I. Appearance and behaviour

II. Mood

III. Speech and language

IV. Thought and perception

V. Cognitive function

Cont,....

Appearance and behavior: assess **state of consciousness**

- A. Glasgow coma scale

✘ Is done for high risk patients

✘ Is done based on eye opening, best motor response and verbal response of the patient to stimuli

Cont,.....

- Values range from 3(deep coma) to 15(alert)
- A score of 7 or less is generally accepted as coma and requires appropriate nursing intervention for the comatose patient.

CHART 63-4

Assessment for Glasgow Coma Scale

The Glasgow Coma Scale is a tool for assessing a patient's response to stimuli. Scores range from 3 (deep coma) to 15 (normal).

Eye opening response	Spontaneous	4
	To voice	3
	To pain	2
	None	1
Best verbal response	Oriented	5
	Confused	4
	Inappropriate words	3
	Incomprehensible sounds	2
	None	1
Best motor response	Obeys command	6
	Localizes pain	5
	Withdraws	4
	Flexion	3
	Extension	2
	None	1
Total		3 to 15

- Individual elements as well as the sum of the score are important. Hence, the score is expressed in the form "GCS 9 = E2 V4 M3 at 07:35".
- Generally, brain injury is classified as:
  - Severe, with GCS < 8
  - Moderate, GCS 8 or 9–12
  - Minor, GCS ≥ 13.

Cont,....

- Tracheal intubation and severe facial/eye swelling or damage make it impossible to test the verbal and eye responses.
- In these circumstances, the score is given as 1 with a modifier attached e.g. "E1c" where "c" = closed, or "V1t" where t = tube.
- A composite might be "GCS 5tc". This would mean, for example, eyes closed because of swelling = 1, intubated = 1, leaving a motor score of 3 for "abnormal flexion".
- Often the 1 is left out, so the scale reads Ec or Vt

Cont,……

- ALERT- patient opens his eyes, looks you, responds fully and appropriately to normal tone voice stimuli.
- Lethargy –patient are drowsy but opens his eyes and looks at you in response to loud voice and immediately falls asleep.
- Obtundation -patient opens his eyes and looks at you but respond slowly and are somewhat confused.

Posture and Motor Behavior:

- ✓ Does the patient lie in bed, or prefer to walk about?
- ✓ Note body posture and the patient's ability to relax.
- ✓ Observe the pace, range, and character of movements.
- ✓ Do they seem to be under voluntary control?

- How is the patient dressed? Is clothing clean, and properly fastened?
- Note the patient's hair, nails, teeth, skin, and, if present, beard. How are they groomed?
- How do the person's grooming and hygiene compare with those of other people of comparable age, lifestyle, and socioeconomic group?

MENTAL STATUS

II. Mood

- ✓ The appropriateness of the patient's mood or affect is noted.
- ✓ E.g. If the patient smiles while experiencing severe chest pain, this is considered as inappropriate mood (In mania and depression)

- The patient's speech reveals important information about his mental function and emotional status.
- Assess the fluency (aphasia):- spontaneous speech, naming, repetition, reading, writing, comprehension, drawing

Cont,....

IV. THOUGHT AND PERCEPTION

- ✓ Observe the patient for logic and coherence.
- ✓ Any unusual aspects of thought, illusions or delusions, hallucinations and insight.

V. Cognitive function:

- ✓ Orientation to time, place, and person.
- ✓ Assess the three aspects to memory, which usually becomes obvious during the interview.

Cont,.....

1. Immediate- recall by saying a series of numbers and having the patient repeat them.
2. Recent memory- by asking the patient to recall something after 5 minutes has elapsed.
3 . Remote memory- refers to events in the distant past.

Reading assignment

ASSESSMENT OF CRANIAL NERVES and MOTOR FUNCTION TEST The Sensory System

NEUROLOGIC DYSFUNCTION

Headache(cephalgia)

- Headache is actually a symptom rather than a disease entity.
- it may indicate organic disease (neurologic or other disease), a stress response, vasodilation (migraine), skeletal muscle tension (tension headache), or a combination of factors.
- Brain parenchyma is not pain sensitive

Cont,.....

- A **primary headache** is one for which no organic cause can be identified. These types of headache include **migraine, tension-type, and cluster headaches.**
- A **secondary headache** is a symptom associated with an organic cause, such as a brain tumor or an aneurysm

Classification of headache based on pathophysiological

1. Vascular headache
    - Migraine headache
    - Cluster headache
    - Miscellaneous (orgasmic, Hangover)
2. Cranial Neuralgias
3. Tension headache

Cont,……

4. Traction –inflammation headache

- Cranial arteritis
- Meningitis
- Brain tumor
- Increased /Decreased ICP

Cont,....

5. Extra cranial lesions

- Paranasal sinusitis
- Dental problems
- Ear problems
- Ocular problems
- Cervical problem

Assessment and Diagnosis

- Appropriate history
- Vital signs (blood pressure, temperature)
- Head and neck examination: scalp tenderness, sinus tenderness, examination of the oral cavity and tempro mandibular joint.
- Ophthalmologic evaluation

A.Migraine Headache

- Migraine headache is a benign and episodic disease, characterized by headache, nausea, vomiting and photophobia.
- Causes often unknown but family history, Environmental, dietary and psychological factors.

1.Prodromal phase

- The prodrome phase is experienced by 60% of patients, with symptoms that occur hours to days before a migraine headache.
- Symptoms may include depression, irritability, feeling cold, food craving, anorexia, change in activity level, increased urination, diarrhea, or constipation.

2.Aura Phase

- Lasts less than 1 hour.
- This period is characterized by focal neurologic symptoms and visual disturbances (i.e., Light flashes and bright spots) are most common and may be hemianopic (affecting only half of the visual field).
- Other symptoms include numbness and tingling of the lips, face, or hands; mild confusion; slight weakness of an extremity; drowsiness; and dizziness.

3.Headache Phase

- A throbbing headache (unilateral in 60% of patients) intensifies over several hours.
- This headache is severe and incapacitating and is often associated with photophobia, nausea, and vomiting.
- Its duration varies, ranging from 4

4.Recovery Phase

- In the recovery phase (termination and postdrome), the pain gradually subsides.
- Muscle contraction in the neck and scalp is common, with associated muscle ache and localized tenderness, exhaustion, and mood changes.
- Any physical exertion exacerbates the headache pain.
- During this post-headache phase, patients may sleep for extended periods.

Characteristic Migraine head ache is:-

- ☑ Moderate to severe head pain, pulsating quality often unilateral
- ☑ It is exacerbation by physical activity and relived by sleeping.
- ☑ It is often associated with Nausea and/or vomiting, photophobia.
- ☑ Multiple attacks may occur, each lasting 4 – 72 hrs.

Management

- **The abortive approach**, best used in those patients who have less frequent attacks, is aimed at relieving or limiting a headache at the onset or while it is in progress.
- **The preventive approach** is used in patients who experience more frequent attacks at regular or predictable intervals and may have a medical condition that precludes the use of abortive therapies.

Acute/abortive treatment of migraine

- **NSAIDS (Nonsteroidal antinflamatory agents)**
- The triptans, serotonin receptor agonists, are the most specific antimigraine agents available.
  - These agents cause vasoconstriction, reduce inflammation, and may reduce pain transmission.

1. Acute treatment, mild attacks:

I.Acetylsalicylic acid, soluble, 600-900mg P.O., once, followed by 300 mg half hourly

up to a maximum dose of 1800mg or

II.Paracetamol, 1000mg P.O., 4-6 hourly. > 4gm/day is associated with liver toxicity.Initiate therapy during the attack or at the very onset of the headache.or

III.Ibuprofen, 600-1,200mg/day P.O., in 2-3 divided doses or

IV.Diclofenac, 50-100mg P.O., or IM per day

2.Moderate to severe attacks

First line

I.Sumatriptan, 50mg, P.O., once, taken with fluids. If asatisfactory response is not obtained at 2 hours, a second dose can be given.The total daily dose should not exceed 200mg.

Alternatives

II.Ergotamine tartrate and Caffeine, 1mg +100mg P.O., 1-2 tablets immediately,followed by 1/2-1 tablet every 30 minutes to a maximum of 4 tables per attack or 10 tablets per week, or until vomiting

Cont,.....

3. Antiemetics — IV metoclopramide 10mg

4. Prevention of early recurrence-add to abortive therapy to prevent early recurrence.

Dexamethasone, 12-24mg, IV, stat.

5.Long term prophylaxis

First line

I.Propranolol, 80mg/day in divided doses; increase by 20-40mg/dose every 3-4 weeks to a maximum of 160-240mg/day)

Cont,.....

II.**Amitriptyline**, 10-25mg P.O., at bed time, titrate dose up to adequate response. It seldom requires more than 75-150mg as a single bedtime dose.

Alternative

I.**Carbamazepine**, P.O., start at 100mg/day, titrate to 200-600mg TID

OR

II.Verapamil, P.O., start at 120mg/day divided in 2 doses to 720mg/day

Cont,....

- The five triptans in routine clinical use include sumatriptan (Imitrex), naratriptan (Amerge), rizatriptan (Maxalt), zolmitriptan (Zomig), and almotriptan.

- Dopamine agonists
- Ergotamine preparation

Preventive Therapy

- Prophylactic treatment is indicated if the patient has three or more attacks per month.
- Drugs used for this purpose include β-blockers (propranolol),Tricyclic antidepressants (amitriptyline), and Calcium channel blockers (Verapamil), Valproic acid.
- Start with low dose and gradually increase if there is no adequate response.

B.Cluster Headache

- Severe, acute headache that occurs in clusters lasting several weeks followed by pain free intervals that averages a year.
- Unilateral and come in clusters of 1-8 daily.
- Pain localized to the eye and orbit and radiating to the facial and temporal regions.
- The pain is accompanied by watering of the eye and nasal congestion.

Cont,……

- Each attack lasts 30 to 90 minutes.
- It has rapid onset without warning.
- It is also severe and explosive in quality lasting 30 min to 2hrs, subsiding abruptly.

Management

Acute attack /abortive therapy (Treatment)

- Inhalation of 100% oxygen and
- **Sumatriptan** 6 mg S.C. stat

Preventions/prophylactic therapy:

- Prednisolone , Lithium, Methysergide, Ergotamine, Sodium valproate and verapamil

3.Tension headache (Tension type headache)

- Steady, constant feeling of pressure that usually begins in the forehead, or back of the neck.
- It is often band like or may be described as “a weight on top of my head.”

Causes

- ✓ Stress – usually occurs in the afternoon after long stressful work hours
- ✓ Sleep deprivation
- ✓ Uncomfortable stressful position and/or bad posture.
- ✓ Hunger (Irregular meal time)
- ✓ Eye strain resulting from continuous TV watching, working on computer screen for a long time.

S/S

- Headache mild or moderate, pain is a constant, tight, pressing or band like sensation in the frontal, temporal, occipital or parietal area.
- Usually lasts less than 24 hrs
- On examination some patients may have tender spots in the pericranial or cervical muscles.

management

Abortive therapy/acute treatment

- Paracetamol, ASA, Ibuprofen, and Diclofenac.
- If treatment is unsatisfactory addition of caffeine or other analgesic is beneficial.

Cont,.....

Long term preventive therapy

- This kind of treatment is indicated if the headache is : Frequent (> 2 attacks / week), Of long duration (> 3hrs) Severe (cause significant disability).
- Commonly used drug for long term treatment is Amitryptilline.

SEIZURE

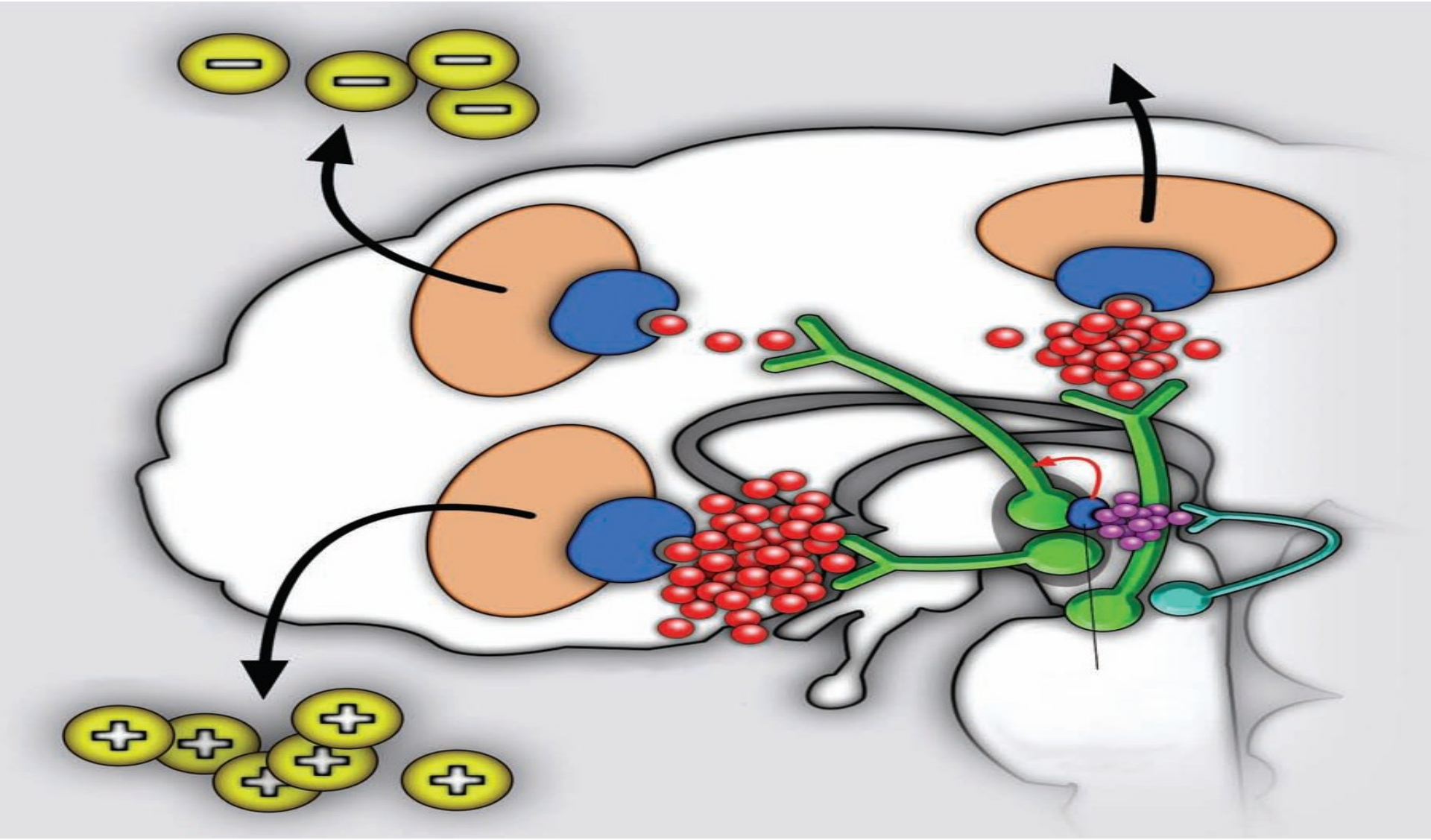

- Seizures are episodes of abnormal motor, sensory, autonomic, or psychic activity (or a combination of these) resulting from sudden excessive discharge from cerebral neurons.
- A part or all of the brain may be involved.
- Most seizures are sudden and transient.

Two main types:-

- **Partial seizures** that begin in one part of the brain, and
- **Generalized seizures** that involve electrical discharges in the whole brain.

Cont,....

- The underlying cause is an electrical disturbance (dysrhythmia) in the nerve cells in one section of the brain, causing them to emit abnormal, recurring, uncontrolled electrical discharges.
- There may be associated loss of consciousness, excess movement or loss of muscle tone or movement, and disturbances of behavior, mood, sensation, and perception.

Cont,.....

- The specific causes of seizures are varied and can be categorized as:
  - Idiopathic (genetic, developmental defects)
  - Acquired.
- Cerebrovascular disease is the leading cause of seizures in the elderly.

Cont,.....

Among the causes of acquired seizures are:

- Hypoxemia of any cause, including vascular insufficiency, fever (childhood),
- Head injury, hypertension, central nervous system infections,
- Metabolic and toxic conditions (e.g., Renal failure, hyponatremia, hypocalcaemia, hypoglycemia, pesticides),
- Brain tumor, drug and alcohol withdrawal, and allergies.

EPILEPSY

EPILEPSY

- Describes a condition in w/c a person has recurrent seizures due to a chronic underlying process. / With evidence of reversible metabolic cause/
- Epilepsy is a group of syndromes characterized by recurring seizures.
- The basic problem is an electrical disturbance

Cont,.....

Causes – Idiopathic

- Birth trauma, asphyxia neonatorum
- Head injuries
- Infectious disease
- Toxicity
- Circulatory problem fever metabolic and nutritional disorder
- Brain tumors, abscess and congenital malformation

Pathophysiology

- Messages from the body are carried by the neurons (nerve cells) of the brain by means of discharges of electrochemical energy that sweep along them.
- These impulses occur in bursts whenever a nerve cell has a task to perform.
- Sometimes, these cells or groups of cells continue firing after a task is finished.

Cont,....

- During the period of unwanted discharges, parts of the body controlled by the errant cells may perform erratically.
- Resultant dysfunction ranges from mild to incapacitating and often causes unconsciousness.
- When these uncontrolled, abnormal discharges occur repeatedly, a person is said to have an epileptic syndrome.
- Epilepsy is not associated with intellectual level.

classification

- Partial seizures are focal in origin and affect only part of the brain.
- Generalized seizures are non specific in origin and affect the entire brain simultaneously.
- Unclassified seizures are so termed because of incomplete data.

Cont,.....

1. Partial Seizures

- Simple partial seizure (with motor sensory autonomic or psychic signs)
- Complex partial seizure
- Partial seizure with secondary generalization

2. Primarily generalized seizures

- Absence (Petit mal)
- Tonic – clonic (grand mal)
- Tonic
- Atonic
- Myoclonic

- Neonatal Seizures
- Infantile Spasms

Partial Selzures

- Occurs within discrete regions of the brain
- Consciousness is fully preserved during the seizure
- The clinical picture is relatively simple and is termed simple partial if consciousness is not altered.
- If symptomatoloty is more complex & the seizure is termed **complex partial seizure.**

Simple Partial Seizures

- Cause motor, sensory, autonomic or psychic symptom with out an obvious alteration in consciousness.
- Only a finger or hand may shake or the mouth may jerk uncontrollably.
- Unusual or unpleasant sights, sounds, odors or tastes but without loss of consciousness.

Cont,.....

Three additional features of partial motor seizures are

1. The abnormal motor mov't may begin in a very restricted region such as the fingers and gradually progress (over seconds to minutes) to include a larger portion of the extremity.

- This phenomenon, known as a "jacksonian march," represents the spread of seizure activity over a progressively larger region of motor cortex.

Cont,...

2)Patients may experience a localized paresis (todd's paralysis) for minutes to many hours in the involved region following the seizure.

3)In rare instance the seizure may continue for hours or days. This conditions termed as ***epilepsia partialis continua***.

Complex Partial Seizures

- Characterized by focal seizure activity accompanied by a transient impairment of the pt's ability to maintain normal contact with the env't.
- The patient is unable to respond appropriately to visual or verbal commands during the seizure and has impaired recollection or awareness of the ictal phase.
- The seizures frequently begin with an aura (i.e., a simple partial seizure) that is stereotypic for the patient.

Cont,....

- ✓ The start of the ictal phase is often a sudden behavioral arrest or motionless stare, which marks the onset of the period of amnesia or loss of memory.
- ✓ The behavioral arrest is usually accompanied by automatisms, which are involuntary, automatic behaviors that have a wide range of manifestations.
- ✓ Automatisms may consist of very basic behaviors such as chewing, lip smacking, swallowing, or “picking” movements of the hands, or more elaborate behaviors such as a display of emotion or running.

Partial Seizures with secondary Generalization

- Can spread to involve both cerebral hemispheres and produce generalized seizure.
- Motionless or moves automatically but inappropriately for time and place.
- Experience excessive emotions of fear, anger elation or irritability
- The person does not remember the episode when it is over.

Generalized Seizure / Grand mal Seizure/

- Arise from both hemispheres simultaneously (bilateral clinical and electrographic events with any detectable focal onset)
- Intense rigidity of the entire body followed by jerky alternations of muscle relaxation and contraction.

Generalized tonic clonic Seizure

- Is the most common seizure type.
- The seizure usually begins abruptly without warning (no aura or focal manifestations.)

Cont,.....

The Ictal Phase is begins with tonic contraction of muscles throughout the body , which is responsible for:

- Loud moan or cry (due tonic contraction of the muscles of respiration and the larynx), tonic posturing, respiration is impaired and the patient falls to the ground, and
- There may be tongue biting due to tonic contraction of the jaw muscles.

Cont,....

- After 10 – 20 seconds the tonic phase evolves to clonic phase characterized by bilateral jerking clonic movement involving the whole body. This lasts for another 1 minute.
- The Post-ictal Phase is characterized by unresponsiveness, muscle flaccidity, excessive salivation and frothing of saliva which may cause stridorous breathing and partial airway obstruction.

Cont,……

- Bladder or bowel incontinence may occur at this point.
- Patients gradually regain consciousness over minutes to hours, and during this transition there is typically a period of post-ictal confusion, headache, muscle ache and fatigue that can last for many hours.

Absence Seizures (Petit Mal)

- Characterized by sudden, brief lapses of consciousness with loss of postural control.
- The seizure typically lasts for only few seconds, consciousness returns as sudden as it was lost.
- It usually manifests with blank staring and they may have also subtle motor manifestations like blinking of the eyes, chewing movements.

Cont,.....

- There is no post-ictal confusion.
- The seizure may occur as many as hundreds of times per day.
- It is usually detected by unexplained day dreaming and decline in school performance.
- It usually begins in childhood (4- 8 yrs) , and it often has a good prognosis.

Atonic Seizures

- Sudden loss of postural muscle tone lasting 1-2s:
- Consciousness is briefly impaired
- No post-ictal confusion
- Very brief seizure may cause only a quick head drop or nodding movement while longer seizure will cause the patient to collapse.

Myoclonic Seizures

- Sudden and brief muscle contraction that involve one part of the body or the entire body.
- Sudden jerking movement observed while falling asleep is common physiologic form of myoclonus.
- Pathologic – most commonly seen in association with metabolic disorder degenerative CNS disease or anoxic brain injury.

Diagnostic Evaluation

- History
- Physical and neurological exam
- EEG / Electroencephalogram/
- CT. Scan, Skull x-ray, serum glucose,
- Lumbar Puncture, cerebral angiography

Management

1st rule of RX – To protect the person from injury.

2nd rule of RX – To treat any underlying disease

- Reduce the frequency of seizure
- Bring seizure under control

* If possible single drug should be in epilepsy to eliminate drug interaction and adverse effects.

Cont,....

When do we start anti epileptic drugs?

- Recurrent seizure of unknown cause or a known cause that cannot be reversed
- Single seizure due to :
  - Identified CNS lesion (tumor, infection, trauma)
  - With abnormal neurologic exam

Cont,……

- Presenting as status epilepticus
- With post-ictal Todd’s paralysis
- With strong family history of seizure disorder
- With abnormal EEG

Cont,.....

- An attempt is usually made to prevent subsequent seizure using a single agent , in order to limit side effects.
- The drugs should be administered in progressive dose until seizure control has been achieved or until drug toxicity

Cont,....

- Only if monotherpay fails should a second drug be added to the patient's regimen. If control is achieved, then the first agent might be carefully withdrawn.
- A number of drugs are available for treatment of epilepsy and the choice of medication is based on the seizure type

Table VIII-5-1 Selection of antiepileptic drugs

	Primary GTCS	Partial	Absence	Atypical absence, myoclonic, Atonic
First line	Valproic acid Lamotrigine	Carbamazepine Phenytoin Valproic acid	Valproic acid Ethusuximide	Valproic acid
Second line	Phenytoin Carbamazepine Phenobarbitone	Topiramate Phenobarbitone	Lamotrigin Clonazepam	Lamotrigin Clonazepam Topiramate

When to stop antiepileptic drugs?

- It is common practice to continue treatment until the patient has been seizure free for at least 3 years.
- Thereafter, consideration of drug withdrawal is based on a number of factors like:-
  - ❖ The ease with which control was achieved starting from the time of AED drug initiation.

Cont,.....

- ❖ The type of seizure
- ❖ The presence of other neurological co-morbidity e.g. mental retardation, focal neurological deficit.

- The probability of relapse after stopping treatment is somewhere around 10-40%

Patient Teaching

- Teach the patient family how to care for the pt during a seizure.
- Help the patient to a lying position; loosen any tight clothing place something soft under head.
- Remove any hard objects

Cont,...

- Avoid forcing anything into the patient mouth if his teeth are clenched.
- Protect patient tongue if his mouth opens by placing soft object b/n his teeth.
- Turn his head to the side to provide an open airway.

STATUS EPILEPTICUS

- A condition characterized by continuous or repetitive discrete seizure with impairment of consciousness during inter-ictal period, which lasts for more than 30 minutes.

It can be caused or precipitated by

- CNS infections, Metabolic derangement, Tumors
- Trauma and Stroke

Medical Management

- The goals of treatment are to stop the seizures as quickly as possible, to ensure adequate cerebral oxygenation, and to maintain the patient in a seizure-free state.
- If the patient remains unconscious and unresponsive, a cuffed endotracheal tube is inserted.

Cont,....

- The goals of treatment are to stop the seizures as quickly as possible, to ensure adequate cerebral oxygenation, and to maintain the patient in a seizure-free state.
- If the patient remains unconscious and unresponsive, a cuffed endotracheal tube is inserted.

Cont,.....

Control the seizure with anticonvulsant

- 1st step: Lorazepam 0.1 mg/kg IC at a rate of 2mg/min or Give diazepam IV 5-10 mg IV
- 2nd step: Phenytoin 20 mg/kg IV at a rate of 50 mg /min if seizure continues

Cont,.....

- 3rd step: Phenobarbital 20 mg/kg IV at a rate of 50 -75 mg/min, if seizure still continues
- 4th Step: General anesthesia with Medazolam, pentobarbitol, if seizure becomes refractory.

Cont,....

- ✓ In resource limited setting Diazepam 5-10 mg IV is given 2-3 times, and if the seizure is not controlled Phenytion 1000 mg PO is given through NG tube. Phenobarbitone can also be used.
- ✓ Give maintenance antiepileptic drug: after the acute condition is controlled.
- ✓ An intravenous infusion of dextrose is given if the seizure is due to hypoglycemia.

MANAGEMENT OF PATIENTS WITH CEREBROVASCULAR DISORDERS

Cerebrovascular Disorders

- Cerebrovascular disorders” is an umbrella term that refers to any functional abnormality of the central nervous system (CNS) that occurs when the normal blood supply to the brain is disrupted.

stroke

Strokes can be divided into two major categories:

- Ischemic (85%), in which vascular occlusion and significant hypoperfusion occur.
- Hemorrhagic (15%), in which there is extravasation of blood into the brain or subarachnoid space.

Classification of stroke

A. Ischemic

- Embolic
- Thrombotic
  - Large vessel disease: resulting from narrowing of cerebral arteries doe to atherosclerosis.
  - Small vessel disease (Lacunar infarct)
  - Miscellaneous:E.g. Vasculitis resulting thrombus formation

Cont,....

B. Hemorrhagic Stroke: accounts for 10-20 % of cerebrovascualr accidents.

- It is a much more commoner cause of stroke in developing countries , mainly associated with poorly controlled hypertension

1. Primary Intracerebral Hemorrhage (PICH)
2. Subarachnoid Hemorrhage (SAH)

Classification based on the duration of stroke

- **Transient Ischemic attack:** are focal neuralgic deficit lasting < 24hrs confined to an area of brain perfused by specific artery , and neurologic deficit resolves in less than 24 hours.
- **Reversible Ischemic neurologic deficit:** sudden onset focal neurologic deficit which lasts for more than 24 hours, but the neurologic deficit recovers / resolves /.

Cont,.....

- **Stroke in evolution:** a focal neurologic deficit, the degree of which is progressing over a couple of hours or days.
- **Complete stroke:** sudden onset of focal neurologic deficit, in which the deficit neither improves nor gets worse over time. It is often associated with infarction of part of the brain.

Risk factors for stroke

- Incidence is higher in men and old age
- Hypertension
- Smoking
- Diabetic mellitus
- Hyperlipidemia
- Atrial fibrillation, Myocardial infarction
- Congestive heart failure and Acute alcohol abuse

Pathophysiology (Ischemic Strock)

- Disruption of the cerebral blood flow due to obstruction of a blood vessel
- Initiates a complex series of cellular metabolic events referred to as the ischemic cascade.
- Neurons can no longer maintain aerobic respiration.

Cont,...

- The mitochondria must then switch to anaerobic respiration, which generates large amounts of lactic acid, causing a change in the pH level.
- The neuron incapable of producing sufficient quantities of (ATP) to fuel the depolarization processes.
- Thus, the membrane pumps that maintain electrolyte balances begin to fail and the cells cease to function.

Clinical Manifestations

- Numbness or weakness of the face, arm, or leg, especially on one side of the body
- Confusion or change in mental status
- Trouble speaking or understanding speech, Visual disturbances.
- Difficulty walking, dizziness, or loss of balance or coordination and Sudden severe headache.

Motor Loss

- The most common motor dysfunction is hemiplegia(paralysis of one side of the body) caused by a lesion of the opposite side of the brain.
- Hemiparesis,or weakness of one side of the body
- In the early stage of stroke, the initial clinical features may be flaccid paralysis and loss of or decrease in the deep tendon reflexes.

Communication Loss

Dysfunctions of language and communication:

- Dysarthria(difficulty in speaking), caused by paralysis of the muscles responsible for producing speech.
- Dysphasia (impaired speech) or aphasia (loss of speech), which can be expressive aphasia, receptive aphasia, or global (mixed) aphasia.

Cont,.....

- Apraxia(inability to perform a previously learned action), as may be seen when a patient makes verbal substitutions for desired syllables or words

Assessment and Diagnostic Findings

- ✓History
- ✓CT scan performed emergently
- ✓Electrocardiogram and a carotid ultrasound are standard tests.
- ✓Cerebral angiography.
- ✓Doppler flow studies.
- ✓Echocardiography, magnetic resonance imaging of the brain.
- ✓Carotid angiography

Management

- Maintenance of air way and ventilation
- Control of blood pressure
- Control of body temperature.
- Fluid management

Glucose is said to be neuro-toxic and it is better avoided in patients with stroke.

Cont,....

If the patient is comatose or has impaired mental status

- Changing the patients position every 2 hrs and avoid the occurrence of bed sores
- Bladder and bowel care: if the patient has incontinence – catheterize.
- Infections such as aspiration pneumonia should be treated with antibiotics.

Specific Management

1) Atherosclerotic stroke (Thrombotic stroke)

i) Thrombolytic therapy: in developed countries thrombolytic therapy with medications such as t-PA (plaminogen activator), to patients who present within 3hrs of onset of stroke helps to lyse the thrombus and restore perfusion to the affected brain.

Contraindications:

- Extensive infarct on CT,
- Recent surgery, Head trauma
- GI or urinary hemorrhage, bleeding disorders
- Seizure at stroke onset
- Severe uncontrolled hypertension.

Cont,.....

ii) Anticoagulants: use of Heparin and Warfarin. Low dose heparin can be given for prevention of thromboembolism.

iii) Anti-platelet aggregation agents: Aspirin 325 mg.

- It may not help to resolve the already formed thrombus, but ASA prevents recurrence of stroke.

2) Embolic stroke: (Cardiogenic embolus)

- Anticoagulation is indicated to prevent recurrent embolic stroke.
- Anticoagulation with heparin should be initiated when the acute phase of stroke is over.
- Warfarin is used for chronic anticoagulation.

Hemorrhagic Stroke

- Hemorrhagic stroke involves bleeding within the brain, which damages nearby brain tissue.
- Caused by an intracranial or subarachnoid hemorrhage.
- Caused by uncontrolled hypertension, arteriovenous malformations (AVMS), intracranial aneurysms, or certain medications (e.g, anticoagulants and amphetamines).
- More severe deficits and a longer recovery time compared to those with ischemic stroke.

Pathophysiology

- ✓ Aneurysm or AVM enlarges and presses on nearby cranial nerves or brain tissue OR
- ✓ Aneurysm or AVM ruptures, causing subarachnoid hemorrhage.
- ✓ Normal brain metabolism is disrupted by the brain being exposed to blood; by an increase in ICP, reduced perfusion pressure and vasospasm that frequently accompany subarachnoid hemorrhage.

Management

1) Intracerebral hemorrhage

- Continue supportive measures
- Control very high blood pressure
- Surgical consultation is indicated for removing cerebellar hematoma, as it may compress vital centers in the brainstem.

2) Subarachnoid Hemorrhage

- Supportive measures include bed rest, sedatives, analgesic, laxative,
- Control of hypertension
- Nimodipin (calcium channel blocker) is given to prevent neurologic deterioration due to vasospasm.
- **Surgical therapy**: Saccular aneurysms are treated surgically

Prevention of further stroke:

- Control of hypertension
- Control blood sugar in diabetics and Ceasation of smoking
- Physical activity and weight reduction
- Anticoagulation for atrial fibrillation
- ASA 75 mg Po daily in individuals older than 50 and have history of TIA (Transient Ischemic Attack)
- Surgery (Endarterioactomy): if a narrowed artery is detected

MANAGEMENT OF PATIENTS WITH NEUROLOGIC TRAUMA

Head Injuries

- Head injury is a broad classification that includes injury to the scalp, skull, or brain.
- A head injury may lead to conditions ranging from mild concussion to coma and death; the most serious form is known as a traumatic brain injury (TBI).

Cont,....

- The most common causes of TBIs are falls (28%), motor vehicle crashes (20%), being struck by objects (19%), and assaults (11%).
- People at highest risk for TBI are those in the 15-19-year age group.
- Males are twice as likely as females to sustain a TBI.

Cont,...

- Damage to the brain from traumatic injury takes two forms: primary injury and secondary injury.

Primary injury is the initial damage to the brain that results from the traumatic event.

- This may include contusions, lacerations, and torn blood vessels due to impact, acceleration/deceleration, or foreign object penetration.

Cont,....

- **Secondary injury** evolves over the ensuing hours and days after the initial injury and results from inadequate delivery of nutrients and oxygen to the cells

Skull Fractures

- A skull fracture is a break in the continuity of the skull caused by forceful trauma.
- It may occur with or without damage to the brain.
- Can be classified as simple, comminuted, depressed, or basilar.
- A simple (linear) fracture is a break in the continuity of the bone.

Cont,.....

- A comminuted skull fracture refers to a splintered or multiple fracture line.
- Depressed skull fractures occur when the bones of the skull are forcefully displaced downward and can vary from a slight depression to bones of the skull being splintered and embedded within brain tissue.

Cont,...

- A fracture of the base of the skull is called a basilar skull fracture .
- A fracture may be open, indicating a scalp laceration or tear in the dura (eg, from a bullet or anice pick), or closed, in which case the dura is intact.

Cont,....

- Basal skull fractures can occur at different sites (anterior, middle or posterior fossa). They often result in CSF leak.
- Anterior fossa fractures present with subconjuctival hematoma, anosmia, epistaxis and CSF rhinorrhoea.
- Middle fossa fracture presents with CSF rhinorrhea or otorrhea, and ecchymosis (bruising) may be seen over the mastoid(Battle's sign).

Brain injuries

Mechanisms of brain injury

- Abrupt deceleration of a moving head results in minor injury at site of impact (coup injury) or contusion of the brain opposite the point of impact (contra coup injury).
- From clinical point of view, brain injuries could be primary (occurring at the time of impact) or secondary (develops subsequently).

Medical Management

- Non depressed skull fractures generally do not require surgical treatment; however, close observation of the patient is essential.
- Depressed skull fractures usually require surgery with elevation of the skull and débridement, usually within 24 hours of injury.

Primary brain injury

Cerebral concussion

- A cerebral **concussion after head injury is a temporary loss of** neurologic function with no apparent structural damage.
- A concussion generally involves a period of unconsciousness lasting from a few seconds to a few minutes.

Cont,....

- This is a clinical diagnosis characterized by temporary dysfunction.
- It is most severe immediately after injury and resolves after variable period of time.

Cont,.....

There are two types of concussion: mild and classic.

- ✓ A mild concussion may lead to a period of observed or self reported transient confusion, disorientation, or impaired consciousness.
- ✓ Commonly, there is a memory lapse at the time of injury and a loss of consciousness lasting less than 30 minutes.
- ✓ Other signs and symptoms may include seizures, headache, dizziness, irritability, fatigue, or poor concentration.

Cont,.....

- A classic concussion is an injury that results in a loss of consciousness; characteristically, this usually lasts less than 6 hours.
- This loss of consciousness is always accompanied by some degree of posttraumatic amnesia.

Cont,……

Cerebral contusion and Laceration

- Cerebral **contusion is a more severe injury in which the brain** is bruised, with possible surface hemorrhage.
- The patient is unconscious for more than a few seconds or minute
- Pia and arachnoid tearing and intracerebral bleeding characterize these conditions.

Cont,....

- It usually produces focal neurologic deficits that persist for more than 24 hours.
- Blood brain barrier defects and cerebral edema are common.
- Contusions may resolve spontaneously or persist.

Intracranial hematomas

Extradural hematoma: this condition usually follows temporal bone fracture with tearing of middle meningeal artery leading to hematoma collection.

- Patients may present in coma after a lucid interval.
- Urgent evacuation of the hematoma is required.

Cont,....

- **Acute Sudbural hematoma:** this state is the most common intracranial mass lesion following head injury.
- Mostly, it results from tearing of bridging veins.
- The lesion is rapidly evolving and early evacuation is mandatory.

Cont,.....

Chronic subdural hematoma: this is most common in infants and adults over 60 years of age.

- ✓ Patients usually present with progressive neurological deficit more than 2 weeks after the trauma.

Intracerebral hematoma: results from areas of contusion coalescing into contusion hematoma.

Cont,…

Cerebral swelling (Brain edema)

- This results from vascular engorgement, due to loss of auto regulation and increased extra and intracellular fluid.
- If not corrected early, it results in cerebral ischemia.

Infections

- Compound depressed fractures or basal skull fractures can lead to meningitis or cerebral abscess.

MENINGITIS

MENINGITIS

- Is an inflammation of the meninges, the protective membranes that surround the brain and spinal cord.

Is classified as aseptic or septic

- **Aseptic meningitis,** bacteria are not the cause of the inflammation; the cause is viral or secondary to lymphoma, leukemia, or human immunodeficiency virus (HIV).

Cont,.....

- The bacteria streptococcus pneumoniae and neisseria meningitides are responsible for 80% of cases of meningitis in adults.

Cont,.....

- Septic meningitis refers to meningitis caused by bacteria, most commonly Neisseria meningitidis, although Haemophilus influenzae and Streptococcus pneumoniae.

Rout of infection

- Droplet infection through the upper airways: E.g. Meningococcus meningitis, with possibly epidemic spread
- Haematogenous spread: e.g. in Pneumococcus pneumonia
- Contagious spread from adjacent sites : e.g. in otitis media , sinusitis.
- Direct: e.g. in open head injury

Pathophysiology

- Once the causative organism enters the bloodstream, it crosses the BBB and proliferates in the CSF.
- The host immune response stimulates the release of cell wall fragments and lipopolysaccharides, facilitating inflammation of the subarachnoid and pia mater.

Cont,……

- Because the cranial vault contains little room for expansion, the inflammation may cause increased intracranial pressure (ICP).
- CSF circulates through the subarachnoid space, where inflammatory cellular materials from the affected meningeal tissue enter and accumulate.

Clinical Manifestations

- Headache and fever are frequently the initial symptoms.
- **Neck mobility:** A stiff and painful neck (nuchal rigidity) can be an early sign and any attempts at flexion of the head are difficult because of spasms in the muscles of the neck.
- **Positive Kernig's sign:** When the patient is lying with the thigh flexed on the abdomen, the leg cannot be completely extended.

Cont,...

- **Positive Brudzinski's sign:** When the patient's neck is flexed , flexion of the knees and hips is produced; when the lower extremity of one side is passively flexed, a similar movement is seen in the opposite extremity.
- Photophobia (extreme sensitivity to light): This finding is common, although the cause is unclear.

Assessment and Diagnostic Findings

- History, physical examination,
- Search for possible source of infection(pneumonia , otitis media , sinusitis , head injury)
- CSF analysis
- Identify the organism from CSF and blood (culture, PCR etc.)
- Serologic antibody test : latex agglutination test

Cont.

	Bacterial meningitis	Viral meningitis	Tuberculosis meningitis	Normal Values
Appearance	Turbid	Clear	Cob-web	Colorless
Cell count/µl	Several thousand	Several hundreds	Several hundreds	
Cell type	Granulocytes(PMNLs)	Lymphocytes	Lympho-,monocytes	
Glucose	↓ (< 30 mg/dl)	Normal	↓ (< 30 mg/dl)	50–75 mg/dL; 50%–80% of blood glucose value
Protein	↑ (> 120 mg/dl)	Normal	↑ (> 120 mg/dl)	15–45 mg/dL

Management

Empirical antibiotic therapy:

- Bacterial meningitis is a medical emergency and antibiotics should be initiated immediately before the results of the CSF gram stain and culture are known. Antibiotics should be given intravenously, at higher doses.
- Ceftriaxone 2 gm IV BID plus Ampicilline 2 gm IV QID for 2 weeks.

Cont,.....

- Crystalline Penicillin 3-4 million IU, IV every 4 hours plus Choramphnicole 1gm IV QID are alternative antibiotics for a resource limited setting
- Patients with ENT infection or head injury: Ceftriaxone 2 gm IV BID and Vancomycin 1gm IV BID + treatment of the underlying cause.

Cont,....

- If suspected hospital-acquired infection: Ceftriaxone 2 gm IV BID plus Vancomycin 1 gm IV BID plus Gentamycin (80 mg TID)
- In immunodeficient patients: Ceftriaxone 2 gm IV BID plus Vancomycin 1 gm IV BID plus Ampicillin (2g IV QID).

Specific antibiotic therapy

- Is given when the specific etiologic agent is identified through gram stain or culture
- ***N. Meningitidis*** *:* even though ceftriaxone or cefotaxim provide adequate empirical coverage , penicillin G remains the drug of choice for *N. Meningitides*
- Crystalline penicillin 3-4 million IU, IV every 4 hours for 7 -10 days may be adequate.

Cont,....

Pneumococcal meningitis:

- Ceftriaxone 2 gm IV BID and Vancomycin 1 gm IV BID for 2 weeks

H. influenza: Ceftriaxone 2 gm IV BID for 1- 14 days

- Choramphnicole 1gm IV QID may be an alternative antibiotic, for patients who may not afford Ceftriaxone.

Symptomatic and adjunctive Therapy

Steroids:

- Dexamethason10 mg IV 15-20 minutes before the first dose of antibiotics and 4 mg IV QID for 4 days
- Dehydration and shock are treated with fluid volume expanders.
- Seizures, which may occur in the early course of the disease, are controlled with phenytoin (Dilantin).

Treat increased intracranial pressure

- Elevation of the patients head to 30-45
- Intubation and hyperventilation (till PaCO2 is lowered to 25-30 mmHg)
- Mannitol IV infusion

HERPES SIMPLEX VIRUS ENCEPHALITIS

HERPES SIMPLEX VIRUS ENCEPHALITIS

- Encephalitis is an acute inflammatory process of the brain tissue.
- It is inflammation of the brain parenchyma, with or without involvement of the meninges, caused by virus.
- The spinal cord and/or nerve roots may also involved rarely.

Cont,....

- Herpes simplex virus (HSV) is the most common cause of acute encephalitis.
- There are two herpes simplex viruses, HSV-1 and HSV-2. HSV-1 typically affects children and adults.
- Viruses causing encephalitis Arboviruses, enteroviruses, mumps

Clinical Manifestations

- Acute febrile illness with meningeal signs
- Altered LOC
- Abnormal mental state (hallucinations, agitation, personality change, behavioral disorder)

Cont,……

- Evidence of either focal or diffuse neurologic signs or symptoms.
- Focal or generalized seizures.
- Most common focal findings are aphasia, ataxia, hemiparesis (with hyperactive tendon reflexes), involuntary movements and cranial nerve deficits.

Diagnostic findings

- CSF examination: Serologic studies and antigen detection, if available
- MRI, CT, and EEG
- HSV-1 infection has abnormalities in the temporal lobe on MRI.
- Brain biopsy: reserved for patients with unclear diagnosis, lack of response to therapy and who have abnormalities on imaging techniques.

Management

Supportive therapy (usually in ICU):

- Check vital signs, restrict fluid, and give antipyretics.
- Treat seizures and/or give prophylactic therapy (high risk for seizures!).

Cont,.....

Medication:

- Acyclovir 10 mg/kg TID for at least 14 days (adult dose).
- Gancyclovir (5 mg/kg BID) or Foscarnet (60 mg/kg TID) are especially recommended for CMV infections.

MULTIPLE SCLEROSIS

MULTIPLE SCLEROSIS

- Multiple sclerosis (MS) is an immune-mediated progressive demyelinating disease of the CNS.
- Demyelination refers to the destruction of myelin, the fatty and protein material that surrounds certain nerve fibers in the brain and spinal cord; it results in impaired transmission of nerve impulses.

Cont,…

- MS typically presents in young adults ages 20 to 40,
- It affects women more frequently than men.
- Causes: genetic predisposition, viruses

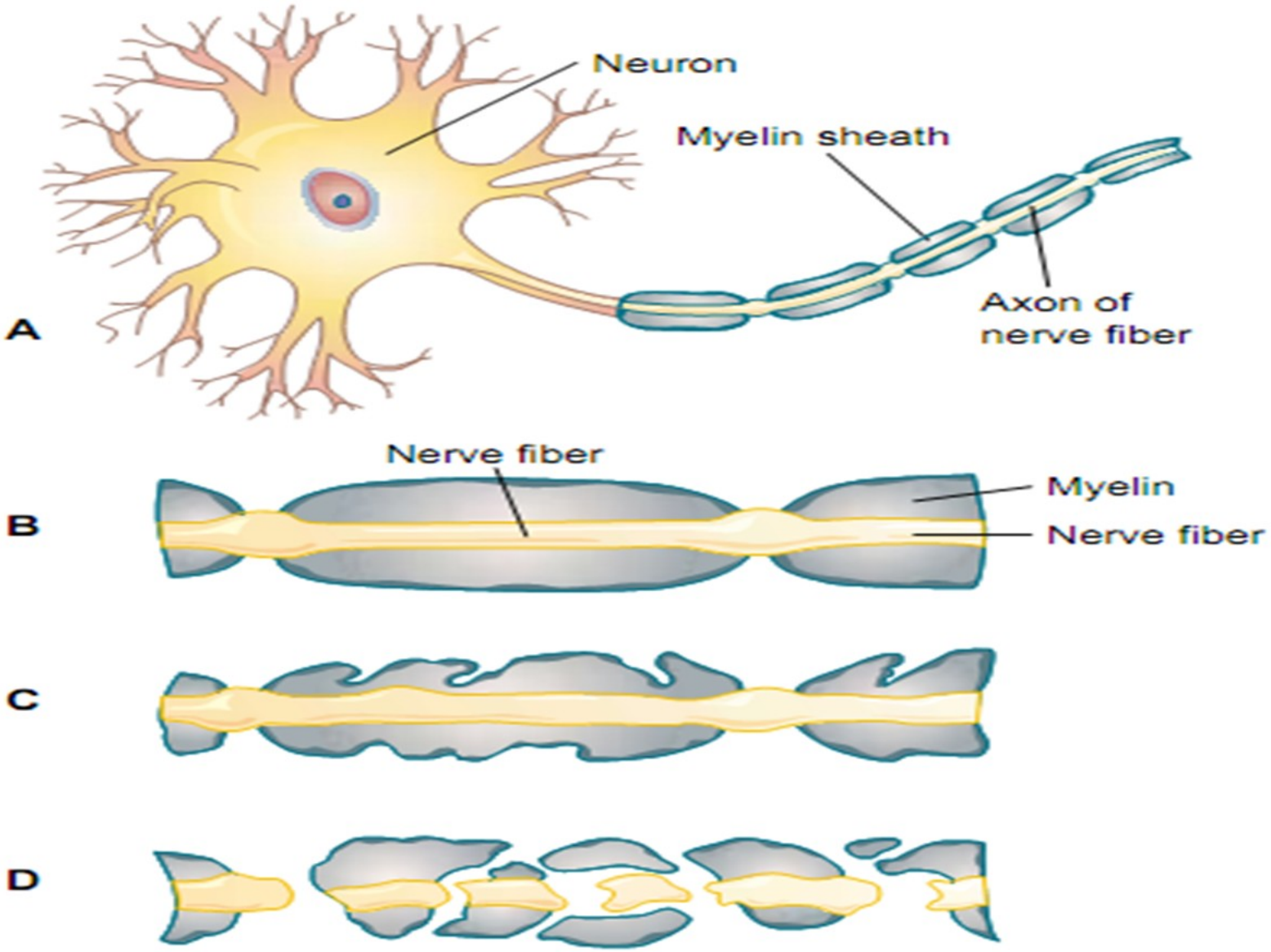

FIGURE 64-2 The process of demyelination. **A** and **B** depict a normal nerve cell and axon with myelin. **C** and **D** show the slow disintegration of myelin, resulting in a disruption in axon function.

Pathophysiology

- Sensitized T cells typically cross the BBB; their function is to check the CNS for antigens and then leave.
- In MS, the sensitized T cells remain in the CNS and promote the infiltration of other agents that damage the immune system.

Cont,...

- The immune system attack leads to inflammation that destroys myelin (which normally insulates the axon and speeds the conduction of impulses along the axon) and oligodendroglial cells that produce myelin in the CNS.
- Plaques of sclerotic tissue appear on demyelinated axons, further interrupting the transmission of impulses.

Cont,....

- Demyelination interrupts the flow of nerve impulses and results in a variety of manifestations, depending on which nerves are affected.
- The areas most frequently affected are the optic nerves, chiasm, and tracts; the cerebrum; the brain stem and cerebellum; and the spinal cord.
- Eventually the axons themselves begin to degenerate, resulting in permanent and irreversible damage.

Clinical Manifestations

- fatigue, depression, weakness, numbness, difficulty in coordination, loss of balance, and pain.
- Visual disturbances due to lesions in the optic nerves or their connections may include blurring of vision, diplopia, patchy blindness (scotoma), and total blindness.
- Spasticity (muscle hypertonicity) of the extremities and loss of the abdominal reflexes.

Cont,....

- Sensory dysfunction (paresthesias, pain).
- Some degree of cognitive change (eg, memory loss, decreased concentration).
- Involvement of the cerebellum or basal ganglia can produce ataxia and tremor.
- Emotional labiality and euphoria.
- Bladder, bowel, and sexual dysfunctions are common.

Assessment and Diagnostic Findings

- History, Physical Examination, MRI, CSF.
- Underlying bladder dysfunction is diagnosed by urodynamic studies.
- Neuropsychological testing may be indicated to assess cognitive impairment.
- A sexual history helps to identify changes in sexual function.

Management

- No cure exists for MS.

The goals of treatment are:

- To delay the progression of the disease, manage chronic symptoms, and
- Treat acute exacerbations.

Cont,.....

- Interferon beta-1a (rebif) and
- Interferon beta-1b (betaseron) are administered subcutaneously.
- Another preparation of interferon beta-1a, Avonex, is administered intramuscularly once a week.

Cont,.....

Glatiramer acetate (Copaxone)

- Reduces the rate of relapse in the course of MS.
- Copaxone is administered subcutaneously daily
- It decreases the number of plaques noted on MRI and increases the time between relapses.

Cont,.....

- Mitoxantrone (Novantrone), used to treat secondary progressive MS due to its immunosuppressive.
- Corticosteroids modulate the immune response and are used to limit the severity and duration of exacerbations.

MYASTHENIA GRAVIS

MYASTHENIA GRAVIS

- Myasthenia gravis, an autoimmune disorder affecting the myoneural junction, is characterized by varying degrees of weakness of the voluntary muscles.
- Women tend to develop the disease at an earlier age (20 to 40 years of age) compared to men (60 to 70 years of age), and women are affected more frequently.

Pathophysiology

- Normally, a chemical impulse precipitates the release of acetylcholine from vesicles on the nerve terminal at the myoneural junction.
- The acetylcholine attaches to receptor sites on the motor end plate, stimulating muscle contraction.
- Continuous binding of acetylcholine to the receptor site is required for muscular contraction to be sustained.

Cont,....

- In myasthenia gravis, auto antibodies directed at the acetylcholine receptor sites impair transmission of impulses across the myoneural junction.
- Therefore, fewer receptors are available for stimulation, resulting involuntary muscle weakness that escalates with continued activity.

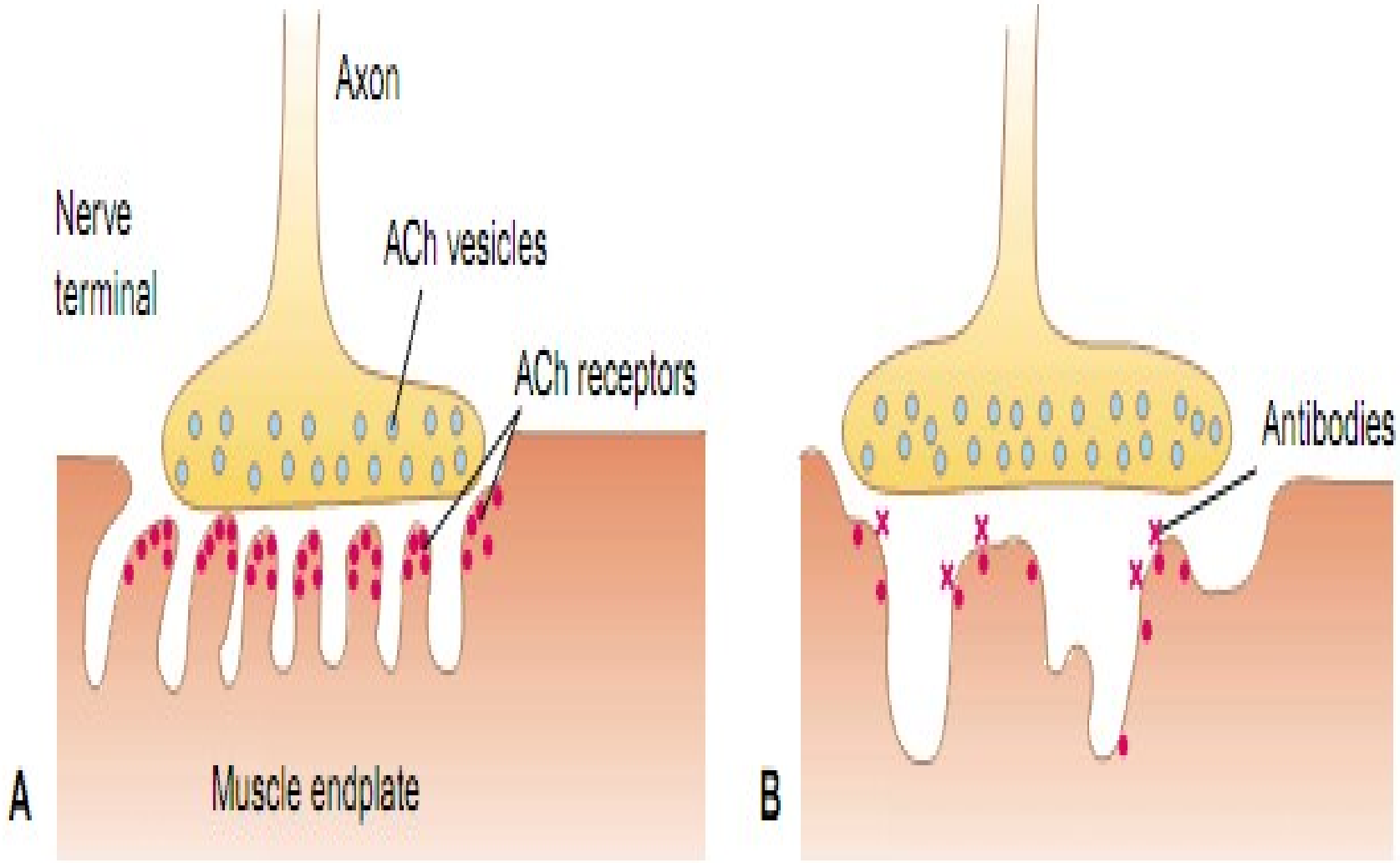

FIGURE 64-5 Myasthenia gravis. (A) Normal ACh receptor site. (B) ACh receptor site in myasthenia gravis.

Clinical manifestations

- Diplopia and ptosis(drooping of the upper eyelid due to paralysis)
- Weakness of the muscles of the face and throat
- Generalized weakness of the muscles
- Dysphonia (voice impairment)
- Decreasing vital capacity and

Assessment and Diagnostic Findings

- An anti-cholinesterase test is used to diagnose myasthenia gravis.
- Anti-cholinesterase agents stop the breakdown of acetylcholine, thereby increasing acetylcholine availability.
- Edrophonium chloride(Tensilon) is injected intravenously, 2 mg at a time to a total of 10 mg

Cont,...

- Thirty seconds after injection, facial muscle weakness and ptosis should resolve for about 5 minutes.
- This immediate improvement in muscle strength after administration of this agent represents a positive test and usually confirms the diagnosis.
- Atropine 0.4 mg should be available to control the side effects of edrophonium, which include bradycardia, sweating, and cramping.

Cont,....

- The thymus gland, which is a site of acetylcholine receptor antibody production, is enlarged in myasthenia gravis.
- MRI demonstrates this enlargement in 90% of cases.

Medical Management

- Management of myasthenia gravis is directed at improving function and reducing and removing circulating antibodies.
- Therapeutic modalities include administration of anti-cholinesterase agents and immunosuppressive therapy, plasmapheresis, and thymectomy.

Anti-cholinesterase agents

- Anti-cholinesterase agents such as pyridostigmine bromide (Mestinon) and neostigmine bromide (Prostigmin) provide symptomatic relief by increasing the relative concentration of available acetylcholine at the neuromuscular junction.
- Dosage is increased gradually until maximal benefits are obtained.

Immunosuppressive therapy

- The goal of immunosuppressive therapy is to reduce the production of the antibody.
- Corticosteroids suppress the patient's immune response, thus decreasing the amount of antibody production.
- Prednisone, taken on alternate days to lower the incidence of side effects, appears to be successful in suppressing the disease.

Cytotoxic medications

- Cytotoxic medications are used to treat myasthenia gravis if there is inadequate response to steroids.
- Medications such as azathioprine (Imuran), cyclophosphamide(Cytoxan), and cyclosporine reduce the circulating anti-acetylcholine receptor antibody

GUILLAIN-BARRÉ SYNDROME

- GBS is an autoimmune attack of the peripheral nerve myelin.
- The result is acute, rapid segmental demyelination of peripheral nerves and some cranial nerves, producing ascending weakness with dyskinesia (inability to execute voluntary movements), hyporeflexia, and paresthesias (numbness).

Cont,.....

- In 66% of cases, there is a predisposing event, most often a respiratory or gastrointestinal infection, although vaccination, pregnancy, and surgery have also been identified as antecedent events.

Cont,……

- Infection with *Campylobacter jejuni (a relatively* common gastrointestinal bacterial pathogen) precedes Guillain-Barreé syndrome in a few cases.
- The antecedent event usually occurs 2 weeks before symptoms begin.

Cont,.....

- Weakness usually begins in the legs and progresses upward for about 1 month. Maximum weakness varies but usually includes neuromuscular respiratory failure and bulbar weakness.
- The duration of the symptoms is variable: complete functional recovery may take up to 2 years.

Pathophysiology

- In Guillain-Barré the Schwann cell is spared, allowing for remyelination in the recovery phase of the disease.
- Guillain-Barré is the result of a cell-mediated immune attack on peripheral nerve myelin proteins.

Cont,.....

- The best-accepted theory is that an infectious organism contains an amino acid that mimics the peripheral nerve myelin protein. The immune system cannot distinguish between the two proteins and attacks and destroys peripheral nerve myelin.

Clinical Manifestations

- Classic Guillain-Barré begins with muscle weakness and diminished reflexes of the lower extremities.
- Hyporeflexia and weakness progress and may result in quadriplegia.
- Sensory symptoms include paresthesias of the hands and feet and pain related to the demyelination of sensory fibers.

Cont,….

- Optic nerve demyelination may result in blindness.
- Vagus nerve demyelination results in autonomic dysfunction, manifested by instability of the cardiovascular system.

Cont,....

- While the classic clinical features include areflexia and ascending weakness, variation in presentation occurs.
- Sensory presentation, with progressive sensory symptoms, an atypical axonal destruction, and the Miller-Fisher variant, which includes paralysis of the ocular muscles, ataxia, and areflexia.

Assessment and Diagnostic Findings

- Clinically
- A history of a viral illness in the previous few weeks suggests the diagnosis.
- Changes in VCF and NIF are assessed to Identify impending neuromuscular respiratory failure.
- Elevated protein levels are detected in CSF evaluation, without an increase in other cells.

Medical Management

- Guillain-Barré is a medical emergency, requiring intensive care unit management.
- Respiratory therapy or mechanical ventilation may be necessary to support pulmonary function and adequate oxygenation.

BELL’S PALSY

BELL’S PALSY

- Bell’s palsy (facial paralysis) is due to unilateral inflammation of the seventh cranial nerve, which results in weakness or paralysis of the facial muscles on the affected side.
- The cause is unknown, although possible causes may include vascular ischemia, viral disease (herpes simplex, herpes zoster), autoimmune disease or a combination of all of these factors.

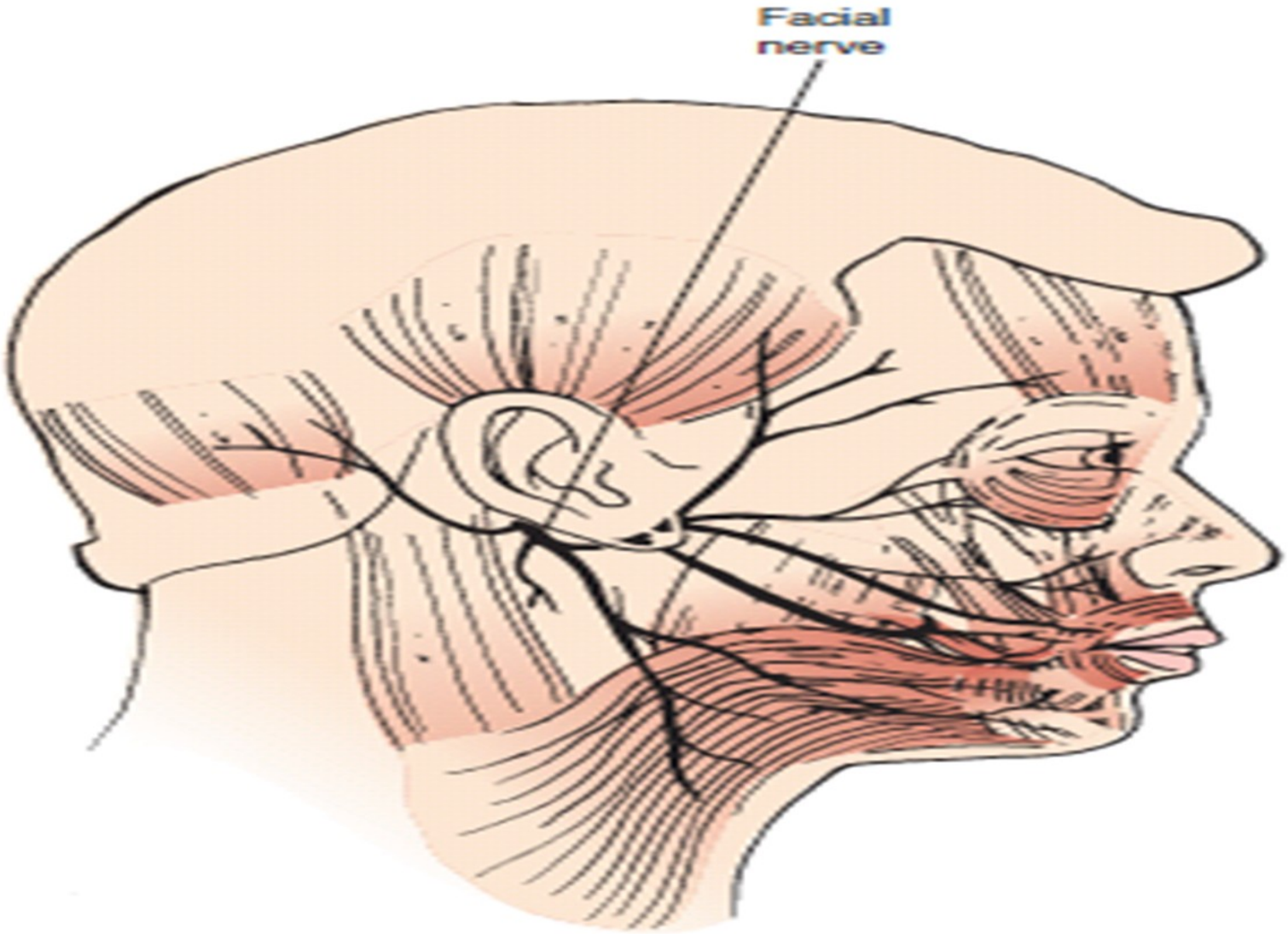

FIGURE 64-8 Distribution of facial nerve.

Cont,.....

- Bell’s palsy is considered by some to represent a type of pressure paralysis.
- The inflamed, edematous nerve becomes compressed to the point of damage, or its nutrient vessel is occluded, producing ischemic necrosis of the nerve.

Cont,....

- There is distortion of the face from paralysis of the facial muscles; increased lacrimation (tearing); and painful sensations in the face, behind the ear, and in the eye.
- The patient may experience speech difficulties and may be unable to eat on the affected side because of weakness or paralysis of the facial muscles.

Management

- The objectives of treatment are to maintain the muscle tone of the face and to prevent or minimize denervation.
- Spontaneous recovery occurs within 3 to 5 weeks in most patients.
- Corticosteroid therapy (prednisone) may be prescribed to reduce inflammation and edema; this reduces vascular compression and permits restoration of blood circulation to the nerve.

DISORDERS OF THE PERIPHERAL NERVOUS SYSTEM

PERIPHERAL NEUROPATHIES

- A peripheral neuropathy (disorder of the nervous system) is a disorder affecting the peripheral motor, sensory, or autonomic nerves.
- A mono-neuropathy affects a single peripheral nerve; multiple mono-neuropathy or mono-neuritis multiplex indicates the involvement of multiple single peripheral nerves or their branches

Cont,...

- Poly-neuropathies are characterized by bilateral and symmetric disturbance of function, usually beginning in the feet and hands.
- The most common causes of peripheral neuropathy are diabetes, alcoholism, and occlusive vascular disease.
- These disorders result in hypoxia or atrophy of the peripheral nerve.
- Many bacterial and metabolic toxins and exogenous poisons also cause peripheral neuropathy.

Cont,……

- The major symptoms of peripheral nerve disorders are loss of sensation, muscle atrophy, weakness, diminished reflexes, pain, and paresthesia (numbness, tingling) of the extremities.
- The patient frequently describes some part of the extremity as numb.

Cont,.....

- Autonomic features include decreased or absent sweating, orthostatic hypotension, nocturnal diarrhea, tachycardia, impotence, and atrophic skin and nail changes.
- Peripheral nerve disorders are diagnosed by history, physical examination, and somatosensory evoked potentials.

treatment

- Treatment of the underlying cause or systemic disorder; recovery is usually slow
- Traumatic lesions with complete transection of nerve require surgery.
- Tri-cyclicantidepressants, carbamazepine, phenytoin and capsaicin can help patients suffering room pain.

DEGENERATIVE DISORDERS

PARKINSON'S DISEASE

- Parkinson's disease is a slowly progressing neurologic movement disorder that eventually leads to disability.
- The cause of most cases is unknown, research suggests several causative factors, including genetics, atherosclerosis, excessive accumulation of oxygen free radicals, viral infections, head trauma, chronic antipsychotic medication use, and some environmental exposures.

Pathophysiology

- Parkinson’s disease is associated with decreased levels of dopamine resulting from destruction of pigmented neuronal cells in the substantia nigra in the basal ganglia region of the brain.
- Fibers or neuronal pathways project from the substantia nigra to the corpus striatum, where neurotransmitters are key to the control of complex body movements.

Cont,....

- Through the neurotransmitters acetylcholine (excitatory) and dopamine (inhibitory), striatal neurons relay messages to the higher motor centers that control and refine motor movements.
- The loss of dopamine stores in this area of the brain results in more excitatory neurotransmitters than inhibitory neurotransmitters, leading to an imbalance that affects voluntary movement.

Cont,....

- Clinical symptoms do not appear until 60% of the pigmented neurons are lost and the striatal dopamine level is decreased by 80%.
- Cellular degeneration impairs the extrapyramidal tracts that control semiautomatic functions and coordinated movements; motor cells of the motor cortex and the pyramidal tracts are not affected.

Clinical Manifestations

- Parkinson’s disease has a gradual onset and symptoms progress slowly over a chronic, prolonged course.
- The three cardinal signs are tremor at rest, rigidity, and bradykinesia (abnormally slow movements).

Cont,...

- Other features include hypokinesia, gait disturbances, and postural instability, excessive and uncontrolled sweating, paroxysmal flushing, orthostatic hypotension, gastric and urinary retention, constipation, and sexual disturbance, depression, dementia (progressive mental deterioration).

Assessment and Diagnostic Finding

- Clinically from the patient's
- History and the presence of two of the three cardinal manifestations: tremor at rest, muscle rigidity, and bradykinesia.
- PET scanning.

Medical Management

- Treatment is directed at controlling symptoms and maintaining functional independence because there are no medical or surgical approaches that prevent disease progression.
- Care is individualized for each patient based on presenting symptoms and social, occupational, and emotional needs.

Cont,....

- Pharmacologic management is the mainstay of treatment.
- Patients are usually cared for at home and admitted to the hospital only for complications or to initiate new treatments.

Cont,…

Antiparkinsonian medications act by:

1) increasing striatal dopaminergic activity,
2) reducing the excessive influence of excitatory cholinergic neurons on the extrapyramidal tract, thereby restoring a balance between dopaminergic and cholinergic activities,

Cont,.....

3)Acting on neurotransmitter pathways other than the dopaminergic pathway.

- Antiparkinsonian Medications; Levodopa (Dopar, Larodopa) is the most effective agent and the mainstay of treatment.

Cont,.....

- Levodopa is converted to dopamine in the basal ganglia, producing symptom relief.
- Levodopa is usually given in combination with carbidopa amino acid decarboxylase inhibitor that helps to maximize the beneficial effects of levodopa by preventing its breakdown outside the brain and reducing its adverse effects.

THANK YOU

–

DISORDER OF THE SKIN

Learning Objectives

At the end of this topic you will be able to:

1. Define skin disorders

2. Identify causative/risk/contributing factors of skin disorders

3. Describe the clinical manifestations of patients with skin disorders

4. Explain pathophysiologic process of skin disorders

5. Discuss diagnostic procedures used in the diagnosis of skin disorders

6. Explain the medical managements of patients with skin disorders

Anatomic and Physiologic Overview

- Largest organ
- Barrier
- Heaviest single organ of the body
- 16% of body wt
- Composed of three layers:
  - Epidermis
  - Dermis
  - Hypodermis
  - Subcutaneous tissue

Epidermis

- Outermost layer
- Stratified epithelial cells
- Replaced every 3 to 4 weeks
- Depends on the underlying dermis for its nutrition
- Composed of
  - Keratinocytes → Keratin
  - Melanocytes → Melanin
  - Merkel and Langerhans cells

Keratin

- Fibrous protein
- The principal hardening ingredient of the hair and nails
- Forms the outer barrier of the skin
- Has the capacity to repel pathogens and prevent excessive fluid loss from the body

Melanin

- Colors the skin and hair
- Its production controlled by Melanocyte Stimulating Hormone
- Can absorb ultraviolet light in sunlight

Merkel cells

- Receptors that transmit stimuli to the axon through a chemical synapse

Langerhans cells

- Believed to play a significant role in coetaneous immune system reactions

Dermis

- Largest portion of the skin
- Providing strength and structure
- Well supplied with blood
- Made up of blood and lymph vessels, nerves, sweat and sebaceous glands, and hair roots
- Referred to as the “true skin”
- Composed of two layers
    - Papillary
    - Reticular

- **Papillary layer**
  - Lies directly beneath the epidermis
  - Composed of fibroblast cells capable of producing collagen

- **Reticular layer**
  - Lies beneath the papillary layer
  - Produces collagen and elastic bundles

Subcutaneous tissue (hypodermis)

- Innermost layer
- Contains adipose tissue
- Promotes skin mobility
- Molds body contours
- Insulates the body
- Fat deposited here

Function

- Protective function
- Thermoregulation
- Metabolism
- Sensation
- Secretion

Skin Assessment

Physical Examination

- Inspection and palpation are common techniques
- Assessment includes
  - Color changes
  - Moisture
  - Temperature
  - Texture
  - Mobility and Turgor
  - Lesions

Assessing Skin Lesion

- **Skin lesions**
  - Can be described as primary or secondary

  - **Primary lesions**
    - Are the initial lesions and are characteristic of the disease itself

  - **Secondary lesions**
    - Result from external causes

Primary Lesions

1. Circumscribed, flat , no palpable lesion

- **Macule**
  - Flat lesion due to a localized color change
  - The surface is normal
  - Size <1cm
  - Eg: petechia


Copyright © 2008 Dr Eric Ehrsam, dermatologist

- **Patch**
  - Similar to a macule but the size > 1cm
  - Eg: rubella, vitiligo, ecchymosis



2. Palpable, elevated, solid masses

- **Papule**
  - Raised lesion
  - Size > 1cm
  - Diameter is much greater than the thickness
  - Eg: Elevated nevi, warts



- **Plaque**
  - A flat, elevated surface larger than 5cm
  - Often formed by the coalescence of papule
  - Eg: Psoriasis, actinic keratosis



- **Nodule**
  - Any elevated lesion (> 1cm diameter)
  - Has a round surface
  - Often due to dermal pathology
  - Eg: Lipoma, squamous cell carcinoma, poorly absorbed injection,





Figuras 2 e 3: Nódulo eritêmato-violáceo na coxa direita.
Figures 2 and 3: Erythematous-violaceous nodule in the right thigh.

- **Tumor**
  - >1–2 cm
  - Larger than nodule
  - Do not always have sharp borders
  - Eg: Larger lipoma, carcinoma



3. Fluid – filled

- **Vesicle**
  - Size < 1cm
  - A fluid filled lesion (blister)
  - Eg: Herpes simplex/zoster, second-degree burn


SFS

- **Bullae**
  - Blister which is > $1\mathrm{cm}$ in size
  - Eg: large burn blisters, poison ivy, bullous impetigo



- **Wheal**
  - Elevated mass with transient borders
  - Often irregular
  - Caused by movement of serous fluid into the dermis
  - Eg: Urticaria (hives), insect bites

Figure 2: Wheals present on anterior aspect of the upper thighs.



- **Pustule**
  - Pus-filled vesicle or bulla
  - Eg: Acne, impetigo, furuncles, carbuncles



- **Cyst**
  - Encapsulated fluid-filled or semisolid mass in the subcutaneous tissue or dermis



Secondary Lesions

1. Loss of skin surface

- **Erosion**
  - Loss of superficial epidermis
  - Does not extend to dermis
  - Depressed, moist area
  - Eg: Ruptured vesicles, scratch marks



- **Ulcer**
  - Skin loss extending past epidermis
  - Bleeding and scarring possible
  - Eg: pressure ulcer



- **Fissure**
  - Linear crack in the skin
  - May extend to derr
  - Eg: athlete’s foot



2. Material on the skin

- **Scales**
  - Flakes secondary to desquamated, dead epithelium
  - May adhere to skin surface
  - Color varies (silvery, white)
  - Texture varies (thick, fine)
  - Eg: Dandruff, psoriasis, dry skin



- **Crust**
  - Dried residue of serum, blood, or pus on skin surface.
  - Eg: Residue left after vesicle rupture: imp



3. Miscellaneous

- **Scar**
  - Skin mark left after healing of a wound or lesion
  - Represents replacement by connective tissue
  - Young scars: red or purple
  - Mature scars: white or glistening


© Jere Mammino, DO

- **Keloid**
  - Hypertrophied scar tissue
  - Secondary to excessive collagen formation during healing
  - Elevated, irregular, red



- **Atrophy**
  - Thin, dry, transparent appearance of epidermis
  - Loss of surface markings
  - Secondary to loss of collagen and elasticity
  - Underlying vessels may be visible
  - Examples: Aged skin



- **Lichenification**
  - Thickening and roughening of the skin
  - Accentuated skin markings
  - May be secondary to repeated rubbing, irritation, scratching
  - Example: Contact dermatitis



Vascular Skin Lesions

- **Petechia**
  - Round red or purple macule
  - Secondary to blood extravasation
  - Associated with bleeding tendencies or emboli to skin



- **Ecchymosis**
  - Round or irregular macular lesion
  - Larger than petechia
  - Secondary to blood extravasation
  - Associated with trauma, bleeding tendencies


A

- **Spider Angioma**
  - Red, arteriole lesion
  - Central body with radiating branches
  - Noted on face, neck, arms, trunk
  - Associated with liver disease, pregnancy, vitamin B deficiency



Diagnostic Testes

- **Skin Biopsy**
  - Obtain tissue for microscopic examination
- **Immunofluorescence**
  - To identify the site of an immune reaction
- **Skin Scrapings**
  - Tissue samples are scraped for microscopic examination

- **Tzanck Smear**
  - Used to examine cells from blistering skin
- **Clinical Photograph**
  - To document the nature and extent of the skin condition
  - Are used to determine progress or improvement

INFLAMMATORY AND ALLERGIC CONDITIONS

ECZEMAS (DERMATITIS)

- Recurrent inflammatory disorder of the skin

- Could be acute, sub-acute or chronic

Classification of eczema

- **Endogenous factors**
  - Atopic
  - Seborrhoeic
- **Exogenous factors**
  - Contact dermatitis (irritant and allergic contacts)
  - Photo dermatitis (Phototoxic and photo allergic)

Etiology

- Allergic substances (dust, pollen)
- Chemicals
- Sun
- Certain drugs
- Foods

Patophysiology

- Most allergens (trigger factors) induce either
  - Type one hypersensitivity reaction

    Or
  - Type four hypersensitivity reaction

Type - 1 reaction

- The reaction begins within minutes of exposure to antigen
- Mediated by IgE (antibody)

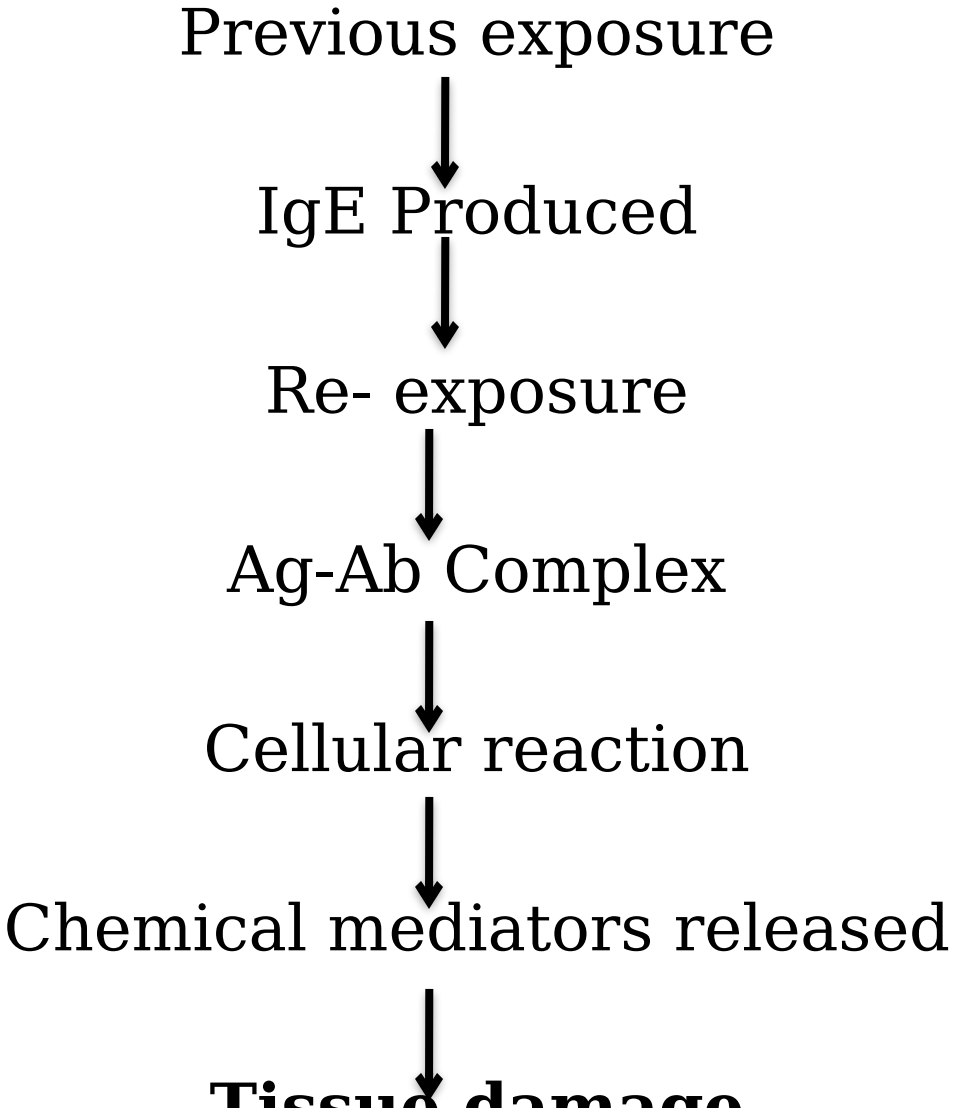
Previous exposure
IgE Produced
Re- exposure
Ag-Ab Complex
Cellular reaction
Chemical mediators released
Tissue damage

Type - IV (delayed Hypersensitivity)

- Occurs in 24 – 72 hrs after exposure to an allergen
- Mediated by sensitized T cells and macrophages

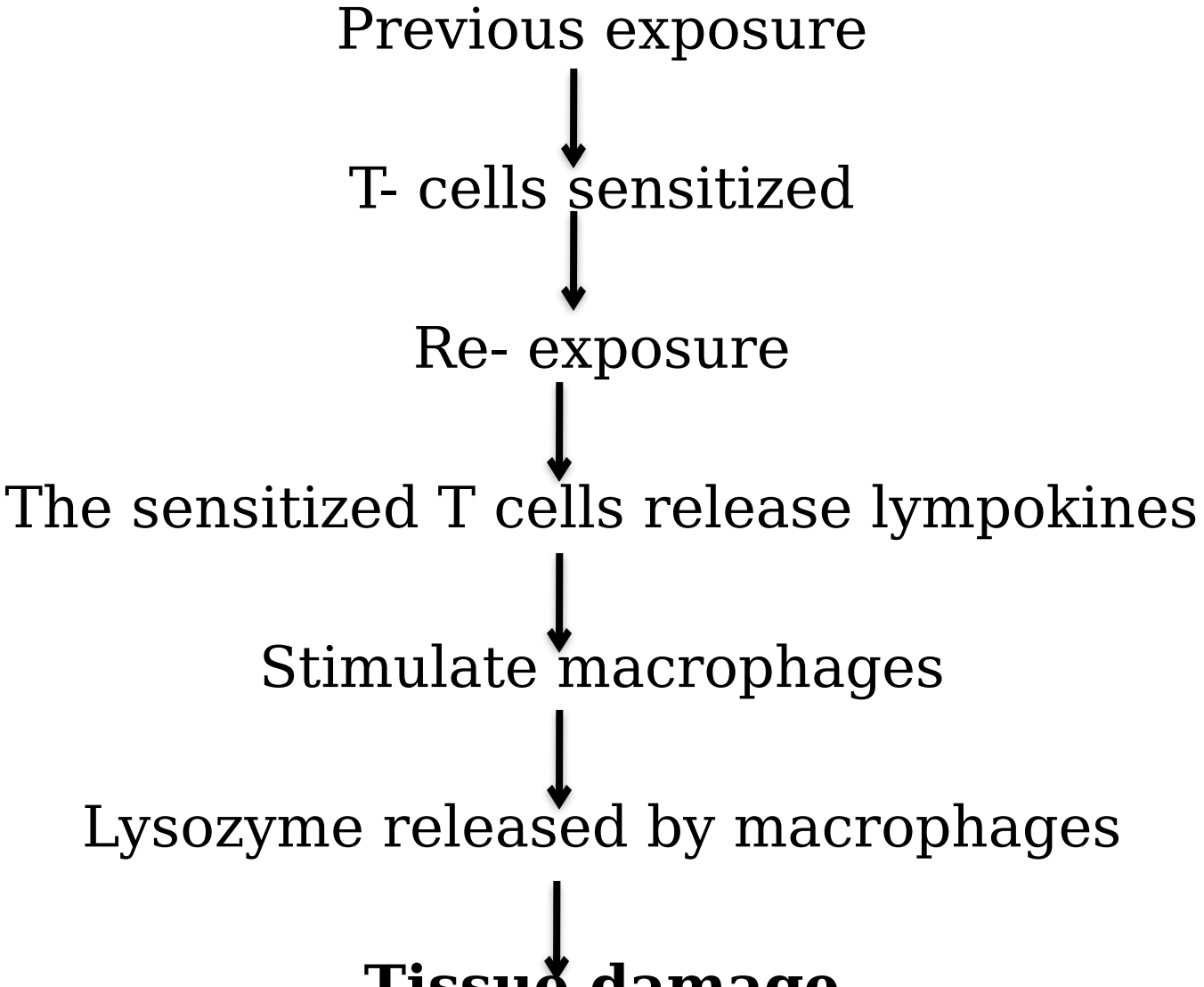
Previous exposure
T- cells sensitized
Re- exposure
The sensitized T cells release lympokines
Stimulate macrophages
Lysozyme released by macrophages
Tissue damage

Clinical Features Common to Most of Eczemas

- **Acute eczema**
  - Redness and swelling
  - Papule, vesicles or large blisters
  - Exudation and crusting
  - Oozing
  - Itching

- **Sub acute eczema**
  - Moist lesion
  - Erythematous, excoriated, scaling papules

- **Chronic eczema**
  - Lichenified
  - Develop painful fissures

Complications

- Bacterial colonization (infection)
- Dissemination
- Anxiety
- Scarring
- Permanent hyperpigmentation

Types of dermatitis

1. Contact dermatitis

- Characterized by erythematous and pruritic skin lesions
- Occur after contact with a foreign substance
- Two forms
  - Irritant
  - Allergic

- **Irritant Contact Dermatitis (ICD)**
  - Caused by irritation of the skin by a substance
  - Non–immune-modulated
  - Skin changes occur immediately after the exposure

- **Allergic Contact Dermatitis (ACD)**
  - Hypersensitivity reaction to foreign substance
  - Immune mediated
  - Skin changes occur after **re-exposure** to the substance

- **Etiology**
  - Soap
  - Detergents
  - Industrial Chemicals
  - Metals in jewelry (Eg. Nickel)
  - Extreme cold and heat
  - Pre – existing skin diseases

Clinical Presentation

- Usually involved
  - Hands
  - Face
  - Neck
- Erythema
- Itching
- Burning


A


B


D


A

Management

- **Identify and avoid the causative substance**
- Washing the affected areas
- **Localized**
  - Topical steroids
    - Hydrocortisone, Methylprednisolone
- **Extensive area**

- **In severe case**
  - Antihistamines
    - Eg. Promethazine, diphenhydramine, citrezine
- **If super-infection**
  - Antibiotics

2. **Atopic dermatitis**

- Chronic inflammatory disorder of the skin
- Inherits tendency of sensitized to allergens
- Intensely pruritic

- Exacerbating factors
  - Sudden changes in climate (temp. or humidity)
  - Exercise
  - Psychological stress
  - Fibers wool, nylon
  - Detergents
  - Perfume

Clinical manifestations

- Severely itching
- The skin is usually dry, itchy & easily irritated by soap, detergents or wool clothing
- May worsen in hot weather & emotional stress
- May worsen with exposure to dust & some animals
- In severe case exudations and massive crusting can occur





- Distribution
  - In infants
    - The *face* is often affected first, then the hands and feet
    - Dry red patches may appear all over the body
  - In older children
    - The **skin folds** are most often affected, especially the elbow and behind the knees.
  - In adults
    - The *face* and *hands* are more likely to be involved

Treatment

- General Measures
  - Avoidance of factors that promotes dryness, itching or inflammation
  - Avoidance of contact with local irritants
- Localized
  - Topical Steroids

- Larger areas and in sever case
  - Systemic Steroids
  - Antihistamines

- If Super-infection
  - Antibiotics

3. **Seborrheic Dermatitis**

- Chronic inflammatory disease of the skin
- Characterized by scaling
- Primarily affects sebum-rich areas

- Commonly aggravated by :
  - Changes in humidity
  - Trauma (eg, scratching)
  - Seasonal changes
  - Emotional stress

Clinical Presentation

- Pruritic
- Erythematous patches with easily detachable
- Greasy large scales
- Commonly affects the scalp, face, upper chest, and pubic areas
- When the scalp involved it is called **dandruff**
- When scaling occurs, it is often accompanied by pruritus

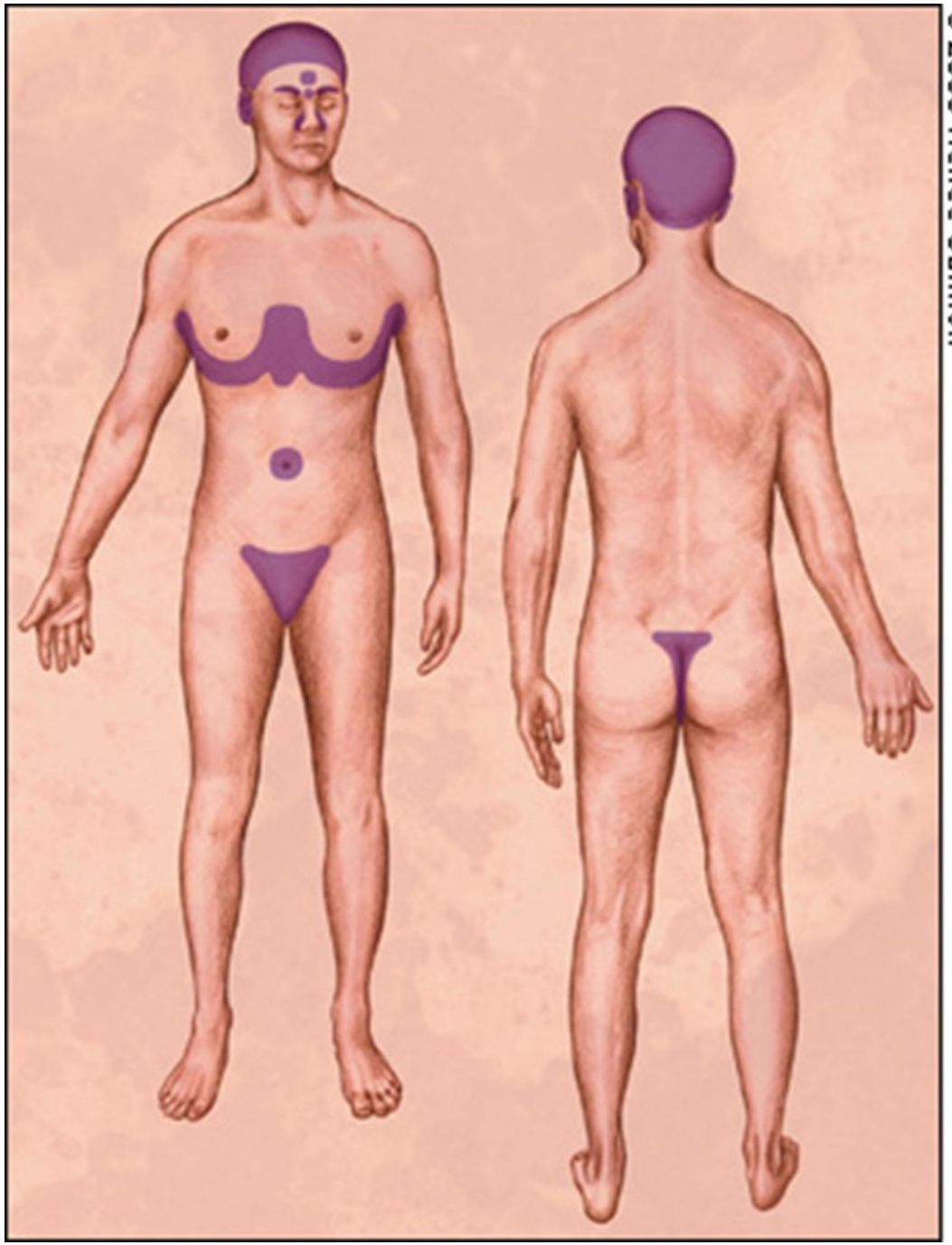

© 2000 Renee Cannon







DDx

- Tinea capitis
- Psoriasis

Treatment

- There is no known cure for seborrhea
- Goal
  - To control the disorder
  - To allow the skin to repair itself

- Antifungal
- Corticosteroids
- Frequent shampooing using medicated shampoos
- Avoid
  - External irritants
  - Excessive heat and perspiration

- Medicated shampoos : shampoo containing
  - Salicylic acid
  - Selenium sulfide
  - Antifungal
- These shampoos can be used at least 2 times a week
- How to use:
  - Rub the shampoo into the hair thoroughly
  - Let it to stay on the hair and scalp for at least 5 minutes
  - Rinsing with water

PSORIASIS

- Chronic noninfectious disease of the skin

- Epidermal cells are produced at a rate **six to nine times** faster than normal

Etiology

- Primary cause is unknown
- Trigger factors
  - Emotional stress and anxiety
  - Trauma
  - Infections
  - Seasonal changes
  - Hormonal changes

Clinical Manifestations

- Mostly affected areas includes
  - Scalp
  - Extensor surface of elbows and knees
  - Lower part of the back
  - Genitalia
- **Silvery scales**
- If the scales are scraped away produce multiple bleeding points

- **Bilateral symmetry** is a feature of psoriasis
- If nails involved
  - Discoloration
  - Crumbling beneath the free edges
  - Separation of the nail plate









Medical Management

- Goal
  - to reduce the rapid turnover of epidermis
  - to promote resolution of psoriatic lesions

- General measures
  - Gentle removal of scales
  - Regular skin care
- Pharmacologic Therapy
  - Three types of therapy are standard:
    - Topical
    - Intra-lesional
    - Systemic

- **Topical Agents**
  - Slow the overactive epidermis without affecting other tissues
  - Includes
    - Medicated shampoos/soap
    - Salicylic acid
    - Topical Retinoid
    - Topical corticosteroids

- **Intralesional Agents**
  - Intralesional injections of triamcinolone acetonide
  - Care must be taken to ensure that normal skin is not injected

- **Systemic Agents**
  - Systemic corticosteroids

ACNE VULGARIS

- Common follicular disorder
- Affect hair follicles
- Occurs primarily in oily {seborrheic} areas of the skin
    - Face, neck, upper trunk, and upper arms

Epidemiology

- Commonly affects adolescents b/n age 12 and 25
- Usually end by age 25
- Both genders are affected equally
- Onset is slightly earlier for girls
- 85% adolescents experience it in the

- Contributing factors
  - Excess secretion of sebum
  - Obstruction of the pilosebeaues orifice
  - Inflammation
  - Mechanical factors (excessive rubbing use of oily cosmetics)

Causes

- **Hormonal**
  - Hormonal activity (menstruation & puberty) contribute for the formation of acne
  - Increase in sex hormones (Androgens) cause the follicular glands to grow larger and produce more sebum

- **Obstruction of follicles**
  - Hair follicles become blocked with keratin (scale)
  - They may rupture, resulting in inflammation

- **Infections**
  - Propionibacterium acnes (P. acnes)
    - Is anaerobic bacterial species widely causing acne
    - Live in the hair follicles
    - Break down the triglycerides of the sebum into free fatty acids and glycerin
    - Result in inflammation

Diet

- The relationship b/n acne and diet is unclear
- High glycemic load diet associated with worsening of acne
- There is association b/n consumption of milk and severity of acne

Pathogenesis

Sebaceous glands enlarge

↓

Sebum production increases and hyperkeratinization

↓

Blockage of follicles

↓

Growth medium for *P. Acnes*

↓

Plugs provide anaerobic, Lipid-rich environment for P.Acne

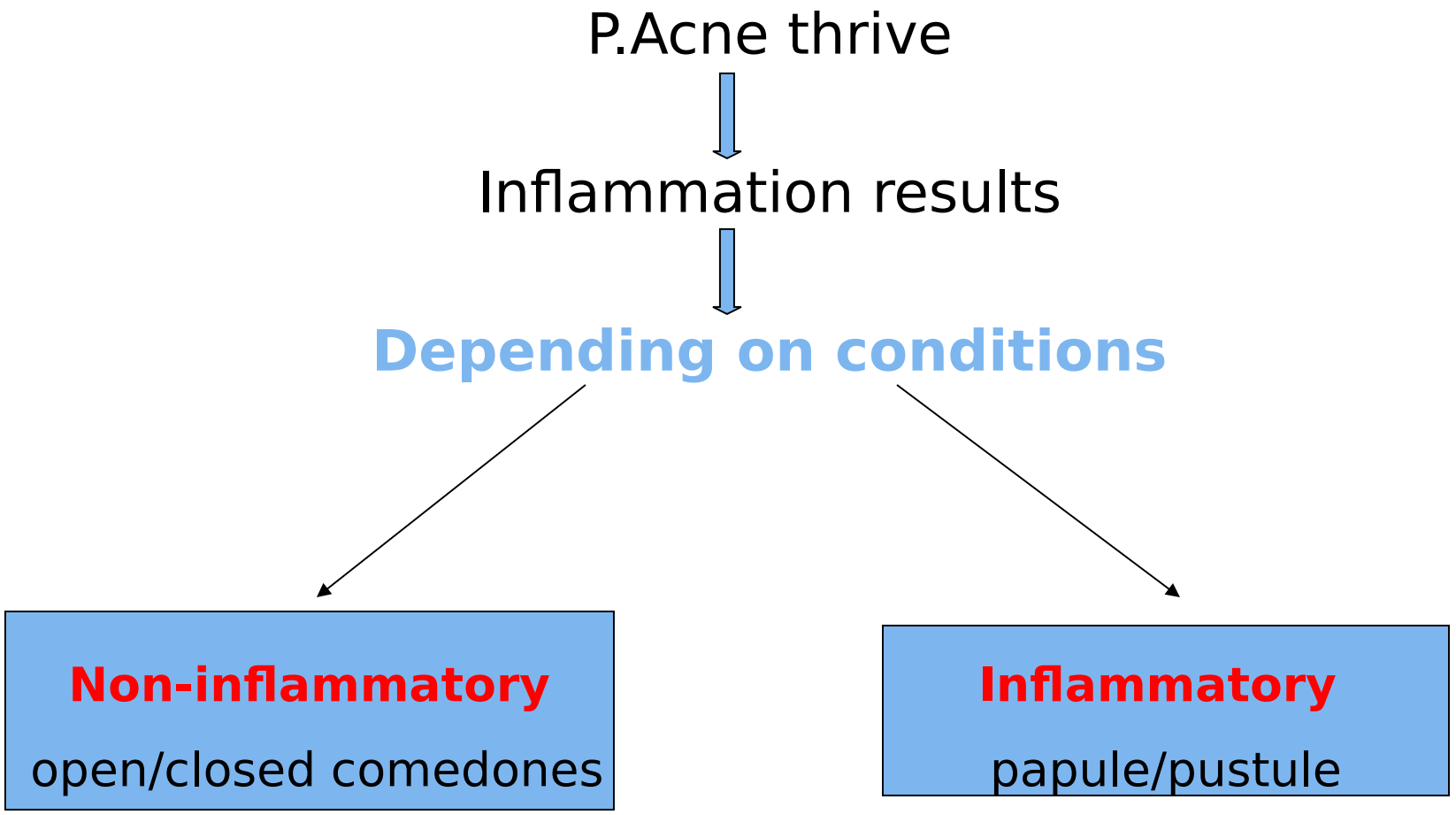
P.Acne thrive
Inflammation results
Depending on conditions
Non-inflammatory
open/closed comedones
Inflammatory
papule/pustule

Clinical manifestations

- Commonly affected areas
  - The face, neck, and upper trunk
- Non- inflammatory acne
  - Comedones (open or closed)
- Inflammatory acne
  - Pustules

Comedones

- The initial lesion of acne
- Due to formation of keriatin and sebum plug
- Two forms
  - **Closed Comedones**
    - White head
    - Formed from impacted sebum and keratin




dreamstime
Download from
Dreamstime.com
This watermarked comp image is for previewing purposes only.
ID 12071231
Stephen Gibson | Dreamstime.com

- **Open Comedones**
  - Black heads
  - Ruptured
  - Accumulation of lipid , bacteria ,and epithelial debris




101

Medical Management

- **Goal**
  - Reduce colonization by bacteria
  - Decrease sebaceous gland activity
  - Prevent the follicles from obstruction
  - Reduce inflammation
  - Minimize scaring

- **Topical treatments**
  - Benzoyl Peroxide
    - Most important organic peroxides
    - Depress sebum production
    - Promote breakdown of comedon plugs

- Topical Retinoids
  - Are comedolytic and anti-inflammatory
  - Reduce hyperkeratinization
  - Applied once daily to clean skin
  - Eg. Adapalene, tazarotene and tretinoin

- Topical Antibiotics
  - Suppress the growth of P. acnes
  - Eg. Tetracycline, clindamycin, and erythromycin

- **Systemic treatment**
  - Antibiotics: oral antibiotics
  - Oral Retinoids

- **Surgical treatment**
  - Comedon extraction
  - Incision and drainage of large comedones
  - Cryosurgery (ie, freezing with liquid nitrogen) may be

SKIN INFECTIONS

- **BACTERIAL SKIN INFECTIONS (PYODERMS)**
- **VIRAL SKIN INFECTIONS**
- **FUNGAL SKIN INFECTION (MYCOSIS)**

BACTERIAL SKIN INFECTIONS (PYODERMS)

- May be primary or secondary
- Primary skin infections
  - Originate in previously normal-appearing skin
- Secondary skin infections
  - Arise from a preexisting skin disorder
- The most common primary bacterial skin infections are impetigo and folliculitis.
- Folliculitis may lead to furuncles or carbuncles

IMPETIGO

- Superficial
- Contagious
- Caused by staphylococci, streptococci, or others
- Affects exposed areas of skin (face, neck and extremities)
- Common among children living in poor hygienic conditions.
- Predisposing factors for adults
  - Poor hygiene
  - Malnutrition

Classification

- **Non-bullous impetigo**
  - Caused by staphylococci, group A streptococci t or both organisms
  - Fragile vesicle or pustule
  - Rupture and produce honey-yellow dherent crust
  - Minimal or no surrounding redness
  - Heal without scaring
  - Sites:
    - Commonly exposed body parts
  - Doesn't affect palms & soles

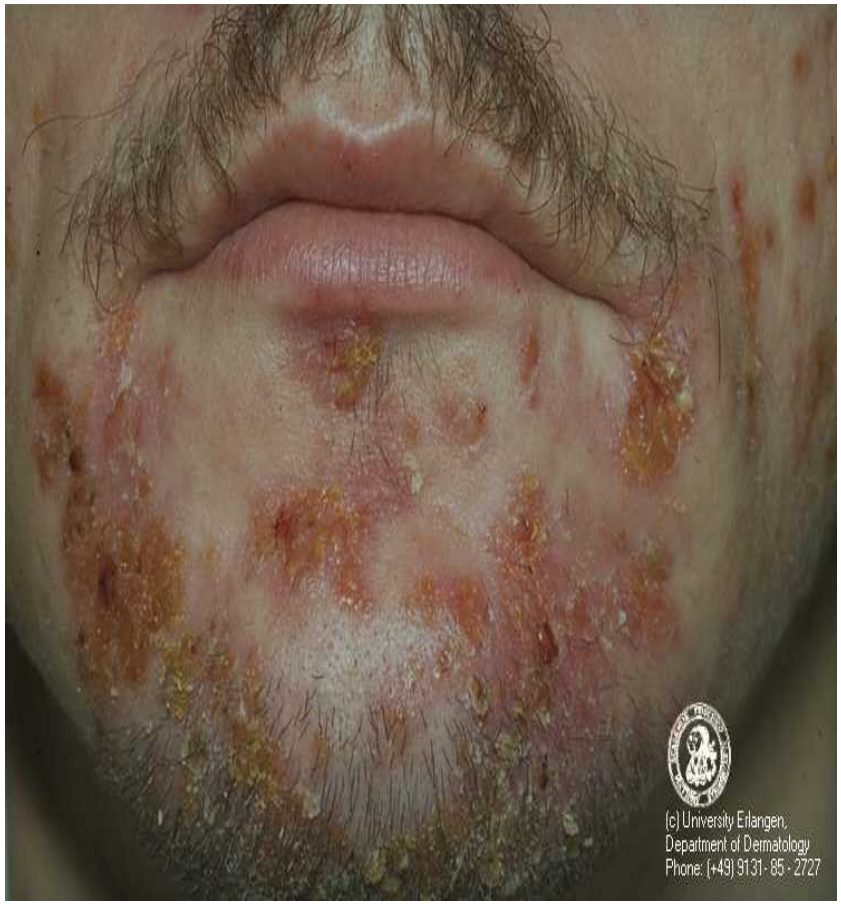
(c) University Erlangen,
Department of Dermatology
Phone: (+49) 9131 - 85 - 27 27



- **Bullous impetigo:**
  - Caused by S. aureus
  - Bulla develops
    - Contents are at first clear, later cloudy
    - After rupture, thin, brownish crusts are formed
  - Affect all age groups, but common in childhood & newborn
  - Site: face is often affected, affect every





Clinical Manifestations

- Lesions begin as small, red macules
- Become thin-walled vesicles
- Rupture produce loosely adherent

  honey-yellow crust

- Crusts are easy to be removed
- After removal red, moist surfaces and eventually new crust will be produced

Medical Management

- Localized
  - Topical antibiotics
- Extensive areas
  - Systemic antibiotics

Nursing management

- Cleanliness and good hygiene practices
- Use antibacterial soap
- Infected people should avoid contact with other people until the lesions heal

FOLLICULITIS, FURUNCLES, AND CARBUNCLES

Folliculitis

- Bacterial infection of hair follicles
- Lesions may be superficial or deep
- Commonly affects the beard area of men who shave and women’s legs
- Other areas include the axillae, trunk, and buttocks

Predisposing factors

- Chronic illness
- Mechanical irritation
- Infection

Clinical manifestation

- Single or multiple papules or pustules appear close to the hair follicles



Furuncle (Boil)

- Infection of hair follicle that involve the dermis
- Deeper form of folliculitis
- More prevalent in areas subjected to:
  - Irritation
  - Pressure
  - Friction
  - Excessive perspiration

- Common in the
  - Back of neck
  - Axillae
  - Buttocks
- Usually caused by S. aurous



Carbuncle

- Multiple furuncle
- Abscess of the skin and subcutaneous tissue
- Involving several follicles
- It is painful usually associated with fever
- It is usually caused by a staphylococcal infection
- Appear most commonly in areas where the skin is thick and inelastic
- The common site includes neck, thighs, and back.


©Mayo Foundation for Medical Education and Research. All rights reserved.

Management

- Treating staphylococcal infections is important
- Systemic antibiotic therapy, selected by sensitivity study, is generally indicated.
- Oral cloxacillin, dicloxacillin, and flucloxacillin are first-line medications
- Cephalosporins and Aminoglycosieds are also effective
- Drainage of abscess
- Local skin care and dressing

Nursing Management

- IV fluids
- Fever reduction
- Warm, moist compresses
- Care for the surrounding skin
- Bed rest
- The boil should never be squeezed

VIRAL SKIN INFECTIONS

VERUCAE (WARTS)

- Benign skin tumors
- A small rough growth resembling solid blister
- Caused by infection with the Human Papilloma Virus(HPV)
- Occurs most frequently between ages 12 and 16 years
- Asymptomatic, except when they occur on weight-bearing areas



Cause

- Warts are caused by HPV infection of the skin
- There are about 130 known types of HPV
- They usually infect squamous epithelium of skin and genitalia
- They can produce a benign growth,

- Can be transmitted by:
  - Direct or indirect contact
  - Autoinoculation
  - Sexual activity → Genital warts

Type

- There are many types of warts
- Varies based on:
  - Shapes
  - Site involved
  - Types of HPV involved

- **Common warts (verruca vulgaris)**
  - Raised warts with rough surface
  - Most common on hands
- **Flat warts (verruca plana)**
  - Small, smooth flattened
  - Flesh-colored
  - Most common in face, neck wrists and



- **Plantar or foot warts (verruca plantaris)**
  - Common on hands or sole f the feet
- **Genital warts (condylomata acuminate)**
  - Occurs in genitalia
- **Filiform warts (digitate warst)**
  - Finger like warts
  - Most common on the face, especially near the eyelids and lips



Treatment

- There is no single effective treatment for warts

- Management is based on:
  - The age of the individual
  - The size, number, and location of warts

- Warts in children, do not necessarily need to be treated, because of remission

- **Medications**
  - **Salicylic acid**
    - Administered on the warts
    - Preparation
      - Adhesive pads treated with salicylic acid (plaster)
      - Bottle of concentrated salicylic acid solution

- **Silver nitrate**
  - In the form of caustic pencil
- **Zink sulfate**
  - Oral preparation
  - Believed to reduce warts

- **Warts removal**
  - Cryosurgery
    - Freezing warts with liquid nitrogen
    - The dry warts will be easily scraped
  - Curettage
    - Scraping warts with cutting instrument
  - Local laser therapy
    - » Excision of warts with laser cutter


© Jere Mammino, DO

HERPES SIMPLEX

- Is a common skin infection
- Caused by herpes simplex type 1 and type 2
- It affects: Skin, Mucous membrane and CNS

Orolabial Herpes

- Also called fever blisters or cold sores
- Caused by type 1 herpes virus
- Affect the lips
- Consists clusters of grouped vesicles

- Tingling or burning with pain may precede the appearance of the vesicles
- Certain triggers, such as sunlight exposure or increased stress, may cause recurrent episodes
- Mode of Transmission:
  - Oral secretions
  - Secretion from the lesions

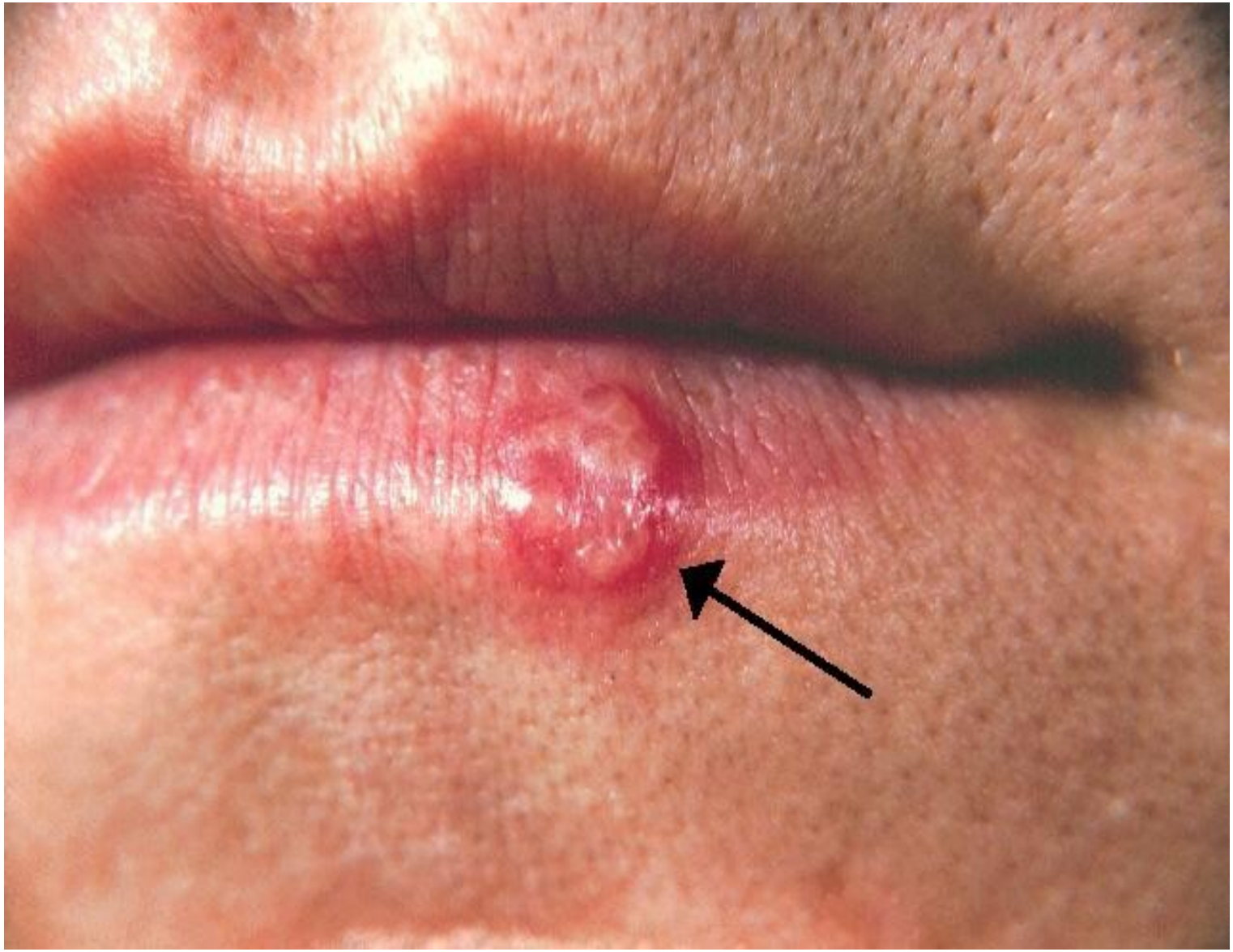

Genital Herpes

- Caused by type 2 herpes simplex
- Lesions appear as grouped vesicles initially involving the vagina, rectum, or penis
- Lesions are symmetric and usually cause regional lymphadenopathy
- Fever and flulike symptoms are common
- Mode of Transmission:
  - Sexual contact
  - Through birth canal neonatal infection

Treatments

- Use of sunscreen on the lips and face

- In sever case, 200 mg of acyclovir administered five times each day for 5 days

HERPES ZOSTER (SHINGLES)

- Infection caused by the varicella-zoster virus
- Characterized by a painful vesicular eruption
- Reflects lowered immunity
- The virus travel by way of the peripheral nerves on the skin
- Create a red rash of small, fluid filled blisters along the area of the

Clinical Manifestations

- Vesicular eruption
  - Grouped
  - Accompanied by burning pain
  - Radiate over the entire region supplied by the affected nerves
  - Unilateral, involving the thoracic, cervical and cranial nerves





Management

- The pain is controlled with analgesics
- Systemic corticosteroids
- Start early oral antiviral
- Apply wet dressing or medication to the lesion
- Systemic antibiotic to control

Complications

- Scarring
- Post-herpetic neuralgia
- Eye complications


UBC
Dermatology

FUNGAL SKIN INFECTION (MYCOSIS)

- The most common fungal skin infection is **tinea**
- Also called ringworm because of its characteristic appearance of ring
- Affect the head, body, groin, feet, and nails

TINEA PEDIS: ATHLETE'S FOOT

- Ringworm of the feet
- Affects the soles of the feet or the space between the toes
- There are dry scaly types of lesion
- Prevalent in those who use communal showers or swimming pools
- **Mode of transmission**
  - Contact with an infected person

Clinical manifestation

- Red weeping vesicles that can be accompanied with itching and burning sensation
-
- The nail may also be involve with chronic infection
-
- Lymphangitis & cellulitis may be seen when bacterial super infections occurs





Managements

- To reduce the inflammation and remove the crusts
  - Soak affected foot in N/S or potassium permanganate solution

- Topical antifungal applied to the infected area
  - Eg. Miconazole, clotrimazole

- General measures
  - Keep the foot clean and dry
  - Clean shoes or boil socks daily
  - Remove dead tissue and dry well between the toes
  - Wear light and open foot wear
  - Pieces of cotton can be placed between the toes at night

TINEA CORPORIS

- Ringworm of the body

- The typical ringed lesion appears on the **face**, **neck**, **trunk**, and **extremities**

- **Mode of transmission**
  - Through direct or indirect contact

Clinical manifestation

- Typical annular ringed lesion with scaly border
- It a purities

Managements

- Topical antifungal medication
- Griseofulvin or ketoconazole is used in extensive cases
- Give education to use clean towel & wash cloth daily
- All area and skin folds that retain moist must be dried thoroughly

TINEA CAPITIS

- Ringworm of the scalp
- Is a contagious fungal infection of the hair shafts and common cause of hair loss in children
- **Mode of transmission**
  - Making contact with infected persons, such as using of hat, comb and brush of diseased person

Clinical manifestation

- One or several round patches and scaling are present on scalp
- Small pustules or papules may be seen at the edges of such patches
- Patchy loss of hair
- Can be complicated by secondary bacterial infection



661

Managements

- Griseofulvin and other anti fungal agents
- The hair should be shampooed two or three times weekly with antifungal shampoo
- Topical antifungal preparation should be applied
- Family member should have a separate comb & brush

TINEA CRURIS (Jock Itch)

- Ringworm of the groin
- May extend to the inner thighs and buttock area
- Occurs most frequently in
  - Young joggers
  - Obese people
  - Those who wear tight underclothing

Management

- Topical antifungal agents
- Oral antifungal agents
- Clean affected area daily and keep it dry
- Drying powder
- Advice to wear light cotton

TINEA UNGUIUM: ONYCHOMYCOSIS

- Ringworm of the nails
- Chronic fungal infection of the toenails or, less commonly, the fingernails
- Usually caused by Trichophyton species or Candida albicans
- Associated with long-standing fungal

- The nails become thickened, friable (easily crumbled) and lusterless
- Debris accumulates under the free edge of the nail
- Ultimately, the nail plate separates
- The entire nail may be destroyed

Copyright © The McGraw-Hill Companies, Inc. Permission required for reproduction or display.



Management

- An oral antifungal agent is prescribed
  - For 6 weeks when the fingernails are involved
  - For 12 weeks when the toenails are involved
- Selection of the antifungal agent depends on the causative fungus

- Candidal infections are treated with fluconazole or itraconazole

- Griseofulvin is no longer considered effective therapy

UNIT 1

HEENT DISORDER (EYE AND EAR)

By

Zinabu Dawit(PBsc)

ASSESSMENT AND MANAGEMENT OF PATIENTS WITH EYE AND VISION DISORDERS

Anatomic and physiologic overview

LEARNING OBJECTIVES

At the end of the lectures students will be able to:

- ✓ *Know anatomy of different structures of the eyeball and adnexea*
- ✓ *Know the different bones forming the orbital walls and contents of the orbital cavity*
- ✓ *Know the blood supply and innervations of ocular structures and adnexea.*
- ✓ *Identify clinical features of ocular*

INTRODUCTION

What is ophthamology?

What is orbit?

What is eye/globe?

Anatomy of the orbit

- Orbits are pear shaped bony cavities that contain the globes, extraocular muscles, nerves, fat, and blood vessels.
- Orbital walls are composed of 7 bones: ethmoid, frontal, lacrimal, maxillary, palatine, sphenoid, and

Cont,

- Each orbit is about 40mm in height, width, and depth.
- It has four walls (medial, lateral,superior and inferior), base and an apex.

Cont,

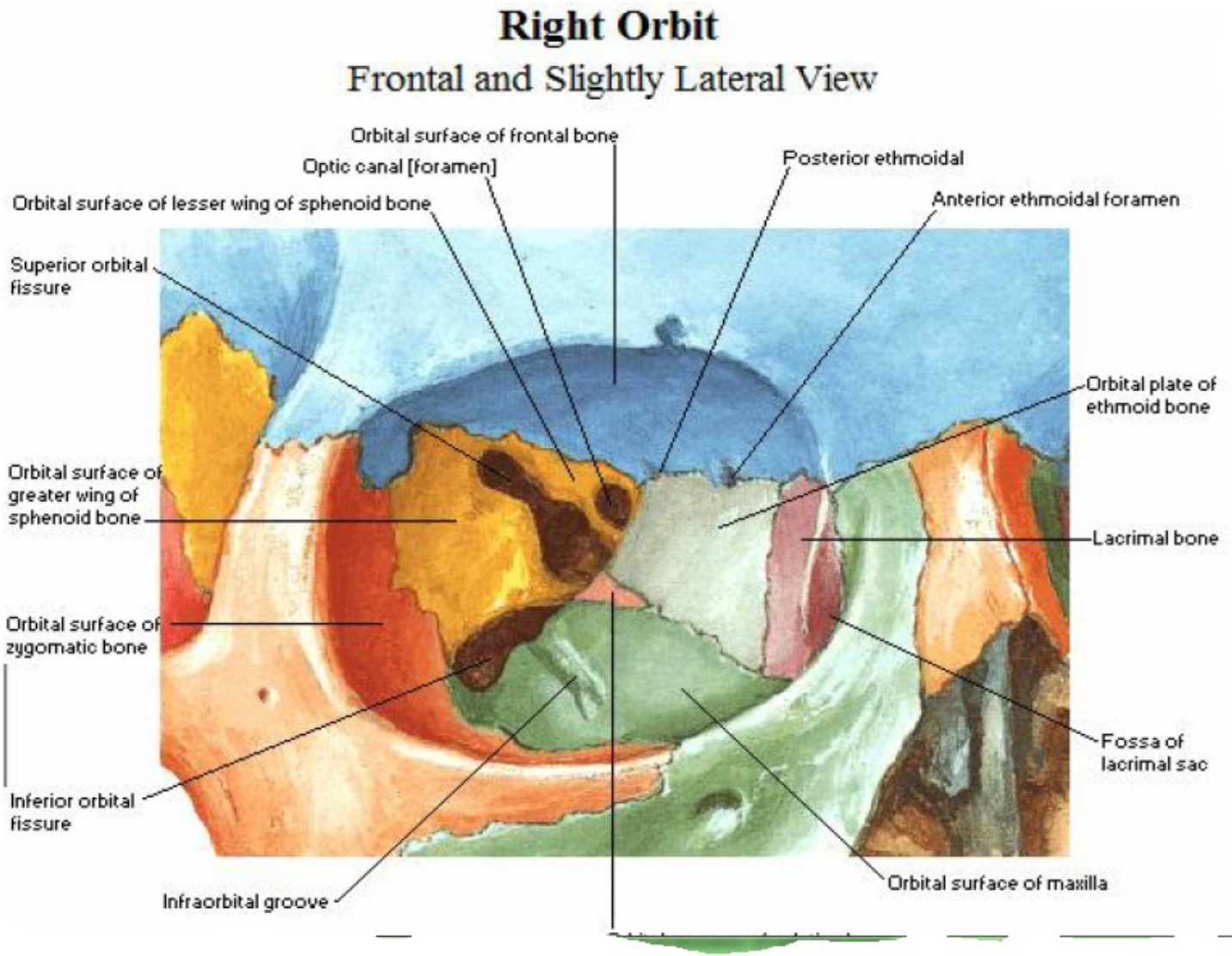
Right Orbit
Frontal and Slightly Lateral View
Orbital surface of frontal bone
Optic canal [foramen]
Posterior ethmoidal
Orbital surface of lesser wing of sphenoid bone
Anterior ethmoidal foramen
Superior orbital fissure
Orbital plate of ethmoid bone
Orbital surface of greater wing of sphenoid bone
Lacrimal bone
Orbital surface of zygomatic bone
Fossa of lacrimal sac
Inferior orbital fissure
Orbital surface of maxilla
Infraorbital groove

CONTENTS OF THE ORBIT

- The volume of each orbit is about 30 cc.
- Approximately one-fifth of it is occupied by the eyeball.
- Other contents of the orbit include:
  - ✓Optic nerve, extraocular muscles
  - ✓Lacrimal gland, lacrimal sac
  - ✓Ophthalmic artery and its branches
  - ✓Third,fourth and sixth cranial nerves and
  - ✓Fifth cranial nerve,sympathetic nerve, orbital fat and fascia.

Clinical Importance Of The Orbit

-Congenital Anomalies

-Infections

-Tumors

-Trauma/Fracture

-Surgical Spaces

Extraocular Muscles

- There are 7 extraocular muscles
  1. Medial rectus(MR)
  2. Lateral rectus(LR)
  3. Superior rectus(SR)
  4. Inferio r rectus(IR)
  5. Superior oblique(SO)
  6. Inferior oblique(IO)
  7. Levator palpebrae superioris

Origin of EOMs

- The annulus of Zinn consists of superior and inferior orbital tendons and is the origin of the four recti muscles
- The superior oblique muscle originates from the periosteum of the body of the sphenoid bone
- The inferior oblique muscle originates from the maxillary bone

Insertion of EOM

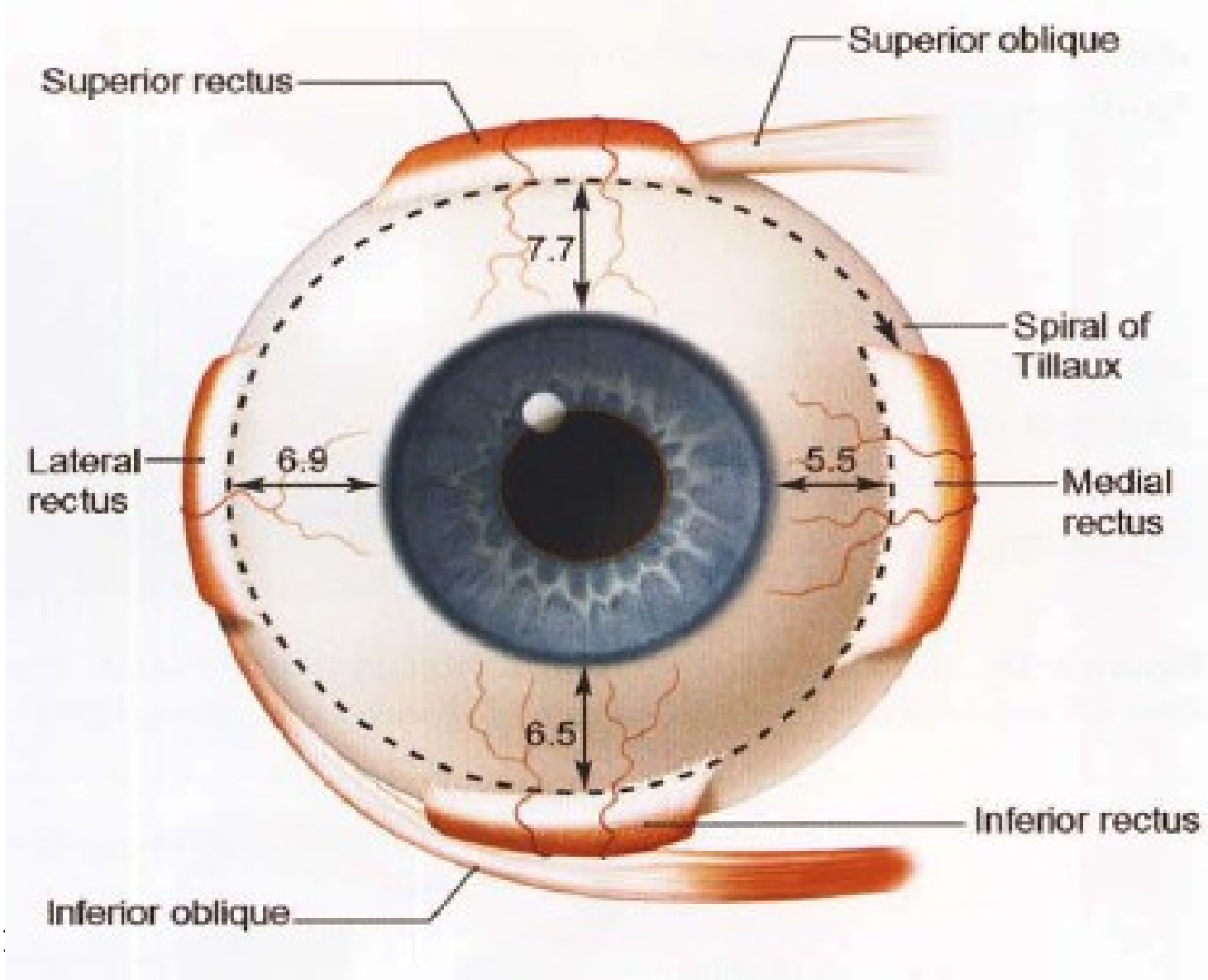

Cont,

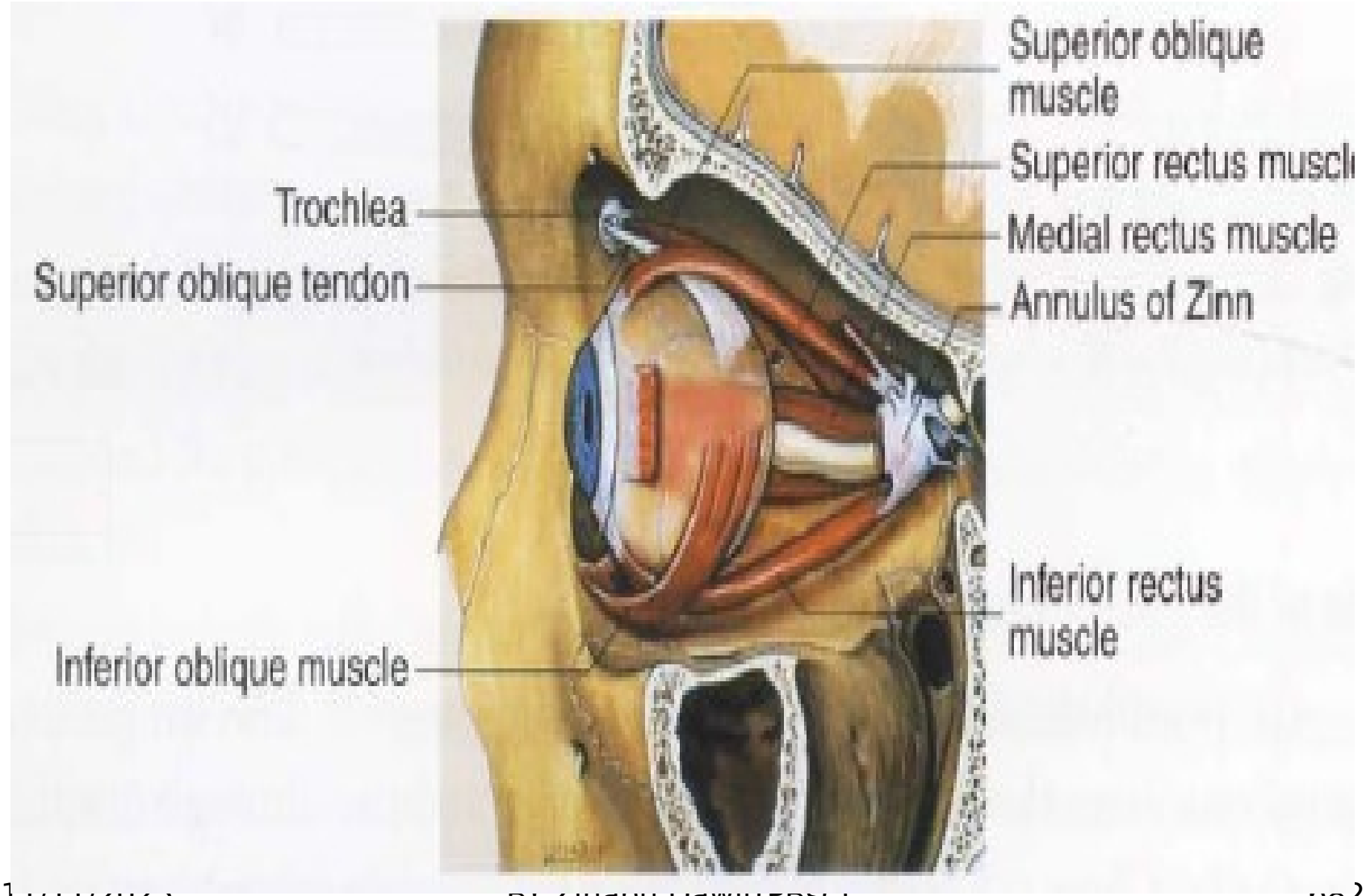
Superior oblique muscle
Superior rectus muscle
Trochlea
Medial rectus muscle
Superior oblique tendon
Annulus of Zinn
Inferior rectus muscle
Inferior oblique muscle

Actions of extraocular muscles

Muscle	Primary action	Secondary action	Tertiary action
MR	Adduction	-	-
LR	Abduction	-	-
SR	Elevation	Intorsion	Adduction
IR	Depression	Extorsion	Adduction
SO	Intorsion	Depression	Abduction
IO	Extorsion	Elevation	Abduction

Blood Supply to the EOMs

- Muscular branches of ophthamic, lacrimal, infraorbital artery.
- Venous drainage of EOMs
  - into the superior and inferior orbital veins

Innervation of EOMs

- Lateral rectus by CN VI (abducens)
- Superior oblique by CN IV (trochlear)
- Levator palpebrae superioris, superior rectus, medial rectus, inferior rectus, and inferior oblique innervated by CN III (oculomotor)

THE EYELIDS (TARSAL PLATES)

- Has 7 structural layers

I. Skin and subcutaneous tissue

II. Muscles of protraction

III. Orbital septum

IV. Orbital fat

V. Muscles of retraction

VI. Tarsus

VII. Conjunctiva

Cont,

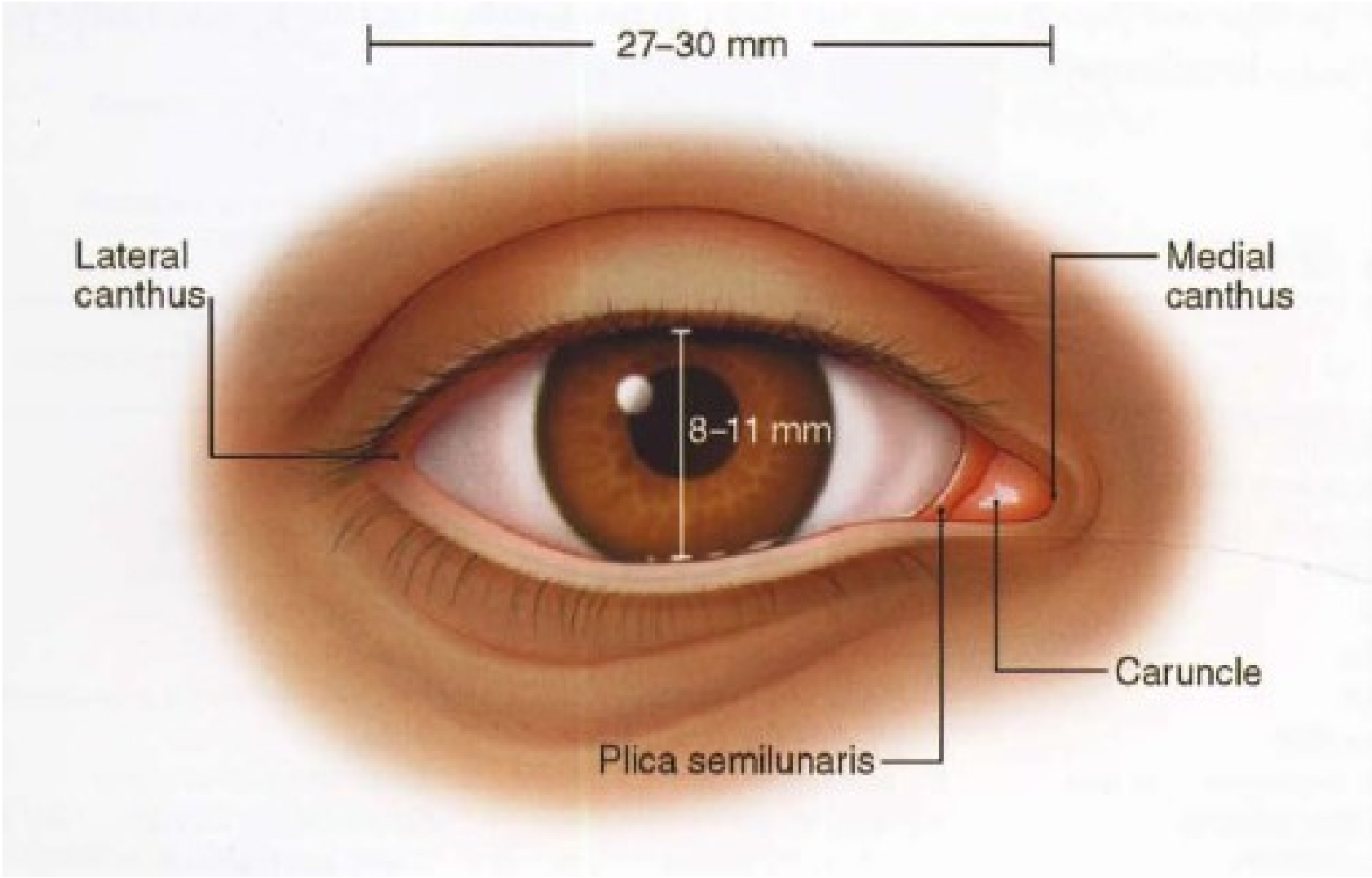
27–30 mm
Lateral canthus
Medial canthus
8–11 mm
Caruncle
Plica semilunaris

Eyelid has two lamellae (anterior & posterior):

1. Anterior lamella:

- composed of eyelid skin and orbicularis oculi muscle.

a) Eyelid skin :

- is the thinnest and most mobile skin in the body
- contains fine hairs, sebaceous and sweat glands
- no fat tissue under the eyelid skin

Cont,

Orbicularis oculi muscle:

- circular muscle inserted on the medial canthal tendon & portion of orbital rim
- has two parts
  - Orbital part,
    - Functions voluntarily only
  - Palpebral (preseptal and pretarsal),
    - Functions both voluntarily and involuntarily
- innervated by facial nerve (CN VII)

Cont,

Posterior lamella

- Composed of tarsal plate and conjunctiva.

a) Tarsal plate - a dense fibrous connective.

- Contains the meibomian glands
  - sebaceous glands secreting the oily (lipid) layer of the tear film with ducts along the lid margins
  - 30-40 in number in the upper eyelid tarsus,
  - 20-30 in number in the lower eyelid tarsus

Cont,

b) Conjunctiva:

extends from the mucocutaneous junction of the lid margin across the fornix up to the limbus. Has 3 parts

- **Bulbar**
- **Forniceal conjunctiva**
- **Palpebral conjunctiva**

- It is a mucous membrane consisting of epithelium & stroma
  - The epithelium:
    - Has 2-6 layers of non-keratinized stratified squamous epithelial cells
    - Contains goblet cells -unicellular mucous glands
  - The stroma:
    - Richly vascularized, contains lymphatic vessels, plasma cells, macrophages, and mast cells

Cont,

- Tarsal conjunctiva (unlike the forniceal and bulbar) is firmly adherent to the whole tarsal plate of the lids
- Functions of the conjunctiva:
  - physical barrier,
  - immune function,
  - goblet cells secret mucous

Eyelid margin contains:

1. Gray line
2. Eye lashes
3. Meibmian gland openings
4. Punctum

Cont,

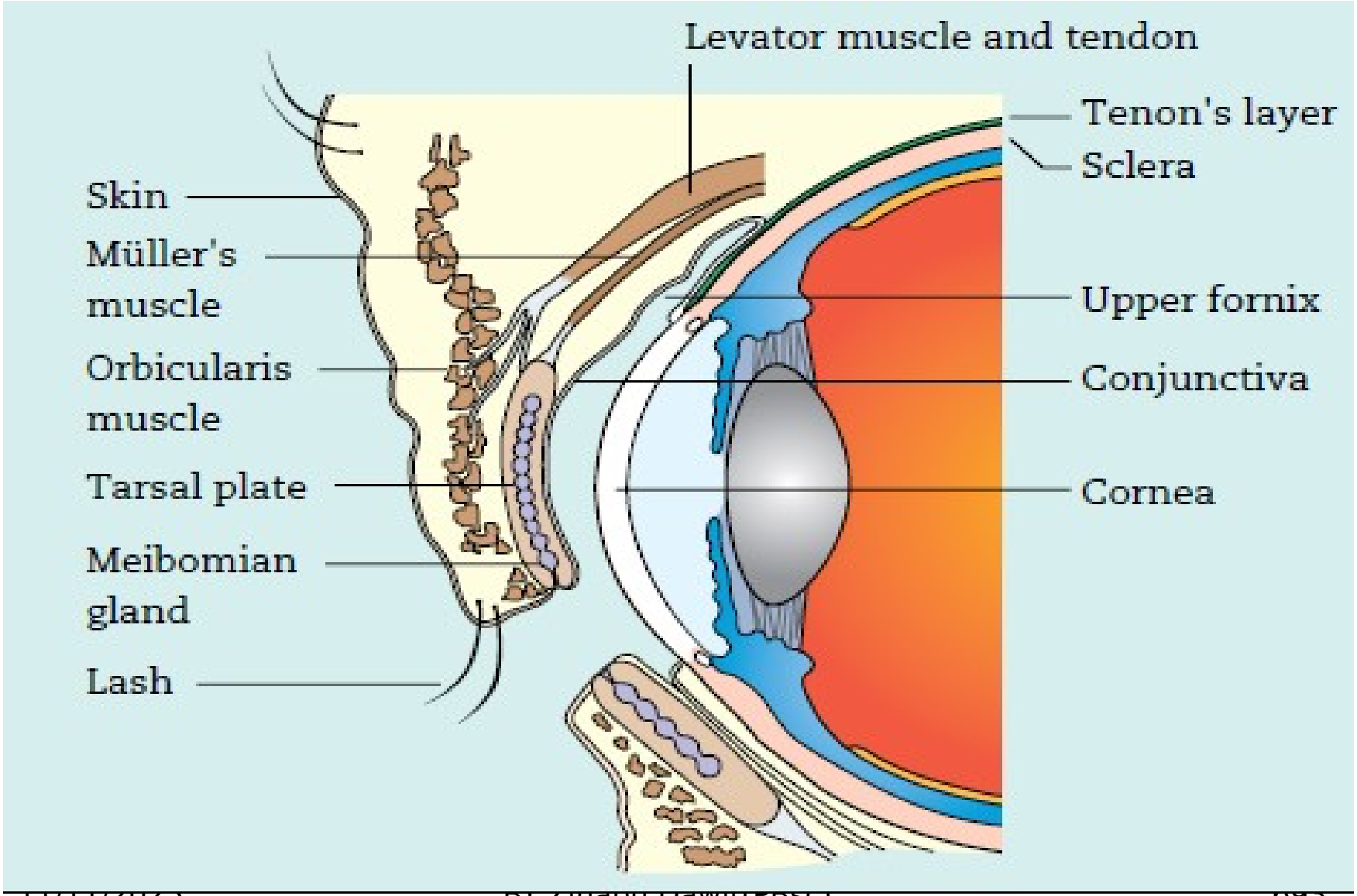
Levator muscle and tendon
Tenon's layer
Sclera
Skin
Müller's muscle
Upper fornix
Orbicularis muscle
Conjunctiva
Tarsal plate
Cornea
Meibomian gland
Lash

Vascular Supply of the Eyelids

- Derived from the facial system, which arises from the external carotid artery, and the orbital system, which originates from the internal carotid artery along branches of the ophthalmic artery.
- Venous drainage: either to superior ophthalmic v or internal jugular vein /external jv

Cont,

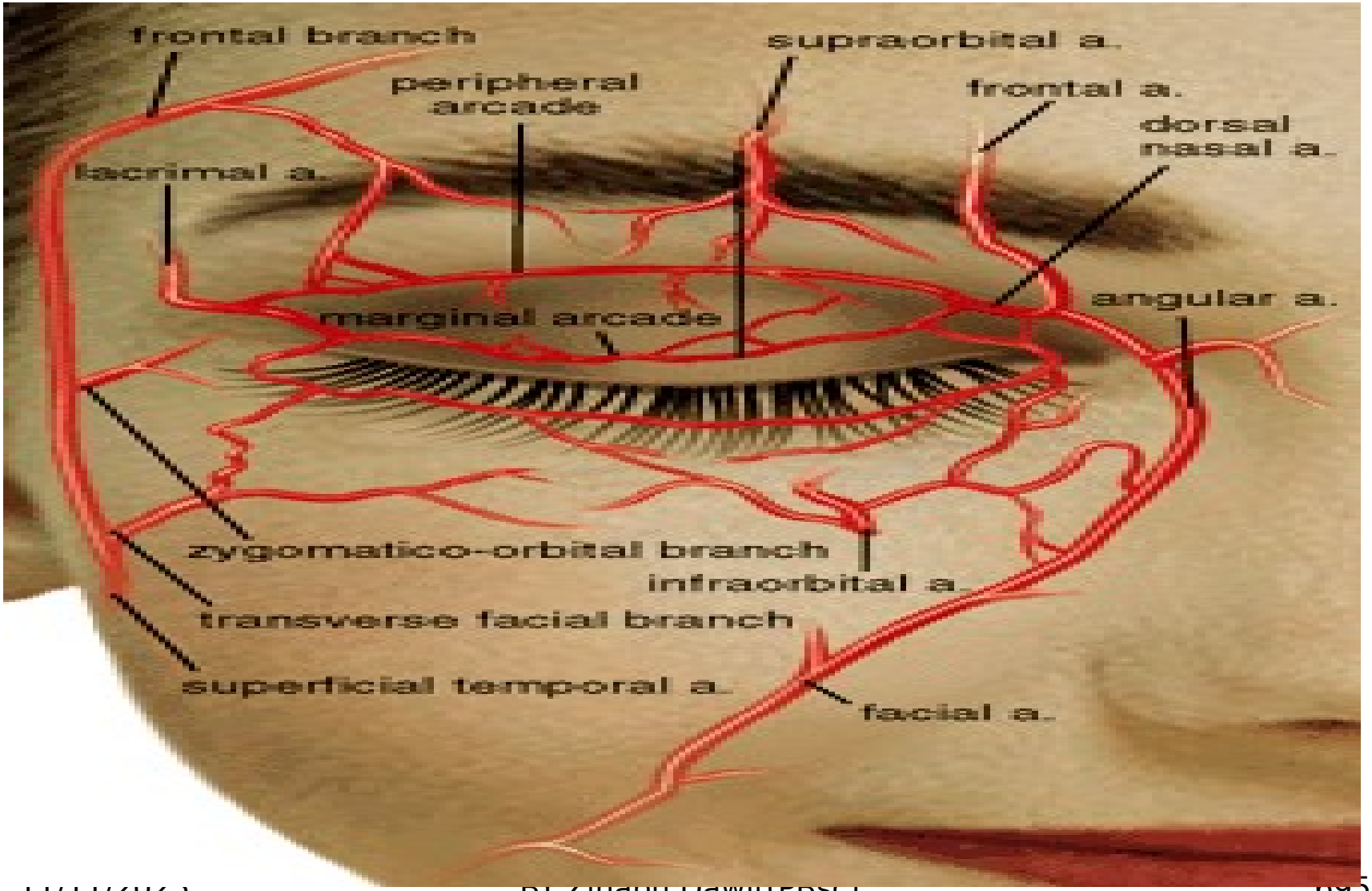
frontal branch
peripheral arcade
supraorbital a.
frontal a.
dorsal nasal a.
lacrimal a.
angular a.
marginal arcade
zygomatico-orbital branch
infraorbital a.
transverse facial branch
superficial temporal a.
facial a.

The eyelids:

. Provide mechanical protection to the anterior globe;

. Secrete the oily part of the tear film;

. Spread the tear film over the conjunctiva and cornea;

. Prevent drying of the eyes;

. Contain the puncta through which the tears drain into the lacrimal drainage system.

Cont,

- **Common clinical importance**
  - Ptosis
  - Chalazion
  - Trichiasis
  - Blepharitis
  - Entropion
  - Ectropion

lacrimal Gland and Excretory System

- Lacrimal Gland: is located in a shallow depression with in orbital part of

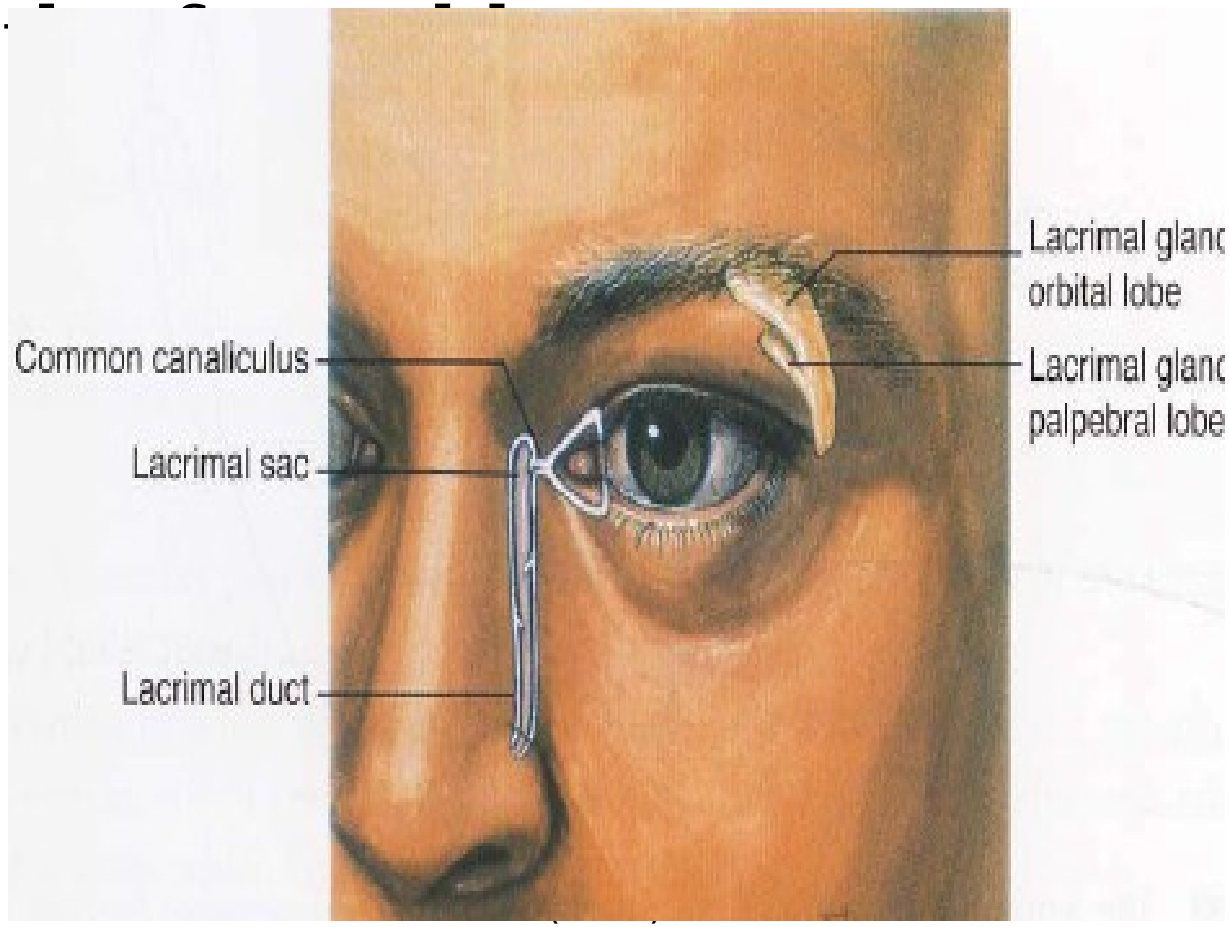

Cont,

The Main Lacrimal Gland-_

- 20mm X 12mm X 5mm
- Has two lobes separated by lateral horn of levator aponeurosis. *Next slide Fig*

1-*Orbital lobe*

lies within the lacrimal gland fossa on the orbital roof anterolaterally

2. *Palpebral lobe*

smaller (1/3rd of that of the orbital lobe

Cont,

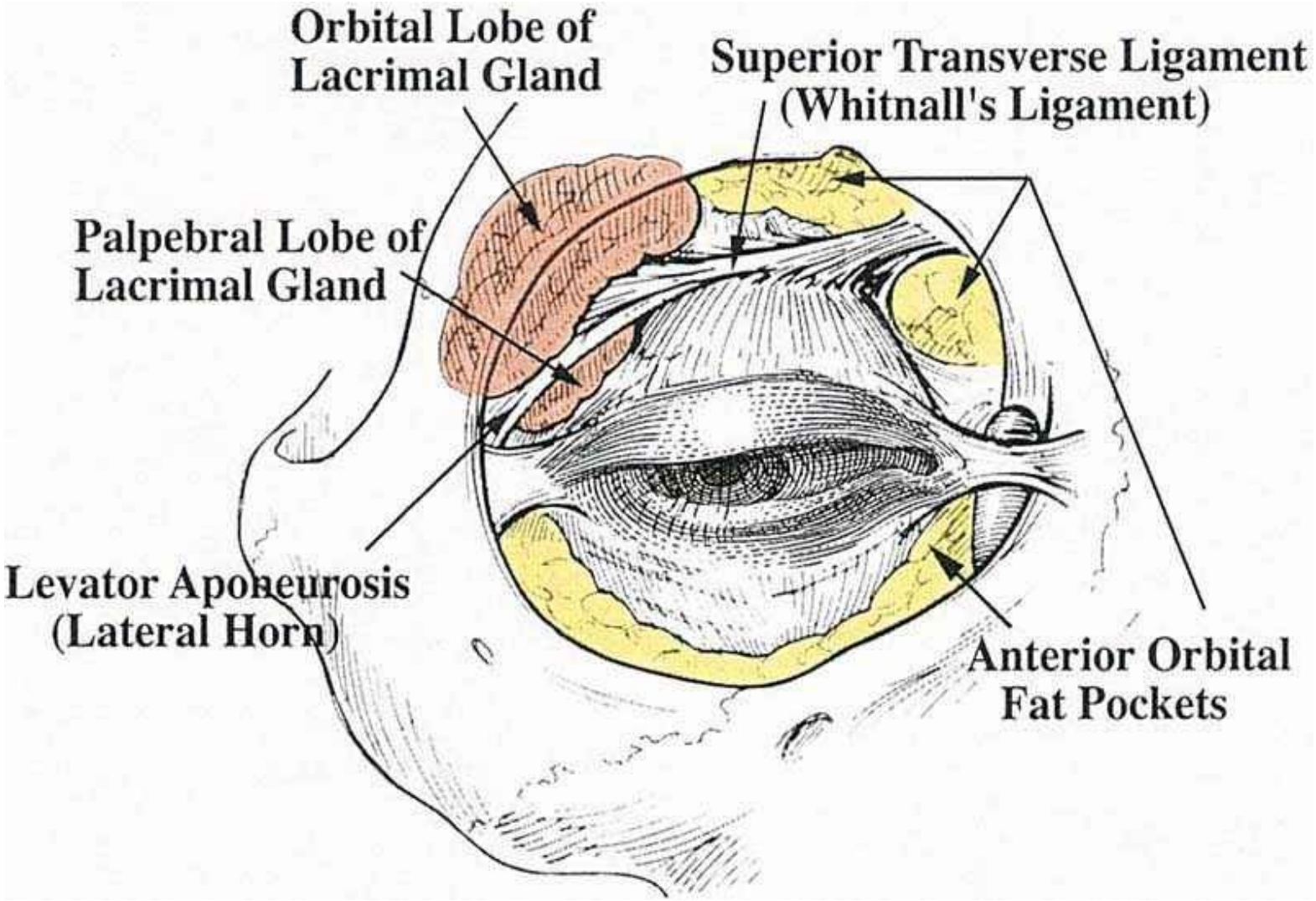
Orbital Lobe of
Lacrimal Gland
Superior Transverse Ligament
(Whitnall's Ligament)
Palpebral Lobe of
Lacrimal Gland
Levator Aponeurosis
(Lateral Horn)
Anterior Orbital
Fat Pockets

Cont,

Accessory lacrimal glands (of Krause & Wolfring)

-Located in the superior fornix (Krause) & above the superior border of the tarsus (Wolfring). Fig

-Account for only 10% of the total lacrimal secretory mass

Tear secretion

- Three sources:
  1. Lacrimal gland (main & accessory)
     - Aqueous (watery) part of the tear
  2. Meibomian glands
     - Oily (lipid) component of the tear
  3. Goblet cells of the conjunctiva
     - Mucous (mucin) component of the tear

Tear Drainage (Excretory) System

- Includes
  1. Punctum (upper & lower),
  2. Canaliculus (upper & lower),
  3. Lacrimal (tear) sac, and
  4. Nasolacrimal duct. Figs

- *Tear Drainage pathways:*
  - Punctum canaliculus common canaliculus lacrimal sac nasolacrimal duct inferior nasal meatus.

Cont,

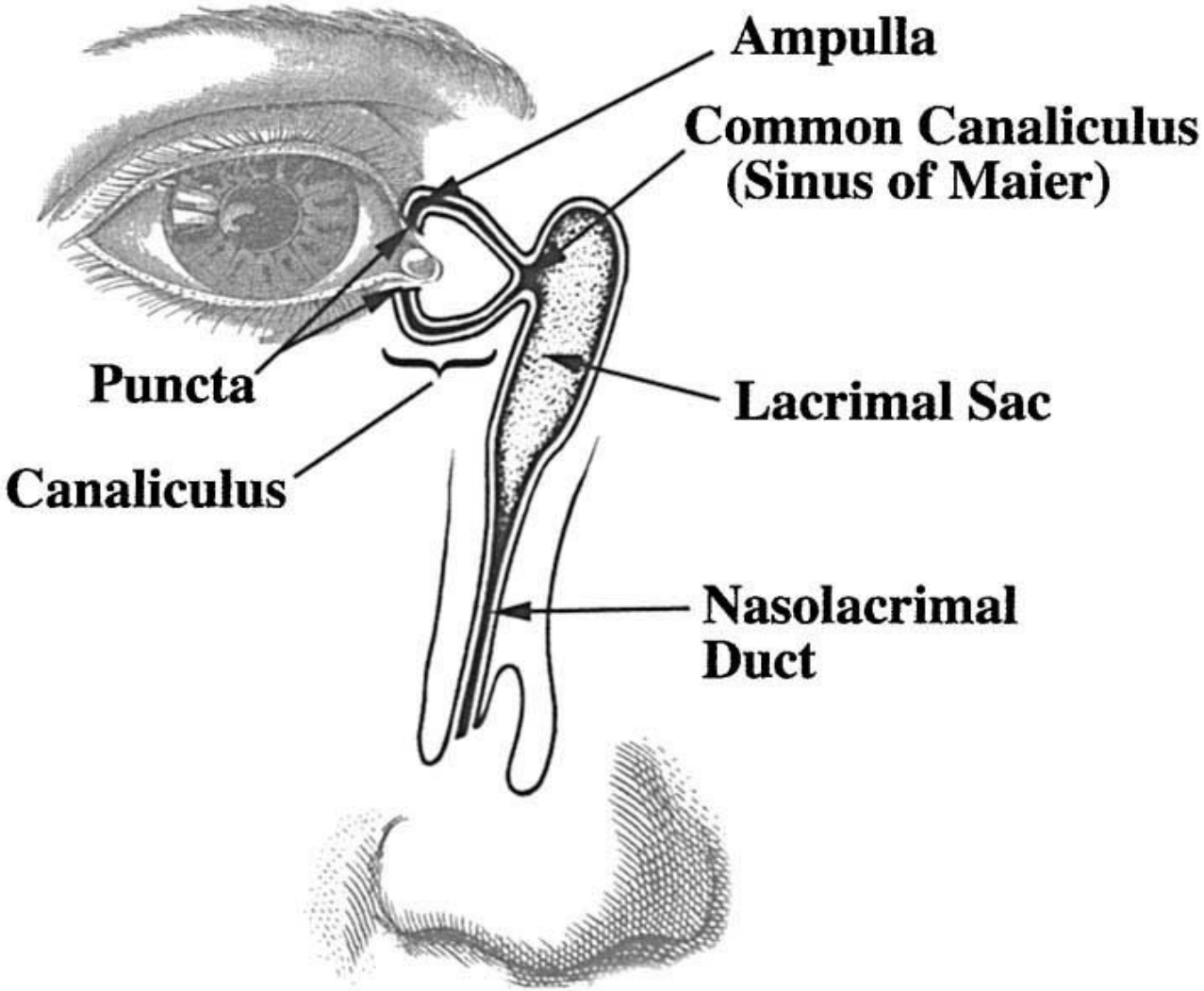
Ampulla
Common Canaliculus
(Sinus of Maier)
Puncta
Lacrimal Sac
Canaliculus
Nasolacrimal
Duct

Functions of the tear

- Wetting the ocular surface
- Wash debris
- Refraction (at air-fluid junction)
- Immunoglobulins
  - IGA

- Lysozyme
  - antibacterial enzyme/protein secreted by epithelial cells of the lacrimal gland
- Lactoferrin
  - iron-carrying protein secreted by the lacrimal gland
  - antibacterial enzyme

ANATOMY OF THE EYE

- The eye or globe is oblate spheroid shape with anteroposterior diameter of about 23-35mm and transverse diameter of 24mm.
- It contains 3 compartments: anterior and posterior chamber and vitreous cavity.
- Has 3 layers:
    1. Outer layer consists of *cornea and sclera*
    2. Middle layer is *uvea*
    3. Inner layer *retina*

Cont,



Cont,

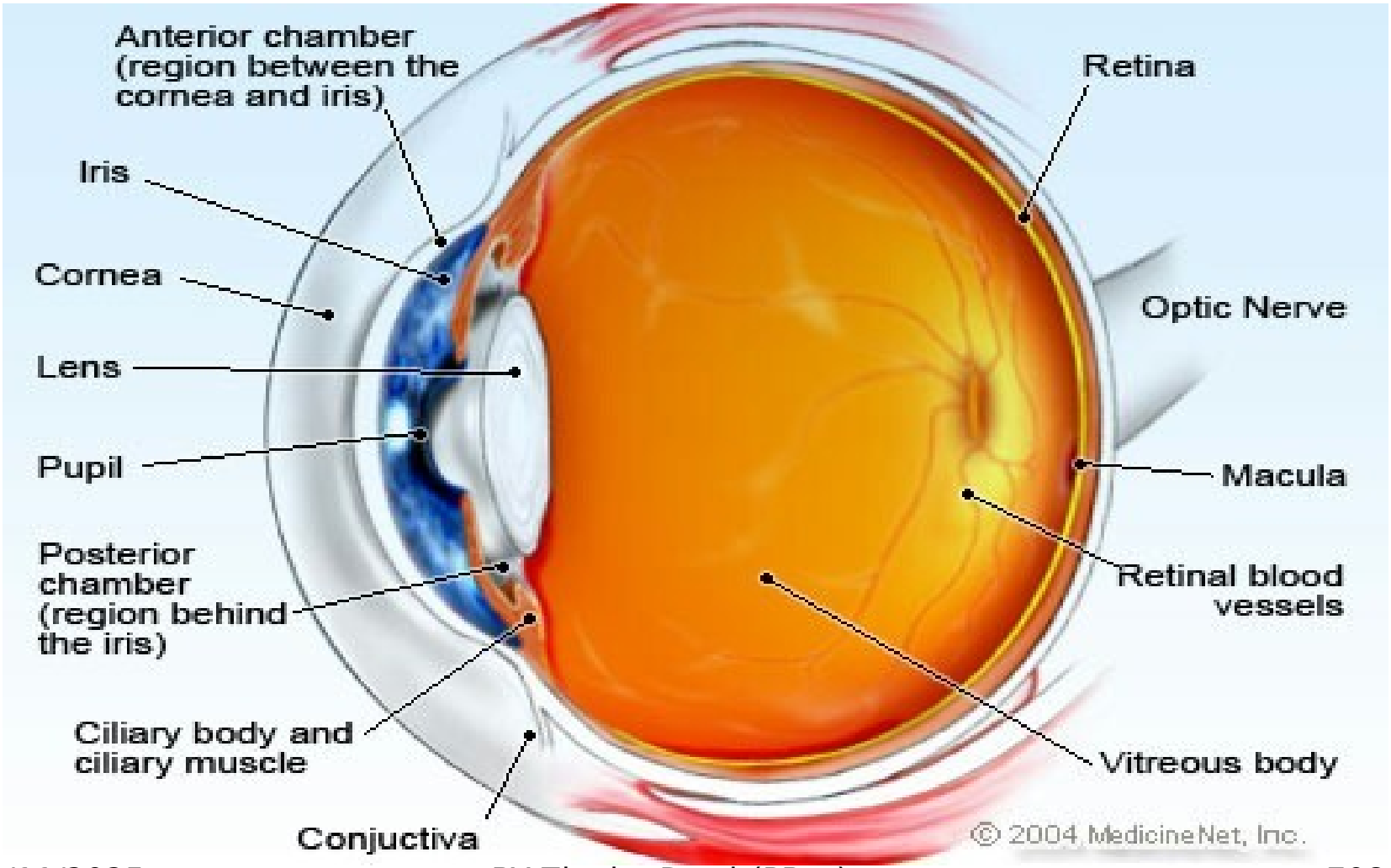
Anterior chamber (region between the cornea and iris)
Iris
Cornea
Lens
Pupil
Posterior chamber (region behind the iris)
Ciliary body and ciliary muscle
Conjuctiva
Retina
Optic Nerve
Macula
Retinal blood vessels
Vitreous body
© 2004 MedicineNet, Inc.

Cont,

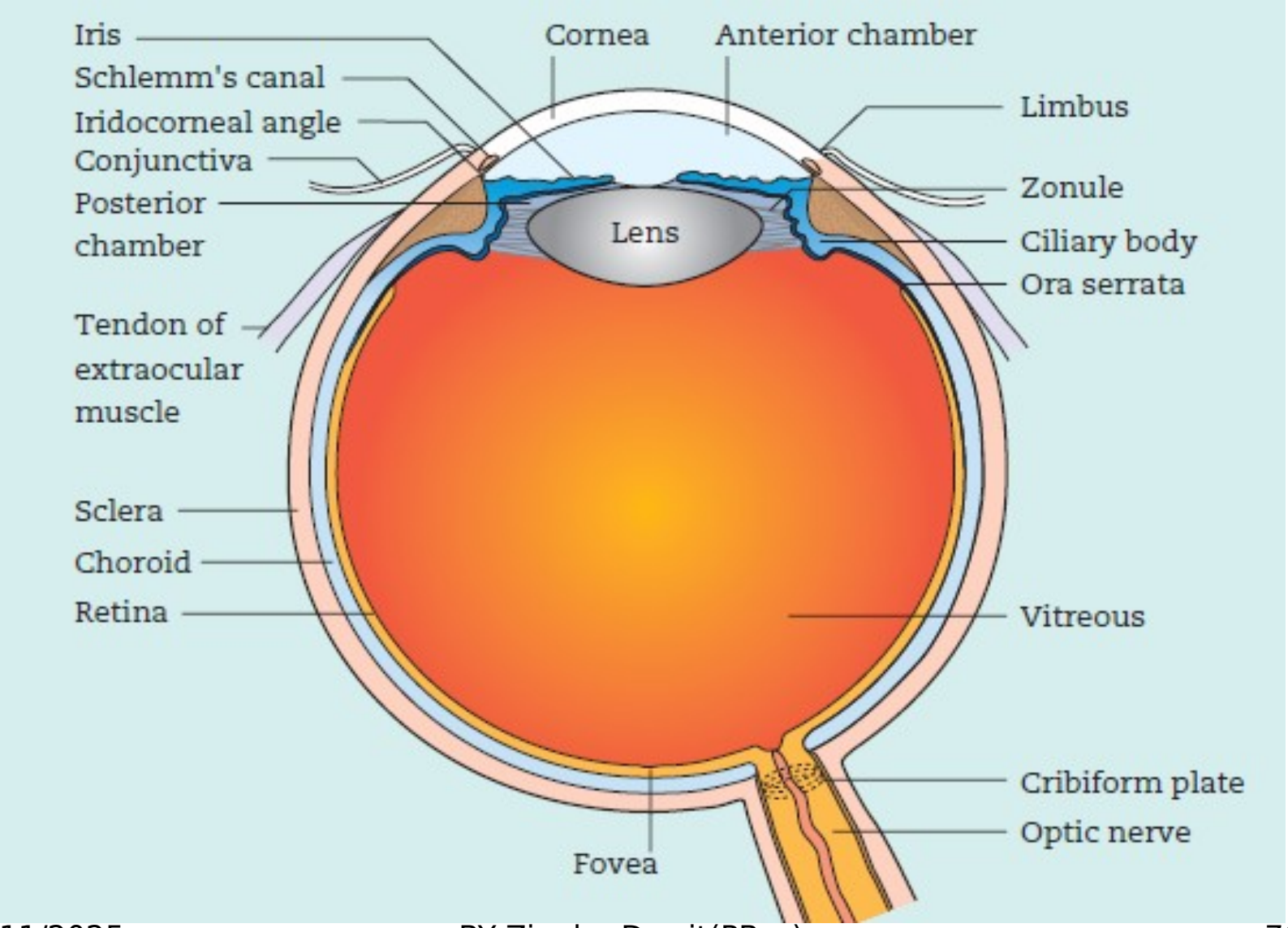
Iris
Schlemm's canal
Iridocorneal angle
Conjunctiva
Posterior chamber
Tendon of extraocular muscle
Sclera
Choroid
Retina
Cornea
Anterior chamber
Lens
Fovea
Limbus
Zonule
Ciliary body
Ora serrata
Vitreous
Cribiform plate
Optic nerve

Cornea

- Cornea is a transparent, avascular tissue occupy 1/5th of anterior eye.
- Continuous with conjunctiva at limbus
- Has about 0.5mm thickness
- It has five layers epithelium, bowman’s membrane, stroma, descement membrane and endothelium.

Cont,

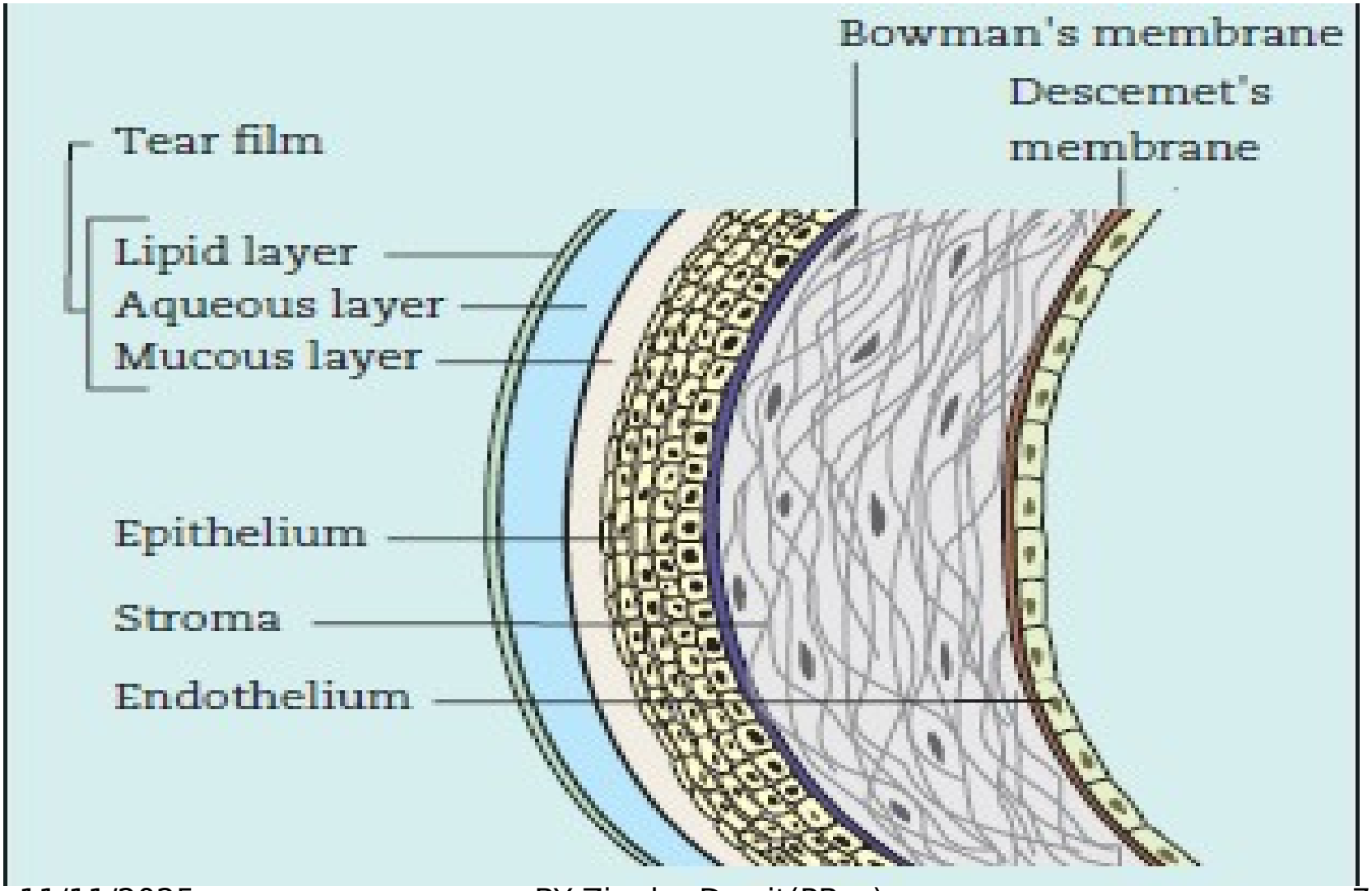
Bowman's membrane
Descemet's membrane
Tear film
Lipid layer
Aqueous layer
Mucous layer
Epithelium
Stroma
Endothelium

Cont,

- *Cornea is nourished from 3 sources:*
  1. A plexus of fine capillaries at the limbus
  2. The tear film
  3. The aqueous humor
- It is highly innervated by posterior ciliary nn braches of CNV

  the most senstive part of our body.
- Functions of cornea

  Refracts light(about 43D)

  Protects the internal ocular structures

The sclera

- It is opaque white, tough connective tissue that covers the posterior 4/5th of the globe with posterior opening for optic nerve.
- It has variable thickness 1mm around optic nn head and 0.3mm just posterior to muscle insertions.
- Limbus the transition zone between the peripheral cornea and the anterior sclera.

Cont,

- *Episclera* –
  - is a loose elastic connective tissue
  - covers the sclera
  - unites the sclera with the conjunctiva above
  - highly vascularized (unlike the sclera

Anterior Chamber

- Is bordered anteriorly by the cornea and posteriorly by the iris diaphragm and the pupil. The average normal depth at the center is 3mm with volume of 200ul and filled with aqueous humor.
- The anterior chamber angle, which lies at the junction of the cornea and the iris, consists of the following structures.

Cont,

Schwalbe line

- The schlemm canal and trabecular meshwork
- Scleral spur
- Anterior border of the ciliary body (where its longitudinal fibers insert into the scleral spur)

Cont,

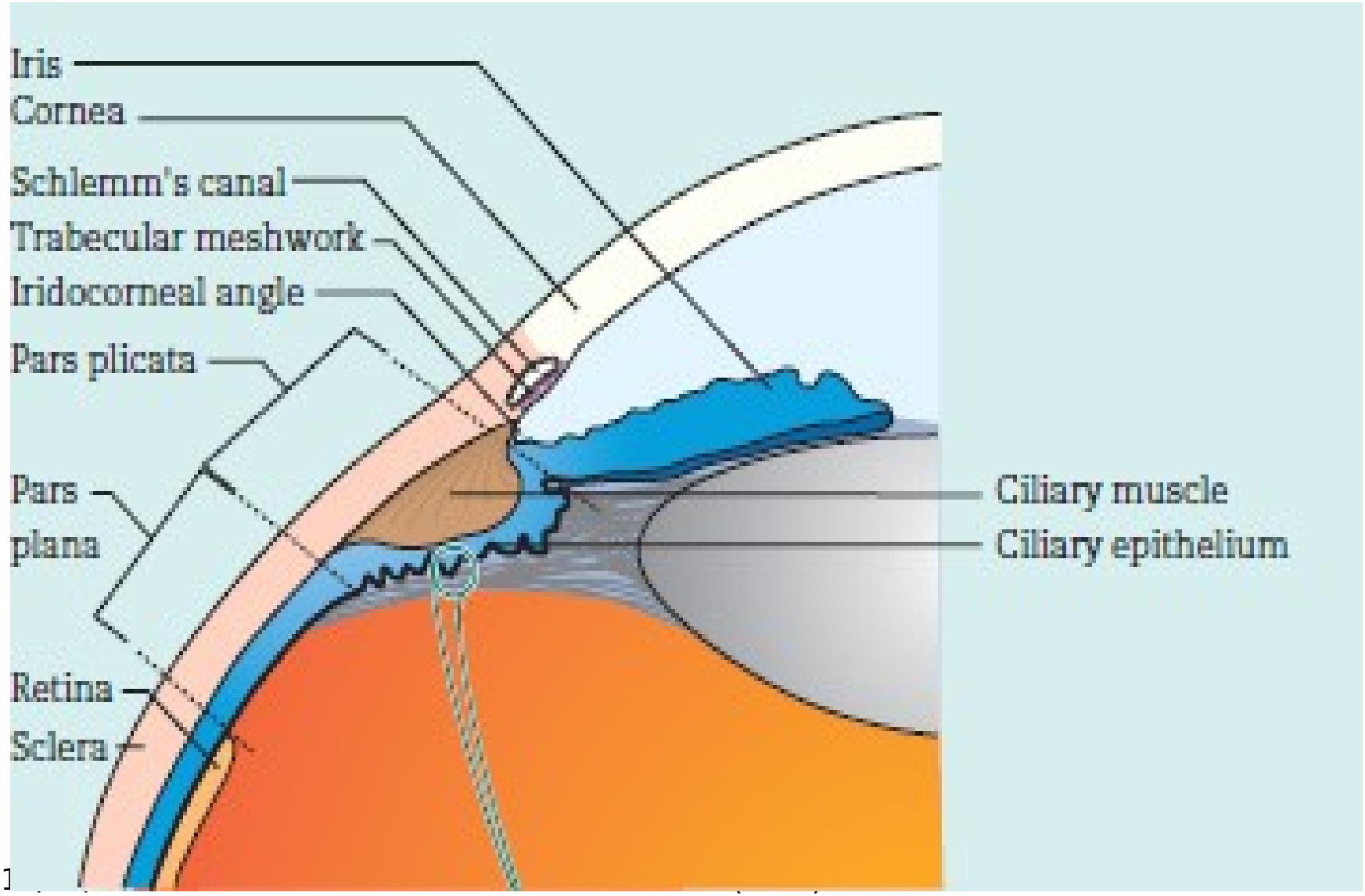
Iris
Cornea
Schlemm's canal
Trabecular meshwork
Iridocorneal angle
Pars plicata
Pars plana
Retina
Sclera
Ciliary muscle
Ciliary epithelium

Aqueous Humor Outflow

- Aqueous humor is produced by ciliary process from posteriorly and enter to anterior chamber though pupillary opening.

It has two outflow mechanisms:

pressure-dependent outflow

pressure-independent outflow

Cont,

Physiology of aqueous humor circulation.

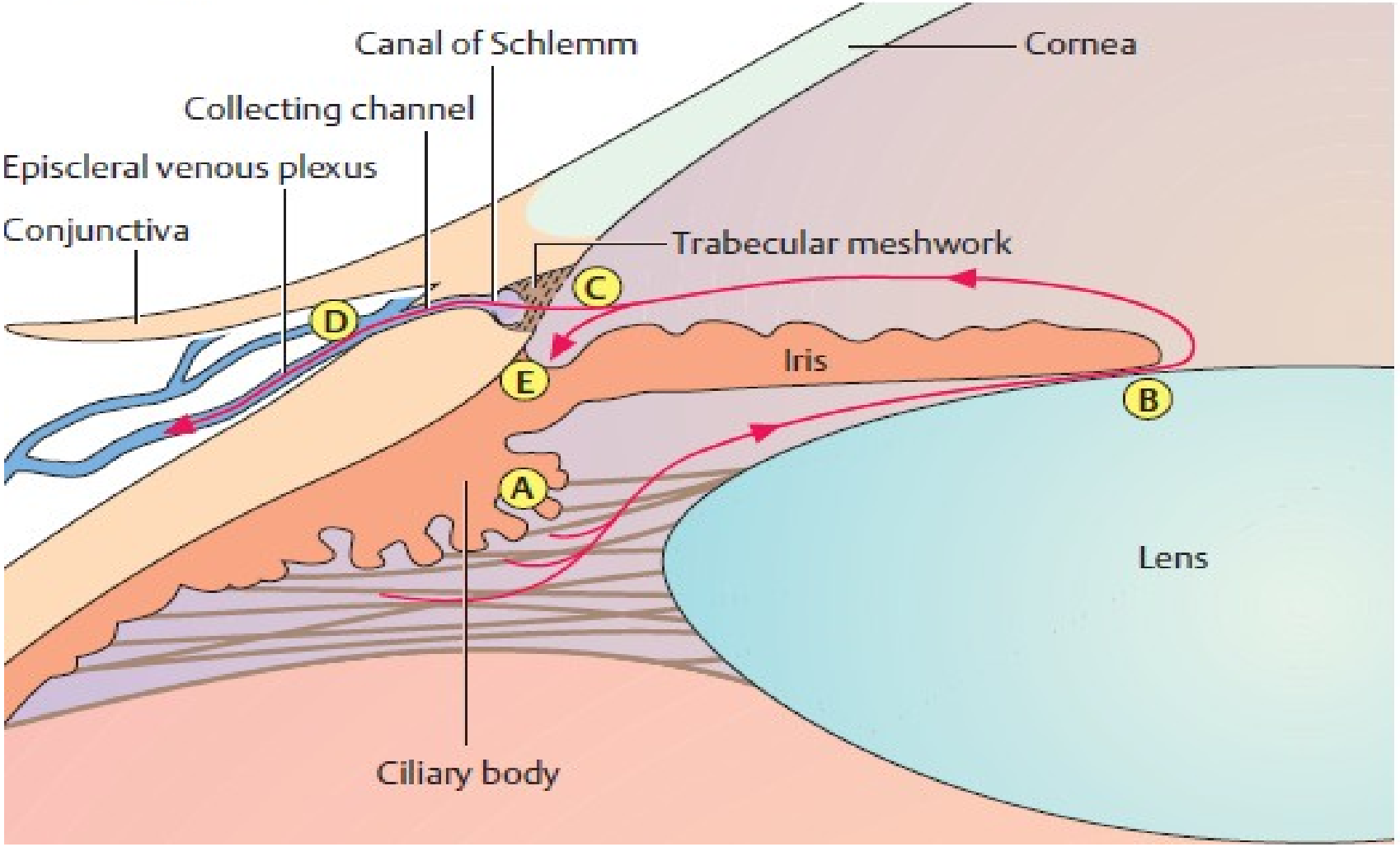

Trabecular Meshwork

- is a circular sponge work of connective tissue lined by trabeculocytes which has contractile properties that may influence out flow resistance.
- Has 3 layers:

1. uveal portion
2. corneoscleral meshwork
3. juxtacanalicular tissue,

Posterior chamber-

- *Bounded anteriorly by the iris & posteriorly by lens & ciliary processes*
- *is filled (occupied) with 0.06ml of aqueous humor*
- ***Functions**: provides optical transparency, structural integrity, and nutrition for the avascular structures of the eye*

Uveal Tract

is the main vascular compartment of the eye

Has 3 parts

1. Iris
2. Ciliary body
3. choroid

1.Iris

- The most anterior extension of uveal tract made up of blood vessels and connective tissue.
- The aperture of iris form pupil
- It subdivides the anterior segment into the anterior and posterior chambers.
- Controls the size of pupil(average 3mm) with it’s dilator and sphincter muscles

Cont,

- **Iris has two layers-**
  1. stroma- anterior layer (surface) containing the iris smooth muscles & blood vessels
  2. epithelium- posterior pigmented layer

- Two smooth muscles in the iris stroma
  1. Iris sphincter muscle (sphincter pupillae)
     - at the papillary margin
     - function- to constrict the pupil
     - innervated by parasympathetic nerve fibers from CN III

Cont,

2. Iris dilator muscle (dilator pupillae)

- function- to dilate the pupil
- innervated by sympathetic fibers from the superior cervical ganglion

2. Ciliary Body- middle layer

- is in direct continuity with the iris
- composed of Pars plicata and Pars Plana
- contains the ciliary processes (70-80 in #)
  site of aqueous humor production
- has the ciliary muscle which lies against the sclera on the outer side of the ciliary body
- ciliary muscle controls the focusing ability (accommodation) of the eye

3. Choroid - inner layer

- is the posterior extension of the ciliary body
- Lies between the retina & sclera
- Thickness 0.2-0.3 mm
- is a highly pigmented & vascular tissue
- Primarily vascular structure with extensive vascular supply from the short and long posterior ciliary Arteries
- Venous drainage is via the vortex veins
- Function is to provide nourishment for the outer layers of the retina

The Lens

- clear transparent biconvex disc like structure
- suspended in place by zonular fibers
- Anterior pole
  - is the center of the anterior surface of the lens
  - Is about 3mm from the back surface of the cornea
- Posterior pole
  - is the center of the posterior surface of the lens
- Lens equator
  - peripheral part of the lens where the zonules attach
  - peripheral margin lies about 0.5mm from the ciliary processes

Cont,

- The equatorial diameter of the lens is about 9-10mm
- *A-P diameter of the lens is 4.5mm*

The lens has 3 parts:

1. *capsule* - a transparent, highly elastic envelope surrounding the cortex,
   - Thinnest part is at posterior pole=4μm
2. *cortex* -the outer lens fibers form the lens cortex
3. *Nucleus* -the harder central portion of the lens found in adults 30 years or older

- Epithelial cells of the lens
  - Located only under the anterior lens capsule
  - Produce new lens fibers (the lens continues to grow through out life

Cont,

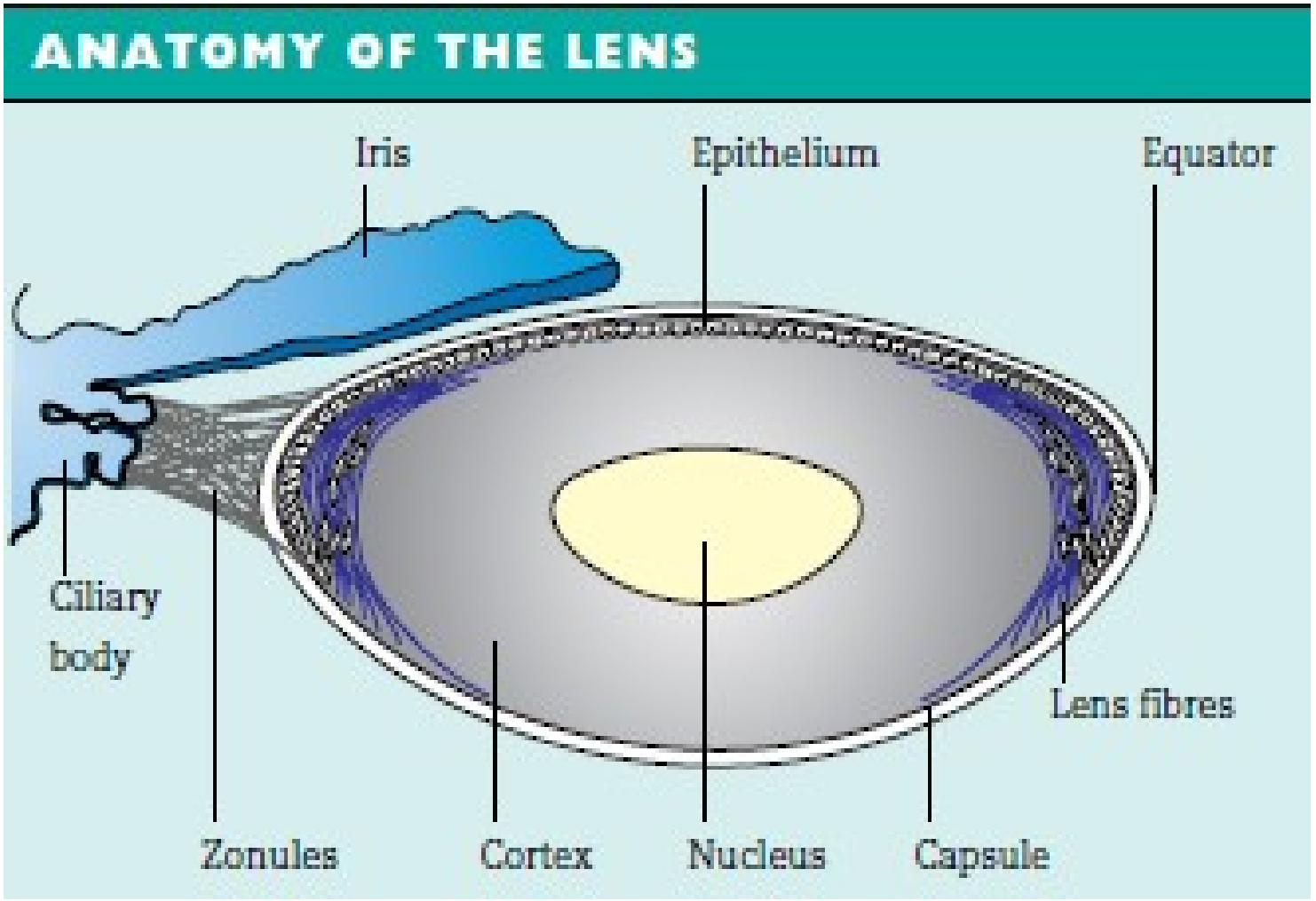
ANATOMY OF THE LENS
Iris
Epithelium
Equator
Ciliary body
Lens fibres
Zonules
Cortex
Nucleus
Capsule

Function of the lens

- Refraction and focusing of light over the retina
- Accommodation

NB:

- *The lens continues to grow throughout life and new lens fibers are produced by lens epithelial cells (metabolically most active cells of the lens)*
- *The lens has neither blood nor nerve supplies*
- *Gets nutrients from aqueous humor by diffusion*
- *Cataract (lens opacity) is the commonest cause of blindness in developing countries*

Vitreous

- jelly, transparent, thick viscous structure,
- occupies the vitreous chamber in the posterior concavity of the globe. fig
- it fills the largest cavity of the eye, occupying 2/3rd of its volume (4ml)
- surrounded mainly by retina
- Vitreous base:
  - part of the vitreous about 4mm across ora serrata
  - Strongest attachment to retina

  Other strong attachments are at optic disc margins, foveal region and back of crystalline lens.

Cont,

- Vitreous consists of
  - water -almost 99% is water
  - Collagens -important structural protein in vitreous,
  - Mucopolysaccharide, glycoproteins, ascorbic acid (antioxidant)
  - hyaluronic acid (shock absorber)
- Function:
  - Structural – maintains the shape of the eyeball
  - Shock absorber
  - absorbs UV light protecting the retina from damage
  - Antioxidant (serve as a free-radical scavenger)

The Retina

- innermost layer of the eyeball.
- is part of the brain
- Thickness –
  - 0.56mm at the optic disc
  - 0.18mm at the equator
  - 0.10mm at the ora serrata

Macula (macula lutea)

- Is the posterior fundus area lying temporal to the optic disc & b/n the vascular arcades

Ora serrata –

- the junction of the peripheral retina & the ciliary body

Cont,

- *Blood supply of the retina –*
  - Inner 2/3 rd is by central retinal artery giving a branch for each of the four quadrants of the retina. fig
  - outer 1/3rd is avascular & gets oxygen & nutrients by diffusion from the choriocapillaries (choroid)
- ***Venous drainage-***
  - Central retinal vein draining into the ophthalmic veins which drains into cavernous sinuses

The optic nerve

This is formed by the axons arising from the retinal ganglion cell layer, which form the nerve fibre layer, the innermost layer of the retina.

Passes out of the eye through the cribriform plate of the sclera, a sieve like structure.

- It is surrounded by dura, arachnoid and pia mater. The central retinal artery and vein enter the eye in the centre of the optic nerve.
- The extraocular nerve fibres are myelinated; those within the eye are not.

History

- It is similar with medical history emphasizes ocular related things.
- Components of the history:
  1. identification
  2. previous admission
  3. chief compliant it is the main concern of the patient.

Complaints can be catagorized:

1.Distrubance of vision

- Blurred or decreased vision
- Altered image size
- Dark adaptation problems
- Color vision abnormalities
- Blindness

2.ocular pain and discomfort:

- Foreign body sensation
- Photophobia
- Burring
- Dryness
- Itching
- Headache

3. Abnormal ocular secretions:

- Lacrimation
- Discharge(purulent, mucopurulent, mucoid, watery)

4. Abnormal appearances:

- Ptosis
- Proptosis(exophthalmos)
- Misalignment
- Redness

Cont,

5. other complaints :

    check up

    trauma

Components of examination

1. Visual acuity is the distance at which a minimal object size seen clearly or resolving power of eye
2. Intra ocular pressure measured with tonometer. normal value 12-21mmHg
3. Ocular alignment and motility examination.
4. Exam. External eye and anexea
5. Anterior segment
6. Posterio segment
7. Pupillary reflex
8. Visual field

OCULAR DISEASES

Contents

- Diseases of the eyelids, Lacrimal apparatus, and orbit
- Diseases of the conjunctiva
- Diseases of the cornea and sclera
- Diseases of the uvea
- Diseases of the lens
- Diseases of the vitreous body and the retina

Diseases of the eyelids

- Infections & inflammations of the eye lids
  - Blepharitis . Mebomianitis
  - Hordeolum . Molluscum contagiosum
  - Lid abscess . Parasitic infections
  - Chalazion
- Positional defects of eye lids(entropion, ectropion)
- Anatomic deformities (congenital anomalies)
- Ptosis and pseudoptosis
- Blepharospasm
- Tumors of the eye lids(benign and malignant)

Blepharitis

- Is an inflammation of eyelids.
- Causes bacteria or skin conditions like dandruff or acne rosacea
- Non contagious and does not cause damage to eyesight.
- Clinical features itchy, red, irritated eyelids ,foreign body sensation and scales.

Cont,

Classification:

1. Anterior inflamation of eyelid skin, lash roots & glands along eyelid margin
   a. Staphylococal
   b. Seborrhoic
   c. Mixed
2. Posterior inflamation of tarsal plate and mebomian gland, characterized by meibomian gland dysfunction(MGD), which may lead to ocular surface disease as well.
3. Mixed anterior & posterior

- Lid hygiene with diluted baby shampoo
- Topical antibiotic ointment in severe
  - Eg TTC bid for 02 month

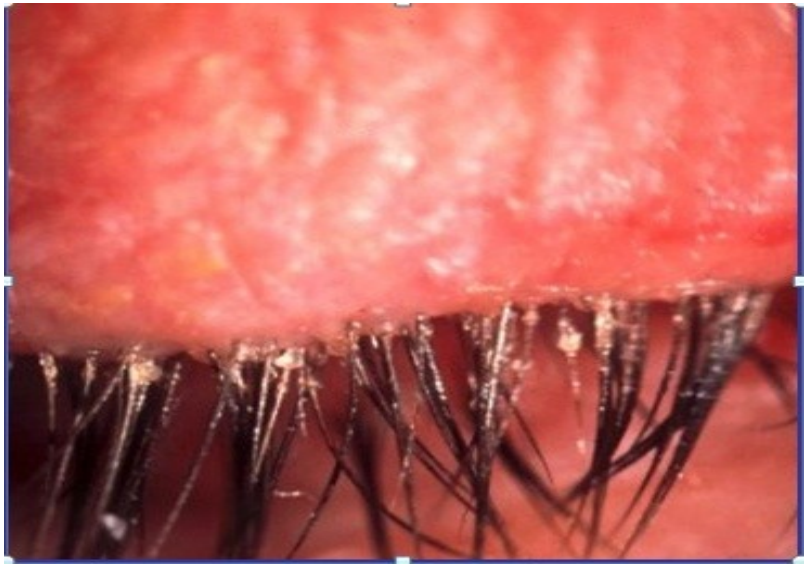

Meibomian Gland Dysfunction(MGD

- is evident by blockage of the oil glands in the eyelids, poor quality of tears, and redness of the lining of the eyelids.
- Inflammation, infection, and obstruction of these glands results in abnormal gland secretion, altered tear film physiology, and ocular surface irritation .
- Most patients have nonspecific complaints inconsistent with the degree of disease clinically evident on examination

Cont,

- The orifices are pouting, obstructed, displaced, or reduced in number. Digital pressure on the lid margins reveals hyposecreting or hypersecreting glands with a foamy, turbid, granular, or pasty discharge.

Cont,







- lid hygiene with warm compresses and expression of glands every day to alleviate symptoms.
- In severe cases, patients should take oral tetracycline (250 mg PO Qid),0r doxycycline (100 mg po Bid), for weeks to months.

Hordeolum(stye)

- It is a staphylococcal abscess of eyelash follicle or sebaceous glands of eyelash roots
- Signs:
  - Tender nodule in the lid margin pointing through the skin which may be associated with mild cellulitis
- Treatment
  - Hot compression
  - Epilation lash associated with infected follicle
  - Antibiotic ointment
  - Systemic antibiotics such as cloxacillin if preseptal cellulitis develops



Chalazion

- A chalazion is a slowly enlarging nodule on the eyelid that is formed by inflammation and obstruction of a sebaceous gland.
  - Predisposition
    - Chronic posterior blepharitis
    - Acne rosacea
    - Seborrhoic dermatiti

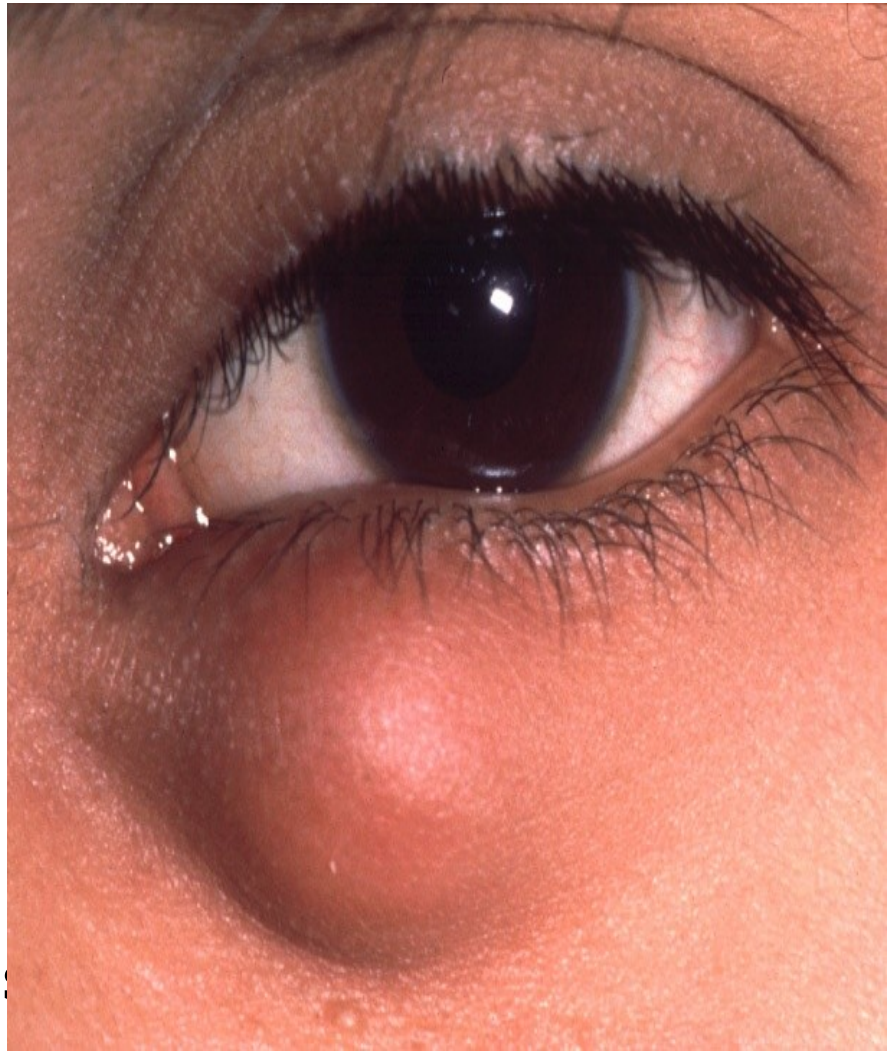

Treatment of chalazion







Molluscum contagiosum

Multiple, dome-shaped, waxy papules are situated along the lid margin

Rx curettage

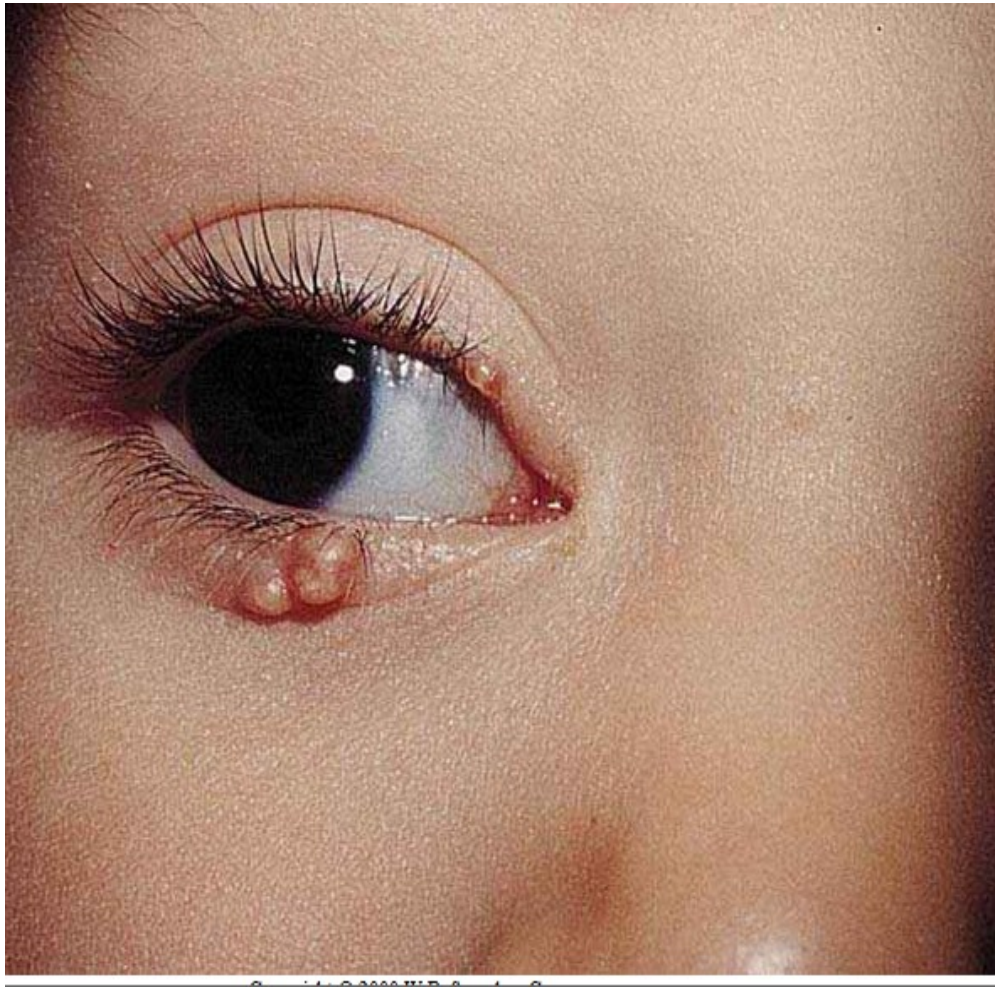

Positional defects of the eyelids

- Entropion
- Ectropion
- Trichiasis

Entropion

- Sign
  - Inward turning of the eyelid margin
- Other signs
  - Superficial punctate keratitis(SPK) (from eye lash contacting the globe), conjunctival injection
- Symptom
  - Ocular irritation, foreign-body sensation,tearing,red eye
- Etiology
  - Involutional (aging)
  - Cicatricial (Due to conjunctival scarring in trachoma, ocular pemphigoid, stevens-Johnson syndrome, chemical burn, trauma & others)
  - Spastic (Due to surgical trauma, ocular

Cont,

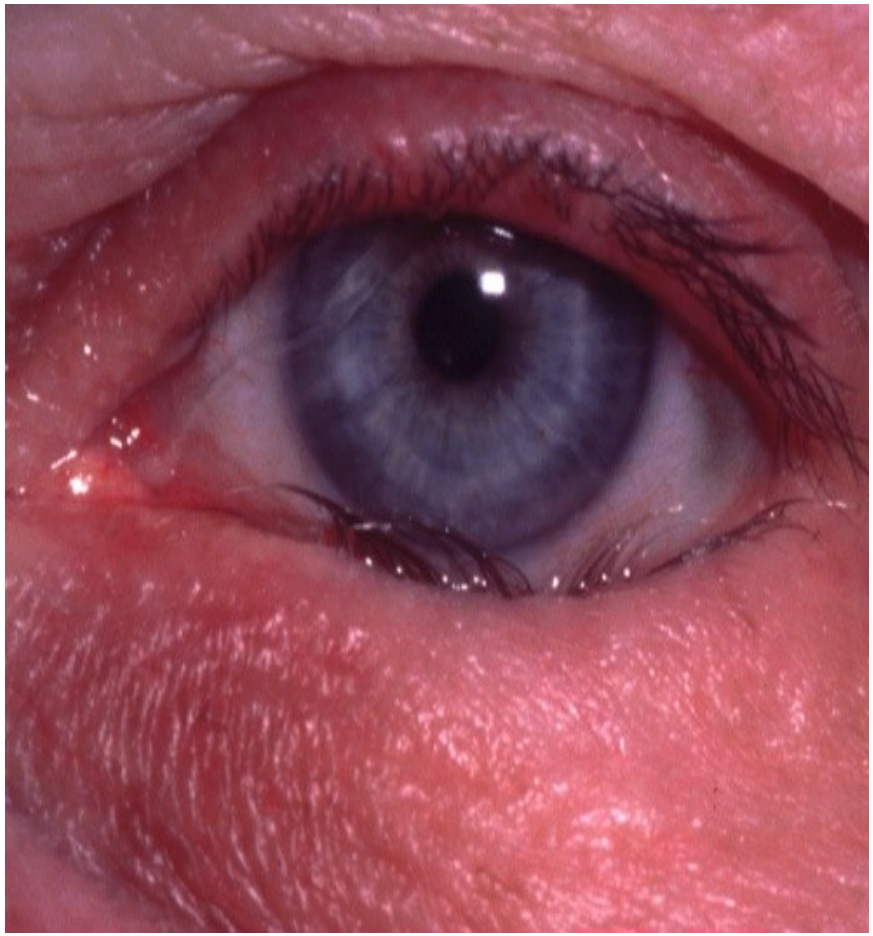



Affects lower lid because upper lid has wider tarsus and is more stable

If longstanding may result in corneal ulceration

Treatment

- 1. Antibiotic ointment for SPK
- 2. Everting the eyelid margin away from globe & taping it in place with adhesive tape may be a temporizing measure.
- 3. Surgery for permanent correction.

ECTROPION

- Critical Sign
  - Outward turning of the eyelid margin
- Other signs
  - SPK(may result from exposure keratopathy), conjunctival injection & eventually , keratinization(from conjunctival drying)
- Symptom
  - Tearing, eye or eyelid irritation ; may asymptomatic
- Etiology
  - Congenital
  - Paralytic(7th nerve palsy)
  - Involutional(aging)
  - Cicatricial(due to chemical burn, surgery,trauma scar, others)
  - Mechanical (Due to herniated orbital fat, eyelid tumor)

Cont,



Unilateral ectropion due to traumatic scarring



Bilateral ectropion due to severe dermatitis

- Treat exposure keratopathy with lubricating agents
- Treat an inflammed , exposed eyelid margin with warm compresses and antibiotic ointment
- Definitive treatment usually requires surgery

Trichiasis

- Sign
  - Posterior misdirection of normal lashes rubbing against the globe
- Symptoms
  - Ocular iritattion, foreign-body sensation, tearing, red eye
- Causes:
  - Idiopathic
  - Secondary: - chronic anterior blepharitis
    - herpes zoster ophthalmicus
    - trachoma
- Treatment

1. Remove the misdirected lashes

   A. If few misdirected lashes: Remove them at slit lamp with fine forceps(recurrence is common)

   B. Diffuse, severe, or recurrent trichiasis: definitive Rx generally requires electrolysis, cryotherapy, or surgery

2. Treat SPK with antibiotic ointment

PTOSIS & PSEUDOPTOSIS

- Defn.:
  - Ptosis is the drooping of the upper eyelid due to innervation or myopthy of levator muscle or aponeurosis
- Evaluation
  - Pseudoptosis
  - True ptosis





Physical exam

4 clinical measurements

- Vertical interpalpebral fissure height
- Marginal- reflex distance
- Upper eyelid crease position
- Levator function(upper eyelid excursion

- Treatment
  - Surgical correction

Diseases of the lacrimal apparatus

- Infections of the Lacrimal apparatus
- Obstructions
- Dry eye syndrome

1. Canaliculitis
2. Acute Dacryocystitis
3. Chronic Dacryocystitis

Canaliculitis

- Symptoms
  - Tearing or discharge, red eye, mild tenderness over the nasal aspect of the lower or upper eyelid.
- Signs
  - Erythmatous pouting punctum, erythema of skin surrounding the punctum.
  - Mucopurulent discharge or concretions may be expressed from the punctum when pressure is applied over the nasal corner of lower eyelid(lacrimal sac).
  - Recurrent conjunctivitis confined to nasal aspect of the eye, gritty sensation on probing

Etiology

- Actinomyces israeli(most common cause; gram positive rod)
- Fungal(e.g. candida, fusarium, Aspergillus)
- Viral(e.g HSV & VZV)
- Other bacteria(e.g Nocardia)

Cont,

- Work-up
  - Apply gentle pressure over lacrimal sac with cotton-tipped swab & rolled it toward the punctum; observe for a punctal discharge
  - Smears and cultures of the material expressed
- Treatment
  1. Remove obstructing concretions, surgical canaliculotomy
  2. After removing irrigate with penicilin G soln. or 1% iodine solution
  3. Warm compresses to the punctal area qid.

Acute dacryocystitis

- **Pathogenesis**
  - Acute staphylococcal infection of the lacrimal sac secondary to nasolacrimal duct obstruction(NLDO)
- Symptoms
  - Pain, redness, and swelling over the innermost aspect of the lower eyelid(over lacrimal sac); tearing; discharge; fever; may be recurrent.
- **Signs**
  - Tender, red, tense swelling at the medial canthus which may be associated with preseptal cellulitis(extending around periorbital area nasally)

- Usually secondary to nasolacrimal duct obstruction



- Tender canthal swelling
- Mild preseptal



May develop into abscess

Chronic dacryocystitis

- Pathogenesis
  - Chronic staphylococcal infection of lacrimal sac secondary to NLDO
- Signs
  - Painless swelling at the inner canthus(mucocele) with reflux of mucopurulent material on pressure over the sac

- Infectious and inflammatory orbital diseases
  - Infections: preseptal cellulitis, orbital cellulitis
  - Inflammations: Graves ophthalmopathy, pseudotumor of orbit

- Space occupying orbital lesions

- Definition
  - Infection & inflammation confined to eyelids or periorbital structures anterior to orbital septum.
- Etiology & Pathogenesis
  - staph. aureus or strept. Pyogenes most common but H. influenzae in children < 5 years.
  - **Etiology**: puncture wound, laceration, retained foreign body from trauma, vascular extension, or extension from sinuses or another infectious site(e.g hordeolum, dacryocystitis , or chalazion)
    - In adults usually caused by penetrating trauma or cutaneous source of infection
    - In children the most common cause is underlying sinusitis

Preseptal cellulitis

- Symptoms:-Tenderness and redness of the eyelid, mild fever, irritability
- Critical signs
  - Eyelid erythema, edema, warmth, tenderness
  - No proptosis, no restriction of extraocular motility, no pain with eye movement, usually the globe is not involved (unlike orbital cellulitis). The patient may not be able to open the eye be



Treatment

1. Systemic Antibiotic therapy
2. Worm compresses to the inflamed area tid prn
3. Antibiotic ointment to eye if secondary conjunctivitis is present
4. Exploration and debridement of lesion if a flucuant mass or abscess is present

Orbital cellulitis

- Symptoms
  - Red eye, pain, blurred vision, fever, headache, double vision
- Critical signs
  - Eyelid edema, erythema, warmth, tenderness, conjunctival chemosis , and injection, **proptosis and restricted ocular motility with pain** on attempted eye movement are usually present.



Pre-treatment



1. Hospital admission
2. Systemic antibiotic therapy
3. Monitoring of optic nerve function
4. **Indications for surgery**
   - Resistance to antibiotics
   - Orbital or subperiosteal abscess
   - Optic neuropathy

Diseases Of The Conjunctiva

- Differential diagnosis of red eye
- Conjunctivitis
- Trachoma
- Degenerations(Pterygium, pingucula)
- Tumors of conjunctiva

THE RED EYE

The differential diagnoses: protean Sleeplessness and fatigue to life

threatening conditions as cavernous sinus thrombosis and carotid cavernous

fistula.

- **Clinically simple and conventional way of categorizing causes of red eye**

1. Painless red eye

conjunctivitis

Pterygium and others

2. Painful red eye

Keratitis and corneal ulcer

Iridocyclitis

Acute angle closure glaucoma

Episcleritis and Scleritis

Conjunctivitis

Definition: a general term for any infection or inflammation of conjunctiva

- **Classification**
  - usually is based on cause, including **viral, bacterial, fungal, parasitic, toxic, chlamydial, chemical, and allergic agents.**
  - It also can be based on age of occurrence or course of disease.
  - Etiology often can be distinguished on clinical grounds.
- **Epidemiology**
  - Conjunctivitis is extremely common
  - The prevalence of each is different in pediatric and adult population. The vast majority of pediatric cases are bacteria, while in adult's bacterial and viral causes are equally common
  - Conjunctivitis occurs in all ages.

Symptoms:

- Eye discomfort in the eye (conjunctivitis does not cause any real pain)
- Vision should be normal except slight blurring in viral conjunctivitis (b/c of corneal involvement)

- **Signs** vary much according to type
  - Vasodilatation of superficial vesels(red)
  - Increased secretion the character of secretions helps to diagnose the cause
    - Purulent or mucopurulent acute bacterial infection
    - Watery(serous) typical of viral infection
    - Thick sticky mucus allergic conjunctivitis
  - Edema of conjunctiva (chemosis)
  - **Follicles** (enlarged nodules of lymphoid tissue)
  - **Papillae** (central core of hypermic blood vessels surrounded by edema & inflammatory cells)
  - Membrane formation
  - Scarring

- **Scare**

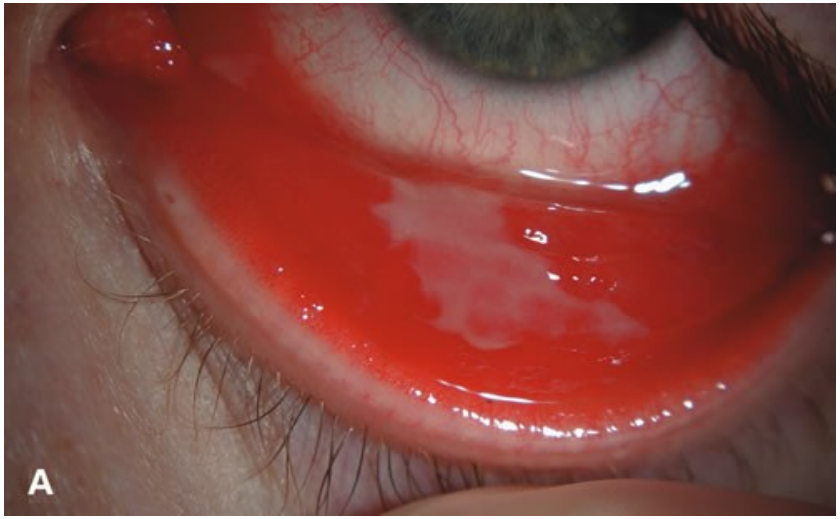

papilae

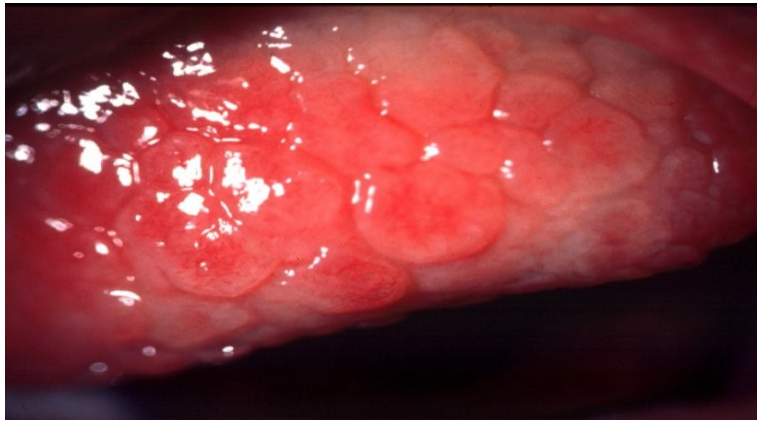

Follicle

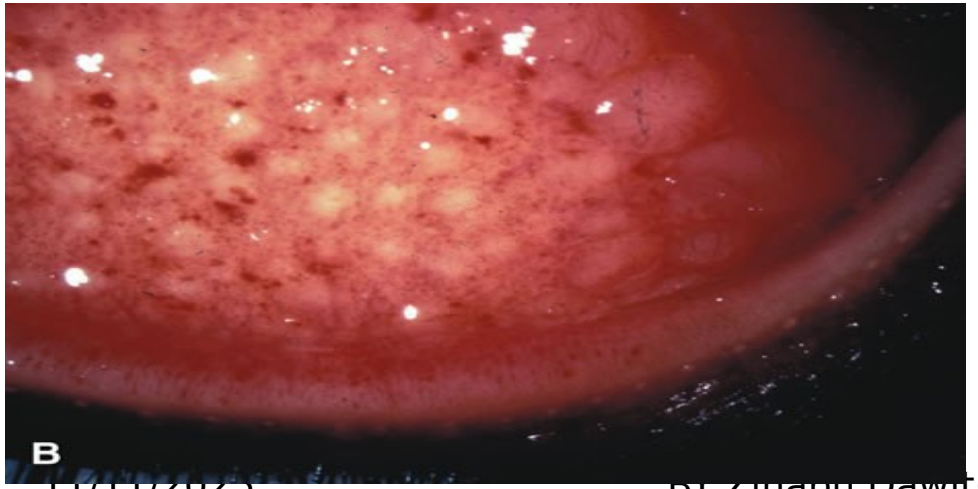

Bacterial conjunctivitis

- Commonly caused by staphylococcus aureus, streptococcus pneumonia, hemophilic influenza, and moraxella catarrhalis
- S. Aureus is common in adults
- Highly contagious from secretions or with contaminated objects and surfaces
- Bacterial conjunctivitis occurs in otherwise healthy individuals.
- Risk factors include frequent exposure to infected individuals, sinusitis, immunodeficiency states, and exposure to agents of sexually transmitted disease at birth

Symptoms:

- Patients typically complain of redness and discharge in one eye; although it can also be bilateral.
- The affected eye often is “stuck shut” in the morning
- Purulent discharge continues throughout the day.
- The discharge is thick; it may be yellow, white or green.
- No real pain as the conjunctiva has few sensory nerve supplies but complain of irritation, itching and discomfort
- Vision is almost always normal.

Signs:

- Purulent discharge at the lid margins and in the corners of the eye. More purulent discharge appears within minutes of wiping the lids
  - Red eye – due to dilatation of superficial blood vessels as apart of inflammation
  - Edema of the conjunctiva (chemosis) and eyelids swelling
  - Cornea is mostly clear; but if it is involved, there will be different degree of corneal opacity it is common specially in untreated and delayed patiens

Diagnosis:

- Mostly clinical
  - Gram stains may be sometimes used.
- **Course :** It lasts for 1 - 2 weeks and then it usually resolves spontaneously.
- ***Treatment***
  - Chloramphenicol eye drop or ointment QID
  - Ciprofloxacillin eye drop QID
  - If the above drugs are not available, one can use tetracycline eye ointment BID
  - Clean any discharge or dried secretions
  - Normally resolves after 3 or 4 days of treatment
  - Evaluate the patient after 48 hrs and if no improvement, refer to ophthalmic center for better evaluation
  - **N.B. *Don't use steroid or steroid containing antibiotic as they will reduce local immunity and encourage micro organism to multiply***

Viral conjunctivitis

- Viruses are a common cause of conjunctivitis in patients of all ages.
  - adenovirus is by far the most common cause, and herpes simplex virus(HSV) is the most problematic.
  - Less common causes include varicella-zoster virus(VZV), picornavirus, poxvirus(molluscum contagiosum, vaccinia), and human immunodeficiency virus(HIV).
- It is highly contagious, spread by direct contact with the patient and his or her secretions or with contaminated objects & surface
- Patient usually presents with watering, photophobia, irritation and mostly associated with upper respiratory tract infection

Treatment

- Usually self limiting
- Treatment of adenoviral conjunctivitis is supportive. Patients should be instructed to use cold compresses and lubricants, such as artificial tears, for comfort.
- Prophylaxis antibiotic eye drops may be given as necessary to prevent bacterial superinfection.
- Never use steroid or steroid containing antibiotics.

Allergic conjunctivitis

- is caused by air borne allergen contacting the eye.
- **Symptoms**
  - Red eye
  - severe and persistent ***itching of both eyes***
  - Mucoid eye discharge
  - No visual reduction
- **Signs:**
  - Visual acuity is normal
  - papillary reaction to hypertrophy on tarsal conjunctiva

Cont,



Allergic conjunctivitis

- **Treatment**
  - Allergic conjunctivitis can be treated with a variety of drugs, which include topical antihistamines, mast cell stabilizers, NSAIDs, and corticosteroids.
    - Vasoconstrictor-antihistamine like cromolyn sodium
    - Topical steroid –Terracortril eye suspension
  - Maintenance of an air-conditioned environment and control of dust particles at home and work also may be helpful. Local measures, such as cold compresses and periodic installation of artificial tears, may provide temporary relief.

TRACHOMA

- **Definition**: Trachoma is a chronic keratoconjunctivitis caused by the obligate intracellular bacterium *Chlamydia trachomatis*
- The second most common cause of blindness in developing countries.(6 million people are blind)
- Trachoma is the leading infectious cause of blindness in the world.

Cont,

- **Pathophysiology:**
  - Infection causes inflammation, that is, a predominantly lymphocytic and monocytic infiltrate with plasma cells and macrophages in follicles. The clinical and pathological hallmark of active trachoma is the conjunctival lymphoid follicle.

  - Repeated episodes of reinfection within the family cause chronic follicular or intense conjunctival inflammation (**active trachoma**), which leads to tarsal conjunctival scarring. The scarring distorts the upper tarsal plate and, in some individuals, leads to entropion and trichiasis (**cicatricial trachoma**). The end result includes corneal abrasions; corneal scarring and opacification; and, ultimately, blindness.

Epidemiology

- Trachoma is endemic in parts of Africa, Asia, the Middle East, Latin America, the Pacific Islands, and aboriginal communities in Australia.Worldwide, an estimated 84 million people in 55 endemic countries have active trachoma. In hyperendemic areas, most members of nearly all families may have active disease.
- WHO estimates about 15% of world blindness is caused by trachoma
- It is the leading cause of preventable blindness
  - 150 million infected with ocular chlamydia
  - 10 million have TT
  - 6 million are blind

Cont,

- The main carriers of infection are children below the age of 10, & especially preschool children
- The disease spreads from child to child by direct contact on fingers & on clothes ,handkerchiefs & pillows(fomite)
- Disease transmission occurs primarily between children and the women who care for them.
- Overcrowding ,poor hygiene & large no.of flies all help disease to spread

- **History**
  - Two phases of the disease process exist: the active phase and the scarring (cicatricial) phase
  - The active phase
    - follicular conjunctivitis is a feature.
    - Most patients with active trachoma are relatively asymptomatic.
  - The cicatricial phase has unique clinical features, which lead to definitive diagnosis in most cases.
    - Conjunctival scarring alone -asymptomatic
    - associated disturbance of the architecture of the tear film dry eye.
    - Trichiasis foreign body sensation, as well as blepharospasm. Ultimately, it leads to corneal scarring.
    - Many patients self-epilate before their presentation.
    - Corneal opacities or scars- impair the patient's vision.

- Eyelids: Trichiasis, entropion
- Conjunctiva: follicles over upper tarsal conjunctiva, tarsal conjunctval scarring(Arlt’s line)
- Cornea: limbal follicles(Herbert’s pit), superior neovascularization (pannus), and punctate keratitis, corneal opacity

Cont,

Follicles,scar
ing

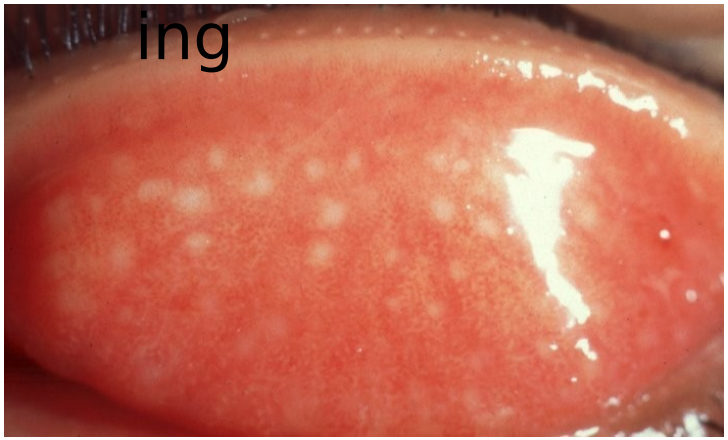



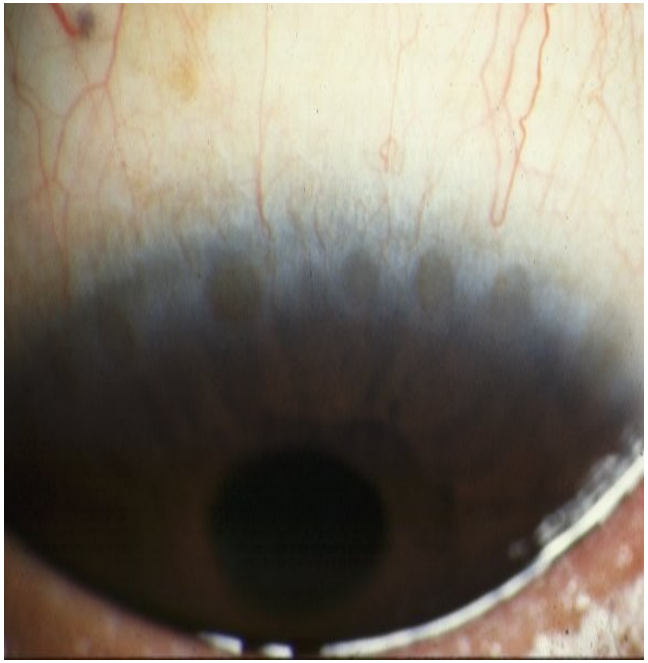

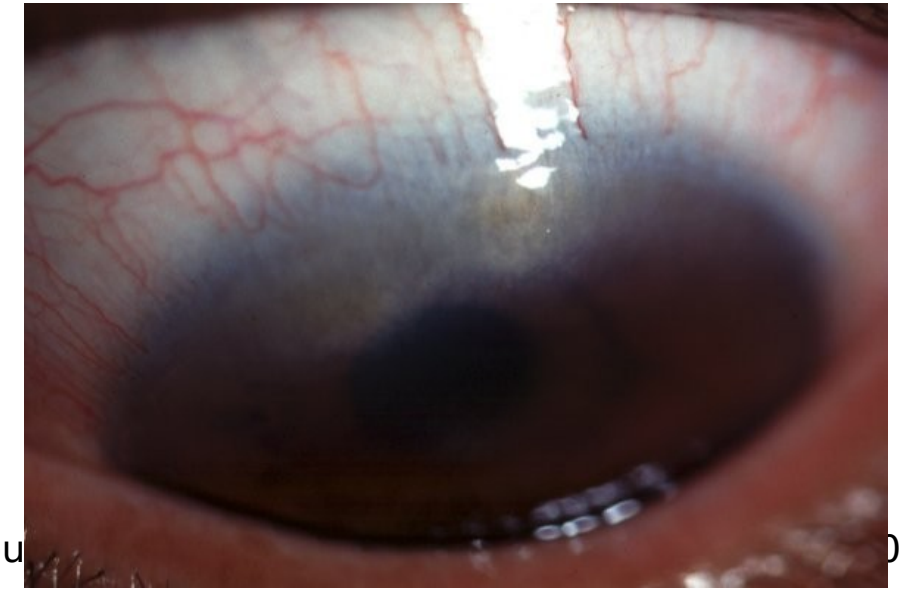

- Clinical Dx of trachoma requires at least 2 of the following:

1. Conjunctival follicles on the upper tarsal conjunctiva
2. Typical tarsal conjunctval scarring(Arlt’s line)
3. Limbal follicles & their sequelae (Herbert’s pit)
4. Vascular pannus most marked on the superior limbus

WHO simplified trachoma grading scheme

- TF : > 5 follicles ,each >0.5mm,in the upper tarsal conjunctiva
- TI :pronounced inflammatory thickening of upper tarsal conjunctiva that obsures more than half of normal deep vessels
- TS : presence of scarring in the upper tarsal conjunctiva
- TT : at least one eyelash touching the cornea or history of previous epilation
- CO : easily visible corneal opacity over the pupil

Normal conjunctiva

- It is pink, smooth, thin, and transparent.
- Over the whole area of the tarsal conjunctiva, there are normally large deep-lying blood vessels that run vertically. The dotted line shows the area to be examined

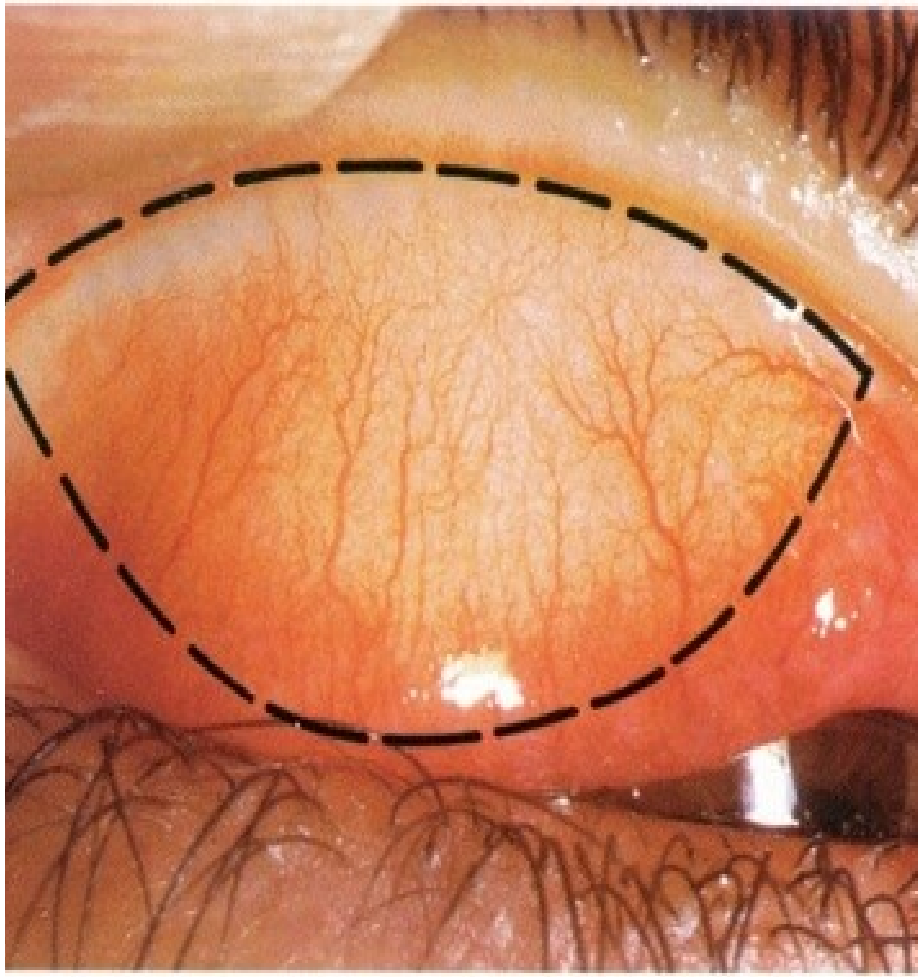

TF

- Trachomatous
- inflammation –follicular



TI

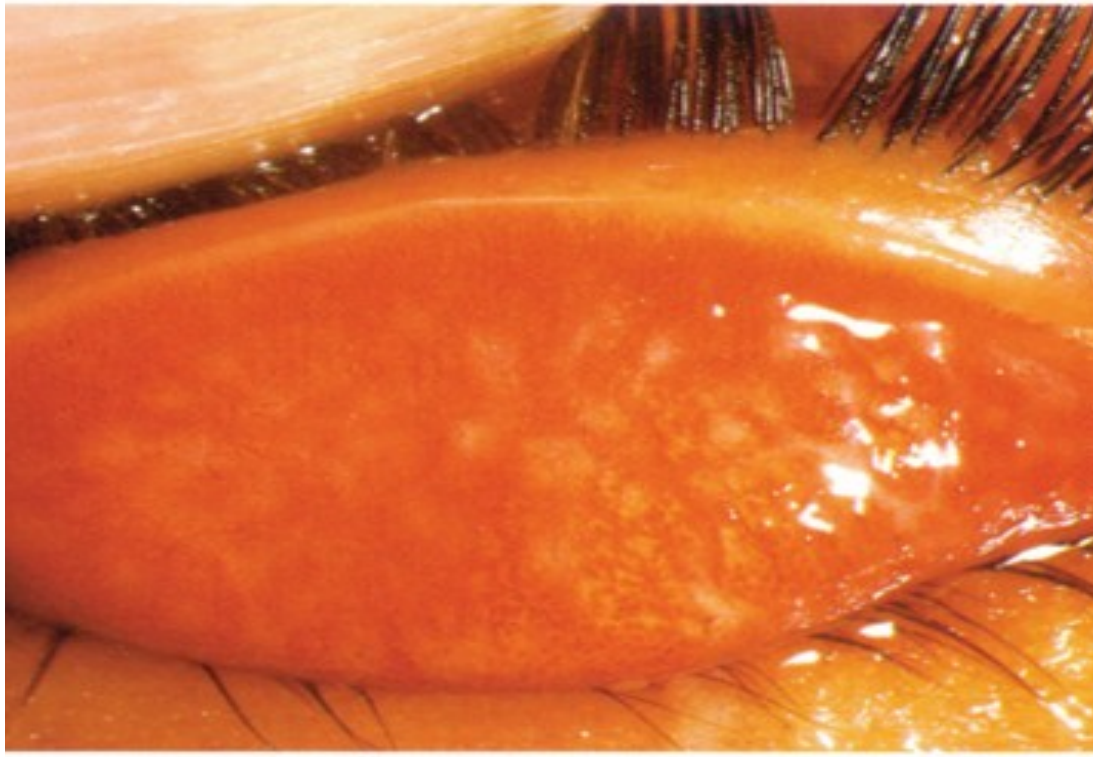

TS

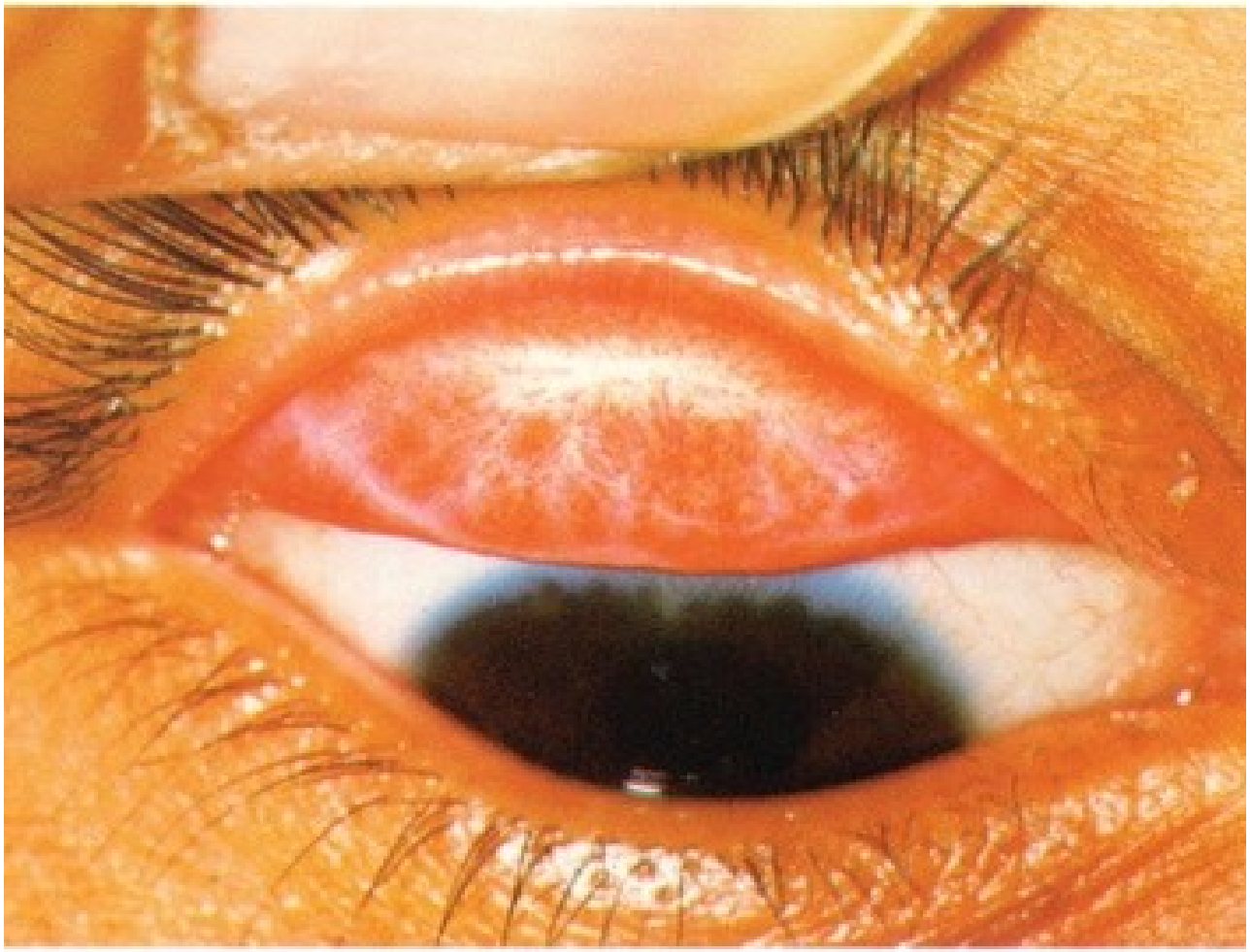

TT

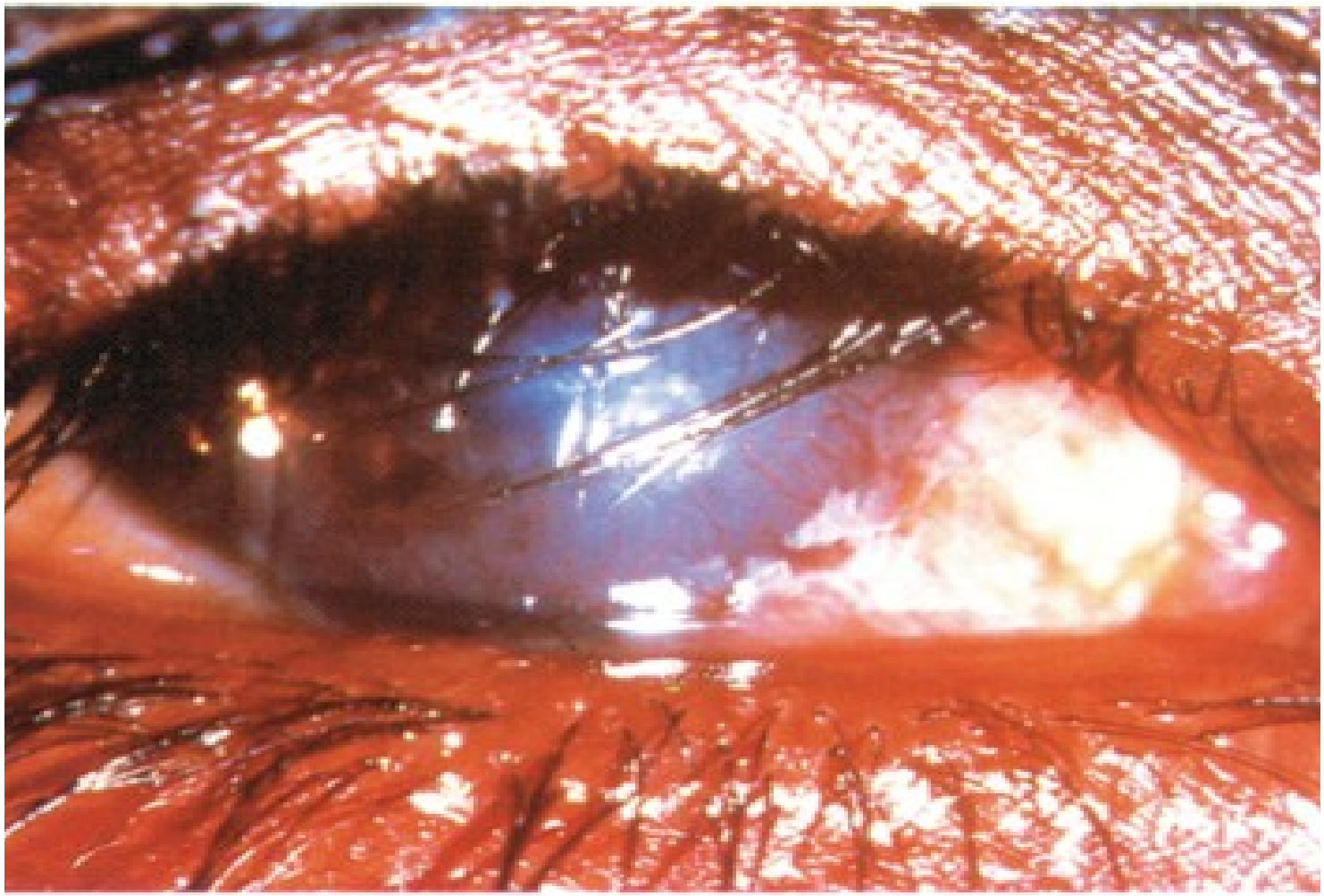

CO



Significance of Trachoma Grading

- TF: Presence of trachomatous inflammation, indicating current infection.
  - Rx: topical 1% tetracycline(TTC) eye ointment BID for 6 weeks.
- TI: indicating severe current infection with increased risk of scarring.
  - Rx: topical 1% TTC ointment + systemic antibiotic treatment(Doxycycline 100 mg po daily for 21 days.)
- TS: Presence of scarring, showing that the patient has, or had had, trachoma. Rx: None
- TT: Presence of trichiasis, indicating patients who will develop corneal opacity and visual loss; this is therefore a potentially disabling lesion, which may rapidly lead to blindness.
  - Rx: corrective lid surgery(Tarsotomy)
- CO: Presence of corneal opacity indicating people who have a visual impairment or blindness. This is a disabling lesion.
  - Rx: corneal transplant, but poor prognosis.

Key measures for assessing the importance of trachoma in a community:

- The proportion of trachomatous inflammation(TF, with or without TI) amongst children < 10 years old
  - This demonstrates how **widespread** the infection is in the community
- The proportion of intense inflammation(TI) in children <10 years old
  - This demonstrates how **severe** the disease is in the community.
- The proportion of conjunctival scarring(TS)
  - This demonstrates how common trachoma was in **the past**.
- The number of people with TT
  - This indicates the immediate need to provide **surgical services** for lid correction.
- The proportion of people with CO
  - This demonstrates the impact of trachoma in the community in terms of **visual loss**.

In Ethiopia:

- According to the 2006 national survey
  - The national prevalence of active trachoma (either TF or TI) for children in the age group 1-9 year is 40.14%.
  - The national prevalence of trachomatous trichiasis (TT) is 3.1%.
  - Over 9 million 1-9 year old children live with active trachoma, and 1.3 million people 15 years and older have trachomatous trichiasis.

Treatment

- The key to the treatment of trachoma is the **SAFE strategy** developed by the WHO.
  - The SAFE strategy
    - S – Surgery for trichiasis
    - A – Antibiotics for active trachoma
    - F – Facial cleanliness
    - E – Environmental hygiene improvement

The SAFE strategy

- Surgery for TT
  - Eyelid surgery to correct entropion and/or trichiasis may prevent blindness in individuals at immediate risk
  - Eyelid rotation limits the progression of corneal scarring
- Trichiasis surgery (bilamellar tarsal rotation or the related Trabut procedure) should be considered if any of the following are present:
  - one or more in-turned eyelashes are abrading the cornea when the patient is looking straight ahead
  - pre-existing evidence of corneal damage from trichiasis
  - severe discomfort from trichiasis
- Epilation is considered an alternative for refusal to have surgery

The SAFE strategy

- Antibiotic for active trachoma(TF or/&TI):
  - Management of trachoma should be community based.
  - If prevalence of TF in children aged 1-9 yr in the community is 10% or more Rx: mass treatment
  - If prevalence of TF in the community is 5% or more but less than 10% Rx: Targeted treatment
  - If TF is < 5% Rx: antibiotic distribution may not be necessary, though targeted treatment can be considered.

Cont,

- The following antibiotic treatment is recommended by the WHO:
  - Single dose azithromycin: in children aged <16 years dosage is 20mg/kg (maximum dose 1g); in adults dosage is 1g.
  - Or, use topical 1% tetracycline eye ointment in pregnant women, children aged below 6 months and those allergic to macrolides, used twice daily in both eyes for 6 weeks.

The SAFE strategy

- Facial cleanliness: promote regular face-washing with clean water
  - Epidemiologic studies and community-randomized trials have shown that facial cleanliness in children reduces both the risk and the severity of active trachoma.
  - To be successful, health education and promotion activities must be community based and require considerable effort

The SAFE strategy

- Environmental improvement: (improving water supply, latrine provision and fly control)
  - promotion of improved water supplies and improved household sanitation, particularly methods for safe disposal of human feces.
  - The face fly *Musca sorbens* has been implicated as a possible vector for trachoma and breeds preferentially on human feces. These flies cannot breed in latrines, so latrine construction is thought to reduce fly populations and trachoma transmission.
  - General improvements in personal and community hygiene are almost universally associated with a reduction in the prevalence of trachoma.

Degenerations of conjunctiva

- Pingucula
- pterygium

Pingucula

- A pinguecula (Latin, *pingueculus* meaning fatty) is a yellowish, raised growth located on the bulbar conjunctiva in the palpebral fissure.
- It is commonly thought to be the precursor of a pterygium .
- Their location in the interpalpebral zone and their occurrence in older individuals living in warmer areas with high levels of sunlight suggest that pinguecula

Pinguecula

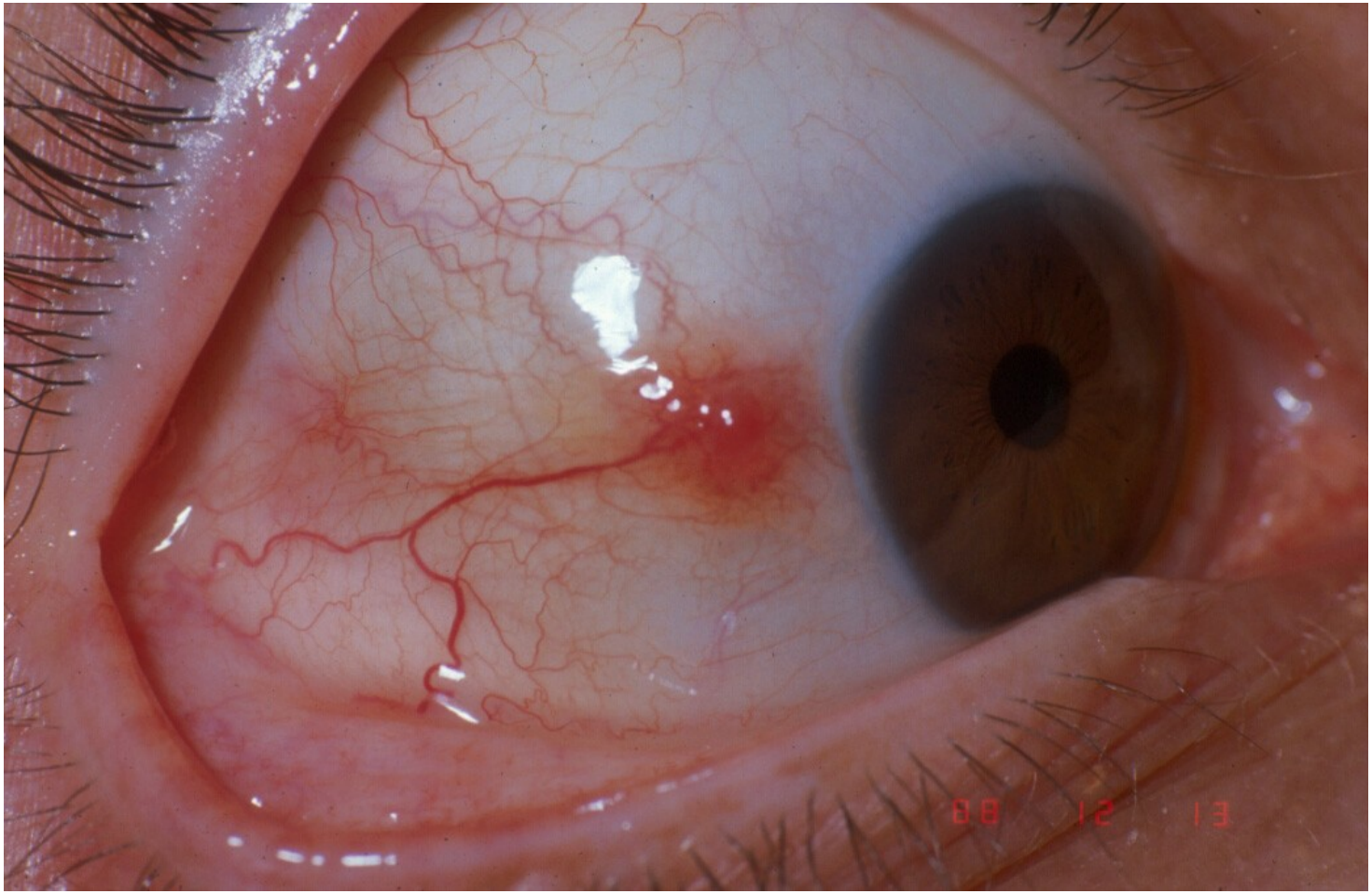

Pterygium

- Fleshy growth of the conjunctiva that encroaches the cornea and cover cornea (Pterygium means wing)
- It usually starts nasally, but occasionally temporally in

  the 3 o'clock or 9 o'clock.
- More common in dry, hot and dusty environment
- The main risk factor for the development of pterygium is exposure to UV light. Chronic environmental exposure to wind and dust might also play a role.
- Patient complains slight cosmetic blemish, irritation of

  the eye
- If it grows into the pupil, it will cause blurring of vision to blindness

Cont,







Pterygium extending along

Treatment

- protection from sun with eye glass or hat
- If irritated, topical steroid- Terracotril eye suspension BID
- Extensive crossing the limbus, it needs referral for surgical excision

Cataract

- Definition: Cataract is any opacity in the ocular lens
- It is the leading cause of blindness worldwide
- **Causes of cataract:**
  - Risk factors for development of cataract:
    - Age the most important cause of cataract
    - Solar radiation (UV radiation)
    - Diet deficient in vitamin c
  - Toxic drugs[Prolonged use of steroids(both systemic & topical), anticholinestrase, antipsychotic drugs, others]

Causes of cataract:

- Eye diseases associated with cataract:
  - Trauma of the eye
  - Uveitis
  - Glaucoma
  - Myopia(short-sightedness)
- Sysemic diseases that increase the risk:
  - Diabetes mellitus
  - Chronic renal failure
  - Hypothyroidism
  - Down’s syndrome
  - Others

Symptoms:

- The particular symptoms are based on the location and density of the opacity.
  - Slowly progressive visual loss or blurring, usually over months to years, affecting one or both eyes.
  - Glare, particularly from oncoming headlights while driving at night, and reduced color perception may occur.
  - Refractive changes increasing myopia
  - Dazzling(deterioration vision in bright light, improvement in dim light)
- **Sign:** opacification of the normally clear lens.

- **Treatment**

  Surgical removal of cataract and replacement with intraocular lens(IOL) to correct the



DISEASES OF UVEAL TRACT

- Uveitis: is broadly defined as inflammation(i.e, -itis) of the uvea(from Latin uva, meaning “grape”)

uveitis

Classification:

1. Anterior uveitis inflammation to anterior uvea, the iris & ciliary body
   - Iritis
   - Anterior cyclitis
   - Iridocyclitis
2. Intermediate uveitis inflamation confined to peripheral choroid and ciliary body
   - Posterior cyclitis
   - Hyalitis
   - Basal retinochoroiditis
3. Posterior uveitis inflamation of choroid & retina(choroiditis, chorioretinitis)
4. Panuveitis (diffuse uveitis) when the whole uvea is involved

Causes of uveitis:

- The causes can be infectious, traumatic, neoplastic or autoimmune.
  - Infective : - bacteria, viral, fungi, protozoa, parasites
  - Non-infective : e.g., sarcoid
- By far, most types of anterior uveitis are sterile inflammatory reactions, where as many of the posterior uveitis syndromes are infectious in origin.

Cont,

- **Symptoms**:
  - ***Acute***: pain, red eye, photophobia, mild decreased vision, tearing.
  - ***Chronic***: Recurrent episodes, fewer or none of the acute symptoms.
- **Signs:**
  - Injection of the perilimbal blood vessels(circumcorneal injection)
  - Keratic precipitates(collections of inflammatory cells on the corneal endothelium)
  - Cells and flares in anterior chamber(A/C)
  - Hypopyon(layers of white cells in the A/C)
  - Papillary miosis, iris nodules
  - Synechiae, both anterior and posterior.
  - Low IOP, but occasionally elevated.
  - Occasionally cataract.

Cont,

- Initial laboratory work-up(CBC, ESR, VDRL, Chest x-ray)
- **Treatment:**
  - The basic treatment for all types of uveitis is corticosteroid(topical/systemic)
  - Cycloplegics(pupil dilating drugs e.g atropine 1% drop) for iridocylitis
  - Antiglaucoma drugs if increased IOP
  - If infective cause identified, treat accordingly.

Referal to ophthalmic center for further evaluation and mgt!

Impaired Vision

REFRACTIVE ERRORS

- In refractive errors, vision is impaired because a shortened or elongated eyeball prevents light rays from focusing sharply on the retina.
- The depth of the eyeball is important in determining refractive error.
- Refractive errors include:
  - Myopia (Short sightedness)
  - Hyperopia or hypermetropia (Long sightedness)
  - Astigmatism (asymmetric focus)

Myopia (Short sightedness)

- People who have **myopia** are said to be nearsighted.
- They have deeper eyeballs; the distant visual image focuses in front of, or short of, the retina.
- Myopic people experience blurred distance vision.

Hyperopia or hypermetropia (Long sightedness)

- People with hyperopia are farsighted.
- These patients experience near vision blurriness, whereas their distance vision is excellent.

Astigmatism (asymmetric focus)

- An irregularity in the curve of the cornea.
- Because astigmatism causes distortion of the visual image, acuity of distance and near vision can be decreased.

Refractive correction:

- Refractive errors may be corrected with
  - Eye glasses (Spectacles)
    - For myopia: - Concave lens (Spherical) or ‘Minus’ lens.
    - For hyperopia: - Convex lens or ‘Plus’ lens.
  - Hard contact lens
  - Soft contact lens
  - Intraocular lenses

LOW VISION AND BLINDNESS

- Low vision is a general term describing visual impairment that requires patients to use devices and strategies in addition to corrective lenses to perform visual tasks.
- The clinical definition of absolute blindness is the absence of light perception.
- The most common causes of blindness and visual impairment among adults 40 years of age or older are diabetic retinopathy, macular degeneration, glaucoma, and cataracts.

Medical Management

- Managing low vision involves magnification and image enhancement through the use of low-vision aids.
- Low-vision aids include optical and non optical devices.
- The optical devices include convex lens aids, such as magnifiers and spectacles; telescopic devices; anti-reflective lenses that diminish glare; and electronic reading systems, such as closed-circuit television and computers with large print.
- Nonoptical aids include large-print publications and a variety of writing aids.

GLAUCOMA

- Glaucoma is a group of ocular conditions characterized by optic nerve damage.
- The optic nerve damage is related to the IOP caused by congestion of aqueous humor in the eye.
- Glaucoma is more prevalent among people older than 40 years of age, and the incidence increases with age.

Pathophysiology

- There are two accepted theories regarding how increased IOP damages the optic nerve in glaucoma.
  - The **direct mechanical** theory suggests that high IOP damages the retinal layer as it passes through the optic nerve head.
  - The **indirect ischemic** theory suggests that high IOP compresses the microcirculation in the optic nerve head, resulting in cell injury and death.

Stages of glaucoma:

1. Initiating events:

- precipitating factors include illness, emotional stress, congenital narrow angles, long-term use of corticosteroids, and mydriatics (ie, medications causing pupillary dilation).
- These events lead to the second stage.

2. Structural alterations in the aqueous outflow system:

- Tissue and cellular changes caused by factors that affect aqueous humor dynamics lead to structural alterations and to the third stage.

3. Functional alterations:

- Conditions such as increased IOP or impaired blood flow create functional changes that lead to the fourth stage.

4. Optic nerve damage:

- atrophy of the optic nerve is characterized by loss of nerve fibers and blood supply, and this fourth stage inevitably progresses to the fifth stage.

5. Visual loss:

- progressive loss of vision is characterized by visual field defects.

Classification of Glaucoma

- There are several types of glaucoma.
- Glaucoma can be primary or secondary, depending on whether associated factors contribute to the rise in IOP.
- The two common clinical forms of glaucoma encountered in adults are open-angle and angle-closure glaucoma.

1. Open-Angle Glaucomas

- Usually bilateral, but one eye may be more severely affected than the other.
- There are three types of open-angle glaucoma.
- In all **three types of open-angle glaucoma**, the anterior chamber angle is open and appears normal.

1. Chronic open-angle glaucoma (COAG)
2. Normal tension glaucoma

2. Angle-Closure (Pupillary Block) Glaucomas

- Obstruction in aqueous humor outflow due to the complete or partial closure of the angle from the forward shift of the peripheral iris to the trabecula.
- The obstruction results in an increased IOP.
- There are three types of angel-closed glaucoma.

1. Acute angle-closure glaucoma

Medical Management

- Several types of ocular medications are used to treat glaucoma, including:
  - **Cholinergics (miotics) (pilocarpine, carbachol)**
    - Increases aqueous fluid outflow by contracting the ciliary muscle and causing miosis (constriction of the pupil) and opening of trabecular meshwork

- **Adrenergic agonists (dipivefrin, epinephrine**)
  - Reduces production of aqueous humor and increases outflow.
- **Beta-blockers (betaxolol, timolol)**
  - Decreases aqueous humor production
- **Alpha-adrenergic agonists (apraclonidine, brimonidine)**
  - Decreases aqueous humor production
- **Carbonic anhydrase Inhibitors (acetazolamide, methazolamide, dorzolamide)**
  - Decreases aqueous humor production
- **Prostaglandin analogs (latanoprost)**
  - Increases uveoscleral outflow

SURGICAL MANAGEMENT

- Laser trabeculoplasty:
- Laser iridotomy:
- Filtering procedures:
- Trabeculectomy
- Drainage implants or shunts

Hearing and Balance Disorders

BY
Zinabu Dawit(PBsc)

LEARNING OBJECTIVES

On completion of this chapter, the learner will be able to:-

- ✓ Describe methods used to assess hearing and diagnose hearing and balance disorders.
- ✓ List the manifestations that may be exhibited by a person with a hearing disorder.
- ✓ Identify ways to communicate effectively with a hearing-impaired person.
- ✓ Differentiate problems of the external ear from those of the middle ear and inner ear.

Cont,...

- ✓ Compare the various types of surgical procedures used for managing middle ear disorders, including appropriate nursing care.
- ✓ Describe the teaching topics that need to be addressed for patients undergoing middle ear and mastoid surgery.
- ✓ Describe the different types of inner ear disorders, including the clinical manifestations, diagnosis, and management.

Anatomic and Physiologic Overview

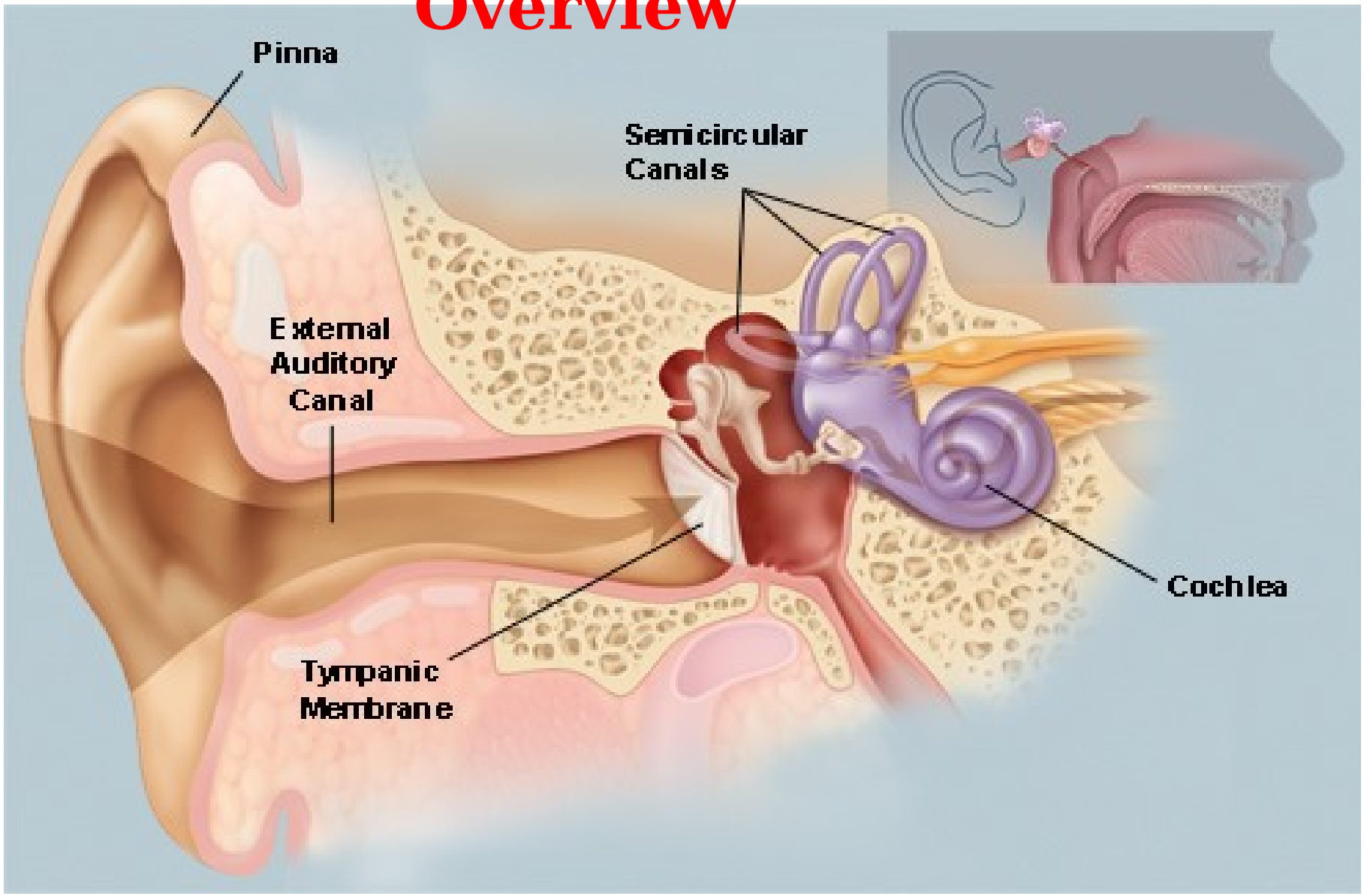

ANATOMY OF THE EXTERNAL EAR

- The external ear, housed in the temporal bone, includes the auricle (i.e., pinna) and the external auditory canal.
- The external ear is separated from the middle ear by a disklike structure called the tympanic membrane (ie, eardrum).

Auricle

- The auricle, attached to the side of the head by skin, is composed mainly of cartilage, except for the fat and subcutaneous tissue in the earlobe.
- The auricle collects the sound waves and directs vibrations into the external auditory canal.

External Auditory Canal

- The external auditory canal is approximately 2.5 cm long.
- The lateral third is an elastic cartilaginous and dense fibrous framework to which thin skin is attached.
- The medial two thirds is bone lined with thin skin.
- The external auditory canal ends at the tympanic membrane.
- The skin of the canal contains hair, sebaceous glands, and ceruminous glands, which secrete a brown, waxlike substance called cerumen (ie, ear wax).

ANATOMY OF THE MIDDLE EAR

- The middle ear, an air-filled cavity, includes the tympanic membrane laterally and the otic capsule medially.
- The middle ear is connected by the Eustachian tube to the nasopharynx and is continuous with air-filled cells in the adjacent mastoid portion of the temporal bone.
- The eustachian tube connects the middle ear to the nasopharynx.

Tympanic Membrane (eardrum)

- Is normally pearly gray and translucent.
- The tympanic membrane consists of three layers of tissue: an outer layer, continuous with the skin of the ear canal; a fibrous middle layer; and an inner mucosal layer, continuous with the lining of the middle ear cavity.
- The tympanic membrane protects the middle ear and conducts sound vibrations from the external canal to the ossicles.

Ossicles

- The middle ear contains the three smallest bones (ie, ossicles) of the body: **malleus, incus, and stapes**.
- The ossicles, which are held in place by joints, muscles, and ligaments, assist in the transmission of sound.
- Two small fenestrae (ie, oval and round windows), located in the medial wall of the middle ear, separate the middle ear from the inner ear.

- The footplate of the stapes sits in the oval window, secured by a fibrous annulus, or ring-shaped structure.
- The footplate transmits sound to the inner ear.
- The round window, covered by a thin membrane, provides an exit for sound vibrations.

ANATOMY OF THE INNER EAR

- The inner ear is housed deep within the temporal bone.
- The organs for hearing (ie, cochlea) and balance (ie, semicircular canals), as well as cranial nerves VII (ie, facial nerve) and VIII (ie, vestibulocochlear nerve), are all part of this complex anatomy

Membranous Labyrinth

- The membranous labyrinth is composed of the utricle, the saccule, the cochlear duct, the semicircular canals, and the organ of Corti.

Semicircular canals

- The membranous labyrinth contains a fluid called endolymph.
- The three semicircular **canals—posterior, superior, and lateral,** which lie at 90-degree angles to one another—contain sensory receptor organs, arranged to detect rotational movement.
- These receptor end organs are stimulated by changes in the rate or direction of an

- **Utricle and saccule**
  - The utricle and saccule are involved with linear movements
- **Organ of Corti**
  - The organ of Corti is located in the cochlea, a snail-shaped, bony tube about 3.5 cm long with two and one-half spiral turns.
  - The organ of Corti, also called the end organ for hearing, transforms mechanical energy into neural activity and separates sounds into different frequencies.

FUNCTION OF THE EARS

- Hearing
- Balance and Equilibrium

Assessment

- Inspection of the external ear
- Otoscopic examination
- Evaluation of gross auditory acuity
  - Whisper test
  - Weber test
  - Rinne test

The Weber test assesses bone conduction of sound

The Weber test uses bone conduction to test lateralization of sound.



- ✓ Normal hearing Sound is heard equally in both ears.
- ✓ Conductive hearing loss is Sound heard best in affected ear (hearing loss)
- ✓ Sensorineural hearing loss is Sound heard best in normal hearing ear

The Rinne test assesses both air and bone conduction of sound.

- ✓ *In a normal hearing ear, air-conducted sound is louder than bone-conducted sound.*
- ✓ *Conductive hearing loss*
  Sound heard as long or longer in affected ear (hearing loss)
- ✓ *Sensorineural hearing loss*
  Air conduction is audible longer than bone conduction in affected ear.





Diagnostic Evaluation

- Audiometry
- Otoscopy
- Tympanogram
- Middle ear endoscopy,

Hearing Loss

- Hearing loss may be:
  - ✓ Conductive
  - ✓Sensorineura
  - ✓Mixed (conductive and Sensorineura)
  - ✓functional (or psychogenic).

- **Conductive hearing loss**
  - Usually results from an external ear disorder, such as impacted cerumen, or a middle ear disorder (otitis media or otosclerosis).
  - The efficient transmission of sound by air to the inner ear is interrupted.
- **Sensorineural hearing loss**
  - Involves damage to the cochlea or vestibulocochlear nerve(CN VIII).

- **Mixed hearing loss**
  - Has conductive loss and sensorineural loss, resulting from dysfunction of air and bone conduction.
- **Functional (psychogenic) hearing loss**
  - Is nonorganic and unrelated to detectable structural changes in the hearing mechanisms.
  - It is usually a manifestation of an emotional disturbance.

Clinical Manifestations

- Tinnitus
- Increasing inability to hear in group
- Changes in attitude, the ability to communicate, the awareness of surroundings, and even the ability to protect oneself.
- For various reasons, some people with hearing loss refuse to seek medical attention or wear a hearing aid.

Medical Management

- If a hearing loss is permanent or untreatable with medical or surgical intervention or if the patient elects not to have surgery, aural rehabilitation may be beneficial.
- The purpose of aural rehabilitation is to maximize the hearing-impaired person’s communication skills.

- Aural rehabilitation includes:
  - Auditory training,
  - Speech reading,
  - Speech training,
  - The use of hearing aids
  - Hearing guide dogs

CONDITIONS OF THE EXTERNAL EAR

Cerumen Impaction

- Cerumen normally accumulates in the external canal in various amounts and colors.
- Although wax does not usually need to be removed, impaction occasionally occurs.

C/M

- Dried cerumen in the outer ear
- Otalgia(pain in the ear)
- Sensation of fullness
- No hearing loss

Management

- Cerumen can be removed by irrigation, suction, or instrumentation.
- Instilling a few drops of warmed glycerin, mineral oil, or half strength hydrogen peroxide into the ear canal for 30 minutes can soften cerumen before its removal.
- Ceruminolytic agents, such as peroxide in glyceryl (Debrox), are available; however, these compounds may cause an allergic dermatitis reaction.

Foreign bodies

- Some objects are inserted intentionally into the ear.
- Insects may also introduced into the ear canal.

Management

- The three standard methods for removing foreign bodies are the same as those for removing cerumen: irrigation, suction, and instrumentation.

- Foreign vegetable bodies and insects tend to swell; thus, irrigation is contraindicated.
- Usually, an insect can be dislodged by instilling mineral oil, which will kill the insect and allow it to be removed.
- In difficult cases, the foreign body may have to be extracted in the operating

EXTERNAL OTITIS (OTITIS EXTERNA)

- Refers to an inflammation of the external auditory canal.

Cause

- Water in the ear canal (ie, swimmer’s ear)
- Trauma to the skin of the ear canal
- Systemic conditions, such as vitamin deficiency and endocrine disorders.
- Bacterial: Staphylococcus aureus and Pseudomonas species.
- Fungal

Clinical Manifestations

- Pain
- Discharge from the external auditory canal
- Discharge may be yellow or green and foul smelling.
- Aural tenderness,
- Fever and lymphadenopathy.
- Pruritus and hearing loss or a feeling of fullness.
- On otoscopic examination, the ear canal is erythematous and edematous.
- In fungal infections, the hair like black spores may even be visible

Medical Management

- Patients may require analgesics for the first 48 to 92 hours.
- Antibiotic otic preparations (administered by dropper at room temperature).
- Corticosteroid agents to soothe the inflamed tissues.
- For cellulitis or fever, systemic antibiotics may be prescribed.
- For fungal disorders, antifungal agents are prescribed.

MALIGNANT EXTERNAL OTITIS

- Is a progressive, debilitating, and occasionally fatal infection of the external auditory canal, the surrounding tissue, and the base of the skull.

Cause

- Pseudomonas aeruginosa is usually the infecting organism in patients with low resistance to infection (eg, patients with diabetes).

Management

- Control of the diabetes,
- Administration of antibiotics (usually combination of an antipseudomonal agent and an aminoglycoside intravenously)
- Aggressive local wound care (includes limited debridement).

Masses of the external ear

- **Exostoses** are small, hard, bony protrusions found in the lower posterior bony portion of the ear canal; they usually occur bilaterally.
- The skin covering the exostoses is normal.
- Many people think exostoses are caused by an exposure to cold water, as in scuba diving or surfing.
- The usual treatment, if any, is surgical excision.

Gapping earring puncture

- Gapping earring puncture results from wearing heavy pierced earrings for a long time or after an infection, or as a reaction from the earring or other impurities in the earring.
- This deformity can only be corrected surgically.

Middle Ear

Tympanic Membrane Perforation

- Perforation of the tympanic membrane is usually caused by infection or trauma.
- Sources of trauma include skull fracture, explosive injury, or a severe blow to the ear.
- Less frequently, perforation is caused by foreign objects
- During infection, the tympanic membrane can rupture if the pressure in the middle ear exceeds the atmospheric pressure in the external auditory canal.

Medical Management

- Although most tympanic membrane perforations heal spontaneously within weeks after rupture, some may take several months to heal.
- While healing, the ear must be protected from water.

Surgical management

- Tympanoplasty (ie, surgical repair of the tympanic membrane)

ACUTE OTITIS MEDIA

- Acute otitis media is an acute infection of the middle ear, usually lasting less than 6 weeks.

Cause

- Streptococcus pneumoniae, Haemophilus &influenzae,
- Bacteria enters the middle ear after eustachian tube dysfunction caused by obstruction related to upper respiratory infections, inflammation of surrounding structures (eg, sinusitis, adenoid hypertrophy), or llergic reactions (eg, allergic rhinitis).

Clinical Manifestations

- Usually unilateral in adults
- Otalgia
- The pain is relieved after spontaneous perforation or therapeutic incision of the tympanic membrane.
- Drainage from the ear
- Fever,and hearing loss.
- On otoscopic examination, the external auditory canal appears normal.
- No pain with movement of the auricle.
- The tympanic membrane is erythematous and often bulging.

Medical Management

- Antibiotic

Surgical management

- Myringotomy or tympanotomy

Serous otitis media

- Serous otitis media (ie, middle ear effusion) implies fluid, without evidence of active infection, in the middle ear.
- In theory, this fluid results from a negative pressure in the middle ear caused by eustachian tube obstruction.
- This condition is found primarily in children.

- Is frequently seen in patients after radiation therapy or barotrauma and in patients with eustachian tube dysfunction from a concurrent upper respiratory infection or allergy.
- Barotrauma results from sudden pressure changes in the middle ear caused by changes in barometric pressure, as in scuba diving or airplane descent.
- A carcinoma (eg, nasopharyngeal cancer) obstructing the eustachian tube should be ruled out in an adult with persistent unilateral serous otitis media.

Clinical Manifestations

- Hearing loss,
- Fullness in the ear or a sensation of congestion,
- Popping and crackling noises, which occur as the eustachian tube attempts to open.

Management

- Myringotomy can be performed, and a tube may be placed to keep the middle ear ventilated.
- Corticosteroids in small doses sometimes decrease the edema of the eustachian tube in cases of barotrauma.

CHRONIC OTITIS MEDIA

- Chronic otitis media is the result of repeated episodes of acute otitis media causing irreversible tissue pathology and persistent perforation of the tympanic membrane.
- Chronic infections of the middle ear damage the tympanic membrane, destroy the ossicles, and involve the

Clinical Manifestations

- Foul-smelling otorrhea
- Hearing loss
- Otoscopic evaluation of the tympanic membrane may show a perforation and cholesteatoma (ingrowth of the skin of the external layer of the eardrum into the middle ear).

Medical Management

- Careful suctioning of the ear under microscopic guidance.
- Instillation of antibiotic drops or application of antibiotic powder is used to treat a purulent discharge.

Surgical Management

- Tympanoplasty, mastoidectomy and ossiculoplasty (surgical reconstruction of the middle ear bones).

OTOSCLEROSIS

- Otosclerosis involves the stapes and is thought to result from the formation of new, abnormal spongy bone, especially around the oval window, with resulting fixation of the stapes.
- The efficient transmission of sound is prevented because the stapes cannot vibrate and carry the sound as conducted from the malleus and incus to the inner ear.
- More common in women and frequently hereditary,
- Otosclerosis may be worsened by pregnancy.

Clinical Manifestations

- Involve one or both ears.
- Conductive or mixed hearing loss
- Bone conduction is better than air conduction on Rinne testing.
- Otoscopic examination usually reveals a normal tympanic membrane.

SURGICAL MANAGEMENT

- A stapedectomy can be performed
- Amplification with a hearing aid also may help

Conditions of the Inner Ear

MOTION SICKNESS

- Motion sickness is a disturbance of equilibrium caused by constant motion.

Clinical Manifestations

- Sweating, pallor, nausea, and vomiting caused by vestibular overstimulation.
- These manifestations may persist for several hours after the stimulation stops.

Management

- Antihistamines such as dimenhydrinate (Dramamine) or meclizine hydrochloride (Bonine).
- Anticholinergic medications, such as scopolamine.

BENIGN PAROXYSMAL POSITIONAL VERTIGO

- Vertigo is defined as the misperception or illusion of motion of the person or the surroundings.
- BPPV is a brief period of incapacitating vertigo that occurs when the position of the patient’s head is changed with respect to gravity, typically by placing the head back with the affected ear turned down.
- Bed rest is recommended for patients with acute symptoms.
- Patients with acute vertigo may be medicated with meclizine for 1 to 2 weeks.

Labyrinthitis

- Labyrinthitis, an inflammation of the inner ear, can be bacterial or viral in origin.
- The infection can enter the inner ear by penetrating the membranes of the oval or round windows.
- Viral labyrinthitis is a common medical diagnosis.
- The most commonly identified viral causes are mumps, rubella and influenza.

Clinical Manifestations

- Sudden onset of incapacitating vertigo, usually with nausea and vomiting,
- Various degrees of hearing loss, and possibly tinnitus.

Management

- For bacterial: intravenous antibiotic therapy, fluid replacement, and administration of a vestibular suppressant, such as meclizine, and antiemetic medications.
- Viral labyrinthitis: symptomatic treatment.

MÉNIÈRE'S DISEASE

- Meniere's disease is an abnormal inner ear fluid balance caused by a malabsorption in the endolymphatic sac.

Clinical Manifestations

- Fluctuating, progressive sensorineural hearing loss.
- Tinnitus or a roaring sound; a feeling of pressure or fullness in the ear; and episodic, incapacitating vertigo, often accompanied by nausea and vomiting.

- Patients also complain of diaphoresis and a persistent feeling of imbalance or disequilibrium, which may last for days.
- They may complain of attacks that awaken them at night.
- Lateralize of Sounds from a tuning fork (ie, Weber test).

Medical Management

- Most patients with Meniere’s disease can be successfully treated with diet and medication therapy.
- Many patients can control their symptoms by adhering to a low-sodium diet.
- Tranquilizers such as diazepam (Valium) may be used in acute instances to help control vertigo.
- Anti-emetics such as promethazine (Phenergan) suppositories help control the nausea and vomiting and the vertigo.
- Diuretic therapy (eg, hydrochlorothiazide) sometimes relieves symptoms by lowering the pressure in the endolymphatic system.

Surgical management

- Endolymphatic Sac Decompression: equalizes the pressure in the endolymphatic space.
- Intraotologic Catheters: to provide a conduit from the outer ear to the inner ear.
- Vestibular Nerve Section:

OTOTOXICITY

- A variety of medications may have adverse effects on the cochlea, vestibular apparatus, or cranial nerve VIII.
- Medication such as aspirin and quinine, cause irreversible hearing loss.
- Intravenous medications, especially the aminoglycosides, are the most common cause of ototoxicity, and they destroy the hair cells in the organ of Corti.
- To prevent loss of hearing or balance, patients receiving potentially ototoxic medications should be counseled about the side effects of these medications.
- Blood levels of the medications should be monitored.

ACOUSTIC NEUROMA

- An acoustic neuroma is a slow-growing, benign tumor of cranial nerve VIII, usually arising from the Schwann cells of the vestibular portion of the nerve.
- Surgical removal of acoustic tumors is the treatment of choice because these tumors do not respond well to irradiation or chemotherapy.

MSN III Individual Assignment =20

1. Describe the structures and functions of the central and peripheral nervous systems.
2. Compare the functioning of the sympathetic and parasympathetic nervous systems.
3. Describe the significance of physical assessment to the diagnosis of MS dysfunction.
4. Describe the bacterial, fungal &viral skin infections including medical and nursing

THANK YOU!!!!!!!!!