Trachea, Oesophagus & Thoracic Duct.

Introduction :

- Trachea / Windpipe is patent tube for passage of air to and from lungs
- Oesophagus lying behind the trachea opens only while eating / drinking.
- Thoracic duct brings the lymph from major part of body to the root of neck.

Trachea :

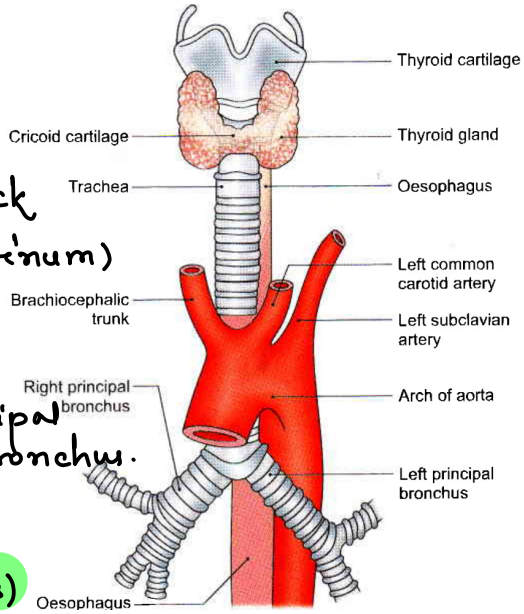

- Wide tube in midline (in lower part of neck and superior mediastinum)
- Upper end is continuous with larynx.
- Lower end is divided into Right & left Principal Bronchus.
- Length = 10–15 cm
  Ext. diameter - 2 cm (males), 1.5 cm (females)
- Lumen = 3mm (1 year old)
  ↓ 12 mm (In adults)
  Increases 1 mm / Year upto 12 years.
- Upper End = 6th Cervical Vertebra, Lower end at 4th thoracic.

Relations :

ANTERIORLY

(1) Manubrium sterni
(2) Sternothyroid muscles
(3) Remains of thymus
(4) Aortic Arch
(5) Cardiac Plexus
(6) Some lymph nodes.

POSTERIORLY

(1) Oesophagus
(2) Vertebral Column

RIGHT SIDE

(1) Righ Lung & Pleura
(2) Righ Vagus
(3) Azygous Vein

LEFT SIDE

(1) Arch of Aorta
(2) left Common Carotid
(3) left Subclavian
(4) left laryngeal N.

Structure :

- It has a **fibroelastic wall** supported by a cartilaginous skeleton formed by **C-shaped rings**.
- About 16-20 in numbers.
- Posteriorly there is a gap which is closed by fibroelastic memb. and contains smooth muscle **(trachealis)**.
- lumen = Ciliated Columnar with Mucous & Serous glands.

Arterial Supply :

- Inferior thyroid arteries

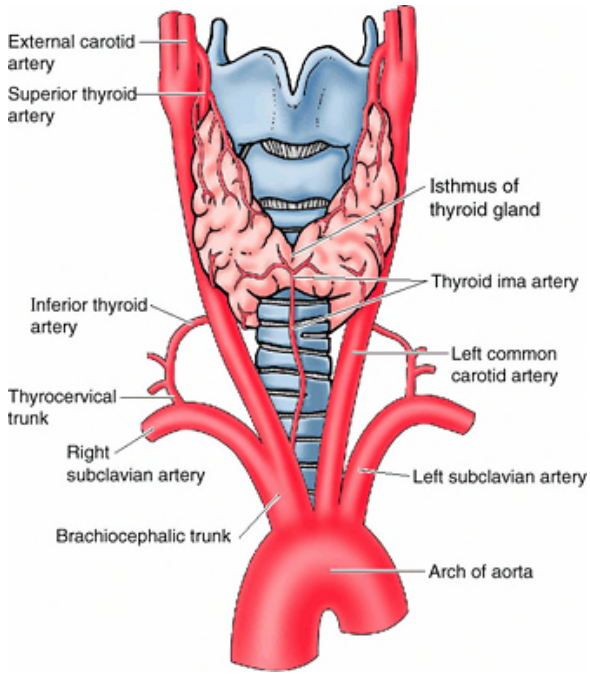

Venous Drainage :

- Into left brachiocephalic Vein.

Lymphatics :

- To pretracheal & Paratracheal Nodes.

Nerve Supply :

- Parasympathetic – Nerves through vagi and recurrent laryngeal nerves. It is :
  - (a) Sensory and secretomotor to mucous membrane.
  - (b) Motor to trachealis muscle.
- Sympathetic – Fibres from middle cervical ganglion reach it along the inferior thyroid arteries and are vasomotor.

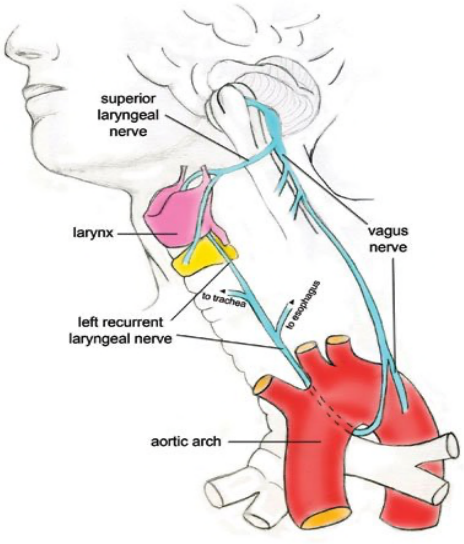

Oesophagus :

- It is narrow, muscular tube, forming food passage.
- Extends from lower part of neck to upper abdomen.
- About 25 cm long.
- It is flattened anteroposteriorly and dilates only during bolus passage.

Constrictions :

- 4 constrictions :

(a) At beginning where it is crossed by cricopharyngeal muscle. (15 cm from incisor teeth)

(b) Where it is crossed by Aortic Arch, 22.5 cm from incisor teeth.

(c) Where it is crossed by left bronchus, 27.5 cm from incisor.

(d) Where it is pierces by diaphragm, 37.5 cm from incisor teeth.

Relations :

ANTERIORLY

(1) Trachea
(2) Right pulmonary A.
(3) left Bronchus
(4) Pericardium
(5) Diaphragm.

RIGHT

(1) Right lung & Pleura
(2) Azygous Vein
(3) The right vagus.

POSTERIORLY

(1) Vertebral Column
(2) Right posterior intercostal Arteries
(3) Thoracic duct
(4) Azygous Vein
(5) Thoracic Aorta
(6) Right Pleural Recess
(7) Diaphragm.

LEFT

(1) Aortic Arch
(2) Subclavian Artery
(3) Thoracic Duct
(4) Left lung & Pleura
(5) left Recurrent Laryngeal N.

Arterial Supply :

- Cervical part including the segment up to Arch of Aorta
  → Inferior thyroid arteries.
- Thoracic Part → Oesophageal Branches of Aorta.
- Abdominal Part → Oesophageal Branches of Left Gastric Artery.

Venous Drainage :

- Upper part - Brachiocephalic Vein.
- Middle part - Azygous Vein.
- Lower End - Left Gastric Vein & Vena azygous via Hemiazygos V.

Lymphatics :

- Cervical part - Deep Cervical Nodes.
  Thoracic part - Posterior mediastinal Nodes.
  Abdominal part - left gastric nodes.

Nerve Supply :

- Parasympathetic - Upper half → Recurrent laryngeal Nerves.
  ↓ [Sensory, Motor and secretomotor.]
  Lower half → Oesophageal Plexus.

- Sympathetic : For Upper half → Middle Cervical Ganglion
  ↓ [Vasomotor]
  Lower half → Upper 4 thoracic ganglia

© MedNotes
(mednotes.in)

Thoracic Duct :

- It is **largest lymphatic** vessel in body.
- Extends from Upper part of abdomen to lower part of Neck.
- About **45 cm long**.
- Have many Valves.

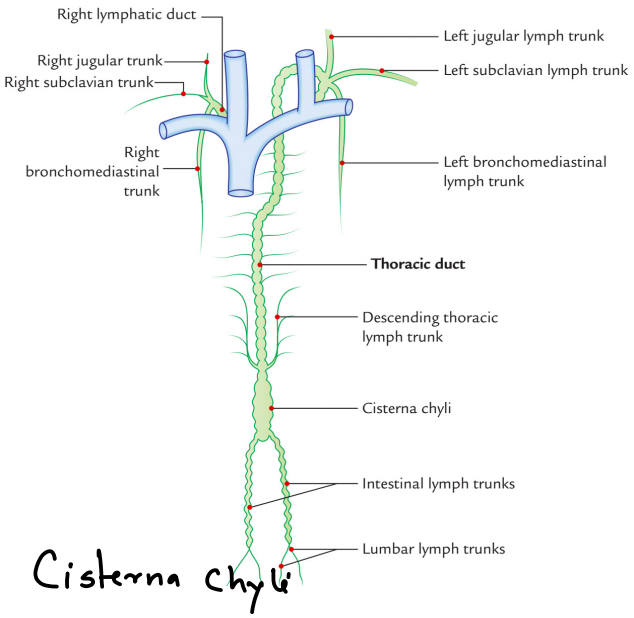

Course :

- Begins as a Continuous of Upper End of Cisterna chyli
  ↓ (enters via Aorta opening) (12th Thoracic)
  Ascends through Post. mediastinum (T12 to T5)
  ↓
  Reaching Neck, it arches laterally at level of transverse process of C7 Vertebrae.
  ↓
  It descends in front of left subclavian A.
  ↓
  Ends by Opening into Angle of Junction between the left subclavian and internal jugular Veins (Left).

Relations :

- At Diaphragm –
  - ANT - Diaphrgm
  - POST - Vertebral Column
  - RIGHT - Azygos Vein
  - LEFT - Aorta.

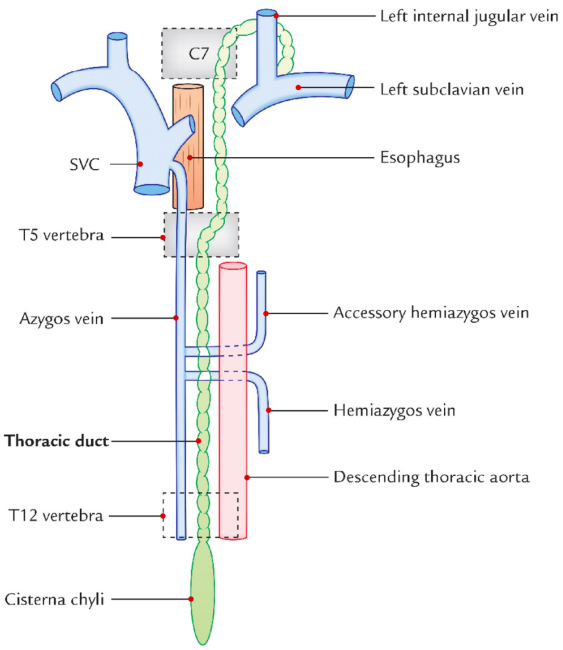

- In Posterior Mediastinum –

ANT – (1) Diaphragm
(2) Oesophagus
(3) Right Pleural Recess

POST – (1) Vertebral Column
(2) Right Posterior Intercostal Arteries
(3) Terminal Part of Hemiazygous Veins.

RIGHT – Azygous Vein

LEFT – Descending thoracic Aorta.

- In Superior Mediastinum –

ANT.. (1) Arch of Aorta
(2) Origin of left Subclavian Artery.

POST – Vertebral Column.

RIGHT – Oesophagus

LEFT – Pleura.

- In Neck: It forms an arch rising 3-4 cm above clavicle.

The Arch → ANT – (1) left Common Carotid
(2) left Vagus
(3) left internal jugular Vein.

POST – (1) Vertebral Artery & Vein
(2) Sympathetic Trunk.
(3) Thyrocervical Trunk
(4) left Phrenic N.
(5) Medial border of Scalenus Anterior
(6) First part of left Subclavian A.

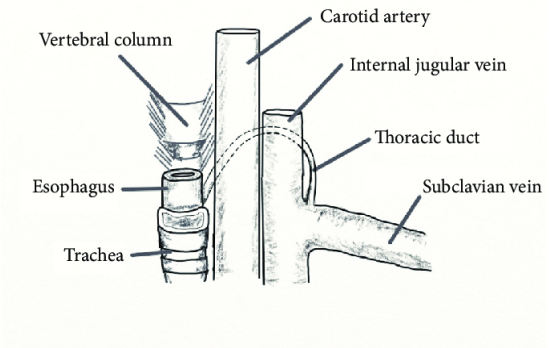

Tributaries :

Tributaries	*Main tributaries:* left and right **lumbar lymph trunks**, left and right **intestinal lymph trunks** (their confluence is called **cysterna chyli**) *Additional tributaries:* **mediastinal** lymph trunks, **left jugular** trunk, **left bronchomediastinal** trunk, **left subclavian** trunk
Drainage	*Drains from:* **75% of the body** → all region **except** for the *right arm, right breast, right lung, right side of the head and neck* (which are drained by the *right lymphatic duct)* *Drains to:* **venous angle (Pirgoff's angle)** between left subclavian vein and left internal jugular vein

[Extras]

Cadaveric Dissection

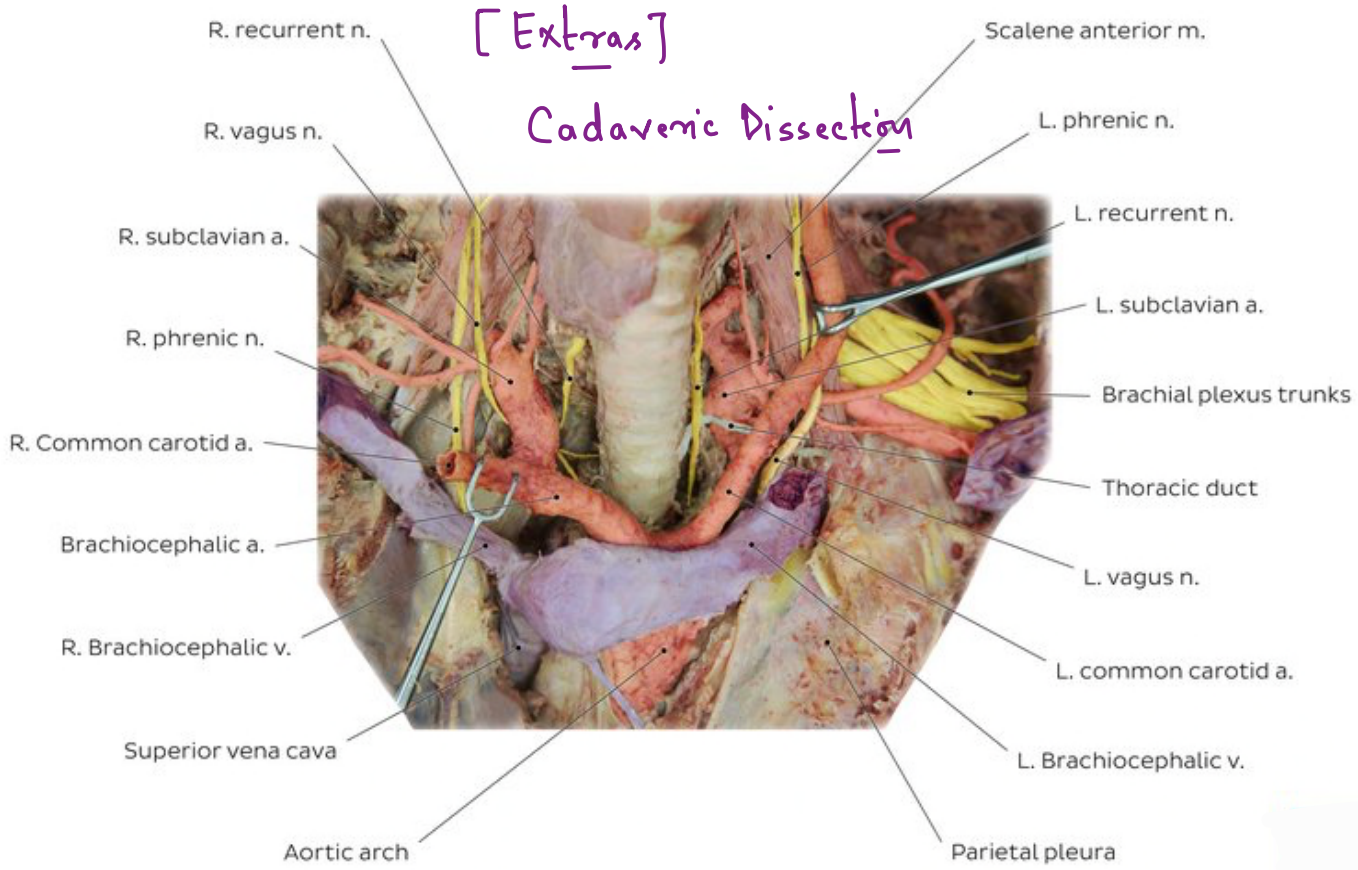

Applied :

Chylothorax

Rupture of the thoracic duct causes chyle to leak into the pleural cavity. The aetiology of this condition includes traumatic and non-traumatic causes. **Traumatic** causes can be either iatrogenic (e.g. surgery, radiation) or non-iatrogenic (e.g. penetrating or blunt trauma to the chest wall, forceful emesis or cough). **Non-traumatic** causes include malignancies, other diseases such as tuberculosis, sarcoidosis, superior vena cava obstruction. Finally, it can also be **congenital** (e.g. Down, Noonan, Turner syndromes).

A chest radiograph would show a pleural effusion while cholesterol and triglyceride measurements in the pleural fluid would point towards the right diagnosis.

Virchow's node

Virchow's node is a large lymph node in the **left supraclavicular area** that drains the lymph from the gut. When it is enlarged (positive **Troisier's sign**), it can be one of the earliest signs of intra-abdominal malignancy, usually a gastric carcinoma following migration of tumour emboli through the thoracic duct. It is located in the venous angle, at the junction of the left subclavian vein and the thoracic duct.

Thoracic duct fistula

This commonly occurs when surgery takes place in the lower part of the left side of the neck. It can lead to prolonged hospital stay, due to protein, electrolyte and fluid imbalances. Presentation will be leakage of milky white fluid from the neck following the incision. If this occurs intraoperatively, it should be repaired, but surgical guidelines for postoperative management are less clear.

[Overview]

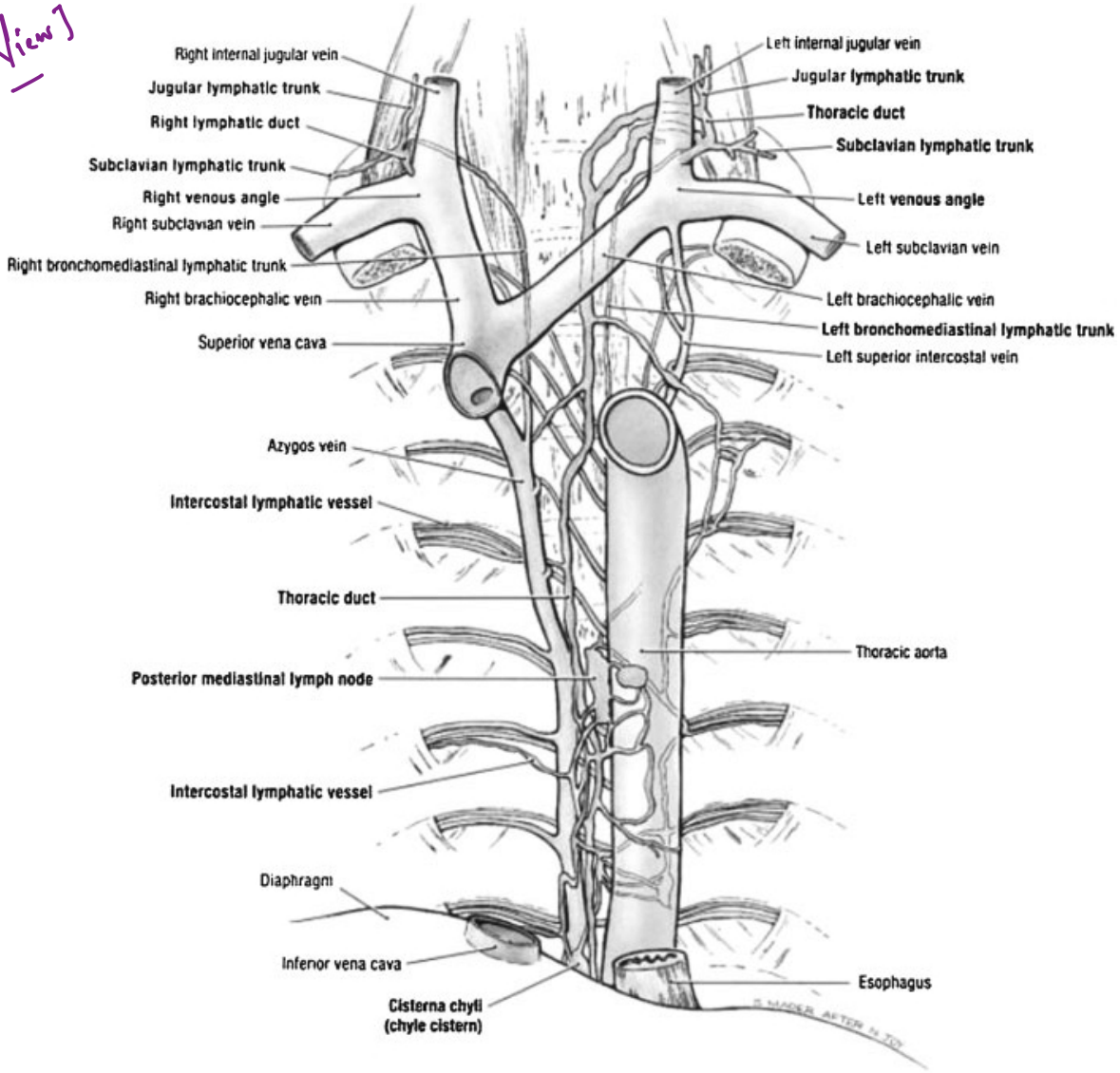

© MedNotes
(mednotes.in)