Surface Anatomy

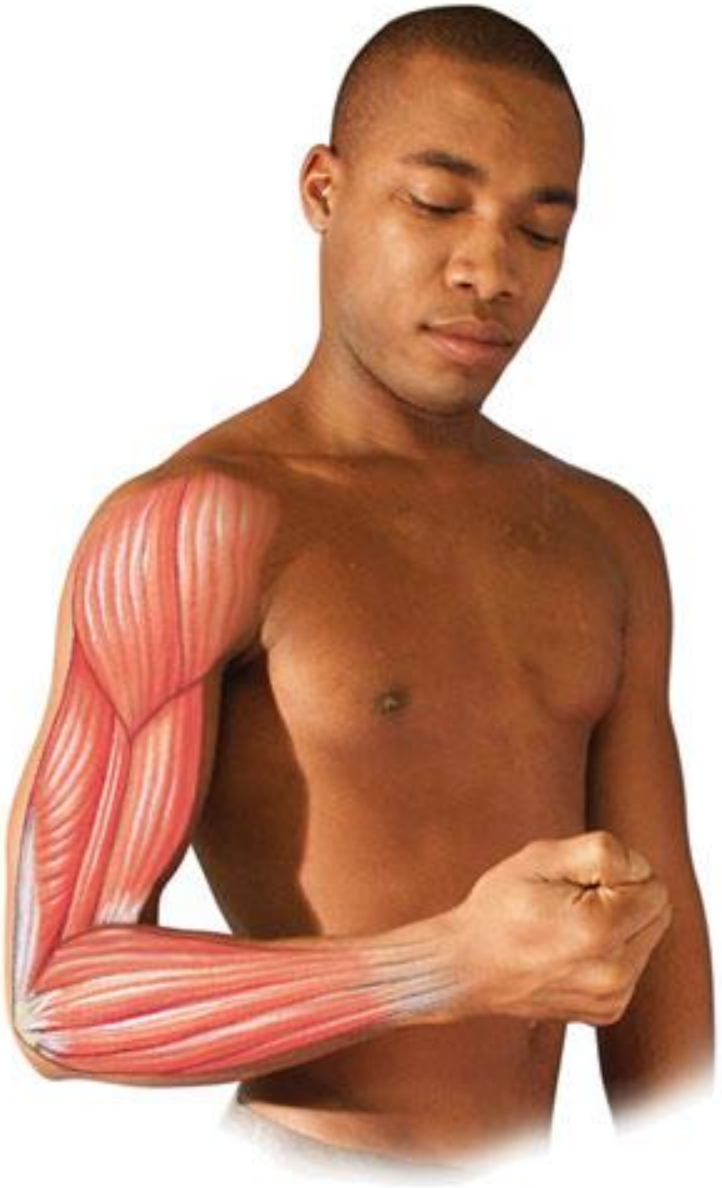

DAVID EBENEZER
DEPARTMENT OF ANATOMY
VELAMMAL MEDICAL COLLEGE

Upper Limb



Axillary Artery

- Abduct the arm to right angles with palm facing upward
- Artery is marked by a straight line joining
  1. Midpoint of clavicle
  2. Junction of anterior 1/3 & posterior 2/3 of lateral wall of axilla at its lower limit

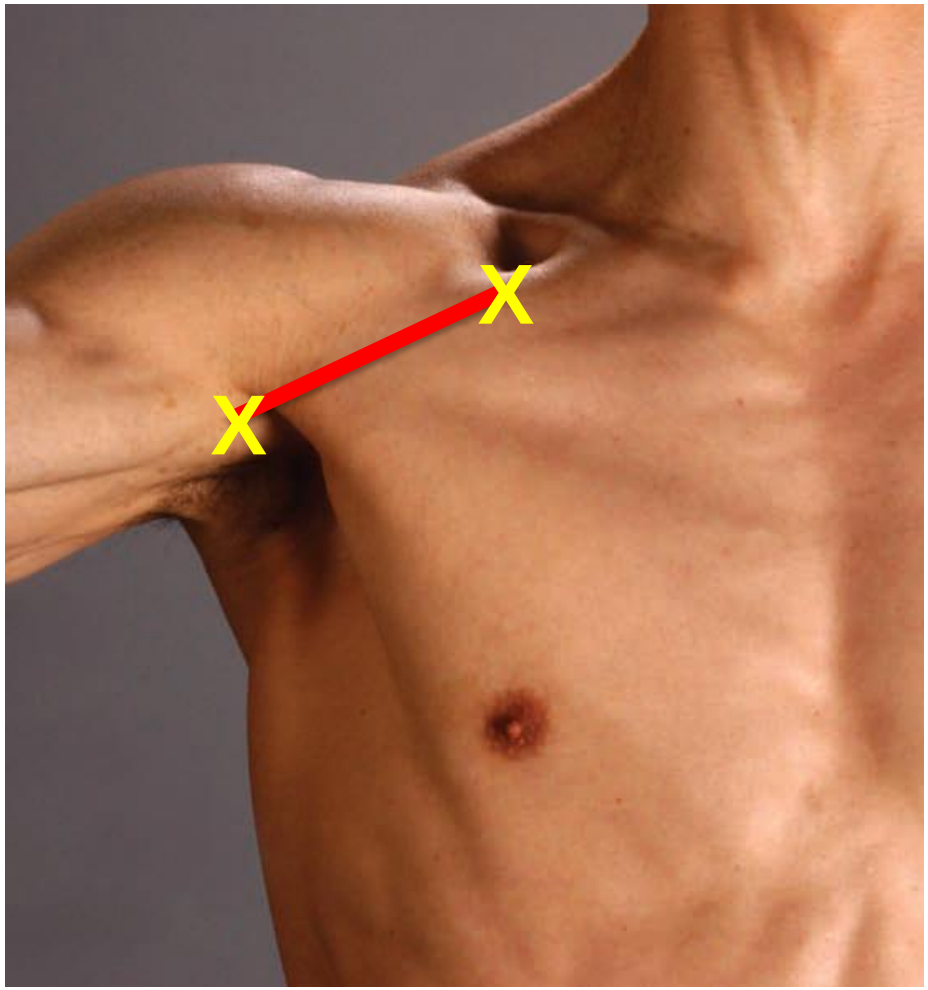

Brachial Artery

1. Junction of anterior 1/3 & posterior 2/3 of lateral wall of axilla at its lower limit
2. Level of neck of radius, medial to the tendon of biceps brachii

Join the above points

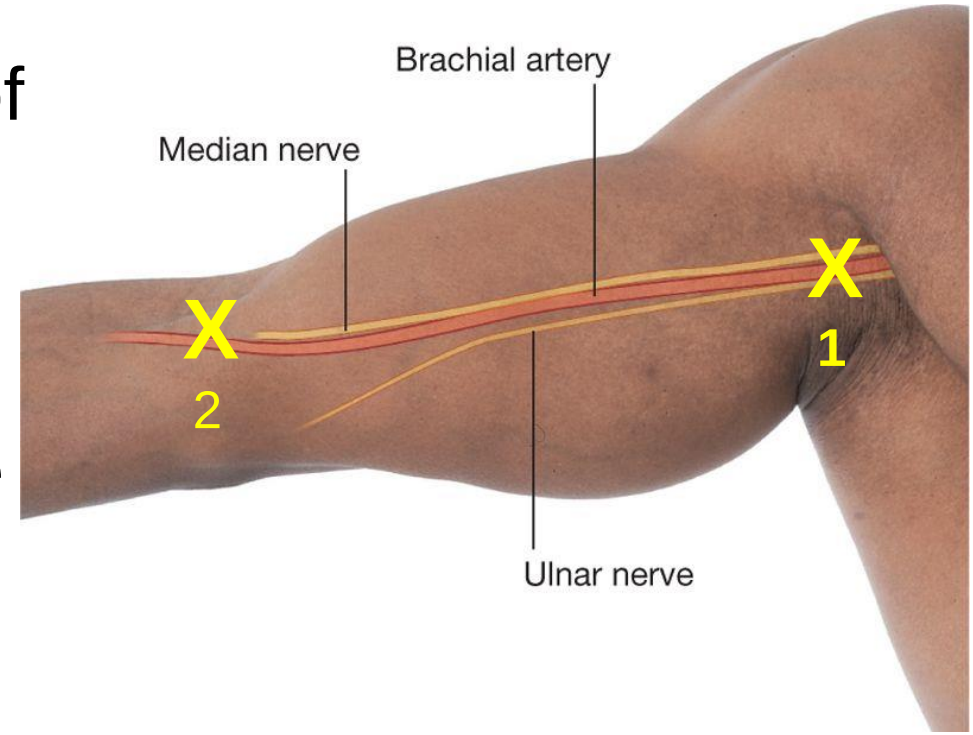

Radial Artery (in forearm)

1. Level of neck of radius, medial to the tendon of biceps brachii
2. At the wrist between anterior border of radius & tendon of flexor carpi radialis

Its course is curved with a gentle convexity laterally

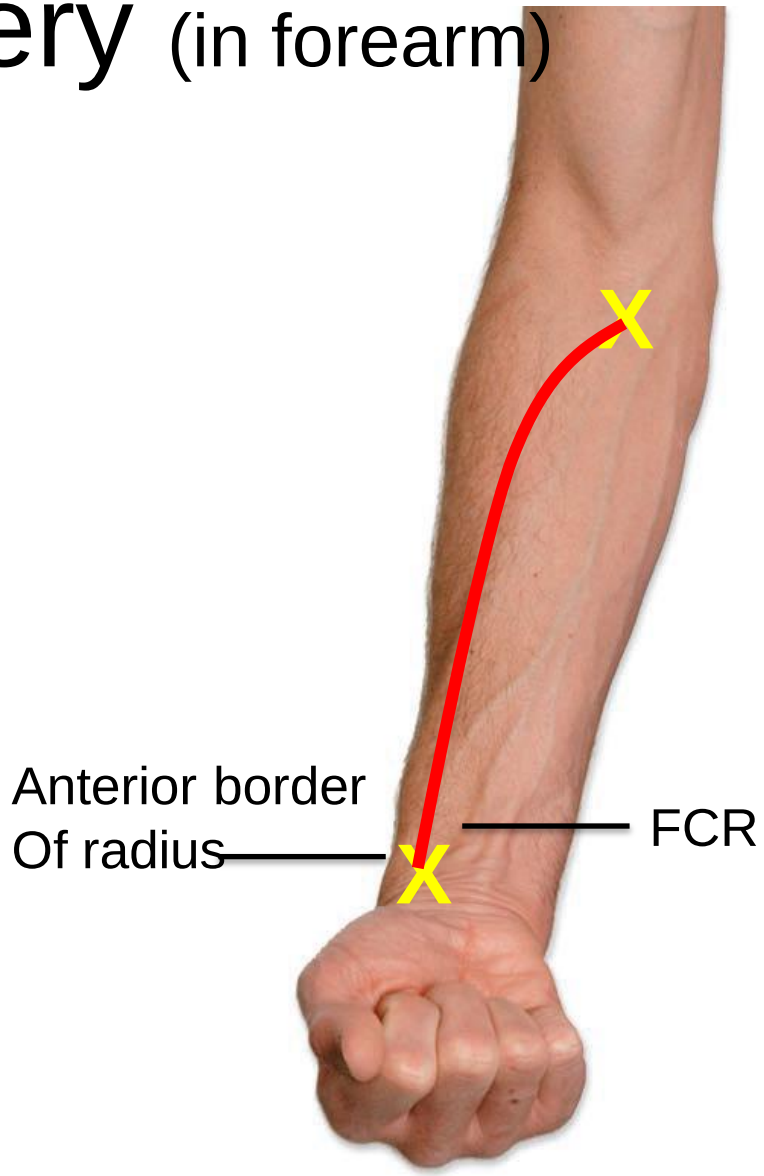

Radial Artery (in hand)

1. At the wrist between anterior border of radius & tendon of flexor carpi radialis
2. Below tip of styloid process of radius
3. Proximal end of 1st intermetatarsal space

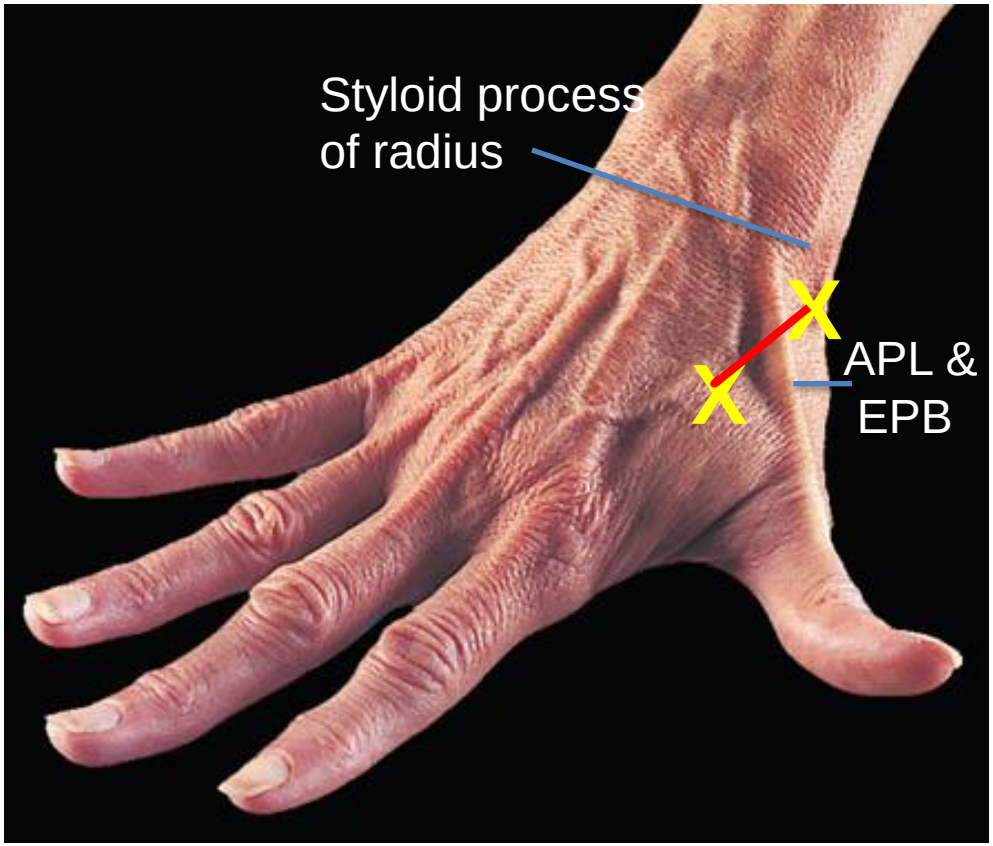

Ulnar Artery

1. Level of neck of radius, medial to the tendon of biceps brachii
2. Junction of upper 1/3 & lower 2/3 of medial border of forearm
3. Lateral to pisiform

The course is oblique in the upper part & vertical in the lower part

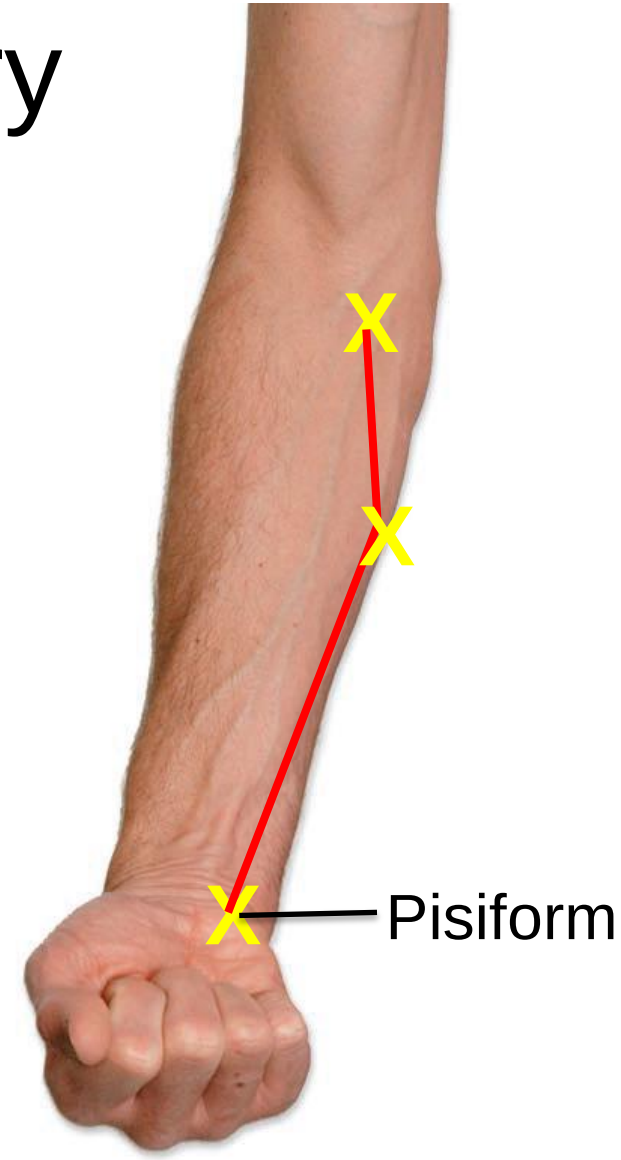

Superficial Palmar Arch

1. A point lateral & distal to pisiform
2. On the hook of hamate
3. On the palm at the level of distal border of the extended thumb in line with cleft between index and middle finger

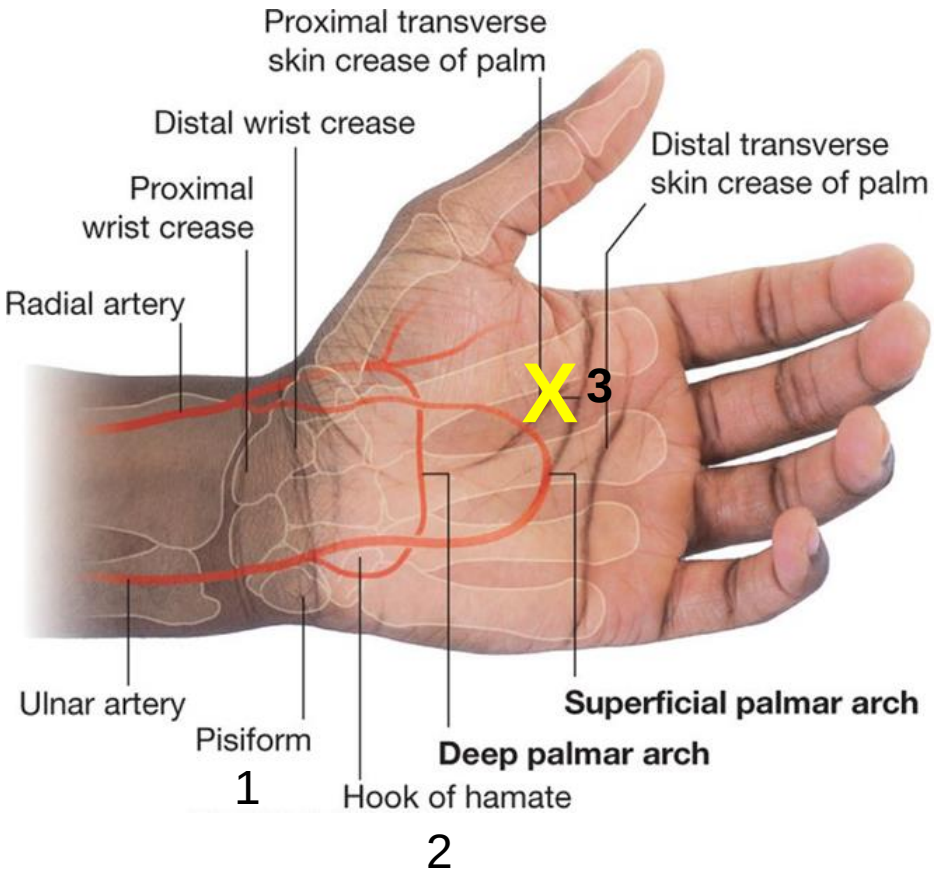

Deep Palmar Arch

- It is marked by a horizontal line 4 cm long just distal to the hook of hamate
- The deep palmar arch lies 1.2 cm proximal to superficial palmar arch

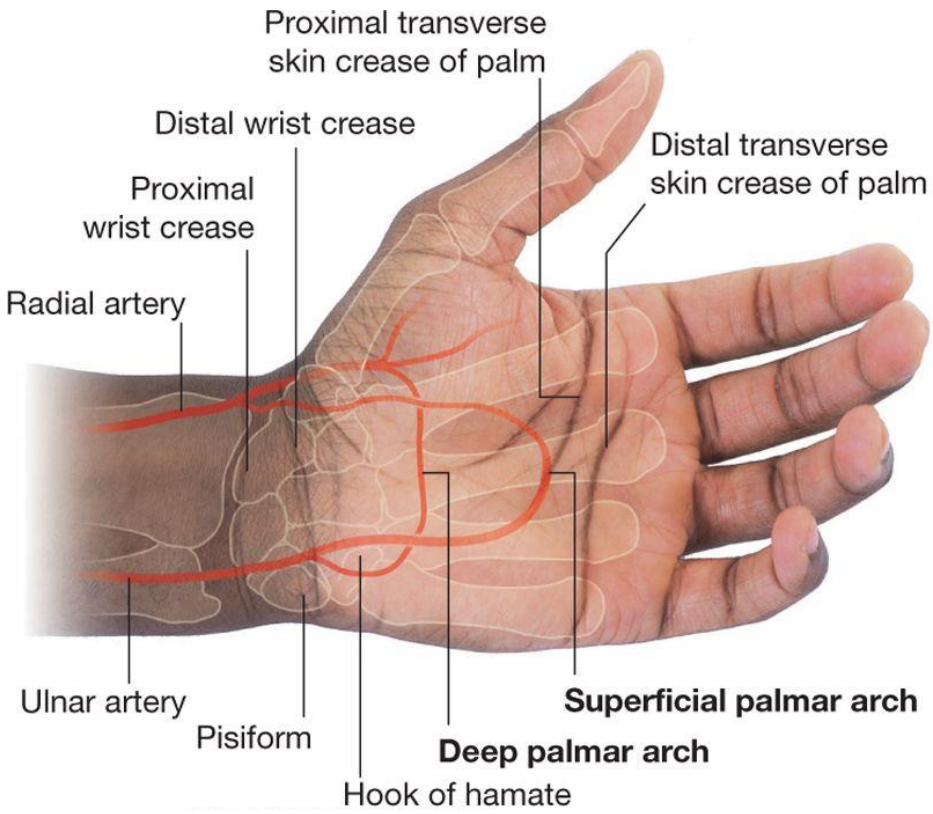

Palpation of Arterial Pulse

1. Brachial pulse- brachial artery lies medial to biceps tendon
2. Ulnar pulse- ulnar artery lies lateral to flexor carpi ulnaris
3. Radial pulse- radial artery lies lateral to flexor carpi radialis







Median Nerve (in the arm)

- Mark the brachial artery
- The nerve is lateral to the artery in the upper half
- The nerve is medial to the artery in the lower half

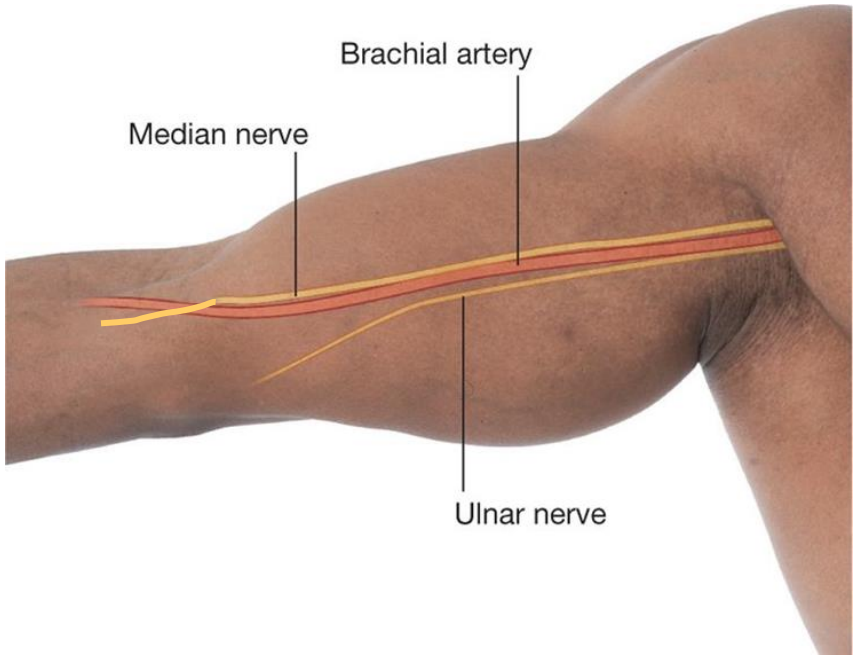

Median Nerve (in the forearm)

- A point medial to the brachial artery at the level of neck of radius
- In front of the wrist 1cm medial to tendon of flexor carpi radialis

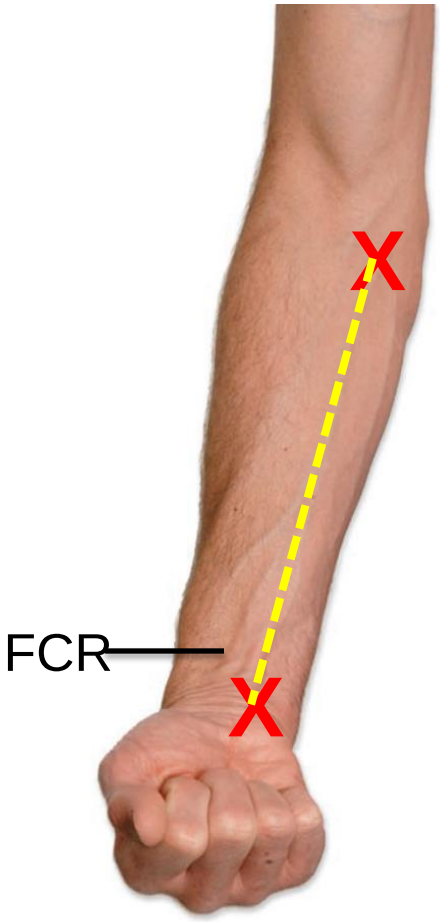

Cephalic Vein

1. In the anatomical snuff box
2. In front of the elbow in the groove between brachioradialis and biceps
3. In the deltopectoral groove below coracoid process

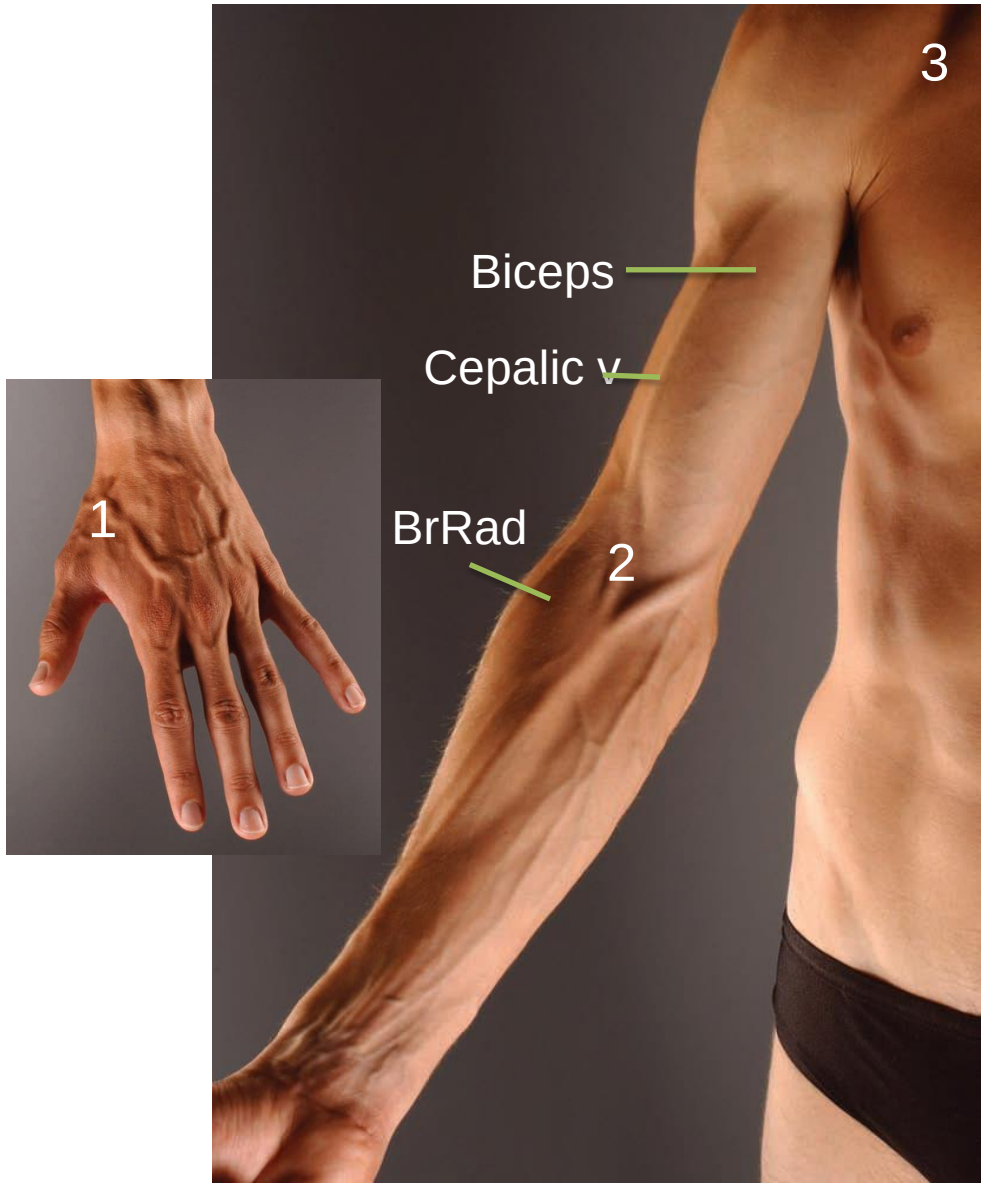

Median Cubital Vein

1. A point 2.5 cm below the lateral side of the elbow
2. A point 2.5 cm above the medial epicondyle

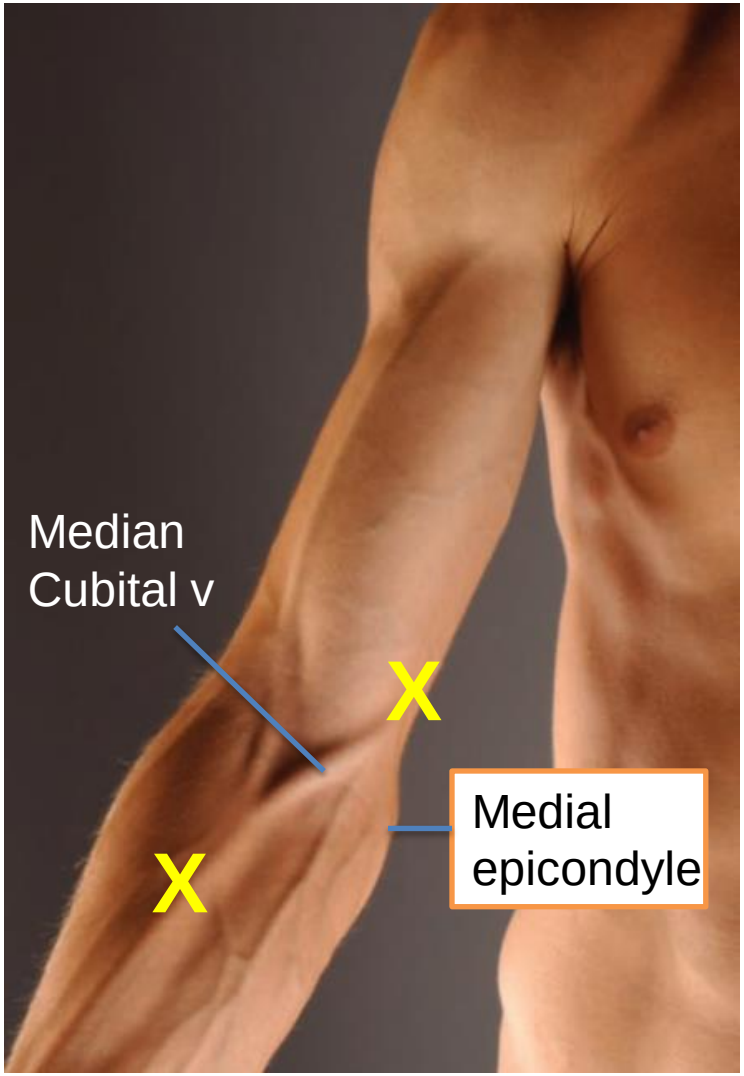

Axillary Nerve

1. Tip of acromion process
2. Insertion of deltoid

Draw horizontal line 2 cm above the midpoint of the above points

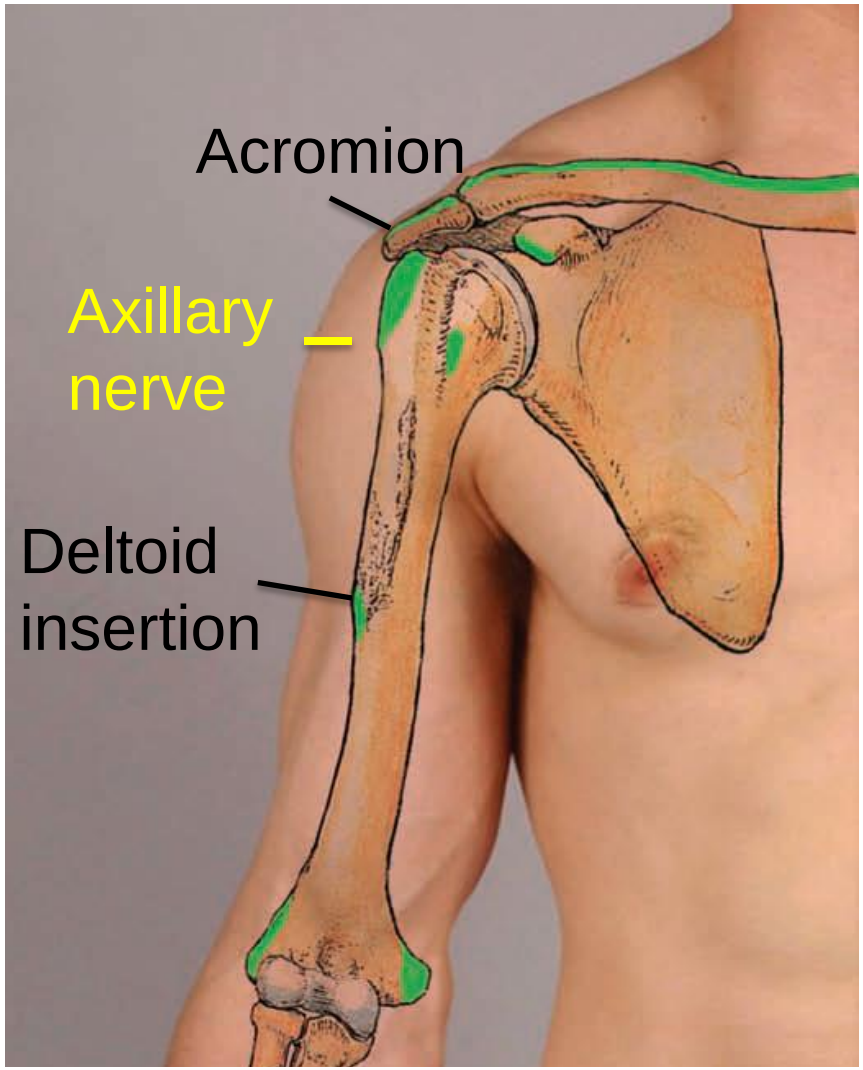

Ulnar Nerve (in the arm)

1. A point on the lateral wall of axilla at its lower limit
2. Middle of the medial border of the arm
3. Behind the base of medial epicondyle of humerus

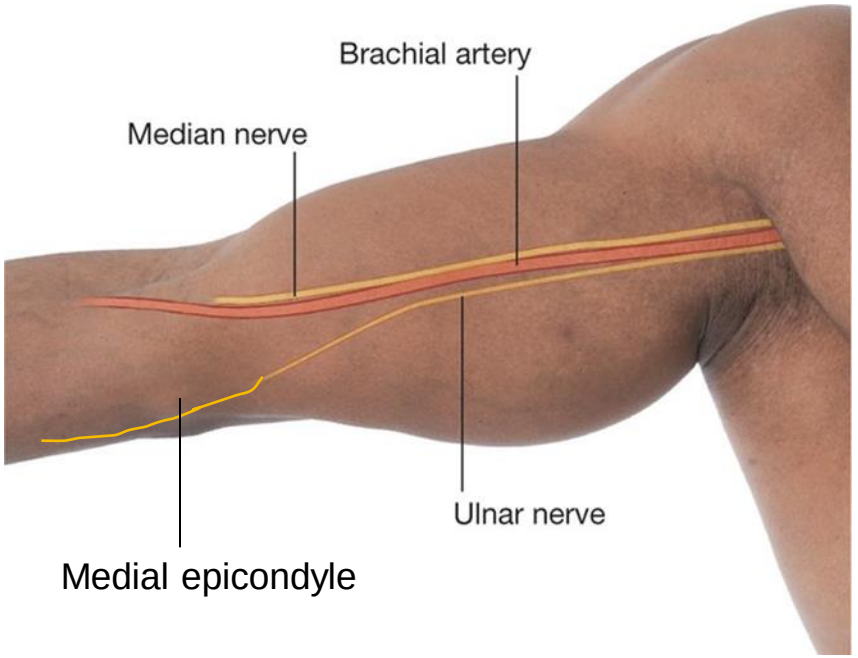

Ulnar Nerve (in the forearm)

1. Behind the base of medial epicondyle of humerus
2. Lateral to the pisiform

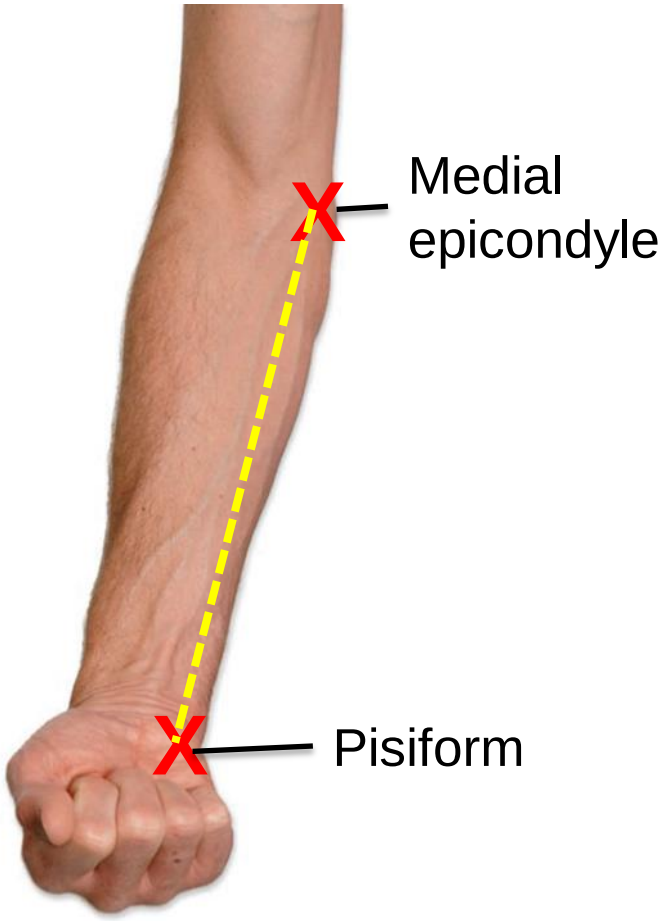

Radial Nerve

- Lateral wall of axilla at its lower limit
- Junction of upper 1/3 & lower 2/3 of a line joining lateral epicondyle & insertion of deltoid
- On the front of the elbow just below the lateral epicondyle 1cm lateral to tendon of biceps brachii

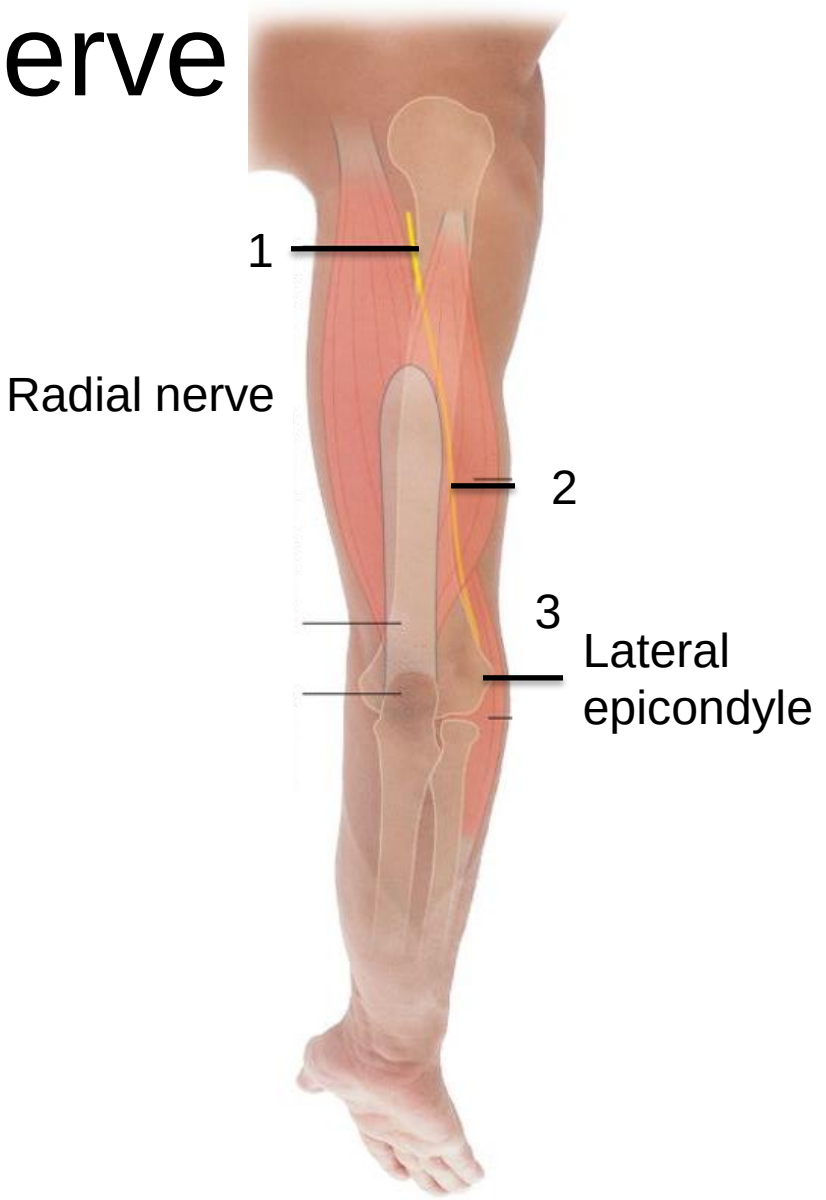

Flexor Retinaculum

1. Pisiform
2. Tubercle of scaphoid
3. Hook of hamate
4. Crest of trapezium

- Proximal border- join 1 & 2 concave downward
- Distal border- join 3 & 4 concave upward

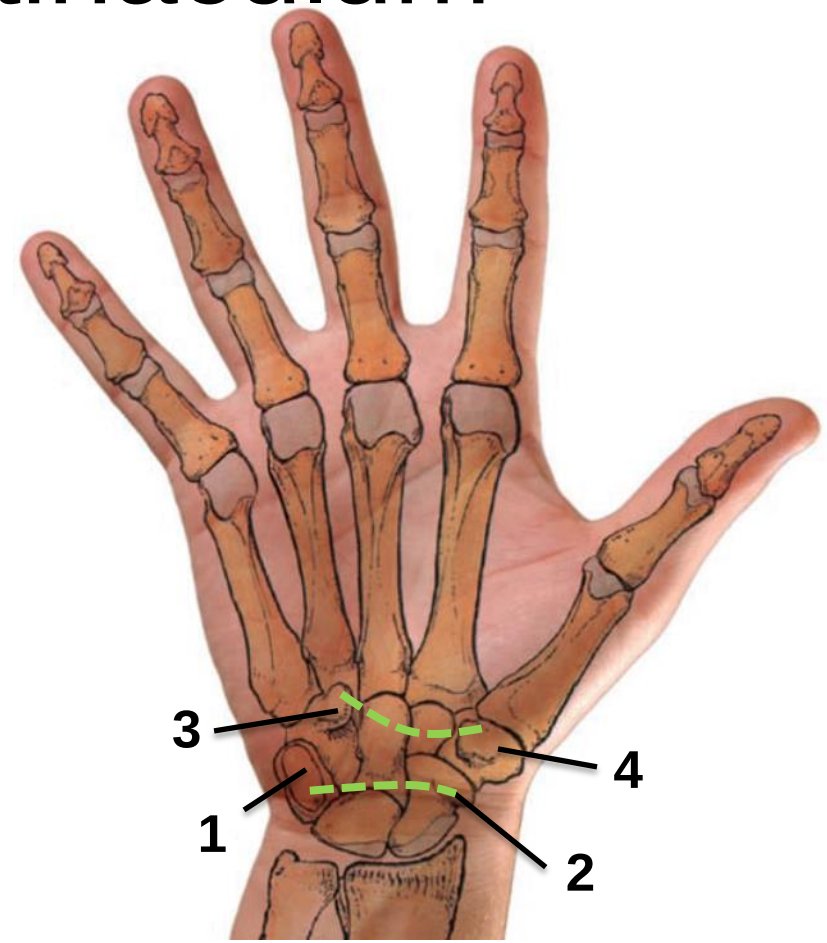

Extensor Retinaculum

1. Lateral- lower part of anterior border or radius
2. Medial- pisiform, triquetral and styloid process of ulna

Extensor retinaculum is 2 cm broad band directed downward and medially

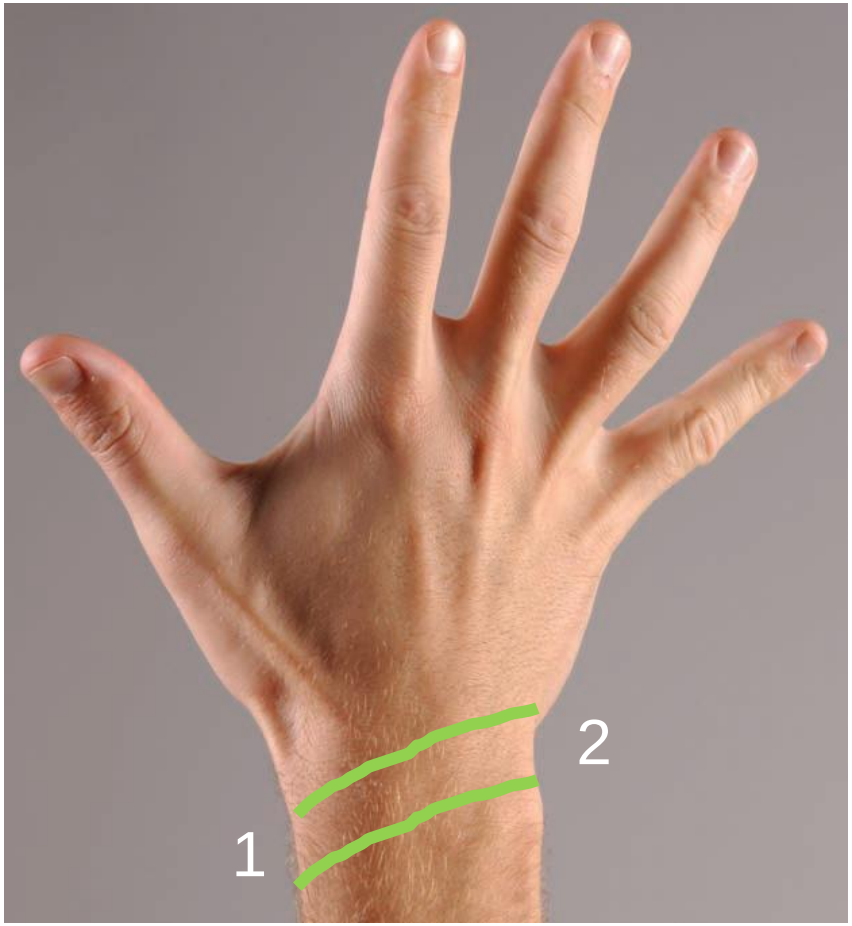

Anatomical Snuff Box

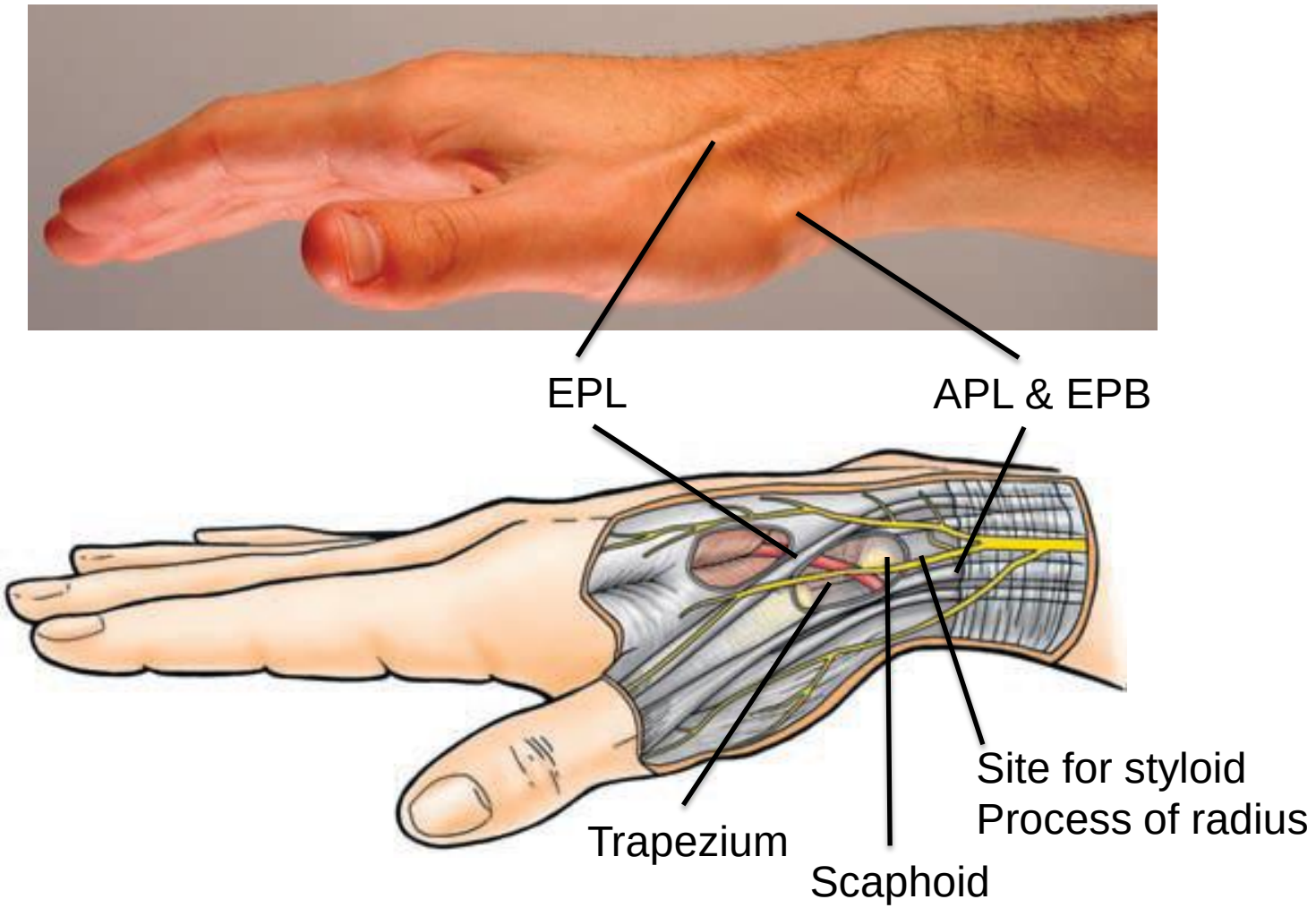

Lower Limb



Femoral Artery

1. Midinguinal point- A point midway between anterior superior iliac spine (ASIS) & pubic symphysis
2. Adductor tubercle

Join the above, the upper 2/3 of the line represents femoral artery

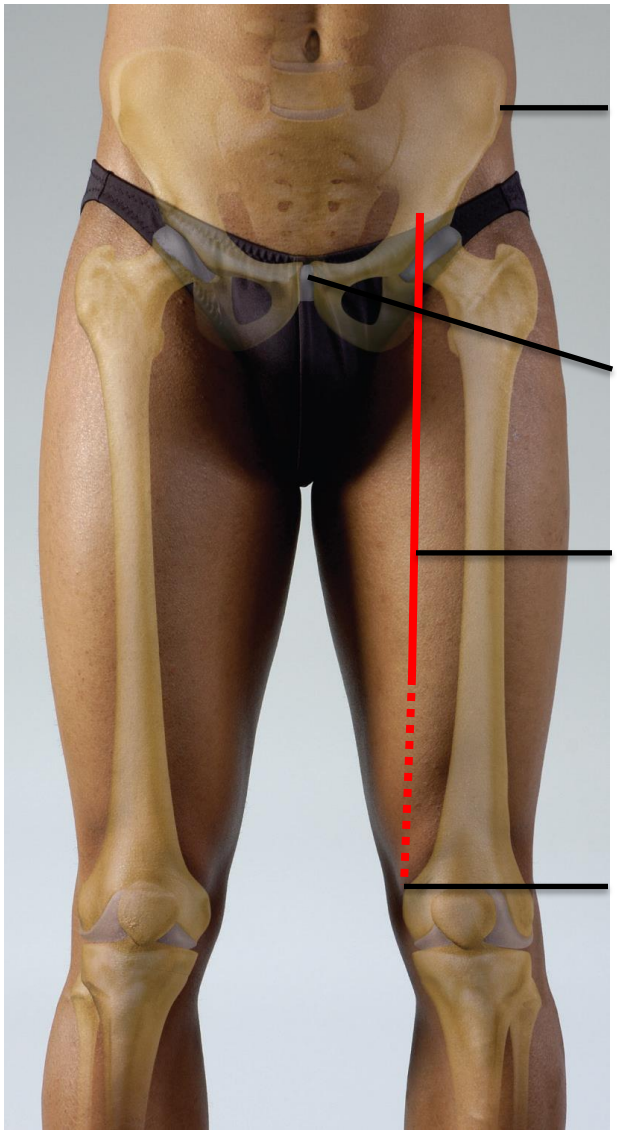

Popliteal Artery

1. At the junction of middle & lower thirds of thigh, 2.5cm medial to the midline on the back of thigh
2. On the midline of the back of the knee
3. On midline of back of leg at the level of tibial tuberosity

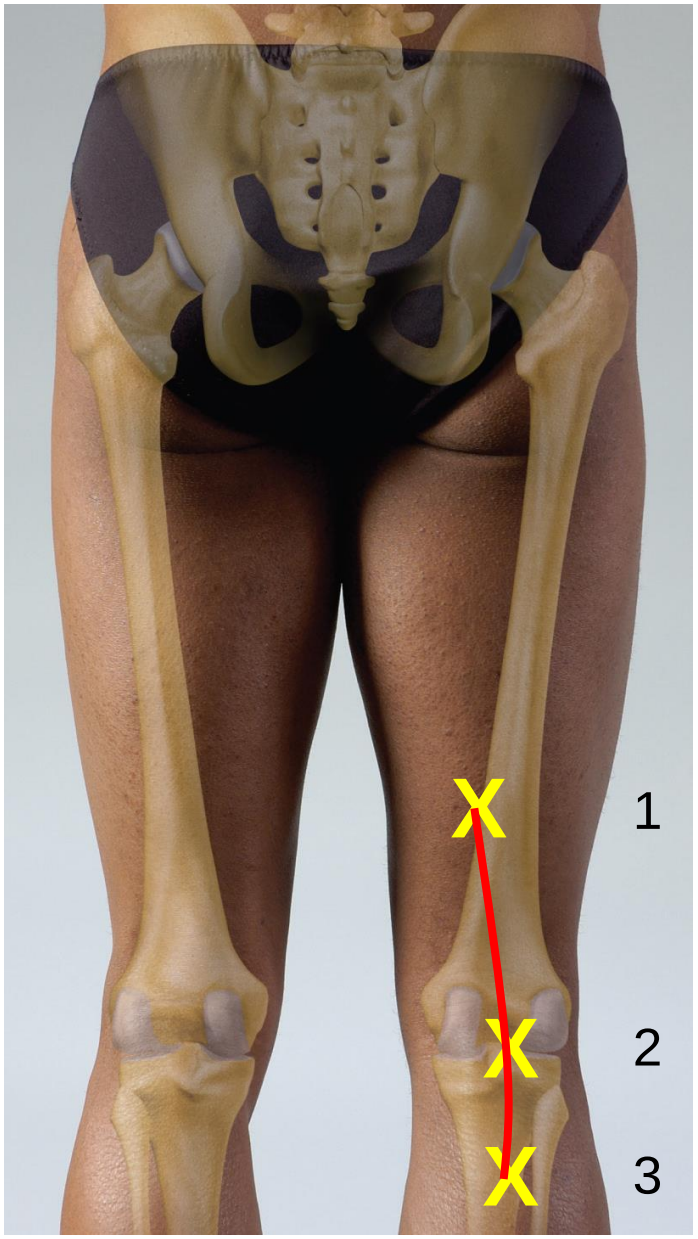

Posterior Tibial Artery

1. On midline of back of leg at the level of tibial tuberosity
2. Midway between medial malleolus and tendocalcanueus

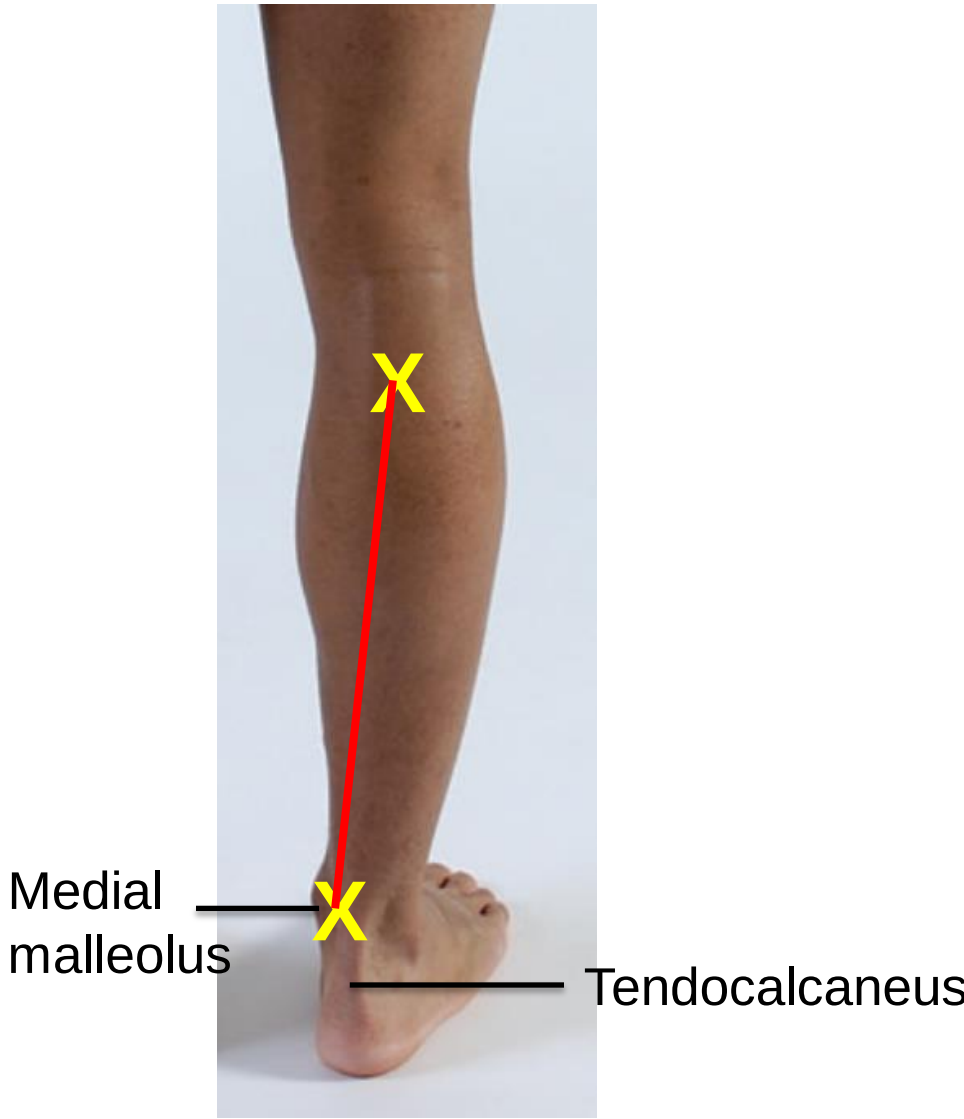

Anterior Tibial Artery

1. 2.5cm below the medial side of head of the fibula
2. Midway between the two malleoli

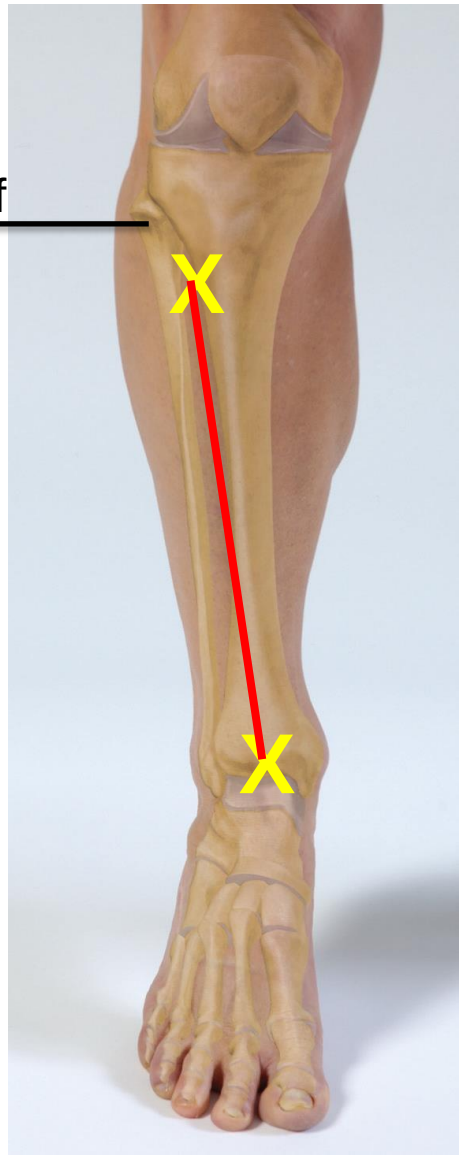

Dorsalis Pedis Artery

1. Midway between the two malleoli
2. Proximal end of first intermetatarsal space

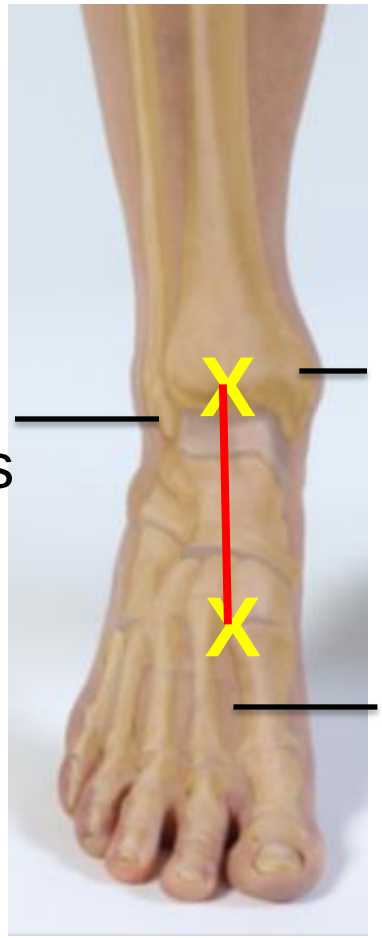

Palpation of Arterial Pulse

1. Femoral pulse- inferior to the inguinal ligament at the midinguinal point
2. Popliteal pulse- deep in the popliteal fossa medial to the midline

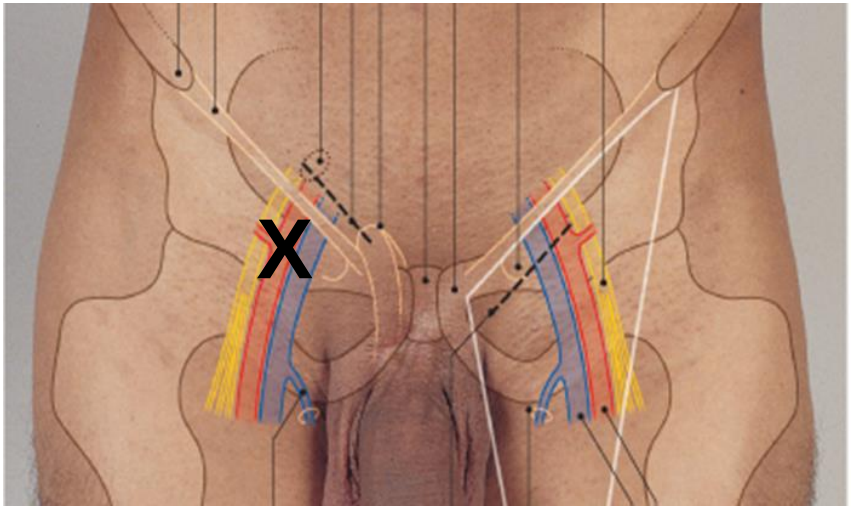



Continued…

3. Posterior tibial pulse- posteroinferior to the medial malleolus
4. Dorsalis pedis pulse- over tarsal bones between tendons of extensor hallucis longus and extensor digitorum longus to the second toe.



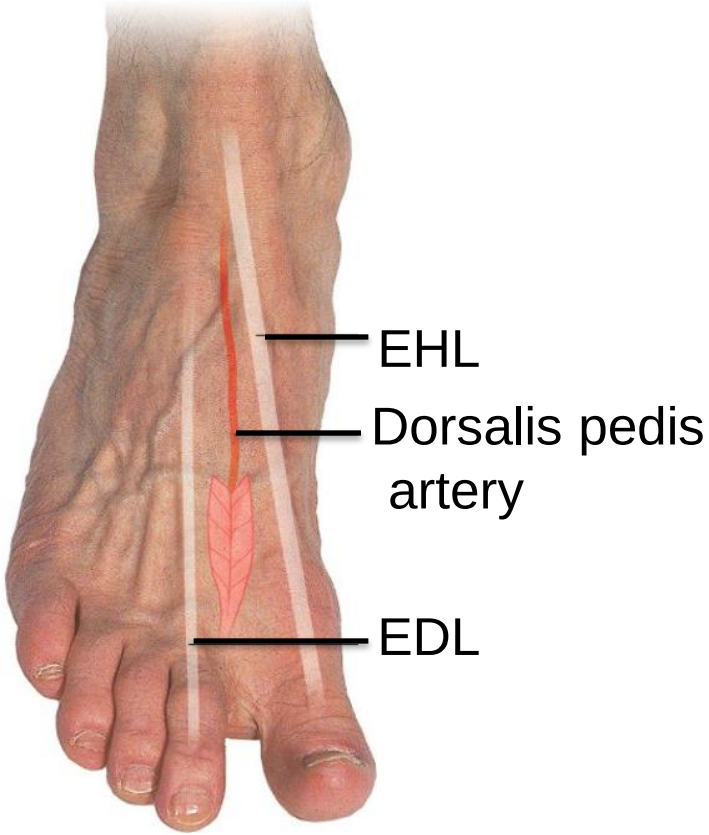

Great Saphenous Vein

1. On the dorsum of foot at medial end of dorsal venous arch
2. Anterior surface of medial malleolus
3. On medial border of tibia at junction of upper 2/3 & lower 1/3 of leg
4. At the adductor tubercle
5. Saphenous opening- 4cm below & 4cm lateral to pubic tubercle



Femoral Vein

Same as femoral artery except-

1. 1cm medial to midinguinal point
2. 1cm lateral to adductor tubercle

Join the above, the upper 2/3 of the line represents femoral vein

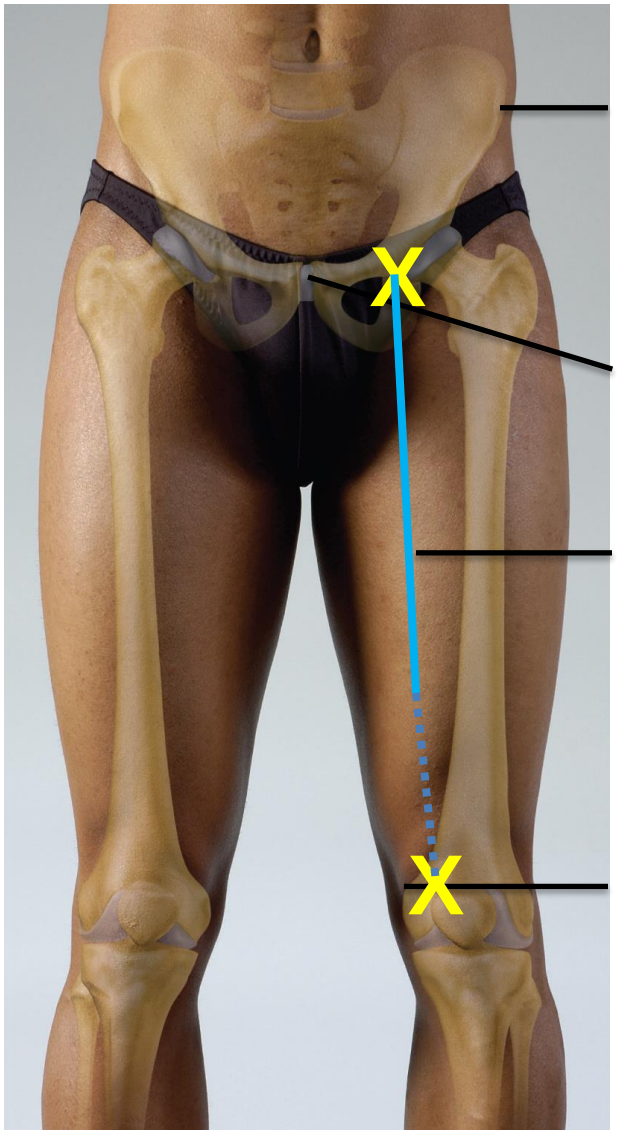

Saphenous Opening

- Its center lies 4cm below and 4cm lateral to the pubic tubercle
- It is about 2.5cm long and 2cm broad with its long axis directed downward and laterally

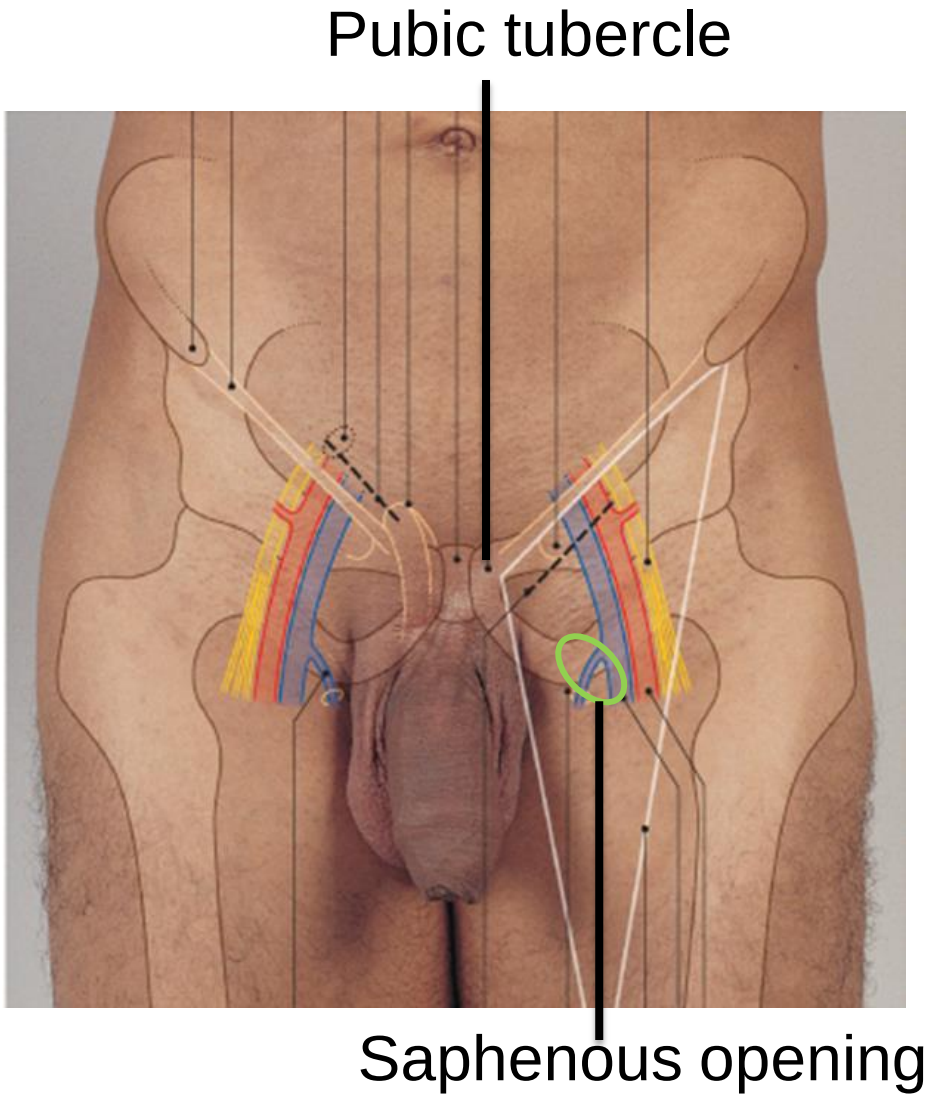

Femoral Nerve

1. 1.2cm lateral to midinguinal point
2. 2.5cm vertically below the first point

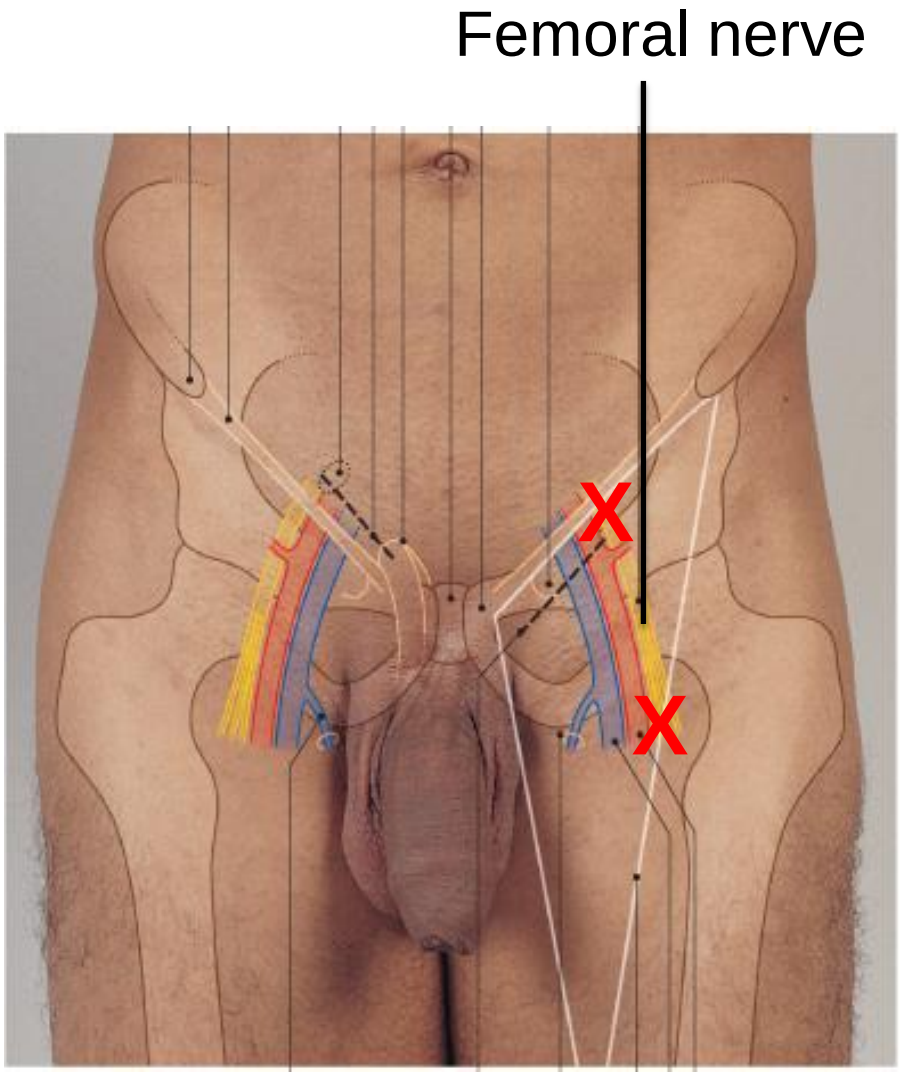

Sciatic Nerve

1. 2.5cm lateral to midpoint between posterior superior iliac spine (PSIS) & ischial tuberosity
2. Just medial to midpoint between ischial tuberosity & greater trochanter
3. In midline of back of thigh at junction of upper 2/3 & lower 1/3 i.e superior angle of popliteal fossa

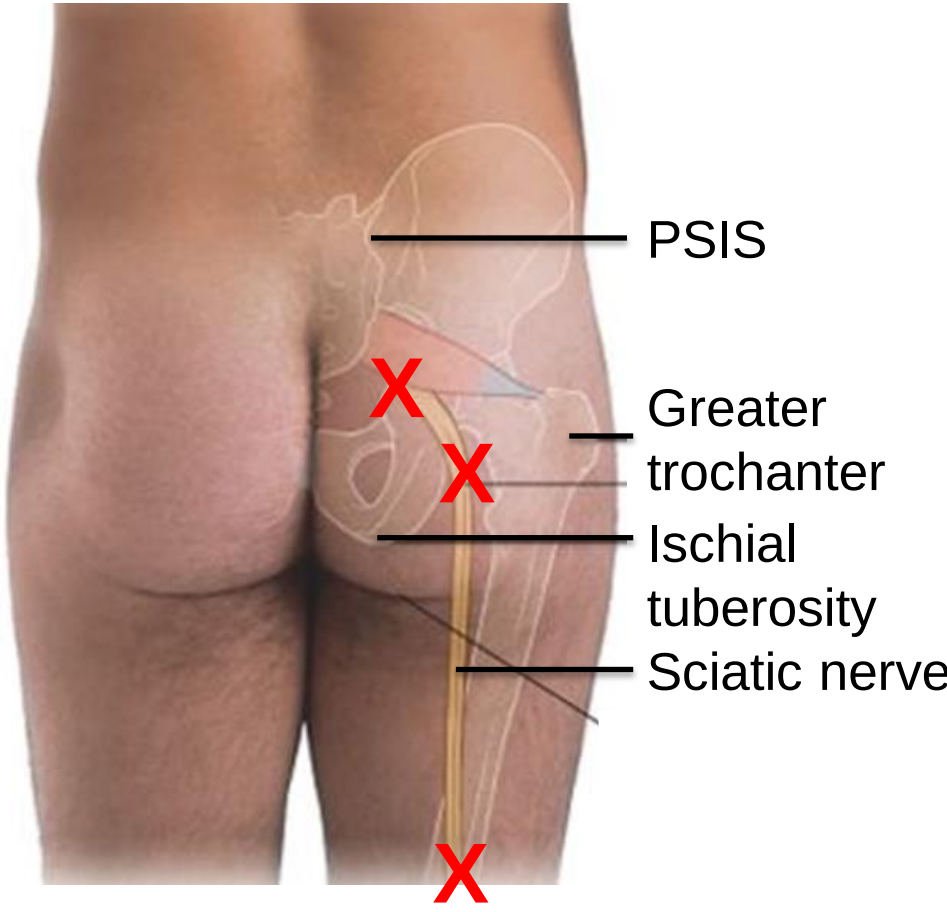

Common Peroneal Nerve

1. Superior angle of popliteal fossa
2. On the back of neck of fibula

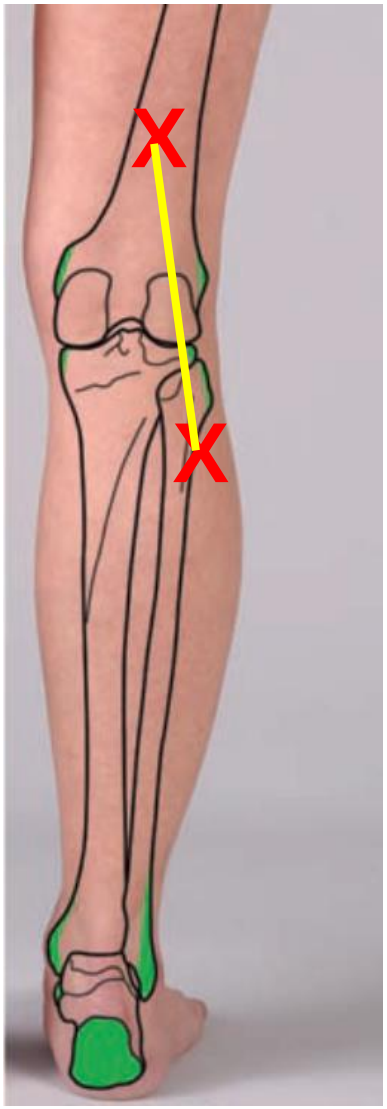

Bryant's Triangle

Drawn with patient supine to detect disturbance in femoral head & neck anatomy

1. Draw line from ASIS (A) to greater trochanter (C)
2. Draw a horizontal line from ASIS
3. Draw vertical line from greater trochanter

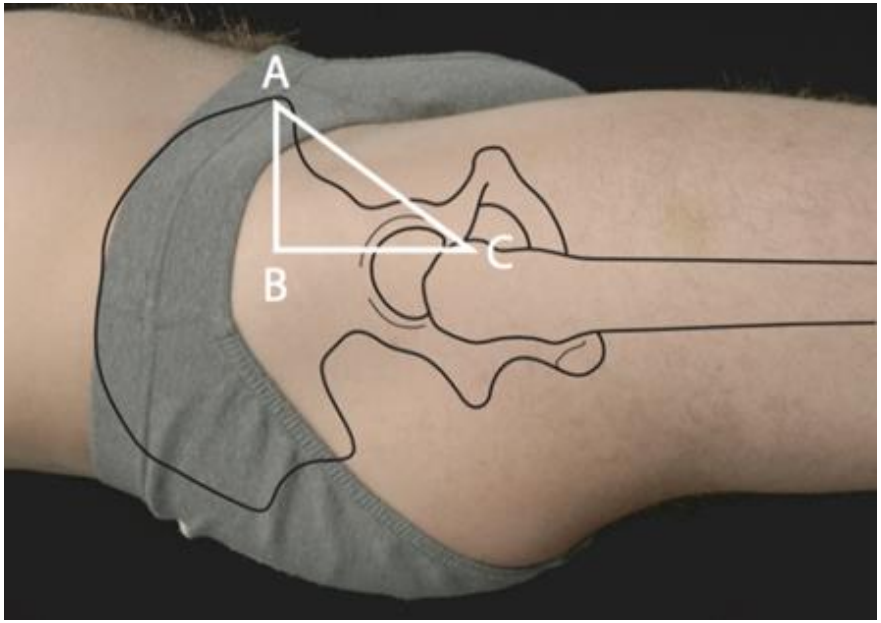

Thorax

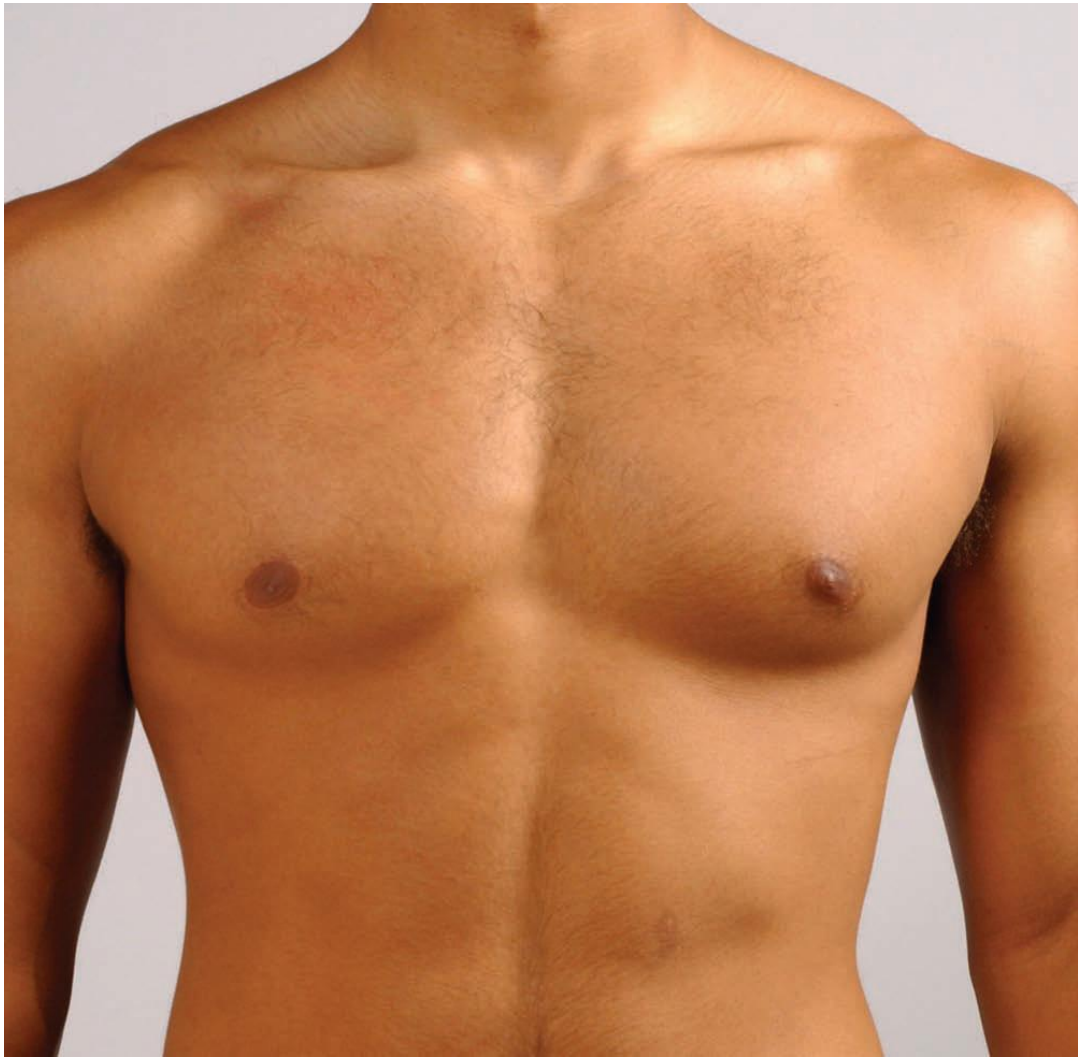

Right Brachiocephalic Vein

1. Medial end of right clavicle
2. Lower border of right 1st costal cartilage close to sternum

Join these by two parallel lines 1.5cm apart

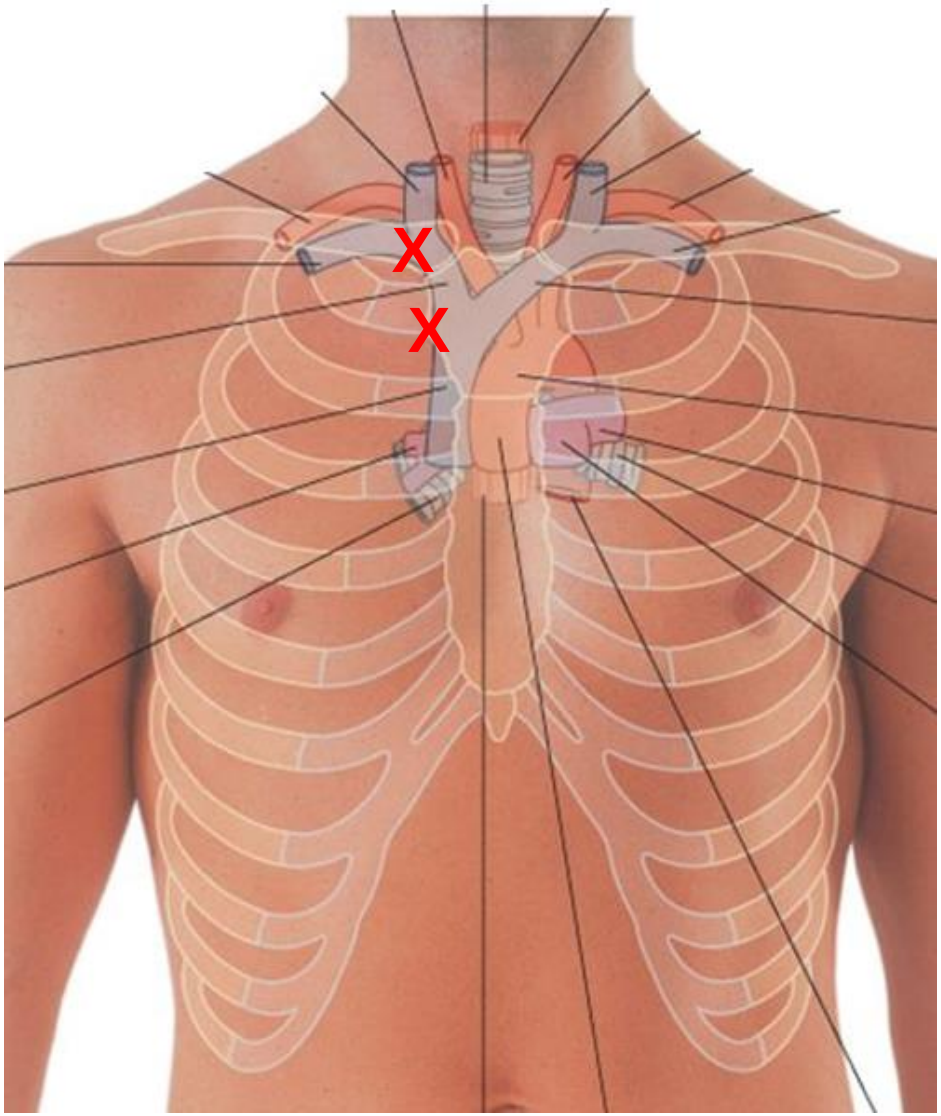

Left Brachiocephalic Vein

1. Medial end of left clavicle
2. Lower border of right 1st costal cartilage close to sternum

Join these by two parallel lines 1.5cm apart going behind the upper half of the manubrium

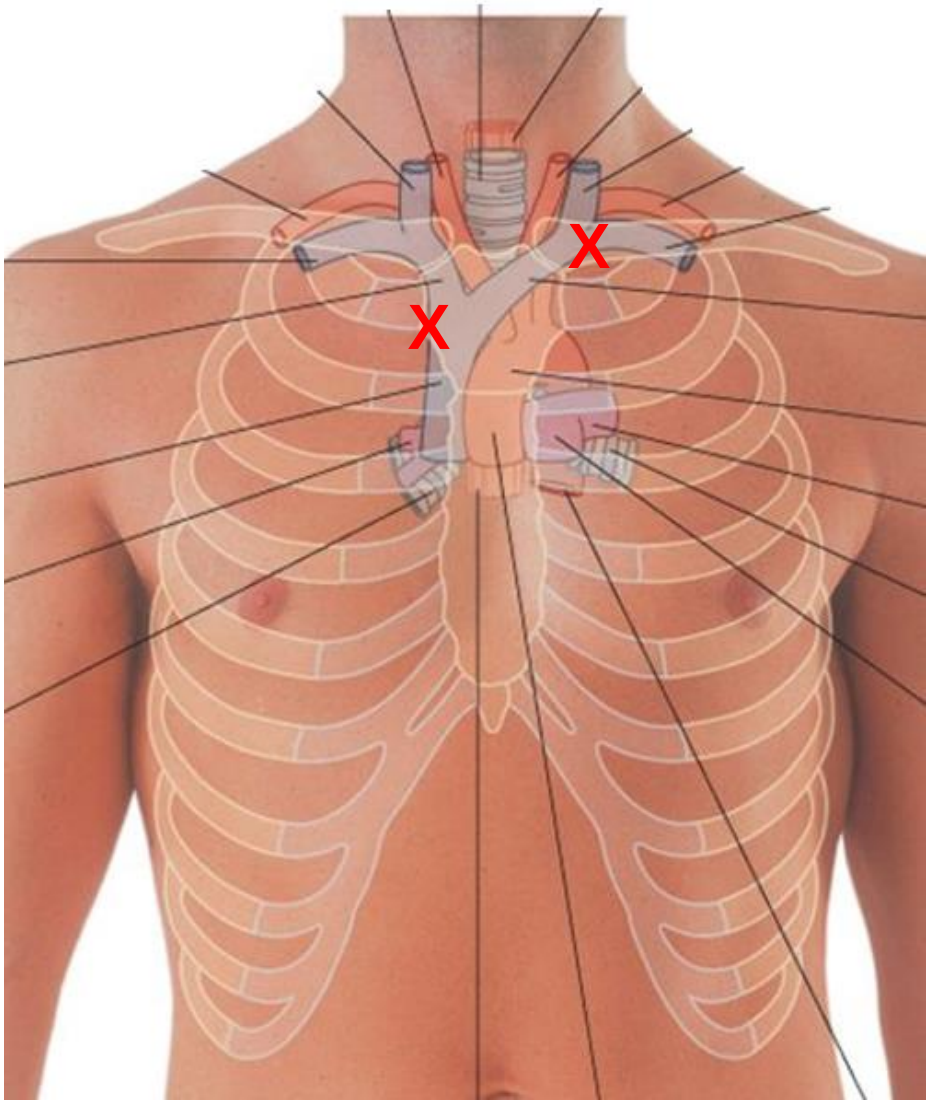

Superior Vena Cava

1. Lower border of right 1st costal cartilage close to sternum
2. Sternal end of upper border of right 3rd costal cartilage

Draw a line 2cm wide joining these partly under cover of right margin of sternum

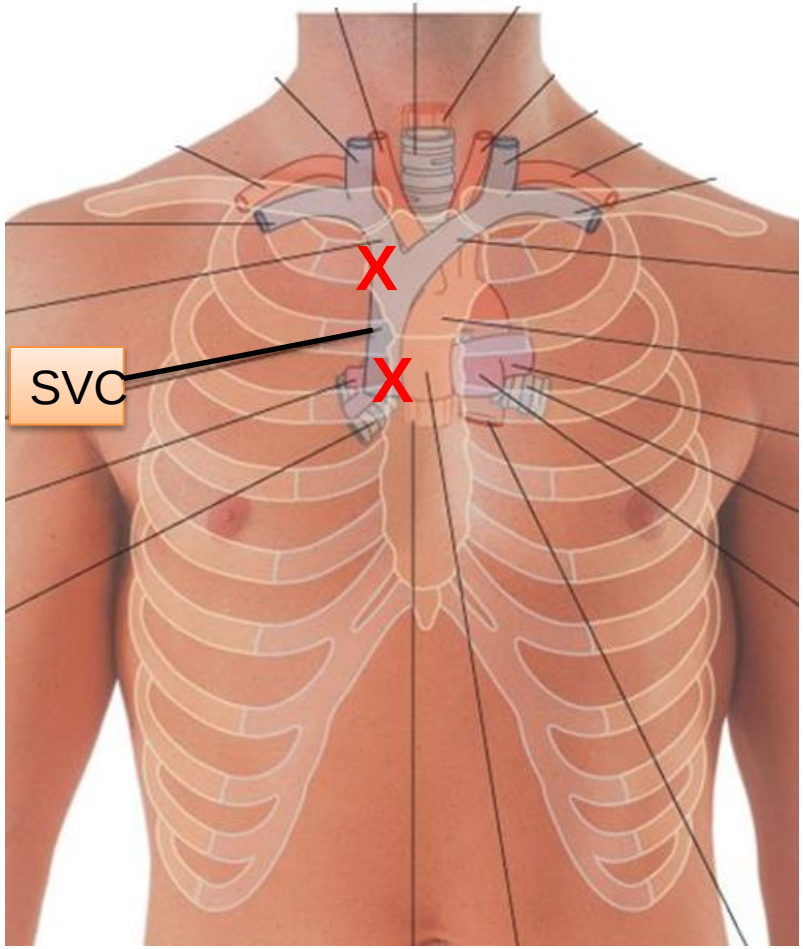

Arch of Aorta

1. Right end of sternal angle
2. Center of manubrium
3. Sternal end of left 2nd costal cartilage

Draw a line through these to represent the outer convexity

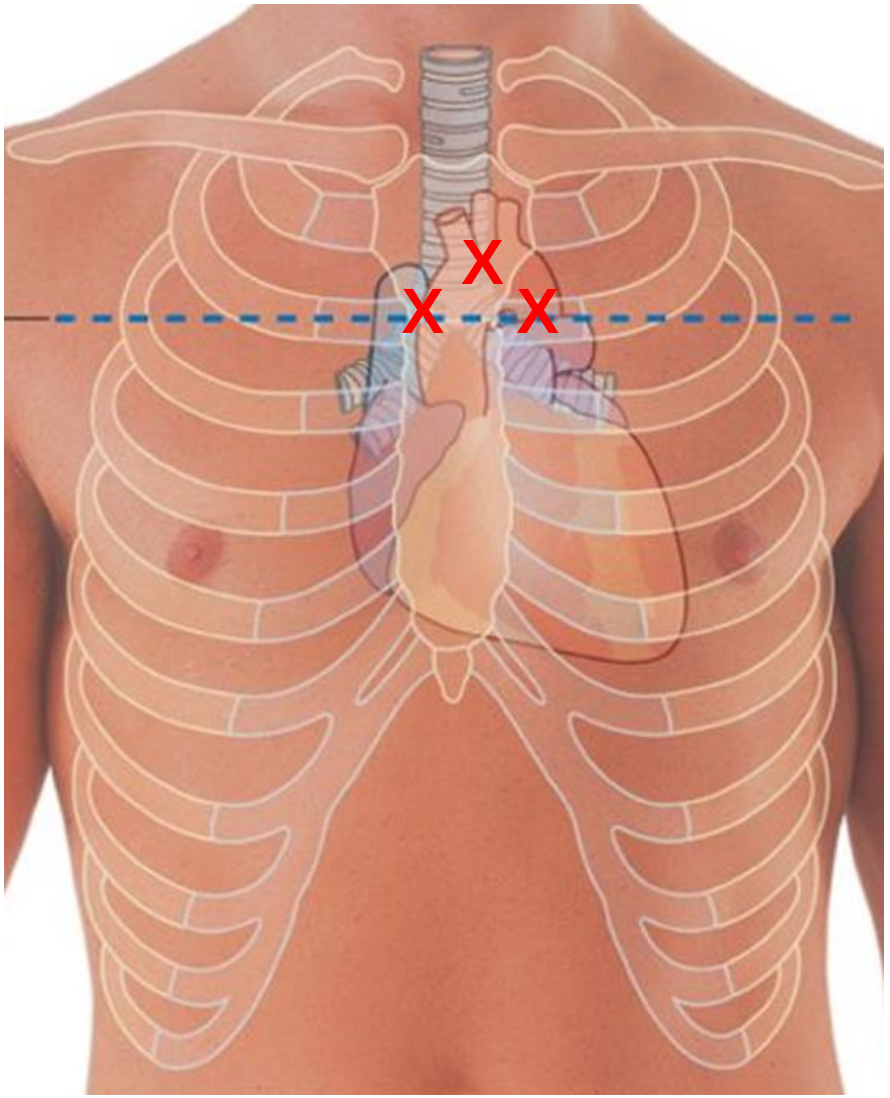

Trachea

1. A point immediately below the arch of cricoid cartilage
2. A point 1cm lateral to center of sternal angle

Draw two parallel lines 2cm apart joining these points

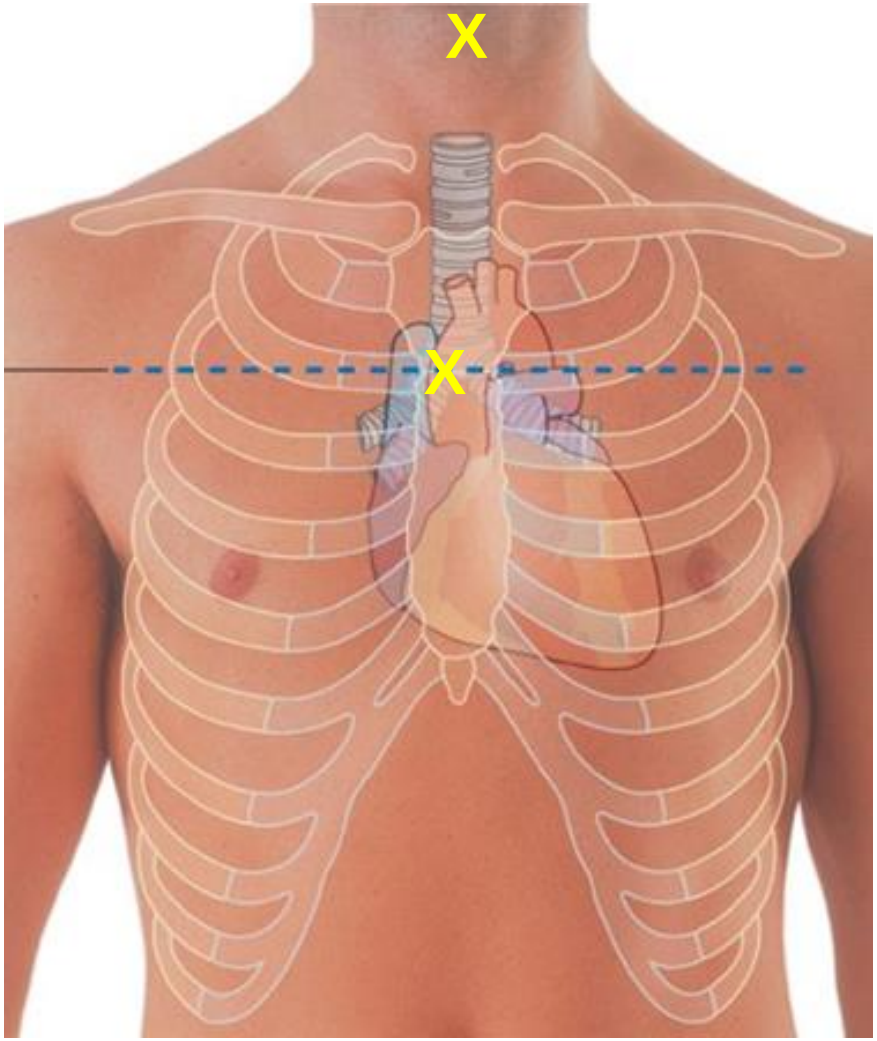

Sternal Angle

- Marks position of manubriosternal joint
- Posteriorly passes through intervertebral disc between T4 & T5
- Costal cartilage of 2nd rib articulates with sternum
- Superior mediastinum is separated from the inferior mediastinum

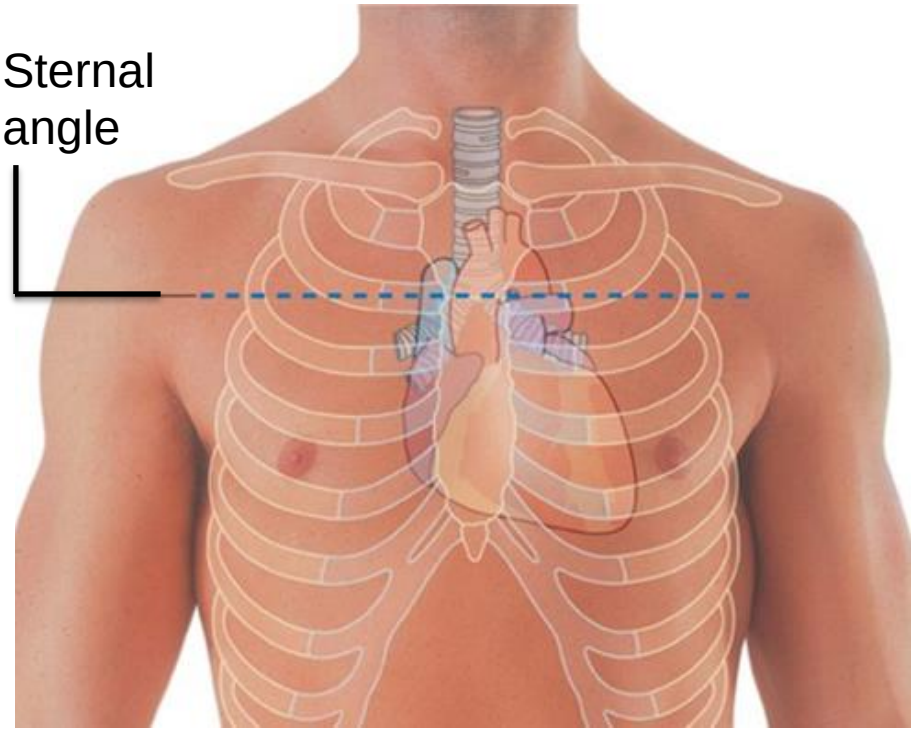

Sternal Angle

- Ascending aorta ends & arch of aorta begins
- Arch of aorta ends & thoracic aorta begins
- Pulmonary trunk divides into left & right pulmonary arteries
- Thoracic duct crosses from right to left
- Trachea bifurcates
- Azygous vein arches over right lung to open into superior vena cava

Heart Borders (continueus)

1. At lower border of 2nd left costal cartilage 1.3cm from sternal margin
2. At upper border of 3rd right costal cartilage 0.8cm from sternal margin
3. Lower border of 6th right costal cartilage 2cm from sternal margin
4. At the apex of the heart at left 5th intercostal space 9cm from midsternal line

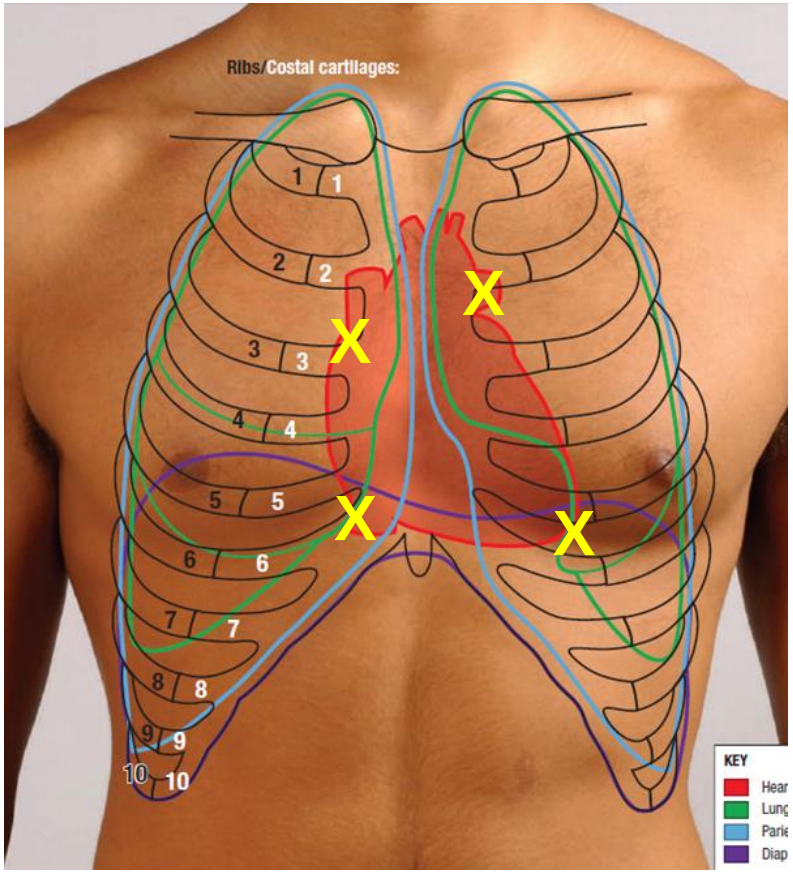

Heart Borders (continuation)

1. Upper border- join 1 & 2
2. Lower border- join 3 & 4
3. Right border- convex line joining 2 & 3 with a convexity at 3.8cm from median plane in 4th intercostal space
4. Left border- convex line joining 1 & 4

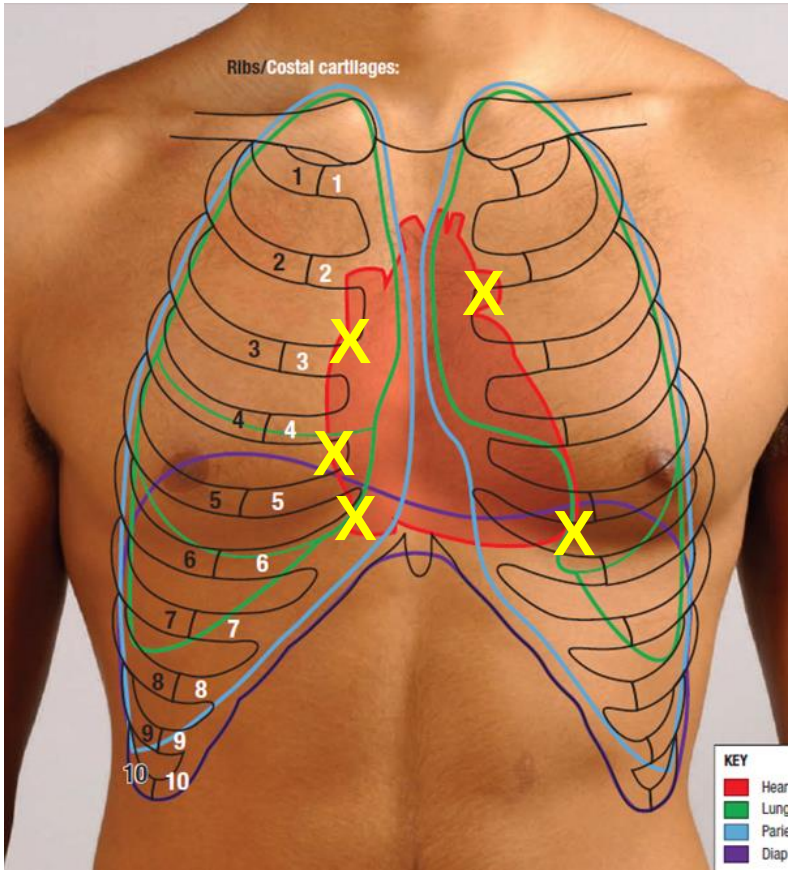

Heart Valves

- Pulmonary valve- a horizontal line 2.5cm long, behind upper border of 3rd left costal cartilage & adjoining part of sternum
- Aortic valve- a slightly oblique line 2.5cm long, behind left half of sternum at the level of lower border of left 3rd costal cartilage

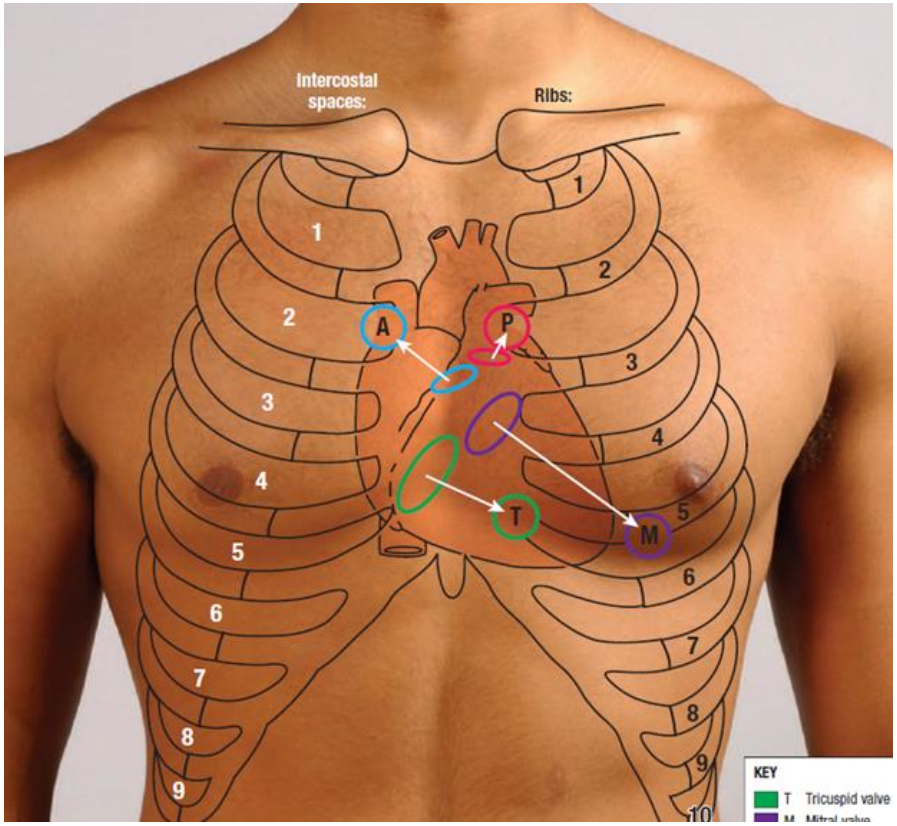

Heart Valves

- Mitral valve- an oblique line, 3cm long; behind left half of sternum opposite the left 4th costal cartilage
- Tricuspid valve- most oblique, being nearly vertical, 4cm long; behind right half of sternum opposite 4th & 5th intercostal spaces

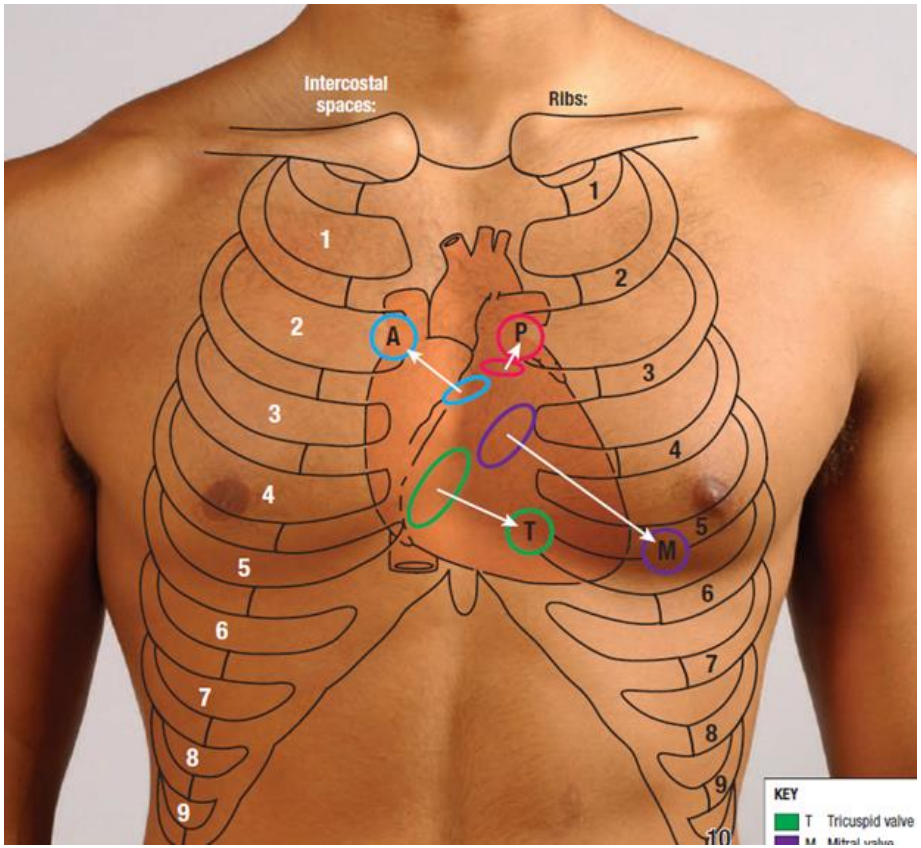

Heart Valve Auscultatory Area

- Pulmonary valve- 2nd left intercostal space near the sternum
- Aotic valve- 2nd right costal cartilage near the sternum
- Mitral valve- left 5th intercostal space 9cm from midsternal
- Tricuspid valve- left of the lower part of the sternum near the 5th intercostal space

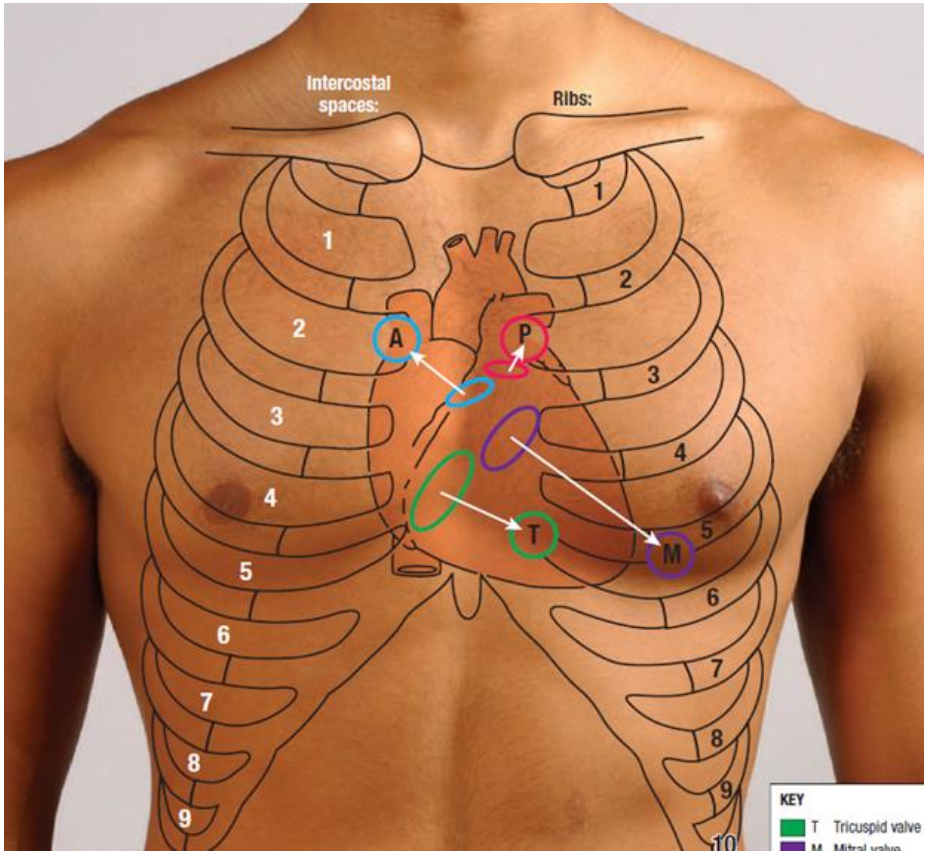

Cardiac Apex

- Left 5th intercostal space 9cm from the midsternal line

or

- Left 5th intercostal space at the midclavicular line

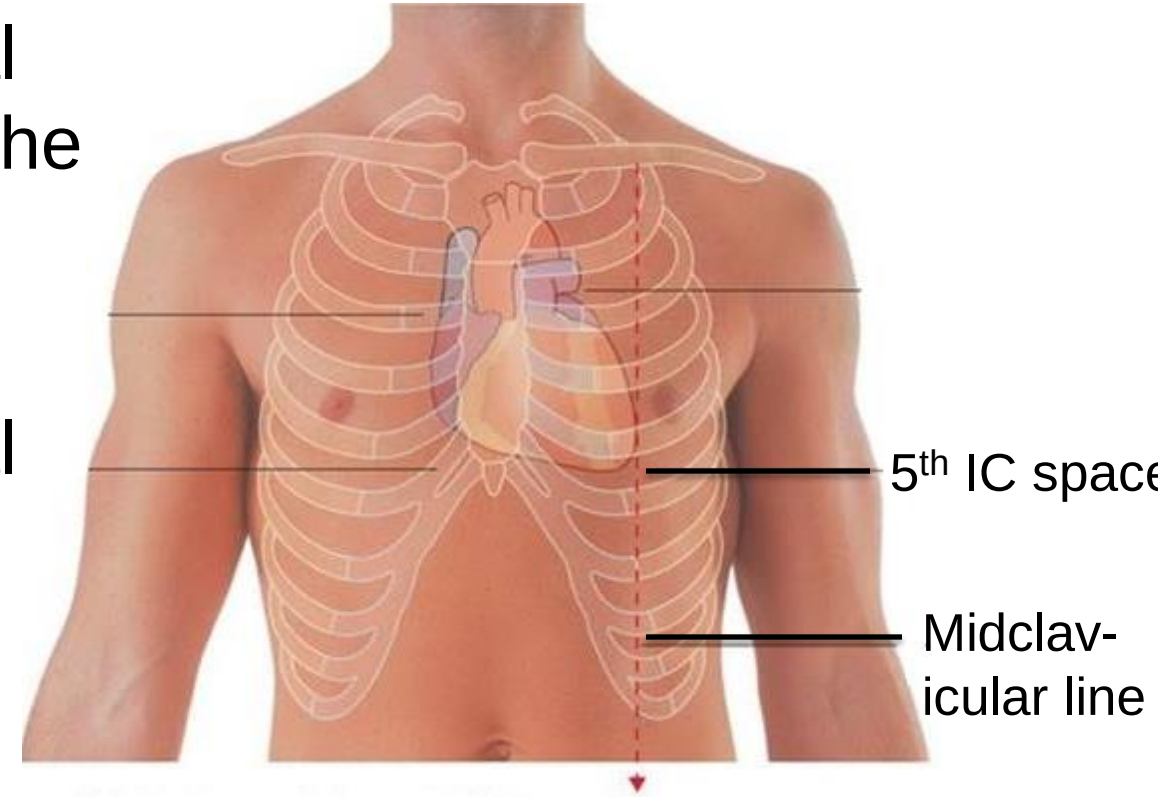

Cervical Pleura/ Apex of Lung

1. Mark the sternoclavicular joint
2. Mark the junction of medial and middle-third of clavicle
3. Put a point 2.5cm above the medial third of clavicle

Join by a curved line

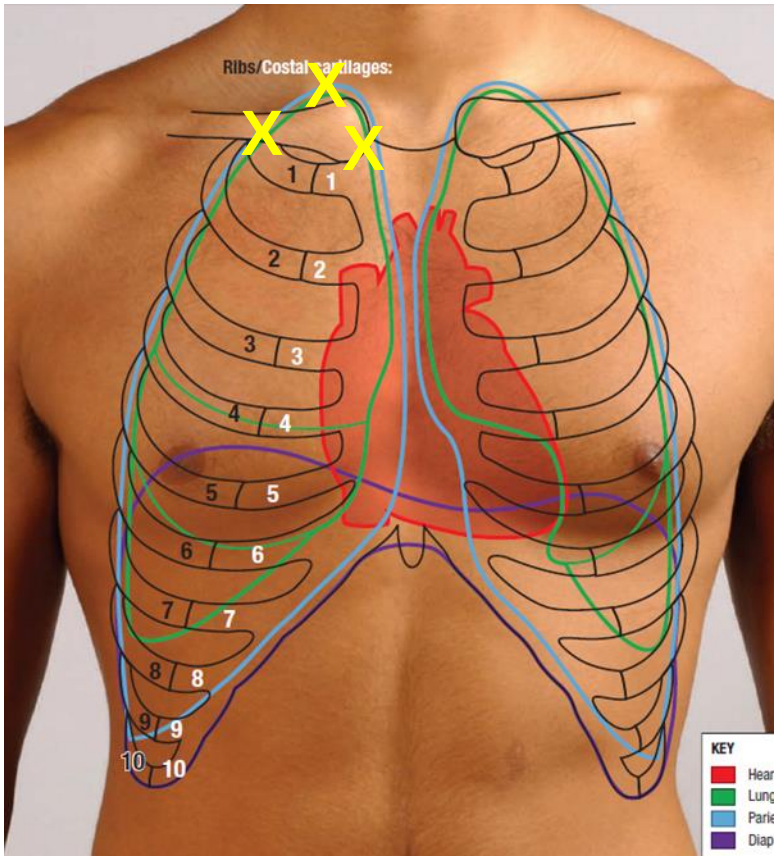

Right Pleura-Anterior Margin

Also called right costo-medeiastinal reflection

1. Right sternoclavicular joint
2. Midpoint of sternal angle
3. Xiphisternal joint

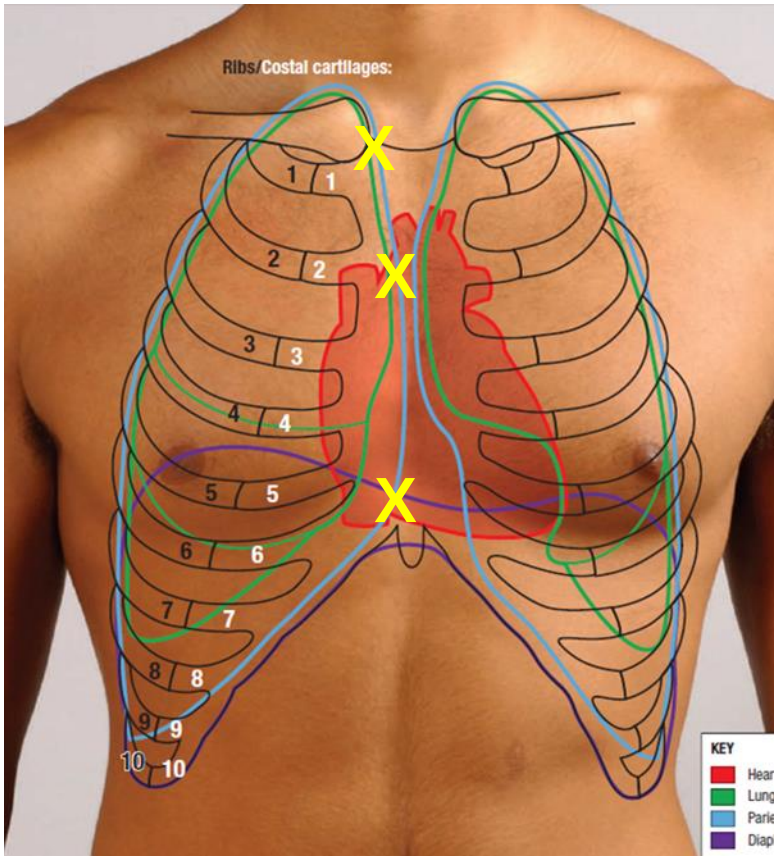

Left Pleura-Anterior Margin

Also called left costo-medeiastinal reflection

1 & 2 same as right side

3. Midline of sternum at level of 4th costal cartilage
4. Sternal margin at level of 6th costal cartilage

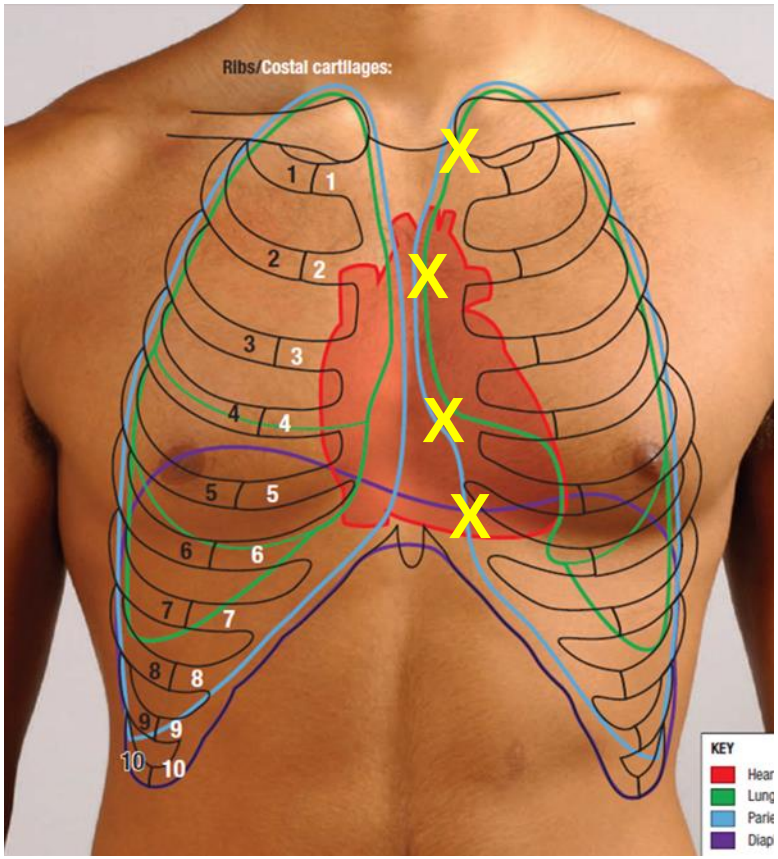

Pleura- Inferior Margin

Also called costo-diaphragmatic reflection

1. 8th rib at midclavicular line
2. 10th rib at midaxillary line
3. 12th rib at lateral border of sacrospinalis
4. 2cm lateral to 12th thoracic spine

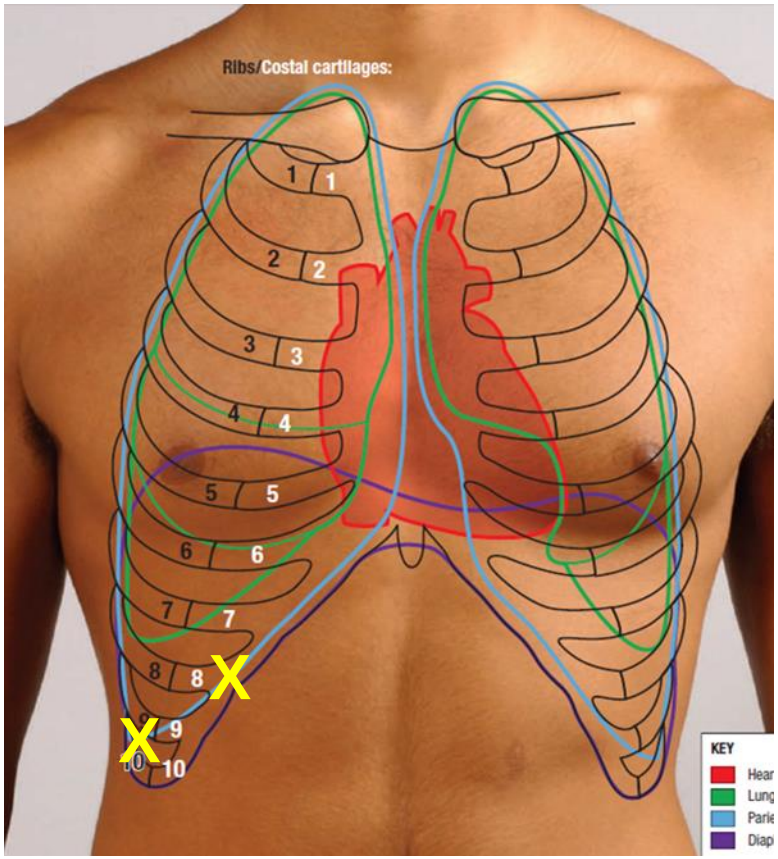

Pleura- Posterior Margin

- 2cm lateral to 12th thoracic spine
- 2cm lateral to 7th cervical spine

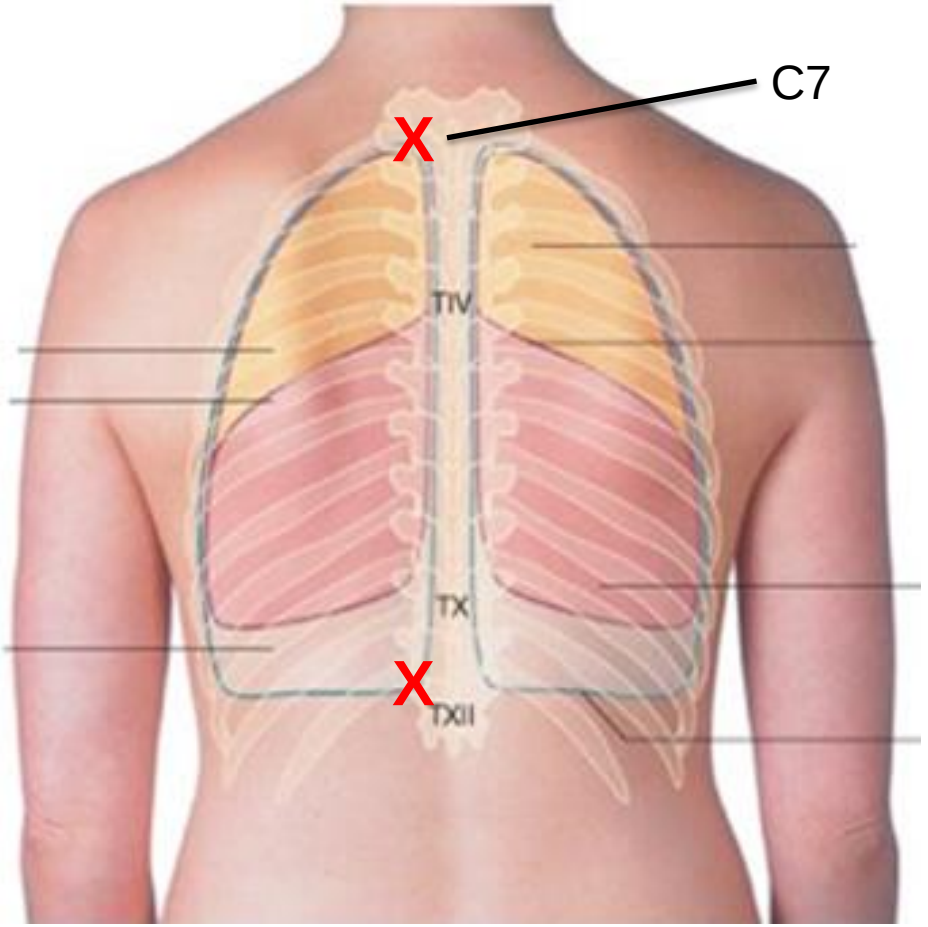

Right Lung-Anterior Border

1. Right sternoclavicular joint
2. Midpoint of sternal angle
3. 6th right costochondral junction

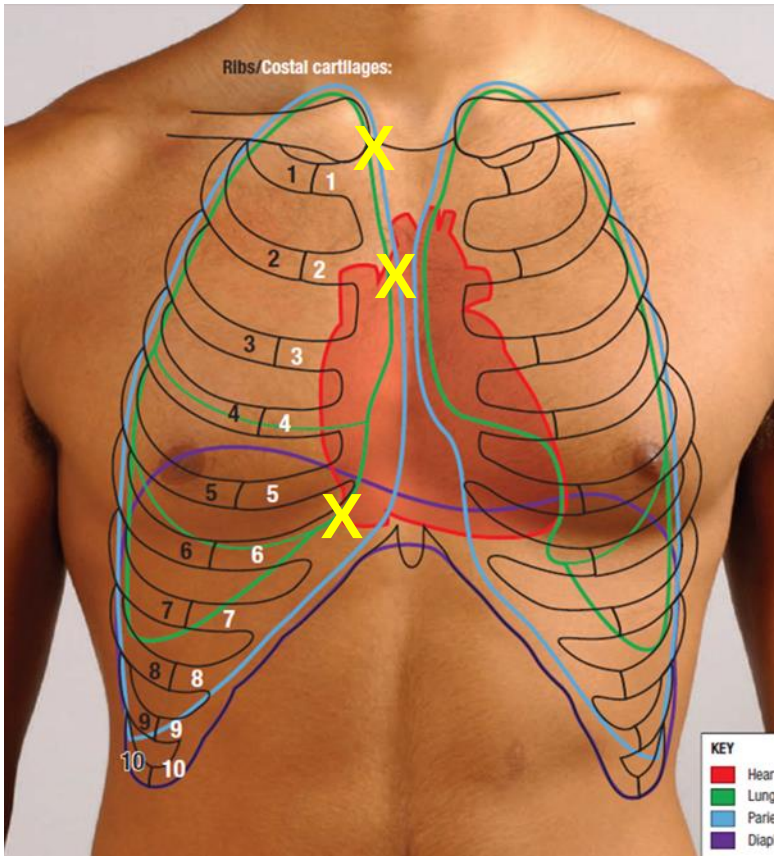

Left Lung-Anterior Border

1 & 2 same as right side

3. 3.5cm from sternal margin at level of 4th costal cartilage
4. 6th costal cartilage 4cm from the midline

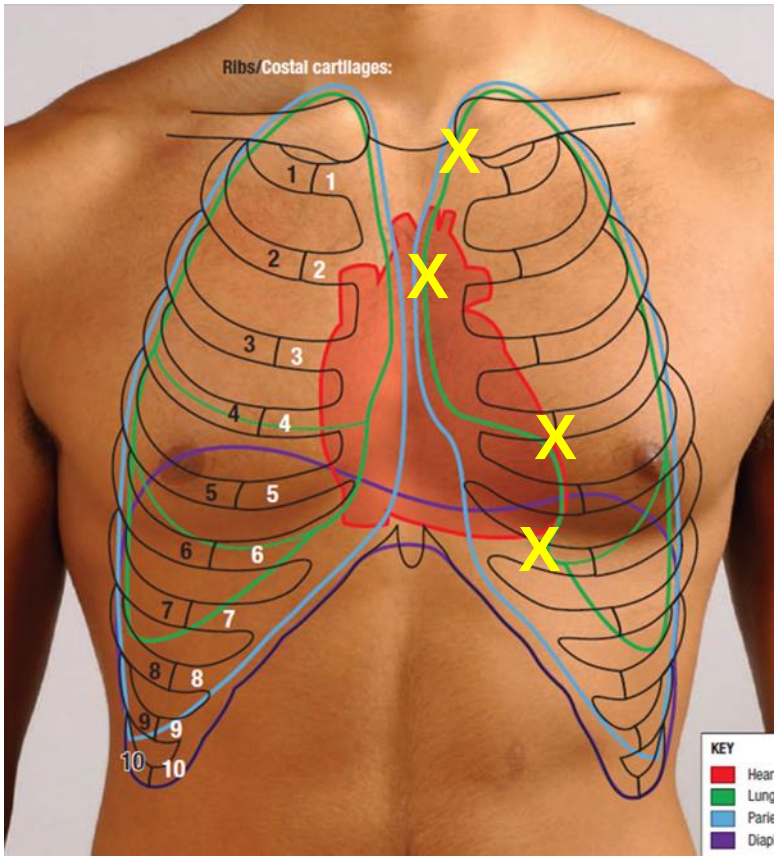

Lung- Inferior Border

1. 6th rib at midclavicular line
2. 8th rib at midaxillary line
3. 10th rib at lateral border of sacrospinalis
4. 2cm lateral to 10th thoracic spine

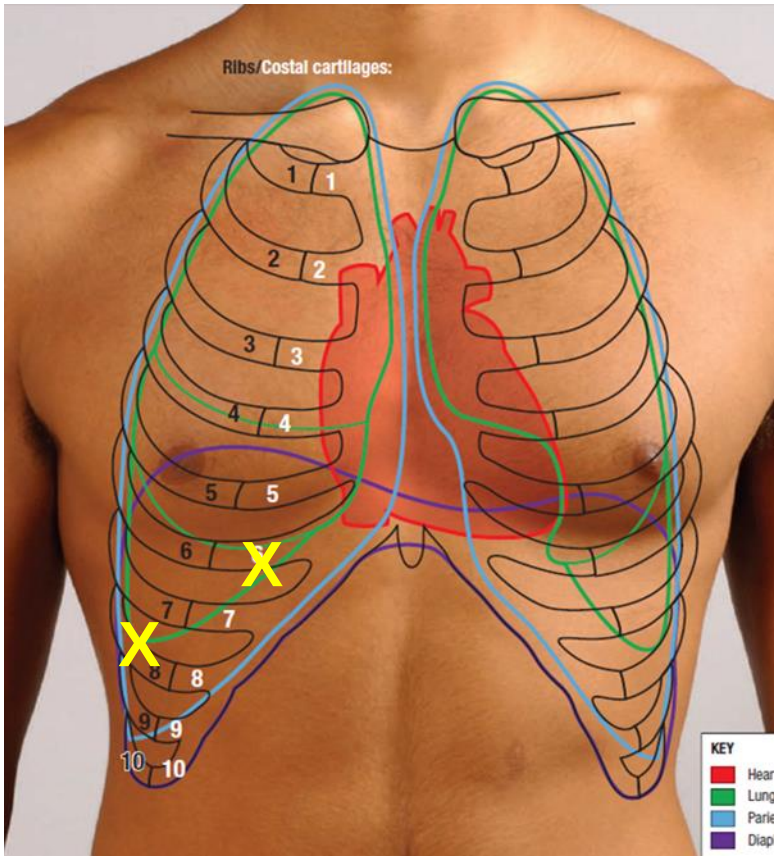

Lung- Posterior Border

- 2cm lateral to 10th thoracic spine
- 2cm lateral to 7th cervical spine

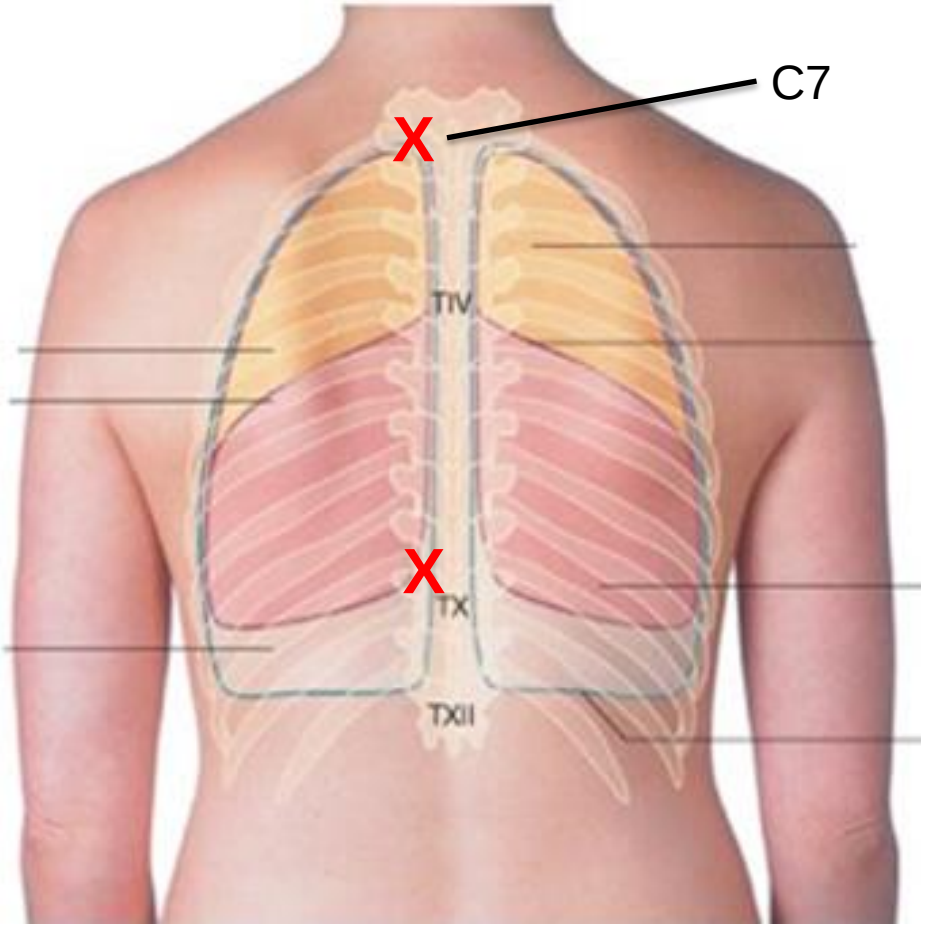

Fissures of Lung

Oblique fissure

1. Spine of T4
2. 5th intercostal space at midclavicular line
3. 6th costal cartilage 7.5cm from midline

Horizontal fissure

1. 5th intercostal space at midclavicular line
2. Anterior border of right lung at 4th costal cartilage

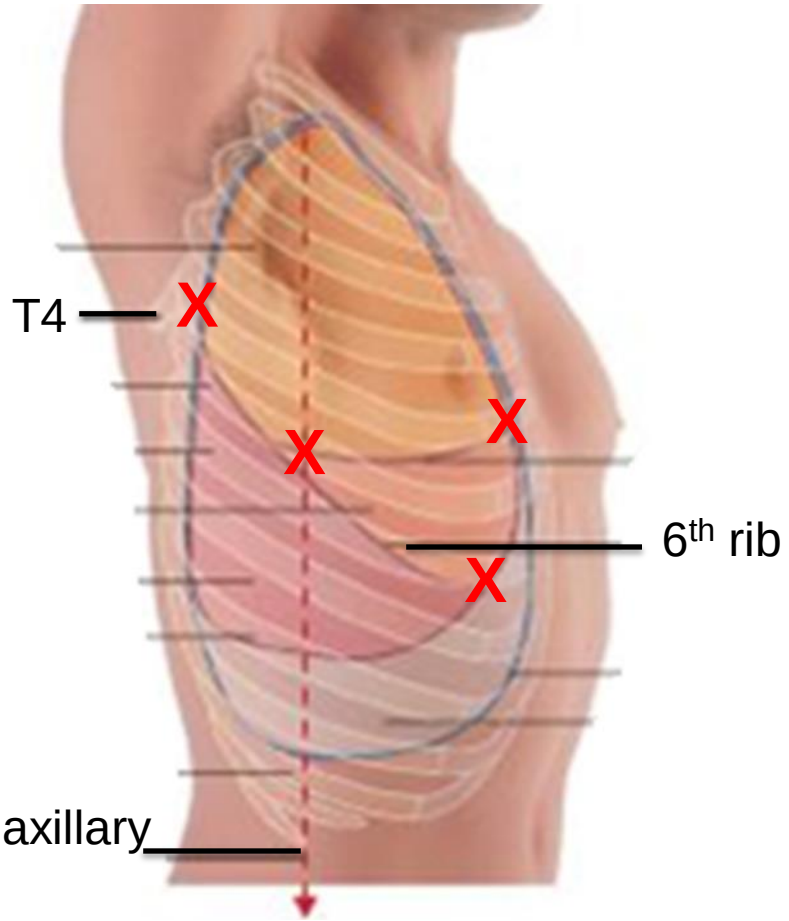

Abdomen

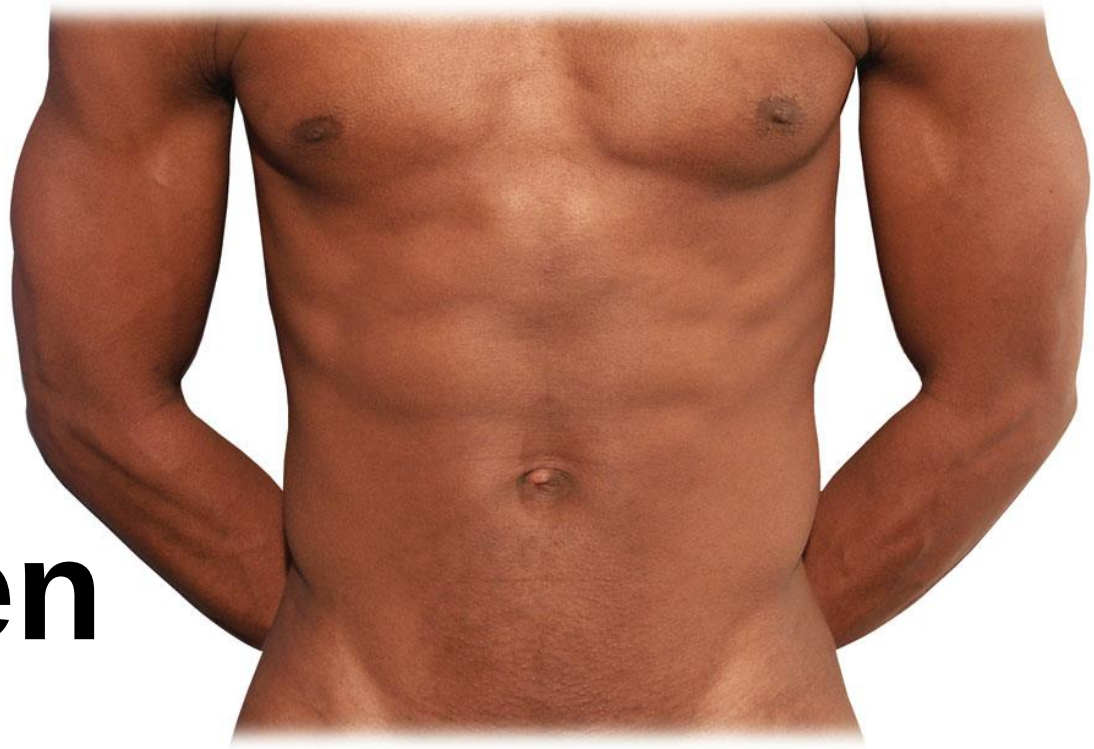

Abdominal Planes

- Transpyloric plane- crosses tips of 9th costal cartilage & lower border of body of L1 vertebra
- Transtubercular plane- passes through tubercles of iliac crest & upper border of body of L5 vertebra
- Right & left midclavicular planes pass through midinguinal point & crosses tip of 9th costal cartilage

Abdominal Planes & Regions

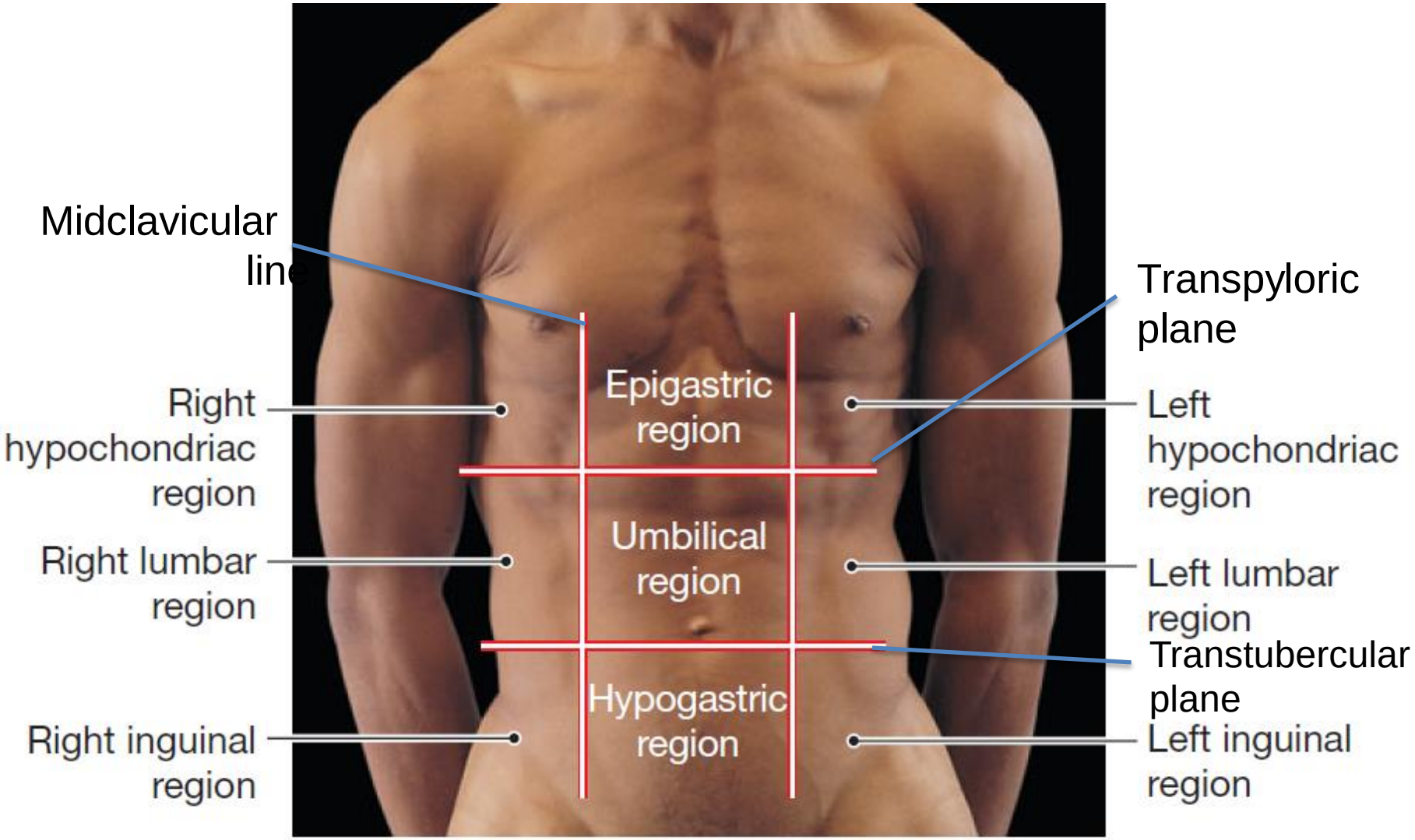

Location of Abdominal Organs

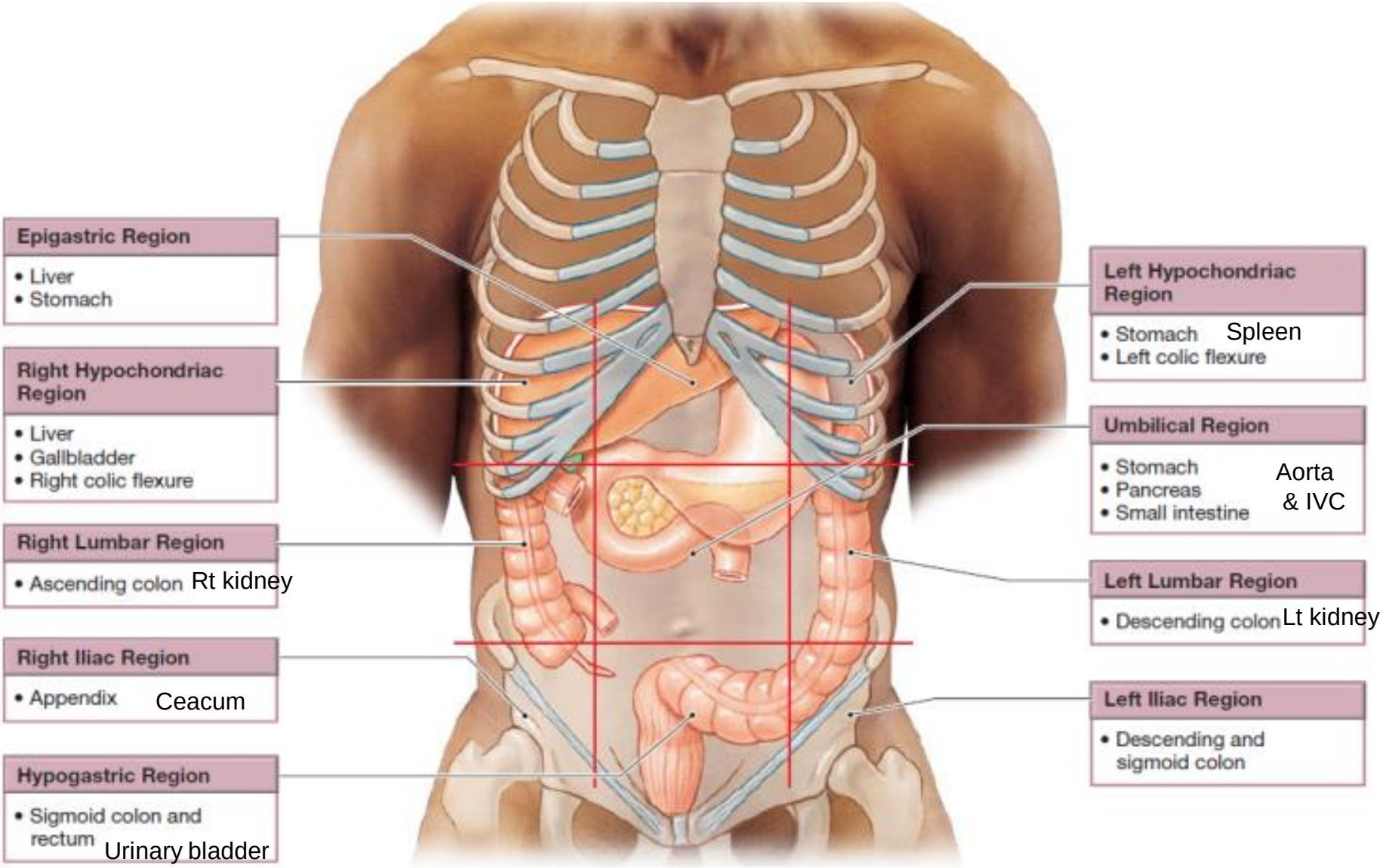

Transpyloric Plane

It is indicated by:

- A line midway between jugular notch & pubic symphysis (or)
- A line midway between umbilicus & xiphisternal joint (or)
- It crosses tips of 9th costalcartilage & lowerborder of L1

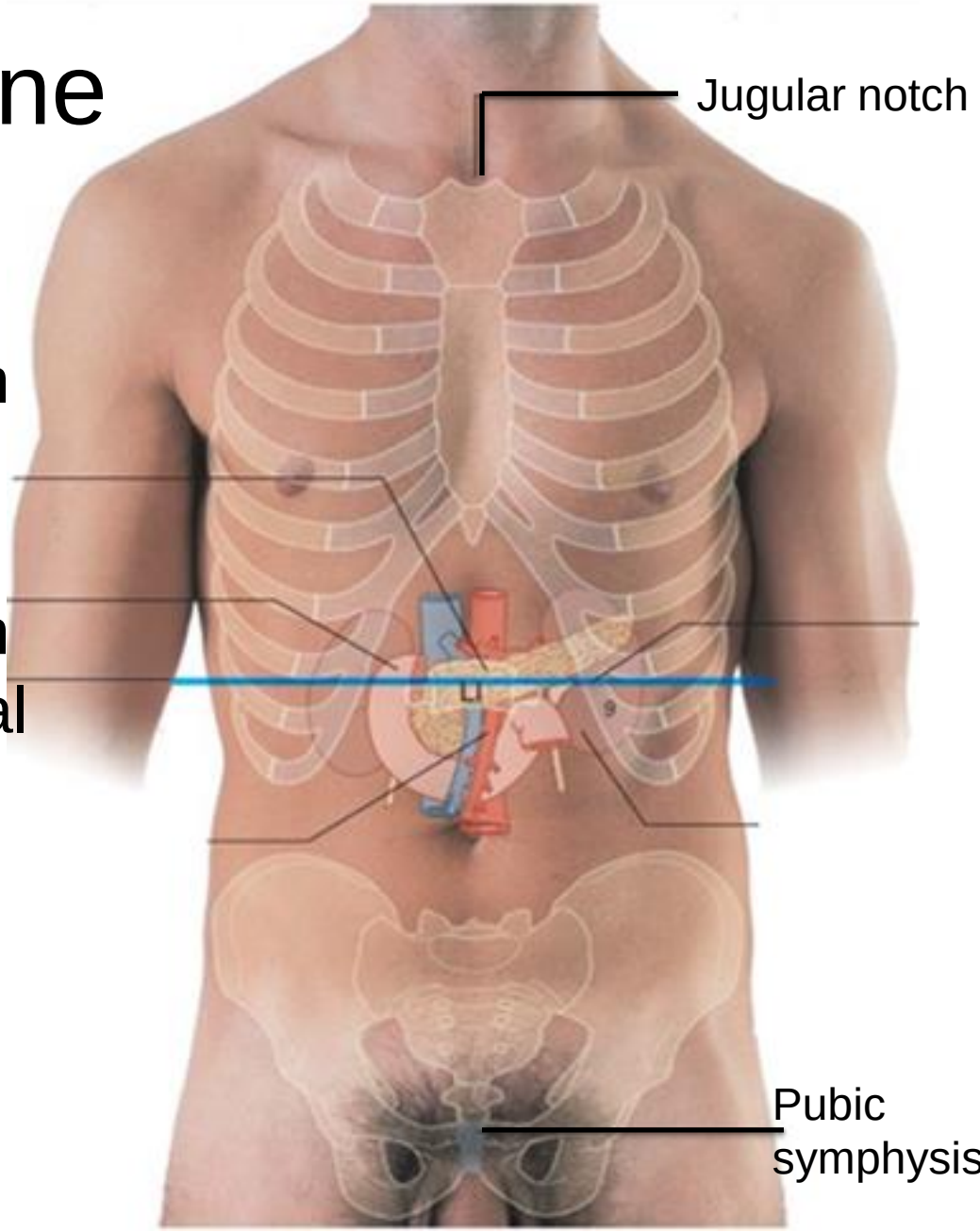

Transpyloric Plane

Passes through-

1. Pylorus of stomach
2. Beginning of duodenum
3. Fundus of gall bladder
4. Hilum of kidneys
5. Neck of pancreas
6. Anterior end of spleen
7. Termination of spinal cord
8. Beginning of thoracic duct
9. Origin of superior mesenteric artery
10. Origin of portal vein

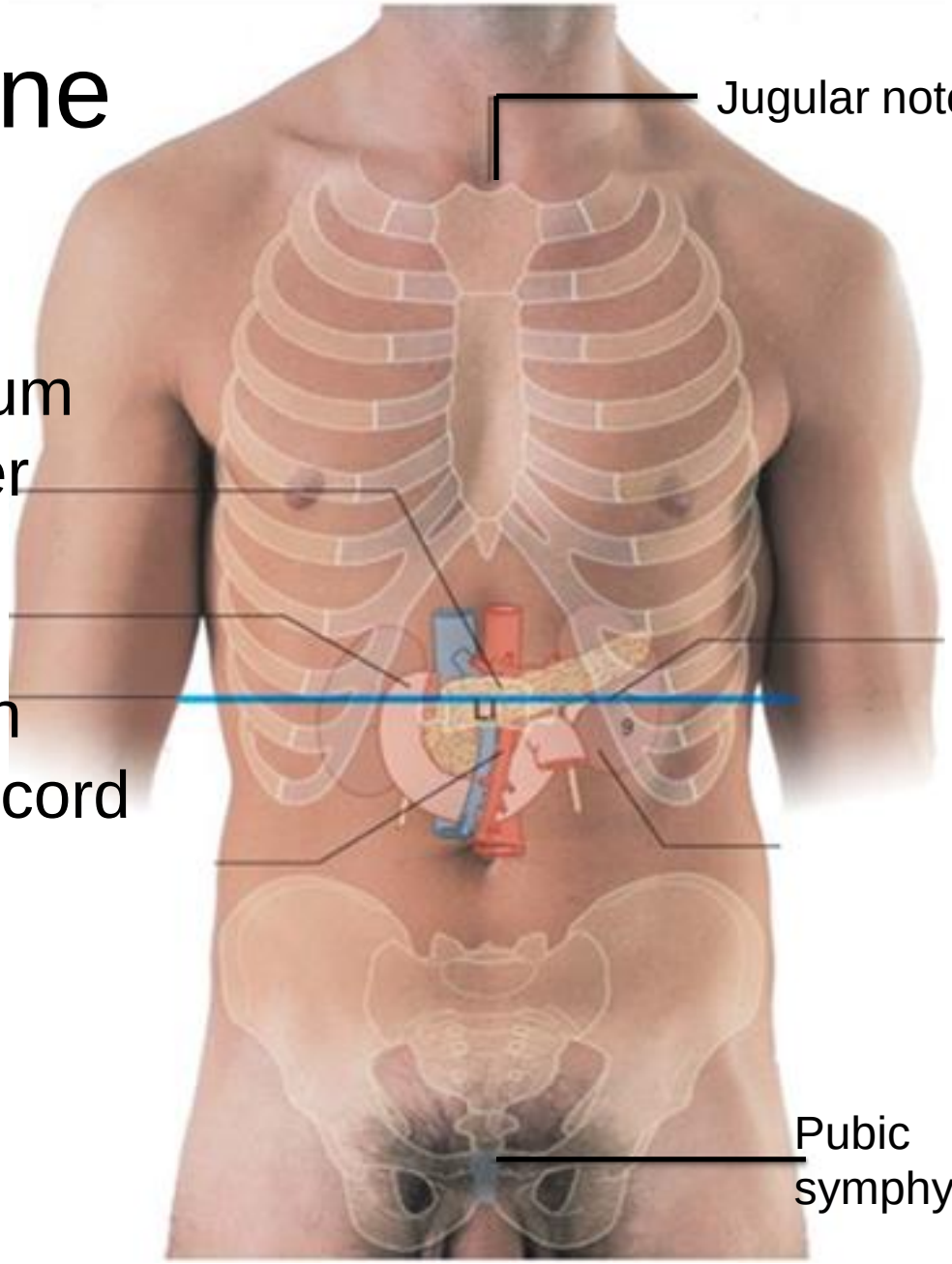

Stomach- Orifices

- *Cardiac orifice*- 2.5cm to the left of median plane on the 7th costal cartilage. Draw two parallel lines 2cm apart directed downward & to the left
- *Pyloric orifice*- on the transpyloric plane, 1.2cm lateral to the median plane. Draw two parallel lines directed upward & to the right

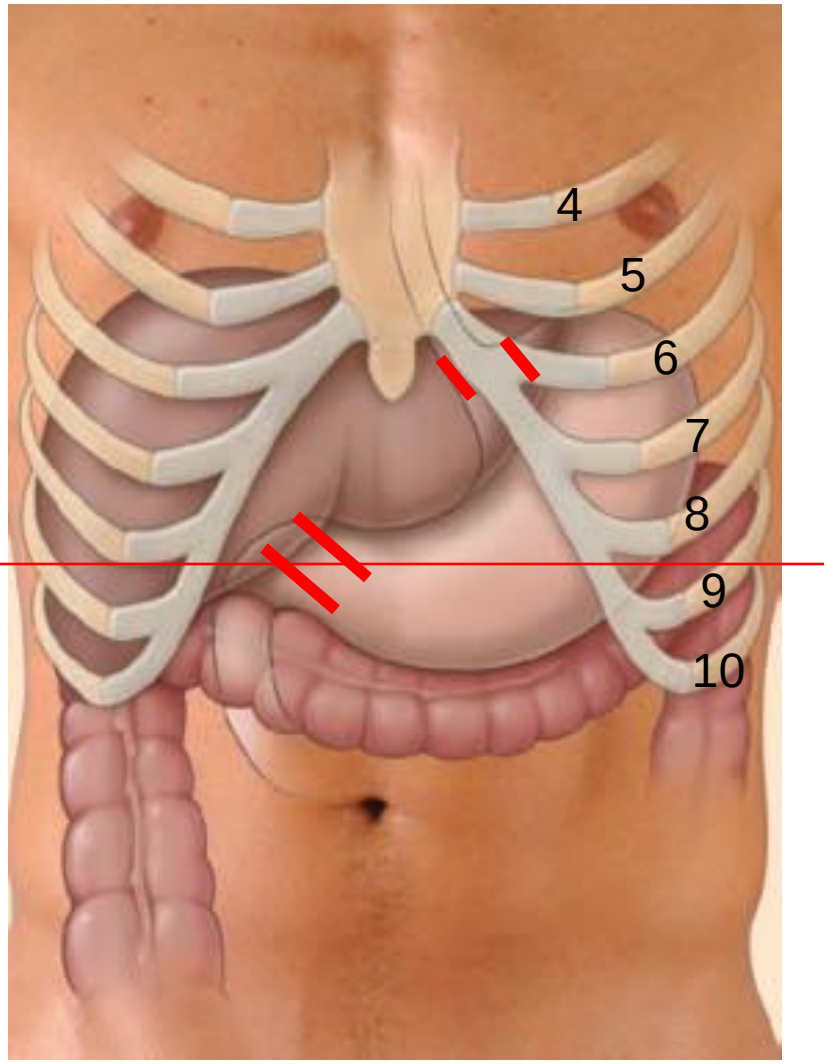

Stomach- Curvatures & Fundus

- Lesser curvature- join right margin of pyloric orifice with upper margin of pyloric orifice by a J-shaped curve. The lowest point reaching transpyloric plane
- Fundus- left 5th intercostal space just below nipple
- Greater curvature- fundus to lower margin of pyloric orifice. It cuts left costal margin between 9th & 10th costal cartilage & extends down to subcostal plane

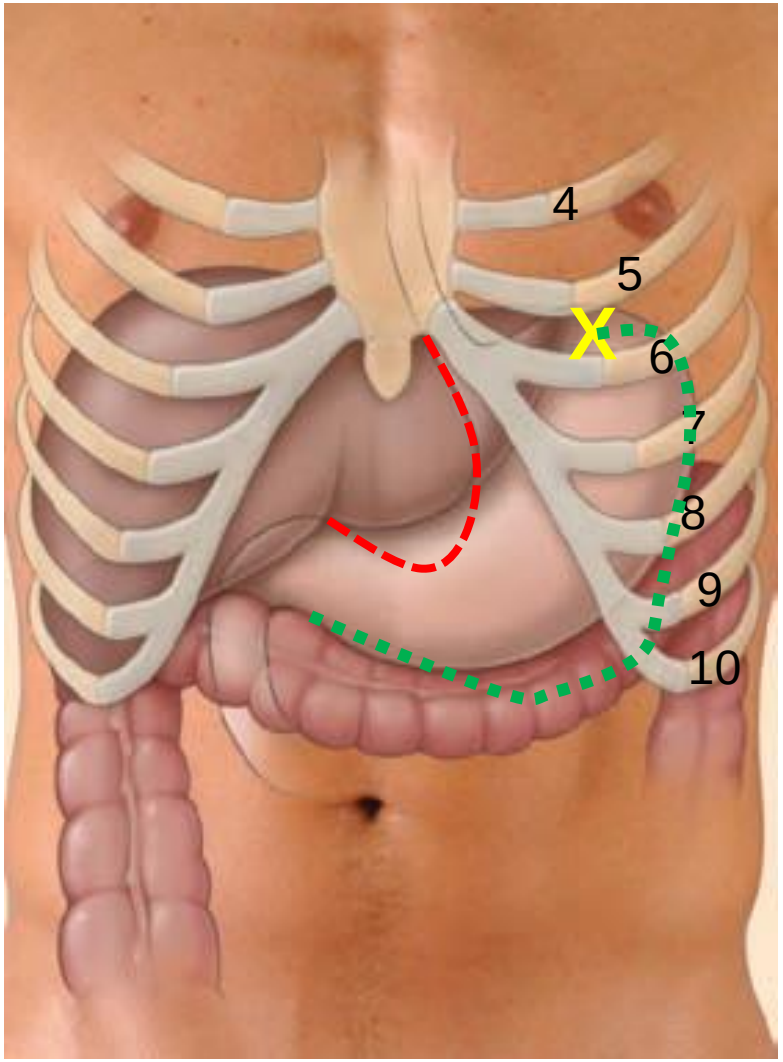

Liver- Inferior Border

1. Left 5th intercostal space below & medial to left nipple
2. Tip of 8th costal cartilage on the costal margin
3. On the transpyloric plane in the midline
4. Tip of 9th costal cartilage on the right costal margin
5. 1cm below right costal margin at tip of 10th costal cartilage

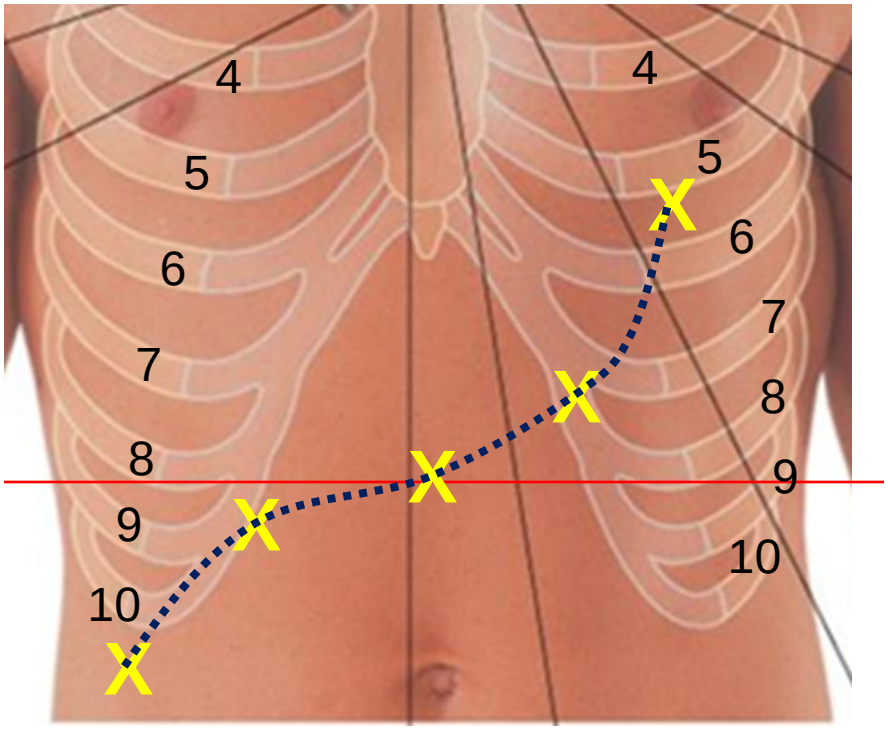

Liver- Superior & Right Border

Superior border

1. Left 5th intercostal space below & medial to left nipple
2. Xiphisternal joint
3. Below the right nipple

Right border

1. Same as 3
2. 1cm below right costal margin at tip of 10th costal cartilage

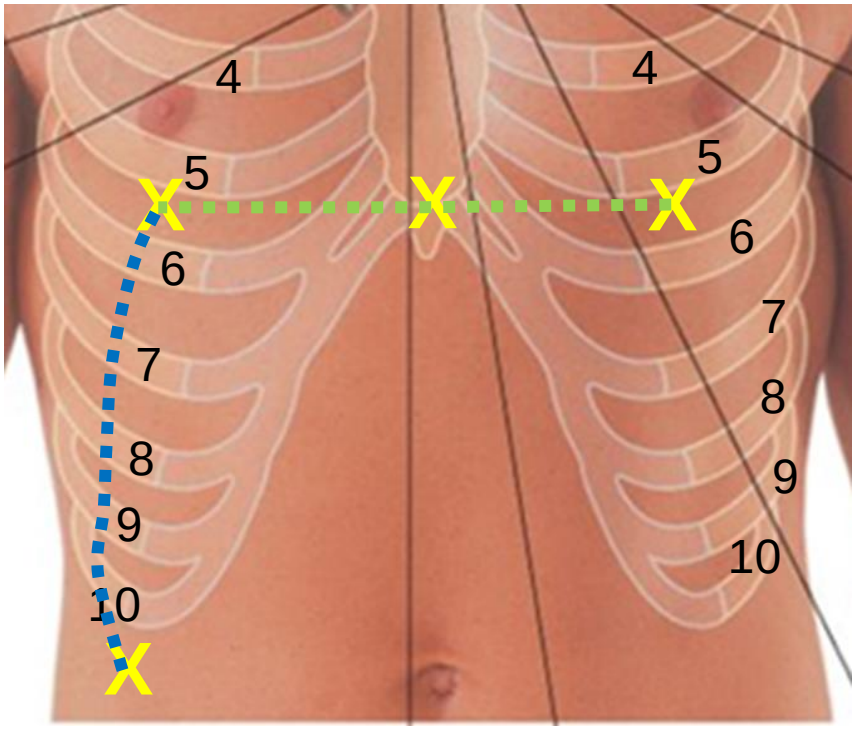

Gall Bladder- Fundus

1. Small convex area at the tip of right 9th costal cartilage

OR

2. Angle between right costal margin and linea semilunaris

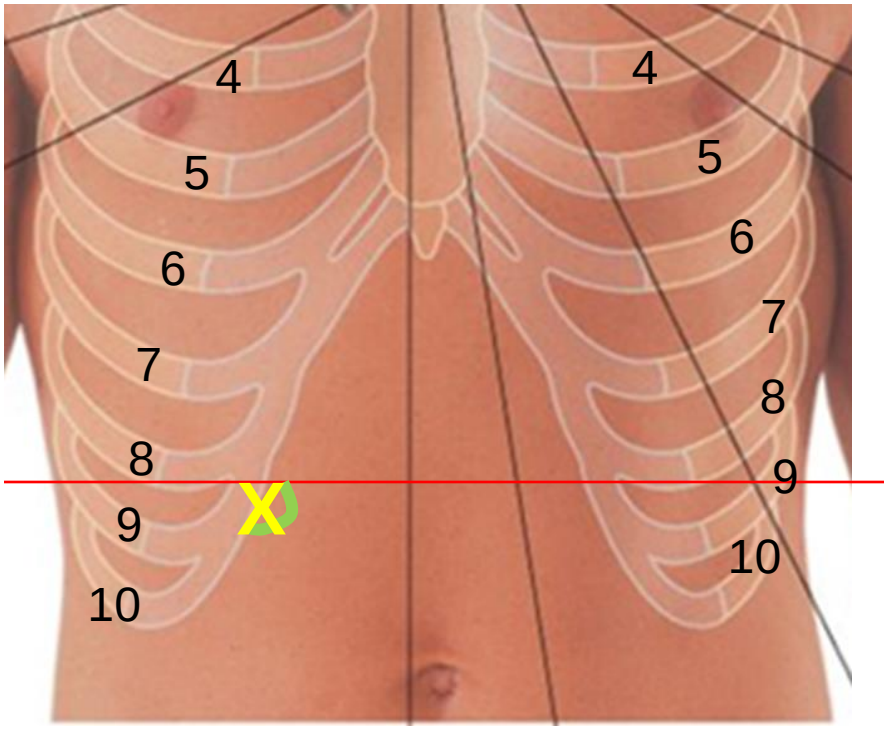

Also called as Murphy's Point

Base of Appendix

1. Mark the intersection of right lateral line and transtubercular plane
2. Base of the appendix is situated 2cm below this intersection

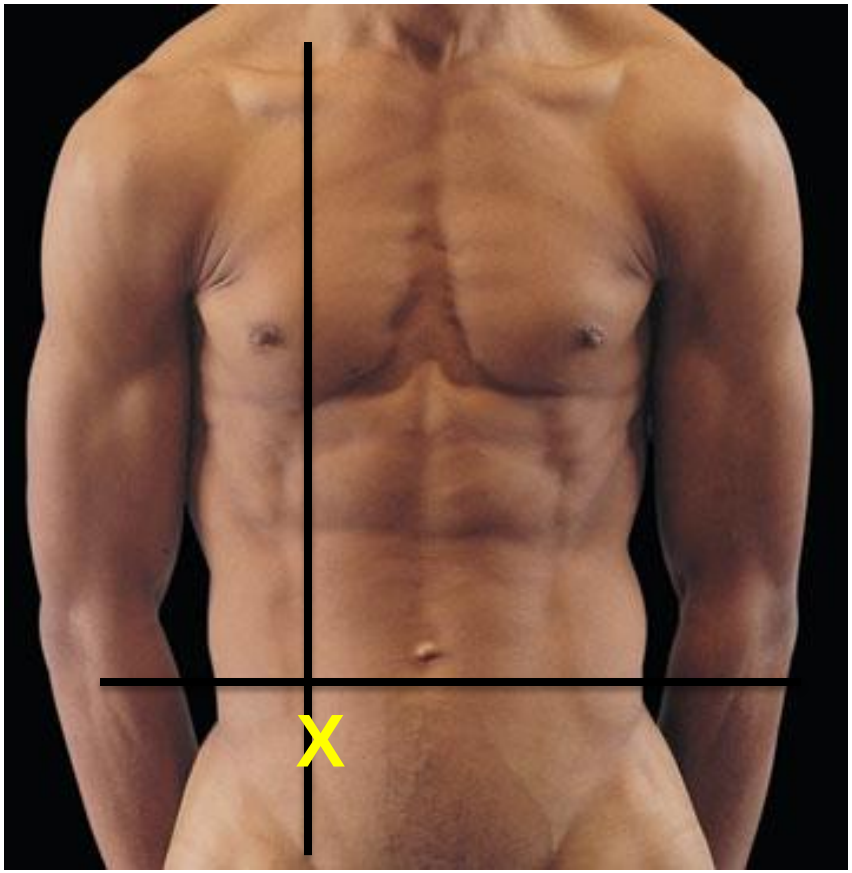

Mc Burney's Point

1. Draw a line from right ASIS to umbilicus
2. Mark the junction of outer and middle third of this line

This is the site of maximum tenderness in case of appendicitis



Root of Mesentery

1. 1cm below transpyloric plane & 3cm lateral to the left of median plane
2. Intersection of right lateral line and transtubercular plane

Join the above

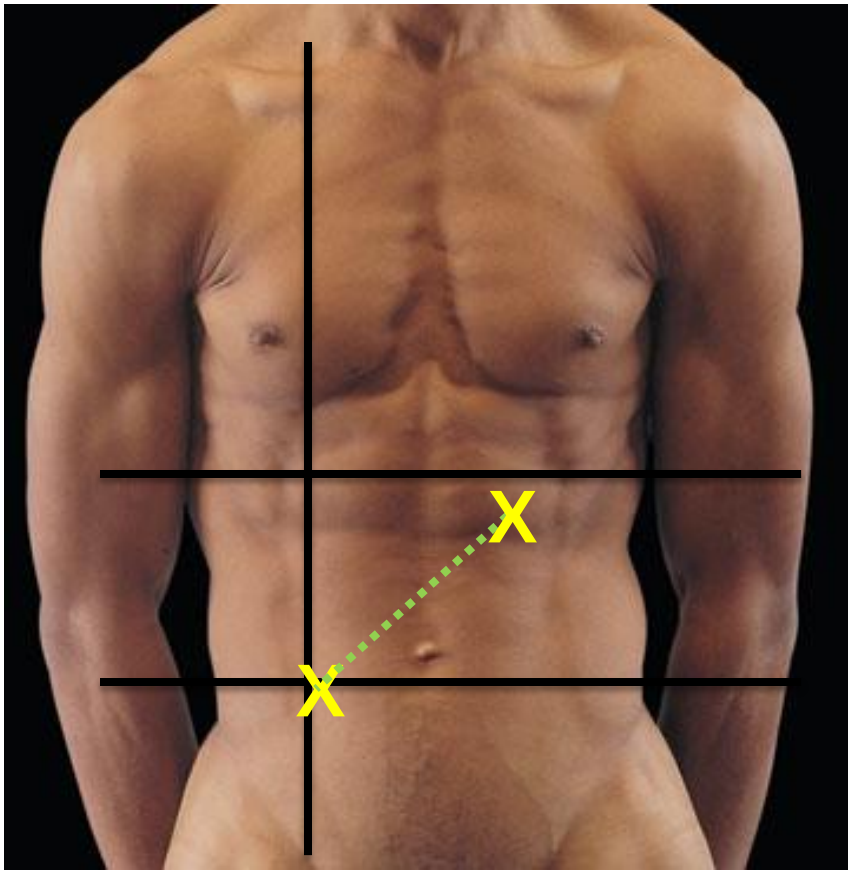

Spleen

- Medial end- 4cm lateral to T10 spine on left side
- Lateral end- left midaxillary line at 10th rib
- Upper border- upper border of 9th rib
- Lower border- lower border of 11th rib

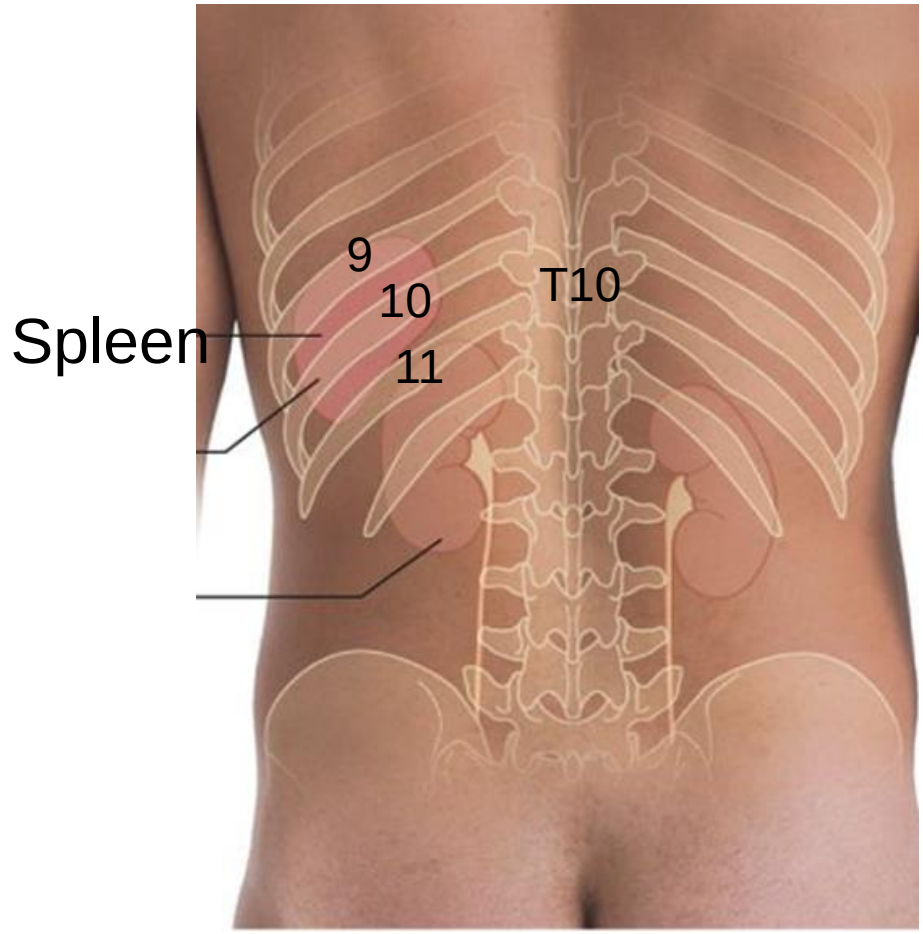

Kidney- on the Back

Map Morrison's parallelogram by:

1. Draw two horizontal lines at T11 & L3 spines
2. Draw two vertical lines 2.5cm & 9.5cm apart from medial plane
3. Mark hilum at level of lower border of L1

Upper poles are nearer & lower poles are farther from the median plane

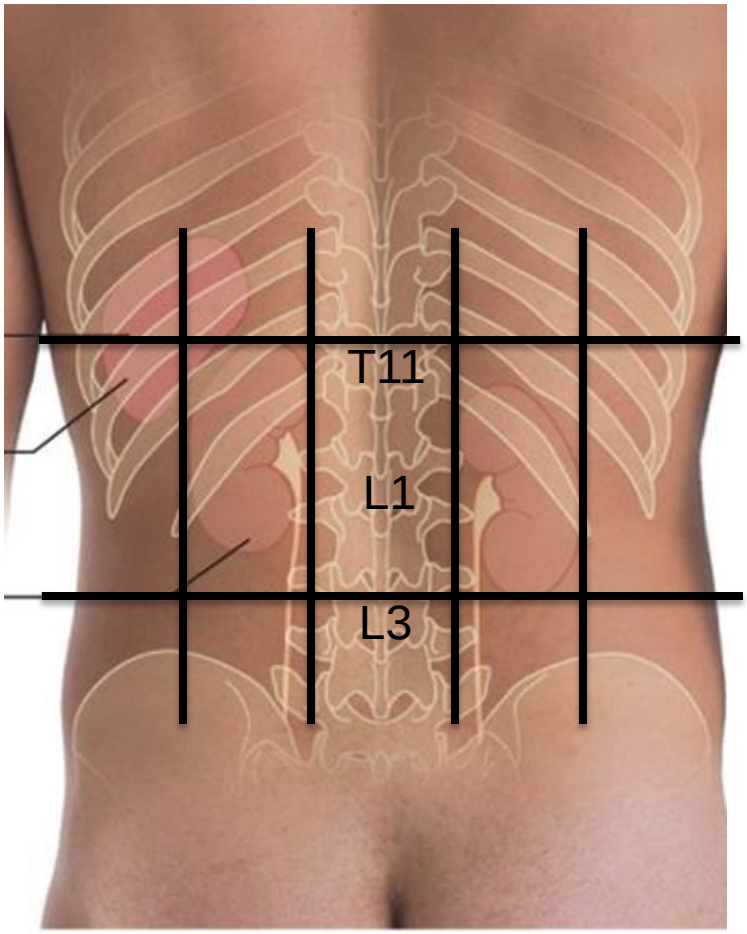

Abdominal Aorta

1. 2.5cm above transpyloric plane in the median plane
2. 1.2cm below and to the left of umbilicus (level of L4)

Join these by two parallel lines 2cm apart

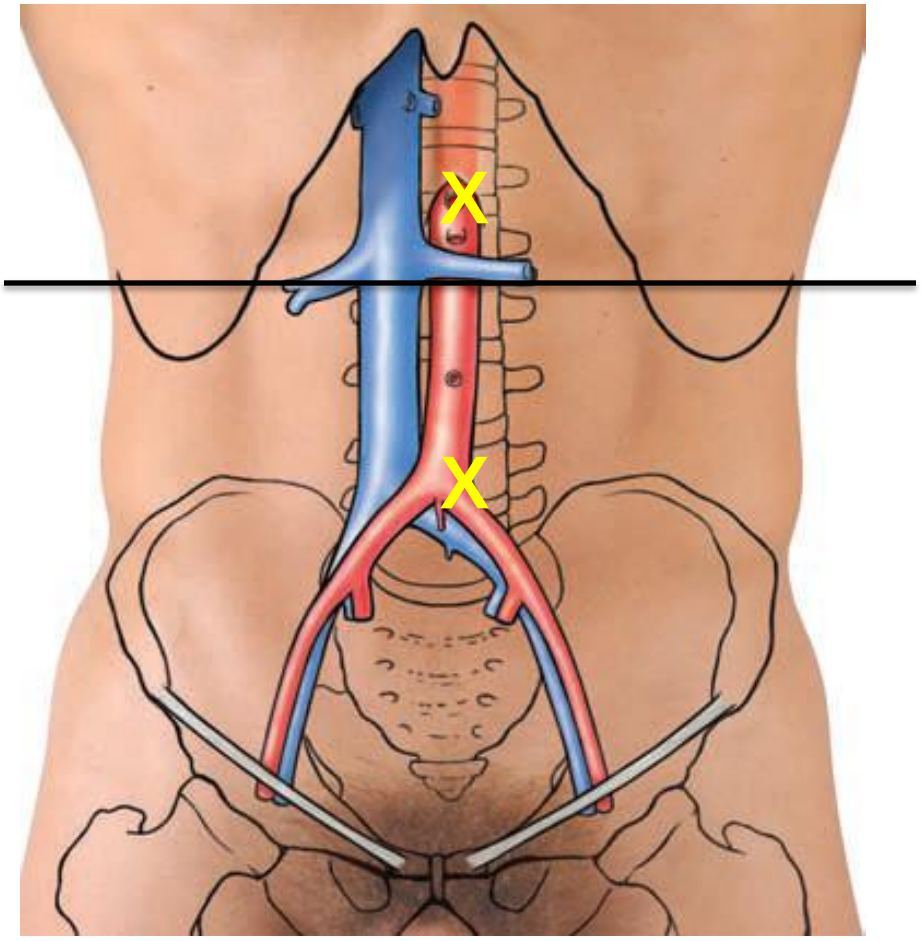

Inferior Vena Cava

1. Mark a point just below transtubercular plane and 2.5cm from the median plane
2. Sternal end of right 6th costal cartilage

Draw two vertical lines 2.5cm joining the above

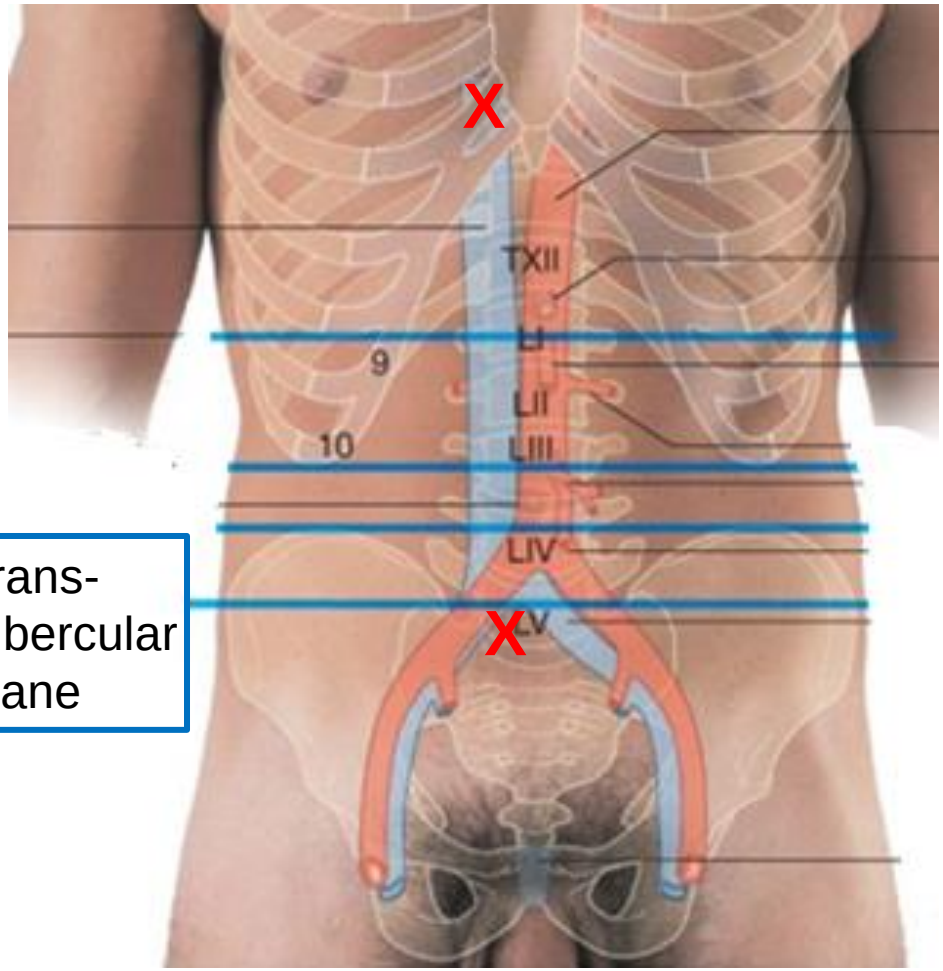

Inguinal Canal

1. *Deep inguinal ring(DIR)*- 1cm above midinguinal point (midway between ASIS & pubic symphysis)
2. *Superficial ingiunal ring (SIR)*- above & lateral to pubic tubercle

Join the above by two parallel lines 1cm apart and 3.7cm long

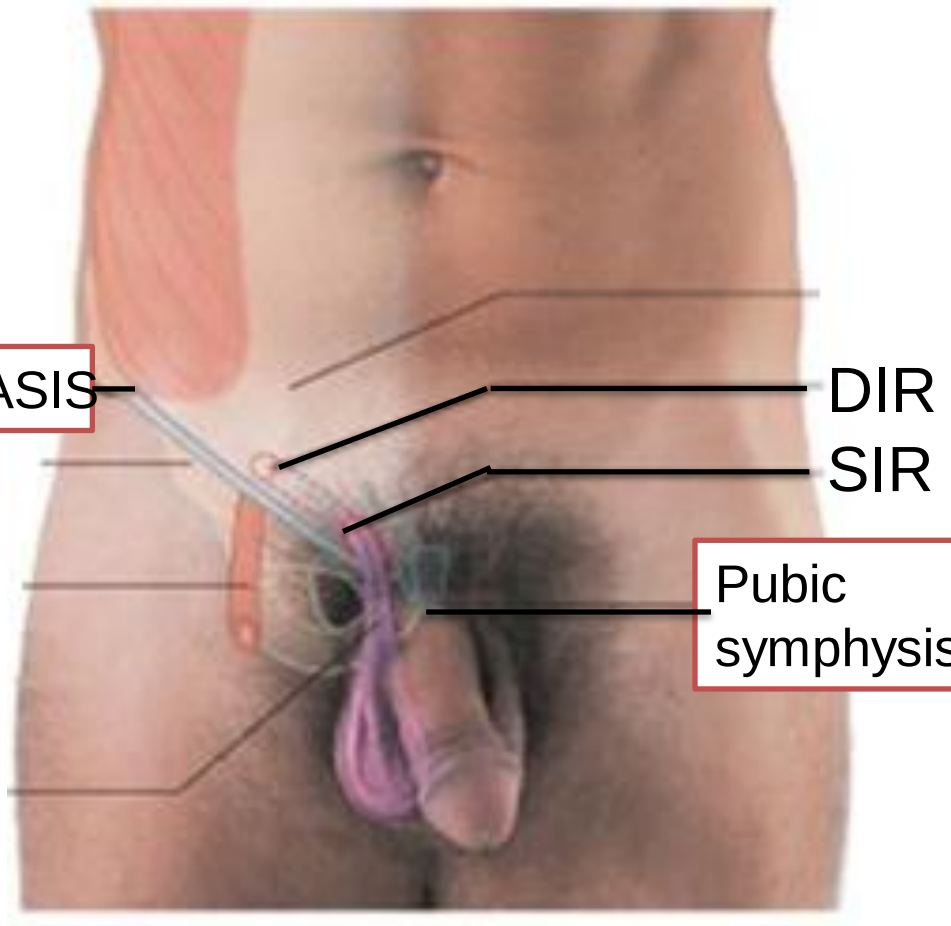

Head & Neck

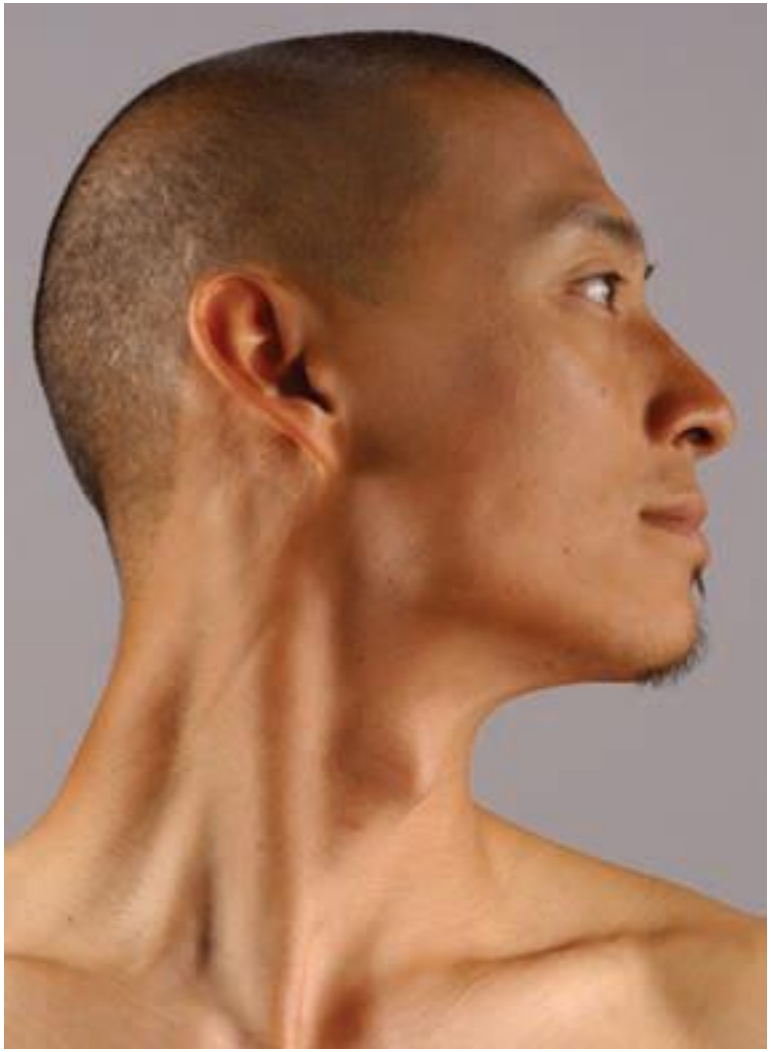

C4 Vertebral Level

- Upper margin of thyroid cartilage
- Bifurcation of common carotid artery

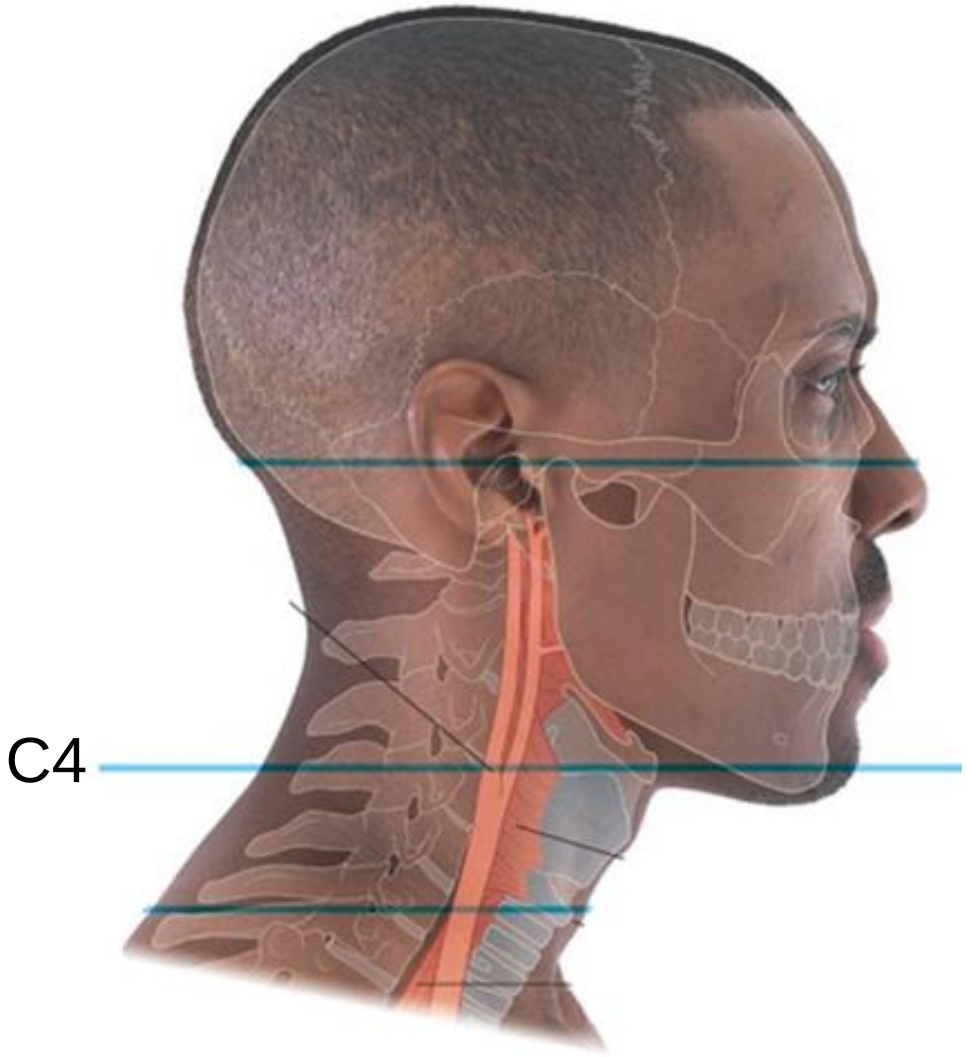

C6 Vertebral Level

- Arch of cricoid cartilage
- Transition from pharynx to esophagus
- Transition larynx to trachea

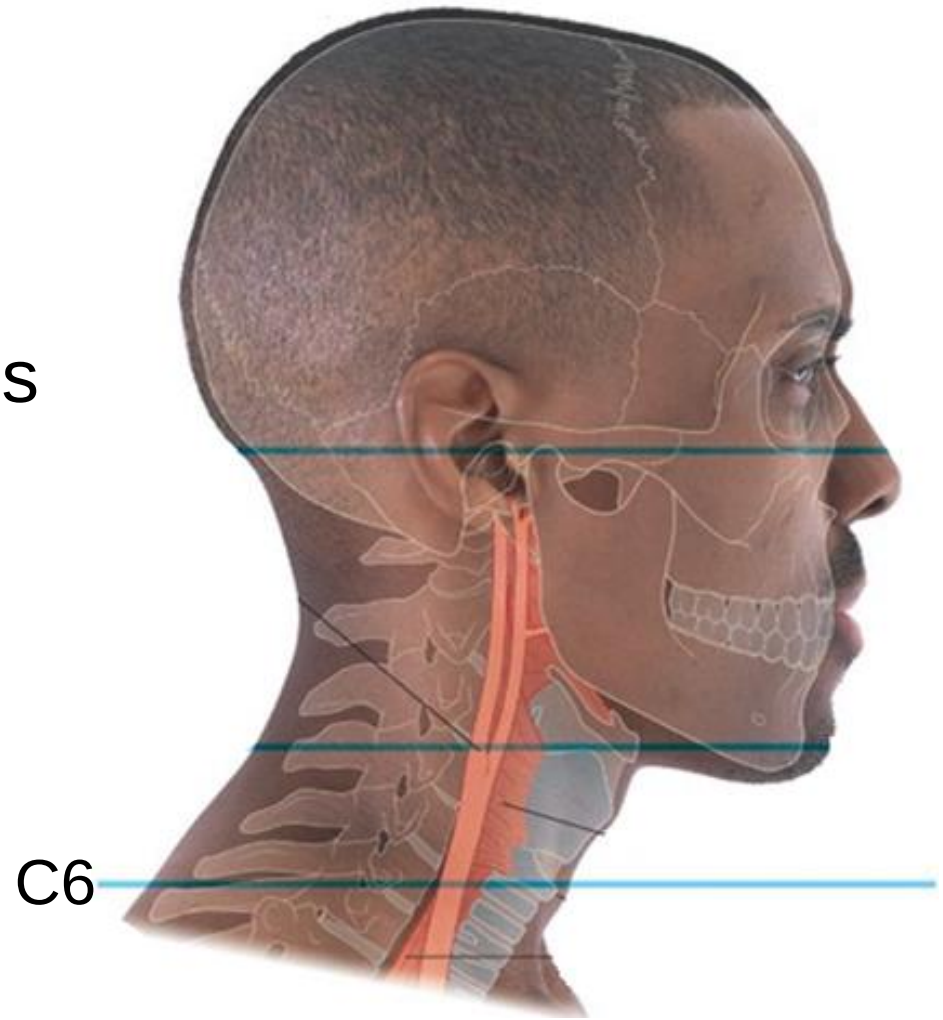

Common Carotid Artery

1. Sternoclavicular joint
2. Anterior border of sternocleidomastoid at the level of upper border of thyroid cartilage

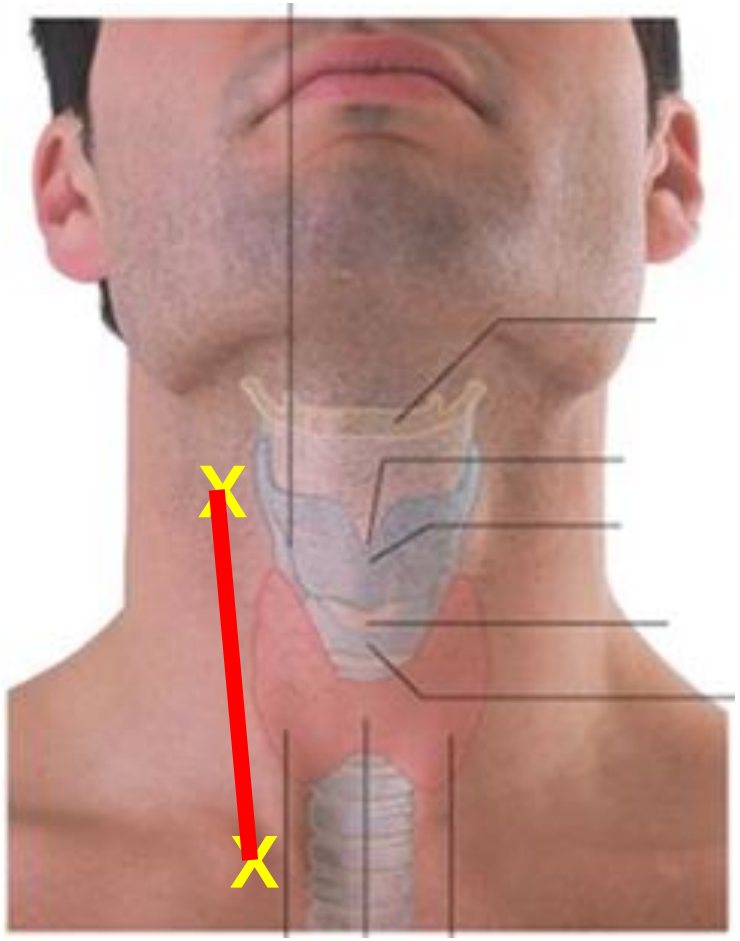

External Carotid Artery

1. Anterior border of sternocleidomastoid at the level of upper border of thyroid cartilage
2. Posterior border of neck of mandible

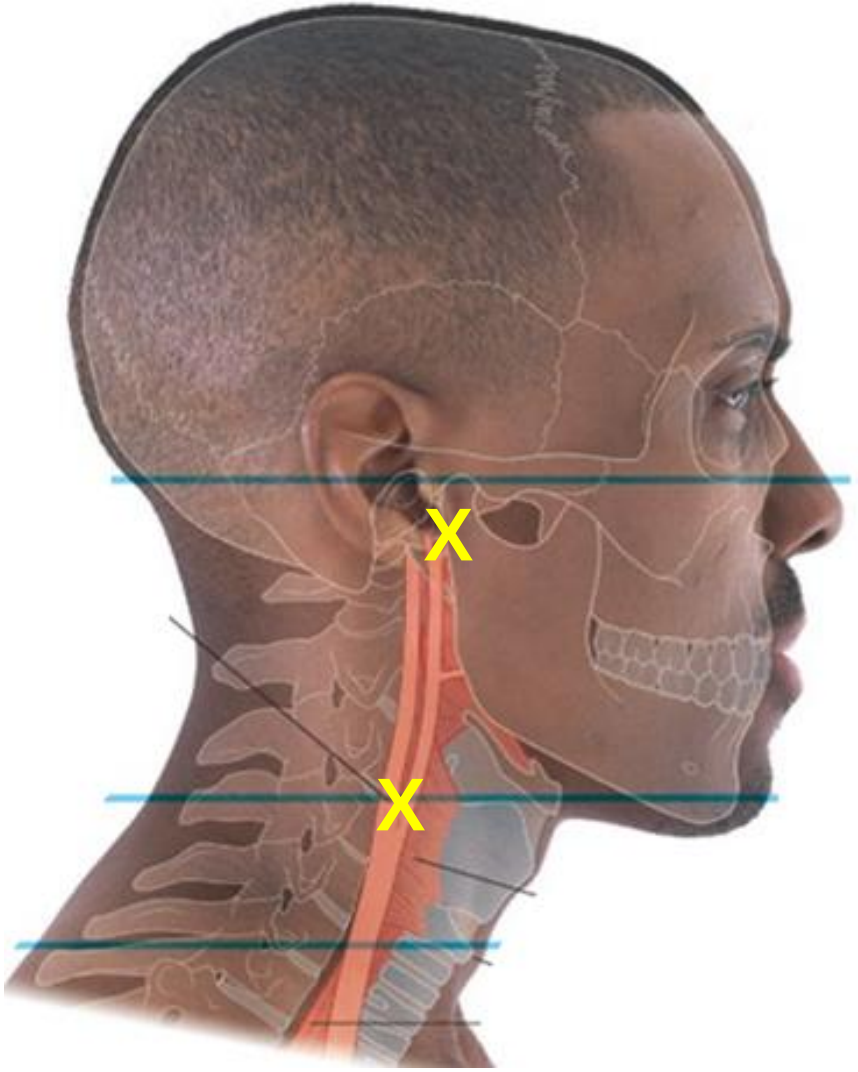

Internal Carotid Artery

1. Anterior border of sternocleidomastoid at the level of upper border of thyroid cartilage
2. Posterior border of condyle of mandible

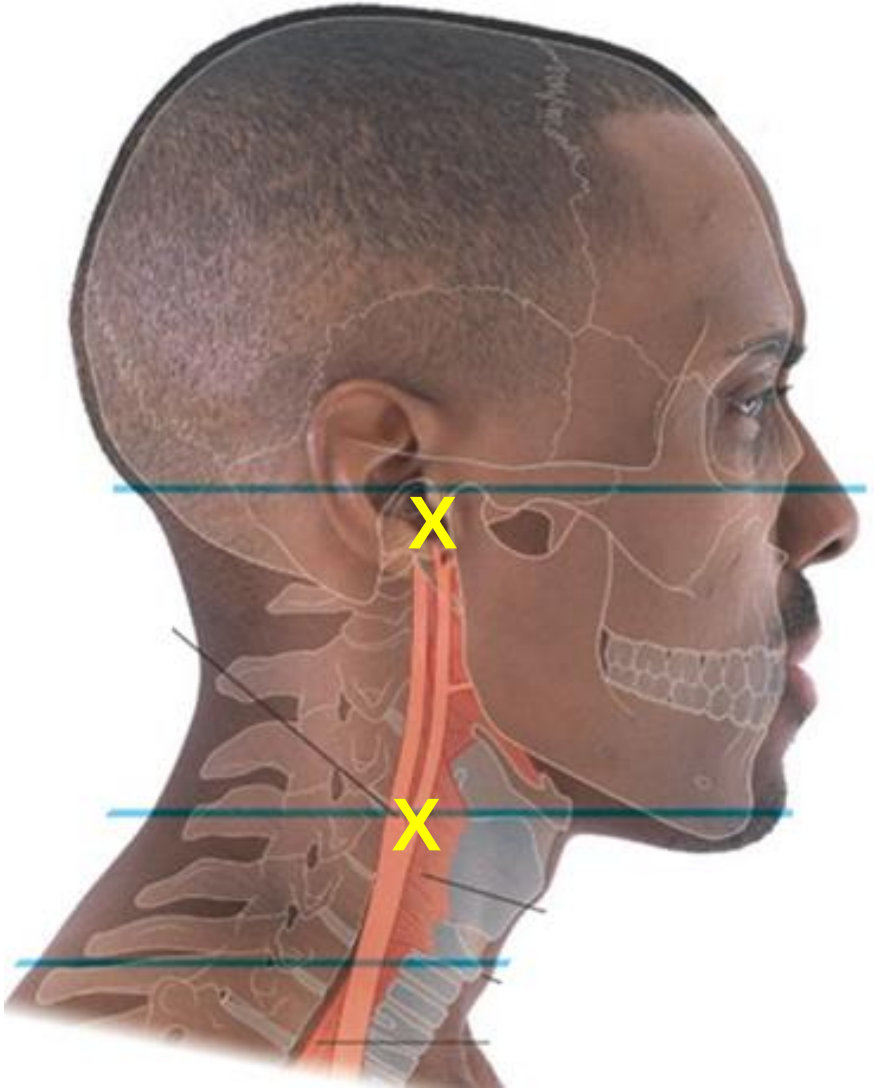

Facial Artery

1. At anterior-inferior angle masseter
2. 1.2cm lateral to the angle of mandible
3. Medial angle of eye

The artery is tortuous in its course

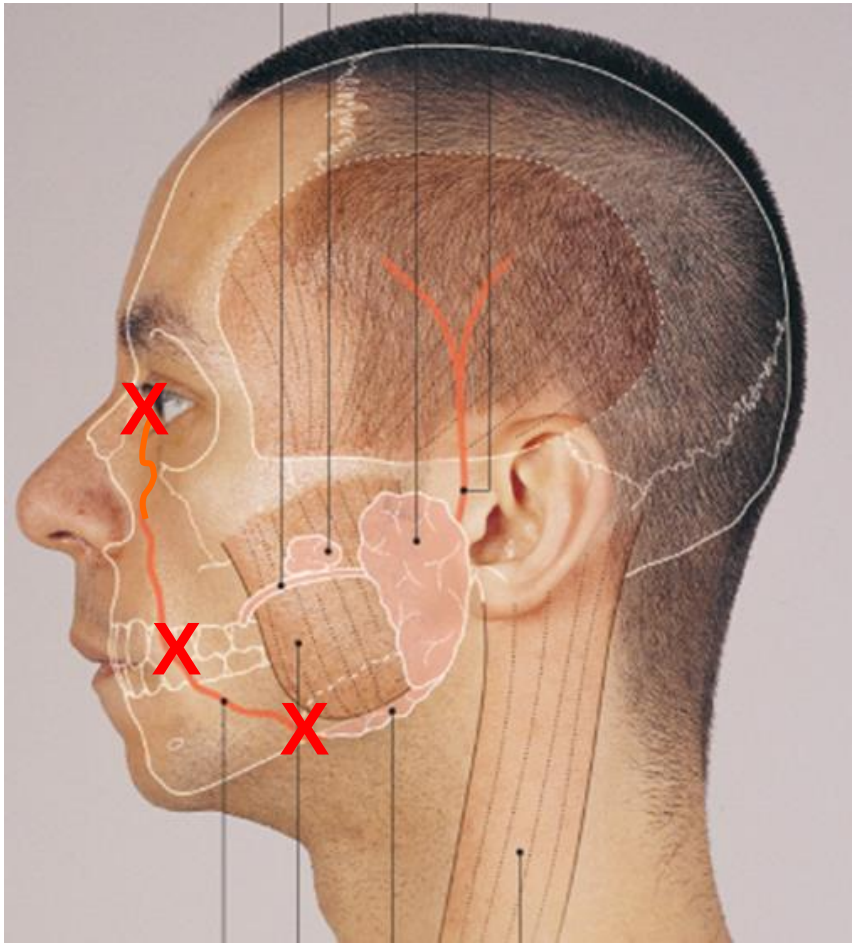

Internal Jugular Vein

1. Medial to lobule of ear
2. Medial end of clavicle

The lower bulb of the vein lies between the sternal & clavicular head of sternocleidomastoid

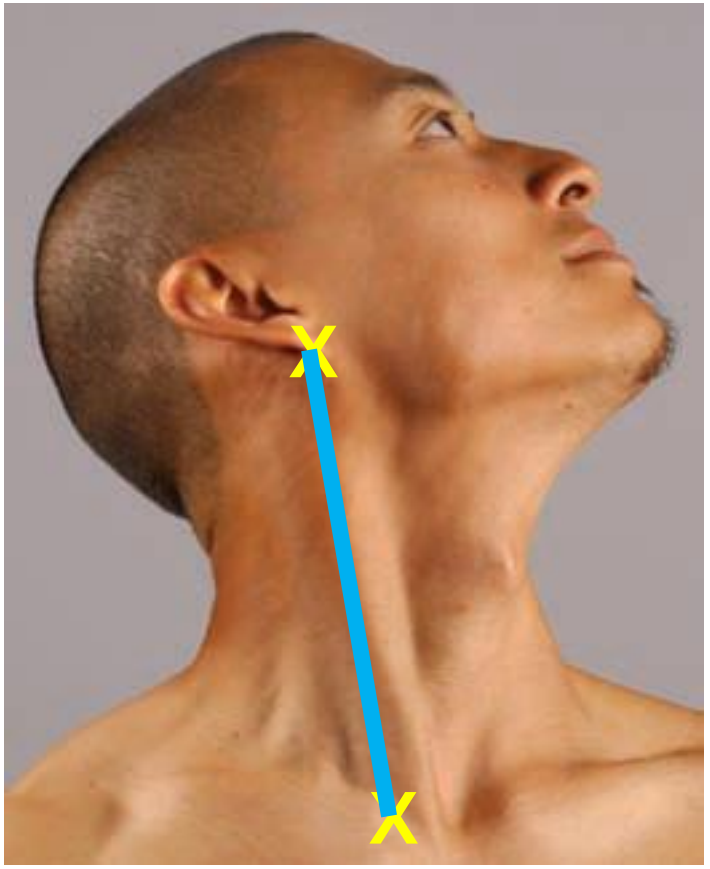

External Jugular Vein

1. Below the angle of mandible
2. On the clavicle just lateral to posterior border of sternocleidomastoid

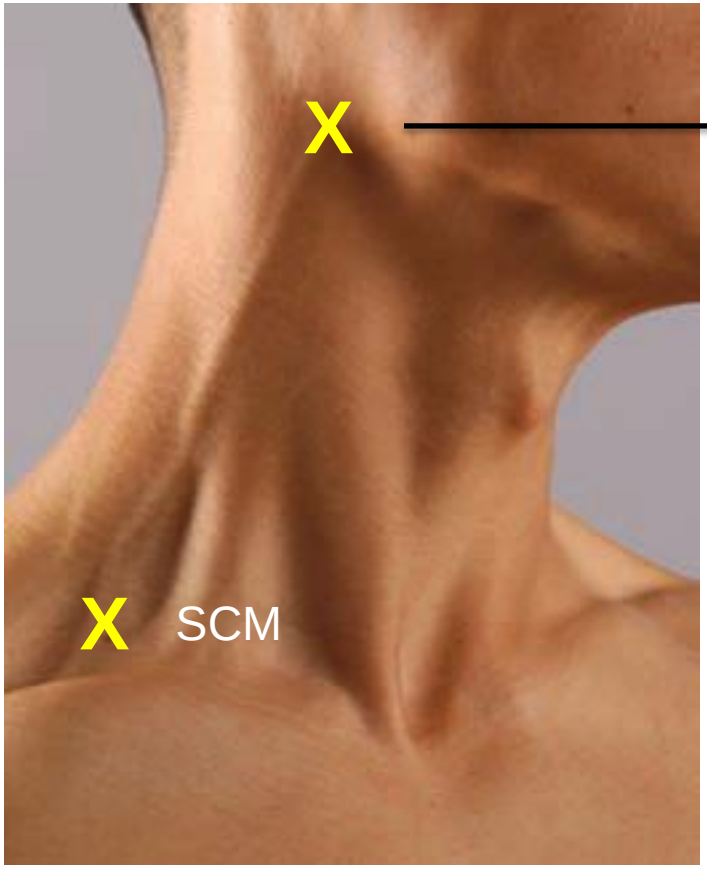

Subclavian Artery

1. Sternoclavicular joint
2. Middle of lower border of clavicle
3. 2cm above clavicle midway between 1 & 2

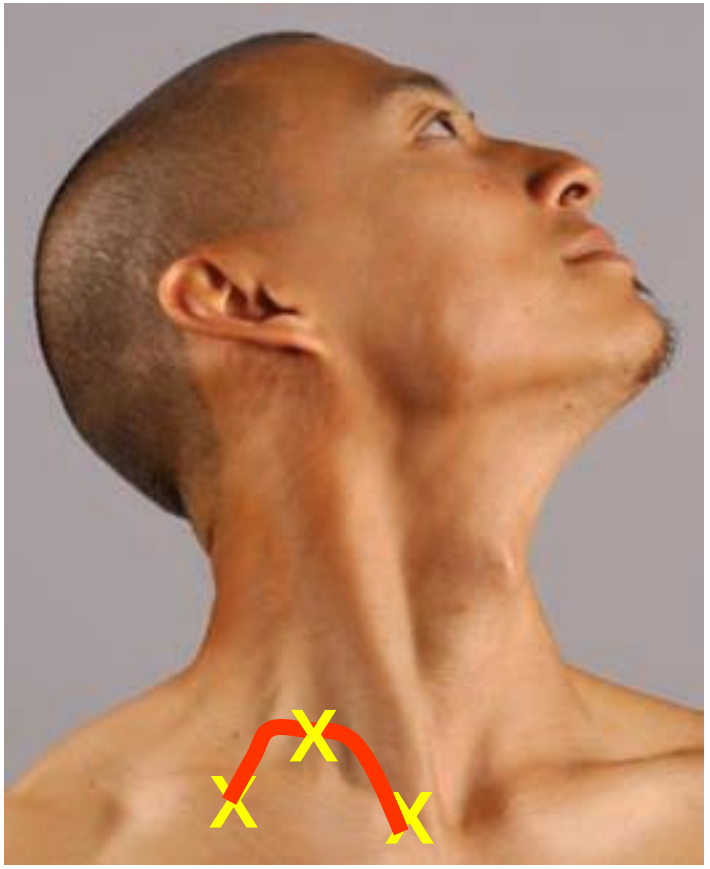

Subclavian Vein

1. Medial to midpoint of clavicle
2. Medial end of clavicle

Join these by short line convex upwards

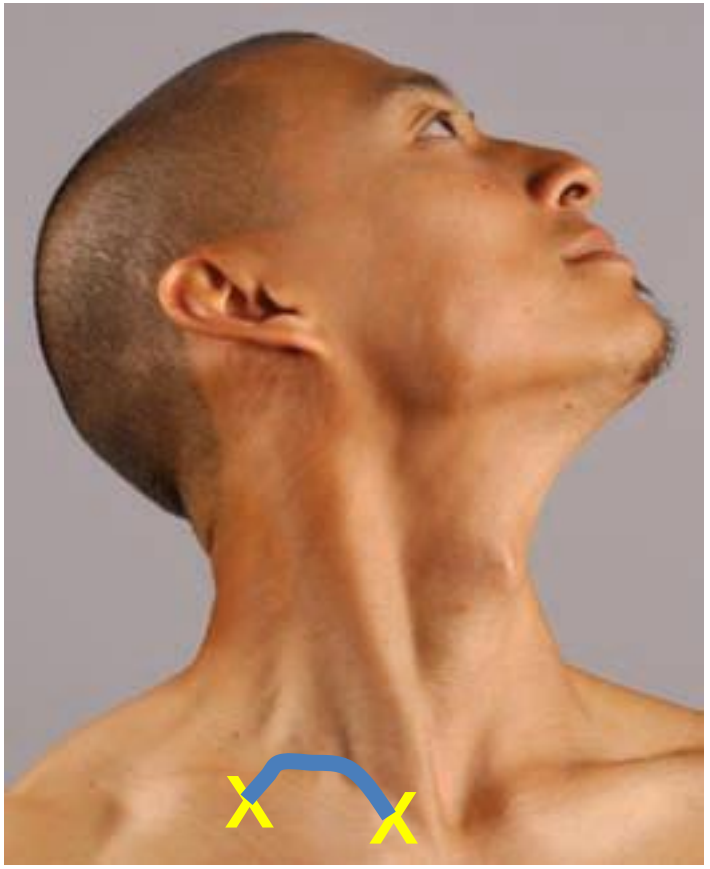

Palpation of Arterial Pulse

1. Superficial temporal- anterior to the ear & posterosuperior to position of TMJ
2. Carotid- posterolateral to the larynx
3. Subclavian-posterior to junction of medial & middle thirds of the clavicle



Parotid gland

1. Upper border of head of mandible
2. Just above the center of masseter
3. 2cm posteroinferior to angle of mandible
4. Upper part of anterior border of mastoid process

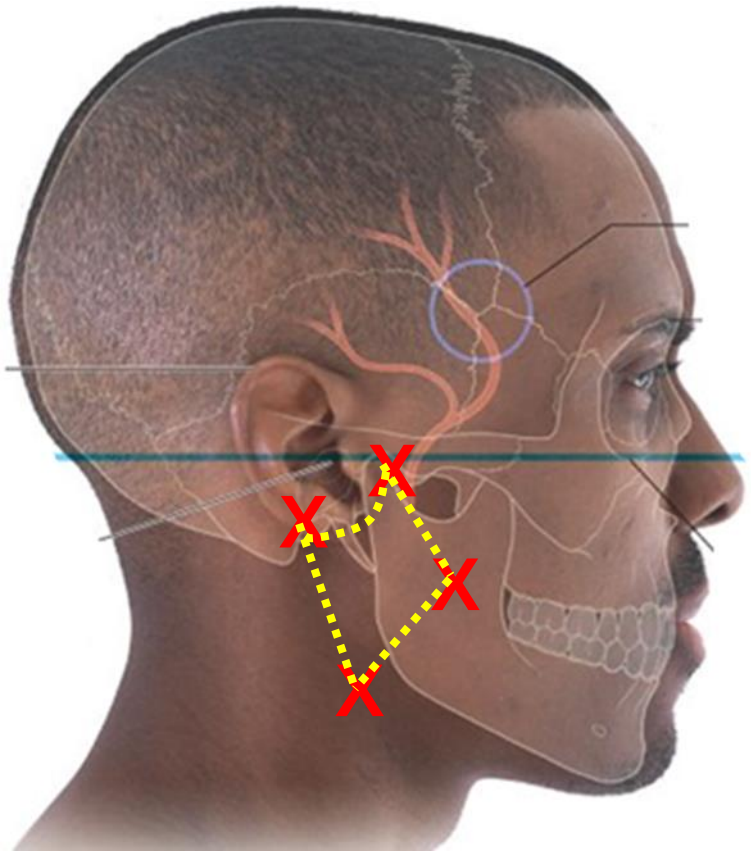

Parotid Duct

1. Lower border of tragus
2. A point midway between ala of nose and red margin of upper lip

The middle- third of this line represents parotid duct

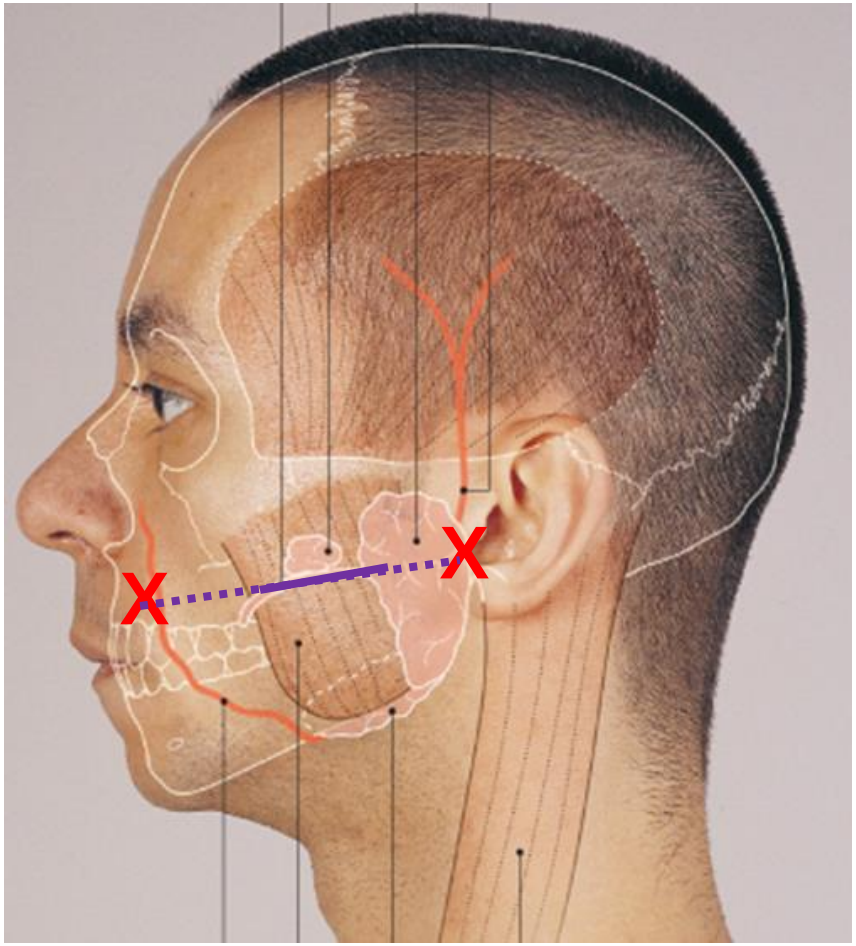

Submandibular Gland

1. Angle of mandible
2. Lower border of mandible midway between angle & the symphysis
3. 1.5cm midway between the above
4. Greater cornu of hyoid

Join these with oval line

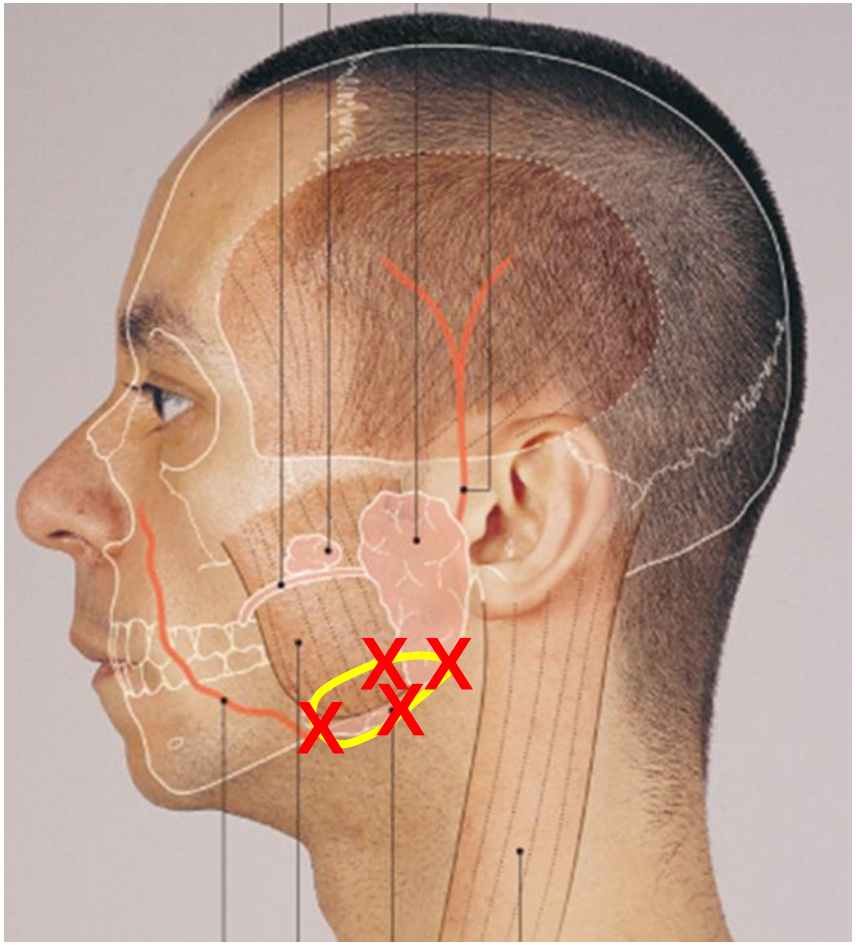

Thyroid Gland- Isthmus

1. Upper border- A line 1.5cm long across the trachea, 1cm below the arch of cricoid cartilage
2. Lower border- A line 1.5cm long across the trachea, 2.5cm below the arch of cricoid cartilage

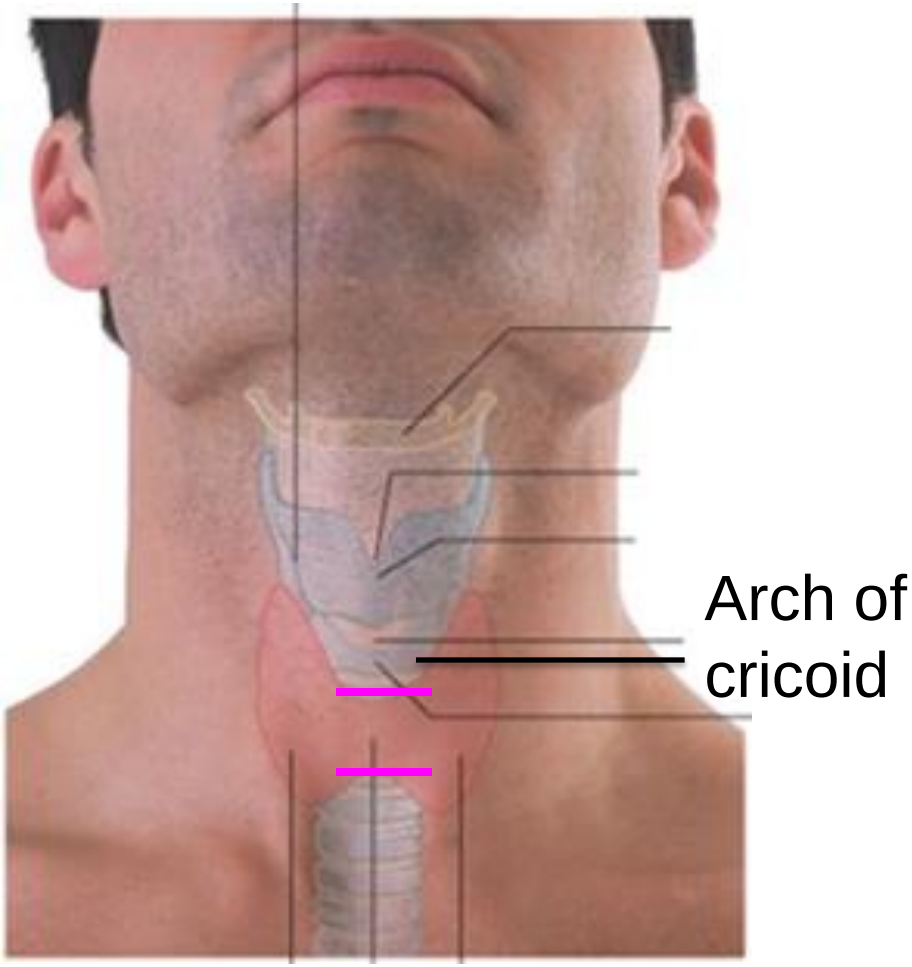

Thyroid Gland- Lateral Lobe

1. 1cm below lateral end of lower border of isthmus
2. 2.5cm below & lateral end of lower border of isthmus
3. A little in front of anterior border of sternocleidomastoid at the level of laryngeal prominence

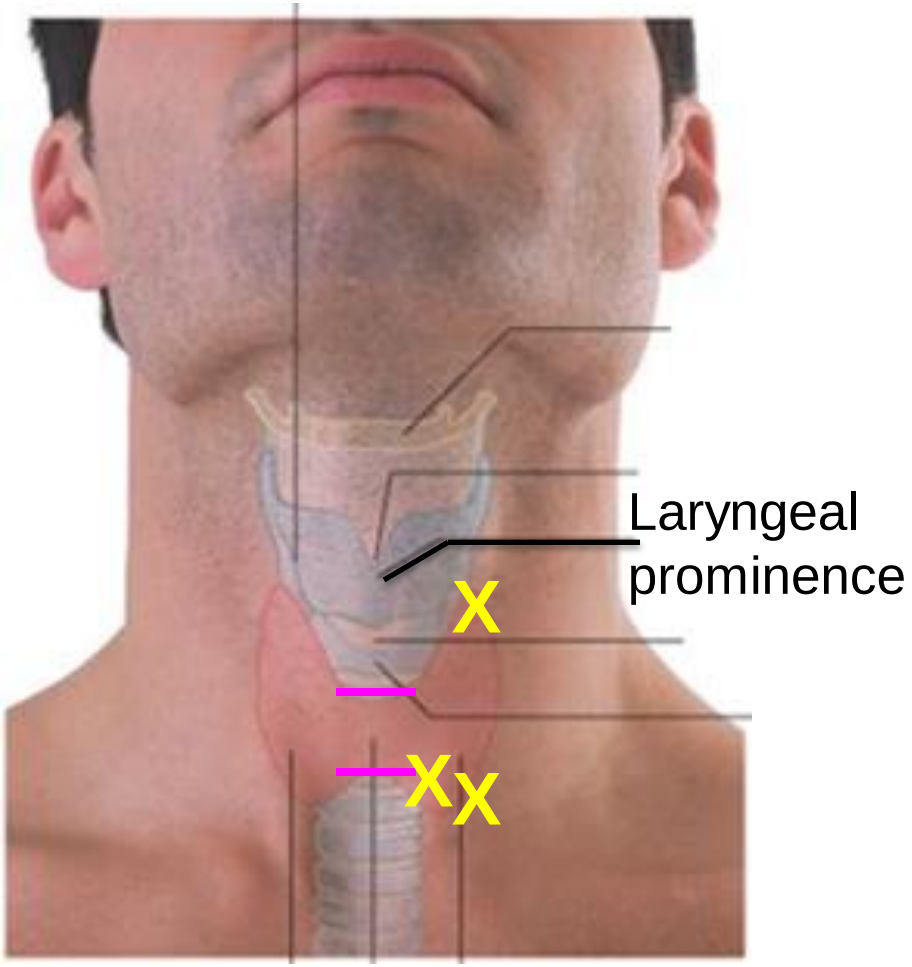

Spinal Accessory Nerve

1. Anteroinferior to tragus
2. Tip of transverse process of atlas (midway b/w angle of mandible & mastoid process)
3. Middle of posterior border of sternocleidomastoid
4. Anterior border of trapezius 6cm above clavicle

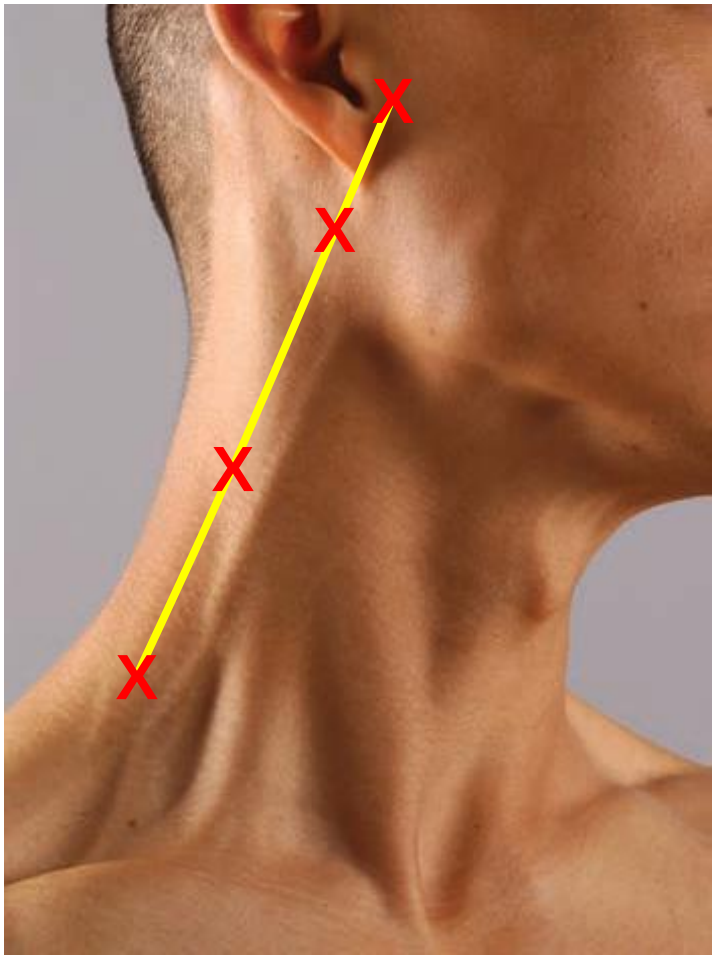

Vagus Nerve

1. Anteroinferior to tragus
2. Medial end of clavicle

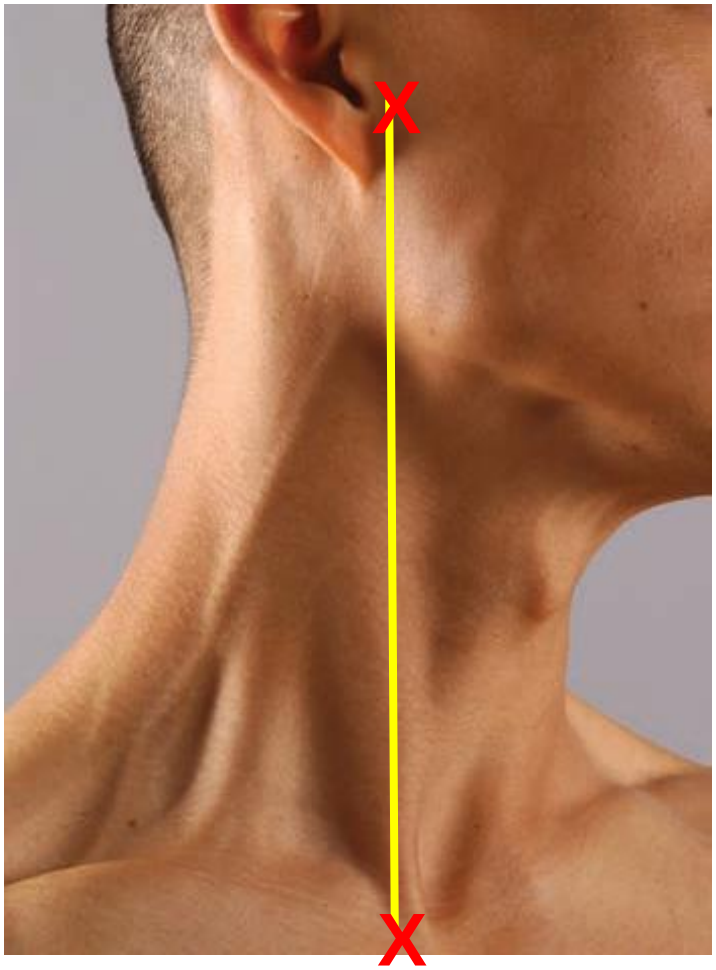

Pterion

3.5cm behind & 1.5cm above fronto-zygomatic suture

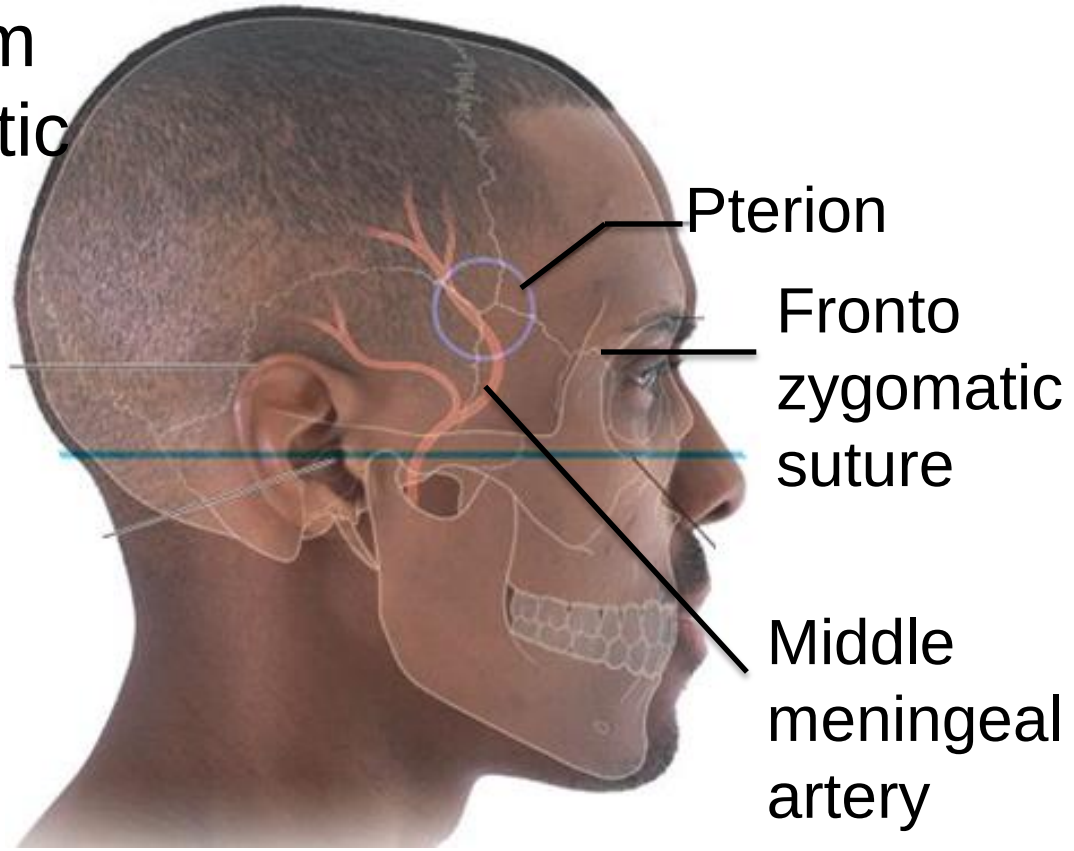

Mastoid Antrum

The lateral wall of the mastoid antrum corresponds to the suprameatal triangle which is represented on the surface by cymba concha



Palpation of Air Sinuses

1. Frontal air sinus- by pressing upwards just below the eyebrow
2. Maxillary air sinus- by pressing below the eyes

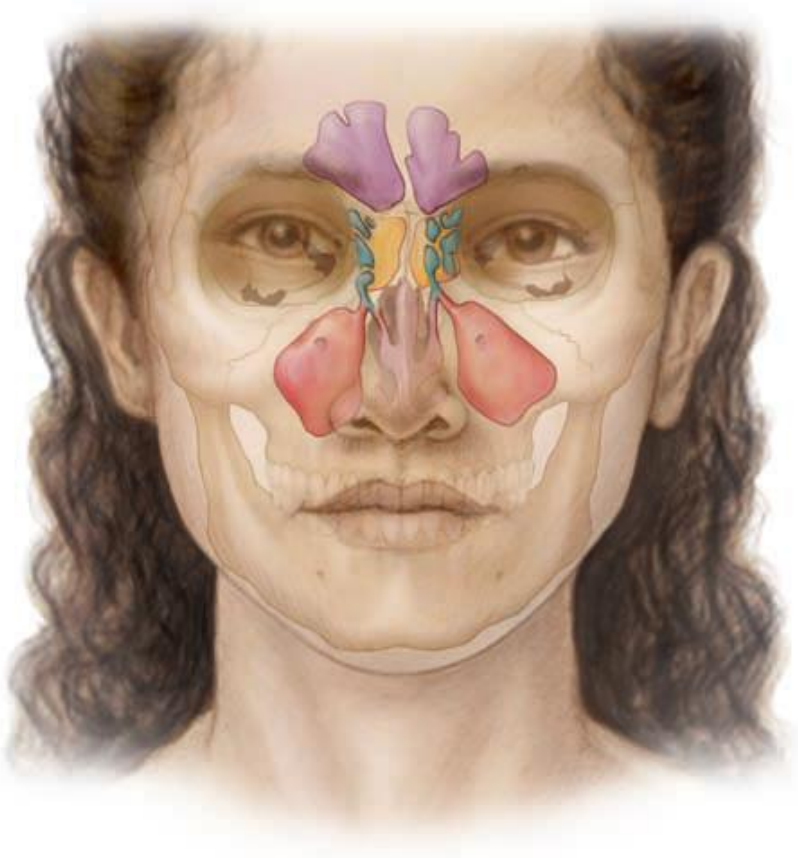

Top Quality Medical Education Sessions on Human Anatomy

Click here

To Watch Quick Revision Series Playlist of Anatomy Decoded

© Anatomy Decoded

Click here

To Join WhatsApp Group of Anatomy Decoded

Click below to Join Anatomy Decoded On

YouTube Instagram Facebook Twitter Telegram

YouTube/Anatomydecoded Instagram/Anatomydecoded





Click here 👆 to Check

What's inside Google Drive of Anatomy Decoded?

(Open with Telegram App)

Click here 👆 to Join

Premium WhatsApp Group of Anatomy Decoded

(Open with WhatsApp)

ANATOMY DECODED

Top Quality Medical Education Sessions on Human Anatomy

YouTube/Anatomydecoded Instagram/Anatomydecoded