International Journal of Surgery Case Reports 123 (2024) 110320



Contents lists available at ScienceDirect

International Journal of Surgery Case Reports

journal homepage: www.elsevier.com/locate/ijscr



Case report

Malrotated subhepatic caecum with subhepatic appendicitis: Diagnostic dilemma: A case report

Biniam Addis Anelay [a,1], Alemneh Mitku Chekol [b,*], Workye Tigabie [c], Michael Sintayew [a], Elleni Tadesse [d]

[a] Department of Surgery, SPHMMC, Ethiopia
[b] Department of Surgery, St. Peter's Specialized Hospital, Ethiopia
[c] Department of Pediatric Surgery, St. Peter's Specialized Hospital, Ethiopia
[d] Department of Pediatrics and Child Health, SPHMMC, Ethiopia

ARTICLE INFO

Keywords:
Acute abdomen
Malrotation
Subhepatic appendicitis
Subhepatic cecum
Case report

ABSTRACT

Introduction: Acute appendicitis is among common surgical emergency. Subhepatic appendicitis is rare and difficult to diagnose and manage. There are few case reports across the world.

Case presentation: We presented a case of 7 year's old child with no known medical illness presented with acute onset vague abdominal pain experienced for three days. he was symptomatically treated as Acute gastroenteritis and dyspepsia later diagnosed with acute appendicitis and underwent laparotomy. He has malrotated subhepatic cecum with Subhepatic gangrenous appendicitis Open appendectomy done and discharged improved.

Clinical discussion: Subhepatic appendicitis is a condition where the appendix is abnormally located in the upper right abdomen. This atypical placement often leads to delayed diagnosis and complications due to its similar symptoms to other abdominal diseases. While ultrasound is a valuable tool for diagnosis, laparoscopic appendectomy is the preferred treatment method when available. However, in resource-limited settings without laparoscopic capabilities, open surgery is necessary.

Conclusion: Subhepatic appendicitis is a rare occurrence and its infrequent location makes it difficult to diagnose. Awareness of various location of appendix, a high index of suspicion and radiological imaging is required for prompt diagnosis and management. Appendicitis in subhepatic appendix and high up cecum creates a lot of confusion in both diagnosis and surgical exploration which may lead in complication and delay in treatment.

1. Introduction

The appendix, a vestigial organ is a small, tubelike structure that belongs to the midgut of the digestive tract system. The most common location of the appendix is retrocecal (74 %), followed by the pelvic region (21 %). Other locations include subcecal (1.5 %), preileal (1 %), and postileal (0.5 %) positions [1]. The appendix is very vulnerable to acute inflammatory processes, and acute appendicitis continues to be one of the most frequently encountered surgical emergencies in pediatrics and adults [2].The site of normally placed appendix and its classical presentation of appendicitis are well documented in the literature. However, the variations in the anatomical position of the appendix contribute to the difficulty in diagnosing appendicitis [2].

Appendicitis occurring in the subhepatic Appendix that is, subhepatic appendicitis (SHA) is largely uncommon, and it occurs as a result of intestinal malrotation and/or non-decent of the cecum during embryonic development [3]. Owing to its unusual site, subhepatic appendicitis presents a substantial challenge in its diagnosis and management as it can mimic upper abdominal conditions [3]. Diagnostic dilemma may arise in case there is abnormal location and atypical presentation which leads to significant challenge to diagnose and management, also cause higher complication and morbidity [4]. We wrote the case report following the SCARE guideline [5].

* Corresponding author.
E-mail addresses: biniamaddis@gmail.com (B.A. Anelay), alemneh.mitku@sphmmc.edu.et, alemnehmitku7@gmail.com (A.M. Chekol), workye62@gmail.com (W. Tigabie), michaelsintayehu1@gmail.com (M. Sintayew), ellunatad@gmail.com (E. Tadesse).
[1] First author.

https://doi.org/10.1016/j.ijscr.2024.110320
Received 8 August 2024; Received in revised form 12 September 2024; Accepted 17 September 2024
Available online 19 September 2024
2210-2612/© 2024 The Authors. Published by Elsevier Ltd on behalf of IJS Publishing Group Limited. This is an open access article under the CC BY-NC-ND license (http://creativecommons.org/licenses/by-nc-nd/4.0/).

2. Case presentation

A 7-year- old, otherwise healthy child, presented to emergency department with an acute onset vague abdominal pain experienced for three days. The pain was associated with three episodes of vomiting of ingested matter, high grade intermittent fever and three episodes of loose stool. The patient was treated symptomatically in our hospital as acute gastroenteritis and dyspepsia discharged with Oral cotrimoxazole syrup 10 ml Po BID and Omeprazole 20 mg Bid for 7 days. Two days later, he presented again with moderate epigastric and right sided abdominal pain. The pain was crampy continuous, non-radiating and associated with loss of appetite and fever. On clinical examination, the patient was mildly dehydrated. The patient vital sign were BP 120/82 mmHg and PR of 106 beats/min, temperature 38.4 °C, RR 18 breath per minute and SaO2 98 % on room air. Examination of abdomen show tenderness without rebound and guarding present only in the right upper quadrant and epigastrium. The abdomen was not distended, there was no palpable mass and normal bowel sound present.

Blood investigation show total white count was elevated 14.5×10^9/l with predominantly neutrophilia of 87 %, hemoglobin was 14.7 g/dl and platelet were 265 × 109/l. Further ultrasound was performed that there is markedly inflamed and edematous mesentery at right lower quadrant of abdomen with loculated hypoechoic collection with internal debris seen measuring 2.3* 1.5 cm with surrounding hyperemia. It showed dilated non compressible appendix perforated at its base measuring 1.2 cm, with fecaliths seen in the middle of collection with multiple mesenteric Lymphadenopathies consistent with features suggestive of acute appendicitis. Exact location of appendix was not described.

After obtaining informed written consent, he was explored under general anesthesia with a diagnosis of acute abdomen secondary to acute appendicitis.

This patient underwent Open appendicectomy through Transverse Right lower quadrant incision which later was extended medially. During exploration, we noted that an abnormally high lying cecum below liver in the right hypochondrium; the ascending colon was short and dilated transverse colon was seen. The appendix was located immediately medial to the ileocecal junction craniocaudally with the tip trailing superiorly in Morison's pouch (Figs. 1,2). It was acutely inflamed gangrenous at the tip with two fecaliths and healthy base (Fig. 2). Appendectomy and local mopping was done. The patient was started on intravenous ceftriaxone 50 mg/kg/day in divided dose twice

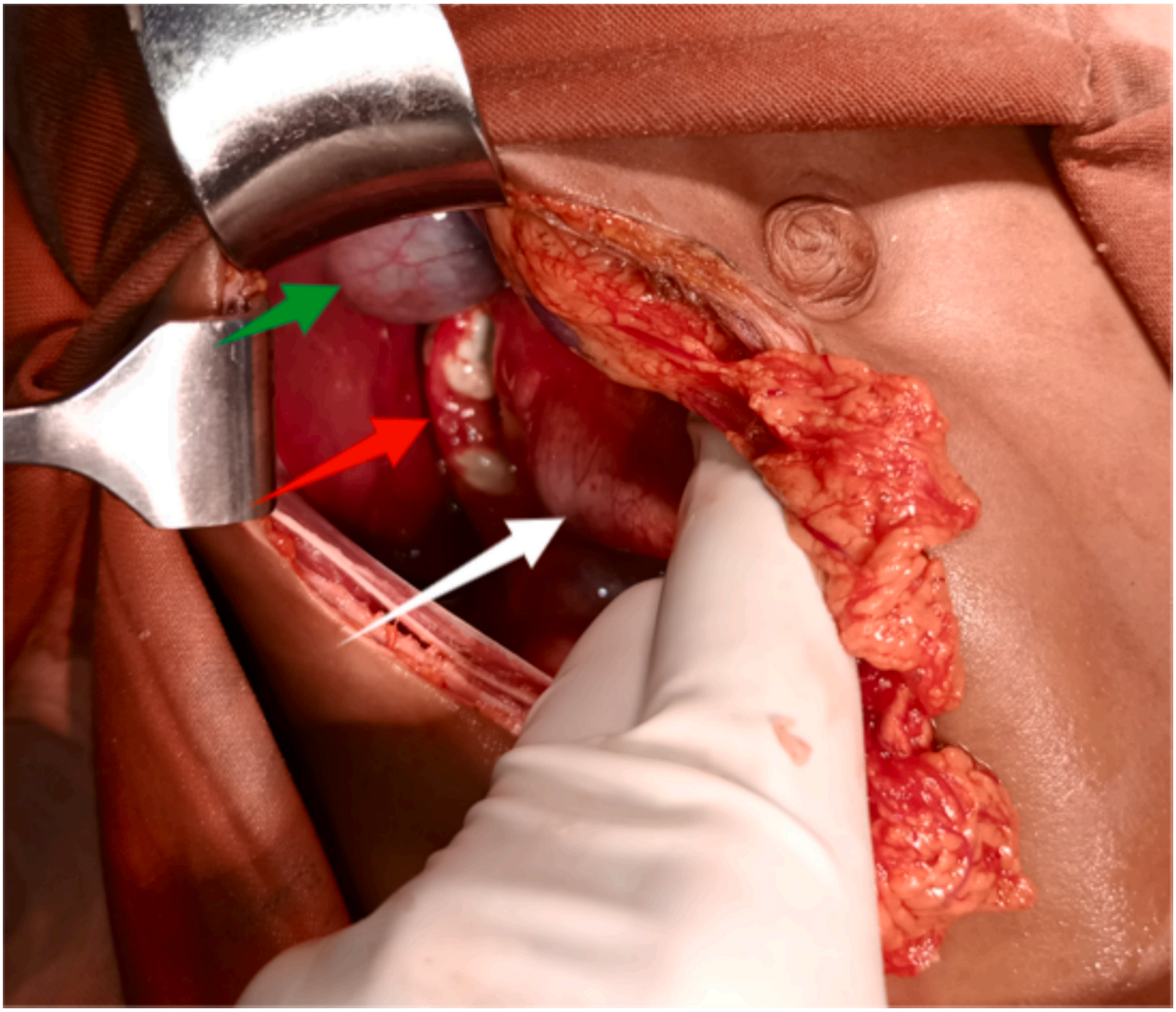

Fig. 1. Intraoperative image demonstrating a phlegmonous sub hepatic appendix (red arrow) in close proximity to Gallbladder (green arrow), Liver, and Anterior to the cecum(white arrow) located in the right upper quadrant of the abdomen. (For interpretation of the references to colour in this figure legend, the reader is referred to the web version of this article.)



Fig. 2. Post operative photo of removed appendix with fecaliths.

daily, intravenous metronidazole 15 mg/kg/dose three times daily, and intravenous paracetamol 15 mg/kg/day three timed per day in the wards until discharge.

The patient had an uneventful recovery and was discharged home on the third postoperative day with Oral Augmentin Syrup 40 mg/kg/day given in divided dose three times daily for five days. The patient was seen in the outpatient clinic, on his 7th an 30th post operative days at which time he had good state of health with healed wound and he was in his usual state of health.

3. Discussion

Acute appendicitis remains one of the most common diseases treated by the general surgeon [6]. Because of abnormal location of subhepatic appendix and high up cecum its disease creates a lot of confusion in both diagnosis and surgical exploration which may lead in complication and delay in treatment. This case report demonstrates the same diagnosis dilemma and management. In 1955, King described the first case of subhepatic appendicitis and concluded that in such conditions the cecum remains in the subhepatic area [7]. Sub hepatically located appendix is very rare and to date only reported in 0.8 % of all appendicitis, which equals an annual incidence rate of approximately 0.09 per 100,000 population [2]. .Although the majority of reports mentioned in the literature discuss the incidence of subhepatic appendicitis in adults, only a few cases have been reported in the pediatric age group [3,8,9]. different review of literature which are reported before mentioned below (Table 1).

Subhepatic location of appendix may occur as appendix resides at right upper quadrant before caecum descends to right iliac fossa during eleventh week of fetal development [4]. In the classic presentation, the patient describes the onset of abdominal pain as the first symptom. The pain is typically periumbilical in nature with subsequent migration to the right lower quadrant as the inflammation progresses. Although considered a classic symptom, migratory pain occurs only in 50 to 60 % of patients with appendicitis. In SHA the symptoms are same except pain in upper abdomen; similarly, the tenderness and other palpating sign demonstrate the pathology in right upper quadrant which may mimic hepatobiliary or gastric pathology clinically. Such atypical presentation may lead to diagnostic dilemma that leads to diagnosis delayed and complication such as sepsis suppuration and perforation [7]. Therefore, radiologic investigations are important to support diagnosis. Ultrasound is the first-line investigation that preferred due to its easily available and eases to perform. It is the best modality to diagnose and to rule other differential diagnosis related. For example, in our case ultrasound

Table 1
Review of literature on cases of subhepatic appendicitis.

Number	Title	Author(s)	Year of publication
1	Subhepatic Appendicitis [7]	King Allen et al.	1955
2	Subhepatic Appendicitis: A diagnostic dilemma [10]	Ball, William Robert, privetera et al.	2013
3	Subhepatic Appendicitis: A Diagnostic Dilemma [11]	N Kumar, B Rehmani, et al.	2015
4	Malrotated Subhepatic Caecum with Subhepatic Appendicitis: Diagnosis and Management [12]	Chong H Chai F Balakrishnan D et al.	2016
5	Subhepatic Appendicitis in an 11-year-old Boy: A Case Report [2]	Alqahtani, Saad M, Lasheen et al.	2019
6	Surgical management of subhepatic perforated appendicitis: a case report [13]	Hakim, Mumin, Mostafa et al.	2020
7	Perforated Subhepatic Appendicitis: A Case Report [14]	Kosai N Hayati F Muhamad Zin M et al.	2021
8	Subhepatic perforated acute appendicitis in a patient with midgut malrotation: A case report and review of the literature [15]	Evola G Lanaia A Cantella R et al.	2022

finding show features suggestive of acute appendicitis. Since our case was readily diagnosed by abdominal sonography, we did not contemplate using CT scan study, which entails additional cost and radiation. In advanced set up, unlike ours where CT scan of abdomen and pelvis is readily available it can also provide high sensitivity (100 %), specificity (95 %), and accuracy (98 %) in identifying acute appendicitis [16].

Broadly speaking, there are two main surgical approaches, namely open and laparoscopic appendectomy. Accumulating evidence from earlier studies demonstrated superiority for the laparoscopic appendectomy over the open appendectomy [2,17]. The laparoscopic appendectomy approach yields numerous advantages, such as reduced incidence of postoperative ileus, lower frequency of surgical wound infection, shorter duration of hospitalization, lesser utility of postoperative pain killers, decreased occurrence of adhesions, minimal body mutilation and faster recovery to previous status of well-being [17]. We, the authors, are in favor of the laparoscopic appendectomy approach too. However, the reason for not performing a laparoscopic appendectomy in our case was attributable to the lack of laparoscopic facility and available expertise in our healthcare center.

4. Conclusion

In conclusion, subhepatic appendicitis is a unique and rare presentation, making its diagnosis and management challenging. Surgeons must be aware of this atypical presentation and how patients can present late due to considering other possible nonsurgical causes such as gastritis. Due to unusual location of appendix in sub hepatic region, its diagnosis may delay or can create confusion in case of appendicitis. High degree of suspicion, good knowledge and higher imaging modalities can aid in diagnosis and results in earlier management.

Consent

Written informed consent was obtained from the patient mother who is the primary care giver, in their native language, for publication of non-identifying information including accompanying intraoperative images. A copy of the written consent is available for review by the Editor-in-Chief of this journal on request.

Ethical approval

Ethical approval is deemed unnecessary by the hospital ethical committee as this is a single case encountered during practice and it doesn't involve human or animal experiments.

Funding

No funding was provided for this case report.

Author contribution

Biniam Addis Anelay, MD -Primary operating surgeon, Study concept and design, writing the paper and literature review.

Workye Tigabie, MD - Editing of the paper and patient management, acquisition of data, and critical review of the paper.

Alemneh Mitku Chekol, MD -Editing of the paper and patient management, acquisition of data, and critical review of the paper.

Michael Sintayehu, MD -Editing of the paper and patient management, acquisition of data, and critical review of the paper.

Elleni Tadesse, MD -Editing of the paper and patient management, acquisition of data, and critical review of the paper.

Guarantor

Biniam Addis Anelay, MD.

Research registration number

N/A.

Conflict of interest statement

No conflict of interest between the authors.

Acknowledgment

We would like to thank all the surgical teams who have participated in the care of this patient.

References

[1] M. Hakim, R. Mostafa, M. Al Shehri, S. Sharawy, Surgical management of subhepatic perforated appendicitis: a case report, J Med Case Reports 14 (1) (Sep 12 2020).
[2] S.M. Alqahtani, M. Lasheen, S. Paray, Subhepatic appendicitis in an 11-year-old boy: a case report, Cureus 11 (12) (2019) e6489.
[3] S.A. McAninch, A. Essenburg, Pediatric subhepatic appendicitis with elevated lipase, Am. J. Emerg. Med. 37 (1) (Jan 2019) 174.e1–174.e3.
[4] V. Schumpelick, B. Dreuw, K. Ophoff, A. Prescher, Appendix and cecum, Surg. Clin. N. Am. 80 (1) (Feb 2000) 295–318.
[5] C. Sohrabi, G. Mathew, N. Maria, A. Kerwan, T. Franchi, R.A. Agha, The SCARE 2023 guideline: updating consensus surgical CAse REport (SCARE) guidelines, Int. J. Surg. (Lond. Engl.) 109 (5) (2023).
[6] R. Singh, Subhepatic appendicitis: diagnostic dilemma: a case report, Int. Surg. J. (2016) 422–424.
[7] A. King, Subhepatic appendicitis, Arch. Surg. 71 (2) (Aug 1 1955) 265. Available from: http://archsurg.jamanetwork.com/article.aspx?doi=10.1001/archsurg.1955.01270140113021.
[8] Ş. Biçer, A. Çelik, Duodenal obstruction caused by acute appendicitis with intestinal Malrotation in a child, Am. J. Case Rep. 16 (2015) 574–576.
[9] B.A. Castro, I.C. Novillo, A.G. Vázquez, P.Y. Garcia, E.F. Herrero, A.G. Fraile, Impact of the appendiceal position on the diagnosis and treatment of pediatric appendicitis, Rev. Paul. Pediatr. 37 (2) (Apr 2019) 161–165.
[10] W.R. Ball, A. Privitera, Subhepatic appendicitis: a diagnostic dilemma, Available from: http://group.bmj.com/group/rights-licensing/permissions, 2013.
[11] N. Kumar, B. Rehmani, N. Kumar, B. Rehmani, A. Kumar, B.N. Chug Citation Kumar, et al., Subhepatic appendicitis: a diagnostic dilemma, Int. J. Surg. (2015) 32. Available from: https://www.researchgate.net/publication/315640972.
[12] H.C. Chong, F.Y. Chai, D. Balakrishnan, S.M.D. Asilah, I.N.I. Adila, K.Z. Syibrah, Malrotated subhepatic caecum with subhepatic appendicitis: diagnosis and management, Case Rep. Surg. 2016 (2016) 1–3.
[13] M. Hakim, R. Mostafa, M. Al Shehri, S. Sharawy, Surgical management of subhepatic perforated appendicitis: a case report, J Med Case Reports 14 (1) (Dec 12 2020) 151.
[14] Perforated subhepatic appendicitis: a case report, Gazi Med. J. 32 (Oct 1 2021) 4.
[15] G. Evola, A. Lanaia, R. Cantella, C. Di Fidio, G.F. Di Fede, L. Piazza, Subhepatic perforated acute appendicitis in a patient with midgut malrotation: a case report and review of the literature, Int. J. Surg. Case Rep. 95 (Jun 2022) 107249.
[16] G. Park, Stratified computed tomography findings improve diagnostic accuracy for appendicitis, World J. Gastroenterol. 20 (38) (2014) 13942.
[17] C. Esposito, A.I. Calvo, M. Castagnetti, F. Alicchio, C. Suarez, I. Giurin, et al., Open versus laparoscopic appendectomy in the pediatric population: a literature review and analysis of complications, J. Laparoendosc. Adv. Surg. Tech. A 22 (8) (Oct 2012) 834–839.