déjà review

Surgery

- Perfect for last-minute clerkship and board review
- Written by medical students who aced the USMLE Step 2 CK
- Rapid-fire, quick-hit Q&A for maximum retention
- Study-enhancing illustrations, mnemonics, and insider advise
- Clinical vignettes chapter prepares you for cases you'll see on the exam

REMEMBER WHAT YOU ALREADY KNOW

Amit D. Tevar
Scott King
Jonathan Thompson

079_BOOKZ

DEJA REVIEW™

Surgery

Notice

Medicine is an ever-changing science. As new research and clinical experience broaden our knowledge, changes in treatment and drug therapy are required. The authors and the publisher of this work have checked with sources believed to be reliable in their efforts to provide information that is complete and generally in accord with the standards accepted at the time of publication. However, in view of the possibility of human error or changes in medical sciences, neither the authors nor the publisher nor any other party who has been involved in the preparation or publication of this work warrants that the information contained herein is in every respect accurate or complete, and they disclaim all responsibility for any errors or omissions or for the results obtained from use of the information contained in this work. Readers are encouraged to confirm the information contained herein with other sources. For example and in particular, readers are advised to check the product information sheet included in the package of each drug they plan to administer to be certain that the information contained in this work is accurate and that changes have not been made in the recommended dose or in the contraindications for administration. This recommendation is of particular importance in connection with new or infrequently used drugs.

079_BOOKZ

DEJA REVIEW™

Surgery

Amit D. Tevar, MD

Assistant Professor of Surgery
Director of Transplant Surgery Fellowship Program
Director of Pancreas Transplant Program
Division of Transplantation
Department of Surgery
University of Cincinnati
Cincinnati, Ohio

Scott J. King, MD

Resident
Radiology
University of Cincinnati
Cincinnati, Ohio

Jonathan R. Thompson, MD

Resident
General Surgery
University of Cincinnati
Cincinnati, Ohio

McGraw Hill Medical

New York Chicago San Francisco Lisbon London Madrid Mexico City
Milan New Delhi San Juan Seoul Singapore Sydney Toronto

079_BOOKZ

Copyright © 2008 by The McGraw-Hill Companies, Inc. All rights reserved. Manufactured in the United States of America. Except as permitted under the United States Copyright Act of 1976, no part of this publication may be reproduced or distributed in any form or by any means, or stored in a database or retrieval system, without the prior written permission of the publisher.

0-07-159400-0

The material in this eBook also appears in the print version of this title: 0-07-148114-1.

All trademarks are trademarks of their respective owners. Rather than put a trademark symbol after every occurrence of a trademarked name, we use names in an editorial fashion only, and to the benefit of the trademark owner, with no intention of infringement of the trademark. Where such designations appear in this book, they have been printed with initial caps.

McGraw-Hill eBooks are available at special quantity discounts to use as premiums and sales promotions, or for use in corporate training programs. For more information, please contact George Hoare, Special Sales, at george_hoare@mcgraw-hill.com or (212) 904-4069.

TERMS OF USE

This is a copyrighted work and The McGraw-Hill Companies, Inc. ("McGraw-Hill") and its licensors reserve all rights in and to the work. Use of this work is subject to these terms. Except as permitted under the Copyright Act of 1976 and the right to store and retrieve one copy of the work, you may not decompile, disassemble, reverse engineer, reproduce, modify, create derivative works based upon, transmit, distribute, disseminate, sell, publish or sublicense the work or any part of it without McGraw-Hill's prior consent. You may use the work for your own noncommercial and personal use; any other use of the work is strictly prohibited. Your right to use the work may be terminated if you fail to comply with these terms.

THE WORK IS PROVIDED "AS IS." McGRAW-HILL AND ITS LICENSORS MAKE NO GUARANTEES OR WARRANTIES AS TO THE ACCURACY, ADEQUACY OR COMPLETENESS OF OR RESULTS TO BE OBTAINED FROM USING THE WORK, INCLUDING ANY INFORMATION THAT CAN BE ACCESSED THROUGH THE WORK VIA HYPERLINK OR OTHERWISE, AND EXPRESSLY DISCLAIM ANY WARRANTY, EXPRESS OR IMPLIED, INCLUDING BUT NOT LIMITED TO IMPLIED WARRANTIES OF MERCHANTABILITY OR FITNESS FOR A PARTICULAR PURPOSE. McGraw-Hill and its licensors do not warrant or guarantee that the functions contained in the work will meet your requirements or that its operation will be uninterrupted or error free. Neither McGraw-Hill nor its licensors shall be liable to you or anyone else for any inaccuracy, error or omission, regardless of cause, in the work or for any damages resulting therefrom. McGraw-Hill has no responsibility for the content of any information accessed through the work. Under no circumstances shall McGraw-Hill and/or its licensors be liable for any indirect, incidental, special, punitive, consequential or similar damages that result from the use of or inability to use the work, even if any of them has been advised of the possibility of such damages. This limitation of liability shall apply to any claim or cause whatsoever whether such claim or cause arises in contract, tort or otherwise.

DOI: 10.1036/0071481141

McGraw Hill Professional

Want to learn more?

We hope you enjoy this McGraw-Hill eBook! If you'd like more information about this book, its author, or related books and websites, please click here.

079_BOOKZ

For more information about this title, click here

Contents

	Student Reviewers	**ix**
	Preface	**xi**
	Acknowledgments	**xiii**
Chapter 1	**ESOPHAGUS** Achalasia / 4 GERD / 6 Esophageal Varices / 13	**1**
Chapter 2	**STOMACH**	**15**
Chapter 3	**SMALL BOWEL** Appendix / 31 Irritable and Inflammatory Bowel Syndromes / 40 Inflammatory Bowel Disease / 40 Tumors / 42	**29**
Chapter 4	**COLON** Mesenteric Ischemia / 50 Obstruction / 51 Colorectal Carcinoma / 53	**45**
Chapter 5	**ANORECTAL** Fistulas / 61	**57**
Chapter 6	**SPLEEN**	**63**
Chapter 7	**HERNIA**	**75**
Chapter 8	**LIVER** Cirrhosis / 90 Esophageal Varices / 96 Hepatic Cysts / 97	**85**
Chapter 9	**GALLBLADDER**	**101**
Chapter 10	**PANCREAS**	**115**

Chapter 11 **ENDOCRINE** **127**
Thyroid / 127
Graves' Disease / 134
Parathyroid / 140

Chapter 12 **TRAUMA** **151**
Circulation / 154
Non-Hemorrhagic Shock / 156
Thoracic Trauma / 158
Abdominal Trauma / 166
Extremity Trauma / 173
Neck Trauma / 173

Chapter 13 **CRITICAL CARE** **177**

Chapter 14 **BURNS** **189**
Treatment / 198

Chapter 15 **WOUND HEALING, SKIN AND SOFT TISSUE, AND PLASTIC SURGERY** **201**
Wound Healing / 201
Skin Infections / 203
Ulcers / 206
Cysts / 206
Skin Lesions / 207
Soft Tissue Tumors / 209
Pediatric Soft Tissue / 210
Plastic Surgery / 211
Pediatric Plastic Surgery / 215

Chapter 16 **BREAST** **217**
Anatomy / 217
Breast Pain / 220
Nipple Discharge / 221
Breast Infection / 221
Breast Mass / 222
DCIS / 224
LCIS / 226
Invasive Breast Cancer / 227

Chapter 17 **PEDIATRIC SURGERY** **231**
Basic Pediatrics / 231
Head and Neck / 232
Thoracic / 233
Gastrointestinal / 237
Anorectal / 244

Jaundice / 245
Abdominal Wall / 246
Genitourinary / 248
Oncology / 249

Chapter 18 **VASCULAR SURGERY** **251**

Chapter 19 **CARDIOTHORACIC SURGERY** **265**
Thoracic / 265
Cardiac / 275

Chapter 20 **TRANSPLANT** **281**
Kidney Transplantation / 284
Liver Transplantation / 285
Pancreas Transplantation / 287

Chapter 21 **ENT** **293**
Anatomy / 293
Cancer / 294
Salivary Glands / 297
Infections / 297
Trauma / 300
Tracheostomy / 303

Chapter 22 **BARIATRIC SURGERY** **305**

Chapter 23 **UROLOGY** **309**
Anatomy and Malformations / 309
Prostate Cancer / 316
Testicular Cancer / 318
Bladder Cancer / 319
Incontinence / 322
Urologic Trauma / 324

Chapter 24 **NEUROSURGERY** **325**
Basics / 325
Lesion / 326
Spinal Cord Injuries / 341
Peripheral Nerve Injuries / 344
CNS Tumors / 348

Chapter 25 **ORTHOPEDICS** **355**
Basics / 355
Orthopedic Emergencies / 356
Fracture / 360
Dislocation / 363
Ligament and Tendon Injuries / 364

079_BOOKZ

Osteomyelitis / 364
Arthritis / 365
Miscellaneous Disorders / 367
Orthopedic Tumors / 368
Pediatric Orthopedics / 374

Chapter 26 **CLINICAL VIGNETTES** **377**
Clinical Vignette 1 / 377
Clinical Vignette 2 / 379
Clinical Vignette 3 / 380
Clinical Vignette 4 / 382
Clinical Vignette 5 / 385

Index **389**

Student Reviewers

Sanober A. Amin
MD/PhD Candidate
University of Illinois—Chicago
Class of 2008

Amy S. Arrington, MD, PhD
Baylor College of Medicine—Houston
Class of 2007

Copyright © 2008 by The McGraw-Hill Companies, Inc. Click here for terms of use.

This page intentionally left blank

Preface

Deja Review: Surgery was developed as a study aid, primarily for third and fourth year medical students, in a clerkship which is often thought of as busy and stressful with little time available for studying. Our goal in writing this book was to include the pertinent pathology with the associated diagnostic and therapeutic options which were tested during the surgical clerkship, shelf exam, and USMLE Step 2 in a concise and easy-to-remember format. As such, this text is not meant to be all-inclusive.

Scott J. King
Jonathan R. Thompson

Copyright © 2008 by The McGraw-Hill Companies, Inc. Click here for terms of use.

This page intentionally left blank

Acknowledgments

We would like to acknowledge our significant others and family as well as Marsha and Laura for their patience and support, as without their dedicated commitment this book would merely remain an idea. We would like to thank Dr. Amit Tevar for giving us this opportunity and Dr. Richard J. Stevenson, whose passion for surgical education paved the way for this book to be written

Scott J. King
Jonathan R. Thompson

Copyright © 2008 by The McGraw-Hill Companies, Inc. Click here for terms of use.

This page intentionally left blank

CHAPTER 1

Esophagus

What are the two anatomic regions of the esophagus?

- Upper esophagus (smooth and striated muscle fibers)
- Lower esophagus (smooth muscle only)

What are the three anatomic constriction points of the esophagus?

- Pharyngoesophageal (cricopharyngeus muscle)
- Thoracic (trachea and aorta)
- Diaphragmatic

What forms the lower esophageal sphincter (LES)?

- Esophageal hiatus
- 2–3 cm intra-abdominal portion maintained by the phreno-esophageal ligament
- Abdominal pressure > thoracic pressure (transmitted to distal esophagus)
- Angle of His (sling fibers of cardia creating functional flap valve)

In patients with portal hypertension which vein acts as a portosystemic shunt producing esophageal varices (see Fig. 1-1)?

Left gastric vein (also known as coronary vein)

What is unique about the layers of the esophagus?

The esophagus lacks a serosal covering, which is important in the earlier mediastinal invasion of cancer and increases risk for anastomotic leaks

What arteries supply the esophagus (see Fig. 1-2)?

- Inferior thyroid artery
- Bronchial arteries
- Branches of the aorta
- Left gastric artery
- Inferior phrenic artery
- Arterial and venous supply are segmental

Copyright © 2008 by The McGraw-Hill Companies, Inc. Click here for terms of use.

079_BOOKZ

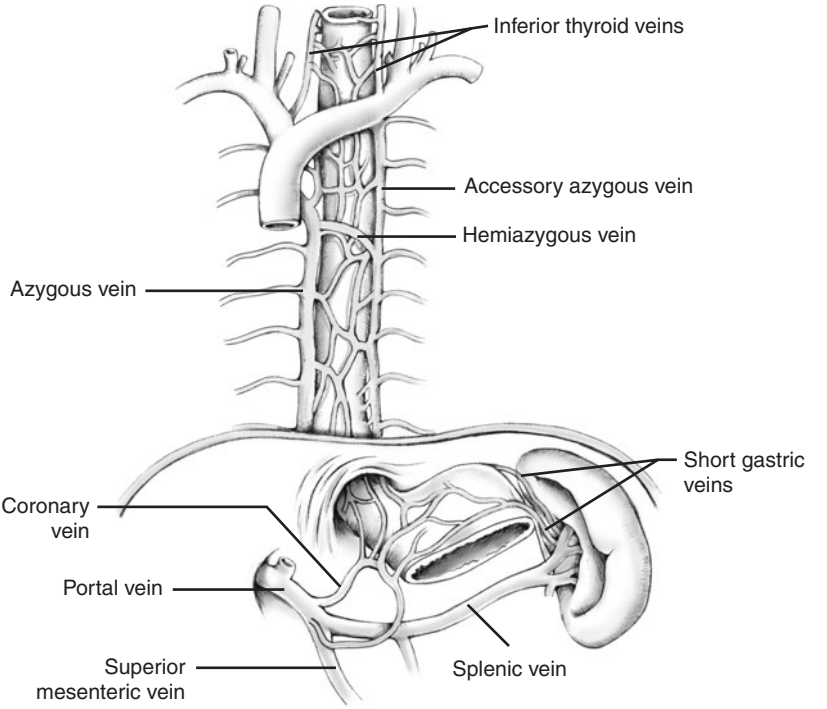

Figure 1-1 Venous drainage of the esophagus. Portal hypertension produces esophageal varices through congestion of coronary vein. In contrast, splenic vein thrombosis produces gastric varices through congestion of the short gastric veins.

How does the lymphatic arrangement differ from the arterial and venous arrangement of the esophagus?

The arteries and veins are segmental. The rich lymphatic network, which usually drains cephalad in the proximal 2/3 of the esophagus and bidirectional in the distal 1/3 allows for early longitudinal spread of malignancy.

What are the three most common motility disorders of the esophagus?

- Achalasia
- Scleroderma
- Diffuse esophageal spasm (see Fig. 1-3)

What are the signs/symptoms and LES manometric findings of the following:

Achalasia

Regurgitation, dysphagia, and weight loss and incomplete LES relaxation and elevated LES pressure

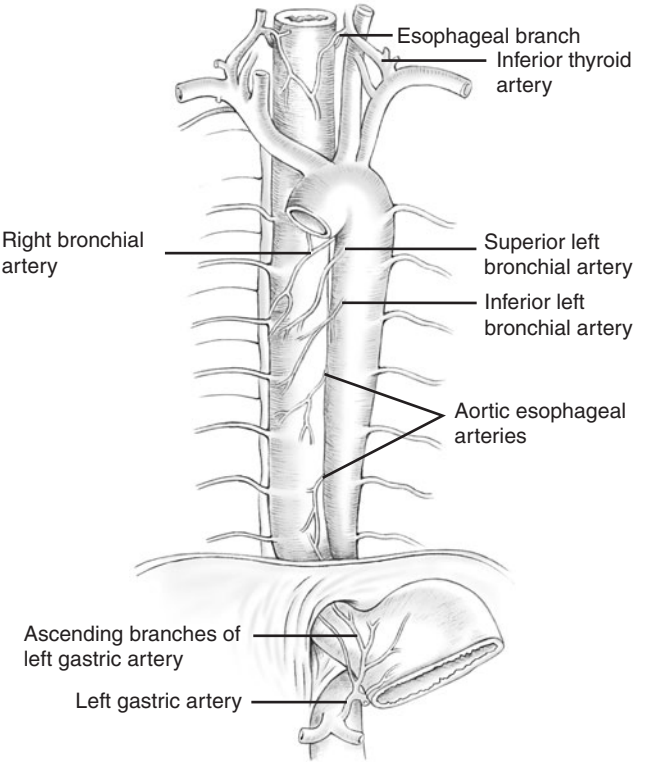

Figure 1-2 Arterial supply of the esophagus.

Scleroderma	Massive gastroesophageal reflux disease (GERD) and decreased LES pressure
Diffuse esophageal spasm	Substernal chest pain and simultaneous, repetitive and high-amplitude contractions, incomplete LES relaxation, and increased LES pressure
The most common manifestations of esophageal motility disorders are what?	Zenker's diverticula and pulsion diverticula
What muscles are involved in Zenker's diverticula (diaphragm)?	This is a weakness in the inferior pharyngeal constrictor muscle known as Killian's triangle. It is located between the oblique fibers of the thyropharyngeus and the horizontal fibers of the cricopharyngeus.

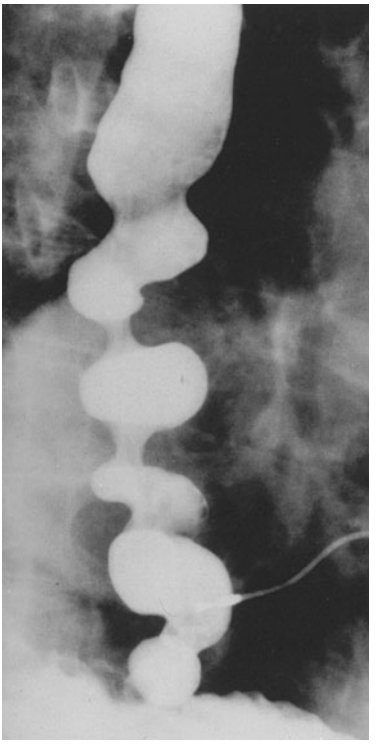

Figure 1-3 Barium esophagram appearance of diffuse esophageal spasm—"corkscrew" esophagus. [*Reproduced, with permission, from Brunicardi CF et al (eds): Schwartz's Principles of Surgery, 8th ed. New York: McGraw-Hill, 2005:880*.]

What are the locations and symptoms of:

Zenker's diverticula (see Fig. 1-4)	Upper 1/3 of the esophagus; regurgitation of food, putrid breath
Pulsion diverticula	Distal 1/3 of the esophagus; asymptomatic

ACHALASIA

What are two most common causes of achalasia?	1. Failure of LES to relax via loss of myenteric plexus 2. Chagas disease
Barium swallow of achalasia (see Fig. 1-5) shows what?	"Bird beak" from dilated esophagus and narrow LES
What other condition can mimic achalasia?	Infiltrating carcinoma = diagnosis with endoscopy and biopsy

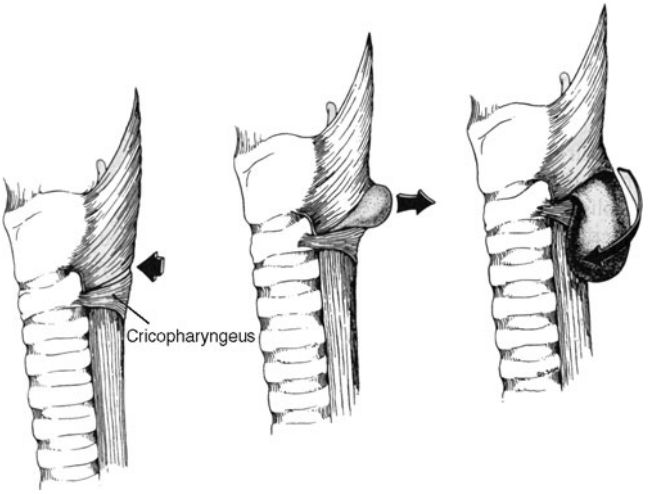

Figure 1-4 Formation of Zenker's diverticulum. [*Reproduced, with permission, from Tevar AD, Azuaje RE, Micon LT (eds): Surgery Review Illustrated. New York: McGraw-Hill, 2005:498.*]

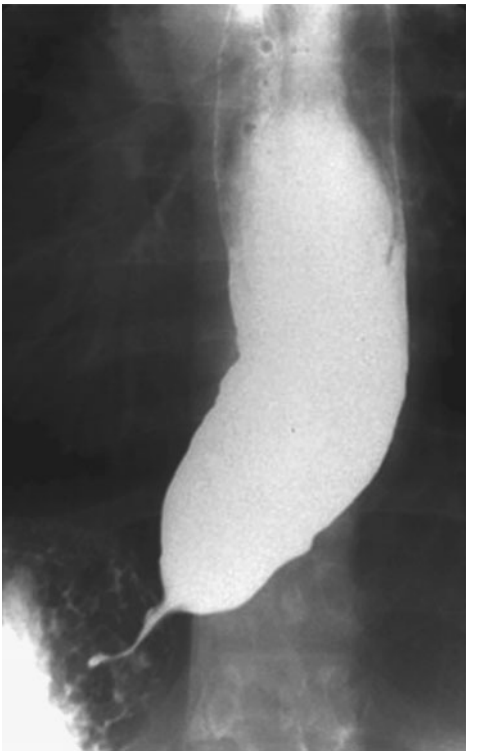

Figure 1-5 Barium esophagram appearance of achalasia with proximal dilation and "bird beak" distally. [*Reproduced, with permission, from Tevar AD, Azuaje RE, Micon LT (eds): Surgery Review Illustrated. New York: McGraw-Hill, 2005:490.*]

079_BOOKZ

What is the risk of carcinoma with achalasia?	↑ 10 × incidence
What is the treatment for achalasia?	• Calcium channel blockers and nitrates • Endoscopic intrasphincteric injection of botulism toxin • Endoscopic pneumatic dilation • Laparoscopic or open Heller myotomy (see Fig. 1-6)

GERD

How does obesity affect the LES?	Increased intra-abdominal pressure applied to the stomach > distal esophagus results in decreased LES tone, resulting in GERD. Large meals and tight garments have similar effect.
What are the three types of hiatal hernias (see Fig. 1-7)?	Type I or sliding (90%), Type II or paraesophageal, Type III or mixed.
Which types are associated with reflux?	Mixed and sliding are associated with reflux due to loss of intra-abdominal portion of the esophagus.
Which ones require repair?	Paraesophageal and mixed hiatal hernias should be fixed due to a risk of volvulus.
What are risk factors for GERD?	Factors that affect the LES or peristalsis: obesity, pregnancy, scleroderma, alcohol, hiatal hernia, caffeine
What are the symptoms of GERD?	Burning substernal or epigastric pain (pyrosis) exacerbated by reclining, sour taste in mouth, dysphagia
What are the complications of GERD?	Barrett's esophagus, adenocarcinoma, aspiration pneumonitis, stricture formation
What is the first line diagnostic test for uncomplicated (no dysphagia) GERD?	Trial of daily proton pump inhibitor (PPI). No further testing needed if symptoms improve.
Complicated (dysphagia) GERD?	Endoscopy (or esophagram) whenever dysphagia is present.
Which test establishes the diagnosis of GERD?	24 h pH test
Other three diagnostic tests for GERD?	Endoscopy (to reveal degree of esophagitis), manometry, esophagram.

079_BOOKZ

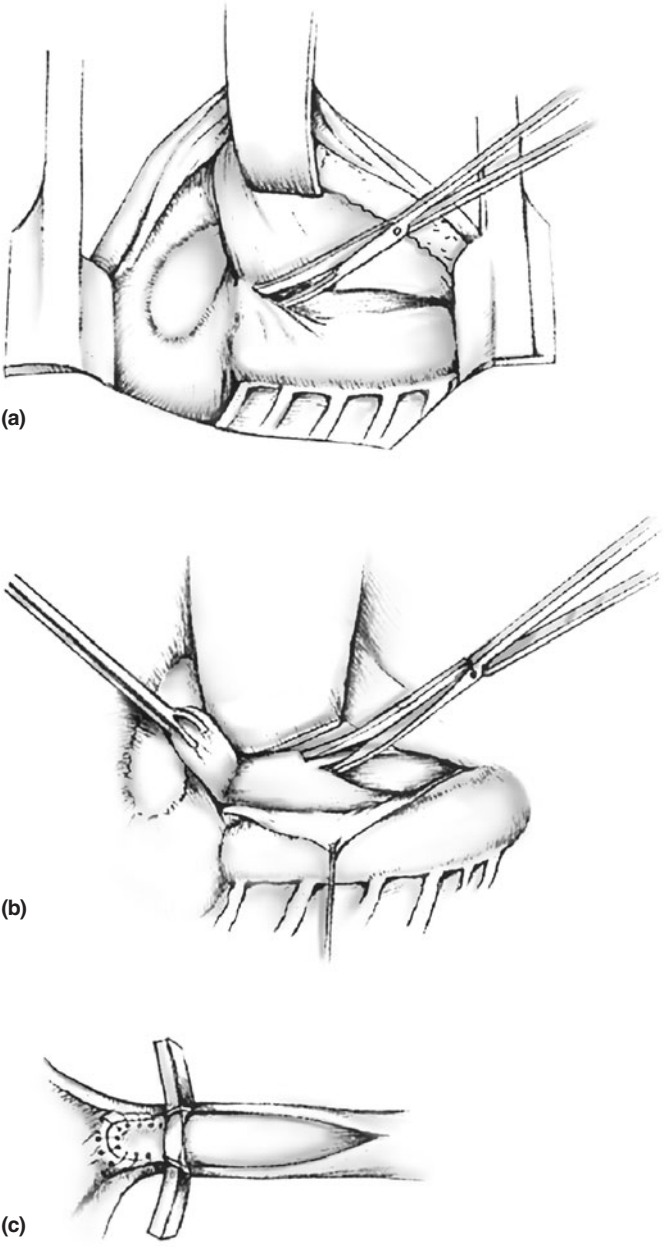

Figure 1-6 Long myotomy—thoracic approach. (a) Esophagus is exposed and dissected by incising pleura. (b) Phrenoesophageal membrane is dissected and gastric fundus is brought up. (c) Segment of esophagus is incised to mucosa and gastric fundus flap is positioned to recreate the cardia along 4 cm of intra-abdominal esophagus.

(a)

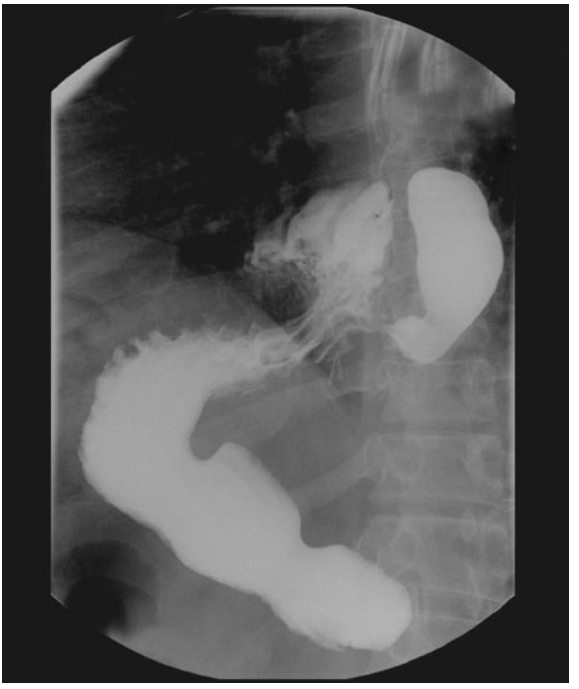

(b)

Figure 1-7 (a) Right anterior oblique and prone images from an upper GI series demonstrates a large sliding hiatal hernia with the gastric body and fundus above the diaphragm. Of note, there is nonobstructive organoaxial rotation of the herniated stomach. (b) Single contrast barium esophagram demonstrates a mixed sliding and paraesophageal hiatal hernia. Note surgical clips at the site of native gastroespohageal junction.

079_BOOKZ

Nonsurgical treatment for GERD includes what?

- Lifestyle changes (diet changes including small meals, cessation of smoking/EtOH, elevate head of bed [HOB])
- Medical: antacids, proton pump inhibitor, and H2 blocker

What are the three most common surgeries used to treat GERD?

1. Nissen fundoplication—360-ft wrap of stomach around the esophagus (intra-abdominal approach; laparoscopic; gold standard)
2. Belsey Mark IV—270-ft wrap of stomach around the esophagus (thoracotomy)—used with poor esophageal motility
3. Toupet fundoplication—180-ft wrap of fundus around the esophagus (intra-abdominal "partial Nissen"), lessens postoperative dysphagia

Note: All wrap gastric fundus around the distal esophagus (creating a "valve" or narrowing of esophagus) and repair hiatal hernia.

Why is only the fundus used in wrap repairs?

Only the LES and fundus undergo vagal mediated relaxation with swallowing.

What are the indications for GERD surgery?

- Symptom failure on proton pump inhibitor (PPI)
- Patient unwilling or unable to take daily meds
- Presence of esophageal complications—Barrett's esophagus, esophagitis, stricture, web
- Presence of extraesophageal complications—adult onset asthma, chronic sinusitis, recurrent pneumonia
- Young patient expected to be on PPI >10 years (more cost effective)

What are the manometric findings that represent a failure of LES?

- Pressure <6 mm Hg
- Total length <2 cm
- Intra-abdominal length <1 cm

What is the clinical significance?

These findings favor surgery over medical management

What are the two most common complications of Nissen fundoplication?	• Dysphagia • Gas-bloat syndrome Both resolve and are less symptomatic with time
What is gas-bloat syndrome?	Post-op complication of GERD surgery caused by overtightening of neosphincter (esophagus too narrow) which results in the inability to belch or vomit
What are serious complications of GERD surgery?	Esophageal perforation, infection, splenic injury
What is Barrett's esophagus?	Specialized intestinal metaplasia (goblet cells) of any portion of the esophagus. This is considered a premalignant condition.
How should a patient with Barrett's esophagus be managed?	Endoscopy with biopsies every 3 years if no dysplasia (if low-grade dysplasia is present, endoscopy required every 6 months, surgery if high-grade dysplasia)
What percentage of patients with GERD develop Barrett's esophagus?	**10%** (~40% of patients with scleroderma develop Barrett's esophagus)
What percentage of patients with Barrett's esophagus develop cancer (see Fig. 1-8)?	(0.5% per year conversion to adenocarcinoma) Most adenocarcinomas of the esophagus arise in Barrett's esophagus, but relatively few with Barrett's esophagus develop esophageal cancer. Approximate number of esophageal cancer per year in the United States is 12,000 with more than 11,000 deaths. ~10% of Barrett's esophagus progresses to adenocarcinoma.
Intermittent dysphagia in a patient with GERD is commonly caused by?	Distal esophageal web (aka Schatzki's rings)—webs are thin, delicate membranes and may occur anywhere in esophagus, causing mild/intermittent dysphagia (most esophageal webs are incidental findings)
What is Plummer-Vinson syndrome?	Dysphagia, atrophic oral mucosa, "spoon-shaped" fingers, chronic iron deficiency anemia
What causes dysphagia in these patients?	Upper esophageal web

079_BOOKZ

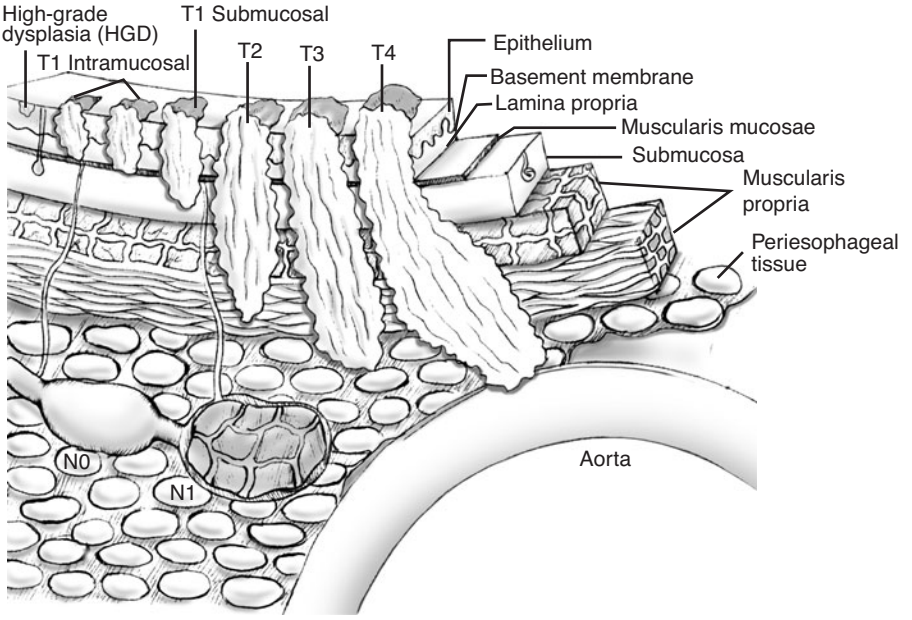

Figure 1-8 Staging of a primary esophageal carcinoma according to the depth of invasion. T1 lesions do not extend past into the muscularis mucosae. T2 lesions extend into the muscularis propria. T3 lesions extend into the adjacent esophageal tissue. T4 lesions invade adjacent organs.

What other symptoms are common with this syndrome?	Choking and aspiration due to the proximal location of the web
Most common cause of progressive dysphagia for solids in patient <50 years of age w/ GERD?	Stricture formation
Most common cause of progressive dysphagia and weight loss in a patient >50 years of age w/ GERD?	Adenocarcinoma
What are the most common forms of malignant esophageal carcinoma?	Squamous cell carcinoma (90%), adenocarcinoma (5%), malignant melanoma (1%). Adenocarcinoma has the fastest growing incidence rate in the United States.
What are the most common signs/ symptoms of esophageal carcinoma?	• Progressive dysphagia beginning with solids • Odynophagia Other symptoms include hoarseness, tracheoesophageal fistula, recurrent aspiration pneumonia, and supraclavicular lymph node

What is neoadjuvant therapy?	Radiation and chemotherapy administered prior to surgery to shrink tumor mass
What are the three surgical approaches for esophageal cancer (see Fig. 1-9)?	• Transhiatal esophagectomy via abdominal and cervical incisions • Ivor Lewis esophagectomy via abdominal and thoracic incisions (for upper and middle 1/3 cancers) • McKeown (also known as three-hole) esophagectomy via abdominal, thoracic, and neck incisions
What is the most common benign tumor of the esophagus?	Leiomyomas (~65%)
What is Mallory-Weiss syndrome?	Partial thickness tear at gastroesophageal junction following severe vomiting
How does it usually present?	Acute upper gastrointestinal (GI) hemorrhage with hematemesis
How is it treated?	Usually supportively, exploratory laparotomy if bleeding persists

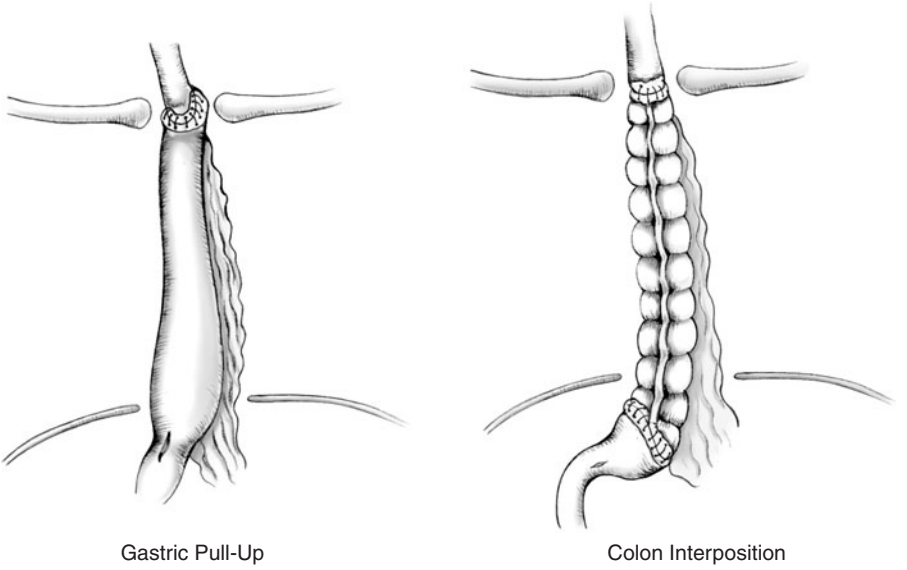

Figure 1-9 Gastric or colonic conduits may be used as esophageal replacements in the three types of esophagectomy.

What are the most common causes of esophageal perforation?	• Iatrogenic (i.e., nasogastric [NG] tube, endoscopy) • Trauma/caustic ingestion • Boerhaave's syndrome
What is Boerhaave's syndrome?	A full thickness, transmural laceration of the esophagus, usually in the relatively weaker left posterolateral wall of the distal esophagus
How does it present?	Usually no hematemesis (as in Mallory-Weiss syndrome), sudden chest pain following vomiting, subcutaneous emphysema, pneumomediastinum (Hamman's sign)
What are common causes of this syndrome?	Forceful vomiting/coughing, trauma, labor, heavy lifting
What is a potentially lethal late complication of an esophageal perforation?	Mediastinitis—may produce septic shock
How would this be treated?	Fluids, antibiotics, and surgical treatment
What are the radiographic findings with a ruptured esophagus?	Subcutaneous emphysema, pneumomediastinum, mediastinal widening, pleural effusion, pneumothorax, or hydropneumothorax

ESOPHAGEAL VARICES

What is the most likely cause of hematemesis in a patient with alcoholic cirrhosis?	Esophageal (or gastric) varices
What else is common in alcoholics?	Mallory-Weiss tear, peptic ulcer disease (PUD)
What is the first step in managing this patient?	Volume resuscitation!
What is the expected hematocrit?	Normal—equilibration has not occurred (unless patient has chronic blood loss or nutritional deficiencies)

What should be used to replace blood loss?	Blood—crystalloid solutions may worsen ascites
What is the best indicator for assessing peripheral perfusion?	Urinary output, with placement of a Foley
How can one quickly diagnose an upper vs lower GI bleed?	NG lavage
Does a negative NG lavage exclude upper GI bleed?	No, approximately 20% of upper GI bleeds are not detected with NG lavage.
What is the best diagnostic test/ procedure to locate upper GI bleeding?	Esophagogastroduodenoscopy (EGD) after NG lavage has cleared debris
What treatment options exist to treat cirrhotic esophageal variceal bleeding?	1. Sclerotherapy (injections of caustic solutions adjacent to varices to induce scarring)—risk further bleeding and esophageal perforation 2. Banding (similar technique as used for hemorrhoids)—few complications 3. IV (intravenous) somatostatin (induces vasoconstriction) with/without nitroglycerin (lowers portal pressures) 4. Sengstaken-Blakemore tube (tamponade varices)—risk esophageal perforation, aspiration, pressure necrosis) 5. TIPS (transjugular intrahepatic portacaval shunt) treatment of last resort before surgery 6. Surgery (portacaval shunting)
What percent of varices bleed?	30%
What is the percentage of repeated bouts of variceal hemorrhaging?	70%

CHAPTER 2

Stomach

What are the anatomic regions of the stomach (see Fig. 2-1)?

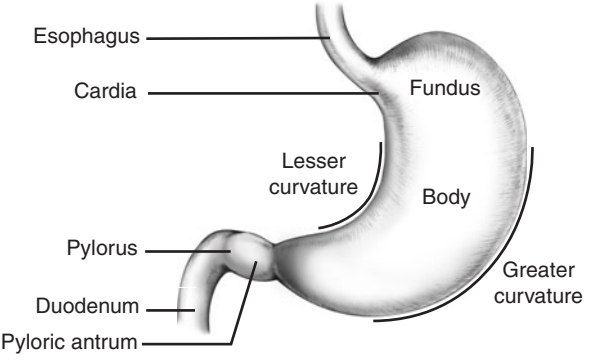

Figure 2-1 Anatomic regions of the stomach.

What arteries supply the stomach (see Fig. 2-2)?

- Right gastric—branch of common hepatic
- Left gastric—branch of celiac trunk
- Right gastroepiploic—branch of gastroduodenal
- Left gastroepiploic—branch of splenic
- Short gastrics—branches of splenic

Note: Stomach has abundant, redundant blood supply which must be devascularized during surgery.

Copyright © 2008 by The McGraw-Hill Companies, Inc. Click here for terms of use.

079_BOOKZ

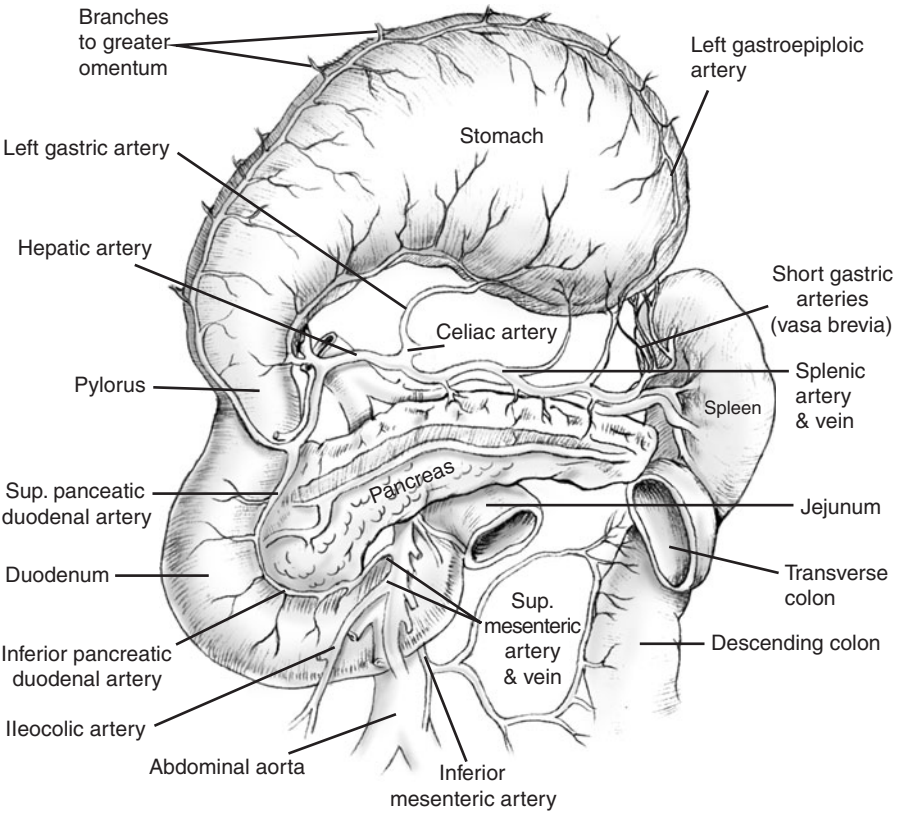

Figure 2-2 Arterial supply of the stomach, pancreas, duodenum, and spleen.

What nerve supplies parasympathetic innervation to the stomach?	Vagus
What do the left (anterior) and right (posterior) branches innervate?	• Right/posterior—supplies the celiac plexus which supplies the midgut (pancreas, small bowel, proximal colon) • Left/anterior—supplies liver, gallbladder, and biliary tree • Remember: **LARP (l**eft/**a**nterior; **r**ight/**p**osterior)
Where does the criminal nerve of Grassi originate?	Posterior (right) vagus branch
Why is it important?	If not severed in peptic ulcer surgery, will cause recurrent peptic ulcer
Sympathetic innervation is supplied by which nerve?	Celiac ganglion via fibers from greater splanchnic

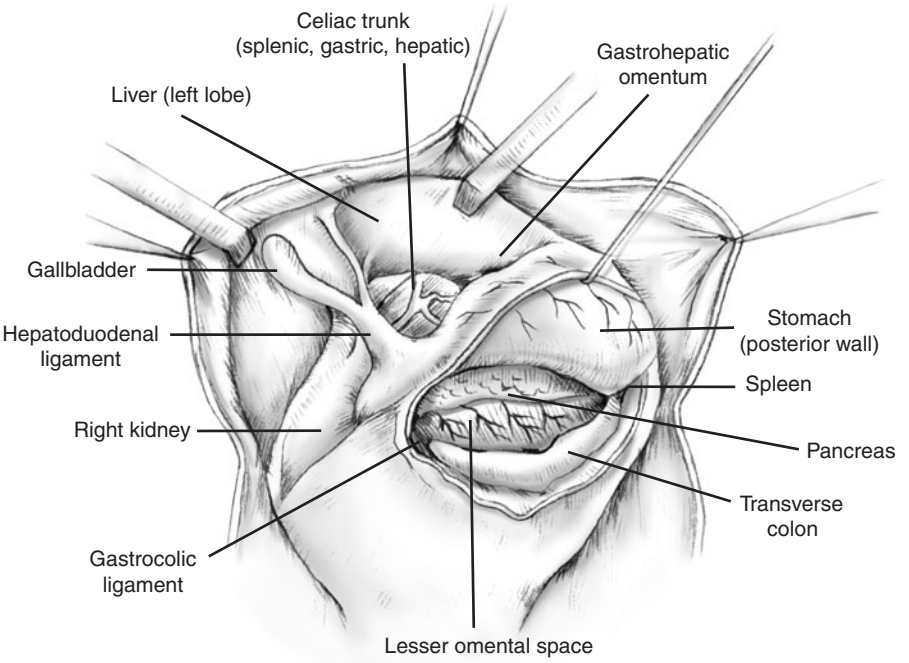

Figure 2-3 Incised greater omentum allows view into the lesser omental space (lesser sac).

What is the space behind the stomach?	Lesser sac (see Fig. 2-3)
What is the opening to this space called?	Epiploic foramen (also called foramen of Winslow) (see Fig. 2-4)
What are the products of the following cells:	
Chief cells	Pepsinogen
Parietal cells	Hydrochloric acid and intrinsic factor
G cells	Gastrin
D cells	Somatostatin
Intrinsic factor is needed for the absorption of which vitamin?	Vitamin B_{12}
Autoimmune destruction of parietal cells causes what condition?	Pernicious anemia (B_{12} deficiency)
What two characteristic findings are seen on a peripheral blood smear?	Macrocytic anemia (mean corpuscular volume [MCV] >100) and hypersegmented neutrophils (5 + lobes)

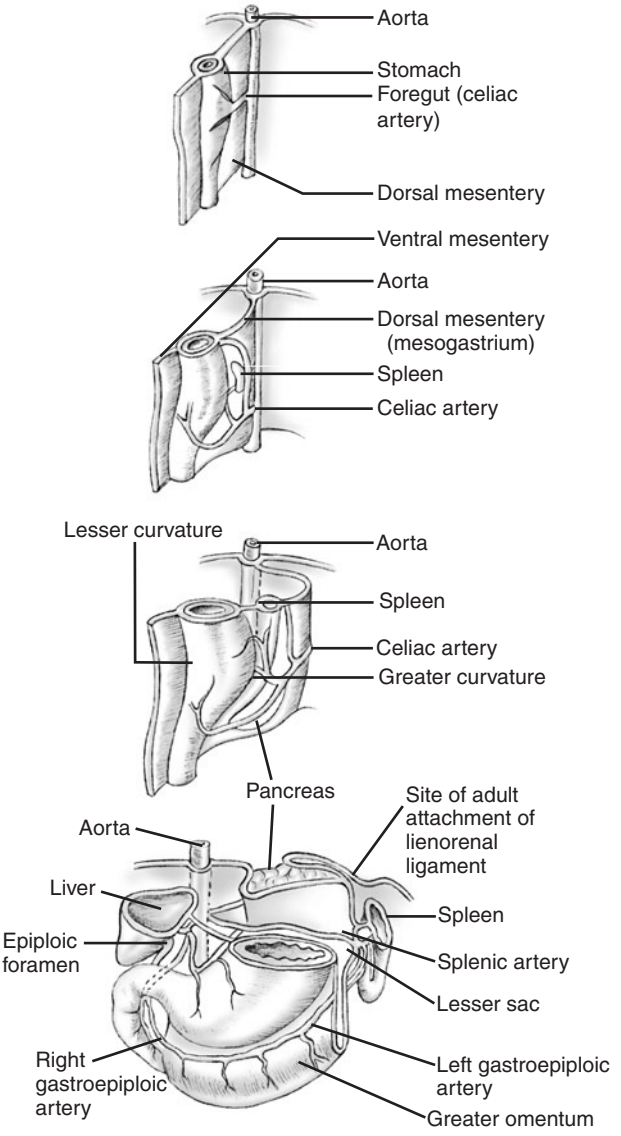

Figure 2-4 Foregut rotation during development is responsible for the anatomy of the lesser and greater omentum positions.

What three products cause secretion of gastric acid (see Fig. 2-5)?

1. Gastrin from G cells
2. Acetylcholine from vagus nerve
3. Histamine from paracrine release via mast cells

Gastrin secretion is inhibited by what hormones?

- Somatostatin due to pH <2 in antrum

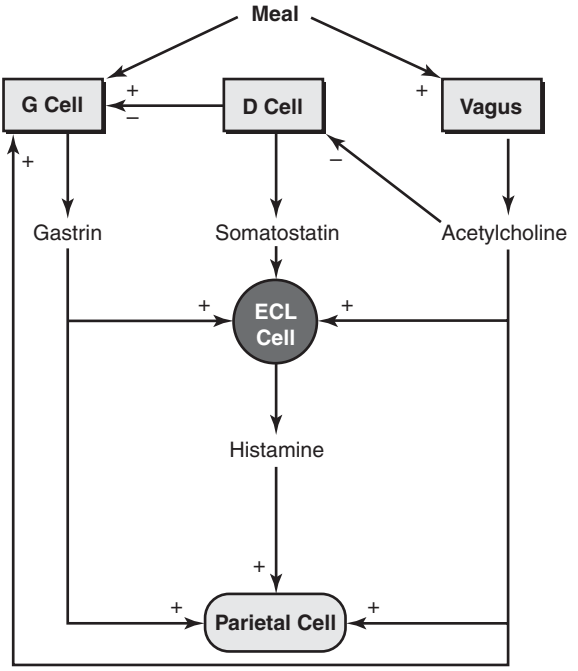

Figure 2-5 Factors contributing to the acid secretion of the stomach.

	• Secretin secreted by duodenum due to presence of acidic chyme (think of somatostatin as "somatostopping" = decrease digestive processes)
How do prostaglandins enhance gastric mucosal protection from acid?	Enhance mucous bicarbonate secretion and maintain blood flow
What is PUD?	Peptic ulcer disease, which refers to gastric and/or duodenal ulcers
Of the four types of gastric ulcers:	
Which is the most common?	Type I (55%) > II > III > IV
Where is each located within the stomach?	Type I—lesser curvature
	Type II—2 ulcers—gastric body and duodenum
	Type III—prepyloric
	Type IV—on lesser curvature near gastroesophageal (GE) junction

Which are associated with acid hypersecretion?	Type II and III
What are the classic symptoms of gastric ulcers?	Pain greater with meals = gastric
With duodenal ulcers?	Pain **d**ecreases with meals = **d**uodenal
What percentage of people with gastric ulcers are infected with *Helicobacter pylori?*	~70%
What percentage of duodenal ulcers have *H. pylori* infection?	~100%
How is *H. pylori* diagnosed?	Immunoglobulin G (IgG) serology, C13 or C14 urea breath test, rapid urease
What is the treatment for *H. pylori?*	Triple therapy of PPI, amoxicillin, and clarithromycin. If eradication fails, then quadruple therapy with PPI, bismuth, metronidazole and tetracycline (or amoxicillin)
What is the most common symptom of PUD?	Dyspepsia (~40%)
What are other causes for this symptom?	Gastroesophageal reflux disease (GERD), gastric cancer, gastroparesis
What is the most sensitive test for PUD?	Endoscopy (95%)—all patients with suspected gastric ulcers need endoscopy to evaluate for dysplasia
What are the indications for such a test?	New onset dyspepsia >45 years, weight loss, bleeding, nausea/vomiting (biopsy all gastric ulcers because of high incidence of cancer)
What are three causes of acute gastritis?	1. Nonsteroidal anti-inflammatory drug (NSAID) ingestion 2. Stress related 3. EtOH ingestion
What are two types of chronic gastritis?	1. Type **A** (**a**utoantibodies to intrinsic factor, producing pernicious **a**nemia, and **a**chlorhydria) 2. Type **B** (from *H. pylori*, a **b**acteria)
Which one is considered premalignant requiring annual endoscopy?	Type A (~40% develop cancer)
What is the cause of stress-related gastritis?	Ischemia to gastric mucosa via shock, hypotension, or catecholamine release

Who is at risk for stress-related ulcers?	Patients who have sepsis, severe trauma, or require ventilator support
What are stress ulcers that occur in burn patients called?	Curling's ulcer
In head injuries?	Cushing's ulcer
What is the only effective prophylaxis of NSAID-induced ulcers?	Misoprostol (prostaglandin E2 agonist)
What drug can be given to create a physical barrier over injured gastric mucosa?	Sucralfate
What is the risk for severe bleeding due to stress-related ulcers?	5%
What are five indications for surgery of PUD?	1. Bleeding (usually posterior ulcers damaging gastroduodenal artery) 2. Perforation (usually anterior duodenal ulcers) 3. Gastric outlet obstruction (usually prepyloric or duodenal ulcers) 4. Intractable pain 5. Failure of medical therapy
What is the most common surgical resection for treatment of PUD?	Vagotomy and antrectomy (highest incidence of postop diarrhea and dumping, lowest incidence of recurrent duodenal ulcer)
What are causes for free air under the diaphragm?	90% = perforation. Peptic ulcer. Also consider aortic dissection, mesenteric ischemia, large bowel perforation, injury to viscus status post (s/p) trauma. All are surgical emergencies in an acute abdomen. Rule out recent surgery, which may or may not be an emergency.
What are the structures denervated with the following vagotomies?	
Total	Transected vagal trunk denervates parietal cell mass, antral pump, pyloric sphincter, abdominal viscera
Selective	Denervation of stomach (including pylorus) above crus of diaphragm—preserve celiac and hepatic branches = no denervation of abdominal viscera
Proximal gastric (highly selective)	Parietal cell vagotomy along lesser curvature of stomach (preserve pyloric sphincter and antral pump = no drainage procedure needed)

079_BOOKZ

What is the cause of truncal vagotomy resulting in an increased rate of gastric emptying of liquids?

Loss of receptive relaxation in the proximal 1/3 of stomach (remember: the fundus can only be used for wrap procedures in treating GERD) causes increased intragastric pressures leading to increased emptying of liquids.

What are the most common reconstructions after antrectomy?

1. Billroth I (see Fig. 2-6) (gastroduodenostomy)

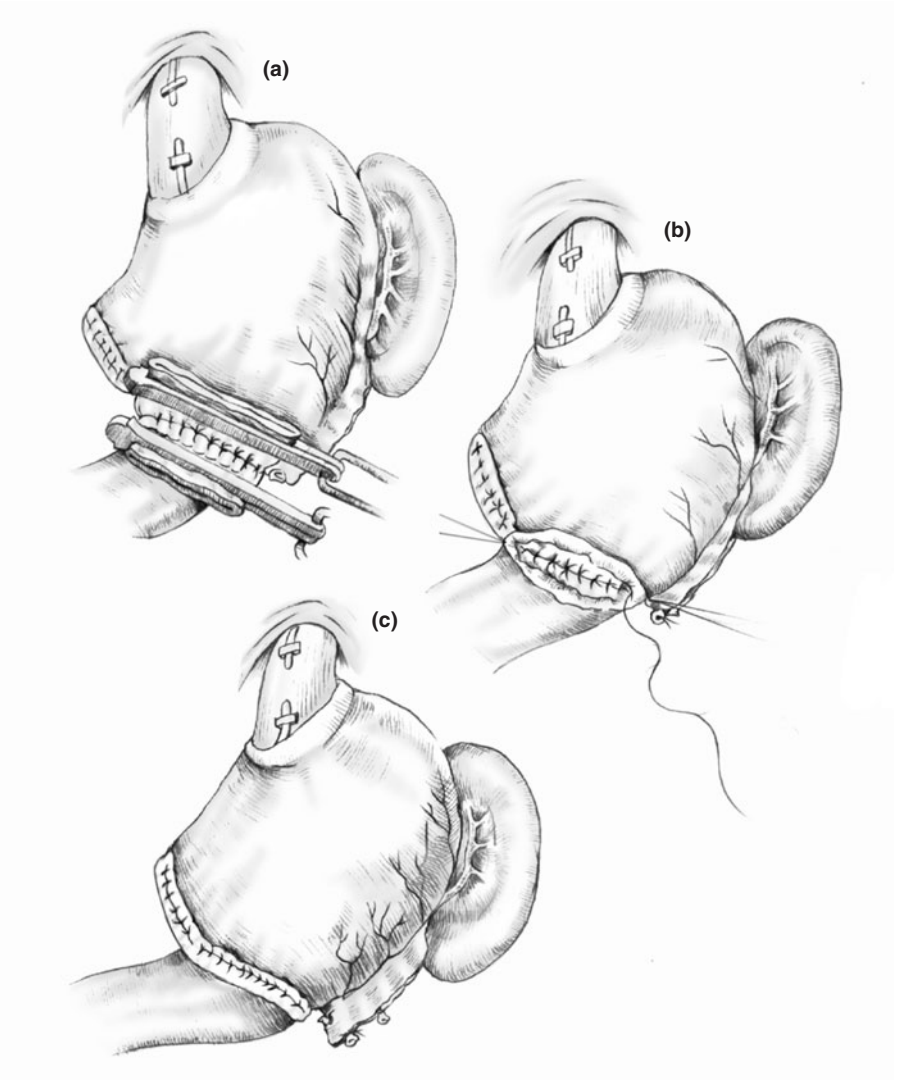

Figure 2-6 Billroth I anastomosis following antrectomy.

2. Billroth II (see Fig. 2-7) (gastrojejunostomy w/closures of duodenal stump—increased incidence of blind loop syndrome)

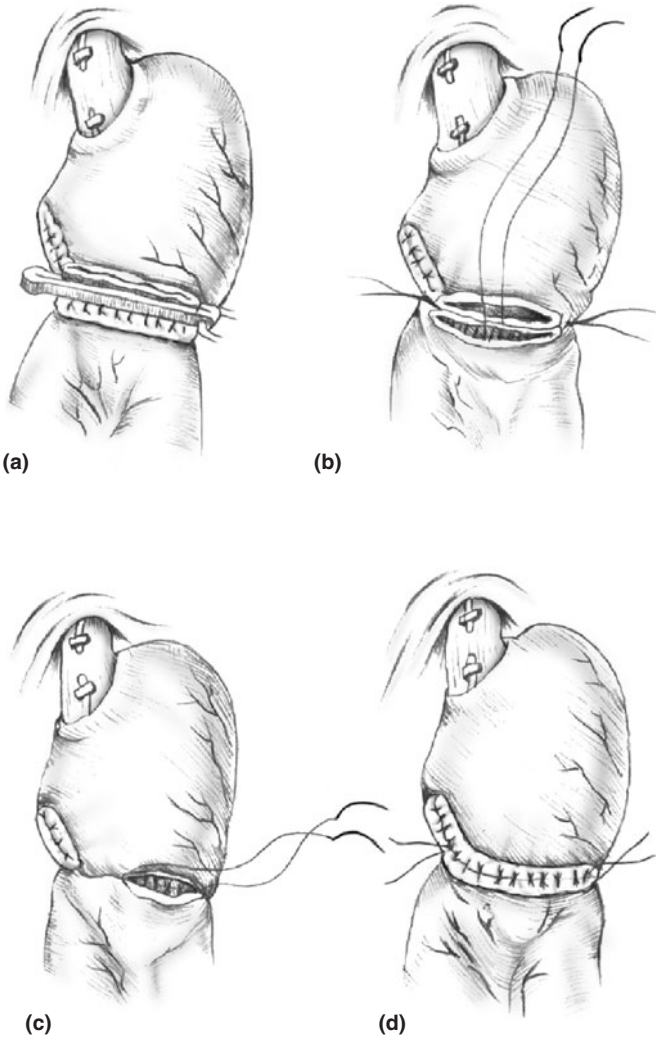

Figure 2-7 Billroth II anastomosis following antrectomy.

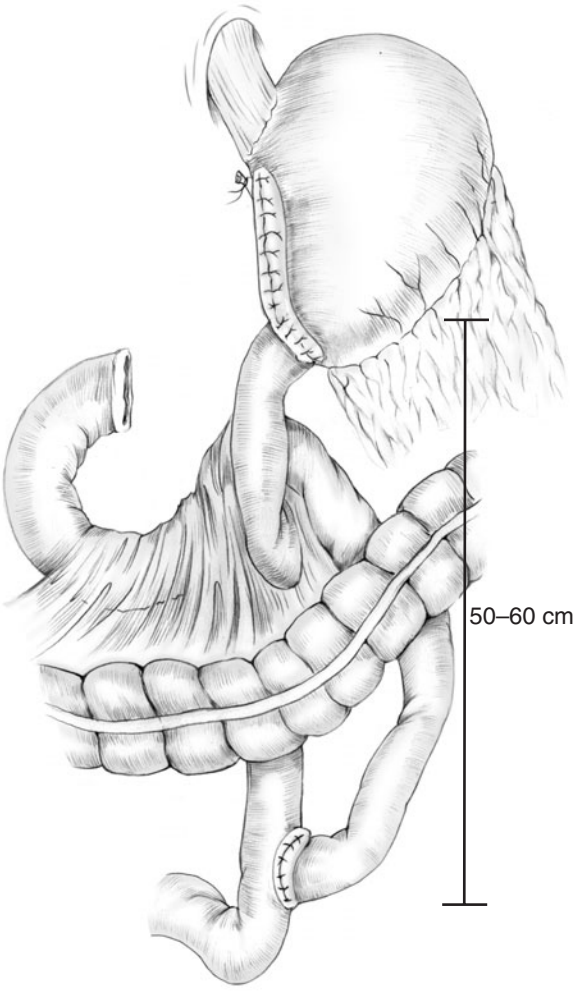

Figure 2-8 Roux-en-Y gastrojejunostomy following antrectomy.

3. Roux-en-Y gastrojejunostomy (see Fig. 2-8)

What is the treatment for a perforated ulcer?

Graham patch (vascularized omental coverage) or resection (see Fig. 2-9)

What are four common postgastrectomy syndromes?

1. **Early dumping syndrome:** high osmolar food causes intravascular volume depletion ~15 min after meal → palpitations, weakness, tachycardia, anxiety, diaphoresis

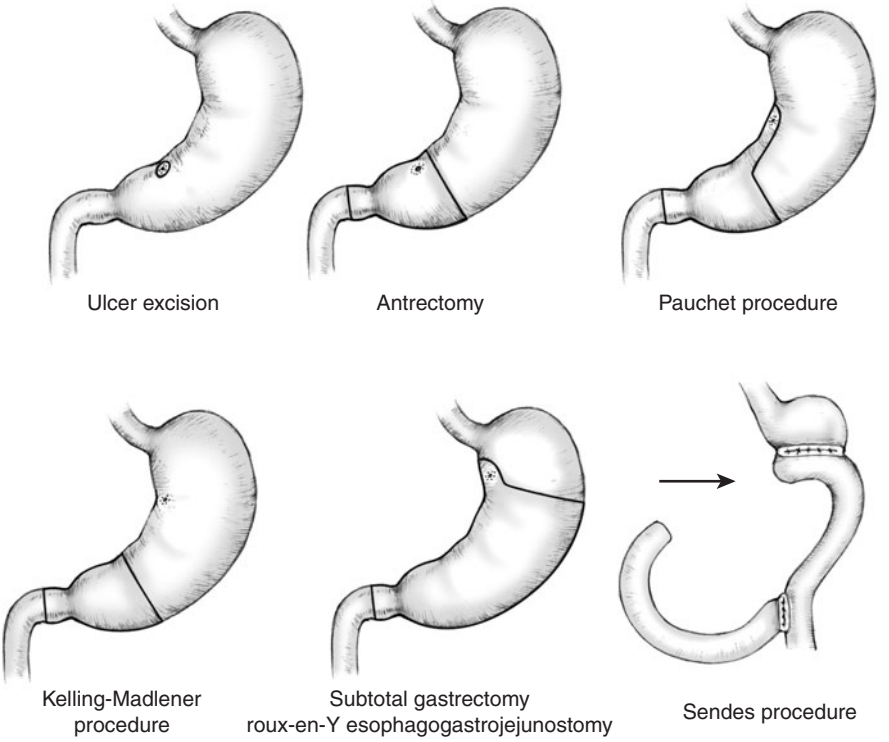

Figure 2-9 Options for resection of gastric ulcer.

2. **Late dumping syndrome**: decreased pyloric tone, causes increased glucose load and absorption in small bowel, resulting in increased insulin and resultant hypoglycemia ~3 h after meal → same symptoms as in early dumping syndrome
3. **Blind loop syndrome**: bacterial overgrowth in closed loop (Billroth II) interferes with folate and B_{12} absorption → (+) schilling, diarrhea
4. **Alkaline reflux gastritis**: (most common) biliary reflux → postprandial epigastric pain, nausea/vomiting, weight loss

What is the likely cause of a recurrent ulcer following vagotomy?	Incomplete vagotomy (intact criminal nerve of Grassi)
Ulcers within the second and third parts of the duodenum are suspicious for what?	Gastrinoma (Zollinger-Ellison syndrome)
What syndrome is this associated with?	MEN I
What are two tests used to diagnose Zollinger-Ellison?	1. High serum gastrin levels (>300 pg/mL) 2. Secretin-stimulation test: increased serum gastrin (>200 above baseline) following intravenous (IV) secretin
What imaging study is used to assess location and metastases of gastrinomas?	Octreotide-labeled nuclear medicine scan
What is the most common anatomic location of gastrinoma?	The gastrinoma triangle is bounded by • Confluence of the cystic duct and common bile duct • Junction of the second and third portion of the duodenum • Junction of the neck and body of the pancreas
What is the preferred treatment of gastrinomas?	Surgical excision
What is the palliative medical treatment for gastrinoma?	Somatostatin
A mass of indigestible fiber is referred to as what?	Bezoar
What are two types of gastric polyps?	Hyperplastic and adenomatous
Which one is associated with risk of malignancy?	Adenomatous
What percent of gastric tumors are malignant?	95% (of which 95% are carcinomas)
What is the most common gastric carcinoma?	Adenocarcinomas encompass all gastric carcinomas
What is the earliest symptom of gastric cancer?	Weight loss (although many are asymptomatic)
What two lab tests are commonly found with GI malignancies?	1. Fe deficiency anemia 2. (+) stool guaiac

079_BOOKZ

What are the three classifications of gastric cancer?	1. Fungating (least common) 2. Ulcerating 3. Diffusely infiltrating (linitis plastica)
Which is the most common?	Ulcerating
Which has the worst prognosis?	Linitis plastica
What is the best predictor of prognosis?	Stage of tumor (TNM—tumor, node, metastases)
What is the best way to establish the diagnosis of gastric cancer?	Endoscopy w/biopsy—"tissue is the issue"—scope all patients with gastric ulcers to evaluate for dysplasia
What are the major risk factors of gastric adenocarcinoma?	• Smoking • Family history including polyposis syndromes • Gastric adenomas • Diet high in nitrates, salt, fat • Atrophic gastritis • Intestinal metaplasia or dysplasia • History of gastrectomy
What is the area of gastric cancer metastatic spread in the following:	
Virchow's node	Left supraclavicular lymph node
Blumer's shelf/drop metastases	Pouch of Douglas (palpated through rectum or vagina)
Krukenberg's tumor	Ovary
Sister Mary Joseph's node	Umbilicus
What is the treatment for gastric cancer	Wide margin resection • Often palliative due to <10% 5-year survival rate

This page intentionally left blank

CHAPTER 3

Small Bowel

What are the three sources of innervation to the gastrointestinal (GI) tract?	1. Sympathetic 2. Parasympathetic 3. Enteric
Which is inhibitory?	Sympathetic (arise from pre- and paravertebral plexuses)
What are the two sources of parasympathetic innervation?	1. Vagus nerve 2. Hypogastric plexus (distal colon)
What two plexuses comprise the enteric nervous system (NS)?	1. Meissner's plexus (submucosal plexus) 2. Myenteric plexus (Auerbach's plexus) Note: The enteric NS is influenced by the parasympathetic and sympathetic NS but primarily responds to local reflexes and continues even in the absence of external input.
What part(s) of the small bowel are retroperitoneal?	Duodenum
What ligament separates duodenum from jejunum?	Ligament of Treitz
What is the blood supply to:	
Duodenum?	Celiac trunk and Superior Mesenteric Artery (SMA)
Jejunum?	SMA
Ileum?	SMA
What is a convenient way to distinguish jejunum from ileum (see Fig. 3-1)?	• Jejunum: 1–2 arcades w/long vasa recta • Ileum: many arcades w/short vasa recta

Copyright © 2008 by The McGraw-Hill Companies, Inc. Click here for terms of use.

079_BOOKZ

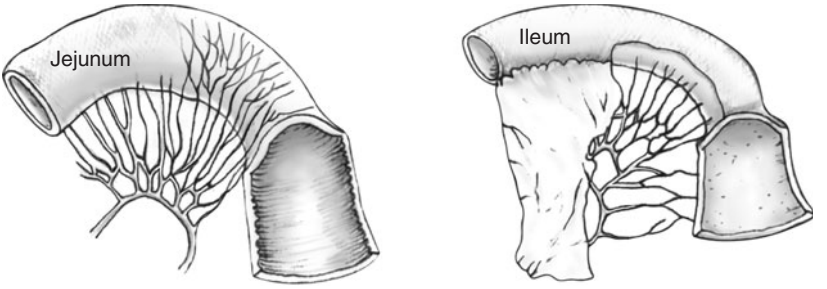

Figure 3-1 Diagram illustrating the long vasa recta of the jejunum and short vasa recta and multiple arcades of the ileum.

What is the strongest tissue layer of the small intestine (see Fig. 3-2)?	Submucosa
What is the most common part of the GI tract involved in malabsorption?	Small bowel
What percentage of the small bowel may be resected without a change in function?	50%
What three areas must be spared to maintain normal bowel function?	Duodenum, proximal jejunum, distal ileum
Match the following symptoms with the area of resection (duodenum, proximal jejunum, distal ileum):	
Gallstones	Distal ileum (decreased bile absorption leads to lithogenic bile)

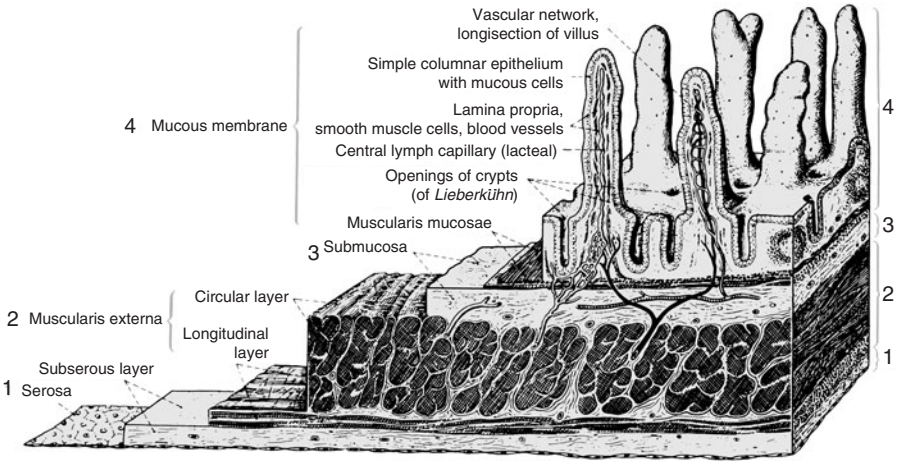

Figure 3-2 Layers of the small intestine. [*Reproduced, with permission, from Brunicardi CF et al (eds): Schwartz's Principles of Surgery, 8th ed. New York: McGraw-Hill, 2005:1019.*]

079_BOOKZ

	and formation of cholesterol gallstones)
Steatorrhea	Distal ileum (decreased bile absorption leads to impaired fat absorption, worsened by osmotic diarrhea of excess bile salts in the colon)
Poor wound healing, osteopenia, neuropathy, prolonged bleeding	Distal ileum (fat soluble vitamin deficiencies A, D, E, and K, respectively)
Kidney stones	Distal ileum (impaired fat absorption leads to binding of calcium to fatty acids, ↑ intraluminal concentration and absorption of oxalate, causing hyperoxaluria)
Megaloblastic anemia	Distal ileum (impaired absorption of vitamin B_{12})
What are common causes of malabsorption?	Celiac disease, short bowel syndrome, pancreatic insufficiency, lactose intolerance, infection
What are symptoms of malabsorption?	• Frequent watery diarrhea causing dehydration and/or pale, smelly, bulky stool • Flatus and bloating • Weight loss • Vitamin and mineral deficiencies
What are treatment options for malabsorption?	Etiology dependent, however, generally: • Small, frequent meals • Total parenteral nutrition (TPN) if severely malnourished • Replacement enzymes if pancreatic insufficiency

APPENDIX

Where is the vermiform appendix located?	Tip of cecum
What landmark can be used to help in locating the appendix?	Junction of the three taenia coli
What is the initiating factor causing appendicitis?	Obstruction of appendiceal lumen

What are the two most common etiologies?	1. Lymphoid hyperplasia (60%) 2. Fecalith (35%) Also consider: foreign body, tumor, parasite
What are the most common ages for acute appendicitis?	5–35 years old
Why these age ranges?	Because they have the greatest concentration of lymph follicles in the appendix
What is a common condition among children before the development of appendicitis?	Viral or bacterial illness
Where is the initial pain located in appendicitis?	Periumbilical or epigastric region
What is commonly associated with the pain?	Anorexia and nausea *after* pain begins
Where does the pain localize as the appendicitis progresses?	Right lower quadrant (RLQ)
Where is McBurney's point?	Outer 1/3 of a line drawn from anterior superior iliac spine to umbilicus (see Fig. 3-3)

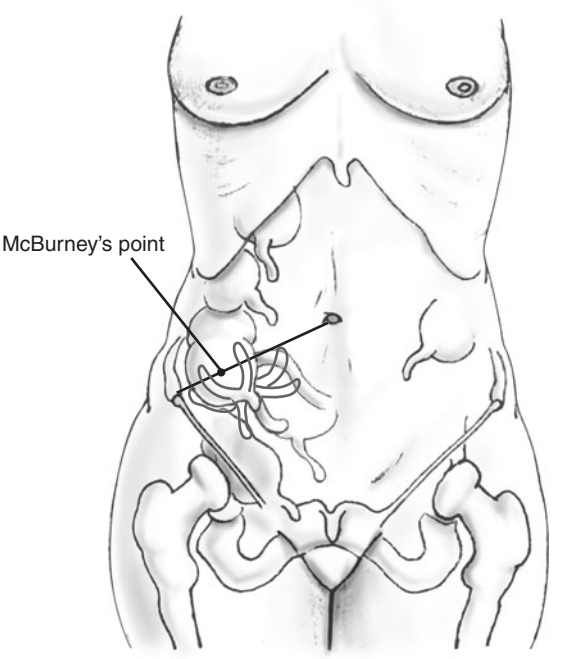

Figure 3-3 Different anatomic locations of the cecum and appendix in relation to McBurney's point.

What are the peritoneal signs common in appendicitis?	Guarding and rebound tenderness (focal peritonitis at RLQ)
Diffuse abdominal pain during appendicitis indicates what?	Diffuse peritonitis from perforation
What are symptoms of peritonitis/ perforation?	• Peritoneal signs (guarding, rebound) • Hypotension • High white blood cell (WBC) • High fever
What are the following signs?	
Rovsing's sign	RLQ pain with palpation of left lower quadrant (LLQ)
Psoas sign	Pain with extension of the right thigh—indicates foci of irritation over psoas muscle; retrocecal appendix
Obturator sign	Pain with internal rotation of a flexed right thigh—indicates foci of irritation over obturator muscle; pelvic appendix
Hamburger sign	Patient requests food = does not have appendicitis
What is the classic position a patient with appendicitis assumes?	On their side with legs drawn up
Diagnosis of appendicitis is based on what?	History and physical if classic. Computed tomography (CT) or ultrasound (US) (ultrasound only in pregnancy and children) to confirm diagnosis.
Atypical signs/symptoms are common in whom?	• Children • Elderly • Pregnant women (displaced appendix) • Patients with retrocecal appendices (less peritoneal irritation)
What other problems in younger females present similar to appendicitis?	• Ectopic pregnancy (obtain beta-hCG or US before CT or surgery) should always be on the differential. • Tubo-ovarian abscess (TOA)/pelvic inflammatory disease (PID)
How do you separate TOA/PID from appendicitis on physical exam?	Cervical motion tenderness

What two other diagnoses present similarly to appendicitis?	1. Crohn's disease 2. Diverticulitis
What type of imaging should be done first?	Plain film of abdomen for fecalith, perforation, or silhouetting of psoas muscle
What are two other imaging techniques commonly used?	1. Ultrasound (kids, pregnancy) 2. Computed tomography
What labs are important for ruling out other causes of RLQ pain?	• UA: few red blood cell (RBC)/WBC suggest no nephrolithiasis or UTI • Beta-hcg to rule out ectopic pregnancy
What two factors suggest complicated (perforated) appendicitis?	1. Temp >102 2. WBC count >18K
What is the treatment for appendicitis?	Appendectomy (see Fig. 3-4)
What is a common complication of appendicitis?	Abscess formation
What is the treatment of an appendiceal abscess?	• Percutaneous drainage • Intravenous (IV) antibiotics and bowel rest until fever and WBC count normalize • Interval (wait 6 weeks) appendectomy
What is the most common tumor of the appendix?	Carcinoid
What is the most common location for carcinoid tumors?	Appendix (40%), small bowel (20%)
What is the rule of 1/3 regarding carcinoid tumors?	• 1/3 metastasize • 1/3 have secondary malignancy • 1/3 are multicentric
What is carcinoid syndrome?	Secretion of serotonin from a metastatic tumor outside of the portovenous system (ie, to the liver)
How does it present?	**Carc**inoid: **c**utaneous flushing, **a**sthma, diarrhea, **c**ardiac arrhythmias
How is it diagnosed?	5-HIAA in the urine (>10 mg/24 h)
How is it treated?	<1.5 cm = appendectomy >1.5 cm = hemicolectomy (highly malignant) octreotide for symptom relief
What cells do carcinoid tumors arise from and where are they found?	Kulchitsky cells in the crypts of Lieberkühn

079_BOOKZ

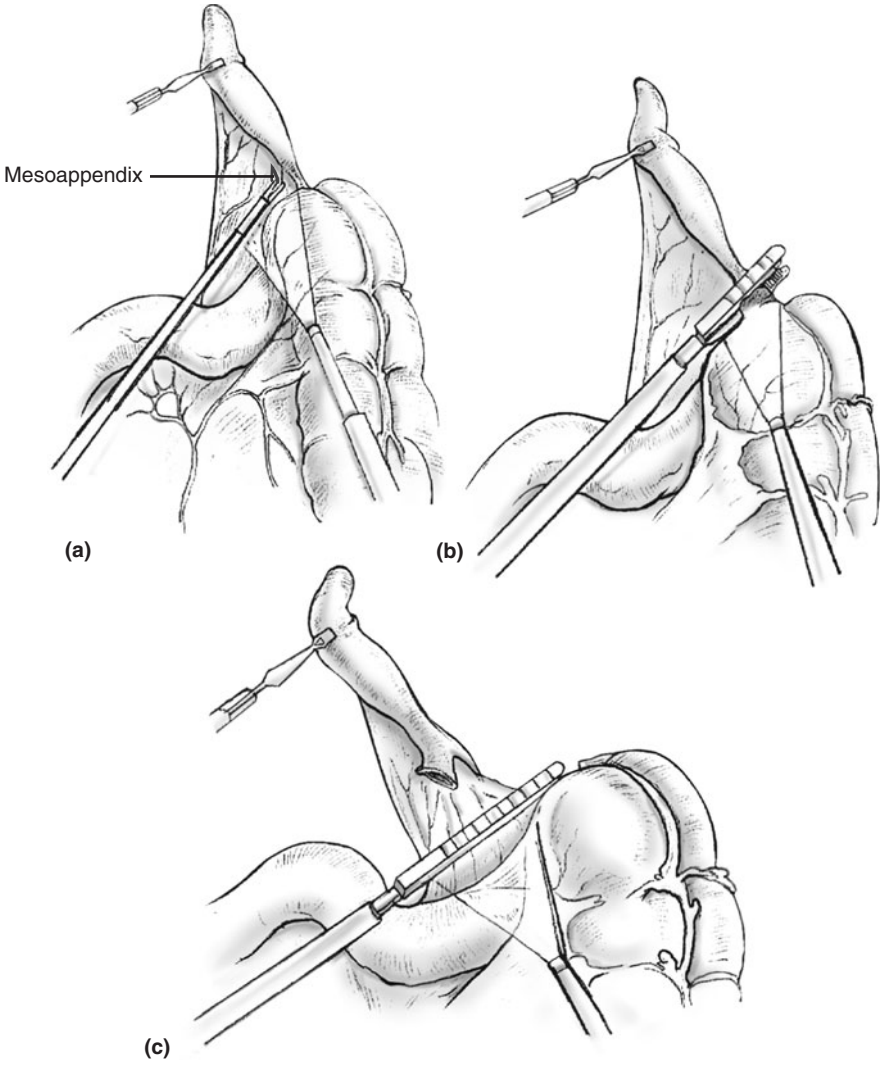

Figure 3-4 Technique of laparoscopic appendectomy.

What other tumors are included in the APUD system?

APUD = amine precursor uptake and decarboxylation (cells with neuroectodermal origin) includes: carcinoid, gastrinoma, insulinoma, glucagonoma, Verner-Morrison syndrome (VIP-oma), somatostatinoma

What hormone is predominately produced from a carcinoid?	Serotonin: patient must have primary/metastasis outside portal venous drainage to develop symptoms due to liver degradation of serotonin.
How are carcinoids diagnosed?	Urinary 5-HIAA (hydroxyindoleacetic acid from liver metabolism of serotonin)—bronchial carcinoids may produce 5-HTP (hydroxytryptophan with normal 5-HIAA)
What is the most common congenital anomaly of the GI tract?	Meckel's diverticulum
What is it a remnant of?	Vitelline (aka omphalomesenteric) duct
What is the rule of 2's?	• **2%** of the population • Presents in first **2** years of life • **2** types of epithelium • **2** ft from ileocecal valve • **2** in long • **2:1** male:female • **2%** are symptomatic
What are two types of epithelium commonly encountered?	Gastric and/or pancreatic tissue
What percentage remain asymptomatic?	95%
How does it typically present when symptomatic?	Young patient with painless hematochezia
What can the symptoms mimic in adults?	Acute diverticulitis
What are complications associated with Meckel's?	Volvulus, intussusception, obstruction, fistulas (umbilical and ileum), hernia (Littre's), tumor (leiomyoma), bleeding ulcer (contain gastric mucosa)
What study establishes the diagnosis of Meckel's diverticulum?	Meckel's scan—a nuclear medicine scan localizing ectopic gastric mucosa or active bleeding
What is the treatment of Meckel's diverticulum?	Surgical resection (You generally only detect it if symptomatic or incidentally, and would resect in these patients. If asymptomatic, it most likely goes unnoticed.) (see Fig. 3-5)
What is the most common cause of small bowel obstruction (SBO) in adults?	Adhesions
What is the most common cause of SBO in children?	Hernias

079_BOOKZ

Figure 3-5 Surgical view of Meckel's diverticulum. [*Reproduced, with permission, from Brunicardi CF et al (eds): Schwartz's Principles of Surgery, 8th ed. New York: McGraw-Hill, 2005:1044.*]

What are other causes of SBO?	Volvulus, intussusception, tumor, gallstone ileus, stricture (due to Crohn's), SMA syndrome
What clinical features distinguish a partial vs a complete SBO?	• Partial: pass gas (flatus) but no bowel movements • Complete: obstipation (no passage of flatus or bowel movements)
What is the typical presentation of a patient with SBO?	Waves of periumbilical, crampy pain relieved with vomiting (vomiting occurs later after pain onset in large bowel obstruction). Early in course, can have diarrhea distal to obstruction
What are the typical findings on physical exam?	Distension, tenderness, infrequent high-pitched bowel sounds with rushes

Figure 3-6 Abdominal x-ray of a patient with small bowel obstruction demonstrating dilated loops of small bowel and air-fluid levels. [*Reproduced, with permission, from Brunicardi CF et al (eds): Schwartz's Principles of Surgery, 8th ed. New York: McGraw-Hill, 2005:1027.*]

What imaging is often diagnostic?	Abdominal x-ray (supine and upright views) (see Fig. 3-6)
What are the characteristics?	• Multiple air-fluid levels • Distended loops of small bowel in a step ladder appearance • Dilation proximal to obstruction with distal collapse • Visible valvulae conniventes • No gas in colon (complete obstruction)
Best test to distinguish partial vs complete SBO?	• CT scan with PO (per orum [by mouth]) and IV contrast. Look for "transition point." • Abdominal plain film 12–24 h after giving PO contrast to look for contrast in colon
Medical management for bowel obstruction consists of what?	Volume and electrolyte management (metabolic alkalosis due to vomiting); nasogastric (NG) tube gastric

	decompression to intermittent low wall suction or sumped NG with continuous low wall suction
How much fluid does the stomach produce in a day?	1.5 L
When should one clamp the NG tube in a patient with partial small bowel obstruction?	If NG output is <500 mL per day, can clamp. Means that at least half is getting through obstruction. Assess for nausea/vomiting (N/V).
The presence of acidosis suggests what?	Necrosis of bowel—likely due to strangulation
What are the surgical indications for an SBO?	Peritonitis, changing abdominal exam, unresolving partial small bowel obstruction
What are the three criteria for determining viability of bowel during surgery?	• Color • Peristalsis • Peripheral arterial pulsations
Define ileus.	Loss of peristalsis in absence of structural obstruction
What are common causes of an ileus?	• Recent surgery • Peritonitis (chemical/bile or bacterial) • Electrolyte abnormalities (especially potassium) • Medications (especially opioids and anticholinergics) • Retroperitoneal process (hematoma, pancreatitis, spinal fracture) • Neuropathic (diabetes mellitus [DM], systemic lupus erythematosus [SLE], multiple sclerosis [MS], scleroderma) • Ischemia • Mechanical causes: intraluminal vs intramural: intraluminal (gallstone ileus, intussusception); intramural (lymphoma, Crohn's, external beam radiotherapy [XRT]). • Extrinsic causes: cancers, adhesions, abscesses
What is the treatment for an ileus?	• Treat etiology (ie, electrolytes, medications, etc) • Decrease/suspend oral intake • Parenteral nutrition if prolonged

IRRITABLE AND INFLAMMATORY BOWEL SYNDROMES

How is the diagnosis of irritable bowel syndrome established?	It is a diagnosis of exclusion
What are common symptoms associated with irritable bowel syndrome?	• "Alternating diarrhea and constipation" • Abdominal pain relieved by bowel movements • Diarrhea and/or constipation that increase with stress
What is not common with irritable bowel syndrome?	• Vomiting • Weight loss • Awakened from sleep
What percentage have comorbid psychiatric disorders?	>50%
What is the treatment of irritable bowel syndrome?	• Fiber supplements • Antidiarrheals (loperamide) • Antispasmodics (anticholinergics) • Tegaserod maleate (acetylcholine, nitric oxide) • Avoidance of caffeine, alcohol, and tobacco

INFLAMMATORY BOWEL DISEASE

Inflammatory bowel disease (IBD) refers to which two diseases?	1. Ulcerative colitis (UC) 2. Crohn's disease
What are the two most common age groups in which IBD occurs and which part of the GI tract is typically involved with Crohn's disease in both groups?	1. Second decade • Small bowel/distal ileum 2. Sixth decade • Colon
Where is the inflammation localized to in:	
Crohn's disease?	Transmural granulomatous
UC?	Mucosa and submucosa
What part of the GI tract is involved in:	
Crohn's disease?	Any part (mouth to anus) can be involved but most commonly distal ileum and colon with *rectal sparring.*
UC?	*Rectum is always involved* with possible proximal extension—remains confined to colon.

079_BOOKZ

What is the term for distal ileitis in ulcerative colitis?	"Backwash ileitis" refers to inflammation of the distal 4 cm of the ileum.
What is the pattern of spread in:	
Crohn's disease?	Discontinuous "skip" lesions
UC?	Continuous pattern
Match the signs/symptoms most associated with either UC or Crohn's:	
Bloody diarrhea	UC
Watery diarrhea	Crohn's
Frequent abdominal pain	Crohn's
Intermittent abdominal pain	UC
Perianal disease	Crohn's (1/3)
Wide, shallow, erythematous, friable ulcers	UC
Narrow, deep ulcers	Crohn's
Fistulas	Crohn's
Weight loss	Crohn's
Pseudopolyps	UC
Granulomas	Crohn's
Crypt abscesses	UC
Toxic megacolon	UC (transluminal inflammation thickens bowel wall in Crohn's)
String sign	Crohn's—stricture of terminal ileum (think: opposite of toxic megacolon)
Increased risk for colon cancer	Both: UC > Crohn's
↑ urgency and frequency for bowel movements	UC—due to proctitis
Abdominal mass	Crohn's—inflammatory mass
Surgery is curative	UC—limited to colon
Recurrence after surgery	Crohn's—can involve GI tract from mouth to anus
Positive antineutrophil cytoplasmic autoantibody (pANCA)	UC (70%)

What is the relationship between smoking and IBD?

- UC is better when patients smoke, if they quit, they flare (**U**se **C**igarettes).
- Crohn's is the opposite. When they quit, symptoms get better.

What are the extraintestinal manifestations of Crohn's and UC?

- Joint: seronegative arthritis
- Skin: aphthous oral ulceration, erythema nodosum, pyoderma gangrenosum
- Ocular: uveitis

What extraintestinal manifestations are more common in UC?

- Axial arthropathies (sacroiliitis and ankylosing spondylitis)
- Primary sclerosing cholangitis

What extraintestinal manifestations are more common in Crohn's?

- Episcleritis
- Nephrolithiasis (from ↑ oxalate absorption)
- Cholelithiasis (disrupted enterohepatic circulation)

Medical management of IBD consists of what?

- Steroids (acute to induce remission, then taper or use chronically)
- Sulfasalazine (UC; chronic)
- TNF (tumor necrosis factor) antibodies (acutely to induce remission)
- Immunosuppressants (chronic)
- Broad spectrum antibiotics
- TPN for bowel rest

What are the surgical indications for IBD?

- Debilitating disease—not treatable medically
- Toxic megacolon/fulminant colitis
- Hemorrhage
- Fistulas
- Abscesses
- Strictures
- Obstruction
- Cancer

Most common indication for surgery in IBD?

Small bowel obstruction

TUMORS

What is the most common location for tumors in the GI tract?

Colon

What is the most common presentation in a patient with small bowel malignancy?

Asymptomatic—often discovered incidentally (however, tumors of the colon may cause bleeding, obstruction, intussusception)

079_BOOKZ

What is more common in small bowel—benign or malignant tumors?	Benign
What is the most common benign small bowel malignancy?	Leiomyomas (smooth muscle origin)
Identify the common syndromes associated with the following benign malignancies:	
Hamartoma	Peutz-Jeghers
Hemangioma	Osler-Weber-Rendu (hereditary hemorrhagic telangiectasia)
What is the treatment of adenomas?	Resection—considered premalignant
What is the best study to diagnose small bowel tumors?	Enteroclysis—a flexible catheter is inserted through the mouth and stomach into the small bowel to inject contrast directly into the small bowel.
What are the most common types of malignant small bowel tumors?	• Adenocarcinomas • Carcinoid tumors (most common) • Leiomyosarcoma • Lymphoma

This page intentionally left blank

CHAPTER 4

Colon

What are the branches of each artery and what part of the colon do they supply (see Figs. 4-1a and b)?	
Superior mesenteric artery	**Superior mesenteric artery:** • Ileocolic: cecum • Right colic: ascending colon • Middle colic: proximal transverse colon
Inferior mesenteric artery	**Inferior mesenteric artery:** • Left colic: distal transverse and descending colon • Sigmoid: sigmoid colon • Superior rectal (hemorrhoidal): rectum
Internal iliac artery	**Internal iliac artery:** • Middle hemorrhoidal: distal rectum • Inferior hemorrhoidal: anus
What is significant about the blood supply to the splenic flexure and distal rectum?	These are watershed areas between two vessels with relatively poor circulation, causing a high risk of ischemia from anastomoses.
What part(s) of the colon are intraperitoneal?	Transverse, sigmoid, and cecum
What is the most common anaerobic bacterium in the colon?	*Bacteroides fragilis*—99%
What is the most common aerobic bacterium in the colon?	*Escherichia coli*
Define hematemesis.	Vomiting of blood—either bright red or coffee grounds (from contact with gastric acid)
What does it indicate?	Upper gastrointestinal (GI) (proximal to ligament of Treitz)

Copyright © 2008 by The McGraw-Hill Companies, Inc. Click here for terms of use.

079_BOOKZ

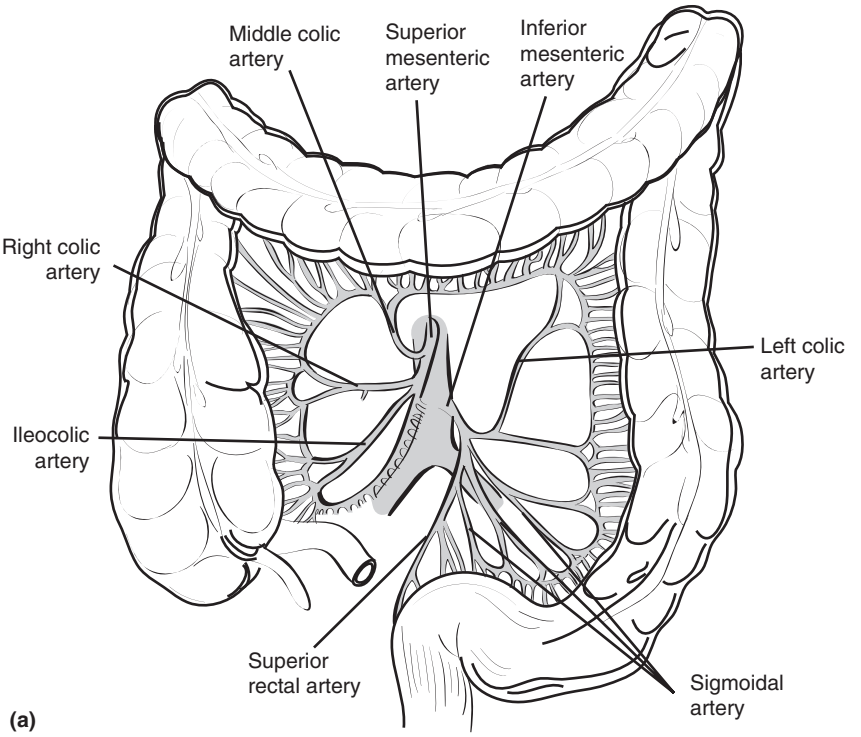

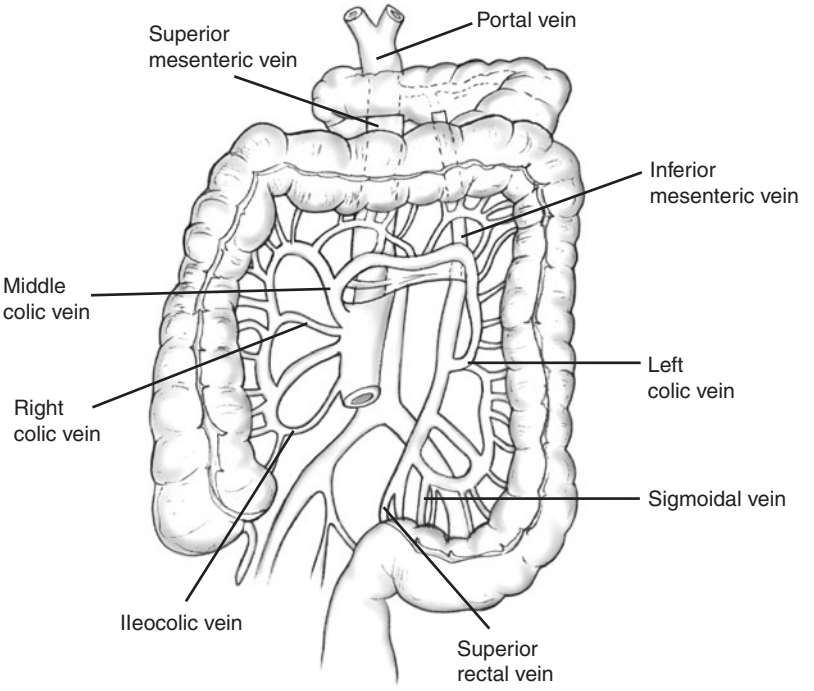

Figure 4-1 (a) Arterial and (b) venous blood supply of the large bowel.

079_BOOKZ

Define hematochezia.	Bright red blood per rectum
What does it indicate?	Lower GI bleed or brisk upper GI bleed
Define melena.	Black, tarry stools, often foul smelling
What does it indicate?	Upper GI bleed or small lower GI bleed
Define tenesmus.	Intense, painful, fruitless desire to defecate
What does it indicate?	Inflammatory bowel disease (IBD), proctitis, space-occupying lesion (abscess, rectal cancer)
What are the two reasons not to perform a digital rectal exam?	1. Patient doesn't have an anus. 2. You don't have a finger. (Be careful if patient has acute bacterial prostatitis for risk of bacteremia.)
What are the two types of diverticular disease of the colon and where are they most frequently found?	1. **True/congenital:** rare, contain all bowel wall layers and are usually near cecum 2. **False/acquired:** common, mucosal herniation at weak points (ie, penetration of arteries) most commonly the sigmoid colon
What is a likely etiology of acquired diverticular disease?	• Motility dysfunction involving simultaneous contractions of two contiguous bowel segments resulting in high localized pressure between the segments. • Due to chronic increased contractions involving low-volume, hard stool.
Diverticulosis refers to what?	Multiple false diverticula (outpouching)
What is the most common presentation of diverticulosis?	Asymptomatic (80%)—discovered incidentally
What are the most common signs/symptoms of diverticulosis?	Recurrent abdominal pain (usually left lower quadrant [LLQ]), diarrhea and constipation, painless hematochezia—secondary to hypermotility
What is the treatment for diverticulosis?	Recommend increased fiber intake

What are two common causes of acute GI bleed in a patient >40 years?	Diverticulosis and angiodysplasia (aka arteriovenous malformation)
What must be ruled out as a source of GI bleeding in patients >40?	Colon cancer
Where does angiodysplasia most commonly occur?	Right colon
How is angiodysplasia diagnosed and treated?	With colonoscopy and subsequent electrocoagulation
What is diverticulitis?	Obstruction of diverticula (ie, fecalith) leading to inflammation. Similar to appendicitis (aka: LLQ appendicitis)
What are the signs/symptoms of diverticulitis?	Steady LLQ cramping pain, constipation/diarrhea, fever, nausea and vomiting (n/v), leukocytosis, +/− palpable mass—perforation will display peritoneal signs → similar to appendicitis
What imaging is recommended for acute diverticulitis?	Abdominal x-rays for perforation and computed tomography (CT) for pericolic inflammation and abscess
What imaging is contraindicated?	Barium enema and flexible sigmoidoscopy or colonoscopy. The insufflation of gas or contrast may cause perforation
What is the treatment for diverticular bleeding?	Usually supportive (hydration and transfusion)—70% spontaneously stop and 30% will need surgical intervention
What is the most common cause for a lower GI bleed?	An upper GI bleed
What are common causes of a GI bleed?	**ABCDEFGHI**: **A**ngiodysplasia **B**owel cancer **C**olitis **D**iverticulitis/**D**uodenal ulcer/Diverticula (Meckel's) **E**pistaxis/**E**sophageal (cancer, esophagitis, varices) **F**istula (anal, aortoenteric) **G**astric (cancer, ulcer, gastritis) **H**emorrhoids **I**nfectious diarrhea/**I**BD/**I**schemic bowel

079_BOOKZ

How do you rule out an isolated or concurrent upper GI bleed?	With a nasogastric (NG) tube aspiration—be careful of patients with esophageal varices
What is the treatment for diverticulitis?	Bowel rest (nothing by mouth, *nihil per os* [NPO]) and broad spectrum antibiotics
For recurrent (greater than one) admissions or complications (abscess or fistula)?	Elective sigmoid colectomy with primary anastomosis
For perforation?	Resection of sigmoid colon with a colostomy and a Hartmann pouch
What are the indications for emergency laparotomy in diverticulitis?	Deterioration of clinical condition and/or development of diffuse peritonitis
In elective sigmoidectomy for diverticular disease, how much colon should be removed?	• Distally, the resection should extend to the rectum • Proximally, the resection should extend to an area that is grossly normal. Not all diverticula need to be removed, just the grossly diseased (inflamed, thickened) portions.
What are common complications of diverticulitis?	Fistulas (especially colovesical in men), abscess, phlegmon (pericolic and sigmoid)
What is a phlegmon?	Localized cellulitis
What is an "acute abdomen"?	A "surgical abdomen," characterized by peritonitis on physical exam
What are the signs/symptoms of peritonitis?	Diffuse abdominal pain, **rebound tenderness**, guarding, fever, hypotension
What are the common microorganisms responsible for peritonitis?	Gram-negative bacilli (especially *E. coli*), streptococcus group D, *Bacteroides fragilis* • For trauma, also staph • For peritoneal dialysis, also yeast
What position(s) do patients assume with:	
Peritonitis?	Patient lies as still as possible in supine position; pain is constant.
Colic (biliary, renal, bowel obstruction)?	Patient is constantly moving, unable to lie still, cannot find comfortable position; pain fluctuates.

What is the difference in neural pathways of these two types of pain?

1. Colic is mediated by visceral pain fibers which localizes in diffuse regions.
2. Peritoneal pain is mediated by somatic pain fibers which innervate the abdominal wall.

What antibiotics are used to treat peritonitis?

- Ampicillin/sulbactam for gram-negative bacillus (GNB) and strep D
- Clindamycin or metronidazole for anaerobes
- Vancomycin if staph is suspected
- Commonly, regimens also include piperacillin/tazobactam alone (Zosyn), ciprofloxacin and metronidazole

What antibiotics have been most associated with pseudomembranous colitis?

Clindamycin and ampicillin (however any antibiotic may be implicated) due to suppression of normal colonic bacteria

What is the causative organism?

Clostridium difficile: overgrowth elaborates two exotoxins causing chronic inflammation

What are the signs and symptoms?

Following antibiotic therapy: watery, nonbloody diarrhea, fever, leukocytosis, abdominal pain

How is it diagnosed?

C. difficile toxin titer in stool sample

What is the drug of choice?

Metronidazole (by mouth, per os [PO])

For refractory cases?

Vancomycin (PO and/or per rectum [PR])

MESENTERIC ISCHEMIA

What is the classical physical exam finding associated with mesenteric ischemia?

"Pain out of proportion to exam"

What lab values are abnormal with dead bowel?

- Elevated white blood cells (WBCs) (often >20,000)
- Increased arterial lactate

What are the imaging modalities used in suspected mesenteric ischemia?

- CT with IV and PO contrast

What is the treatment of acute mesenteric ischemia due to:

Fluid resuscitation and antibiotics as soon as possible if suspected

079_BOOKZ

Embolization?	Surgical embolectomy and anticoagulation; "second look" laparotomy to assess ischemia; hypercoagulable workup
Thrombus?	Aortomesenteric bypass, resection of nonviable bowel
Nonocclusive?	Local intra-arterial infusion of vasodilators, supportive care
When is percutaneous transluminal angioplasty and stent used for mesenteric ischemia?	Reserved for patients with chronic mesenteric ischemia who have high surgical risk
How much small bowel is necessary to sustain life?	50 cm if ileocecal valve is present
Postprandial abdominal pain/bloating, food fear leading to weight loss and an abdominal bruit in a patient with atherosclerotic disease (cerebrovascular accident [cva], coronary artery disease [cad]) suggest what?	Chronic mesenteric ischemia due to atherosclerotic thrombus
Progressive, insidious onset abdominal pain and distention out of proportion to physical exam are common symptoms of what?	Mesenteric venous thrombus
What is this associated with?	Hypercoagulable state (cancer, hematological disorder, infection, etc)
What must be ruled out?	Bowel obstruction

OBSTRUCTION

What are the two most common causes of small bowel obstruction (SBO)?	Adhesion and hernia
What are additional causes more common in the elderly?	Volvulus, gallstone ileus, tumor (obstruct or leading point of intussusception)
What are the typical symptoms associated with small bowel obstruction?	Cramping periumbilical pain w/ intermittent vomiting—may be feculent if distal obstruction
Signs?	Infrequent high-pitched bowel sounds w/occasional rushes
What is obstipation?	No passage of flatus or stool
What does it indicate?	Complete obstruction

What are the typical findings on abdominal supine and upright radiographs?	Multiple air fluid levels producing step ladder appearance, proximal dilation, distal collapse, look for free air under diaphragm
How does one distinguish large from small bowel?	Identify valvulae conniventes (transverse entire small bowel)
What other condition presents similar to SBO?	Paralytic ileus
How can this best be differentiated?	Abdominal films show air evenly distributed in small and large bowel—barium enema if uncertain
Best test to distinguish partial vs complete small bowel obstruction?	• Abdominal CT with IV and PO contrast. • If in question, get abdominal plain film at 12 and 24 hours. See contrast in colon if partial. • Continue to assess patient with serial abdominal exams. Peritonitis gets surgery.
What is the treatment for:	
Partial SBO?	Correct electrolyte imbalances, supportive (NG decompression, NPO), surgery if symptoms worsen or symptoms lasting >3 days
Complete SBO?	Correct electrolyte imbalances, then surgery
Ileus?	Correct cause (drugs, electrolyte imbalance, infection, etc), NG suction and parenteral feeds
What are the typical symptoms of a large bowel obstruction?	Same as SBO (especially if incompetent ileocecal valve); however, less emesis that presents at a later stage and is often feculent
What are common causes of large bowel obstruction (LBO) in adults?	Carcinoma (70%), scarring inflammatory (20%) (ulcerative colitis [UC], diverticulitis, radiation), volvulus (5–10%), fecal impaction (adhesions very uncommon)
Where is the most common site for volvulus?	Sigmoid (70%)
What is the greatest risk factor?	Age (usually >50 years of age)

079_BOOKZ

How is it evaluated and treated?

Same as causes of LBO:
- Evaluation: abdominal x-ray, (barium enema if uncertain—use water soluble contrast if perforation suspected)
- Treatment: sigmoidoscopy and rectal tube decompression, surgery (cecal volvulus always surgically repaired –1/3 mortality rate if perforation occurs)

How does adult treatment for intussusception differ from pediatric intussusception treatment?

- Clinical presentation—just like a small or large bowel obstruction. Rarely feel mass. Rarely have "currant jelly" stool.
- Unlike pediatric intussusception, adult intussusception warrants laparotomy and resection given the high incidence of malignancy—reduce and resect lead point (suspect cancer)

What imaging modality is used to diagnose adult intussusception?

Abdominal CT scan

COLORECTAL CARCINOMA

What are the risk factors for colorectal carcinoma?

- Age (90% of cancer diagnosed in patients >50 years of age)
- Family history (especially first degree relative <50 years of age)
- IBD (UC > Crohn's)
- Hereditary syndromes (hereditary nonpolyposis colorectal cancer [HNPCC—Lynch syndrome I and II], familial adenomatous polyposis [FAP][100%] [Gardner's syndrome], diffuse juvenile polyposis [both hamartomas and adenomas])
- Adenomas/history of colorectal cancer
- Diet: low fiber/high fat

Where is the most common location of a polyp?

Rectosigmoid area ~50% (almost all villous polyps are located in the distal colon)

Identify whether the following benign types of polyps have malignant potential:	
Hyperplastic	No
Hamartoma	Low
Inflammatory	No
Adenoma	
Tubular	~10%
Villous	~1/3
What is the most common type of polyp?	Hyperplastic (~50% of adults)
How are they treated?	Without atypia polyps can be endoscopically resected and observed
What is a hamartoma?	Mass of disorganized tissue indigenous to the particular site
What two conditions are they associated with?	Peutz-Jeghers syndrome and juvenile polyps
How are they treated?	Observation; excision if symptomatic
What are two types of inflammatory polyps?	Pseudopolyps (associated with UC) and lymphoid polyps (nonspecific infectious cause)
How are they treated?	Observation
What is the most common type of adenoma?	Tubular adenoma (~75%)
What is the treatment for:	
Tubular adenoma?	Endoscopic polypectomy
Villous adenoma?	Endoscopic polypectomy (if small) or segmental colectomy Note: Remove all adenomas regardless of morphology
What is the malignancy potential of a polyp 2+ cm?	50%
What are the three genes typically involved in malignant transformation of an adenoma?	1. APC tumor suppressor (causes FAP) 2. Kras oncogene 3. p53 tumor suppressor
How long is it believed to take for an adenoma to progress to cancer?	10 years

079_BOOKZ

At what age should asymptomatic individuals be screened for colorectal cancer?	50 years of age
What if they have a first degree relative diagnosed with colorectal cancer?	10 years before the age of diagnosis of the relative with colorectal cancer
What are approved screening methods and how frequently are they needed?	• Fecal occult blood test every year • Flexible sigmoidoscopy or barium enema every 3–5 years—must evaluate with colonoscopy if polyp detected with either method • Colonoscopy every 10 years
How is colon cancer staged?	• Duke's classification—based on depth of invasion • TNM classification
What does TNM stand for?	• T: tumor invasion depth • N: lymph node involvement • M: distant metastasis
What is the most important prognostic variable in staging colon cancer?	Lymph node involvement
Right-sided colon carcinomas typically grow as what type of structure?	Exophytic, fungating, and bulky lesions
What is the typical presentation?	• Occult blood loss with iron deficiency anemia • Weight loss, abdominal pain or mass (advanced cases) • Obstruction is rare (due to large diameter bowel with liquid consistency of stool in proximal colon).
Left-sided colon carcinomas typically grow as what type of structure?	Annular, "apple core or napkin-ring," often invasive
What is the typical presentation?	• Change in bowel habits (constipation, diarrhea, ostipation) • "Pencil" stools (small caliber) • Obstruction symptoms (cramping)
What is the treatment of colon cancer?	Surgical resection including the lymphatic drainage basin (12 lymph nodes in specimen is adequate resection) with 3–5 cm margins, can resect isolated liver metastases

Why must the arterial supply at the origin be resected?

Because the lymphatics follow the arterial supply.

What lab tests are used to follow patients after colon cancer resection?

CEA (carcinoembryonic antigen), LFTs (liver function tests) (liver is the most common organ involved in metastases), stool guaiacs

079_BOOKZ

CHAPTER 5

Anorectal

What is the dentate line (see Fig. 5-1)?

The anatomic transition from endodermal origin rectal mucosa to ectodermal origin anoderm

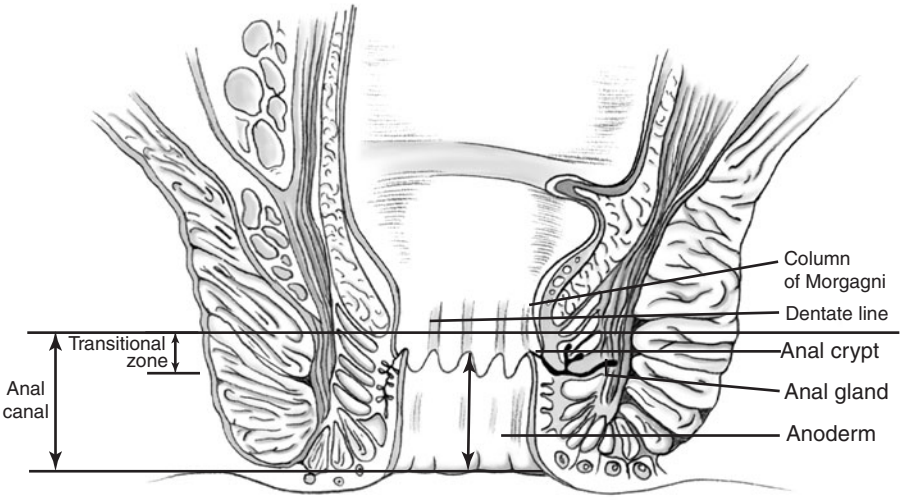

Figure 5-1 Diagram of the anal canal displaying anatomy of the dentate line.

Young man with localized pain and swelling to sacrococcygeal area is typical for what?

Pilonidal disease (from obstruction of hair follicle causing inappropriate hair growth with foreign body reaction and infection)

What is the treatment for pilonidal disease?

1. Acute abscess—incision and drainage of abscess
2. Chronic sinus tract = excision with: closure by secondary intention or marsupialization

Copyright © 2008 by The McGraw-Hill Companies, Inc. Click here for terms of use.

079_BOOKZ

What are the two types of hemorrhoids and how do they differ?	1. Internal hemorrhoids—above dentate line, are not painful, covered with columnar epithelium 2. External hemorrhoids—below dentate line, painful, covered with squamous epithelium
What are the causes of hemorrhoids?	Engorged anal cushions and vessels from increased pelvic/abdominal pressures: • Constipation/straining • Pregnancy • Ascites/abdominal tumors • Portal hypertension
What are the typical signs/symptoms of hemorrhoids?	Bleeding (bright red, covering—not mixed with stools—may be mild to severe causing anemia), pruritus, pain (thrombosed external hemorrhoids), perianal moistness (with prolapsed internal hemorrhoids)
Are internal hemorrhoids painful?	No
Are external hemorrhoids painful?	Yes
How are internal hemorrhoids classified?	By degree of prolapse 1. First degree: no prolapse 2. Second degree: prolapse with spontaneous reduction 3. Third degree: prolapse with manual reduction 4. Fourth degree: permanently prolapsed
What are the available treatment options for hemorrhoids?	
External	External: prevent with bulk forming agents/stool softeners; symptom relief with sitz baths and analgesics; self limited 1–2 weeks; excision if severe pain
Internal	Internal: depends on degree of prolapse • First: bulk forming agents/stool softeners; rubber band ligation or infrared coagulation • Second: rubber band ligation • Third: rubber band ligation or hemorrhoidectomy • Fourth: hemorrhoidectomy

079_BOOKZ

Extreme sharp/burning rectal pain associated with bowel movements and minimal bright red blood coating stools suggests what?	Anal fissure (most common cause of rectal bleeding in 0–2 years of life)
What is the most common cause?	Trauma (constipation, diarrhea, colonoscopy, surgery)
Where are they typically located and why?	Posterior midline of anus. ~10% of women have anterior midline lesions—weakest muscular support
Multiple, atypical appearing, or ectopic location of anal fissures suggest what?	Underlying disease: sexually transmitted disease (STD) (*Chlamydia*, gonorrhea, herpes, syphilis, acquired immunodeficiency syndrome [AIDS]), tuberculosis (TB), leukemia, inflammatory bowel disease (IBD)
What is the triad of secondary changes associated with chronic, recurrent fissures?	1. Hypertrophied anal papilla 2. Sentinel tag 3. Anal stenosis (from fibrosis or spasm of internal sphincter)
What are the treatment options for:	
Acute anal fissures?	Bulk forming agents and stool softeners (↓ trauma [diarrhea/constipation])
Chronic anal fissures?	Lateral internal sphincterotomy (relieves spasm) w/ medical management; anal dilation (↑ risk of incontinence)
A patient with acute onset fever, perianal pain, redness, swelling, and purulent discharge with mass on exam suggests what?	Anorectal abscess
Where do they originate?	Anal crypts between the internal and external sphincters (intersphincteric) perianal abscess = does not cross sphincters ischiorectal abscess = transverses external anal sphincter supralevator abscess = spreads superior to levator
How are they treated?	Incision and drainage (with antibiotics if cellulitis or immunocompromised)

Chronic purulent and fecal drainage and recurrent abscess with cord-like tract palpated on exam suggests what?

Fistula *in ano* (occurs at the level of the dentate line)

What are two causes associated with their development?

Anorectal abscess (~50% develop fistula)
Crohn's disease

Fistulas above the dentate line are typically associated with what two causes?

Inflammation (diverticulitis) or trauma

What is Goodsall's rule (see Fig. 5-2)?

Predicts the course of a fistula: with patients in a lithotomy position a transverse line is drawn through the anus parallel to the floor.

- External openings anterior to this line have straight trajectories to anus.
- External openings posterior to this line have curved trajectories to the posterior midline of anus.

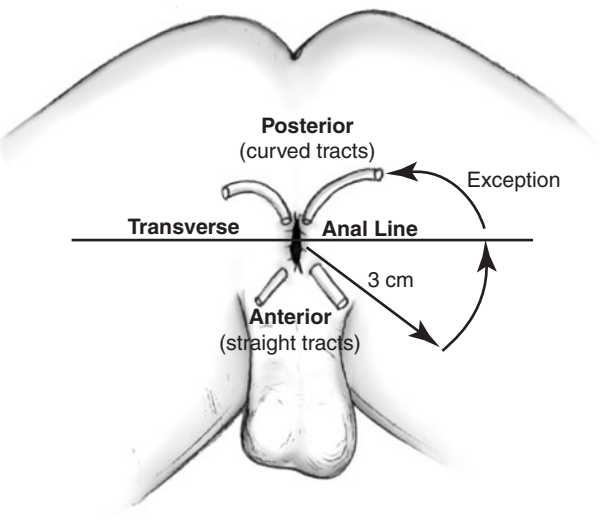

Figure 5-2 Goodsall's rule of fistula origin.

What is the exception?

Anterior external openings that are >3 cm from anus typically curve to connect to the posterior midline of anus

Fistulas which do not follow Goodsall's rule raise suspicion for what?

Inflammatory bowel disease or rectal carcinoma

What is the treatment for fistulas?

Fistulotomy (unroofing) with the known risk of causing incontinence

What are three common mechanical causes of obstructed defecation?

1. Rectal prolapse
2. *Condyloma acuminatum*
3. Anal cancer

FISTULAS

Define fistula.

An abnormal connection between two epithelialized structures.

What are some common causes of fistula formation?

- Trauma: labor
- Iatrogenic: surgery, radiation, intended (G-tubes)
- Diseases: IBD, neoplasm
- Infectious: diverticulitis, abscess
- Congenital: VATER (**V**ertebrae, **A**nus, **T**rachea, **E**sophagus, and **R**enal) syndrome

What are common conditions preventing fistulas from closing?

- **F**oreign body
- **R**adiation/**R**ate (high output)
- **I**nfection/**I**nflammation
- **E**pithelialization
- **N**eoplasia
- **D**istal obstruction
- **S**hort wide tract

"**FRIENDS** of fistulas"

Define the two organs involved with the following fistulas and what conditions they are associated with:

Colovesical	Colon to bladder—diverticulitis
Enterocutaneous	Stomach/intestine (small or large) to skin—surgery/Crohn's disease
Enteroenteral	Intestine to intestine—surgery/Crohn's disease
Vesicovaginal	Bladder to vagina—surgery (fibroids, hysterectomy)
Fistula in ano	Anus to perirectal skin—perianal abscess

Match the symptoms with the likely fistula.

1. Surgical history, painless urinary incontinence	1. Vesicovaginal
2. Recurrent UTI (urinary tract, infection) pneumaturia, palpable mass	2. Colovesical (also have fecaluria)
3. Diarrhea, malabsorption, dehydration	3. Enteroenteral
4. Constant drainage of pus and stool from anus	4. Fistula in ano

What is the underlying cause of most anal cancer? HPV (human papilloma virus)

079_BOOKZ

CHAPTER 6

Spleen

From what embryonic tissue is the spleen derived?

Mesoderm (also the splenic ligaments). Incomplete fusion of dorsal mesogastrium results in accessory spleens

Where are accessory spleens most commonly found (see Fig. 6-1)?

Splenic hilum

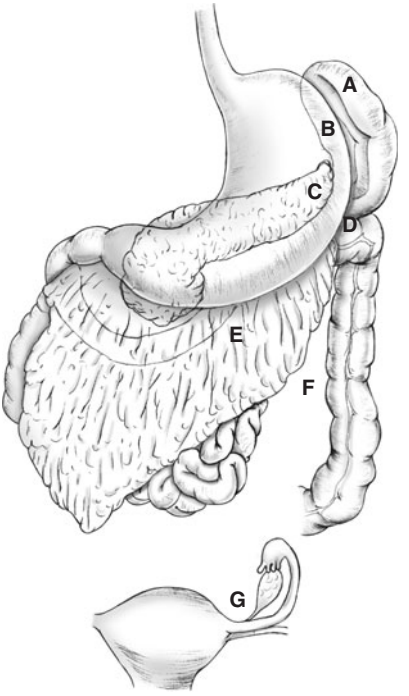

Figure 6-1 Sites where accessory spleens are found in order of importance. A. Hilar region, 54%. B. Pedicle, 25%. C. Tail of pancreas, 6%. D. Splenocolic ligament, 2%. E. Greater omentum, 12%. F. Mesentery, 0.5%. G. Left ovary, 0.5%.

Copyright © 2008 by The McGraw-Hill Companies, Inc. Click here for terms of use.

079_BOOKZ

What are the four peritoneal "ligaments" that hold the spleen in place (see Fig. 6-2)?

1. Phrenosplenic
2. Splenorenal
3. Gastrosplenic
4. Splenocolic

Which contains:

Splenic vein/artery and tail of pancreas? Splenorenal

Short gastric vessels? Gastrosplenic

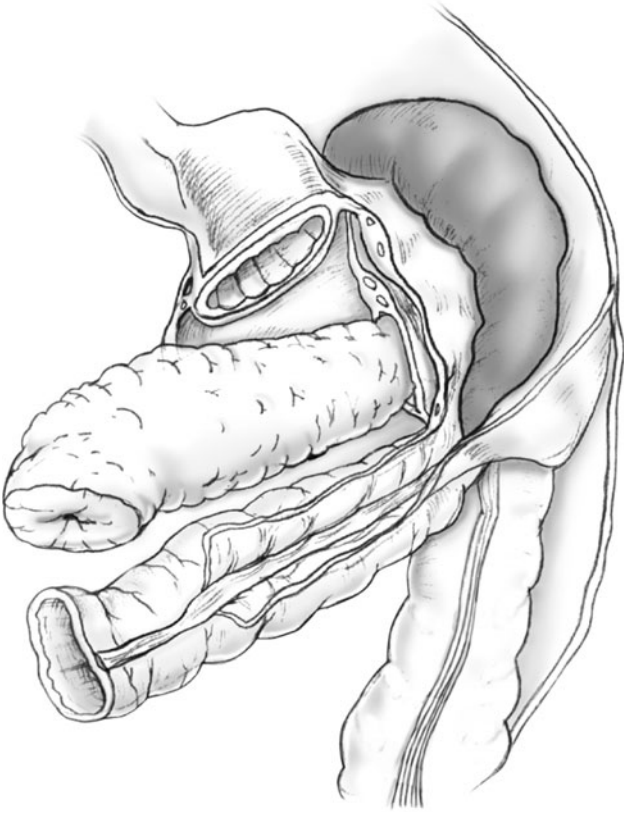

Figure 6-2 Peritoneal ligaments of the spleen.

What is the condition in which the ligaments are not formed (or laxity of ligaments)? "Wandering" spleen

How is it treated? Splenopexy. Splenectomy if torsion is evident on contrast computed tomography (CT), which is diagnosed by a lack of contrast seen in the spleen.

079_BOOKZ

Which ribs overlie and protect the spleen?	Eighth to eleventh on left side. If fractured, suspect splenic injury ~10%.
What is polysplenia?	Absence of normal spleen in the presence of multiple, small spleens—often associated with multiple congenital anomalies
Is the splenic vein portal or systemic?	Portal
Where does the splenic vein lie in relation to the pancreas?	Posterior (may develop thrombus from local inflammation due to pancreatitis)
What is the result of splenic vein thrombosis?	Gastric varices (not usually esophageal varices, which result from backup of the coronary vein)
What is the treatment of splenic vein thrombosis?	Splenectomy, which cures both hypersplenism and gastric varices
Risk factors for splenic vein thrombosis (or mesenteric vein thrombosis)?	• Pancreatitis • Pancreatic pseudocyst • Hypercoagulable states (protein C/S deficiency, polycythemia vera, malignancy, oral contraceptives) • Blunt trauma • Abdominal surgery • Infection • Smoking • Peptic ulcer disease (PUD) • Idiopathic (up to 50%)
Splenic artery is a branch of what major artery?	Celiac trunk
What other arteries supply the spleen?	Short gastrics (branches of the gastroepiploic), which may cause significant bleeding during splenectomy
What are the hemotologic functions of the spleen?	• Assists in maturation of red blood cells (RBCs) • Filters deformed and old RBCs • Sequesters platelets (over one-third) • Removes abnormal white blood cells (WBCs), platelets, and cellular debris
What are the immunologic functions of the spleen?	• Reticuloendothelial system and opsonin production, which assists in phagocytosis and activation of complement system, especially with encapsulated organisms

- Production of properdin and tuftsin
- Antibody synthesis (IgM)
- Clearing bacteria

Removal of the spleen predisposes to what type of infection?

Polysaccharide encapsulated bacterial infection termed overwhelming postsplenectomy infection (OPSI)

What are the most common organisms involved in postsplenectomy infection?

Streptococcus pneumoniae, *Haemophilus influenzae* type B, meningococcus and group A streptococci.

What are the two microcirculations present in the spleen?

1. Open circulation—arteriole capillaries drain freely into spleen parenchyma then drain into venous sinus fenestration.
2. Closed circulation—arteriole capillaries are contiguous with venous capillaries within the red pulp

What clinical implications do these have?

Spleen is extremely vascular and bleeds readily on disruption of the capsule

What are the two types of pulp in the spleen?

1. Red pulp—vascular component with branching thin walled sinuses with intervening areas with phagocytes and WBCs known as splenic cords
2. White pulp—immunologic component, three types—periarteriolar lymphoid sheets (T cells), lymphoid nodules (B cells), marginal zone

What is hypersplenism?

Splenic "hyperactivity" resulting in increased destruction and/or sequestration of circulating RBCs, WBCs, and platelets, resulting in pancytopenia

How does this differ from splenomegaly?

Splenomegaly is a physical sign. Hypersplenism is a physiologic condition

What does tender splenomegaly suggest?

Splenic infarction, infection, or trauma. Typically splenomegaly is nontender.

What are the common clinical findings of hypersplenism?

Pallor (anemia), infection (leukopenia) and easy bruising, and bleeding (thrombocytopenia)

079_BOOKZ

What are the signs associated with thrombocytopenia?	Petechiae, particularly in areas of increased pressure
Coagulation disorder?	Ecchymoses
How is primary hypersplenism diagnosed?	Diagnosis of exclusion. Primary hypersplenism is a rare disorder affecting women more commonly due to exaggerated destruction/sequestration.
How is this treated?	Splenectomy
What is the most common cause of secondary hypersplenism?	Portal hypertension (due to congestion and ↑ sequestration)
What is the abnormal protein in hereditary spherocytosis?	Spectrin
What is the inheritance pattern?	Autosomal dominant
What are the signs/symptoms of hereditary spherocytosis?	Malaise, abdominal pain, jaundice, anemia, splenomegaly, gallstones, chronic leg ulcers from poor circulation
What are three laboratory tests for hereditary spherocytosis?	1. Spherocytes on peripheral blood smear 2. Positive osmotic fragility test 3. Negative Coombs' test
What is the treatment of choice?	Splenectomy is helpful with anemia and jaundice and leg ulcers. Splenectomy should be postponed until at least 5 years of age to avoid sepsis Cholecystectomy if gallstones present
Why is splenectomy rarely needed in patients with sickle cell anemia?	Most patients "autosplenectomize" with intermittent splenic infarction
When is splenectomy required in patients with sickle cell anemia?	Excessive splenic sequestration or abscess after splenic infarction
What disease is characterized by a defect in hemoglobin synthesis?	Thalassemia
What are the two types?	1. α-Thalassemia: Asians and African Americans. The severity depends on number of affected α-globin alleles. 2. β-Thalassemia: Mediterranean origin, only two β-globin alleles • Thalassemia major: Cooley's anemia = homozygote for no β-globin production.

	• Thalassemia minor: heterozygote, underproduction of β-globin production.
What is a common complication of thalassemias and associated treatment?	Hemochromatosis due to hemolysis and blood transfusions, which may cause cardiac failure
How can this be managed?	Splenectomy (reduces transfusion needs) and deferoxamine. Splenic embolization/partial splenectomy may decrease risk of infection
Describe the following:	
Direct Coombs' test	Red blood cells (RBCs) are washed (patient serum is removed) and incubated with antihuman globulin. Aggregation will occur if antibodies/complement have aggregated on RBCs in vivo.
Indirect Coombs' test	Washed RBCs are incubated with patient serum. RBCs are washed and incubated with antihuman globulin. Aggregation (positive test) occurs if antibodies present have bound to RBCs after first wash. (Used in blood transfusion preparation.)
What are common causes of Coombs' negative hemolytic anemia?	Infection, drug/toxin. Treatment is by removing offending stimulus, not splenectomy.
What is the treatment for patients with Coombs' positive hemolytic anemia?	Steroids
When is splenectomy indicated?	If steroids fail to improve anemia or due to the toxic side effect of steroids
Describe the following autoimmune anemias:	
Warm antibody related anemia	Usually immunoglobin G (IgG) (no complement fixation), splenic sequestration, associated with lymphoma/leukemia and autoimmune disorders
Cold antibody related anemia	Usually immunoglobin M (IgM) (complement fixation) causes agglutination in periphery, no splenic sequestration, associated with

	lymphoma and acute infection (mycoplasma, mononucleosis) and presents similar to Raynaud's
In which anemia (warm or cold antibody related) is splenectomy useful?	Warm antibody-related anemia
An otherwise healthy 60-year-old woman with Coombs' positive hemolytic anemia, normal bone marrow, no drugs.	
What is her disease?	Idiopathic autoimmune hemolytic anemia, which is most common in old women
What is the treatment?	Can be self limiting. Steroids and azathioprine for chronic complications. Splenectomy is second line.
What condition is associated with iron deficiency anemia in each patient population?	
50-year-old man	Colon cancer
30-year-old woman	Menstruation
60-year-old woman	Colon cancer
	Note: Although other conditions may cause iron deficiency anemia always rule out colon cancer in an older adult, especially if anemia is new onset.
What are the common causes of thrombocytopenia due to:	
Sequestration?	• Hypersplenism—usually due to liver disease, portal hypertension
Increased destruction?	• Sepsis/disseminated intravascular coagulation (DIC) • Idiopathic thrombocytopenic purpura (ITP) • Thrombotic thrombocytopenic purpura (TTP)/hemolytic uremic syndrome (HUS) • Drugs—heparin-induced thrombocytopenia (HIT), caused by circulating antibody. Other drugs quinidine, quinine, sulfonamides. • HEELP syndrome in pregnancy • Lymphoproliferative disorders (production of platelet antibodies)

Decreased production?	Decreased production • Leukemias • Myelodysplasia • Metastatic disease • B_{12} or folate deficiency • Chemotherapy Note: Dilutional can be an etiology due to acute fluid resuscitation, multiple blood transfusions.
What is the definition of thrombocytopenia?	Platelet count <100,000
Below what platelet count is a patient at risk for increased bleeding with surgery?	<50,000
Below what platelet count is a patient at risk for spontaneous bleeding?	<20,000
When should prophylactic platelet transfusion be given?	Platelet count <10,000
Why not give platelet transfusions to patients with HIT or TTP?	Associated with thrombosis. In the case of thrombotic thrombocytopenic purpura (TTP) it can rapidly worsen the clinical picture.
What is the most likely disease process in a 30-year-old woman with bleeding gums, oral bullae, petechiae, low platelet count, normal RBCs on peripheral blood smear, and a normal-sized spleen?	Idiopathic thrombocytopenic purpura (ITP)
What are the treatment options?	Treatment • Steroids induce remission in 75% of chronic ITP. • Splenectomy if patients do not respond to steroids. Also indicated for women in second trimester of pregnancy and have failed medical therapy. Success rate 65%. • Treat if platelet count <30,000 or <50,000 in patients with symptoms.
Indicate whether the following is characteristic of chronic or acute forms of ITP:	
More common in children	Acute
Affects males and females equally	Acute
Common in adult women (<40)	Chronic
Postviral	Acute
Spontaneous remission (80%)	Acute

079_BOOKZ

When are platelet transfusions indicated in ITP?	
Absolute number?	<10,000 to prevent spontaneous intracranial hemorrhage
Before surgery or labor?	<20,000
If symptomatic (ie, spontaneous bleed)	<50,000
What is the role of intravenous immunoglobulin (IVIG) in ITP?	IVIG helps in treating acutely low platelet counts associated with severe bleed and improves half life of transfused platelets. • Give if platelet count is <20,000 and if patient is to have splenectomy to raise count before surgery. • Give IVIG for 3 days then platelet transfusion if no response. • Does not induce sustained remission.
What infectious disease is associated with chronic ITP?	Human immunodeficiency virus (HIV) (10–20% of symptom-free patients)
What is Evan's syndrome?	ITP and autoimmune hemolytic anemia (+ Coombs' test)
Difference in pathology of TTP and ITP?	• TTP is microvascular platelet coagulation/hemolysis resulting in consumption of platelets and schistocytes. • ITP is autoantibody to platelets resulting in increased splenic destruction (no schistocytes). • Can differentiate between the two processes on peripheral blood smear.
What are the clinical features of TTP?	"**FAT RN**" • **F**ever • Hemolytic **a**nemia • **T**hrombocytopenic purpura • **R**enal failure • **N**eurologic disturbance (change in mental status)
What is the prognosis of TTP?	Usually fatal if not treated
Treatment of TTP?	Large volume plasmapheresis which results in a 70% cure

What labs distinguish DIC from TTP?

TTP usually has normal or near normal coagulation parameters.

What clinical feature distinguishes HUS from TTP?

HUS lacks neurologic disturbance

Laparoscopic splenectomy is preferred to open. What are the indications for open splenectomy?

- Megaspleen due to the technical difficulty for laparoscopic surgery
- Acute trauma in order to assess other injuries
- Portal hypertension
- Severe ascites
- Uncorrectable coagulopathy

What are the complications of splenectomy?

- Post splenectomy sepsis
- Thrombocytosis, which can be greater than 1 million
- Watch for pulmonary, mesenteric, and other embolic events
- Subphrenic abscess
- Injury to tail of pancreas

Why not perform a splenectomy on a patient <4 years of age?

Higher risk of postsplenectomy sepsis

What are the pre-op measures taken before splenectomy?

- Polyvalent *S. pneumoniae* vaccine two weeks before procedure
- *H. influenzae* and menigococcus vaccines 2 weeks before procedure
- Platelet count
- Prophylactic penicillin to pediatric patients

What is the normal rise of platelets postsplenectomy?

Rise to 500,000 is not abnormal. Patients with platelets count >1,000,000 need anticoagulation to prevent spontaneous thrombosis

What do you suspect in an ITP patient who has continued thrombocytopenia after splenectomy?

Accessory spleen (20% of population)

- Common locations (in order of occurrence) splenic hilum, pedicle, greater omentum, tail of pancreas, splenocolic ligament, mesentery, left ovary
- Looking for accessory spleens in those locations is an important step in ITP splenectomy

At what point in the surgery should the surgeon look for accessory spleens?

The very beginning before visualization in the operative field becomes difficult due to intraoperative bleeding.

079_BOOKZ

What imaging study is used to diagnose accessory spleens?	Technetium radionucleotide scan. Colloid is taken up by reticuloendothelial cells.
When extracting a spleen during a laparoscopic splenectomy, why is it necessary to use an impermeable bag?	Risk of splenosis from mesenteric seeding of normal splenic tissue. To extract a spleen, it must be divided into fragments. These fragments can implant and act like accessory spleens.
Determine if splenectomy would be useful in the following conditions:	
Sickle cell anemia	No
Pyruvate kinase deficiency (PKD)/glucose-6-phosphate dehydrogenase (G6PD)	No
Thalassemia major	No
Hereditary spherocytosis	Yes
Splenic vein thrombosis	Yes
TTP	No (treat with plasmapheresis and steroids)
	Note: In metabolic abnormalities (polycystic kidney disease [PKD]/G6PD) and hemoglobinopathies (sickle cell/thalassemia) splenectomy is rarely useful though may reduce need for multiple transfusion (especially thalassemia major). Splenectomy is useful for abnormalities in membrane structure (spherocytosis)

This page intentionally left blank

CHAPTER 7

Hernia

Define hernia.	Protrusion of *any* organ through its normal anatomic confines
Define the following types of hernias:	
Reducible	Hernia can be restored to anatomic location.
Incarceration	Irreducible hernia.
Strangulation	Ischemic incarcerated hernia.
Sliding	Protruding hernia wall contains organ (ie, bladder, colon, etc.).
Richter's	Portion of bowel wall becomes trapped—"knuckle of bowel."
What is significant about this type?	Necrosis can occur in the absence of symptoms (obstruction).
Aponeurosis from what muscle group overlies the spermatic cord?	External oblique aponeurosis
Aponeuroses from what two muscles form the conjoint tendon (inguinal falx)?	Internal oblique and transversus abdominis (tendon often contains muscle)
Where is this tendon located?	Posterior wall of medial inguinal canal
The floor of the inguinal canal is formed from what fascia?	Transversalis fascia
Aponeurotic fibers from what muscle group form the inguinal ligament?	External oblique muscle
What is another commonly used name for this ligament?	Poupart's ligament

Copyright © 2008 by The McGraw-Hill Companies, Inc. Click here for terms of use.

079_BOOKZ

What ligament lies along the iliopectineal line along the superior pubic ramus and connects with the medial inguinal ligament?	Cooper's ligament
What ligament lies between Cooper's ligament and inguinal ligament?	Lacunar ligament
What are the borders of Hesselbach's triangle?	Inferior epigastric vessels, inguinal ligament, rectus sheath (lateral edge)
What is the most common hernia in adults?	Indirect inguinal hernia (50% males, 70% females)
What is hydrocele?	A patent (communicating) or partial (noncommunicating) processus vaginalis which contains no bowel—"an indirect hernia with no bowel protrusion"
Identify if the following refer to a direct or indirect hernia.	
Acquired lesion	Direct
Congenital patent processus vaginalis	Indirect
Lateral to the epigastric vessels	Indirect
Medial to epigastric vessels	Direct
Herniation through floor of Hesselbach's triangle	Direct
Herniation through internal then external inguinal ring	Indirect
Lower risk of incarceration	Direct
More common in elderly	Direct
Enters the scrotum	Indirect
Peritoneal covering	Indirect
Defect in transversalis fascia	Direct
What type of hernia has a sac that passes both medial and lateral to the epigastric vessels (ie, elements of indirect and direct hernias)?	**Pant**aloon hernia. (Remember: two legs in **pant**s, therefore two types of hernias)
What type of hernia commonly found in females passes anterior to Cooper's ligament and posterior to inguinal ligament?	Femoral hernia
What is significant about this hernia?	~35% become incarcerated

079_BOOKZ

What types of hernias have the highest risk for strangulation?	Umbilical, femoral, spigelian, and indirect inguinal (small/narrow hernias = increased risk of incarceration)
How do hernias typically present?	Enlarging bulge most pronounced with straining, may be tender if strangulation has occurred
How can hernias be assessed in obese patients?	Ultrasound or computed tomography (CT)
What are other causes of inguinal masses?	• **H**ernias (inguinal, femoral) • **V**ascular (femoral aneurysm, saphenovarix) • **M**uscle (psoas abscess) • **L**ymph nodes • **T**esticle (ectopic, undescended) • **S**permatic cord (lipoma, hydrocele) Note: "**H**ernias **V**ery **M**uch **L**ike **T**o **S**well."
Describe whether the following description refers to simple, omphalocele, or gastroschisis umbilical herniations:	
95% spontaneously close	Simple
Covered by skin	Simple
No covering of herniated organs	Gastroschisis
Lateral to umbilicus	Gastroschisis
Peritoneal covering of organs	Omphalocele
What is a groin hernia that contains Meckel's diverticulum called?	Littre's hernia
Herniation through the superior lumbar triangle is referred to as what?	Grynfelt's hernia
Through the inferior lumbar triangle?	Petit's hernia
Where does a spigelian hernia occur?	**S**pigelian = **s**emilunar line
A ventral hernia resulting from abdominal surgery is referred to as what?	Incisional hernia
What is it caused by?	Incomplete fascial closure or failure of fascial healing
How are hernias treated?	Surgical repair (hernias never close spontaneously—except congenital umbilical hernias—more common in women, 95% close spontaneously)

What is the underlying principle of surgical hernia repair?

"Tension free" repair

Describe the following open surgical repairs:

Bassini repair (see Fig. 7-1).

Conjoint tendon and transversalis fascia are attached to Poupart's ligament (spermatic cord lies in normal anatomic position).

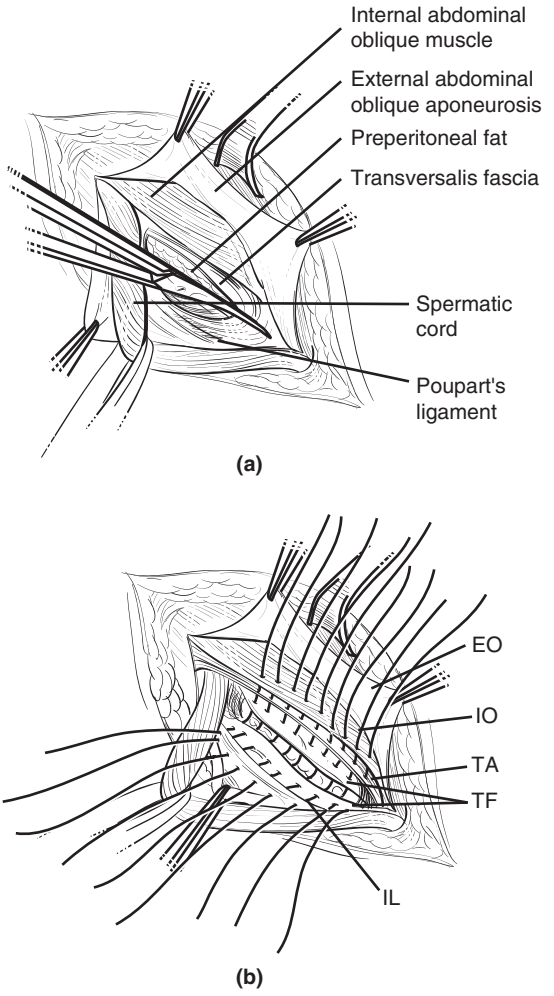

Figure 7-1 Bassini inguinal hernia repair. EO = external oblique aponeurosis, IO = internal oblique muscle, TA = transversus abdominis muscle, TF = transversalis fascia, IL = inguinal ligament. [*Reproduced, with permission, from Brunicardi CF et al (eds): Schwartz's Principles of Surgery, 8th ed. New York: McGraw-Hill, 2005:1370.*]

McVay repair (Cooper's ligament repair) (see Fig. 7-2).

Conjoint tendon and transversalis fascia are attached to Cooper's ligament.

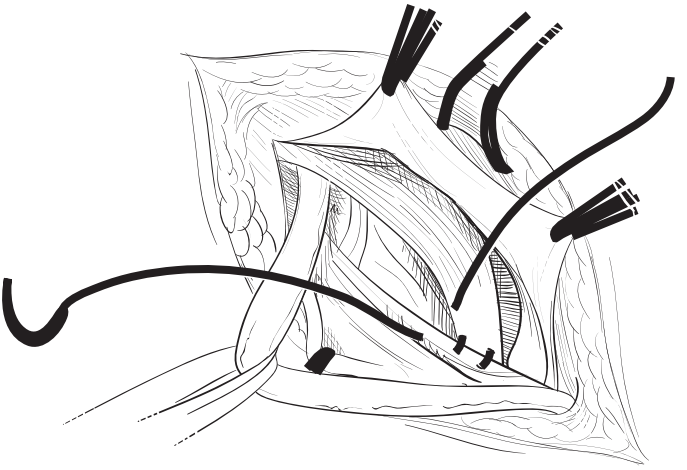

(a)

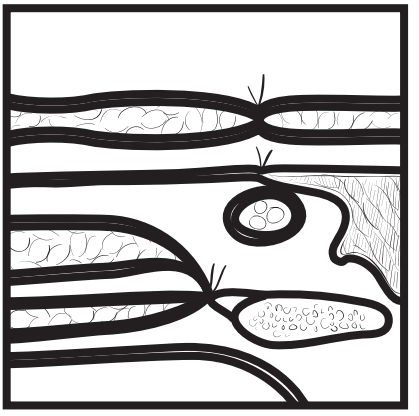

(b)

Figure 7-2 McVay repair. Used for inguinal and femoral hernia repair. [*Reproduced, with permission, from Brunicardi CF et al (eds): Schwartz's Principles of Surgery, 8th ed. New York: McGraw-Hill, 2005:1373.*]

Marcy repair (see Fig. 7-3). Tightens the aperture of transversus aponeurosis—sew lateral side of transversus aponeurosis to medial side

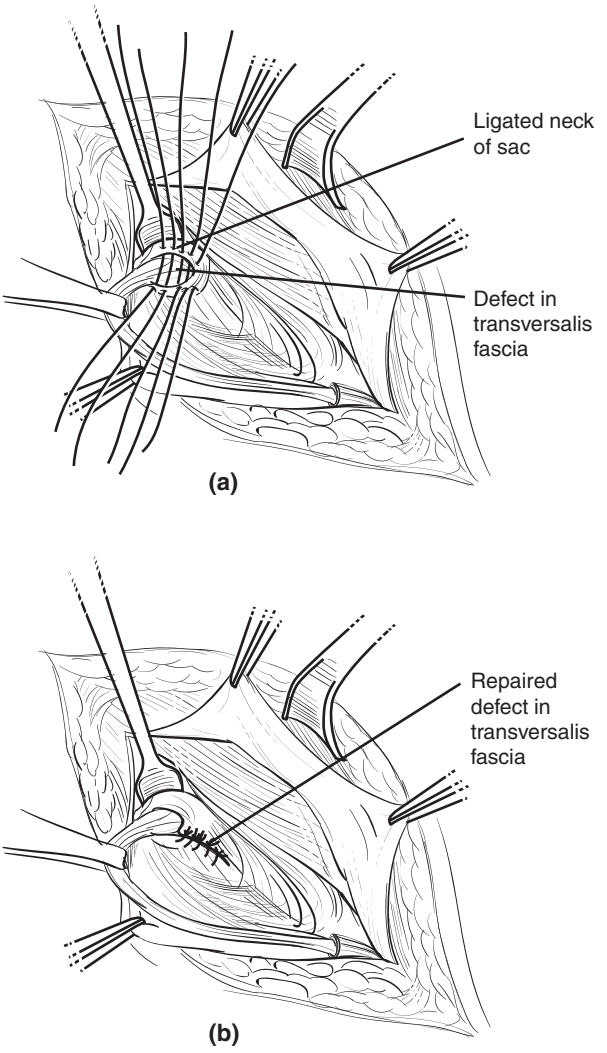

Figure 7-3 Marcy repair. Used in children and adolescents. [*Reproduced, with permission, from Brunicardi CF et al (eds): Schwartz's Principles of Surgery, 8th ed. New York: McGraw-Hill, 2005:1370.*]

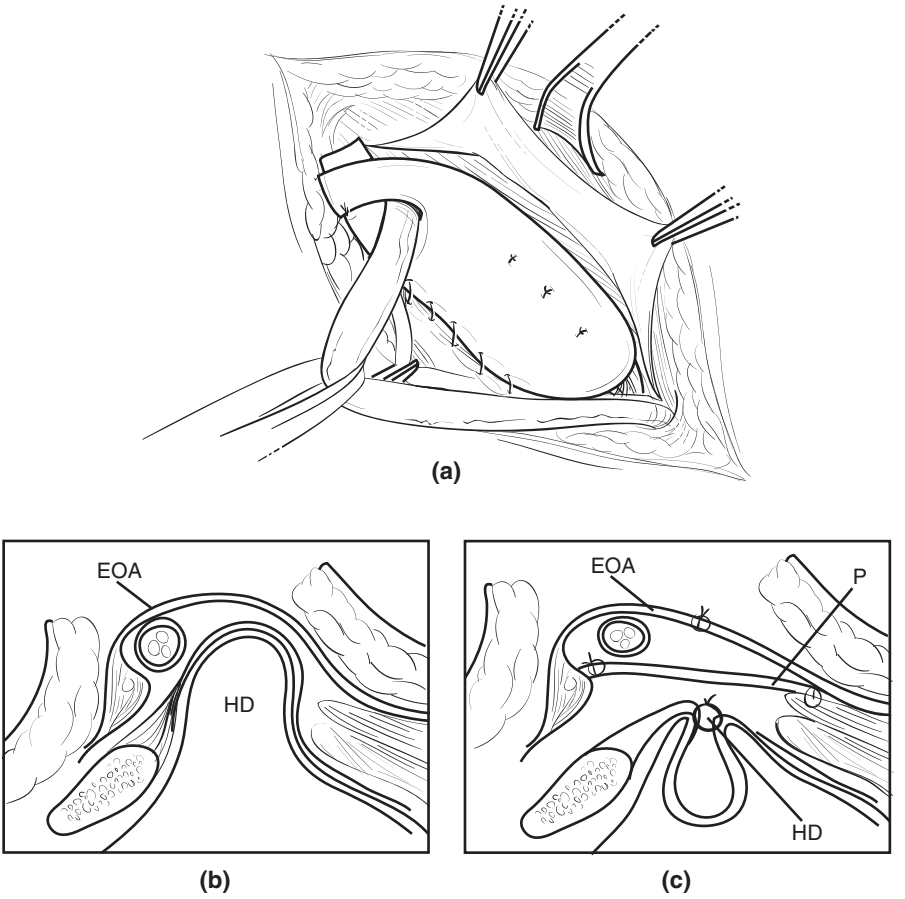

Figure 7-4 Lichtenstein mesh hernia repair. EOA = external oblique aponeurosis, HD = hernia defect, P = prosthesis. [*Reproduced, with permission, from Brunicardi CF et al (eds): Schwartz's Principles of Surgery, 8th ed. New York: McGraw-Hill, 2005:1375.*]

Lichtenstein repair (see Fig. 7-4).	Placement of mesh *over* defect—many prefer placement of mesh *under* defect to reduce recurrences.
Shouldice repair (see Fig. 7-5).	Transversalis fascia is divided and imbricated (overlapped like shingles on a roof) to Poupart's ligament followed by internal oblique muscle and conjoint tendon (total four suture lines).

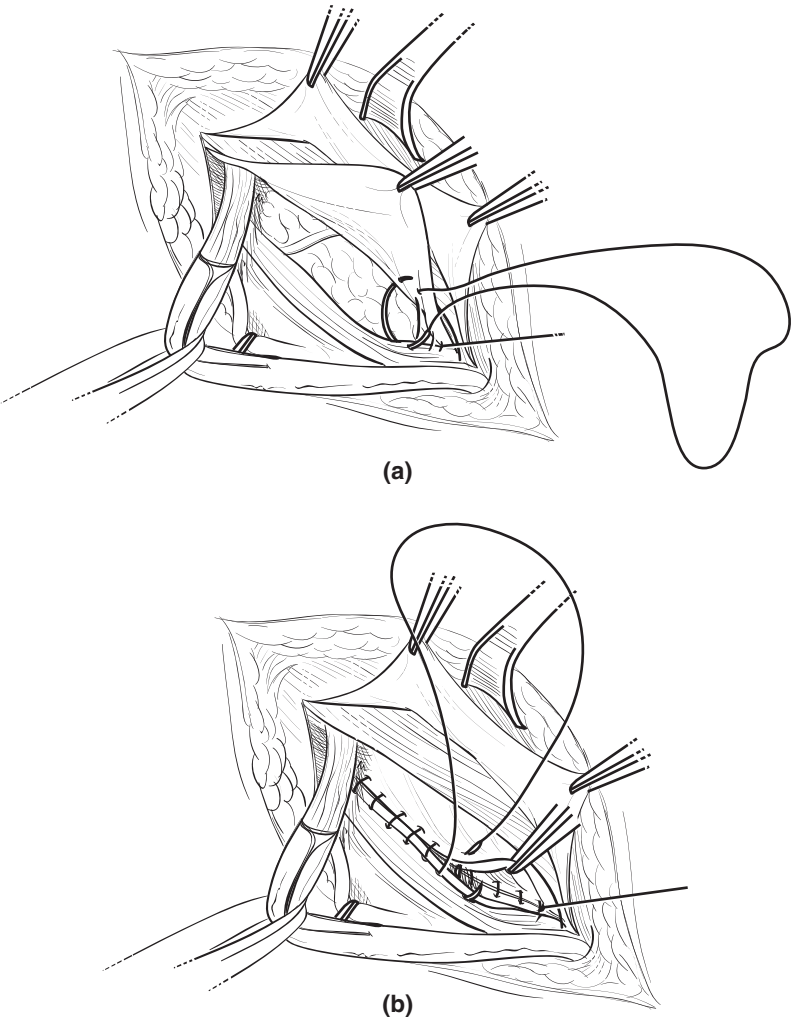

Figure 7-5 Shouldice repair. Notice the multiple layers of running suture. [*Source: Brunicardi, CF, et al: Schwartz's Principles of Surgery, 8/e, McGraw-Hill, 2004:1372.*]

Describe the following laparoscopic surgical repairs:

TAPP	Transabdominal pre-peritoneal (TAPP)—Defect is identified and mesh is placed to the posterior surface of the abdominal wall (increased risk for adhesions and bowel perforation).

TEP/ELM

Totally extraperitoneal/extraperitoneal laparoscopic repair (TEP/ELM)—balloon is insufflated in the preperitoneal space and mesh is placed to the posterior surface of the abdominal wall (difficult to reduce large hernia sac) (see Fig. 7-6).

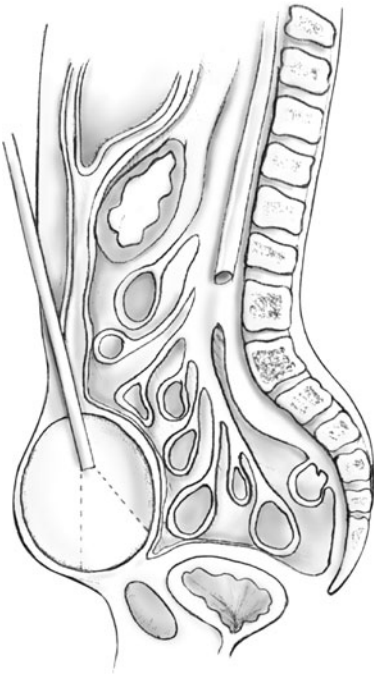

Figure 7-6 Balloon dissection of the plane between the transversus abdominis and peritoneum used in TEP hernia repair.

IPOM

Intraperitoneal onlay mesh (IPOM)—Diagnostic laparoscopy identifies defect and mesh is placed over and stapled (quickly repair inguinal hernias but risk development of adhesions).

Indications for laparoscopic repair?

- Recurrent hernia after repair
- Bilateral inguinal hernia

What is the major contraindication to mesh placement?

Strangulated or perforated bowel found in hernia sac. This must be resected and a traditional repair must be done.

This page intentionally left blank

CHAPTER 8

Liver

What is the name of the thick fibrous capsule surrounding the liver?	Glisson's capsule
What is Fitz-Hugh-Curtis syndrome?	Inflammation of Glisson's capsule
What are the macrophages lining the vascular endothelium of the liver called?	Kupffer cells are specialized macrophages located in the liver that form part of the reticuloendothelial system.
What two structures divide the liver into two lobes?	Line connecting the left side of the gallbladder and vena cava
How many segments does each lobe contain?	Four segments per lobe. These segments are divided by perforating blood vessels used to determine the anatomical definition of liver resections. Segment IV consists of IVa and IVb.
Segment I corresponds to what lobe of the liver (see Fig. 8-1)?	Caudate lobe
What segments comprise the left lobe?	II–IV
What segments comprise the right lobe?	V–VIII

Copyright © 2008 by The McGraw-Hill Companies, Inc. Click here for terms of use.

079_BOOKZ

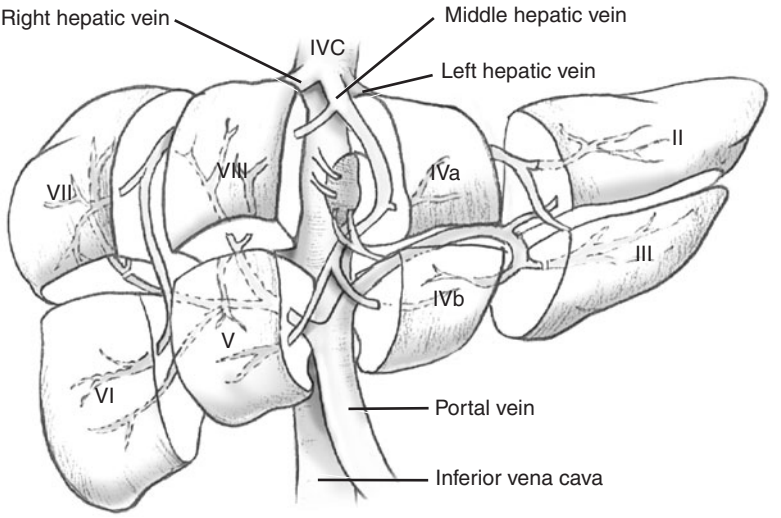

Figure 8-1 Segments of the liver. Right and left lobes are separated anatomically by an invisible line drawn between the gallbladder fossa anteriorly and the gallbladder fossa posteriorly.

What are the five ligaments of the liver?

Four formed by peritoneal folds (see Fig. 8-2)
- Falciform
- Coronary (thick crown; encircles bare area of liver like a crown)
- Right and left triangular

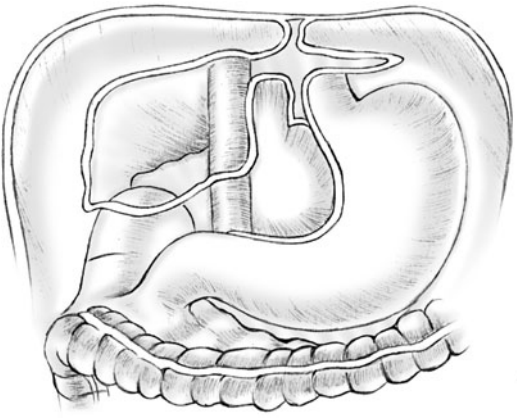

Figure 8-2 Peritoneal attachments of the liver.

	• Round ligament (ligamentum teres) is formed by an obliterated vessel
What is the embryologic origin of the round ligament (ligamentum teres)?	Umbilical vein
What two vessels supply blood flow to the liver?	Hepatic artery and portal vein
Which supplies the majority of the blood flow?	Portal vein (supplies 2/3 of blood supply and 1/2 of oxygen requirement)
Where does each lie in the porta hepatis?	
Hepatic artery	Medial
Common bile duct	Anterior-lateral
Portal vein	Posterior
What is the most common benign hepatic tumor?	Cavernous hemangioma
What is the most common symptom?	Usually asymptomatic, though may have right upper quadrant (RUQ) pain from stretching of Glisson's capsule or transient thrombosis.
How are these diagnosed?	Often found incidentally on imaging studies such as computed tomography (CT) scan and diagnostic ultrasound. Do not attempt percutaneous biopsy because of bleeding risk.
What are the characteristic findings of cavernous hemangioma on the following imaging modalities?	
CT scan	CT scan • A low density lesion on unenhanced scan • Early peripheral contrast enhancement • Progressive opacification from the periphery to the center • A delay of at least 3 minutes before total opacification • Eventual isodense appearance
MRI	Magnetic resonance imaging (MRI) • Hypointense signal intensity compared to the surrounding liver tissue on T1-weighted imaging • Hyperintense signal intensity on T2-weighted images

Note: MRI has a diagnostic accuracy as high as 96% for hepatic hemangioma.

What are the indications for surgery of cavernous hemangiomas?

Symptoms—usually pain is the only indication for surgery. Rupture is rare, even in very large tumors.

What tumors are strongly associated with a long history of oral contraceptive or anabolic steroid use?

Hepatic adenoma which often presents around 40 years of age. There is a 10% potential for malignant transformation in hepatic adenomas.

What is the most common sign and symptom?

Abdominal pain, which is present in 25% of patients. Mass is usually solitary.

What are the patients at greatest risk for?

Spontaneous rupture, which occurs in 1/3 of patients and can lead to pain, bleeding, and/or shock.

Are the liver function tests (LFTs) expected to be low, normal, or elevated in hepatic adenomas?

Normal, because there is no hepatocellular necrosis and the tumors do not contain portal triads/bile ducts although alpha-fetoprotein (AFP) may occasionally be helpful to distinguish from hepatocellular carcinoma (HCC).

What is the typical finding on CT scan for hepatic adenoma?

Solid, sharply demarcated, and hypo- or isoattenuating. Nonenhanced images may identify areas of fat or hemorrhage that is typical of adenoma. Enhancement in adenoma will not persist secondary to arteriovenous shunting (unlike focal nodular hyperplasia [FNH]).

How are patients with hepatic adenomas treated?

Surgical resection (especially if patient anticipates becoming pregnant) for risk of rupture. Occasionally regresses with discontinuation of oral contraceptives/steroids.

What asymptomatic lesion would present with a central stellate scar on CT and scattered bile ducts on biopsy?

Focal nodular hyperplasia (FNH), which is the second most common benign liver tumor. Diagnosed if bile duct epithelium seen on biopsy: stellate scar appearance due to central scar with nodular hyperplasia and fibrous septa.

Does this lesion have potential for malignant transformation?

No malignant potential (or risk of spontaneous rupture)

079_BOOKZ

How is FNH diagnosed?	1. MRI demonstrates stellate scar. 2. ^{99m}Tc sulfur colloid scanning demonstrates Kupffer-cell activity (usually absent in adenoma = filling defect).
What is the preferred treatment of FNH?	Observation if diagnosis is certain, though often resected due to concern for hepatic adenoma
What is the most common malignant tumor found in the liver?	Metastatic tumors (especially colorectal cancer), 20:1 ratio of metastatic to primary
Where are the most common locations of primary tumors producing liver metastases?	Colon, stomach, pancreas, breast, lung (mostly GI sources)
What is the most common primary malignancy found in the liver?	Hepatocellular carcinoma (HCC) (also known as hepatoma) >90%
What are the differences between the two histologic HCC subtypes?	
Fibrolamellar	Unknown etiology, younger patients, associated with hepatitis or cirrhosis <10%, better prognosis
Nonfibrolamellar	Most frequent, associated with cirrhosis (most commonly from hepatitis C virus [HCV] and alcohol use), poor prognosis if untreated
What are the common risk factors for HCC (nonfibrolamellar)?	• Cirrhosis: from all causes including alcohol abuse, hepatitis B virus (HBV), HCV, hemochromatosis, α_1-antitrypsin, etc. • Infectious: viral hepatitis (HCV and HBV) and schistosomiasis • Environmental: vinyl chloride, aflatoxin, cigarette smoking, steroid use, alcohol
What is the most common symptom of HCC?	Weight loss
What tumor marker is commonly elevated with HCC?	Alpha-fetoprotein (>500 mg/dL). 1/3 may be normal.
What other conditions may have elevation of this tumor marker?	Acute/chronic hepatitis, cirrhosis, pregnancy (usually <400 mg/dL)
What is the treatment of choice?	Liver resection or liver transplant
What are other treatment options for patients who are not candidates for liver resection or transplantation?	1. Radiofrequency ablation 2. TACE (tumor-necrosis factor alpha converting enzyme) 3. Ethanol injection 4. Cryoablation

What is TACE?

Transarterial chemoembolization which involves hepatic artery infusion of chemotherapy and foam particles to occlude artery and cause ischemia to tumor while increasing chemotherapy dwell times. Remember, most blood to liver is supplied by the portal vein. Furthermore 90% of blood to tumor is supplied by the hepatic artery.

What are the two most important prognostic indicators in patients with HCC?

Presence of vascular invasion and degree of fibrosis throughout the liver. However, large tumor size increases the likelihood of vascular invasion.

Why are these considered the most significant?

Determine resectability and long-term recurrence and survival.

- HCC more often invades the portal venous tracts than the hepatic veins, causing satellitosis or distal metastases.
- Fibrosis of liver reduces the extent of segmental resection due to loss of function of remaining tissue and regenerative capacity.

What imaging modalities may be used to diagnose HCC?

- Ultrasound with Doppler (to assess patency of portal vein)
- Triphasic CT (no contrast, arterial, portal phases)
- MRI

What is the prognosis of HCC?

Poor. 10% are resectable. 5%, 5-year survival for all patients.

What is the most common primary liver tumor in children?

Hepatoblastoma (rarely associated with cirrhosis)

CIRRHOSIS

What is cirrhosis?

Fibrosis of the liver. This causes a change in architecture which increases resistance in blood flow (and bile) causing shunting. Furthermore, there is often decreased hepatic functioning affecting multiple organ systems. This is made of two subtypes: micronodular (EtOH) and macronodular (infectious/inheritable causes).

What is the most common cause of cirrhosis in the United States?	HCV
What are the suspected transaminase levels and liver size in a cirrhotic patient?	Variable. In longstanding cirrhosis, fibrosis may yield a normal size or small (but firm) liver; with long standing necrosis of hepatocytes the transaminases may begin to decrease and return to "normal" (even with continued exacerbations).
What are common signs associated with cirrhosis?	Ascites, jaundice, muscle wasting, peripheral edema, splenomegaly, encephalopathy, asterixis, palmar erythema, loss of body hair, testicular atrophy, gynecomastia, spider angioma, varices, and caput medusa
Describe whether the following will be increased, decreased, or variable:	
Prothrombin time	↑: due to decreased factor production and impaired biliary secretion (↓ vitamin K/fat soluble vitamins)
Blood sugar	Variable: impaired glucose and glycogen metabolism—hyperglycemia in early cirrhosis and hypoglycemia in advanced cirrhosis
Serum cholesterol	↓: impaired synthesis, leading to accumulation = fatty liver
Drug metabolism	Variable: depending on drug uptake, metabolism, and excretion
Estrogen	↑: due to decreased metabolism which leads to gynecomastia
Testosterone	↓: due to decreased albumin (major binding protein of testosterone)
Aldosterone	↑: decreased inactivation leads to increased total body water
What are common complications of cirrhosis?	• Renal dysfunction • Portal hypertension (resulting in GI bleeding, encephalopathy, and ascites)
What is hepatorenal syndrome (HRS)?	Renal failure in patients with advanced, chronic liver disease
What is the underlying mechanism for renal failure?	Diffuse renal vasoconstriction of unknown etiology

What are common precipitating factors leading to the development of HRS?

- Spontaneous bacterial peritonitis
- Alcoholic hepatitis
- Large volume paracentesis

Note: However, HRS may develop spontaneously.

What is the prognosis of HRS?

Highly morbid within 4 weeks–6 months, depending on the rate of renal failure

How is HRS diagnosed?

A diagnosis of exclusion (exclude pre- and postrenal azotemia, and acute tubular necrosis [ATN])

- ↓ glomerular filtration rate (GFR) (↑Cr [>1.5 mg/dL], 24h CrCl <40 mL/min)
- No improvement in Cr with diuretics and 1.5 L isotonic fluids
- Proteinuria <500 mg/day (rule out glomerular disease)
- Minor criteria are consistent with prerenal azotemia: serum sodium >130 mEq/L; urine sodium <10 mEq/L; urine volume <500 mL/day; urine Osm > plasma Osm

What is the treatment of HRS?

Liver transplant resolves renal failure and is curative.

What are common causes of portal hypertension arising:

Prehepatic?

Most common in children—portal vein obstruction (thrombosis, stenosis, compressing tumors), primary biliary cirrhosis, arteriovenous fistula

Intrahepatic?

Most common—cirrhosis, schistosomiasis (most common worldwide)

Posthepatic?

Budd-Chiari syndrome (hepatic vein occlusion from hypercoagulable state cancer, trauma, oral contraceptives), constrictive pericarditis (↑inferior vena cava [IVC] pressures)

Portal venous pressures are relieved by what?

Portosystemic collaterals

079_BOOKZ

What vessels are associated with the following portosystemic shunts (see Fig. 8-3)?

Caput medusae	Umbilical vein
Hemorrhoids	Hemorrhoidal vein
Esophageal varices	Coronary vein
Gastric varices	Splenic vein

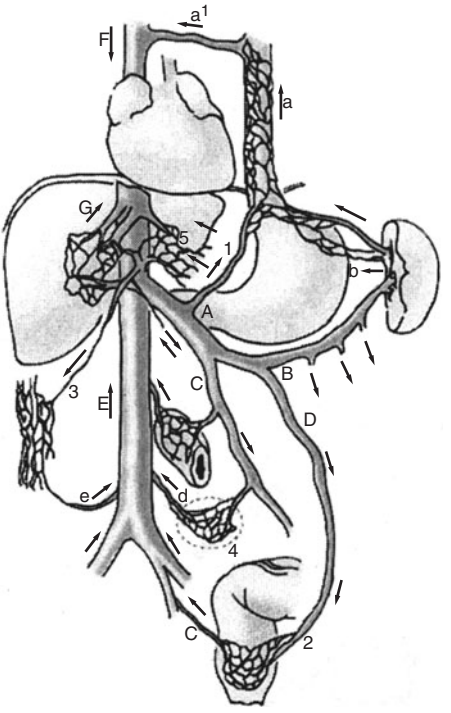

Figure 8-3 Intra-abdominal venous flow pathways leading to engorged veins (varices) from portal hypertension. 1, coronary vein; 2, superior hemorrhoidal veins; 3, paraumbilical veins; 4, veins of Retzius; 5, veins of Sappey; A, portal vein; B, splenic vein; C, superior mesenteric vein; D, inferior mesenteric vein; E, inferior vena cava; F, superior vena cava; G, hepatic veins; a, esophageal veins; a^1, azygos system; b, vasa brevia; c, middle and inferior hemorrhoidal veins; d, intestinal; e, epiqastric veins. [*Reproduced, with permission, from Brunicardi CF et al (eds): Schwartz's Principles of Surgery, 8th ed. New York: McGraw-Hill, 2005:1155.*]

How can one distinguish caput medusae from inferior vena cava obstruction on physical exam?

By determining the direction of collateral blood flow

- Toward the head = IVC obstruction—collaterals bypassing occlusion
- Toward the legs = caput medusae

Splenomegaly and gastric varices in a patient with chronic pancreatitis is likely due to what?

Thrombosis of splenic vein (from chronic inflammation) or pancreatic tumor

How is this treated?

Splenectomy

What are the treatment options for symptomatic portal hypertension?

1. Conservative medical management, including diuresis, lactulose, and paracentesis
2. TIPS—see below.
3. Surgical selective and nonselective portosystemic shunting
4. Liver transplantation

What is TIPS?

Transjugular intrahepatic portosystemic shunt (TIPS) is a procedure performed by interventional radiologists to create a nonselective portosystemic shunt (see Fig. 8-4).

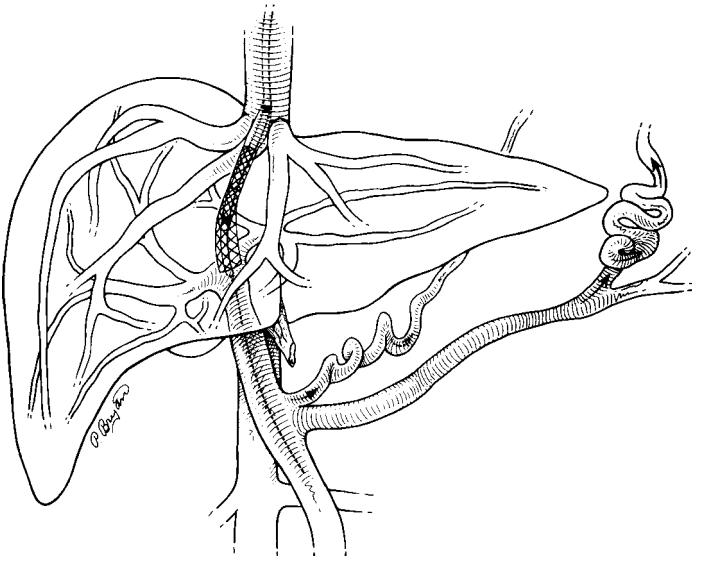

Figure 8-4 Transjugular intrahepatic portosystemic shunt. [*Reproduced, with permission, from Zinner MJ, Ashley SW (eds): Maingot's Abdominal Operations. New York: McGraw-Hill, 2006:Fig 31-6.*]

What is the technical approach for a TIPS?

1. Puncture of the internal jugular vein.
2. Catheter through the right atrium into the right hepatic vein.
3. Transparenchymal puncture of the liver to cannulate the portal vein.

	4. Intraparenchymal track is dilated. 5. Expandable metal stent in the 10–12 mm placed.
TIPS technical success rate?	>90%
TIPS mortality rate?	<10%
TIPS new encephalopathy rate?	30%
What are common signs/symptoms of hepatic encephalopathy?	• Altered consciousness (confusion, obtundation) • Asterixis • Tremor • Hyper-reflexia • Fetor hepaticus (feculent breath)
How is hepatic encephalopathy diagnosed?	Clinically—rule out other potential causes: intoxication, infection, injury to central nervous system (CNS).
What is most commonly elevated in hepatic encephalopathy?	Ammonia (~90% of patients have elevation.)
What precipitates encephalopathy?	Many factors: GI bleed, constipation, drugs (ie, sedatives/narcotics), dehydration/surgery, ↑ dietary protein
How do you treat hepatic encephalopathy?	• Decrease protein intake • Lactulose—acts as a cathartic and changes colonic pH ↓ bacterial ammonia production • Neomycin—not absorbed by GI causes a decrease in bacterial load which leads to ↓ ammonia production
What are six causes of ascites?	1. Portal hypertension (↑ hydrostatic pressure) 2. ↓ Albumin (↓ oncotic pressure) due to lack of production (cirrhosis, malnutrition) or wasting (nephrotic syndrome, protein-losing enteropathy) 3. Hyperaldosteronism (↓ metabolism) 4. Lymphatic obstruction 5. ↑ Antidiuretic hormone (ADH) secretion (due to perceived hypovolemia—congestive heart failure [CHF]) 6. Malignancy

How can the etiology of ascites be determined?	Diagnostic paracentesis (including cytology) and determination of SAAG
What is SAAG ratio?	Serum ascites:albumin gradient
What does a value >1.1 indicate?	Imbalance between oncotic and hydrostatic pressure = transudative ascites (ie, cirrhosis, CHF, hepatic metastases, Budd-Chiari)
What does a value <1.1 indicate?	Protein leakage = exudative ascites (nephrotic syndrome, carcinoma, vasculitis, granulomatous peritonitis [tuberculosis (TB), histoplasmosis, sarcoidosis], Whipple)
What is the likely diagnosis of a patient with ascites, diffusely tender abdomen, fever, and falling blood pressure?	Spontaneous bacterial peritonitis (SBP)—usually from colonic bacteria or iatrogenic contamination from paracentesis. Suspect in all patients with ascites and fever. Can be asymptomatic.
How is SBP diagnosed?	Paracentesis demonstrating >250 polymorphonuclear leucocytes (PMNs)/mL (absolute neutrophil count) or >500 white blood cells (WBCs)
How is ascites treated?	Medically—restrict salt and fluid intake, diuresis (especially with aldosterone antagonist), therapeutic paracentesis. Surgically—portosystemic shunts/transjugular intrahepatic portacaval shunts (TIPS)—both allow portal blood to bypass the liver.

ESOPHAGEAL VARICES

What is the #1 cause of esophageal varices?	Alcoholic cirrhosis
What is the mechanism of varices?	Portal hypertension
What portal system vein is responsible for esophageal varices?	Coronary vein
What methods are used to prevent rebleeding in esophageal varices?	• Medical—beta-blocker or octreotide • Surgical—TIPS or open surgical shunts; liver transplantation

HEPATIC CYSTS

What is the incidence of hepatic cysts in the general population?	Estimated 5%—most (~85%) remain asymptomatic and are never discovered.
What are the four different types of cystic fluid collections in the liver?	Congenital (simple) cysts Neoplastic cysts Hydatid cyst Hepatic abscess (pyogenic and amebic)
What epithelium lines congenital (simple) cysts?	Biliary-type epithelium (simple columnar)—cysts likely result from progressive dilation of microhamartomas.
Do these cysts contain bile?	No—they are not connected to the biliary tree.
The cystic fluid resembles what type of body fluid?	Plasma
What is the best imaging modality to characterize simple cysts?	Ultrasound
What characteristics indicate a benign lesion?	• Anechoic • Thin walls • Posterior acoustic enhancement • No septa or internal debris (though may be present if infected)
How are simple cysts treated?	Unroofing or fenestrating cysts to allow drainage only if symptomatic. Cysts recur after needle aspiration due to epithelium continually secreting fluid.
What must one consider when an atypical cystic liver mass is discovered?	Cystic/necrotic tumor which is often metastatic, though primary tumor such as cystadenocarcinomas can arise.
What findings on ultrasound suggest cystic neoplasm?	• Thick walls • Multiple septations • Calcification
How are neoplastic cysts treated?	Surgical resection especially for cystadenomas, due to malignant potential. Marsupialization or drainage not indicated due to high rates of infection and recurrence if malignant.

What is the typical patient population presenting with cystadenomas?	Middle-aged women
Are neoplastic cysts usually serous or mucinous?	Mucinous (in contrast to congenital cysts, which are usually are serous) (**m**alignant = **m**ucinous)
What is the autosomal dominant disorder that results in innumerable liver cysts that resemble simple cysts?	Polycystic liver disease
What other disorder frequently accompanies this?	Polycystic kidney disease—renal cysts usually precede liver cysts
Does this disorder affect liver functioning?	Rarely associated with liver failure (unlike **polycystic kidney disease** [PKD] which is associated with renal failure)
How is this disorder treated?	Surgical resection of area with greatest density of cysts, but only if symptomatic
What is the parasite causing hydatid cysts?	*Echinococcus granulosus.* Cysts can occur anywhere in the body, especially the lungs. >50% have hepatic cysts.
What is the definitive host?	Dogs are the definitive host.
What is significant about the lining of the cyst?	Host tissue contains the endocyst of larval origin.
Why is needle aspiration or biopsy avoided?	Disruption of cyst lining may result in seeding of parasite and induce an anaphylactic reaction.
What two characteristics on imaging suggest *Echinococcus* infection?	Daughter cysts and calcification
What is the significance of pericystic calcification?	Suggests death of parasite; therefore, no further treatment is indicated.
What are the symptoms of *Echinococcus* infection?	Symptoms and their causes: • Compression (abdominal pain, obstructive jaundice) • Rupture (biliary colic, jaundice, urticaria from biliary obstruction) Note: Rupture of cysts responsible for the formation of daughter cysts.
How is the diagnosis of a hydatid cyst made?	• Enzyme-linked immunosorbent assay (ELISA) for echinococcal antigen • CT and ultrasound can show simple or complex cysts

079_BOOKZ

What is the first-line treatment of a hydatid cyst?	Albendazole
How is surgical treatment accomplished?	If cyst is refractory to anthelmintics, surgery is considered. Since risk of rupturing the cyst during removal is so high, controlled aspiration of the cyst is followed by removal of cyst lining and sterilizing bed with silver nitrate.
What are the most common causes of pyogenic abscesses?	• Instrumentation • Gastrointestinal pathology (diverticulitis or appendicitis) • Biliary tract pathology (ascending cholangitis) Note: However, any infection can cause hematogenous seeding.
What are the types of organisms encountered in pyogenic liver abscess?	*Staphylococcus aureus*, *Streptococcus*, and anaerobes • If enteric bacteria is suspected—gram-negative aerobes, gram-positive aerobes, and anaerobes • 40% monomicrobial • 40% polymicrobial • 20% culture negative
What are the common symptoms of pyogenic abscesses?	• Right upper quadrant (RUQ) pain • Fever • Leukocytosis • Occasionally jaundice
What diagnostic studies are needed?	• Right upper quadrant (RUQ) ultrasound • CT with contrast • Percutaneous aspiration with Gram stain and culture of fluid
What is the most common cause of amebic abscess?	*Entamoeba histolytica*
In what region of the world is this most common?	Central and South America
What is the typical appearance of aspirated cystic fluid?	Anchovy paste
Is the cystic fluid sterile or infected?	Sterile
What are the common symptoms of amebic abscess?	Same as pyogenic abscess; however, may have history of diarrhea, weight loss, and travel

What lobe of the liver is typically involved with amebic abscess?	Right lobe (~90%) may rupture through right hemidiaphragm
What is the treatment for:	
Pyogenic abscess?	Percutaneous aspiration, drain placement, and antibiotics
Amebic abscess?	Metronidazole (*Entamoeba histolytica*)

079_BOOKZ

CHAPTER 9

Gallbladder

Which is the most posterior of the three structures of the portal triad?

The portal vein. The common duct, portal vein, and hepatic artery make up the portal triad (see Fig. 9-1).

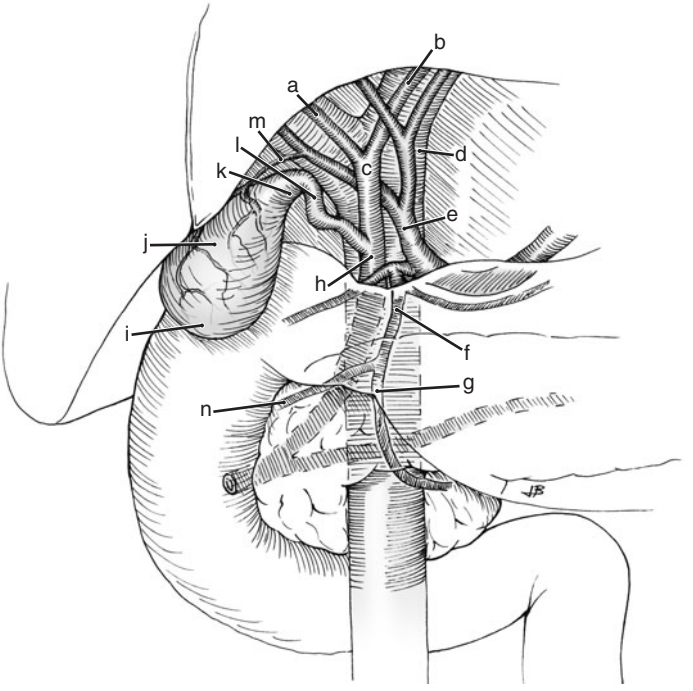

Figure 9-1 Anterior aspect of the biliary anatomy. *a*. Right hepatic duct. *b*. Left hepatic duct. *c*. Common hepatic duct. *d*. Portal vein. *e*. Hepatic artery. *f*. Gastroduodenal artery. *g*. Right gastroepiploic artery. *h*. Common bile duct. *i*. Fundus of the gallbladder. *j*. Body of the gallbladder. *k*. Infundibulum. *l*. Cystic duct. *m*. Cystic artery. *n*. Superior pancreaticoduodenal artery. Note the situation of the hepatic bile duct confluence anterior to the right branch of the portal vein, and the posterior course of the right hepatic artery behind the common hepatic duct. [*Reproduced, with permission, from Brunicardi CF et al (eds): Schwartz's Principles of Surgery, 8th ed. New York: McGraw-Hill, 2005:1188.*]

Copyright © 2008 by The McGraw-Hill Companies, Inc. Click here for terms of use.

079_BOOKZ

What three structures define the triangle of Calot?	1. Superiorly: inferior margin of liver 2. Medially: common hepatic duct 3. Laterally: cystic duct
What artery transverses this triangle?	Right hepatic artery and the cystic artery >90% of the time. Many variants exist. These are important anatomical landmarks during cholecystectomy in order to successfully ligate the arterial supply to the gallbladder, while avoiding injury to the right hepatic artery.
Where is the ampulla of Vater (also known as papilla) located (see Fig. 9-2)?	Second portion of the duodenum
What does this drain?	Common bile duct and pancreatic duct (though anatomic variations exist)
What sphincter surrounds the common bile duct to regulate bile flow?	Sphincter of Oddi

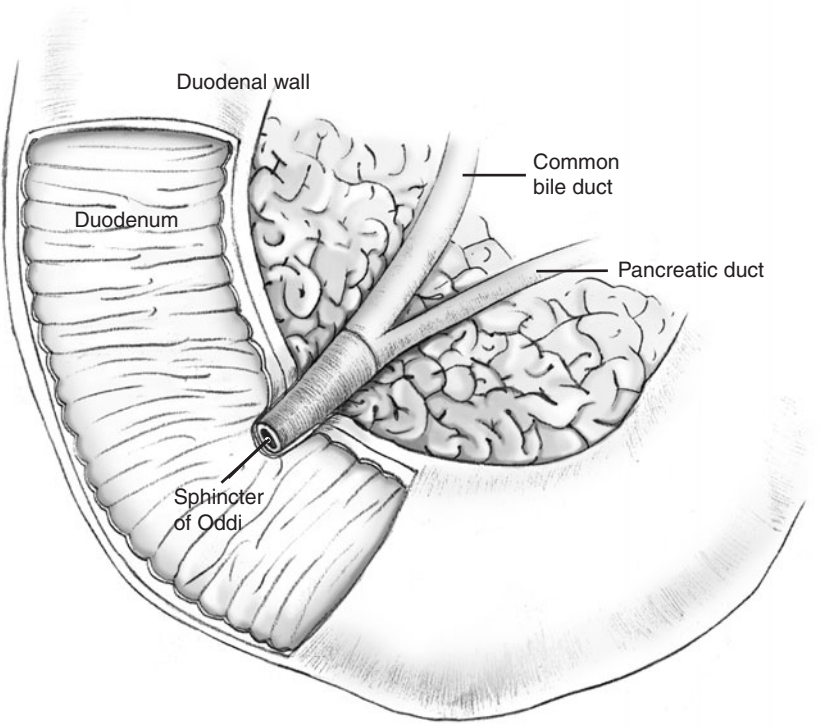

Figure 9-2 Pancreatic and common bile duct join to form the major papilla.

What is the "double duct" sign?	Dilation of pancreatic and common bile duct seen on imaging studies—can be seen in distal obstruction (ampullary/pancreatic carcinoma, stricture, stone)
What is the major stimulus for contraction and release of bile by the gallbladder?	Cholecystokinin
What cell produces this?	Pancreatic acinar cells
What are the three major lipids found in bile?	1. Phospholipids (lecithin) 2. Bile salts (chenodeoxycholic acid) 3. Cholesterol Note: A change in relative concentration of these lipids promotes the precipitation of cholesterol.
Following secretion from the gallbladder, where is the majority of bile reabsorbed in the intestines?	Terminal ileum
What laboratory test can be used to distinguish elevated alkaline phosphatase from hepatic versus skeletal origin?	GGT (gamma-glutamyltranspeptidase) or 5-nucleotidase which is elevated in biliary obstruction
Indicate whether the following will be decreased, unchanged, or increased in the event of bile duct obstruction:	
Alkaline phosphatase	↑ (confirm with 5-nucleotidase or GGT)
Alanine aminotranferease/aspartate aminotransferase (AST/ALT)	Mildly ↑ (alkaline phosphatase >AST/ALT)
Urobilinogen	↓ (produced from bacterial metabolism of bilirubin in intestine, reabsorbed, and secreted in urine—Obstruction causes less secretion in intestine = less absorption)
Amylase	Mildly ↑ (large ↑ = think pancreatitis)
Direct bilirubin	↑
Indirect bilirubin	Unchanged
What are the three types of gallstones?	1. Cholesterol stones 2. Mixed stones 3. Pigment stones (calcium bilirubinate)

Which is the most common?

Mixed stones (>70%), cholesterol and pigment (~10% each)

What are the two types of pigmented stones and what are they associated with?

1. Black, which are found in gallbladder, hemolytic disorders (sickle cell, spherocytosis), and cirrhosis
2. Brown, which are found in bile ducts and infected bile

What is biliary colic?

Intermittent mild to severe crampy right upper quadrant (RUQ) pain without fever or lab abnormalities

What is the cause?

Transient obstruction of the cystic duct due to gallstones

What are the six F's regarding risk factors for gallstones?

Fat

Female

Forty

Fertile

Family (more common among Native Americans)

Flatulence/intolerance to fatty foods

What are other risk factors for development of gallstones?

- Oral contraceptive pill (high dose estrogen)
- Pregnancy
- Diabetes—slow bile motility
- Rapid weight loss
- Cholesterol lowering medications (changes relative concentration of lipids in bile)
- Total parenteral nutrition
- Disorders affecting the terminal ileum (resection, Crohn's)—decrease absorption of bile (also fat soluble vitamins and B_{12}) causing supersaturation of cholesterol
- Cirrhosis
- Hemolytic disorders

What percentage of patients with gallstones will develop symptoms?

Approximately 1% per year—smaller stones more often obstruct and become symptomatic. (Therefore, prophylactic cholecystectomy not needed for asymptomatic patients.)

What happens to the risk of developing complications as the length of time the gallstones remain asymptomatic increases?

Decreases—The longer the stones remain asymptomatic the less likely they will ever cause symptoms.

079_BOOKZ

What is the preferred treatment of asymptomatic gallstones diagnosed during laparotomy?	Cholecystectomy (if technically feasible) due to increased likelihood of acute cholecystitis postop (dehydration, fasting/weight loss, hypotension, immobilization)
Which stones are radiolucent and which are radiopaque?	Degree of calcification determines radiopaque vs radiolucent. The more "pigment" correlates to more calcification. • Mixed—~15% calcify = radiopaque • Cholesterol—radiolucent • Pigment—~50% calcify = radiopaque Note: Only about 15% of all gallstones are visible on abdominal x-ray, the majority of which are mixed.
What is the initial imaging study of choice for biliary disease?	Ultrasound (not sensitive for detecting stones in bile duct but can suggest distal obstruction from dilation of ducts)
What are the characteristic findings in cholecystitis?	Pericholecystic fluid collection, thickened gallbladder, cholelithiasis
What is the diameter of a normal common bile duct?	6 mm is the upper limit of most healthy adults. 10 mm is the upper limit of normal in patients >65.
What is an HIDA scan and what is it used for?	Hepatobiliary iminodiacetic acid scan—inject radiolabeled technetium IV, which in normal conditions is excreted in bile—useful to detect choledochal cyst, bile leak, biliary tree **obstruction** (not necessarily stones)
Determine the location of the obstruction with the following HIDA scan findings:	
No visualization of gallbladder?	Cystic duct (make sure patient has not undergone cholecystectomy! False positive in patients on TPN or fasting = cholestasis)
No visualization of duodenum?	Common bile duct
Describe the following procedures and when they are indicated:	
Percutaneous transhepatic cholangiogram (PTC)	Direct injection of contrast through the skin into intrahepatic ducts—used with proximal obstruction

079_BOOKZ

	causing dilation of ducts—allows cytologic sampling, stone extraction, and catheter placement
Endoscopic retrograde cholangiopancreatogram (ERCP)	Injection of contrast through sphincter of Oddi—used for suspected distal or ampullary lesions—allows biopsy, sphincterotomy (used to extract stones), or stent placement
Define the following:	
Cholelithiasis	Presence of gallstone in gallbladder
Cholecystitis	Inflammation of gallbladder—often caused by a stone obstructing the cystic duct
Choledocholithiasis	Gallstone in the common bile duct causing a variable degree of obstruction (can occur after cholecystectomy)
Cholangitis	Bacterial infection of biliary tree usually from choledocholithiasis or primary sclerosing cholangitis (affects intra- and extrahepatic ducts)
What is Charcot's triad?	1. RUQ pain 2. Fever 3. Jaundice
Reynold's pentad?	Charcot's triad, plus 4. Hypotension 5. Altered mental status Note: Charcot's triad is associated with suppurative cholangitis.
What is Murphy's sign?	Cessation of inhalation on palpation of RUQ
What does it indicate?	Indicates inflammation of gallbladder. Pain occurs as gallbladder descends with contraction of diaphragm. Often elicited during RUQ ultrasound.
A nontender, palpable gallbladder in a patient with jaundice is referred to as which sign?	Courvoisier's sign

079_BOOKZ

What does this suggest?	Pancreatic head carcinoma causing passive distention of gallbladder—an obstruction caused by stone is typically associated with a thickened gallbladder which resists distention (One type of Courvoisier's sign is VSOP—**v**ery **s**uspicious **o**f **p**ancreatic head mass)
Make the diagnosis of acute or chronic cholecystitis, choledocholithiasis or cholangitis:	
Restless patient with colicky RUQ pain with normal liver function tests (LFTs) and normal complete blood count (CBC)	Chronic cholecystitis
Febrile patient with nausea/vomiting and constant RUQ pain with a history of biliary colic	Acute cholecystitis
Charcot's triad/Reynold's pentad	Cholangitis
Murphy's sign	Acute cholecystitis
Afebrile patient with light colored stools and dark urine with a history of biliary colic and fluctuating degrees of jaundice	Choledocholithiasis (produces variable degrees of obstruction—jaundice due to malignancy is typically progressive.)
What is the appropriate treatment for a patient with chronic cholecystitis?	Analgesics and cholecystectomy (also intraoperative cholangiogram to examine for stones in common bile duct)
What if the patient has numerous comorbidities?	Two options exist: 1. Extracorporeal shock wave lithotripsy 2. Ursodeoxycholic acid dissolution (for small cholesterol stones)
What is the cause of inflammation in acute cholecystitis?	Obstruction of cystic duct causes ischemia, edema, and impaired venous return leading to intense inflammation (same mechanism as appendicitis). Systemic signs of infection occur in 75% of cases.
What microorganisms are commonly associated with acute cholecystitis?	*Escherichia coli*, *Streptococcus faecalis*, *Clostridium perfringens*, *Klebsiella pneumoniae*—mixed enteric flora
What are the complications of acute cholecystitis?	Gallbladder perforation, gangrene, or empyema

079_BOOKZ

A patient with acute cholecystitis develops diffuse rebound tenderness. What is the likely explanation for these findings?

Diffuse rebound tenderness reflects diffuse inflammation of parietal peritoneum likely caused by perforation.

What is the differential diagnosis of these findings?

Acute appendicitis, perforated peptic ulcer, acute pancreatitis

What two imaging studies should be performed?

Upright abdominal x-ray (evaluate for pneumoperitoneum, ie, perforated ulcer) and ultrasound

What is the time period in which cholecystectomy is recommended for acute cholecystitis?

Within 72 h from symptom onset. Performing cholecystectomy in patients >72 h from the onset of symptoms has an increased rate of complications and these patients should be allowed 4–6 weeks for resolution of inflammation before cholecystectomy.

What is the preferred treatment for systemic symptoms extending beyond this time period?

Percutaneous cholecystostomy and medical management: nothing by mouth, *nihil per os* (NPO), nasogastric (NG) tube to treat paralytic ileus from local inflammation, intravenous (IV) fluids, broad spectrum antibiotics (gram-negative and -positive aerobes), analgesics, and cholecystectomy when stable (see Fig. 9-3)

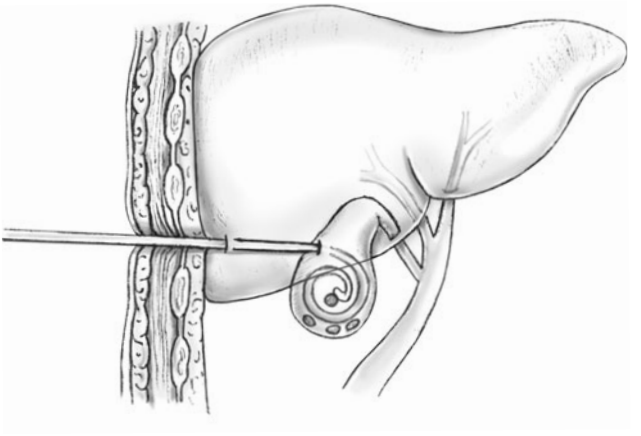

Figure 9-3 Percutaneous cholecystostomy drain placement. In cholecystitis, fluid may be purulent or colorless, so-called white bile.

079_BOOKZ

When should cholecystectomy be performed regardless of time course of disease?	If complications arise, ie, perforation, abscess, gangrene (see Fig. 9-4)

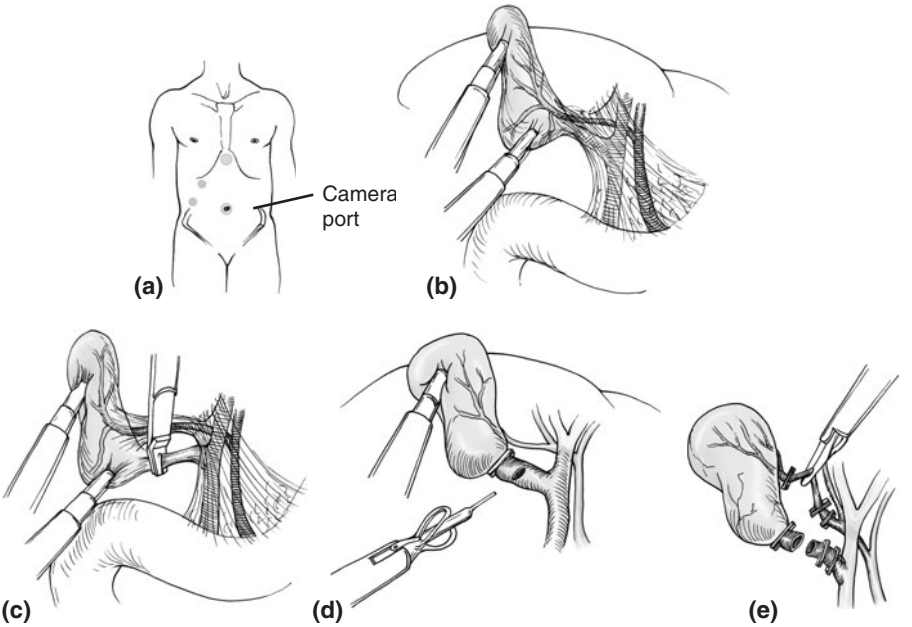

Figure 9-4 Technique of laparoscopic cholecystectomy. Cystic artery is found in the triangle of Calot (liver edge, cystic duct, common hepatic duct). Cystic duct and artery are then clipped and divided and gallbladder is incised off the liver bed. [*Reproduced, with permission, from Brunicardi CF et al (eds): Schwartz's Principles of Surgery, 8th ed. New York: McGraw-Hill, 2005:1205.*]

What is the mechanism responsible for causing gangrenous cholecystitis?	Local inflammation causes thrombosis of cystic artery resulting in necrosis of gallbladder.
Abdominal x-ray showing air within the lumen of the gallbladder in a patient suspected to have acute cholecystitis is referred to as what?	Acute emphysematous cholecystitis, which is invasion of gas-forming bacteria into wall usually secondary to gangrenous cholecystitis
What are these patients at high risk for developing?	Perforation
What is the recommended treatment for these patients?	Emergent cholecystectomy and antibiotics, including coverage against anaerobes (specifically *Clostridium*)

What are common complications of gallbladder peforation?	Peritonitis (infectious or chemical) and subhepatic abscess formation
Patients receiving blood transfusion, TPA, and mechanical ventilation are at risk for developing which type of cholecystitis?	Acute acalculous cholecystitis. Other risk factors include post-trauma/burn, surgery, sepsis, dehydration, sphincter of Oddi spasm, collagen vascular disease (fibrosis), and HIV
What is the preferred treatment?	Managed similar to calculous cholecystitis with cholecystectomy (percutaneous cholecystostomy if multiple comorbidities)
What are the typical symptoms associated with choledocholithiasis?	Episodic biliary colic with fluctuating degrees of jaundice, light-colored stools, and tea-colored urine—all a result of variable degrees of obstruction of common bile duct
What are the symptoms of acute cholangitis?	Acute cholangitis is an infected choledocholithiasis—therefore, all the previous symptoms plus fever and RUQ pain (Charcot's triad).
What is suppurative cholangitis?	Pus in biliary ducts, associated with Reynold's pentad
What bacteria are commonly associated with cholangitis?	Same as acute cholecystitis *(E. coli, S. faecalis, C. perfringens, K. pneumoniae)* plus *Pseudomonas* and *Enterobacter*
What is the proper treatment of cholangitis?	NPO, NG tube, IV fluids, IV antibiotics (anaerobic and aerobic), and once stable ERCP or PTC and stone removal
How is suppurative cholangitis treated?	IV antibiotics and urgent decompression. Remember to check and fix coagulopathies
Match the signs/symptoms most associated with either primary biliary cirrhosis, primary sclerosing cholangitis, or both:	
Male predominance	Primary sclerosing cholangitis
Onset in middle-age (>40)	Both

079_BOOKZ

Associated with inflammatory bowel disease	Primary sclerosing cholangitis (~70% have IBD, particularly UC)
Female predominance	Primary biliary cirrhosis
Strictures of intra- and extrahepatic biliary tree	Primary sclerosing cholangitis
Antimitochondrial antibodies	Primary biliary cirrhosis
Most common symptoms are fatigue and pruritis	Both
Granulomatous destruction of intrahepatic bile ducts	Primary biliary cirrhosis
ERCP diagnostic test of choice	Primary sclerosing cholangitis
Increased risk of cholangiocarcinoma	Primary sclerosing cholangitis
Liver transplant only effective treatment	Both
Associated with autoimmune disorders (pernicious anemia, Sjögren's, etc)	Primary biliary cirrhosis
What is a likely cause of small bowel obstruction in a 75-year-old female with a history of biliary colic with dilated loops of small bowel with multiple air-fluid levels and pnemobilia on abdominal x-ray?	Gallstone ileus. Often found in older females with nonspecific symptoms. Gallstone most often enters duodenum through a fistula.
What is the incidence of small bowel obstruction from gallstones?	~2%
Where is the most common site of obstruction due to a gallstone?	*Distal ileum* > jejunum > stomach. This is due to the fact that the distal ileum is most narrow just proximal to the ileocecal valve. As stones travel to this point they may produce episodic partial small bowel obstruction.
What is the triad of radiographic findings in gallstone ileus?	Rigler's triad: 1. Pneumobilia 2. Small bowel obstruction 3. Impacted gallstone
What is the appropriate treatment for gallstone ileus?	Laparotomy and enterolithotomy (stone extraction). Cholecystectomy and fistula correction should be performed if patient can tolerate surgery.

079_BOOKZ

What are the most common symptoms associated with gallbladder cancer?

Asymptomatic until advanced and usually present with vague RUQ pain, weight loss, fatigue, jaundice

What is the most common histological variant?

Adenocarcinoma

What factors are associated with a higher risk of developing gallbladder cancer?

Gender (female)

Gallstones

Age (>60 years)

Porcelain gallbladder (indication for prophylactic cholecystectomy ~50% have carcinoma)

Alcohol and tobacco

What is the earliest/most common route of metastases?

Local invasion (into porta hepatis or "drop" metastases into peritoneum) and lymphatic spread

What is the prognosis of invasive gallbladder cancer?

<5% 5-year survival rate

What is cholangiocarcinoma?

Carcinoma (90% adenocarcinoma/10% squamous cell) of bile ducts

What risk factors are associated with this?

1. Gallstones
2. Primary sclerosing cholangitis
3. Chronic parasitic infection (liver flukes *Clonorchis sinensis/Opisthorchis viverrini; Ascaris lumbricoides*)

What is an Altemeier's tumor?

Cholangiocarcinoma of intrahepatic bile ducts

What is a Klatskin tumor?

Perihilar cholangiocarcinoma (bifurcation of right/left hepatic ducts)

What is the treatment of cholangiocarcinoma?

Surgical resection is the only curative option. Must be locally contained (not invading vital structures) and have no evidence of metastases. Less than 10% are resectable at presentation.

What are the two most common symptoms of cholangiocarcinomas?

Jaundice and pruritus

079_BOOKZ

What are choledochal cysts?

Congenital cystic dilatation of the extrahepatic and/or intrahepatic biliary tree

What are the five types of choledochal cysts?

Type I: cystic dilatation of the CBD (95% of cysts)

Type II: CBD diverticulum

Type III: choledochocele, cystic dilatation of the distal CBD protruding in to the duodenum

Type IV: cystic dilatation of the CBD with extension to the intrahepatic ducts

- Type IVa: multiple cysts of the intrahepatic and extrahepatic bile ducts
- Type IVb: cysts involving only the extrahepatic bile ducts

Type V: cystic dilatation of the intrahepatic ducts with normal CBD, (Caroli's disease)

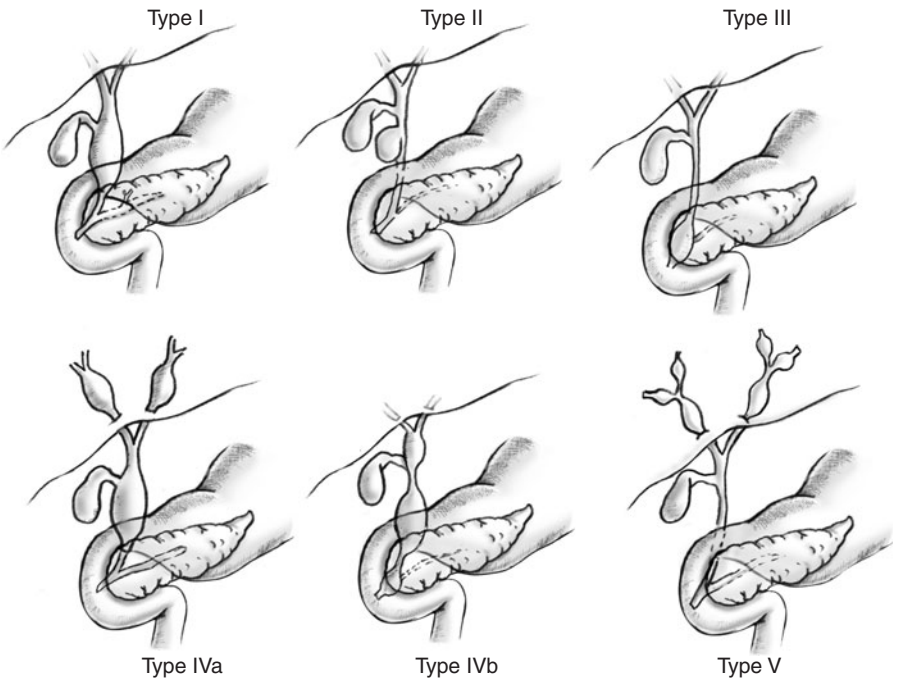

Figure 9-5 Five types of choledochal cysts.

What is the recommended treatment of each type of choledochal cyst?

Type I: complete excision of cyst with Roux-en-Y hepaticojejunostomy

Type II: complete excision of cyst with Roux-en-Y hepaticojejunostomy

Type III: <3cm endoscopic sphincterotomy, >3cm transduodenal excision

Type IV: complete excision of cyst with Roux-en-Y hepaticojejunostomy and liver lobar resection if intrahepatic disease is unilateral

Type V: Hepatic lobectomy if disease is unilateral, otherwise liver transplant

079_BOOKZ

CHAPTER 10

Pancreas

What two ducts does the ampulla of Vater drain?	Common bile duct and main pancreatic duct (duct of Wirsung) (see Fig. 10-1)
What is the pancreas divisum?	Affects ~10%; occurs when ventral and dorsal ducts do not fuse causing the pancreas to be drained by two ducts (see Fig. 10-2)
What are these patients at risk for?	Mostly asymptomatic; however, may cause recurrent pancreatitis

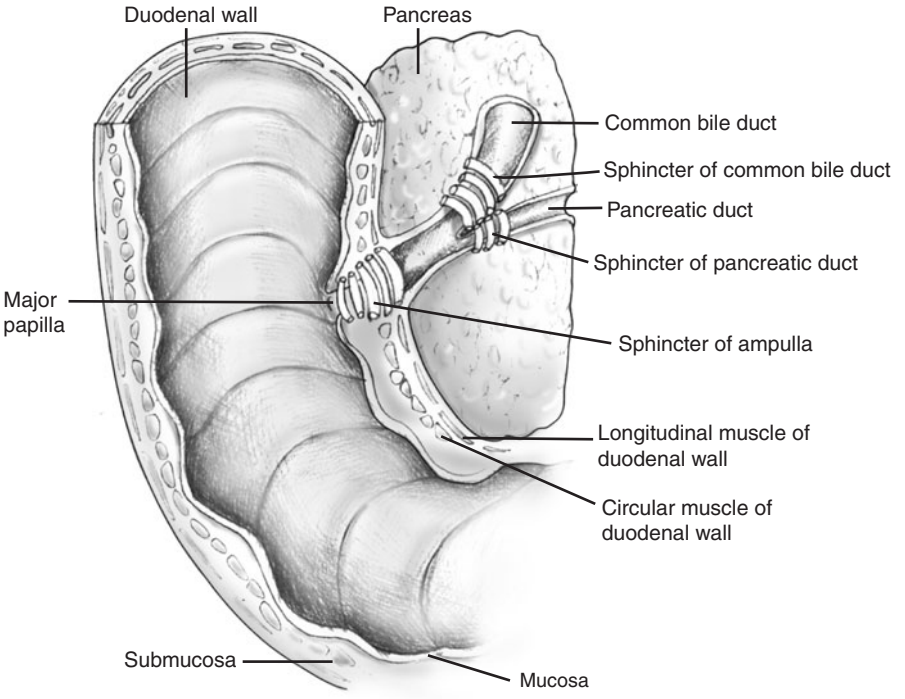

Figure 10-1 Anatomy of the major papilla.

Copyright © 2008 by The McGraw-Hill Companies, Inc. Click here for terms of use.

079_BOOKZ

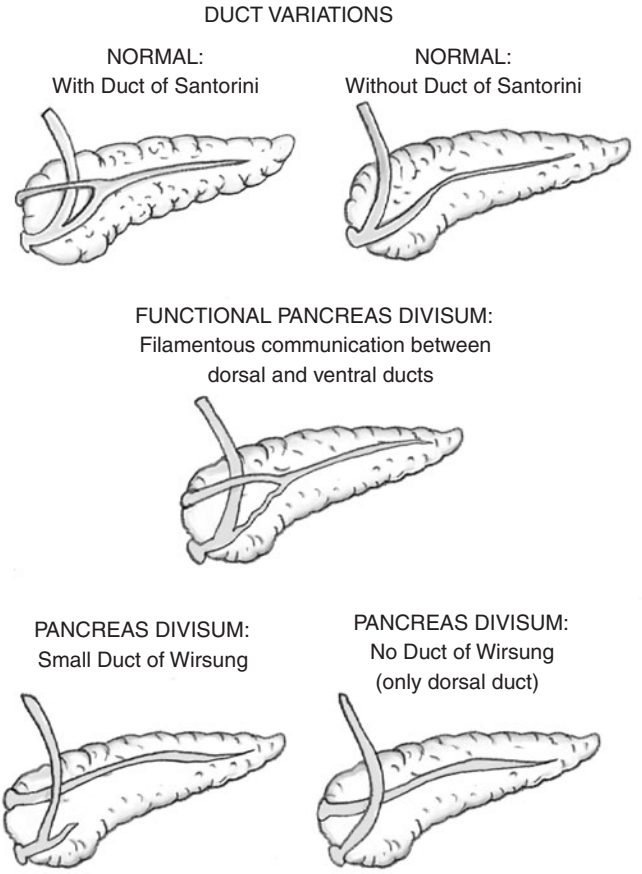

Figure 10-2 Pancreatic duct anatomy and pancreas divisum.

What is annular pancreas?	Incomplete rotation of ventral pancreatic bud causing ring of tissue surrounding duodenum (see Fig. 10-3)
What are these patients at risk for?	Duodenal obstruction (often seen in newborns)
What is the major artery supplying the pancreatic head (see Fig. 10-4)?	Gastroduodenal artery
Why is this important?	Also supplies duodenum, which means the duodenum must be resected if the pancreatic head is resected
What artery supplies the tail of the pancreas?	Greater pancreatic artery (a branch of the splenic artery)

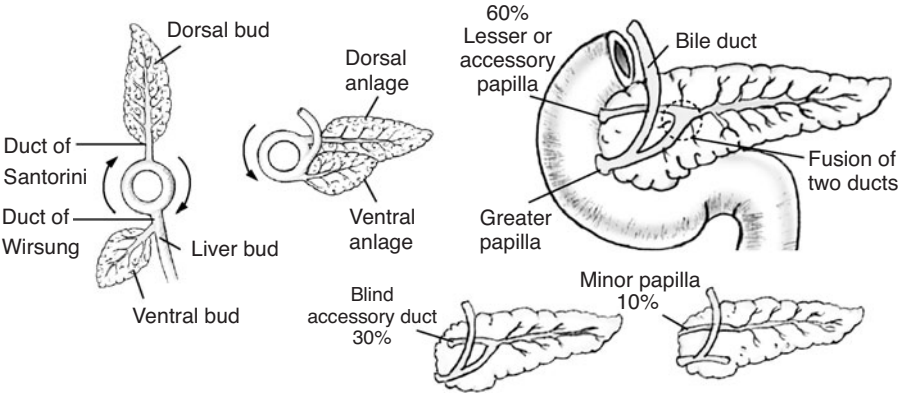

Figure 10-3 Embryology of the pancreas. Annular pancreas is due to abnormal migration of the dorsal and ventral pancreatic buds.

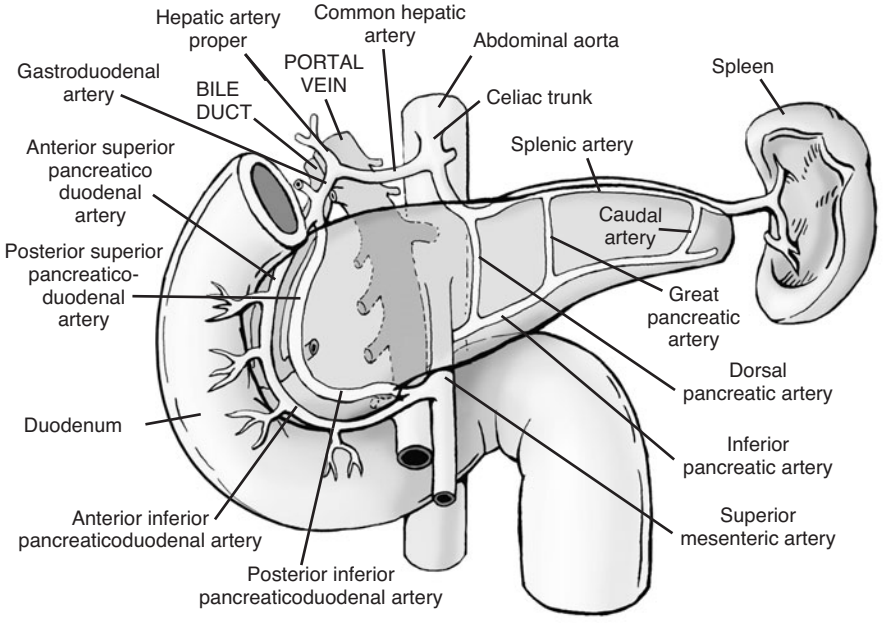

Figure 10-4 Arterial supply of the pancreas. [*Reproduced, with permission, from Brunicardi CF et al (eds): Schwartz's Principles of Surgery, 8th ed. New York: McGraw-Hill, 2005:1225.*]

An alcoholic patient presents with abrupt onset, severe epigastric pain radiating to the back with nausea and vomiting (n/v), anorexia, and partial relief when sitting up most likely presents with what?	Acute pancreatitis
What other diagnoses must be considered?	Perforated ulcer, mesenteric ischemia, cholecystitis
What are common causes of acute pancreatitis?	**"I GET SMASHED"** **I**schemia (shock, emboli, vasculitis) **G**allstones **E**thanol **T**rauma (blunt, penetrating, post-endoscopic retrograde cholangiopancreatography [ERCP]) **S**corpion sting **M**edications (thiazides, lasix, steroids, dideoxyinosine) **A**utoimmune **S**ick (mumps, CMV, HBV) **H**ypertriglyceridemia **E**ndocrine (hyperparathyroidism, hypercalcemia (ie, multiple myeloma) **D**uct obstruction (ampullary stenosis, cancer, pancreas divisum)
What are the following and what do they suggest?	
Grey-Turner's sign	Left flank ecchymosis
Cullen's sign	Periumbilical ecchymosis Note: Suggest retroperitoneal hemorrhage with blood dissecting through tissue planes causing the ecchymosis.
What laboratory studies may be used to aid in the diagnosis of acute pancreatitis?	Amylase (sensitive) • Amylase: creatine >5 • Extremely high, usually represents gallstone pancreatitis (alcohol pancreatitis usually involves a damaged/less functioning pancreas.) • Lipase (specific)
What two imaging modalities are commonly used to assess etiology and severity of acute pancreatitis?	1. Ultrasound useful for assessing cholelithiasis and pseudocyst formation

079_BOOKZ

2. Computed tomography (CT) (more sensitive)—useful for assessing pancreatic swelling, gallbladder pathologies, pseudocysts, duct caliber, and calcifications

Note: Magnetic resonance cholangiopancreatography (MRCP) useful for assessing bile and pancreatic ducts.

What do the following signs refer to on abdominal x-ray?

Both are nonspecific signs

Sentinel loop sign

Dilated proximal jejunal loop

Colon cutoff sign

Transverse colon spasm causes gas to end abruptly with no air distally.

What do the following signs refer to on upper GI barium studies?

Pad sign

Enlarged pancreatic head causes effacement of gastric antrum and duodenal mucosal folds.

Frostberg inverted-3 sign

Enlarged pancreatic head may cause traction on the medial wall of the duodenum producing an "ε" appearance.

What two indices can be used to assess prognosis?

1. Ranson's criteria (only useful in the first 48 h after admission)
2. Acute Physiology and Chronic Health Evaluation (APACHE II) (can be used at any time during hospitalization)

What are the prognostic factors using Ranson's criteria?

At admission

"**LA***st* **GAL**": **L**eukocytosis (>16,000), **A***st* (>250), **G**lucose (>200), **A**ge (>55), **L**DH (>350)

48 h after admission

"CHOBBS"

Calcium (<8)

Hematocrit (**H**ct) (>10 point decrease)

Oxygen (<60 mm Hg on room air)

Base excess (>4)

BUN (5 mg/100 mL increase)

Sequestration of fluid (>6 L)

Note: 3+ indicates severe pancreatitis.

What are the prognostic factors using the APACHE II criteria?

Initially developed to assess intensive care unit (ICU) patients, so think how you would when working a patient up:

Vitals: Temperature, mean arterial pressure, respiratory and heart rates, oxygenation

Neuro: Glasgow coma scale

Labs: pH (Arterial blood gas [ABG]), sodium/potassium/creatinine (renal), Hct/white blood cells (WBC) (complete blood count [CBC])

Note: 8+ indicates severe pancreatitis.

What is the prognosis of severe pancreatitis?

~15% are severe, ~50% of which have mortality

What is the treatment of acute pancreatitis?

The 4 N's

NPO (nil per os—nothing by mouth)

NG (nasogastric decompression)

NS (normal saline, ie, IV fluids)

Narcotics (pain control)

72 h after a patient presents with acute pancreatitis, he develops mental status changes, tachycardia, fever, hypertension. What is the likely explanation for these findings?

Alcohol withdrawal—always watch pancreatitis patients for this preventable complication.

What is the most important aspect to consider when treating severe pancreatitis?

Cardiopulmonary functioning

- Maintain perfusion with isotonic volume resuscitation (due to fluid sequestration)—monitor with Foley (urine output—maintain 0.5–1.0 cc/kg/h).
- Monitor respiratory function with ABG and pulse oximetry (ox) because of severe electrolyte abnormalities (calcium, magnesium) causing respiratory failure.

What are the indications for surgical management in acute pancreatitis?

- Establish diagnosis (if uncertain)
- Deterioration
- Relieve pancreatic or biliary duct obstruction (ie, gallstones)
- Complications

079_BOOKZ

What is the definitive treatment for gallstone (biliary) pancreatitis?

Cholecystectomy following resolution of acute episode of pancreatitis (also cholangiography with extraction of stones from common bile duct)

What are possible complications due to acute pancreatitis?

- Pancreatic necrosis
- Pancreatic abscess (may cause sepsis), 1–4 weeks after bout
- Pseudocyst: 2–3 weeks after bout with early satiety, abdominal pain, n/v, hyperamylasemia
- Paralytic ileus
- Fistulas: may be treated with total parenteral nutrition (TPN) 4–6 weeks
- Hemorrhage (usually due to erosion or arterial pseudoaneurysm)—signs/symptoms: abdominal pain, increasing abdominal mass, hypotension, falling Hct
- Respiratory insufficiency (from release of phospholipase into blood or thromboemboli)
- Chronic pancreatitis

What is the treatment for pseudocyst?

Conservative with TPN and avoiding by mouth, per os (PO) intake (surgery or drainage necessary if persistent)

What are potential complications?

Hemorrhage (from pseudoaneurysm) and infection (see Figs. 10-5 to 10-7)

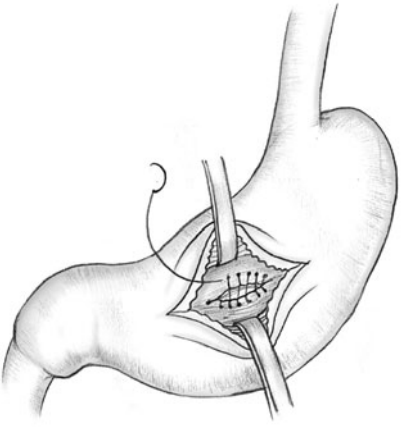

Figure 10-5 Open cystogastrostomy for drainage of pancreatic pseudocyst.

079_BOOKZ

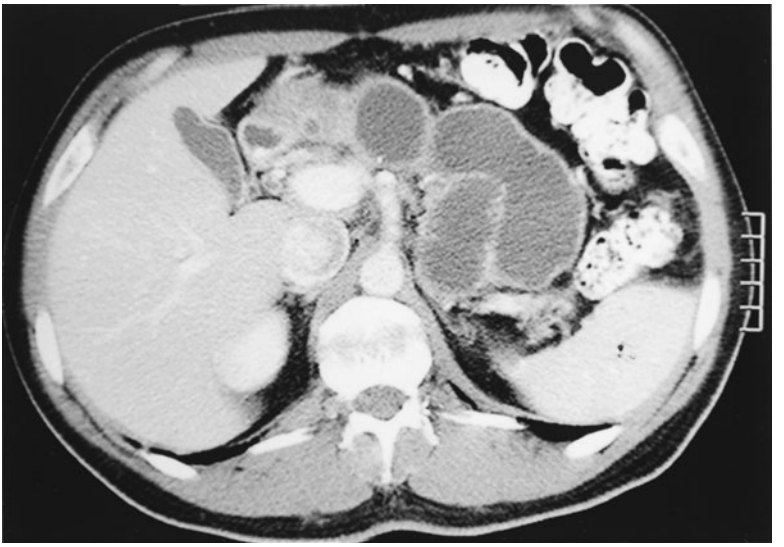

Figure 10-6 CT appearance of a multiloculated pancreatic pseudocyst. [*Reproduced, with permission, from Brunicardi CF et al (eds): Schwartz's Principles of Surgery, 8th ed. New York: McGraw-Hill, 2005:1257.*]

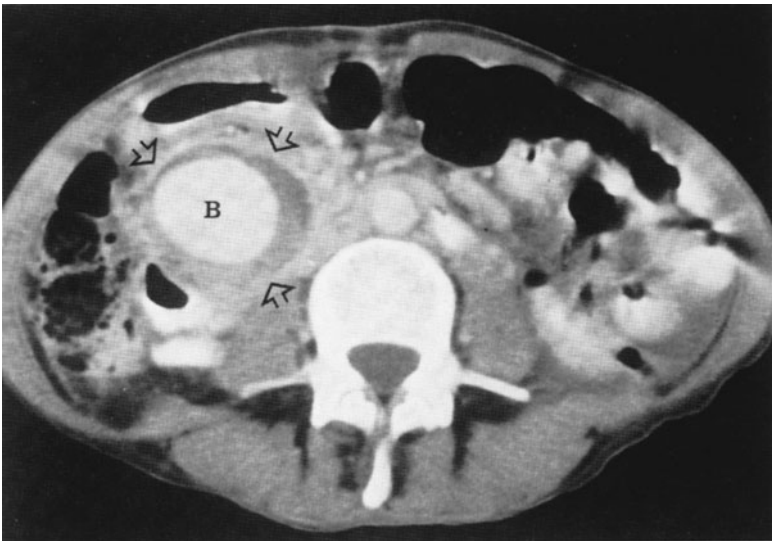

Figure 10-7 CT appearance of a gastroduodenal artery pseudoaneurysm due to pseudocyst erosion. [*Reproduced, with permission, from Freeny PC: Radiology, in Beger HG et al (eds):* The Pancreas. *London: Blackwell Science, 1998:728.]*

A patient with a history of acute pancreatitis and complaints of persistent epigastric pain, steatorrhea, and weight loss likely presents with what?	Chronic pancreatitis
What other condition is commonly associated with this?	Insulin dependent diabetes mellitus ~1/3 (endocrine insufficiency). Steatorrhea and weight loss is usually a sign of exocrine insufficiency.
How is chronic pancreatitis medically treated?	Analgesia, frequent/small volume/ low-fat diet, replacement of enzymes and insulin
What are the indications for surgical treatment in chronic pancreatitis?	• Unrelenting pain • Bile duct obstruction • Persistent fistula or pseudocyst
Describe the common surgical procedures for treating chronic pancreatitis.	Choice of procedure depends on location of disease and patency of ducts with attempts to preserve endocrine and exocrine function.
Duval procedure	Used for relief of proximal duct obstruction (not involving ampulla)—distal pancreatectomy with pancreaticojejunostomy allows retrograde draining of pancreas
Puestow procedure	(Most common) used when diffuse ductal dilation—involves incising pancreatic duct with side-to-side anastomosis with jejunum
Whipple procedure	Also known as pancreaticoduodenectomy used for disease restricted to head of pancreas or biliary or duodenal obstruction—resect head of pancreas, duodenum, pylorus, distal stomach, gallbladder, and distal common bile duct (see Fig. 10-8)
Distal pancreatectomy	For relief of distal obstruction of pancreatic duct
Total pancreatectomy with islet cell transfer	Last resort treatment. Islet cells isolated and injected into portal vein to seed liver. Risk of brittle diabetes.

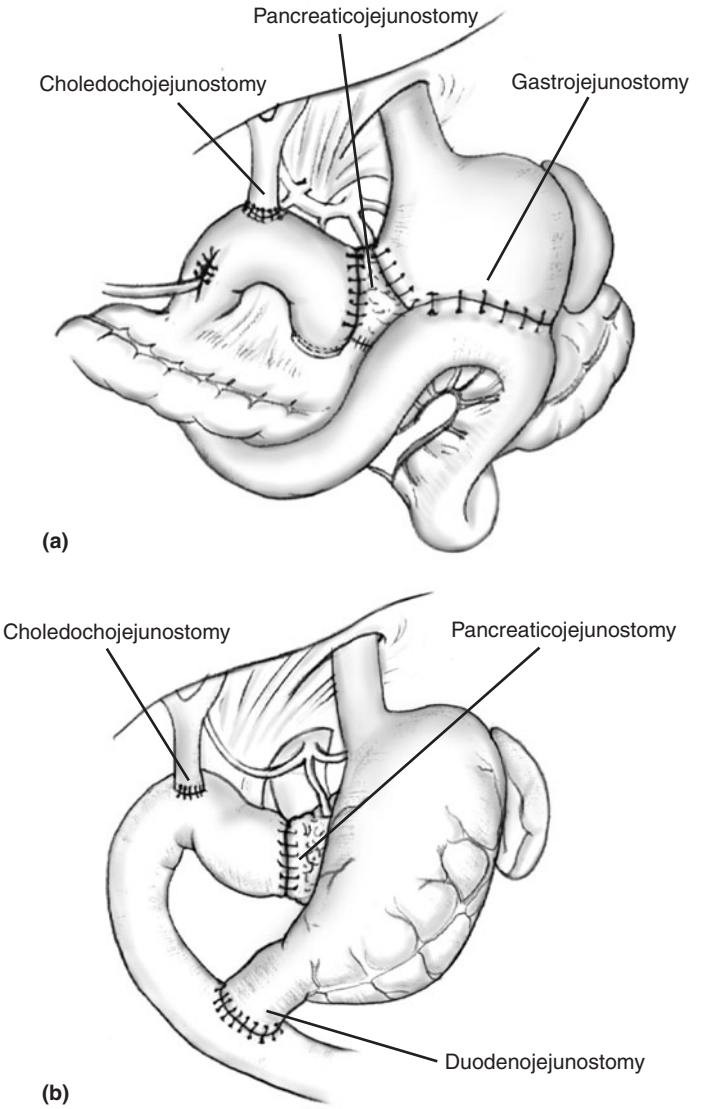

Figure 10-8 Whipple procedure (a), pylorus sparing pancreaticoduodenectomy (b).

A 60-year-old male smoker who presents with depression, chronic/vague epigastric pain radiating to the back, with weight loss and jaundice is at risk for what?	Pancreatic cancer—consider in any patient 50+ years of age with vague abdominal pain and weight loss.
Where is the disease likely located?	Pancreatic head
What imaging modality is used to diagnose?	CT

What if he had weight loss and jaundice without abdominal pain; where is the likely location of disease?	Periampullary region (usually symptomatic earlier in disease)
What imaging modality is used to diagnose?	ERCP
What is the most common pancreatic cancer?	Adenocarcinoma from ductal epithelium (90%)
What is the most common location?	Head (70%), body (20%), tail (10%)
What are the two most significant risk factors?	Cigarette smoking and increasing age (~70% 60+ years of age); also consider multiple endocrine neoplasia (MEN) syndrome if positive family history
What are the most common symptoms?	• Vague epigastric pain radiating to back • Weight loss and anorexia • Jaundice (if tumor involves head) • Weakness/fatigue/depression
Describe the following signs:	
Courvoisier's sign	Refers to palpable, nontender gallbladder in a jaundiced patient—suspect malignancy. (One type of Courvoisier sign is VSOP—**v**ery **s**uspicious of **p**ancreatic head mass.)
Trousseau's sign	Refers to migratory thrombophlebitis (~10% of patients with pancreatic cancer)
What is the preferred imaging study?	CT with contrast (initially ultrasound to evaluate liver and biliary tree if diagnosis is uncertain in a jaundiced patient)
What three radiographic signs suggest unresectable lesions?	Peritoneal/liver metastases, ascites, vascular invasion
How is the diagnosis of pancreatic cancer confirmed?	Percutaneous fine needle aspiration—should not be performed on patients with resectable lesions.
What is the definitive treatment for pancreatic cancer?	Whipple procedure (pancreaticoduodenectomy) for lesions in head and distal pancreatectomy for body and tail lesions—often laparoscopy is used first to assess for peritoneal metastases before laparotomy.

079_BOOKZ

What does a Whipple procedure entail?

- Removal of head of pancreas, distal stomach, pylorus (preserved = modified Whipple), duodenum, gallbladder, distal common bile duct, vagotomy
- Reconstruction: choledochojejunostomy, pancreaticojejunostomy, gastrojejunostomy

What are the two most common complications of a Whipple procedure?

1. Pancreatic fistula (drainage of amylase rich secretion)
2. Abscess formation and sepsis

What is the goal of palliative care in pancreatic cancer?

Relief of biliary and gastric obstruction

What is the common chemotherapy regimen for pancreatic cancer?

5-fluorouracil (5-FU) and gemcitabine with or without radiation therapy

What tumor marker is best used for following response to treatment?

Cancer antigen (CA) 19-9

What is the 5-year survival rate for pancreatic adenocarcinoma?

~5% (prognosis depends on clinical stage using TNM classification—Tumor, Nodal involvement, Metastasis)

What are the five islet cell neoplasms?

1. Insulinoma (β-cell)
2. Gastrinoma (δ-cell)
3. Glucagonoma (α-cell)
4. Somatostatinoma (D-cell)
5. VIPoma (D-cell)

Note: Insulinoma and gastrinoma are the most common.

What are the common symptoms and laboratory findings with an insulinoma?

Hypoglycemia (palpitations, tachycardia, tremulousness), elevated blood insulin, and c-peptide levels

CHAPTER 11

Endocrine

THYROID

What two arteries supply the thyroid gland?	1. Superior thyroid artery 2. Inferior thyroid artery
Where does each originate?	Superior thyroid artery arises from external carotid artery/inferior thyroid artery arises from thyrocervical trunk of subclavian artery. Note: In <5% of patients there is the thyroidea ima artery, which arises from the aorta or innominate artery (replaces absent inferior thyroid artery).
What two nerves innervate the thyroid gland?	1. Superior laryngeal nerve 2. Inferior (recurrent) laryngeal nerve
What does the recurrent laryngeal nerve (RLN) course around on the:	
Right?	Subclavian artery
Left?	Arch of the aorta adjacent to ligamentum arteriosum (See Fig. 11-1)
Where are the two most common places the RLN is injured during surgery?	1. Penetration into cricothyroid membrane 2. Crossing the inferior thyroid artery
Which is the only laryngeal muscle not innervated by the RLN?	Cricothyroid, which is innervated by the external branch of the superior laryngeal nerve
What is the main function of this muscle?	Adduction (tension) of vocal cords (however, does not affect cord position in injury to the RLN)
Unilateral injury to the RLN leads to what two symptoms?	Weak voice and ineffective cough (↑ aspiration risk)

Copyright © 2008 by The McGraw-Hill Companies, Inc. Click here for terms of use.

079_BOOKZ

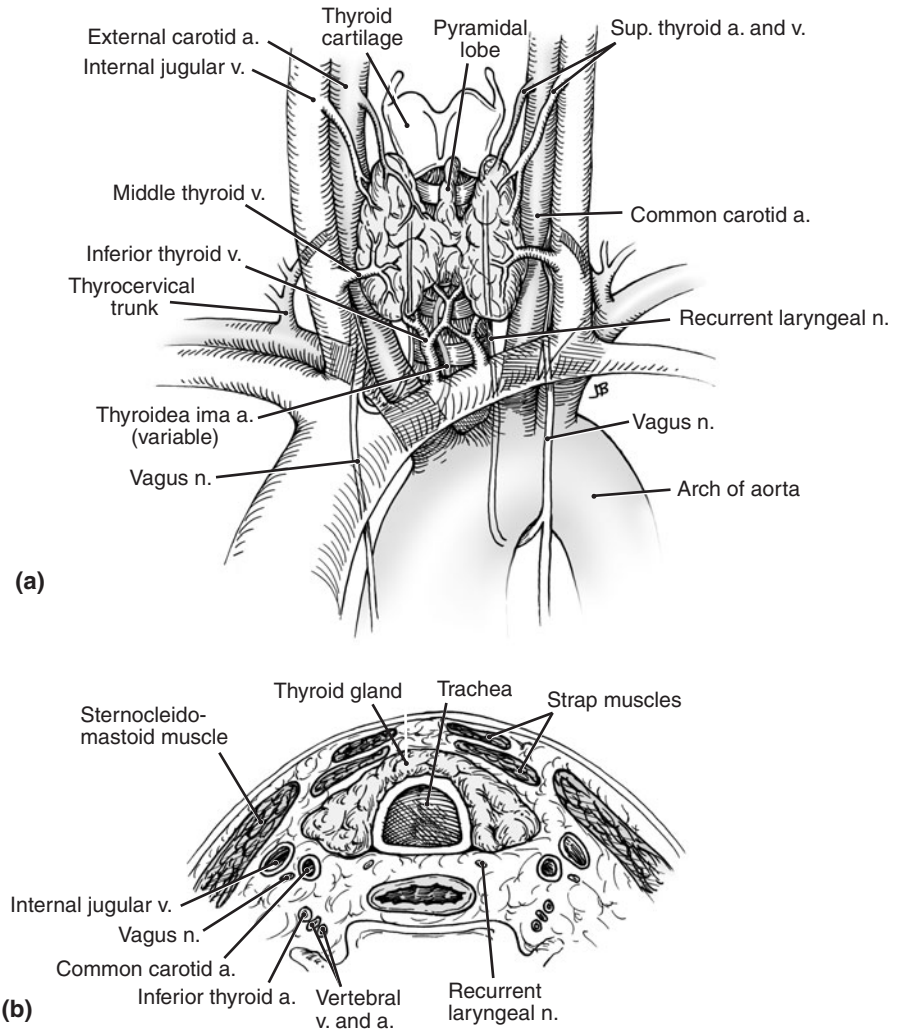

Figure 11-1 Anatomy of thyroid and surrounding neck structures. [*Reproduced, with permission, from Brunicardi CF et al (eds): Schwartz's Principles of Surgery, 8th ed. New York: McGraw-Hill, 2005:1399.*]

Bilateral injury may cause what?	Airway obstruction requiring emergency tracheostomy (though this is usually temporary because vocal cord paralysis is usually transient)
What is the function of follicular cells?	Produce, store, release T_3 (triiodothyronine) and T_4 (thyroxine)
Parafollicular cells (C cells)?	Secrete calcitonin

What are the four steps in thyroid hormone production?

1. Iodide trapping: Iodine, converted to iodide in enterocytes is taken up by thyroid with an adenosine triphosphate (ATP)-dependent mechanism.
2. Organification: Iodide is converted back to iodine and conjugated to tyrosine residues on thyroglobulin. Catalyzed by thyroid peroxidase.
3. Coupling: of monoiodotyrosines and diiodotyrosines to form T_3 and T_4.
4. Release: with stimulation by thyroid-stimulating hormone (TSH), lysosomal degradation of thyroglobulin results in release of T_3 and T_4.

What is the hormonal control of thyroid hormone release?

TRH is released from the hypothalamus, which stimulates the release of TSH in the anterior pituitary through the portal circulation. T_3 is primarily responsible for negative feedback at the hypothalamus and pituitary levels (See Fig. 11-2).

What is the physiologic role of T_3 and T_4?

↑ metabolic rate (pulse, CO, catecholamines, blood glucose). Excess causes nervousness, irritability, heart arrhythmias

What class of medications may be used to temporarily relieve the symptoms caused by T_3 and T_4?

Beta blockers (inhibit peripheral conversion of T_4 to T_3)

What is the difference between the terms hyperthyroidism and thyrotoxicosis?

- Thyrotoxicosis is a hypermetabolic state resulting from an increase in the levels of circulating thyroid hormone. Can result from increased synthesis (hyperthyroidism), inflammation, and destruction of the thyroid gland releasing existing thyroid hormone, or exogenous thyroid hormone.
- Hyperthyroidism is a type of thyrotoxicosis that results in the increased biosynthesis and secretion of thyroid hormones T_3 and T_4.

079_BOOKZ

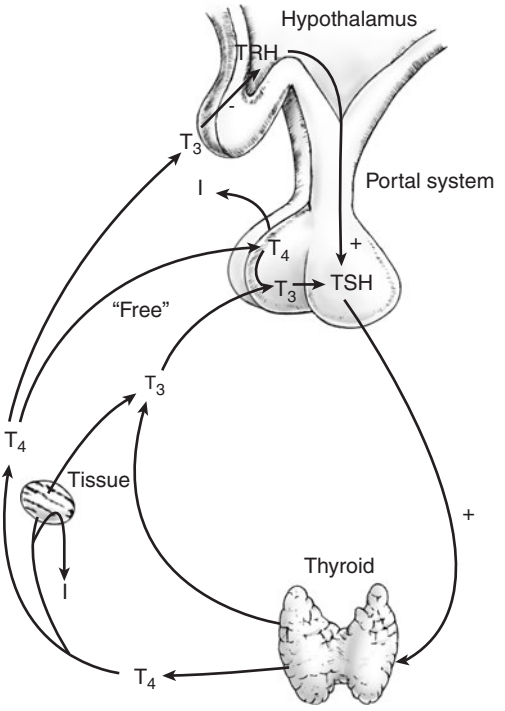

Figure 11-2 Hypothalamic-pituitary-thyroid axis.

Determine whether the following are associated with hypo- or hyperthyroidism:

Weight loss	Hyperthyroidism (associated with normal appetite)
Myxedema coma	Hypothyroidism
Pretibial myxedema	Hyperthyroidism
Facial/periorbital myxedema	Hypothyroidism
Menorrhagia	Hypothyroidism
Amenorrhea	Hyperthyroidism
Carpal tunnel	Hypothyroidism
Arrhythmia	Hyperthyroidism
Bradycardia	Hypothyroidism

What is the percentage of T_3 and T_4 released by the thyroid in euthyroid states?

~ 20% T_3 and 80% T_4.

How is the ratio of T_3 to T_4 affected in hyperthyroid states?

↑↑↑ T_3 and ↑/normal T_4, results in an ↑ T_3:T_4 output from the thyroid.

What is a better indicator of thyroid function free T_4 or total T_4?

Free T_4, because it is not affected by thyroid binding globulin, which is increased in pregnancy, estrogen, and progesterone and decreased in protein losing disorders, such as nephrotic syndrome and liver disease.

What is the most sensitive test for hypo- or hyperthyroidism?

Thyroid stimulating hormone (TSH). Low in primary hyperthyroid disorders, High in primary hypothyroid.

What is the physiologic role of calcitonin?

Inhibit osteoclast activity, though no effect on skeletal system following total thyroidectomy

Where is the embryologic origin of the thyroid gland?

Foramen cecum. C cells derived from neural crest cells, which is part of amine precursor uptake and decarboxylation (APUD) system.

A 10-year-old boy is seen for an asymptomatic, well-defined, midline neck mass that moves upward with protrusion of the tongue. What is the likely diagnosis?

Thyroglossal duct cyst (TDC), which is always connected to the base of the tongue. 80% found juxtaposed to the hyoid bone (cysts may become infected).

How is this treated?

Sistrunk operation—cystectomy in continuity with the mid-portion hyoid bone and a small section of muscle around the foramen cecum

Note: Avoid I & D—makes future complete excision more difficult.

What must be ruled out before excision for a TDC?

Ectopic thyroid. Palpate for normal thyroid placement (use computed tomography [CT] or ultrasound [US] if gland is not palpated).

Pediatric patient with difficulty swallowing, visible mass midline at the back of the tongue with no palpable thyroid gland.

Disease?

Lingual thyroid: failure of descent of the primordial thyroid tissue.

Treatment?	Exogenous thyroid: supplementation to decrease TSH and size of ectopic thyroid tissue. Radioactive iodine ablation second line. Surgery usually not necessary. Treatment needed if choking, dysphagia, airway obstruction, hemorrhage.
The pyramidal lobe is a remnant of what structure?	Distal thyroglossal duct, present in 50% of individuals, becomes palpable from disorders resulting in thyroid hypertrophy.
What is a goiter?	Enlargement of thyroid (regardless of functional status): can be diffuse, uninodular, or multinodular. Thyroid masses will move as patient swallows and may produce dysphagia or dyspnea, especially when arms are lifted above the head, if large or retrosternal.
How are small, euthyroid goiters treated?	Observation
Large, euthyroid goiters?	Exogenous thyroid to suppress TSH to decrease or stabilize size
What are five indications for surgical resection of goiters?	1. Obstructive symptoms 2. Continued growth with exogenous T_4 therapy 3. Suspected/proven malignancy 4. Substernal extension of goiter 5. Cosmetically unacceptable
What are four common causes of thyrotoxicosis?	1. Graves' disease (most common cause in United States, ~70%) 2. Solitary toxic nodule 3. Toxic multinodular goiter 4. de Quervain's thyroiditis (transient) Note: Less common causes include factitious thyrotoxicosis and struma ovarii.
Which one has a low radioactive iodine uptake (RAIU)?	de Quervain's thyroiditis: due to release of stored hormone from injury to the thyroid gland, not increased hormone production. Note: This test is not helpful in distinguishing causes of hypothyroidism.

079_BOOKZ

What are the two radioisotopes used for thyroid imaging?	1. Radioiodine (I-131 or I-123) 2. Technetium-99m pertechnetate (^{99m}Tc)
Cold nodules on RAIU will appear as what (hot or cold) using ^{99m}Tc?	Cold
Hot nodules using ^{99m}Tc will appear as hot or cold on RAIU scan?	Hot or cold: ^{99m}Tc is trapped by the thyroid but not organified. Thus, a cold/nonfunctioning nodule that is very vascular may appear "hot" with ^{99m}Tc but "cold" with RAIU.
A patient with hyperthyroidism has increased, homogeneous uptake of radioactive iodine with diffuse goiter. What is the likely diagnosis?	Graves' disease
What will the RAIU scan demonstrate in a patient with a toxic (hot) nodule(s)?	Increased uptake in the nodule(s) with decreased uptake in the remaining gland (due to suppression of TSH)
Is malignancy more common in a "hot" or "cold" lesion?	Cold, 15–20% carry malignancy; hot, <5% carry malignancies
Are thyroid nodules more common in males or females?	Females
Is cancer more common in a thyroid nodule found in a male or female?	Male
Match the following with the appropriate diagnosis of Graves', Hashimoto's, and/or de Quervain's diseases:	
Antibodies against the thyrotropin receptor	Graves' disease
Subacute thyroiditis	de Quervain's thyroiditis (multinucleated giant cell infiltrate)
Chronic thyroiditis	Hashimoto's thyroiditis (lymphocytic infiltrate)—also Riedel's (fibrous) thyroiditis
Antibodies to thyroid peroxidase and/or thyroglobulin	Hashimoto's thyroiditis
Diffuse, nonpitting edema and thickening of the skin on lower legs	Graves' disease (pretibial myxedema)
Often follows flu-like illness (coxsackievirus, mumps)	de Quervain's thyroiditis
Nontender, diffuse enlargement of thyroid gland	Hashimoto's thyroiditis, Graves' disease

079_BOOKZ

Exophthalmos	Graves' disease (proptosis usually referred to nonendocrinological cause of eye protrusion)
Most common cause of hyperthyroidism	Graves' disease
Thyrotoxicosis with a reduced RAIU	de Quervain's thyroiditis—early stages; from release of preformed thyroglobulin (struma ovarii (rare) can also present similarly)
↑ Risk of thyroid lymphoma	Hashimoto's thyroiditis (biopsy needed to distinguish from lymphoma)
Tender thyroid gland	de Quervain's thyroiditis (enlargement may be asymmetrical)

GRAVES' DISEASE

What are two medical treatments for Graves' disease?	1. Antithyroid medications—propylthiouracil (PTU), methimazole 2. Radioactive iodine ablation, which does not injure parathyroids or ↑ cancer risk
What is the preferred surgical treatment?	Subtotal thyroidectomy (must balance risk of recurrence with euthyroidism). Can be done in two ways—bilateral subtotal thyroidectomy or doing total lobectomy on one side and subtotal thyroidectomy on the other (Hartley-Dunhill procedure). Advantage of Hartley-Dunhill procedure is the ability to reenter only one side of the neck if reoperation is needed.
Medical therapy fails to improve what comorbid condition of Graves' disease?	Ophthalmopathy, which may cause blindness from compression of optic nerve or limited eye mobility from inferior or medial recti muscle involvement. Thyroidectomy may stabilize or improve ophthalmopathy, possibly by removing antigen stimulation.
What is the mechanism of action of PTU?	Inhibition of thyroperoxidase and peripheral conversion of T_4 to T_3. May be used to treat thyroid storm.

079_BOOKZ

What are the six surgical indications for subtotal thyroidectomy?

1. Young patient (↑ cancer risk, best chance at being euthyroid)
2. Pregnant or breast feeding patients (antithyroid medications cross placenta ➔ fetal goiter)
3. Goiters causing compressive symptoms
4. Allergic/adverse reaction to antithyroid medications
5. Confirmed or suspected cancer
6. Severe ophthalmopathy—progresses in 33% of patients after RAI vs 16% after surgery

What is the most common side effect of radioactive iodine ablation or surgery?

Hypothyroidism

Why is it necessary to achieve a euthyroid state before radioactive iodine ablation therapy?

Discontinuing antithyroid drugs in a euthyroid patient allows for maximal uptake of radioactive iodine.

Before surgery?

Minimize the risk of thyroid storm intra- and postop (also ↓ size and vascularity of gland)

What are the other preop medications that should be given?

Propranolol is best for presurgical thyroid therapy if patient is pregnant. Lugol's solution (iodine) for 10 days preoperatively to decrease vascularity and inhibit release of thyroid hormone.

Following surgery a woman with poorly controlled Graves' disease develops fever (103°F), diaphoresis, tachycardia (140 bpm) with periods of atrial fibrillation, and nausea/vomiting. She complains of heat intolerance and becomes agitated with tremors. What is the likely diagnosis?

Thyroid storm. This is an emergency diagnosed on clinical grounds—can lead to high-output cardiac failure and shock.

What are common causes?

Any stressor: infection, surgery, trauma, unstable medical condition (DKA, CVA). In only 1–2% of patients with hyperthyroidism will develop, usually in patients with poorly treated Graves' or toxic multinodular goiter.

What is another common cause for these symptoms?

Delirium tremen, also consider septic shock, neuroleptic malignant syndrome, diabetes mellitus (DM), pheochromocytoma.

079_BOOKZ

What are the four steps for treating this condition?

1. PTU: blocks the production and conversion of T_4 to T_3.
2. Lugol's solution or potassium iodide: inhibits the release of T_4 and T_3.
3. Dexamethasone: stress response causes cortisol deficiency (also blocks conversion of T_4 to T_3.
4. Propranolol/esmolol: inhibits response to catecholamines and blocks conversion of T_4 to T_3—Use caution as may worsen high-output congestive heart failure (CHF).

Note: Mortality—90% if untreated; 20% if treated.

What is the preferred treatment for toxic multinodular goiter?

Surgical resection. Lobectomy with subtotal thyroidectomy on the other side (ie, Hartley-Dunhill) after hyperthyroidism has been controlled. No need to preserve gland since chronic thyroid medication is needed to prevent recurrence.

Why is RAIU not preferred for treating toxic multinodular goiter disease?

- Poor/uneven uptake requires large doses.
- Greater likelihood of recurrent hyperthyroidism.
- RAI—Induced thyroiditis may cause swelling leading to airway compromise.

Determine whether the following refer to primary or secondary hypothyroidism.

↓TSH/↓T_4 and T_3

Secondary hypothyroidism (pituitary failure)—does not respond to thyrotropin-releasing hormone (TRH)

↑TSH/↓T_4 and T_3

Primary hypothyroidism

A 6-year-old boy presents with a fever and swollen, tender thyroid with erythema of the overlying skin. The boy recently had an earache which went untreated. What is the likely diagnosis?

Acute, suppurative thyroiditis. This is rare, but usually occurs following upper respiratory infection or otitis media (OM) and is associated with developmental abnormalities (ie, thyroglossal duct or brachial cleft cysts).

Note: May also develop in the immunocompromised.

079_BOOKZ

How is this treated?	Antibiotics and surgery if abscess develops or to correct anatomic abnormality
What is Riedel's thyroiditis?	A very rare condition where dense fibrotic tissue replaces thyroid parenchyma and extends to involve adjacent tissues (trachea, esophagus, parathyroid glands, RLN)
What are the characteristic exam findings of the thyroid?	Hard, stony or woody, fixed, painless goiter
What are the typical thyroid function lab values?	Euthyroid, but may be hypothyroid if there is extensive fibrosis
How is this treated?	Corticosteroids eorticosteroids and surgery, which relieves compression on trachea and establishes diagnosis
A 60-year-old male is referred for evaluation for a solitary thyroid nodule. There is no history of radiation exposure or family history of cancer. Exam reveals a small, nontender, hard mass without any associated lymphadenopathy. What is the next step in establishing a diagnosis?	Fine needle aspiration (FNA)
The test is reported as nondiagnostic. What should be done next?	Repeat the FNA, as this is the most important test in evaluating a mass. Thyroid cancer is more common in women; however, a thyroid mass has a greater likelihood to be cancerous in men.
Testing shows the mass to be a benign colloid nodule. What is the next step in management?	T_4 therapy and monitor suppression with TSH levels: • If mass is unchanged in size, repeat FNA • If mass shrinks, continue T_4 • If mass enlarges, thyroidectomy Note: Thyroidectomy is accepted if there is a family or radiation exposure history. A suspicious follicular lesion that is "hot" on RAIU can be treated with RAI or thyroidectomy.
What are two indications for surgical resection of a cystic thyroid mass?	1. Recurrent after three attempts at drainage 2. Residual mass following aspiration

Thyroid cancer incidence increases linearly with low dose radiation (<2000cGy). Why does the incidence of thyroid cancer decrease with doses >-2000cGy?	Higher doses cause destruction of the gland, while lower doses allow mutations to accumulate within the DNA.
Determine the type of thyroid cancer (papillary, follicular and/or medullary) associated with the following:	
The most common thyroid cancer in the United States	**P**apillary carcinoma—**P**opular in the United States (80%)
The most common thyroid cancer following radiation exposure	Papillary carcinoma
The most common thyroid cancer in iodine deficiencies	Follicular carcinoma
Multiple endocrine neoplasia (MEN) 2A or 2B	**M**edullary carcinoma—associated with **M**en
Lymphatic spread	Papillary and medullary carcinoma—**LMNOP** = **L**ymphatic (spread is) **M**edullary **N**eoplasm **o**r **P**apillary
Multicentric	Papillary and medullary carcinoma
Unifocal	**F**ollicular carcinoma = **F**ocal
Hematogenous spread	Follicular carcinoma (medullary anaplastic carcinomas also commonly spread via bloodstream)
Distant metastases to lung and bone	Papillary and follicular carcinoma
What are the three types of thyroid carcinoma arising from follicular cells?	Papillary, follicular (also Hürthle cell tumor, a subtype of follicular carcinoma), anaplastic
C cells (1 type)?	Medullary
What protein is measured to monitor patients who underwent thyroidectomy for thyroid cancer?	Thyroglobulin Note: If extremely elevated prior to surgery this suggests metastatic thyroid cancer, otherwise not a reliable test to determine benign vs malignant lesions.
What is the only reliable tumor marker for thyroid carcinoma?	Calcitonin, for medullary carcinoma. Serum thyroglobulin may be elevated in benign causes and is not always elevated in malignant causes.

079_BOOKZ

What is the recommended treatment for medullary thyroid cancer (MTC)?	Total thyroidectomy due to the aggressiveness and multicentricity of MTC
A patient is found to have MTC on FNA. What are two associated conditions that must be evaluated before surgery?	Pheochromocytoma and hyperparathyroidism
What lab tests are used to evaluate fort hese conditions?	24-hour urinary levels of VMA, metanephrine, catecholamine for pheochromocytoma Serum calcium for hyperparathyroidism
What genetic test should be performed on all patients with MTC?	RET oncogene mutations. MEN syndromes are inherited in autosomal dominant pattern. If children acquire mutation, it is recommended they too undergo total thyroidectomy.
Why must a pheochromocytoma be excluded before total thyroidectomy of an MTC?	To avoid a hypertensive crisis. Always treat the pheochromocytoma first.
What is the most sensitive tumor marker to evaluate for recurrent/persistent MTC?	Calcitonin
What is the best tumor marker for predicting prognosis?	Carcinoembryonic antigen (CEA)
A 30-year-old female presents for evaluation of a firm, slowly enlarging, nontender mass that moves with swallowing. Palpation of the lateral neck reveals a solitary, firm mass. FNA reveals thyroid carcinoma. What is the likely tumor type?	Papillary carcinoma. Remember papillary carcinoma tends to spread via lymphatics. Lateral neck mass likely cervical lymph node metastasis, so called "lateral aberrant thyroid." FNA may be performed on lymph node or thyroid mass.
If no other abnormal findings are discovered, what is the prognosis?	Excellent (>90% 10-year survival)
Does lymph node involvement worsen prognosis of papillary thyroid carcinoma?	No. ~50% present with positive lymph nodes and does *not* affect prognosis. Prognosis is more adversely affected by advanced age, poorly encapsulated, and extrathyroidal invasion.
A patient with papillary carcinoma undergoes total thyroidectomy. After surgery the thyroglobulin begins to increase. What is the likely explanation?	Recurrent or persistent disease

079_BOOKZ

What is/are the next step(s) in diagnosis and treatment?

RAIU, which allows detection and treatment of persistent or metastatic disease. Only helpful if patient underwent total thyroidectomy, as residual thyroid will preferably uptake RAI.

Note: Total thyroidectomy is advised for papillary carcinoma due to multicentricity (↓ recurrence) of the tumor as well as increasing the sensitivity of thyroglobulin and RAIU for detecting/treating the carcinoma.

A 30-year-old female presents for evaluation of a firm, nontender, fixed thyroid mass that moves during swallowing. FNA reveals a follicular type lesion. What is the next step in diagnosis and treatment?

Thyroid lobectomy. >80% will be benign. FNA cannot distinguish benign follicular adenomas from follicular carcinomas.

Intraop frozen section reveals capsular and vascular invasion. What is the next step in treatment?

Total thyroidectomy to treat follicular carcinoma, which also allows for RAIU detection/treatment of metastatic disease. Mean survival rate is 60% at 10 years, but depends on age, grade of tumor, and metastases.

A patient is evaluated for a rapidly enlarging neck mass, dysphagia, and cough. Biopsies reveal anaplastic carcinoma. What is the prognosis?

Poor, with 5-year-survival rate <10%. Most die within a few months of diagnosis.

What is the role of surgery for this cancer?

To protect the airway. Conservative resection is recommended to reduce postop morbidities. Prophylactic tracheostomy may be required. Chemoradiation has limited efficacy.

PARATHYROID

What is the origin of:

Superior parathyroid glands?

Fourth pharyngeal pouch, also the C cells of the thyroid

Inferior parathyroid glands?

Third pharyngeal pouch, also the thymus

079_BOOKZ

Where are the most common abnormal parathyroid locations for:	
Superior parathyroid glands?	Intrathyroidal or posterior mediastinum
Inferior parathyroid glands?	Superior mediastinum (often associated with thymus gland) Note: Inferior parathyroid glands more often associated with ectopic locations that range from the base of the skull to the thymus gland.
What is the location of recurrent laryngeal nerve to the:	
Superior parathyroid gland?	Ventral
Inferior thyroid gland?	Dorsal
What is the main blood supply of the parathyroid glands?	Inferior thyroid artery. The parathyroids are drained by the ipsilateral superior, middle, and inferior veins.
What are the two most common cells in the parathyroid glands?	1. Chief cells—secrete PTH 2. Oxyphil cells—unknown function
What is the function of PTH?	• ↑ Serum Ca • ↓ Serum phosphate
What are the mechanisms by which PTH ↑ serum Ca and ↓ serum phosphate in:	
Bone?	(+) Osteoclasts = ↑ Ca and phosphate
Kidney?	• ↑ Ca reabsorption distal collecting tubule • ↓ phosphate reabsorption proximal collection tubule • (+) 1α—hydroxylase
Gut?	↑ Ca reabsorption • 25-hydroxy vitamin D produced by liver ➔ 1,25-dihydroxy vitamin D produced by kidney ➔ ↑ Ca reabsorption in duodenum (passively in jejunum)

What are the two most common causes of hypercalcemia?

1. Primary hyperparathyroidism
2. Malignancy (lytic lesions or ectopic PTH production)

Note: Immunoassays are able to distinguish PTH from the parathyroid vs tumor. Alkaline phosphatase may be elevated in both conditions.

What are other causes of hypercalcemia?

Remember the mnemonic for hypercalcemia:

CHIMPANZEES

Calcium supplementation

Hyperparathyroidism

Iatrogenic (thiazides)/**I**mmobility

Milk alkali syndrome/**M**yeloma

Paget's disease

Addison's disease/**A**cromegaly

Neoplasm

Zollinger-Ellison syndrome/MEN

Excess vitamin A

Excess vitamin D

Sarcoidosis/granulomatous disease

What are the three most common causes of primary hyperparathyroidism?

1. Solitary adenoma ~80%
2. Hyperplasia ~15%
3. Parathyroid carcinoma ~2%

Intraoperatively a patient is found to have two grossly enlarged parathyroid glands. What is the likely cause for this?

With two or more abnormal glands it is assumed to be due to hyperplasia (as opposed to multiple adenomas) until proven otherwise. Hyperplasia may be asymmetrical.

How is this diagnosed?

Biopsy of other glands and all will show hypercellularity

How is this treated?

Two methods:

- Removal of three complete glands and one partial gland
- Removal of all four glands with autotransplantation

Determine whether the following refer to primary, secondary, or tertiary hyperparathyroidism:

↓Ca, ↑↑PTH

Secondary hyperparathyroidism

079_BOOKZ

↑Ca, ↑↑↑PTH	Primary hyperparathyroidism (also with pseudohyperparathyroidism and ectopic PTH production)
↑Ca, ↑PTH, and calcinosis	Tertiary hyperparathyroidism
Four gland hyperplasia	Primary (hyperplasia), secondary, and tertiary hyperparathyroidism
Often found in patients with chronic renal disease	Secondary hyperparathyroidism

Note: Ca refers to ionized calcium.

What are the surgical indications for parathyroidectomy?

1. All symptomatic patients
2. Asymptomatic patients with:
   - Ca >11 mg/dL
   - <50 years of age
   - Osteopenia (<2 standard deviations from age, race, and gender)
   - Calciuria (>400 mg/d)
   - ↓ Cr clearance

What are the common symptoms of hypercalcemia?

Kidney stones, painful bones, abdominal groans, psychic moans, fatigue overtones

1. Kidney:
   - Nephrolithiasis or nephrocalcinosis (calcium phosphate or oxalate stones)—never both
2. Bones:
   - Osteopenia/osteoporosis
   - Osteitis fibrosa cystica/brown tumors
3. Abdominal:
   - PUD (PTH ↑ gastrin secretion)
   - Cholelithiasis (calcium bilirubinate stones)
   - Pancreatitis
4. Neuropsychiatric:
   - Basically any symptom: depression, fatigue, anxiety, psychosis, obtundation, coma
5. Musculoskeletal:
   - Muscle aches, arthralgias, proximal weakness (likely due to neuropathy), pseudogout (calcium pyrophosphate crystals)

Note: Also ↑ risk of HTN and CHF.

What is osteitis fibrosa cystica?	Extensive bone resorption with marrow fibrosis and cysts. Part of a continuum of bony changes associated with hyperparathyroidism: Demineralization ➔ osteitis fibrosa (↑ osteoclast activity leads to bone resorption and peritrabecular fibrosis) ➔ osteitis fibrosa cystica
What is a brown tumor (also known as osteoclastoma)?	Seen in osteitis fibrosa cystica represents localized replacement of bone with vascularized fibrous tissue which may undergo necrosis and cyst formation (high hemosiderin content produces brown color)
Surgery improves all symptoms of hyperparathyroidism except which one?	Anxiety
What does a neck mass palpated in a patient with hyperparathyroidism likely suggest?	Thyroid pathology—physical exam usually not helpful for evaluating parathyroid pathologies
What is the embryologic origin of the adrenal cortex?	Mesoderm
Adrenal medulla?	Ectoderm (neural crest)
What are the three layers of the adrenal cortex, and which hormone(s) does each produce?	1. Zona glomerulosa: mineralcorticoid (aldosterone) 2. Zona fasciculata: glucocorticoids (cortisone and hydrocortisone) 3. Zona reticularis: estrogen, androgen, progesterone (precursor to estrogen/androgen)
What hormone(s) is/are produced by the adrenal medulla?	Catecholamines (epinephrine and norepinephrine)
What are four major stimulators of aldosterone release?	1. Hyponatremia 2. Sympathetic stimulation 3. ↓ Renal blood flow 4. Hyperkalemia
Describe the pathway of stimulation.	Juxtaglomerular cells release renin ➔ angiotensin I release ➔ pulmonary ACE ➔ angiotensin II ➔ aldosterone release
Where is the most common location for ectopic adrenocortical tissue?	Arises from mesoderm near the gonads; therefore, most common location is the testes, ovaries, and spermatic cord.

079_BOOKZ

What is the organ of Zuckerkandl?

During development neural crest cells migrate to para-aortic, paravertebral, and developing adrenal cortex. These ectopic locations usually regress. The largest region of ectopic medullary tissue is at the aortic bifurcation, near the inferior mesenteric artery, and is referred to as the organ of Zuckerkandl.

What is its significance?

Most common location for ectopic pheochromocytomas—may account for up to 10% of cases.

Where does the venous blood from the left adrenal gland drain?

Left renal vein

Right adrenal gland?

Inferior vena cava

Note: Arterial blood arises from the phrenic artery, aorta, and renal artery.

A 35-year-old female presents with refractory moderate-severe hypertension, hypokalemia, and metabolic alkalosis. What is the likely diagnosis?

Conn's syndrome (primary hyperaldosteronism)

What is the most common cause?

Solitary adenoma ~70% (idiopathic bilateral hypertrophy ~30%).

How is the diagnosis confirmed?

Diagnosis requires imaging with CT unless patient is pregnant or cannot tolerate IV contrast. Plasma aldosterone:renin >25:1 suggests diagnosis.

A patient is noted to have bilateral enlargement of adrenal glands on CT scan. What is the next step in diagnosis?

Scintigraphy (NP-59, a cholesterol derivative). An adenoma will appear as a "unilateral hot nodule" with contralateral suppression, or less commonly, selective catheterization of adrenal vein to measures aldosterone : cortisol ratio.

How is this treated?

If unilateral, then adrenalectomy (correct potassium and hypertension first), if bilateral, then medical management with potassium sparing diuretic (spironolactone)

How can one distinguish between primary and secondary hyperaldosteronism?

Measure plasma renin. Low plasma renin suggests primary hyperaldosteronism.

What are common causes of secondary hyperaldosteronism?	Conditions that cause ↓ CO or intravascular volume—CHF, cirrhosis, nephrotic syndrome
What is the most common cause of:	
Nonfunctioning adrenocortical adenoma seen on CT?	Benign adenoma
Functional adrenocortical adenoma seen on CT?	Primary hyperaldosteronism (80%), Cushing's syndrome (10%)
What physical finding is seen in primary but not secondary adrenocortical insufficiency?	Hyperpigmentation (though not a universal sign) due to corticotropin and melanocyte-stimulating hormone being produced by the same progenitor hormone
What segment(s) of the adrenal gland are destroyed in Addison's disease?	The entire adrenal cortex, which produces mineralocorticoids and glucocorticoids. Symptoms arise when >90% of both cortices are destroyed.
A patient with Addison's disease is recovering from surgery when you are called by the nurse stating the patient has a temperature of 103°F with confusion, nausea, vomiting, and orthostatic hypotension. What is the likely diagnosis?	Acute adrenal crisis (though sepsis should also be in the differential)
How is this treated?	Administration of hydrocortisone
How could this have been prevented?	By increasing the steroid dose before times of stress
What are the causes of Addison's disease?	There are many causes—use "vitamin E" mnemonic for developing differentials. **V** vascular: hemorrhage, embolus (heparin-induced thrombocytopenia [HIT]) **I**nfectious: human immunodeficiency virus (HIV), tuberculosis (TB), histoplasmosis, fungal, pseudomonas, meningococcus, or any infection that causes stress response **T**rauma: abdominal/surgical, or stress response **A**utoimmune: associated with other autoimmune disorders: sarcoid, Graves', DM I, pernicious anemia, etc **M**etabolic: amyloidosis, hemochromatosis

Idiopathic/**i**atrogenic: surgery, abdominal radiation, medications (failure to adjust for drugs that ↑ P450 metabolism), **long term use of corticosteroids** (most common)

Neoplastic: lymphomas, metastatic disease

Endocrine: removal of functional adrenal adenoma (causes transient adrenal insufficiency from chronic inhibition)

A 35-year-old female presents with fatigue, weight gain, with increased "fullness" in the face and back, hypertension, easy bruising, menstrual irregularities, acne, polyuria, and polydipsia. Physical exam reveals striae on the abdomen and thighs that are bright red. What is the likely diagnosis?

Cushing's syndrome—Whenever symptoms span multiple systems, think of endocrine causes first, especially thyroid. Also common are metabolic or infectious causes.

What is the most common cause?

Exogenous glucocorticoids

What is the most common endogenous cause?

Cushing's disease ~70%

What is Cushing's disease?

Cushing's syndrome due to adrenocorticotropic hormone (ACTH) producing adenoma of the pituitary gland associated with headaches and visual changes

A former smoker presents with easy bruising, ↓ libido, and emotional liability. What two lab tests are commonly done to diagnose Cushing's syndrome?

1. 24-hour urine cortisol level as a screening test (3–4× higher in pseudo-Cushing's syndrome). >4× normal is highly suggestive of Cushing's syndrome
2. Dexamethasone suppression (cortisol) test

The patient is found to have elevated urinary cortisol levels. A dexamethasone suppression test shows:

No suppression at low doses

No suppression at high doses

What is the likely cause of Cushing's syndrome in this patient?

A normal individual will have suppression of cortisol secretion at low doses. Suppression at low doses rules out normal individuals with high cortisol. In Cushing's syndrome, cortisol secretion will be reduced by >50% with **high dose** dexamethasone. Patients whose cortisol cannot be suppressed is suggestive of ectopic production of ACTH (usually very high concentrations and associated with hyperpigmentation) or adrenal adenoma.

079_BOOKZ

Where is the most common location of ectopic ACTH production?	Small cell lung cancer (~50%, also by pancreatic, thymoma, or carcinoid tumors). Most of these patients do not appear as cushingoid, but appear as cachectic.
What is the treatment of choice for Cushing's disease?	Transsphenoidal microadenomectomy, which is successful in 80%
A patient has recurrence after initial treatment, what is the next step in treatment?	Repeat excision has ~50% cure rate, therefore pituitary irradiation is recommended. Usually with stereotactic radiosurgery/gamma knife to reduce panhypopituitarism or visual defects.
The patient again fails treatment, what is the next step in managing this patient?	Medical therapy (ie, ketoconazole) or bilateral adrenalectomy. ~90% have uni-/bilateral pathologic changes in adrenal glands (adenomas, hyperplasia).
A patient is found to have a unilateral adrenal adenoma causing Cushing's syndrome. What is the treatment of choice?	Unilateral adrenalectomy (bilateral adrenalectomy if bilateral cortical hyperplasia is present)
What needs to be given perioperatively and postoperatively?	Cortisone, due to suppression of the contralateral adrenal gland from the hyperfunctioning adenoma to prevent an addisonian crisis. Steroids are needed for life in bilateral adrenalectomy.
What is the most common hormone produced by an adrenal cortical carcinoma (ACC)?	Cortisol (30%). ~50% are functional and more common among women. Others secrete androgens, estrogens, aldosterone, or a mix of hormones.
What are the most common signs/symptoms of:	
Functional ACC?	Rapidly progressive Cushing's syndrome or virilizing features
Nonfunctional ACC?	Abdominal mass and pain

079_BOOKZ

A man presents with Cushing's syndrome. CT of the abdomen reveals a 4-cm mass on the adrenal gland. What is the likely diagnosis?

Though ACC tumors are extremely rare, a male with Cushing's syndrome and an adrenal mass is suspected of ACC until proven otherwise.

What is the best way to distinguish benign vs malignant ACC?

With radiographic studies. Most important factor is size: 6 cm has >90% chance of malignancy. It is difficult to distinguish adenomas from carcinomas with histologic examination.

What is the treatment for ACC?

Surgical excision or debulking and chemotherapy, as they are relatively resistant to radiation. This is reserved for unresectable recurrences or bony metastases, which have a poor prognosis with 25% 5-year survival, 40% if localized disease.

A patient presents complaining of paroxysmal headaches associated with palpitations, flushing, shortness of breath, and diaphoresis. On physical exam the patient is noted to be hypertensive. What is the suspected diagnosis?

Pheochromocytoma, with the classic triad: headache, palpitations, diaphoresis. Hypertension may be sustained or paroxysmal.

What lab test(s) are used to establish the diagnosis?

Urinary catecholamines and the metabolites (metanephrine, normetanephrine, and vanillylmandelic acid)—Assure patient is not taking medicines that ↑/↓ catecholamines (tricyclic antidepressants [TCA], benzodiazepines, alcohol, labetalol, clonidine, iodinated contrast, etc).

A patient suspected of having a pheochromocytoma is found to have elevated levels of norepinephrine. What is the significance of this finding?

Elevated norepinephrine suggests extra-adrenal site of tumor, most likely via the organ of Zuckerkandl. These sites lack phenylethanolamine-*N*-methyltransferase and cannot convert norepinephrine to epinephrine, which is predominately secreted by adrenal pheochromocytomas.

What is the preferred screening imaging modality for evaluating pheochromocytomas?

Noncontrast CT. Iodinated contrast can precipitate a hypertensive crisis. T2 magnetic resonance imaging (MRI) with or without gadolinium is most specific/sensitive.

What is an MIBG scan?

Radioactive iodine labeled metaiodobenzylguanidine (MIBG) nuclear scan that is taken up by chromaffin tissue directly in proportion to catecholamine synthesis/secretion. Normal adrenal medullary tissue does not take up MIBG, this is helpful in locating extra-adrenal sites.

079_BOOKZ

CHAPTER 12

Trauma

What is an "AMPLE" history?

Allergies

Medications

Previous illnesses

Last meal

Events surrounding injury (mechanism of injury)

What is the three-step approach to a trauma patient?

Approach first addresses the question "what is most likely to kill the patient fastest?" This is done by using the ABCDEF mnemonic.

1. **Primary Survey**

   Airway

   Breathing

   Circulation

   Disability (neurologic)

   Exposure (remove clothing)

   Finger, **f**oley, or tube (NG) in every orifice
2. **Secondary survey** (detailed head to toe H+P)
3. **Definitive care**

In a multisystem injury patient, which problem is to be addressed first?

Airway. **ABC** (**a**irway, **b**reathing, **c**irculation) will always be the order of importance *regardless of mechanism of injury.*

How is the level of consciousness quickly established in the primary survey?

Determination of Glasgow Coma Scale (GCS). See Table 12-1.

- Verbal response to stimuli
- Motor response to stimuli
- Eye opening

Copyright © 2008 by The McGraw-Hill Companies, Inc. Click here for terms of use.

079_BOOKZ

What is a normal score?	15 (maximum score)
Score in a comatose patient?	8 or less
Score in a deceased patient?	3 (minimum score)

Table 12-1 The Glasgow Coma Scale (GCS) Score[a]

Motor Response (M)		Verbal Response (V)		Eye-Opening Response (E)	
Obeys commands	6	Oriented	5	Opens spontaneously	4
Localizes to pain	5	Confused	4	Opens to speech	3
Withdraws from pain	4	Inappropriate words	3	Opens to pain	2
Flexor posturing	3	Unintelligible sounds	2	No eye opening	1
Extensor posturing	2	No sounds	1		
No movement	1				

[a]Add the three scores to obtain the Glasgow Coma Scale score, which can range from 3 to 15. Add "T" after the GCS if intubated and no verbal score is possible. For these patients, the GCS can range from 2T to 10T.

What is the revised trauma score (RTS)?	A physiologic scoring system derived from the GCS, blood pressure, and respiratory rate. Scores range from 0–4 with a total maximum value of 12. This is used to help triage patients.
What are common causes of altered level of consciousness?	Remember the mnemonic: "**TIPPS** on the vowels (**AEIOU**)" **T**rauma, toxin, temperature **I**nfection **P**sychogenic, pulmonary embolus **S**hock, seizure, space occupying lesions, stroke **A**lcohol, abdominal aortic aneurysm **E**lectrolytes, encephalopathies, endocrine problems (thyroid, adrenal) **I**nsulin (hypoglycemia) **O**piates, overdose **U**remia

079_BOOKZ

What is a common cause of agitation in a patient involved in a traumatic accident?

Hypoxia. Consider even if patient is intoxicated.

What is a common cause of obtundation?

Hypercarbia

What must be done prior to securing the airway in a trauma patient?

Stabilize the cervical spine in any patient where the mechanism of injury is unknown.

What are three ways to definitively establish an airway?

1. Intubation (nasotracheal or orotracheal)
2. Cricothyroidotomy (surgical or needle)
3. Tracheostomy

Which of these three ways is not preformed in emergency situations?

Tracheostomy. Care must be taken not to injure the thyroid gland and its blood supply.

What are three indications for a definitive airway?

1. Need for mechanical ventilation (oxygenation or ventilation deficit)
2. GCS <8
3. Possible loss of airway (edema, burn, anaphylaxis, expanding mass or hematoma, head or neck injury, epiglottis, etc.)

What must be assessed immediately after attempting intubation?

Determination whether the esophagus or trachea was intubated.

What are two ways in which this is performed?

Bilateral breath sounds w/chest rise and measurement of end-tidal carbon dioxide

What are three causes of diminished or unilateral breath sounds?

1. Main stem bronchus intubation, most often on the right
2. Hemothorax
3. Pneumothorax

When is a surgical airway indicated?

- Inability to intubate (oropharyngeal hemorrhage, glottic edema)
- Contraindication to intubation (severe facial injury, larynx fracture)
- Inability to mask ventilate

Which method, needle or surgical cricothyroidotomy, is recommended for children <12 years old?

Needle cricothyroidotomy

Why is this recommended?

Incision through the cricothyroid membrane increases risk of children developing subglottic stenosis.

079_BOOKZ

What is the maximum length of time needle cricothyroidotomy will provide effective oxygenation?	Inadequate exhalation allows a maximum of 45 minutes of oxygenation, after which a tracheostomy should be performed. Surgical cricothyroidotomy may be used for 24 hours after which a tracheostomy should be performed.

CIRCULATION

Shock

What are the six shock states?	1. Hypovolemic (hemorrhagic) 2. Cardiogenic 3. Septic (vasodilatory) 4. Neurogenic 5. Obstructive 6. Traumatic
Determine the minimum systolic blood pressures from the following pulses:	
Radial	80 mm Hg
Femoral	70 mm Hg
Carotid	60 mm Hg
What percentage of body weight is derived from blood volume?	7%
In a 70-kg patient, how many milliliters of blood is this?	~5000 mL
Determine the % of blood loss for:	
Mild shock	<20% (1000 mL in 70-kg patient)
Moderate shock	20–40% (1000–2000 mL)
Severe shock	>40% (2000 mL)
What percentage of blood is taken during a blood donation?	~10% (500 mL)
At what percentage of blood loss do minimal physiologic changes appear (tachycardia, decreased capillary refill, ↓ urine output, ↑ RR)?	~20% (moderate shock)
At what percentage does blood pressure begin to decrease?	30%

Describe the heart rate, blood pressure, symptomatic changes in the four classes of hypovolemic shock.

See Table 12-2.

Table 12-2 The Four Classes of Hypovolemic Shock

	Class I	Class II	Class III	Class IV
% loss	10–15	20–30	30–40	>40
mL loss	500–750	750–1500	1500–2000	>2000
BP	—	—	↓	↓↓
HR	—	↑	↑↑	↑↑
sx	—	Anxiety < Cap refill Narrow pulse pressure	Confusion Oliguria Diaphoresis Pallor	Coma CV Instability Preterminal

SX = symptoms

When is OR trauma resuscitation indicated?

Hemodynamic instability. In the unstable trauma patient, the biggest decision a surgeon has to make is what body cavity to explore.

What is the first step in treating hemorrhage (assume airway/breathing secure)?

- Finger pressure to decrease the hemorrhage (digital control).
- Establish venous access with two large bore IV (min. 16 gauge). Avoid placement in injured extremities.

Why should vasoconstrictors be avoided in treating hemorrhagic shock?

- ↑ systemic vascular resistance (SVR)/afterload = ↑ cardiac oxygen consumption
- Worsens ischemia to kidneys

What is the preferred crystalloid in large volume resuscitation?

Lactated Ringer's (LR)

What is a possible complication of infusing large amounts of NS (saline)?

Hyperchloremic acidosis

What is meant by "fluid bolus"?

Patient is given 1–2 L of fluid and vital signs/urine output are recorded. If no response, a second bolus is repeated. Allows one to judge the degree of blood loss.

How much does a 1 L bolus increase intravascular volume?

~200 mL

In a bleeding patient, what is the ideal volume replacement solution?

Packed red blood cells and fresh frozen plasma 1:1. Massive transfusion protocol.

A patient in hemorrhagic shock is brought to the ED. Is transfusing O-negative blood safe?	Yes—though, matched blood is preferred.
Is transfusing O-positive blood safe?	Depends—typically safe for young males. Avoid in females or those who have received blood transfusions for possibility of Rh isoimmunization.
What are the four body cavities capable of holding >1 L of blood?	1. Abdomen 2. Retroperitoneum 3. Hemithorax 4. Femur

NON-HEMORRHAGIC SHOCK

Lesions in what part of the spinal cord lead to neurogenic shock?	High thoracic or cervical segments, not closed head injuries. May also be a result of regional anesthetic agent.
Why these segments?	Neurogenic shock is caused by injury to the descending sympathetic pathways.
Determine the signs of neurogenic shock to the following:	
Blood pressure	Hypotension, which is a result of losing sympathetic autonomic vascular control, leading to vasodilation and pooling of blood
Heart rate	Bradycardia
Skin	Warm, well-perfused
Urine output	Normal/low
Pulmonary capillary wedge pressure (PCWP)	Normal
Cardiac output	Normal
Systemic vascular resistance	Low
	• Hyp**o**tension and bradycardia = neur**o**genic shock • Hyp**er**tension and bradycardia = Cushing's triad
How is neurogenic shock treated?	IV fluids to restore intravascular volume. Vasoconstrictors and atropine may also be used to restore

	vascular tone and heart rate, respectively.
What is the risk of using vasoconstrictors?	Areas with intact autonomic regulation may constrict excessively causing ischemia to organs or extremities.
Determine the signs of septic shock to the following:	
Blood pressure	Hypotension
Heart rate	Tachycardia
Skin	Warm (initially)
Urine output	Normal (initially)
PCWP	Decreased
Cardiac output	Increased (initially)
Systemic vascular resistance	Decreased
	Note: In early septic shock (warm shock) the cardiac output is increased, however, continued vasodilation and damage to endothelium causes ↓ cardiac output, hypoperfusion, capillary leakage, and microthrombi causing end-organ ischemia
An immunosuppressed patient following trauma has persistent high fevers, rigors, and negative blood cultures. What is the likely cause of these symptoms?	Disseminated fungal infection. ~50% have negative blood cultures and many are on broad spectrum antibiotics, which is a risk factor, seen in burn, multitrauma, or immunosuppressed patients.
What is the most common organism?	*Candida* sp
What is an often missed sequela?	Retinal injury. Fungus lodges in microcirculation and may cause loss of vision, therefore should obtain ophthalmology consultation if suspected.
Patients taking corticosteroids are at risk for developing what type of shock following trauma?	Hypoadrenal shock. Steroid dosage usually increased prior to non-emergent surgery to compensate for the increased stresses.
What are the typical findings?	Hypotension not responsive to IV fluids or inotropic agents
How is this treated?	Stress doses of corticosteroids (100 mg q 6–8 hours)

What are the causes of cardiogenic shock?

- Arrhythmias/MI
- Valvular stenosis/insufficiency
- Increased PVR or SVR—pulmonary embolus or tension pneumothorax
- Cardiac contusion
- Papillary muscle or myocardial rupture
- Constrictive pericarditis
- Ventricular septal defect (VSD)
- Congestive heart failure (CHF)

Determine the signs of cardiogenic shock to the following:

Blood pressure	Decreased (systolic <90 mm Hg)
Heart rate	Increased (irregular if arrhythmia is present)
Skin	Cool
Urine output	Oliguria
PCWP	Increased
Cardiac output	Decreased
Systemic vascular resistance	Elevated

THORACIC TRAUMA

What are six immediately lethal thoracic injuries?

1. Airway obstruction
2. Cardiac tamponade
3. Hemothorax
4. Flail chest
5. Tension pneumothorax
6. Open pneumothorax

Explain how cardiac tamponade leads to decreased cardiac output.

Blood accumulates inside noncompliant pericardial sac, outside heart chambers. Low pressure right atrium is compressed and blood cannot return to the heart.

What is the most common cause of cardiac tamponade?

Penetrating injuries. Blunt trauma may also cause rupture of vessels or chambers, especially of the right atrial appendage, because it is the thinnest chamber.

079_BOOKZ

What is Beck's triad?

Physical signs of cardiac tamponade:

- Distended neck veins
- Hypotension
- Muffled heart sounds

What is pulsus paradoxus?

↓ >10 mm Hg of systolic blood pressure during inspiration

What is Kussmaul's sign?

↑ central venous pressure; jugular venous distention (JVD) during inspiration

Note: Both associated with cardiac tamponade.

What other signs indicate cardiac tamponade?

- Respiratory distress.
- Pressure equalization of all four heart chambers.
- Pulseless.
- Cardiac activity on EKG may show low-voltage with electrical alternans.

What is the first step in management of a patient with cardiac tamponade?

Fluids to raise CVP > intrapericardial pressures

What can provide immediate, temporary relief in patients with cardiac tamponade?

Pericardiocentesis, which should not be delayed due to onset of cardiogenic shock.

What provides definitive treatment?

Surgery to identify and correct source of bleeding

How is continued clinical tamponade despite attempted pericardiocentesis treated?

Emergency thoracotomy. Blood in pericardium is clotted and needs to be physically removed to release heart.

A collection of blood within the pleural cavity is referred to as what?

Hemothorax

What is the most common cause?

Trauma, though neoplasms, blood dyscrasias, infections may be the other causes

What are the common symptoms of a hemothorax?

- Hypoxia
- Decreased/absent breath sounds
- Dullness to percussion

Note: If stable, confirm with chest x-ray (CXR). If penetrating trauma or unstable with signs, do not wait for CXR.

How is a hemothorax initially treated?

Insertion of a chest tube (tube thoracostomy) (See Fig. 12-1)

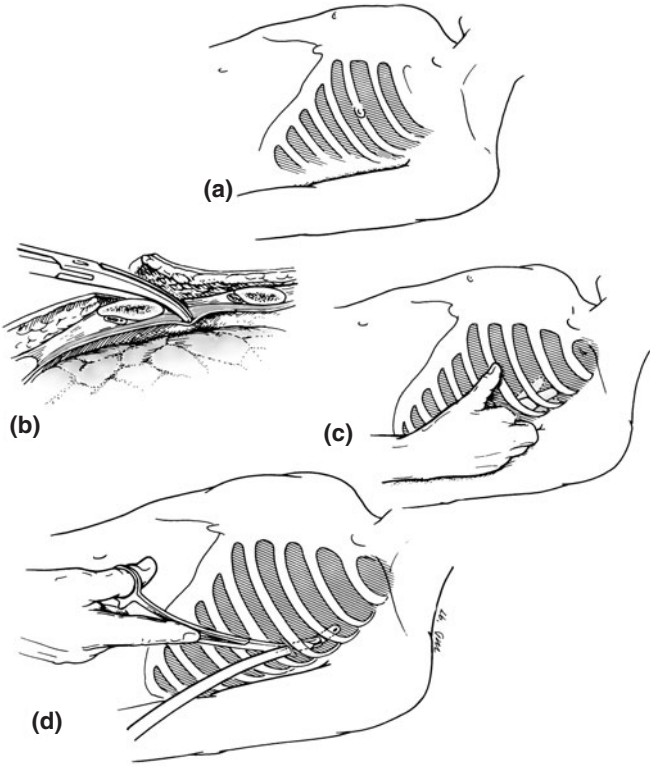

Figure 12-1 Chest tube insertion. (a) Incision is made over the fourth or fifth interspace at the anterior axillary line. (b) Kelly clamp is directed straight down on the rib and slid immediately over the rib. Must go directly over rib to miss the vessels which run underneath the rib. Will feel a "pop" as you violate the pleura. (c) Finger is inserted into pleural space to confirm pleural space and to feel for adhesions. Lung will feel spongy. (d) Tube is fed on a Kelly clamp. Direct anterior for pneumothorax, posterior for hemothorax. [*Reproduced, with permission, from Brunicardi CF et al (eds): Schwartz's Principles of Surgery, 8th ed. New York: McGraw-Hill, 2005:131.*]

What percentage of penetrating chest wounds can be treated solely with a chest tube?	75%
What are the surgical indications for a hemothorax?	Massive hemothorax = >1000 mL. Initially drained from chest tube. >150 mL/h drainage of blood from chest tube for 2 hours. Blood transfusions to maintain hemodynamic stability.

What is the likely diagnosis in a patient with distended neck veins, respiratory distress, absent unilateral breath sounds, hyperresonance to percussion, inflated hemithorax on expiration?	Tension pneumothorax. JVD may be absent if hypovolemic.
A pneumothorax in a ventilated patient is considered what?	Tension pneumothorax. Usually barotrauma from right mainstem bronchus intubation or too high PEEP.
How is a tension pneumothorax best diagnosed?	• Clinical exam. *Do not* wait for chest x-ray results. • Swish of air on needle thoracostomy.
What are the typical findings of tension pneumothorax on chest x-ray?	• Collapsed lung • Hyperexpanded lower diaphragm • Hyperlucent lung field • Tracheal deviation • Mediastinal shift
What is the initial treatment for suspected tension pneumothorax?	Immediate needle decompression
What is the next step in treatment?	Insertion of a chest tube
What is the mechanism by which a tension pneumothorax causes death?	Mediastinal shift causes compression of superior and inferior vena cavae, reducing venous return and cardiac output resulting in cardiogenic shock.
A pneumothorax in which the intrathoracic pressure equilibrates with the atmospheric pressure is referred to as what?	Open pneumothorax, or sucking chest wound
Why is this considered a life threatening injury?	Air passes preferentially through the wound instead of the trachea during ventilation, resulting in hypoventilation.
What size injury is needed to develop the fatal condition?	Wound >2/3 the diameter of the trachea, because air follows the path of least resistance
What is the initial treatment for an open pneumothorax?	Close the wound with sterile/occlusive dressing taped on three sides. Definitive treatment requires chest tube and surgical closure of wall defect.
What will develop if the dressing is taped on all four sides?	Tension pneumothorax

A patient with blunt trauma to the chest presents with hypoxia and paradoxical chest wall motion with ventilation. What is the likely diagnosis?	Flail chest
What is the cause of the paradoxical motion?	Multiple ribs which are broken in at least two places disrupt bony continuity of thoracic cage.
What are two causes of hypoxia in this condition?	1. Underlying lung contusion 2. Severe pain on respiration
How is this condition treated?	• Re-expansion of lung • Adequate ventilation, which may require intubation and ventilation • Adequate pain control • Maintain intravascular volume (measure with Swan-Ganz) and minimize use of fluids (risk pulmonary edema)
A patient with blunt trauma to the chest immediately presents to the emergency room (ER) with hypoxia and a normal chest x-ray. What is the likely cause of hypoxia?	Pulmonary contusion
Why is the chest x-ray normal?	Opacities on x-ray may take an hour or more to appear, making hypoxia a better indicator of contusion immediately following trauma.
What is the cause of hypoxia due to pulmonary contusion?	Ventilation-perfusion mismatch from: • Interstitial hemorrhage • Leakage of fluids (blood/plasma) into alveoli • Alveolar collapse
What other condition is similar to this?	Adult respiratory distress syndrome (ARDS), which is loss of integrity to alveolar-capillary barrier
How are patients with pulmonary contusion treated?	Analgesics, pulmonary toilet, and intensive care unit (ICU) monitoring for 24 hours. Intubation if respiratory distress.
Explain the significance of the following rib fractures:	
Ribs 1–3	Indicates severe trauma. Search for great vessel and visceral injuries. Often associated with subclavian artery/vein or brachial plexus injuries.

079_BOOKZ

Ribs 5–9	May produce flail chest, pneumothorax, or hemothorax.
Ribs 10–12	Injury to liver or spleen.
A patient presents following a motor vehicle accident (MVA) with chest pain. A chest x-ray reveals a widened mediastinum, fracture of first and second ribs, deviation of trachea, and depression of left mainstem bronchus, indistinct aortic knob. What is the likely diagnosis?	Aortic transection associated with deceleration injuries. 90% die at the scene.
Where is the most common location for such an injury?	Insertion of the ligamentum arteriosum, just beyond the left subclavian artery branch, which is an anatomic fixation point
What is the diagnostic test of choice?	Chest computed tomography (CT) with contrast
What layers of the vessel does this injury involve?	Intima and media. If the adventitia also tears then the patient will exsanguinate. Bleeding into the mediastinum is from bridging veins or lumbar arteries, not the aorta.
What does this form?	Pseudoaneurysm
How is an aortic transection treated?	• Immediate surgical repair with either grafting or resection. • If patient has other immediately life-threatening injury, intensive blood pressure control is required. • If aorta begins to bleed, patient will almost always die.
A patient involved in an MVA presents with a fractured sternum and abnormal electrocardiogram (ECG) tracing. What is the likely diagnosis?	Myocardial contusion, patient may not have any fractures of ribs or sternum.
What are the associated ECG changes?	Trauma can affect via: • Conduction abnormalities—ST elevation or depression • Irritability focus—PAC, PVC, atrial fibrillation (a.fib.), bundle branch block
Why is a myocardial contusion considered life-threatening?	High risk for arrhythmias
What other blood test will be elevated?	Creatine kinase MB ([CK-MB] >6% of total CK)

Which chamber is most commonly involved?	Right ventricle, which is closest to sternum and contusion may lead to right-heart failure.
How are these patients managed?	Hemodynamic monitoring (arterial line, Swan-Ganz) and ICU monitoring
What injury may cause a recurrent pneumothorax following chest tube placement?	Injury to major bronchus. This is an uncommon injury and when found is ~1 in from carina.
Why is this considered a potentially lethal injury?	Risk of airway obstruction
What are the common signs of injury to the bronchial tree?	• Hemoptysis • Subcutaneous emphysema • Tension pneumothorax • Pneumomediastinum
How are bronchial tree injuries diagnosed?	Bronchoscopy
What is the treatment?	Airway maintenance with ET tube or surgical repair if severe injury
A patient presents with hoarseness, subcutaneous emphysema, and palpable fracture crepitus along trachea. What is the likely diagnosis?	Fracture of larynx
How is this treated?	Surgical repair
Following blunt trauma to the lower chest a patient is found to have respiratory distress. On physical exam bowel sounds are noticed in the chest. What is the likely diagnosis?	Traumatic diaphragmatic rupture. Large tears often caused by blunt trauma.
Which side of the body is most often affected?	90% left hemidiaphragm. Liver prevents herniation of contents through right sided tears.
How can this be quickly diagnosed?	Placement of nasogastric (NG) tube. Herniation of the stomach will cause the tube to curl in the chest.
What is the surgical approach (thoracic or abdominal) in:	
Acute setting?	Abdominal approach. Exploratory laparotomy is necessary.
Delayed setting?	Thoracic approach, due to the formation of intrathoracic adhesions that require lysis.

079_BOOKZ

Following a penetrating chest injury a patient complains of severe epigastric pain, dysphagia, and hematemesis. A chest tube that had been inserted is noted to have drained food particles and continuously bubbles equally through respiration. What is the likely diagnosis?	Esophageal injury which presents similar to Boerhaave's syndrome
How is this diagnosed?	Esophagoscopy or esophagogram
How is this treated?	Surgical repair with wide drainage of pleural space and mediastinum. Esophageal diversion may be necessary.
A few days later, the patient develops pleuritic, retrosternal chest pain that radiates to the neck. On physical exam the patient has a fever, local cellulitis of the chest, and a Hamman sign (crunching sound over the precordium during systole). A chest x-ray demonstrates a pneumomediastinum and air-fluid levels within the mediastinum. What is the likely diagnosis?	Mediastinitis, which may also occur during post-op period from damage to the airway or esophagus from surgery or intubation. 50% mortality rate.
How is this treated?	• Often of polymicrobial origin, therefore broad spectrum antibiotics with anaerobic coverage (vancomycin and piperacillin-tazobactam) until culture results return. If post-op or sepsis, consider adding an aminoglycoside or quinolone for *Pseudomonas* coverage. • Surgical debridement may be necessary.
Which is more common in ingestions, alkaline or acid esophageal damage?	Alkaline; strong acid burns mouth leading to lesser amount ingested
What is the first priority after identifying the caustic agent during an ingestion?	Airway maintenance
How is severity of injury best estimated?	Endoscopy
What are the indications for emergent surgery in a caustic ingestion?	Esophageal perforation, otherwise observe
What is the common long-term complication in caustic ingestion?	Stricture formation

079_BOOKZ

ABDOMINAL TRAUMA

Determine whether the following are intraperitoneal or retroperitoneal.

Stomach	Intraperitoneal
Pancreas	Retroperitoneal
Urinary bladder	Retroperitoneal
Duodenum	Retroperitoneal (first part [5 cm] is intraperitoneal)
Gallbladder	Intraperitoneal
Transverse colon	Intraperitoneal
Aorta	Retroperitoneal
Inferior vena cava	Retroperitoneal
Appendix	Intraperitoneal
Ascending colon	Retroperitoneal
Descending colon	Retroperitoneal
Sigmoid colon	Intraperitoneal
Rectum	Retroperitoneal
Jejunum	Intraperitoneal
Liver	Intraperitoneal
Kidneys	Retroperitoneal
Spleen	Intraperitoneal
Ileum	Intraperitoneal
Cecum	Intraperitoneal
Pancreas	Retroperitoneal
Adrenal glands	Retroperitoneal

What are the four zones of the abdomen and what are the contents of each?

1. Intrathoracic/upper abdomen: liver, spleen, stomach, transverse colon, diaphragm
2. True/lower abdomen: small bowel, intraperitoneal colon, gravid uterus, distended bladder
3. Pelvic abdomen: bladder, urethra, small intestine, rectum, iliac vessels, uterus, ovaries, fallopian tubes

079_BOOKZ

4. Retroperitoneal abdomen: kidneys, ureters, duodenum, pancreas, aorta, vena cava, ascending/descending colon, iliac vessels

Why is physical exam unreliable in patients with retroperitoneal injuries?

Although patients may display pain on palpation, they may not display any peritoneal signs.

How are retroperitoneal injuries evaluated?

Best evaluated with imaging: CT, x-ray (oblique views), US (these imaging studies also used for intraperitoneal injuries)

Why is an NG tube needed prior to beginning bag-mask ventilation?

Prevents:
- Regurgitation and aspiration: May lead to chemical and bacterial pneumonitis. Lower the pH of aspirate = greater the risk of chemical pneumonitis, hence the reason for a PPI prior to surgery
- Gastric dilation: may cause vasovagal reflux (bradycardia and hypotension) leading to cardiac arrest

How should an NG tube be inserted if a patient has significant facial trauma?

Orally to avoid penetrating the cribriform plate

Define:

Grey Turner sign

Ecchymosis involving the flanks

Cullen sign

Ecchymosis involving the umbilicus

What do these indicate?

Retroperitoneal hemorrhage (these signs are usually delayed hours to days)

What is a FAST scan?

Focused abdominal sonography for trauma

What is it used for?

- To identify the presence of fluid. Does not determine the source or type of fluid.
- Areas assessed:
  1. Morrison's pouch and R paracolic gutter (RUQ)
  2. Splenorenal area and L paracolic gutter (LUQ)
  3. Subxiphoid and substernal paracardial views
  4. Pouch of Douglas (suprapubic)

079_BOOKZ

What is a DPL?	Diagnostic peritoneal lavage
What is it used for?	Intraperitoneal bleeding (most sensitive test) often used in hemodynamically unstable patients whose FAST scan was negative.
What must be performed before a DPL?	• Stomach decompression via NG tube, which also reduces risk of aspiration and vasovagal reflex from gastric distension during ventilation and allows for gastric lavage. • Bladder decompression via Foley catheter, that also allows for evaluation of adequate volume resuscitation.
What defines a positive DPL?	• 10+ mL free blood aspirated. • If <10 mL, then 1 L NS instilled and aspirated; an RBC count > 100,000/μL is positive. Note: May also detect alkaline phosphatase or amylase levels for bowel injuries. Presence of food, fecal, or bile also defines a positive result. A negative result does not rule out an abdominal bleed (false negative ~15%).
Under what circumstances will a DPL be falsely negative?	Retroperitoneal injuries
How should a patient be treated if:	
FAST scan or DPL is positive in hemodynamically stable patients?	Penetrating injury = laparotomy. Blunt injury = CT or laparotomy if fluid cannot be explained (See Fig. 12-2.)
FAST scan or DPL is positive in hemodynamically unstable patients?	Laparotomy
A patient is brought to the ER hypotensive with normal breath sounds and no external bleeding or extremity fracture following an MVA. What is the likely source of hemorrhage?	Abdomen. Due to altered LOC and other injuries, especially neurological, the patient may not display any symptoms. Note: Other sources of blood loss include: blood loss at the scene, hemothorax, hemoperitoneum, retroperitoneal hematoma, or bleeding into the thighs from a femoral fracture.

079_BOOKZ

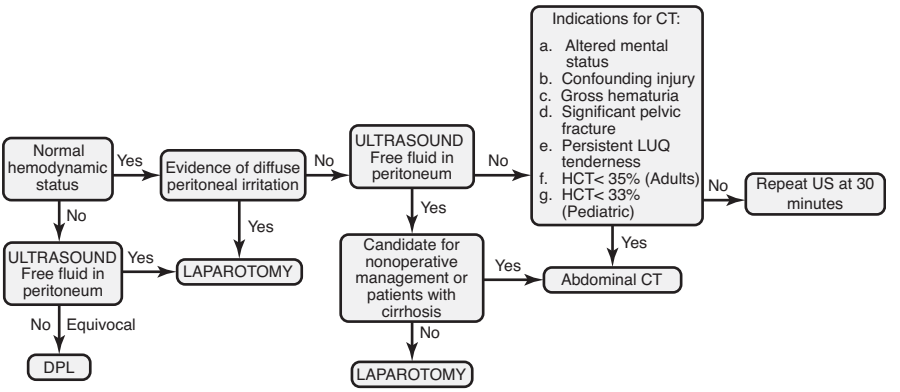

Figure 12-2 Algorithm for management of blunt abdominal trauma for adults and pediatric patients (>12 years).

What percentage of patients with abdominal injuries will have a normal exam?

20%. Therefore determine if significant abdominal injury is present, no need to determine organ specific injuries.

What are two signs that indicate a surgical exploration?

1. Tense abdominal distension, which indicates severe bleeding.
2. Involuntary muscle guarding, which indicates muscle spasm from bleeding or inflammation/peritonitis.

What is the main goal when performing a laparotomy?

Hemostasis. This is considered "Damage control surgery" and is done to establish hemostasis. Surgeries are often incomplete and definitive repairs are scheduled once patients regain normothermia, coagulopathies are treated and acidosis is corrected.

A multiple trauma patient is likely to die from what three factors intraoperatively?

1. Coagulopathy (correct with blood and clotting factors—crystalloids may worsen coagulopathy)
2. Hypothermia
3. Metabolic acidosis

Note: Hence the need for "damage control surgery"—stop bleeding and let the body correct the metabolic factors.

A trauma patient who was hemodynamically unstable on admission underwent laparotomy (with primary fascial closure) and now presents with decreased urine output, hypoxia requiring increasing positive end-expiratory pressure (PEEP), and worsening abdominal distension. What is the likely diagnosis?	Intra-abdominal hypertension/ abdominal compartment syndrome
What is the underlying pathophysiology?	Blood, bowel edema and distension causing compression of IVC and elevation of diaphragm
What are the causes of this condition?	Causes: • Blood: coagulopathy, missed vascular injury • Bowel edema: ischemia (causes capillary leakage, ↓ oncotic pressure, and impaired drainage of vessels and lymphatics), reperfusion injury • Space occupying lesions contribute (hematomas, packing)
How would this condition be diagnosed?	Measurement of intra-abdominal pressures with foley catheter
What is the normal intra-abdominal pressure?	Subatmospheric—0 mm Hg (<15 cm H_2O)
How is this treated?	Decompressive laparotomy
At what pressures do patients undergo surgical intervention?	20–25 mm Hg (patients may begin to show symptoms with pressures of 10–15 mm Hg)
How is this prevented?	Temporary closure (leave fascia and skin open with Silastic bag sewn to fascia)
Explain the pathophysiology of retinal hemorrhages and intracranial pressure ↑ (ICP) encountered with abdominal compartment syndrome.	Expanding abdominal contents ➔↑ intrathoracic pressure via elevated diaphragm causing ↑ pleural pressure ➔ ↑ CVP via ↓ venous compliance) ➔ ↓ CO and ↑ ICP ➔ bowel ischemia, oliguria, cerebral edema, retinal hemorrhage
What is a scaphoid/navicular abdomen?	Sunken anterior abdominal wall
What does it indicate?	Traumatic diaphragmatic hernia allows passage of abdominal contents; may display respiratory symptoms.

079_BOOKZ

Determine the likely injury of the following signs.	
Tympany over right upper quadrant	Pneumoperitoneum
Abnormal sphincter tone	Neurologic injury
Blood found during digital rectal exam (DRE)	Rectal injury
Boggy, soft prostate	Periurethral bleeding
Superiorly displaced prostate	Urethral transaction
Blood at urethral meatus	Urethral injury
Hematuria (gross or microscopic)	Multiple sites: kidney, ureter, bladder
What are the causes of pneumoperitoneum?	• **Perforated bowel/viscus** (except appendix): from ulcer, tumor, trauma, ischemia, infection (NEC, toxic megacolon) • Iatrogenic: recent surgery (resolves 4–7 days), peritoneal dialysis, paracentesis • Infection with gas forming bacteria • Penetrating trauma • Ruptured urinary bladder
Best x-ray to show pneumoperitoneum?	**Upright** chest x-ray
How should a gun shot wound (GSW) to the anterior abdomen (between fourth intercostal space and pubic symphysis) be treated?	Laparotomy. >90% associated with intraperitoneal injury. GSW to the posterior abdomen or flank or stab wound anywhere in the abdomen requires wound exploration. If peritoneum was penetrated then laparotomy, otherwise wound care. However, laparotomy is indicated if in doubt of peritoneal penetration.
How should hemodynamically stable patients with blunt injuries be evaluated?	If peritoneal signs on exam, then laparotomy. Otherwise evaluate with ultrasound. If free fluid in peritoneum without a known cause (eg, cirrhosis), then laparotomy. If patient is expected to have free fluid or has altered mental status, HCT <35, gross hematuria, confounding injuries, or persistent abdominal tenderness then CT is indicated.
How should hemodynamically unstable patients with blunt injuries be evaluated?	Ultrasound to evaluate free fluid. If negative, DPL is performed. If either is positive, then laparotomy.

079_BOOKZ

What two imaging studies are used to evaluate kidney or ureter injuries?	1. Intravenous pyelogram (IVP) 2. CT
What are two findings that indicate a positive intravenous pyelogram?	1. Delay of contrast excretion 2. Absence of contrast excretion
Microscopic hematuria is noted following blunt injury to the abdomen. What is the likely cause for this finding?	Renal contusion
What type of fracture is associated with urethral injury?	Pelvic fracture
What is the best way to assess adequate perfusion in a traumatic patient?	Urine output with Foley catheter
What is considered adequate urine output?	50 mL/h (adults)/1 mL/kg/h (children) Note: Maintain urine output to avoid acute tubular necrosis (ATN).
Following an abdominal trauma a patient is noted to have a perineal hematoma. What must be assured before a Foley catheter is inserted?	Retrograde urethrogram (RUG) or voiding cystourethrogram (VCUG) to assure no injury to the urethra. This is used when there is a pelvic fracture, perineal hematoma, blood at the urethral meatus, or high riding prostate. Urethral injuries are more common among men due to a longer urethra.
Injury to the urethra is noted. What should be used to monitor urine output?	Suprapubic bladder catheter
Following an MVA, a patient is suspected of having a pelvic fracture. What imaging test would confirm the diagnosis?	X-rays are used for screening. However CT is superior to evaluate for retro/intra-peritoneal bleeding, dislocation, and acetabular fractures.
The patient is found to have an associated retroperitoneal bleed. How is this treated?	Stabilization of pelvis with external fixation. Most pelvic bleeding is low pressure from fractures and will tamponade because pelvic fractures are found in severe trauma, look for organ injury. Diagnostic peritoneal lavage (DPL) should be performed through a supraumbilical incision to avoid entering the pelvic hematoma.
After treatment the hematoma continues to expand. What is the next step in treatment?	Arteriography and embolization

079_BOOKZ

What percentage of bleeds associated with pelvic fracture are venous?	>80%
How is venous bleeding controlled?	Immobilization—with sheet wrap then external fixation
What raises suspicion of arterial bleed?	Continued bleed after fixation

EXTREMITY TRAUMA

What are the "hard signs" of arterial injury?	• Pulseless limb • Pulsatile hemorrhage • Expanding hematoma • Thrill or bruit • Acute ischemic limb
What is the treatment of a patient with a "hard sign"?	Surgical exploration
What are the "soft signs" of arterial injury?	• Hypotension • Unequal pulses • Neurologic deficit • Proximity to major vascular structure • Small or stable hematoma
What is the first test performed when a "soft sign" is found?	ABI—ankle brachial index—blood pressure cuff measurement of brachial BP/ankle BP. Pulse should be measured with Doppler, not stethoscope.
What would be a concerning ABI?	<0.90
What would the next test be if the ABI was decreased?	Duplex ultrasound—then angiogram or operative repair
What fracture is associated with a 10% chance of limb-threatening injury?	Midshaft femur fracture
What dislocation is an indication for an angiogram?	Posterior knee dislocation

NECK TRAUMA

What patient population is suspected of having cervical spine injuries following blunt trauma?	All blunt trauma patients until proven otherwise
What are two methods used to rule out cervical spine injuries?	1. Clinical exam 2. Radiographically

079_BOOKZ

What are three imaging modalities used to rule out cervical spine injury?

1. X-ray
   - At least two views at 90° to each other
   - Lateral C-spine view first to avoid moving patient and if normal can proceed to AP and flexion/extension, but only if patient can initiate the movement without aid
2. Cervical CT
   - Very helpful if patient has point tenderness with a negative x-ray to rule out fracture, especially useful for suspected laryngeal fracture
3. MRI
   - Useful for evaluation of ligamentous injury. CT and MRI only employed if patient is stable.

What is the first step of evaluating penetrating neck trauma?

Evaluate airway. Intubate or surgical airway if expanding neck hematoma, tracheal deviation or obvious tracheal involvement. Fascial layers may limit exsanguinations.

What is the anatomic landmark that in zone II injuries separates deep from superficial neck wounds?

Platysma muscle. If platysma is violated, use selective penetrating neck trauma algorithm (see Fig. 12-3).

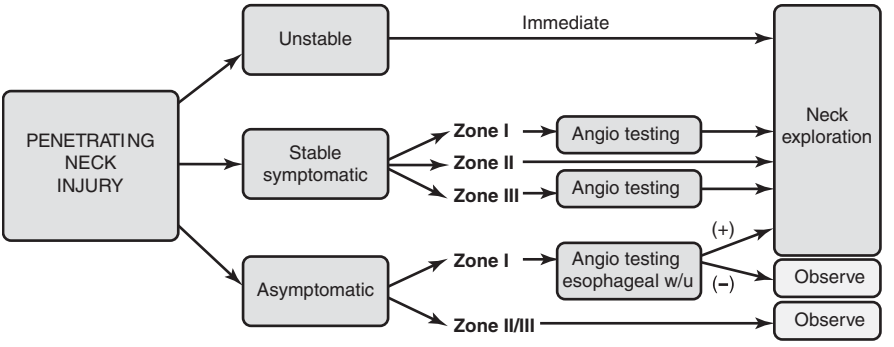

Figure 12-3 Algorithm for the selective management of penetrating neck injuries. w/u = work up

What are the anatomic boundaries (separating the three zones) of the neck used for selective management of penetrating neck trauma (see Fig. 12-4)?

- Zone I—between sternal notch/clavicles and cricoid cartilage
- Zone II—between cricoid cartilage and angle of mandible
- Zone III—between angle of mandible and base of skull

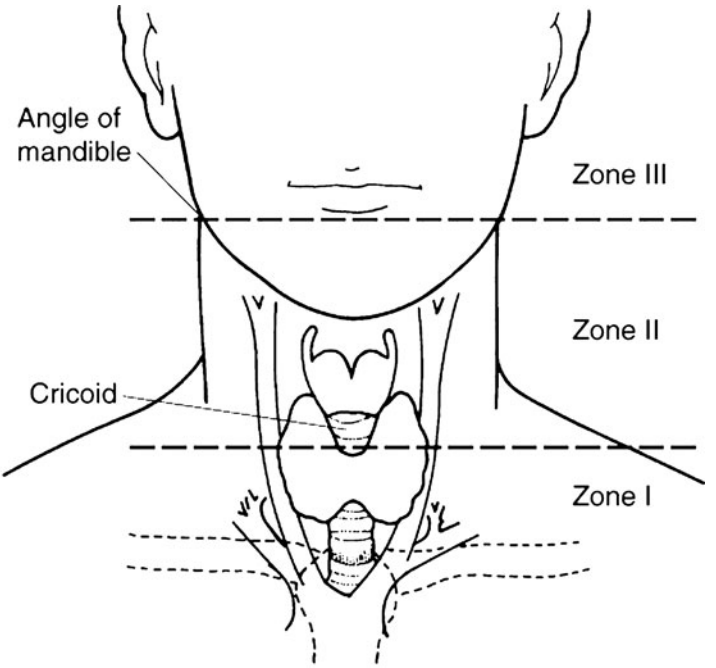

Figure 12-4 Zones of the neck for the purpose of evaluating penetrating injuries. [*Reproduced, with permission, from Brunicardi CF et al (eds): Schwartz's Principles of Surgery, 8th ed. New York: McGraw-Hill, 2005:140.*]

Injuries involving zone I must be evaluated for immediate life-threatening injuries to what two major structures within this zone?

1. Trachea
2. Vessels: proximal common carotid, vertebral, and subclavian arteries

Note: Other structures in zone I: thoracic duct, esophagus, thymus.

What structures lie within zone II?

- Internal/external carotid arteries
- Jugular veins
- Trachea
- Larynx
- Pharynx
- Esophagus
- Thyroid/parathyroids

What structures lie within zone III?

- Distal external carotid arteries
- Vertebral arteries
- Jugular veins

What are the four vessels that must be evaluated in penetrating neck trauma?

- Two carotids
- Two vertebrals

How are these vessels evaluated?

CTA or angiography. CTA is faster and safer but angiography has capability of treating vertebral injuries with embolization and carotid injuries with stenting.

What other vessels can be injured in zone I injuries?

Subclavian vessels

What are the three causes of subcutaneous emphysema in penetrating neck trauma?

1. Entrance through wound
2. Esophageal injury
3. Tracheal injury

How are suspected esophageal injuries evaluated?

Combination of esophagoscopy and soluble contrast swallow study followed by barium swallow can discover most esophageal injuries. Esophageal injuries need to be evaluated in zones I and II injuries.

What is the classic treatment of any zone II injury that penetrates platysma?

Operative exploration

What is the current approach?

Only unstable patients get immediate surgery. Stable patients get endoscopic, bronchoscopic, radiologic, and angiographic evaluation to identify injuries to determine the need for surgery.

What is the treatment for an unstable patient with penetrating neck trauma?

Operative exploration

079_BOOKZ

CHAPTER 13

Critical Care

Define shock.

Tissue hypoperfusion that is insufficient to maintain normal aerobic respiration.

What are the six shock states?

1. Hypovolemic (hemorrhagic)
2. Cardiogenic
3. Septic (vasodilatory)
4. Neurogenic
5. Obstructive
6. Traumatic

With regard to severity, how is shock classified?

1. Compensated : some objective findings of shock, such as acidosis, increased pulse, mildly decreased blood pressure.
2. Decompensated: overt shock necessitating intervention to preserve life.
3. Irreversible: final common pathway to death. Shock refractory to fluid and pressors. Invariably fatal.

What are the endpoints of resuscitation?

1. Normal lactic acid
2. Corrected base deficit
3. Normal mixed venous saturation

What is oxygen debt?

Oxygen debt occurs when there exists an excess of lactate. When oxygen delivery and perfusion are impaired, tissues switch to anaerobic metabolism, producing lactate. Oxygen debt is repaid when the body converts lactate back to pyruvate when oxygen is available to undergo aerobic cellular respiration.

Copyright © 2008 by The McGraw-Hill Companies, Inc. Click here for terms of use.

079_BOOKZ

Define in physiologic terms:

Cardiac output	Cardiac output (CO) = stroke volume × heart rate. Influenced by contractility, preload (volume status), and afterload (SVR). Usually expressed by cardiac index (CI = CO/ body surface area in m^2).
Central venous pressure	Predicts volume status by measuring pressure in superior vena cava.
Pulmonary capillary wedge pressure	Predicts volume status by reflecting end diastolic pressure in the left ventricle.
SVR	Systemic vascular resistance. Afterload seen by the left ventricle. Calculation of the pressure seen in the proximal aorta. SVR = (MAP – RAP)/CO. MAP is mean arterial pressure, RAP is mean right atrial pressure.
PVR	Pulmonary vascular resistance. Afterload seen by the right ventricle. PVR = (PAP – LAP)/ CO. PAP is mean pulmonary artery pressure; LAP is left atrial pressure.
EDVI	End diastolic volume index. Calculated value reflecting volume status.
SvO_2	Mixed venous oxygen saturation. Lower value indicates increased oxygen extraction, inadequate tissue oxygenation.
DO_2	Oxygen delivery. Most affected by hemoglobin (Hb), oxygen saturation, and cardiac output.
VO_2	Oxygen uptake.
O_2 ER	VO_2/DO_2. Oxygen extraction ratio. Elevated in shock times due to decreased oxygen delivery or increased uptake.

079_BOOKZ

What are the three modifiable elements that determine stroke volume?

1. Preload
2. Afterload
3. Contractility

What factors falsely elevate CVP?

High ventilatory pressures, expiratory airway obstruction, tension pneumo**thorax**, tamponade, heart failure

Which shock state is associated with an ↑ in pulmonary capillary wedge pressure (PCWP)?

Cardiogenic shock

How is this pressure measured?

With a Swan-Ganz (pulmonary artery) catheter, which can be used to differentiate cardiogenic and hypovolemic etiologies.

What does PCWP correspond with?

Left atrial pressure

What does this reflect?

Left ventricular end-diastolic pressure = preload (end diastolic volume depends on ventricular compliance)

What does preload reflect (two factors)?

- Venous capacitance (affected by vasoconstrictors and outside forces such as compression, as seen in abdominal compartment syndrome
- Volume status

What does afterload reflect?

Systemic vascular resistance (SVR) which is ↑ with vasoconstrictors

What is the normal PCWP?

6–12 mm Hg

What is a common complication encountered when inserting a Swan-Ganz catheter?

Arrhythmia, especially ventricular tachycardia as the catheter passes the atrioventricular (AV) node

What physical exam findings are useful in determining peripheral tissue perfusion?

- Pulse, capillary refill (normal = 2 seconds)
- Tissue temperature and color
- Level of consciousness/lethargy (↓ blood flow in periphery likely = ↓ cerebral flow)
- Urine output

What is adequate urine output per hour?

>30 mL/h

What are the homeostatic mechanisms to maintain perfusion and what neurohumoral chemicals are responsible for these effects?

Tachycardia	Dopamine, epinephrine, norepinephrine
Vasoconstriction	Norepinephrine, vasopressin, angiotensin
Oliguria	Vasopressin
Sodium retention	Adrenocorticotropic hormone (ACTH), aldosterone
Hyperglycemia	Epinephrine, glucagon, cortisol

Describe the heart rate, blood pressure, symptomatic changes in the four classes of hypovolemic shock. See Table 13-1.

Table 13-1 Four Classes of Hypovolemic Shock

	Class I	Class II	Class III	Class IV
% loss	10–15	20–30	30–40	>40
mL loss	500–750	750–1500	1500–2000	>2000
BP	—	—	↓	↓↓
HR	—	↑	↑↑	↑↑
sx	—	Anxiety < cap refill Narrow pulse pressure	Confusion Oliguria Diaphoresis Pallor	Coma CV Instability Preterminal

What is the first step in evaluating a patient with shock? Ensure control of airway and sufficient ventilation. Then address shock (**A**irway, **B**reathing, **C**irculation).

What is the definition of septic shock? Systemic inflammatory response to infection in conjugation with arterial hypotension despite adequate fluid resuscitation

What is the primary problem in septic shock? Low SVR

What are the two stages of septic shock?

1. Warm (hyperdynamic): early septic shock. Peripheral vasodilation (low SVR), warm flushed extremities, tachycardia to compensate (high CO).

079_BOOKZ

2. Cold (hypodynamic): late septic shock. Worsened peripheral perfusion due to decreased myocardial contractility, vasoconstriction, extremity mottling, oliguria, hypotension.

What are the causes for septic shock in the following?

Gram-positive bacteria

Exotoxin: *Staphylococcus, Streptococcus, Clostridium.*

Gram-negative bacteria

Endotoxin: lipopolysaccharide.

Which is associated more often with bacteremia?

- Gram-negative bacteria. If blood cultures are repeatedly negative in immunocompetent patient suspect gram-positive via exotoxin.

What are the other causes of vasodilatory shock?

- Prolonged and severe hypotension (all other forms of shock)
- Inadequate tissue oxygenation (lactic acidosis, carbon monoxide poisoning)

Vasodilatory shock is the final common pathway of other forms of shock.

What is the treatment of septic shock?

1. Treat shock symptomatically by optimizing oxygenation, ventilation, and perfusion.
2. Source control: antibiotics, drainage of fluid collections, debridement of nonviable tissue.

What is the primary hemodynamic problem in cardiogenic shock?

Low cardiac output. A problem with the pump, which can be muscle, valve, or conduction problems.

What is the most common cause of cardiogenic shock?

Mitral insufficiency (MI)

What are two variables that affect coronary blood flow?

1. Pressure gradient between LV and coronary artery
2. Duration of diastole

What is the treatment of cardiogenic shock?

1. Treat shock with inotropes and pressors.
2. Treat underlying cardiac dysfunction: early revascularization if MI, tx of arrhythmia or valvular disorder.

079_BOOKZ

What is the primary hemodynamic problem in neurogenic (spinal) shock?

Low SVR ± bradycardia. Loss of all peripheral sympathetic tone can include tone to heart and adrenal glands.

What is the primary treatment of neurogenic shock?

1. Fluid resuscitation
2. Pressors: α-vasoconstrictor

What is the primary hemodynamic problem in obstructive shock?

Impedance of venous return leading to decreased CO

What are the three common causes of obstructive shock?

1. Tension pneumothorax: air under pressure compressing superior vena cava (SVC).
2. Cardiac tamponade: fluid in noncompliant pericardial sac compressing atria and impairing filling.
3. Abdominal compartment syndrome: Accumulated fluid or bowel edema maximally distends the abdomen to the point where intra-abdominal pressure rises, compressing inferior vena cava (IVC).

What is the best test for tension pneumothorax?

Physical exam: Overinflated, hyper-resonant hemithorax with decreased breath sounds. Immediate needle decompression should be undertaken if suspected.

What is the best test for cardiac tamponade?

Ultrasound. Treatment should consist of pericardial window. Emergently, pericardiocentesis can be done and a pigtail drain kept in place.

What is Beck's triad?

Sign of cardiac tamponade: hypotension, distant heart sounds, distended neck veins

A 36-year-old burn patient with a 50% total body surface area (TBSA) burn is 40-hours postburn and is partially covered. Patient is having an increasing fluid requirement and has decreasing urine output. Blood pressure is transiently fluid responsive. Abdomen is getting distended. Patient begins having an increase in peak airway pressures to maintain set volume.

079_BOOKZ

Patient becomes oliguric and more hypotensive.

What is the suspected diagnosis?

1. Abdominal compartment syndrome.

What confirmatory test should be performed?

2. Bladder pressure—using clamped Foley catheter, 60 mL of sterile saline injected into bladder and pressure transduced. >25 mm Hg is diagnostic.

What is the best treatment?

3. Decompressive laparotomy—use of a temporary Silastic mesh bag sewn to fascia or skin keeps evaporative losses down and helps decrease loss of domain that happens as open abdomen retracts laterally. Close once bowel edema has decreased.

Note: Indication based on hemodynamic instability and abdominal perfusion pressure (APP) <50: APP = mean arterial pressure (MAP) – Intra-aortic balloon pump (IABP). Mortality >50% for patients needing decompressive laparotomy due to underlying condition, not procedure.

What is the difference between traumatic shock and hypovolemic shock?

Increased degree of inflammatory mediator release after significant soft tissue injury, long bone fracture. Higher rates of multiple organ failure, ARDS, and mortality after traumatic shock vs simple hemorrhagic shock (GI bleed). Treat injuries early to minimize effect on proinflammatory cascades.

What are the functions of the following sympathetic receptors:

1. **α** — Peripheral vasoconstriction
2. **β_1** — ↑ rate, ↑ contractility, enhance AV conduction
3. **β_2** — ↑ rate, bronchodilation, skeletal/splanchnic vasodilation

How is dopamine concentration dependent?

- Low concentration—<2mcg/kg/min increases renal and splanchnic blood flow (at expense of SVR) through dopamine receptors
- Intermediate concentration—3–5mcg/kg/min increases contractility and heart rate (HR): β_1 agonist
- High concentration—>5 mcg/kg/min will increase CO and blood pressure (BP): β_1, α

What are the two predominantly peripheral vasoconstrictors?

1. Phenylephrine: pure alpha
2. Norepinephrine: $\alpha > \beta$

What is an important step when starting peripheral vasoconstrictors?

Stop tube feeds as vasoconstrictors will cause mesenteric ischemia.

What are the two pure inotropes?

Milrinone and amrinone: Phosphodiesterase antagonists. Work by increasing intracellular cAMP, alter Ca metabolism. Will also reduce afterload.

What is the best pressor in post MI cardiogenic shock?

Dobutamine—primarily β-adrenergic

- ↑ contractility with mild-moderate increase in HR
- Used to increase cardiac output, **not to treat hypotension**
- Will decrease peripheral vascular resistance

What pressor will treat virtually every type of shock?

Epinephrine—β_1 predominate: ↑ SVR, HR, contractility

- $\alpha > \beta_2$ resulting in ↑ BP and SVR
- Associated with cardiac dysrhythmias
- Increases myocardial oxygen demand
- Mimics body's response to shock: perfuse heart and brain at the expense of everything else

A septic patient is persistently hypotensive and refractory to pressors.

What test must be ordered?

Baseline cortisol and cosyntropin stimulation test. Hypotension refractory to volume and pressors is one of two things: irreversible shock (and impending death) or adrenal insufficiency.

What treatment is undertaken immediately following the test?	Empiric administration of IV hydrocortisone—must treat for adrenal insufficiency while awaiting the result.
What are the options for tightly controlled afterload reduction?	• Nitroprusside—decreases arteriolar smooth muscle dilation and will ↓ SVR • Calcium channel blockers
What is the toxic metabolite that accumulates with prolonged (>3 days) use of nitroprusside?	Thiocyanate toxicity (cyanide)
What intravenous antihypertensive agent works by decreasing venous smooth muscle tone?	Nitroglycerin: ↓ preload
What is the initial treatment for a patient with low blood pressure, tachycardia, low urine output?	Crystalloid (NS or LR) fluid bolus then reassess
In a nonbleeding, noncardiac patient, what is the Hb cutoff for transfusion?	Hb <7
What are the two components of respiratory failure treated by mechanical ventilation?	1. Failure to oxygenate 2. Failure to ventilate
What laboratory or clinical values are used to follow oxygenation?	O_2 saturated (SpO_2) and PaO_2
What laboratory or clinical values are used to follow ventilation?	$PaCO_2$ and sometimes end-tidal CO_2
What should always be performed when evaluating a patient in respiratory distress?	Arterial blood gas (ABG)
What mechanical ventilation parameters affect oxygenation?	FiO_2 and PEEP
What vent parameters affect ventilation?	Tidal volume and respiratory rate (TV × RR = minute ventilation)
What is the normal $PaCO_2$?	40
What defines a respiratory acidosis?	Acidemia (pH <7.35) with a PCO_2 >45 mm Hg
For every 10 mm Hg in $PaCO_2$, how much will the pH decrease (ie, how do you confirm a pure respiratory acidosis)?	0.08. This is the only number you have to remember in diagnosing acute acid-base disorders. If the pH change is less than this, you have metabolic compensation. If the pH change is more than this, you have concurrent metabolic acidosis.

079_BOOKZ

What is the RSBI?	Rapid shallow breathing index. Rate/tidal volume. Predictor of successful extubation. Assessed with each spontaneous breathing trial. RSBI <80 is predictive of successful extubation.
What complication is avoided with early extubation?	Ventilator-acquired pneumonia
What is the difference between ventilator-acquired pneumonia (VAP) and community-acquired pneumonia (CAP)?	VAP is usually caused by multidrug resistant organisms—treat empirically with broad spectrum antibiotics until culture results return.
How is VAP diagnosed in the intensive care unit (ICU)?	Fever, infiltrate on chest x-ray (CXR), **plus** bronchoalveolar lavage with colony counts consistent with infection. Empirically treat gram-positives and gram-negatives based on Gram stain and await sensitivity data.
What is acute respiratory distress syndrome (ARDS)?	Bilateral pulmonary edema due to lung injury and capillary leak. Causes hypoxia. Defined as P/F ratio <200, bilateral consolidation of chest x-ray, absence of clinical findings of cardiogenic pulmonary edema.
What is the P/F ratio?	Good indicator of oxygen diffusion across alveoli. P is PaO_2. F is FiO_2. P/F ratio of 400 is normal. <200 is ARDS, 300 is acute lung injury.
The cause of acute renal failure can be lumped into what three categories?	1. Prerenal: a systemic problem 2. Intrinsic renal: a kidney problem 3. Postrenal: a voiding problem from bilateral ureteral obstruction or urethral obstruction
What is the most common cause of acute renal failure (ARF) in the ICU?	Prerenal
What is the basic cause of prerenal azotemia?	Renal hypoperfusion: can be caused by shock, hypovolemia, or dehydration
What value is paramount in differentiating prerenal from intrinsic renal or postrenal?	Fractional excretion of sodium (FENa): (Urine Na × serum Cr)/(Serum Na × Urine Cr) × 100. Value of <1% is diagnostic of prerenal.

079_BOOKZ

What are the common causes of intrinsic acute renal failure (ARF)?	• Contrast: radiocontrast dye used in CT scans or angiography • Meds • Prerenal or postrenal ARF: kidney begins to become ischemic then fails. Intrinsic acute renal failure is the final common pathway to chronic renal failure.
What are the three sites of central venous line insertion?	Subclavian, internal jugular, femoral
Name the central venous catheter site most commonly associated with the following complication.	
Uncontrolled bleeding	Subclavian (can compress the other two)
Arterial puncture	Internal jugular (IJ) (>F >SC)
Infection	Femoral (F) (> IJ >SC)
Pneumothorax	Subclavian (SC) (can happen in IJ)
What is the most important rule in placing a central line?	Never let go of the wire.
A 20-year-old trauma patient has been in the ICU for 2 weeks with multiple bouts of sepsis; now is having melanotic stools. You place a nasogastric (NG) tube and get bright red blood.	
Diagnosis?	Bleeding stress gastric ulcer
How could this have been prevented?	Stress ulcer prophylaxis with H_2 blocker or PPI
What other prophylaxis should be routine in the ICU?	Deep vein thrombosis (DVT) prophylaxis: with lower extremity intermittent compression boots, subcutaneous heparin, or subcutaneous low-molecular weight heparin (LMWH)
What are the two fatal arrhythmias treated with defibrillation?	Ventricular fibrillation and pulseless ventricular tachycardia
A patient develops atrial fibrillation. What are the two things you need to know?	1. Heart rate 2. Blood pressure **Note:** Goal of atrial fibrillation is rate control. If rate is controlled, no intervention is necessary. If rate is not controlled, the next question is how is this affecting the blood pressure.

079_BOOKZ

Your atrial fibrillation patient becomes unresponsive and has a blood pressure of 80/40. What do you need to do?	Synchronized cardioversion
After dysrhythmia is stabilized, what blood tests should be ordered?	Electrolytes
What are the 5 H's and 5 T's of pulseless electrical activity (PEA)?	Hypoxia Hydrogen ion (acidosis) Hypovolemia Hypothermia Hyper- /hypokalemia Tension pneumothorax Tamponade Thrombosis (coronary—MI) Thrombosis (pulmonary—PE) Tablets/toxins

079_BOOKZ

CHAPTER 14

Burns

How are burns classified according to depth?	1. Epidermal (first degree) 2. Superficial partial thickness (second degree) 3. Deep partial thickness (deep second degree) 4. Full thickness (third degree) 5. Fourth degree: through subcutaneous fat
What anatomic layer of skin corresponds to each burn depth?	1. Epidermal: epidermis only. To the basement membrane zone (BMZ) 2. Superficial partial thickness: papillary dermis 3. Deep partial thickness: reticular dermis 4. Full thickness: all dermis gone, into subcutaneous fat
Re-epithelialization occurs from what structures?	Accessory structures of the dermis (hair follicles, sweat glands) (see Fig. 14-1).
Why does it take longer for deeper wounds to epithelialize?	Fewer accessory structures to re-epithelialize the wound

Copyright © 2008 by The McGraw-Hill Companies, Inc. Click here for terms of use.

079_BOOKZ

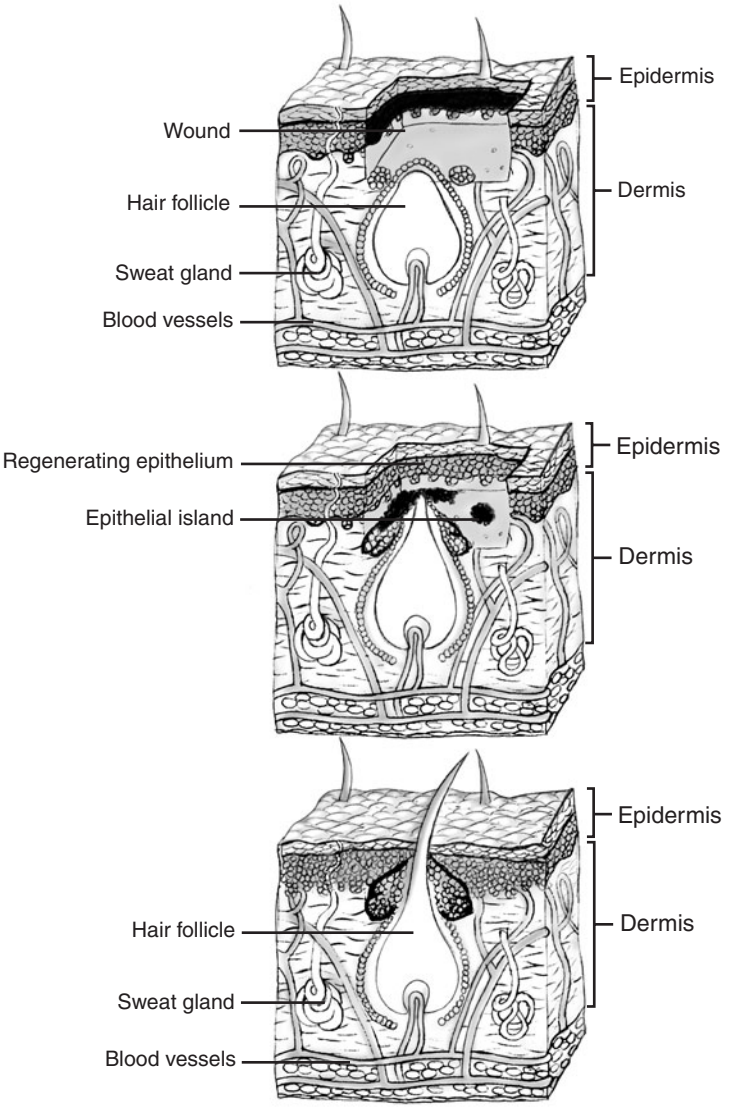

Figure 14-1 Accessory structures of the dermis.

What is the clinical appearance and healing time for each burn depth?

See Table 14-1

Table 14-1 Clinical Appearance and Healing Time for Burns of Different Depths

Burn Depth	Skin Structure Depth	Clinical Appearance	Healing Time
Epidermal	Epidermis only	Red and painful (sunburn)	3–4 days
Superficial partial thickness	Papillary dermis	Blisters > pink, moist, blanching, painful	10 days–3 weeks
Deep partial thickness	Reticular dermis	Mottled, pink-white, less painful	3–8 weeks, may need skin graft
Full thickness	Subcutaneous fat	Leathery, waxy, white, insensate	Needs skin graft

What are the three zones of a burn characterized in the Jackson classification?

1. Zone of coagulation: central area of dead tissue (full thickness).
2. Zone of stasis: area surrounding the zone of coagulation made up of ischemic tissue which is vasoconstricted. Indeterminate thickness that may convert to partial thickness or full thickness burn. Viability in question.
3. Zone of hyperemia: outermost area of a burn. Vasodilated from release of cytokines. Viable tissue.

How is a burn classified according to area?

By percent of total body surface area (% TBSA) (see Fig. 14-2).

What is the "rule of 9's"?

"Rule of 9's" is used to estimate TBSA in adults.

9% areas:

Head and neck

Each upper extremity

18% areas:

Anterior trunk

Back

Each lower extremity

1% areas:

Perineum

Palm

Palm rule:

To estimate irregular burns, palm of the patient is a reliable estimate.

Palm with fingers together = 1% TBSA

Note: exceptions—Infant head is disproportionately large : 18% TBSA, each lower extremity becomes 14%

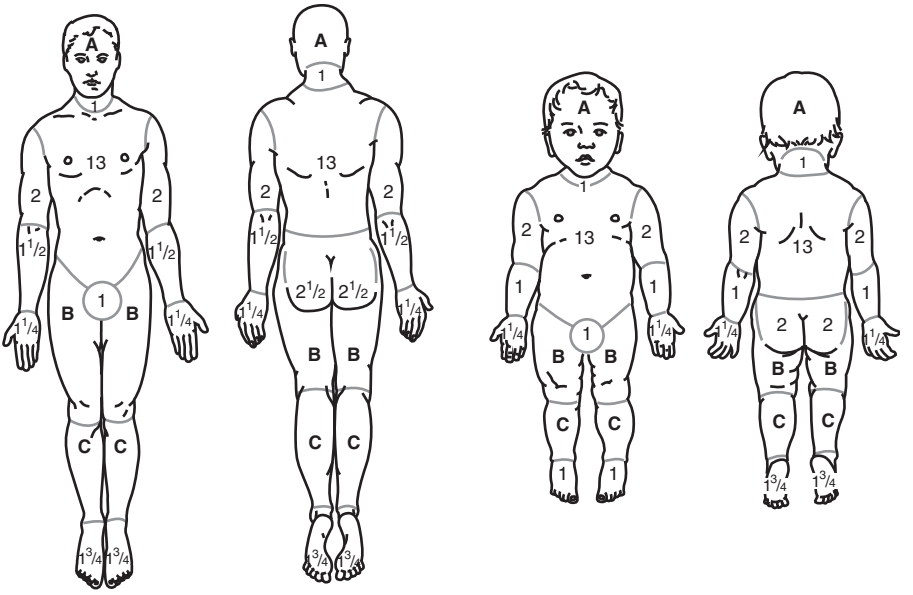

Relative Percentages of Areas Affected by Growth

Area	Age 10	Age 15	Age Adult
A = half of head	$5\frac{1}{2}$	$4\frac{1}{2}$	$3\frac{1}{2}$
B = half of one thigh	$4\frac{1}{4}$	$4\frac{1}{2}$	$4\frac{3}{4}$
C = half of one leg	3	$3\frac{1}{4}$	$3\frac{1}{2}$

Relative Percentages of Areas Affected by Growth

Area	Age 0	Age 1	Age 5
A = half of head	$9\frac{1}{2}$	$8\frac{1}{2}$	$6\frac{1}{2}$
B = half of one thigh	$2\frac{3}{4}$	$3\frac{1}{4}$	4
C = half of one leg	$2\frac{1}{2}$	$2\frac{1}{2}$	$2\frac{3}{4}$

Figure 14-2 Burns diagrams of children and adults estimate burn area. [*Reproduced, with permission, from Doherty GM (ed): Current Surgical Diagnosis & Treatment. New York: McGraw-Hill, 2005.*]

What is the burn LD50 (lethal dose in 50%) in TBSA?

Currently it is 80%. This is up from 30% before early excision and grafting became standard of care.

What is the initial treatment protocol of a burn patient?

ABCs (**A**irway, **B**reathing, **C**irculation). First and foremost, large burn area patients are considered trauma patients.

What is the emergency physician's rule for burns in a multisystem trauma?

Ignore the burn completely until life-threatening injuries are treated.

Is inhalation injury more commonly an upper (trachea and bronchi) or a lower airway (alveoli) process?

Upper airway. Risk of inhalation injury is upper airway edema and eventual airway obstruction.

What are the physical signs that increase the risk of airway obstruction?

- Burn in an enclosed space
- Singed nasal hairs
- Charring in oropharynx
- Carbonaceous sputum

What is the treatment if inhalation injury is suspected?

Endotracheal intubation

What is the physical exam that is a clue that upper airway edema is resolved?

Leak of air around a previously snug endotracheal cuff

What is the earliest sign of airway injury?

Low P/F ratio (PaO_2 to FiO_2 ratio)
- Normal: 300–400
- Indication for intubation: <250
- Definition of Adult respiratory distress syndrome (ARDS)—<200

Hemoglobin has more affinity for carbon monoxide or oxygen?

CO. 200 × that of oxygen

What oxygen measuring device cannot be used if a patient is suspected of carbon monoxide poisoning?

Pulse oximetry. Contraindicated in CO poisoning. Will give overestimate of oxygen content.

What are the five ways carbon monoxide causes tissue damage?

1. Prevents reversible displacement of O_2 from Hb leading to tissue hypoxia.
2. Shifts O_2 dissociation curve to the left to decrease O_2 unloading also leading to tissue hypoxia.
3. Binds cytochrome a_3 to interfere with cellular respiration.
4. Directly toxic to skeletal and cardiac muscle.
5. Causes peripheral demyelination.

What are the symptoms of carbon monoxide poisoning?

See Table 14-2.

Table 14-2 Symptoms of Carbon Monoxide Poisoning

COHb Level	Symptoms
<10%	None
20%	Headache, nausea, vomiting, loss of manual dexterity
30%	Confusion, weakness, lethargy
40–60%	Coma
>60%	Death

What is the treatment of choice for carbon monoxide poisoning?

100% FiO_2 via nonrebreather mask or if decreased level of consciousness, intubation and 100% FiO_2.

Effect of 100% inhaled oxygen is to decrease the half life of carboxyhemoglobin (COHb) from 4 hours on room air to 1 hour.

What are the hemodynamic components of burn shock?

- Intravascular depletion due to venule dilation and increased permeability
- Decreased cardiac output due to direct cardiac depression

Note: Burn shock is basically a systemic inflammatory response syndrome (SIRS) due to release of cytokines.

Goal of therapy in burn shock is to restore plasma volume to prevent tissue hypoperfusion.

What is the TBSA cutoff for resuscitation according to a burn shock protocol?

20% TBSA and greater

What is the Parkland formula?

Estimate of the amount of fluid volume needed for initial burn shock resuscitation in the first 24 hours.

Resuscitative volume = 4mL × (%TBSA burned) × (weight in kg)

Give one-half estimated volume in first 8 hours, then the rest over the next 16 hours.

Use lactated Ringer's (LR,) not colloid in the first 24 hours. Children <20 kg get $D_{5_{1/2}}$ normal saline (NS) as resuscitation fluid (never use this for any other population).

Why not use normal saline as resuscitation fluid in burn shock?

Risk of hyperchloremic metabolic acidosis. Volume of fluid needed is such that this is inevitable. Kidneys waste bicarbonate when they see too much anion (chloride) resulting in acidosis.

What are the urine output goals to guide burn shock resuscitation and maintenance fluid?

Kids: 1 mL/kg/h
Adults: 0.5 mL/kg/h

What are some complications associated with burn shock resuscitation?

- Compartment syndrome—both extremity and abdominal
- Pulmonary edema

What are the indications for escharotomy? (See Fig. 14-3)

- *Circumferential* full thickness burn to an extremity with signs of distal perfusion compromise.
- Chest burns in which the eschar is a mechanical barrier to respiration.

Burn wound infection can be prevented by using topical or systemic antibiotics?

Topical. Systemic antibiotics are only indicated if cellulitis arises in healthy tissue. They do not penetrate eschar.

What treatment, if any, should a patient with a burn wound receive according to the following history?

1. **Tetanus booster 7 years ago**
   1. Tetanus and diphtheria (Td) booster
2. **Never vaccinated**
   2. Tetanus immune globulin (TIG) then three dose tetanus vaccination
3. **Tetanus booster 3 years ago**
   3. No treatment

The Centers for Disease Control and Prevention (CDC) guidelines are >5 years for Td and nonvaccinated or unknown should get TIG. Many people do not practice this and just give Td to unknowns.

Figure 14-3 Anatomic escharotomy sites. Escharotomy should be carried down to fat. No anesthesia is necessary. Extremity escharotomy needs to be performed on both medial and lateral surfaces to release circumferential tension.

What is the first step in management of a chemical burn?

Decontamination—Remove the chemical and clothes from the patient. If dry, brush off all visible chemical before irrigation. Whether acid or base exposure, use water to dilute (15 minutes continuously). Do not use neutralizing agents. These cause exothermic reactions that can add heat damage to chemical damage. Chemicals continue to burn until they are removed.

Which is usually deeper—an acid or an alkali burn?

Alkali. An acid burn usually creates a tanned, impermeable skin whereas alkali tends to combine with lipids and create a soap which dissolves skin.

What is the electrolyte disturbance induced by a hydrofluoric acid burn?

Hypocalcemia

What is the only test needed to rule out cardiac injury in a low voltage (<440 volts) electrical injury?

ECG

What are three short-term and three long-term complications of high-voltage electrical burns?

Short-term
1. Arrhythmia (including ventricular fibrillation (VF), asystole)
2. Myoglobinuria and acute tubular necrosis
3. Extremity compartment syndrome

Long-term
1. Cataracts (5–10%)
2. Peripheral neuropathy
3. Reflex sympathetic dystrophy

What is the goal urine output in a patient with myoglobinuria?

For adults, >100 mL/h. For kids, >2 mL/kg/h

What medication can be used to facilitate urine output in a patient with myoglobinuria?

Mannitol, but use with caution, urinary output (UOP) will not be a predictor of fluid status.

Why is a high voltage electrical injury considered an "iceberg" injury?

What you see is the tip of an iceberg. Muscle, fat, and bone damage can be severe with minimal skin manifestation. Of these, muscle damage is most dangerous. Muscle may swell causing compartment syndrome. Dead muscle will produce myoglobinuria and acute tubular necrosis leading to renal failure. It may also be a source of infection.

How does a lightning strike kill?

Apnea induced by the strike. Cardiac activity will spontaneously resume. Start cardiopulmonary resuscitation (CPR) on lightning strike patients because they are salvageable.

What are the four degrees of frostbite?

First degree: hyperemia and edema without blistering

Second degree: hyperemia and edema with blisters

Third degree: freezing of tissue with necrosis, hemorrhagic vesicles seen

Fourth degree: gangrene and full thickness tissue loss

What is the acute treatment of frostbite?

Rapid rewarming—immersion in 37–40°C water for 10–40 minutes. This will be painful. Use parenteral nonsteroidal anti-inflammatory drugs (NSAIDs) and narcotics to control pain. Tetanus prophylaxis.

What is the chronic treatment of frostbite?

- Neutral temperature
- Hydrotherapy active movement physical therapy
- Ibuprofen
- Debridement/amputation after long demarcation period (weeks if no signs of infection)

TREATMENT

What is the treatment of choice for:

Superficial burns (epidermal or superficial partial thickness)?

Primary healing

Deep burns (deep partial thickness or full thickness)?

Excision and grafting

Indeterminate burns?

Healing trial if small. If patient is in burn shock, excision and grafting. If burn takes longer than 3 weeks to heal, excision and grafting is treatment of choice.

What is the goal of wound excision?

Remove all devitalized tissue to get to a tissue plane that will support skin graft.

What is the difference between a tangential and a fascial excision?

Tangential: remove random swipes of tissue to get to punctate bleeding.

Fascial: formal removal of skin and subcutaneous fat to get to muscle fascia.

Note: Tangential more commonly used. Saves tissue, prevents cosmetically inferior contour deformity and allows softer area once graft healed (graft directly on fat, not muscle).

With a tangential excision, how do you know you have reached a vital wound bed?

Punctate bleeding

079_BOOKZ

What is the anatomic difference between a split thickness and full thickness skin graft?

A split thickness graft leaves much of the dermis behind. A full thickness graft is all dermis. Split thickness grafts will not bear hair even coming from hair-rich donor sites (scalp). Full thickness grafts will bear hair.

How long does it take for a split thickness donor site to re-epithelialize?

10–14 days. Donor site can be available for reharvest at 14 days.

What is a sheet graft?

Unmeshed split thickness skin graft used on hands, feet, face, visible portions of extremities. Gives more natural cosmetic appearance. Higher maintenance care with frequent monitoring for and evacuation of seroma/hematoma.

How can you maximize healing in superficial burn wounds?

1. Prevent infection—clean wounds, keep in fresh dressings at least daily.
2. Keep in a moist environment—antibiotic ointment or cream.

This page intentionally left blank

CHAPTER 15

Wound Healing, Skin and Soft Tissue, and Plastic Surgery

WOUND HEALING

What are the three phases of wound healing?

1. Hemostasis and inflammation: day 0–4, primary cell types are polymorphonuclears (PMNs) and macrophages.
2. Proliferation: day 4–12 collagen synthesis (Type 3 transitioning to Type 1) endothelial proliferation and angiogenesis.
3. Maturation: balance between collagen synthesis and breakdown. Collagen matrix remodeling from random to organized collagen fibers.

What is the strength of a scar at 6 weeks?

90%

When does epithelialization occur in reapproximated surgical wounds?

Within 48 hours. Dressings can be safely removed on post-op day 2 and not redressed if wound is dry and intact.

What are the factors that are associated with delayed or impaired wound healing?

- Age
- Smoking
- Protein calorie malnutrition
- Diabetes
- Immunosuppression (steroids, chemotherapy)
- Radiation
- Infection
- Foreign body

Copyright © 2008 by The McGraw-Hill Companies, Inc. Click here for terms of use.

079_BOOKZ

What are the three categories of wound reapproximation (see Fig. 15-1)?

1. Primary intention: wounds are reapproximated with sutures, staples, tissue glue, etc.
2. Secondary intention: wounds are left open to heal by granulation tissue deposition, wound contraction, and epithelialization.
3. Tertiary intention: delayed primary closure. Wounds are left open to granulate and after a time, they are reapproximated. Risk of wound infection. Reapproximate loosely.

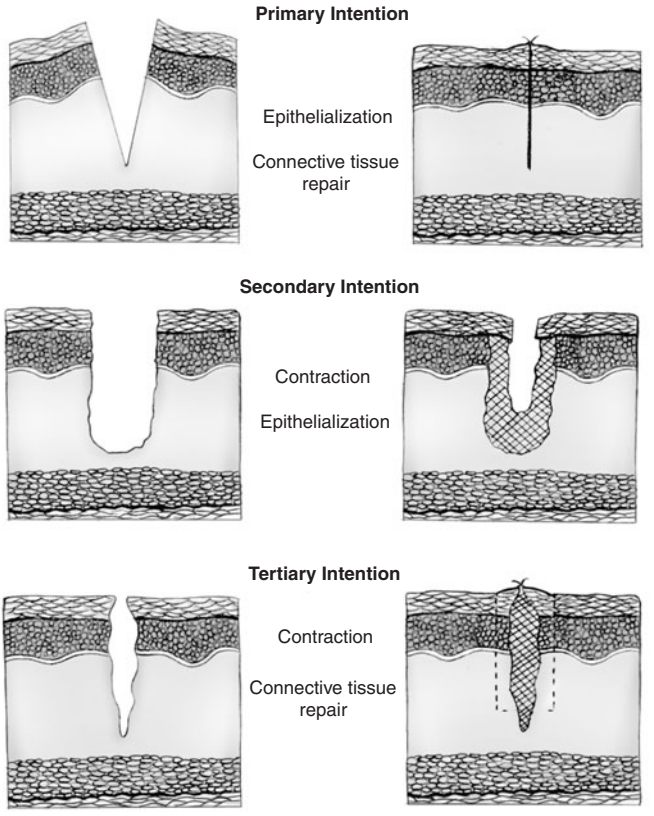

Figure 15-1 Wound reapproximation.

What are two other options of closing wounds?

Skin graft and vascularized tissue flap

What are the four degrees of wound contamination?

Class I: clean—skin and soft tissue surgery in non-infected area. 2% infection rate.

Class II: clean contaminated—gastrointestinal (GI), genitourinary (GU), or respiratory tracts are entered during the course of the case (ie, cholecystectomy) 3% infection rate.

Class III: contaminated—gross GI spillage and all traumatic wounds. 5% infection rate.

Class IV: dirty—established infection drainage of a deep abscess. 50% infection rate.

SKIN INFECTIONS

What are the physical signs suggesting wound infection?

Fever, warm erythema, purulent drainage

What is the treatment of a superficial wound infection?

- Removing sutures or staples
- Probe wound to determine extent of infection
- Drain and culture pus
- Irrigate and pack wound
- Empiric antibiotics
- Tailor to culture and sensitivity

What is the definition of cellulitis?

Superficial spreading infection of the skin and subcutaneous fat. Typical organisms are *Staphylococcus* and *Streptococcus* species.

What must be ruled out when treating cellulitis?

Abscess: Local collection of pus walled off from the body. Can be done on physical exam. Feel for "fluctuance" which is a feeling of fluid beneath the skin. Pus under pressure also feels like pushing on a blown up basketball. Always send culture. Other ways of evaluating abscess—ultrasound (US) or computed tomography (CT) scan.

What is the treatment of an abscess?

Incision and drainage. Skin incision along the length of the abscess cavity is best. Then insert hemostats to break up loculations. ± irrigation. Pack with gauze to stent opening and allow healing from "inside out."

Are antibiotic needed for abscess without cellulitis?

No. The disease is treated.

Define the following terms:

Folliculitis	Infection and inflammation of a single hair follicle.
Furuncle	Folliculitis that produces a small abscess. Will usually spontaneously drain.
Carbuncle	Deep furuncle with multiple draining sinuses.
What is a necrotizing soft tissue infection?	Fast-spreading, often polymicrobial, deep infection
What are the two types of necrotizing soft tissue infections?	1. Necrotizing fasciitis: infection of tissue planes deep to fat. Spreads along fascial planes. 2. Necrotizing myositis: infection of fat and underlying muscle.
What is the key to diagnosis?	High index of suspicion. Speed of spread. Outline erythema with pen on initial exam and assess for spread. Pain out of proportion to exam can occur. Can have bullous changes or necrotic appearance of overlying skin. Do not delay—surgical exploration and tissue biopsy is the diagnostic test of choice.
How are necrotizing soft tissue infections treated?	1. Aggressive surgical debridement of all involved tissue—may require multiple excisions 2. Broad spectrum IV antibiotics 3. Intensive care unit (ICU) management of sepsis
What is the mortality rate of necrotizing soft tissue infections?	20%

A 30-year-old obese woman presents with chronic drainage from the skin of bilateral groins for >6 months. Physical exam reveals indurated areas of the groin creases in hair bearing regions. There are multiple small abscesses, some spontaneously draining, some intact. There are visible healed tracts. No surrounding erythema.

079_BOOKZ

What is the diagnosis?	Hidradenitis suppurativa
What is the etiology?	Chronically infected apocrine glands—defect in terminal follicular epithelium leads to blockage and secondary infection. Diagnosis is by physical exam. See induration, multiple stages of abscess formation, draining and healing. Polymicrobial—cultures not helpful.
Where is hidradenitis suppurativa typically located?	Axilla, groin, perianal region; can involve scalp.
What is the treatment?	Antibiotics can temporize. Incision and drainage (I & D) and warm compresses for acute presentation. Wide surgical excision of all involved areas with or without skin grafting is the only cure.

A 35-year-old HIV-positive man not on antivirals presents with a fumigating perianal mass. He is having itching and hygiene problems.

What is the diagnosis?	Condylomata acuminatum (genital warts)
What is the etiology?	Viral infection—human papillomavirus (HPV)
What is the differential?	Squamous cell anal cancer—HPV is predisposing factor.
What is the treatment?	Surgical curettage and electrodesiccation. Can manage medically with sclerotic agents, but surgery offers tissue diagnosis in case of cancerous transformation.

A 20-year-old with ulcerative colitis develops a chronic nonhealing necrotic ulcer with surrounding erythema in the area over his anterior tibia.

What is the diagnosis?	Pyoderma gangrenosum
What are the predisposing conditions?	Inflammatory bowel disease, rheumatoid arthritis, malignancy
What is the treatment?	Do not debride. Treat underlying condition. Steroids or cyclosporine will usually help if cannot be identified.

ULCERS

What are the three types of foot ulcers?	Arterial insufficiency ulcer, diabetic foot ulcer, venous stasis ulcer
What are the key physical exam findings of:	
Venous stasis ulcer?	Scaly skin, venous tattooing, medial malleolus
Arterial insufficiency ulcer?	Toe ulcers, hairless, waxy legs, no peripheral pulses
Diabetic foot ulcer?	Plantar and toe ulcers, peripheral neuropathy
Which ulcers get infected?	Diabetic and arterial insufficiency
What must be ruled out in an infected ulcer?	Osteomyelitis
What is the treatment of a necrotic toe?	Amputation, which may be delayed with dry gangrene
What is the difference between a keloid and a hypertrophic scar?	Keloids extend beyond wound margins. Both are abnormal deposition of randomly organized collagen fibers and abnormal remodeling resulting in a heaped-up scar.
A 50-year-old has a nonhealing wound on the edge of a burn scar that was previously healed but has broken down many times. The tissue is now heaped up around the edges of the ulcer. The burn occurred 15 years ago. What is the lesion?	Marjolin's ulcer—squamous cell cancer in a burn scar

CYSTS

What are the three types of cutaneous cysts?	1. Epidermal 2. Trichilemmal (pilar) 3. Dermoid
How are they similar?	All epithelium lined and filled with keratin. Have a tendency to get infected.
How do they differ?	Histologically. The degree of maturity of the epidermis and the presence of skin adnexa.

079_BOOKZ

Where do dermoid cysts usually form?	Along embryonic fusion planes, mostly craniofacial fusion planes. Commonly found at the medial and lateral eyebrow.
What is the treatment of a cutaneous cyst?	If infected, I & D followed by excision. If not infected, excision. Important to get the whole cyst, which is easiest to do if the cyst is not ruptured.

SKIN LESIONS

Seborrheic keratosis lesions are characterized by what appearance?	"Stuck on," velvety, brown (look like barnacles). Found in elderly.
Actinic keratosis is characterized by yellow, rough, scaly appearance. Distribution is on sun-exposed skin. It is premalignant for which type of skin cancer?	Squamous cell carcinoma
A 60-year-old patient presents with a cutaneous lesion on his nose. It has a pearly appearance, an ulcerative base, and rolled borders.	
What is the diagnosis?	Basal cell carcinoma
What is the treatment?	Local excision. Microscopic margins are commonly obtained on the nose and scalp to minimize tissue defect.
What is the most common skin cancer?	Basal cell
A 60-year-old man with a large, bleeding, slow growing, skin lesion on his shoulder. It has an ulcerative center and heaped up margins that are flesh colored.	
What is the first step in diagnosis?	Biopsy—punch biopsy at margin obtaining full thickness lesion and normal skin in the same sample. Shave biopsy not as helpful.
What is the most likely diagnosis?	Squamous cell carcinoma
What is the treatment?	Excision with 1 cm margin

What are the ABCDE's of melanoma diagnosis?

Asymmetry

Border (irregular)

Color (black to blue, multiple colors in same lesion)

Diameter >6 mm

Evolution—change over time—growing, inflammation, pruritic

How is a suspected melanoma lesion initially dealt with?

Biopsy

What are precursor lesions that predispose to melanoma?

Dysplastic nevi, which can be part of a heritable syndrome with multiple dysplastic nevi

What is the most important characteristic of the primary melanoma lesion with regard to prognosis?

Depth of invasion

What are the four types of melanoma? What is the percentage of occurence and where are they located?

1. Superficial spreading—70%. Most common. Flat, radial growth pattern.
2. Nodular—15–30%. Raised lesions, lack of radial growth pattern. All are in vertical growth pattern.
3. Lentigo maligna—4–15%. Face, hands, neck of elderly. Surrounded by area of solar degeneration. Late vertical growth phase.
4. Acral lentiginous—2–8%. Palms, soles, under nails. Most frequent type in dark-skinned individuals.

How is melanoma stage assessed?

Based on depth of invasion (T), lymph node status (N), metastases (M)

What is the current T staging system for melanoma?

T1—0 to 1 mm

T2—1.01 to 2 mm

T3—2.01 to 4 mm

T4—4.01 or greater

Modifiers—a for no ulceration, b for ulceration

What type of biopsy should be used for melanoma?

Excisional biopsy—1 mm margin. Orient incision along the long axis of extremities. If lesion is too large, may do incisional biopsy of the area of concern.

If melanoma is found, what is the first line of therapy?

Surgery

079_BOOKZ

How large of a margin should be taken?	Depth 1 mm or less: 1 cm margin Depth >1 mm: 2 cm margin
How deep do you take your melanoma resection?	To the level of fascia to ensure all lymphatic tissue is taken.
How do you assess lymph node status?	Clinically—palpable lymph nodes require formal lymphadenectomy Surgically—sentinel lymph node biopsy. If positive, then formal lymphadenectomy
What stage of melanoma requires a formal lymphadenectomy?	Stage III
Does systemic chemotherapy improve survival in metastatic melanoma?	No
What systemic agents have been shown to increase survival?	Interferon—alfa 2b Cancer vaccine
What is the treatment of choice for in transit metastatic melanoma?	Isolated limb perfusion (using melphalan plus interferon gamma or tumor necrosis factor (TNF) alpha)

SOFT TISSUE TUMORS

A 40-year-old man presents with multiple spongy, well-circumscribed, subcutaneous masses on his back.	
What is the diagnosis?	Lipoma—benign fatty tumor
What is the treatment?	Excision
What is the typical clinical presentation of a patient with soft tissue sarcoma?	Asymptomatic enlarging mass
What is the imaging modality of choice in	
Extremity soft tissue sarcoma?	Magnetic resonance imaging (MRI)
Retroperitoneal sarcoma?	Computed tomography (CT)
What are the four ways to obtain a tissue diagnosis in soft tissue sarcoma?	1. Fine-needle aspiration (FNA) cytology—perform only if cytopathologist is available. 2. Core-needle biopsy. 3. Incisional biopsy—last resort if not accessible by needle biopsy techniques. Use for lesions >3 cm. Orient longitudinally along extremity. 4. Excisional biopsy—use for lesion <3 cm. Attempt at curative resection.

What is the most important predictor of prognosis in soft tissue sarcoma?	Histologic grade
What are the common locations of soft tissue sarcoma?	Extremities—59% Trunk—19% Retroperitoneum—13% Head and neck—9%
What is the most common type of soft tissue sarcoma in childhood?	Rhabdomyosarcoma
What is the most common type of soft tissue sarcoma in adulthood?	Malignant fibrous histiocytoma
What is the route of metastatic spread in soft tissue sarcoma?	Hematogenous
What is the most common site of metastasis?	Lungs—all sarcoma patients should have chest x-ray or CT to look for metastasis.
What is the treatment for isolated lung metastases?	Resection
Are sarcomas radiosensitive?	Yes
What is the treatment of choice for extremity soft tissue sarcoma?	Wide local excision plus adjuvant radiation if tumor >5 cm. 2 cm margin is goal. Biopsy tract should be taken en bloc with specimen. Current goal is limb salvage.
When is amputation indicated for sarcoma?	Only when function of the limb cannot be preserved after wide local excision.
What is the treatment of retroperitoneal sarcoma?	Margin-free resection. This is more difficult in retroperitoneal sarcomas. 50% of which are >20 cm at time of diagnosis.
What is the most common visceral sarcoma?	GIST—gastrointestinal stromal tumor. Treatment is resection.

PEDIATRIC SOFT TISSUE

A newborn with a large, hairy, raised, brown-black lesion on her back.

What is the diagnosis?	Giant hairy nevus
What is the treatment?	Excision—5% chance of malignant transformation

An infant with a raised, red-purple lesion on her face. It has a sharp border and is spongy. It has been enlarging over the past months.

What is the diagnosis?	Hemangioma (cavernous)
What is the treatment?	Observation. Most will spontaneously involute before 7 years of age. Thrombocytopenia, high output cardiac failure, or interference with function (feeding, urinating), are indications for resection.
What is the difference between the natural history of port wine stains and cutaneous hemangiomas?	Port wine stains (geographic pink-red flat discolorations usually found on the face in trigeminal distribution) do not spontaneously involute. They can be treated with laser or excision.
What are the complications of vascular malformations?	• High output cardiac failure • Ischemic ulcers • Bone erosion
What is the treatment of a symptomatic vascular malformation?	Resection or embolization
What is the growth pattern of vascular malformations?	In contrast to hemangiomas, vascular malformations grow commensurate to the child, as hemangiomas have a rapid growth phase then involute.

PLASTIC SURGERY

The following types of skin closure are shown in Fig. 15-2:

A. Simple interrupted

B. Vertical mattress

C. Subcuticular running

D. Horizontal mattress

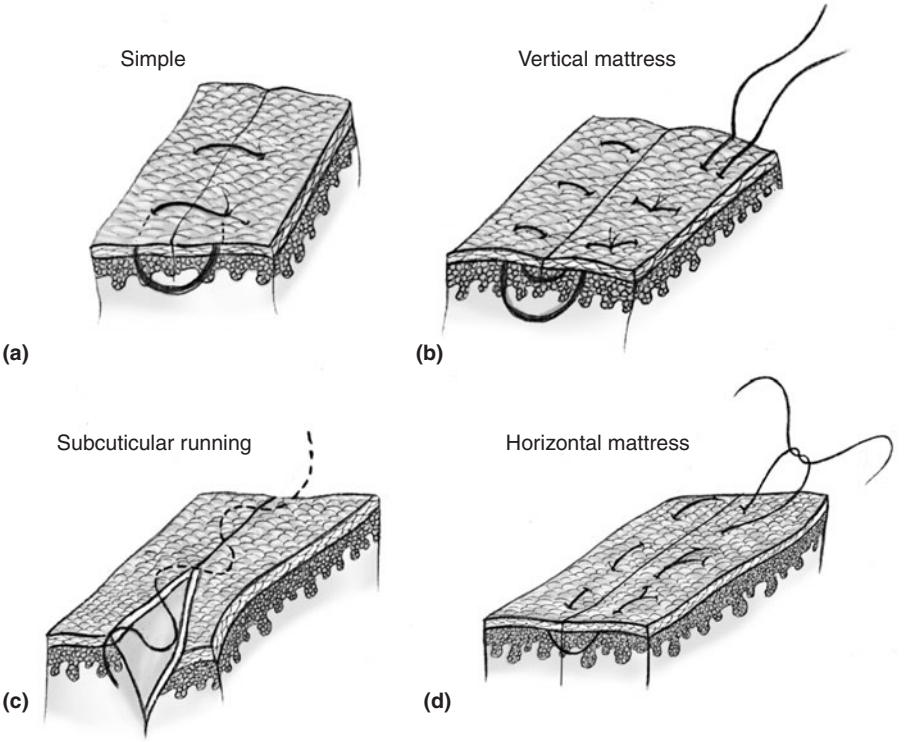

Figure 15-2 Four common types of primary skin closure.

With regard to tissue defects, what is the reconstructive ladder?

Closure techniques of increasing complexity:
1. Primary closure
2. Skin graft
3. Local vascularized tissue flap
4. Remote pedicled flap
5. Vascularized-free flap with microvascular anastomosis

What tissues will not take a skin graft?

- Devitalized tissue
- Infected tissue
- Bone (granulated periosteum will)
- Tendon (granulated peritenon will)

What are the three phases of skin graft and how long do they take?

1. Serum imbibition—24 hours—skin graft survives solely on diffusion of nutrients through wound bed.
2. Inosculation—24–72 hours—connection of graft capillaries to wound bed capillaries.

	3. Angiogenesis—>72 hours—ingrowth of new vessels into the skin graft from the wound bed.
What is the time frame for reliable graft "take"?	5 days
What factors will cause a skin graft to fail?	• Fluid collection under graft (seroma, hematoma) • Infected wound bed • Mechanical sheer forces
What are the two types of skin grafts?	1. Split thickness skin graft (STSG) 2. Full thickness skin graft (FTSG)
The following properties apply to FTSG or STSG.	
Contraction	STSG
Longer time to revascularization	FTSG
Include adnexal structures—hair follicles and sweat glands	FTSG
Donor must be closed primarily	FTSG
Donor site heals like a second degree burn	STSG
Can be meshed	STSG
Retains native color	FTSG
What is a random flap (see Fig. 15-3)	Skin and subcutaneous, ie, has blood supply based on subdermal plexus

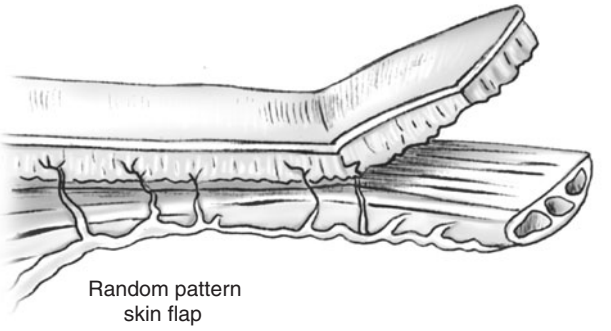

Figure 15-3 Random skin flap. Blood supply comes from subdermal plexus, not a named vessel.

What is an axial flap (see Fig. 15-4)?

Skin and subcutaneous tissue (can include muscle) that is based on a defined vascular supply, often a named vessel.

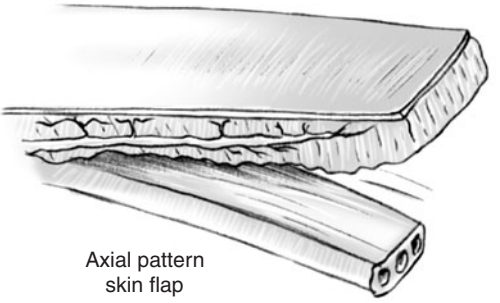

Figure 15-4 Axial skin flap based on a known artery and vein. Able to hear arterial flow with a Doppler.

What is a flap's pedicle?

In flaps that have a defined vessel, it is the portion of the flap that contains the vessels. Used with "island flaps" where the vascular supply is dissected free from surrounding tissue.

What is a common flap used to treat scar contracture bands?

Z plasty (see Fig. 15-5)

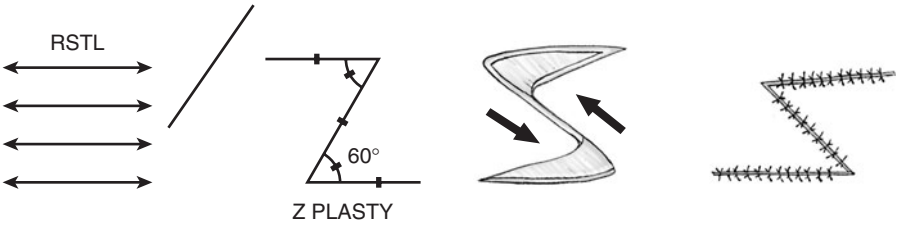

Figure 15-5 Z plasty for scar contracture is made by incisions equal in length to the central member oriented at 60°. Use as few sutures as possible and stagger to preserve blood supply.

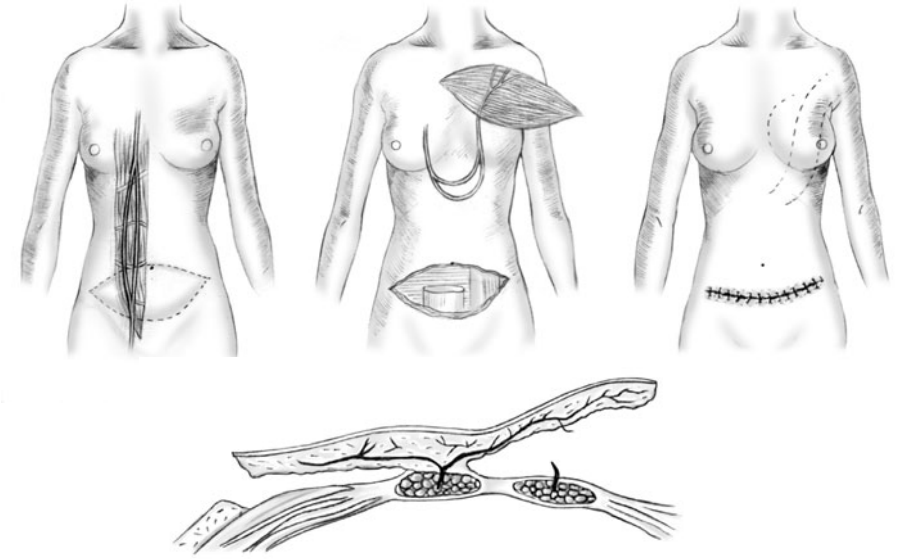

Figure 15-6 TRAM flap for breast reconstruction based on superior epigastric vessels.

What is a free flap?

Vascularized tissue flap (myocutaneous, muscle, bone) in which the native blood supply has been disconnected and reanastamosed to vessels dissected free in the recipient wound bed.

What are the reconstructive options after mastectomy?

- Implant after tissue expansion
- TRAM (transverse rectus abdominis myocutaneous) flap (see Fig. 15-6)
- Latissimus dorsi myocutaneous flap
- Free TRAM (can be muscle sparing)

PEDIATRIC PLASTIC SURGERY

What is the primary palate?

Lip, alveolus, and hard palate to the incisive foramen

What is the secondary palate?

Hard and soft palate posterior to the incisor foramen

What are the types of cleft lip/palate?

1. Cleft lip with cleft palate
2. Isolated cleft lip
3. Isolated cleft palate

Complete—to nostril floor

Incomplete—Tissue bridge connects lateral and central lip.

When should cleft lip repair be done?

Rule of 10's
10 weeks of age
10 lb
10 mg/dL hemoglobin

When should cleft palate repair be done?

Before 12 months of age to facilitate normal feeding

What is craniosynostosis?

Premature closure of one or more cranial sutures

What are the complications of craniosynostosis?

- Intracranial hypertension
- Hydrocephalus
- Visual disturbance
- Abnormal brain development

What are the goals of craniosynostosis repair?

Decompression, remodeling of the cranial vault. Usually performed at 6–12 months. (See Fig. 15-7.)

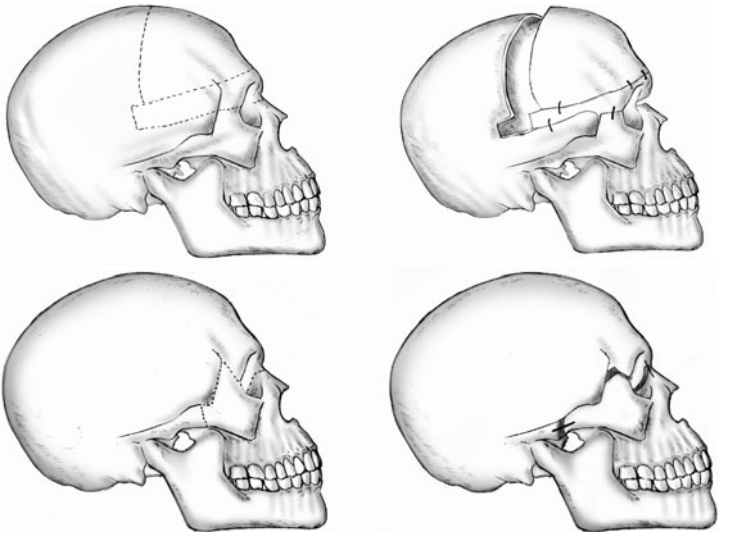

Figure 15-7 Fronto-orbital remodeling and advancement above. Le Fort III advancement below.

What is micrognathia?

Hypoplastia of the mandible

What is a major concern for neonates with micrognathia?

Airway compromise

079_BOOKZ

CHAPTER 16

Breast

ANATOMY

What are the functional histologic components of breast tissue?	1. Stroma, fat (mesenchymal origin) 2. Alveolus (ectodermal origin) 3. Ducts (ectodermal origin)
What physiologic effect does estrogen have on breast tissue?	Growth—ductal development, epithelial growth, increased sprouting and mitotic rate
What physiologic effect does progesterone have on breast tissue?	Maturation—lobular differentiation, epithelial maturation, milk production. Withdrawal causes menstruation and apoptosis of the differentiated glands.
What is the functional unit of the breast?	Lobe. Each lobe empties into a lactiferous duct which dilates to form lactiferous sinus just proximal to the nipple. There are 15–20 lobes in each breast (see Fig. 16-1). **Note:** From proximal to distal: alveoli > minor ducts > lactiferous (major) duct > lactiferous sinus.
What anatomic structures support the breast?	Stromal tissue and the suspensory ligaments of Cooper, which are fibrous bands that suspend the breast by inserting on the dermis (see Fig. 16-2).
What is the clinical significance?	Invasive breast cancer can shorten Cooper's ligaments and cause skin dimpling.
The breast rests on the fascia of what muscles?	Pectoralis major, serratus anterior, external oblique, rectus abdominis
What is the arterial supply to the breast?	• Internal mammary (thoracic) 60% • Lateral thoracic 40%

Copyright © 2008 by The McGraw-Hill Companies, Inc. Click here for terms of use.

079_BOOKZ

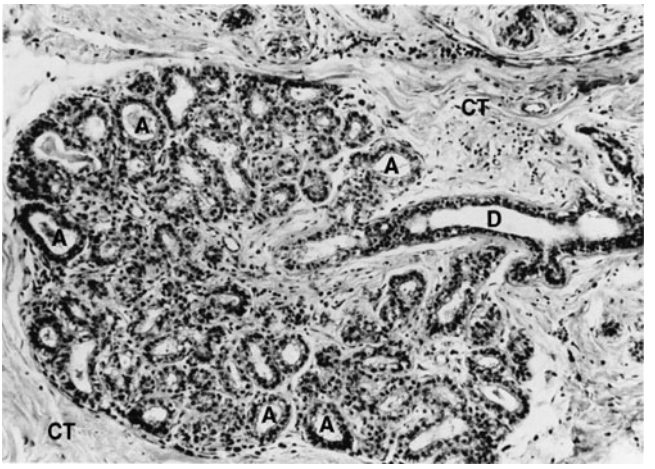

Figure 16-1 Active human breast: pregnancy and lactation (x160). The alveolar epithelium becomes conspicuous during the early proliferative period. An alveolus (A) and a duct (D) are shown. The alveolus is surrounded by cellular connective tissue (CT). [*Reproduced, with permission, from Romrell LJ, Bland KI: Anatomy of the breast, axilla, chest wall, and related metastatic sites, in Bland KI, Copeland EM III (eds):* The Breast: Comprehensive Management of Malignant Diseases, *Philadelphia; WB Saunders, 1998:23.]*

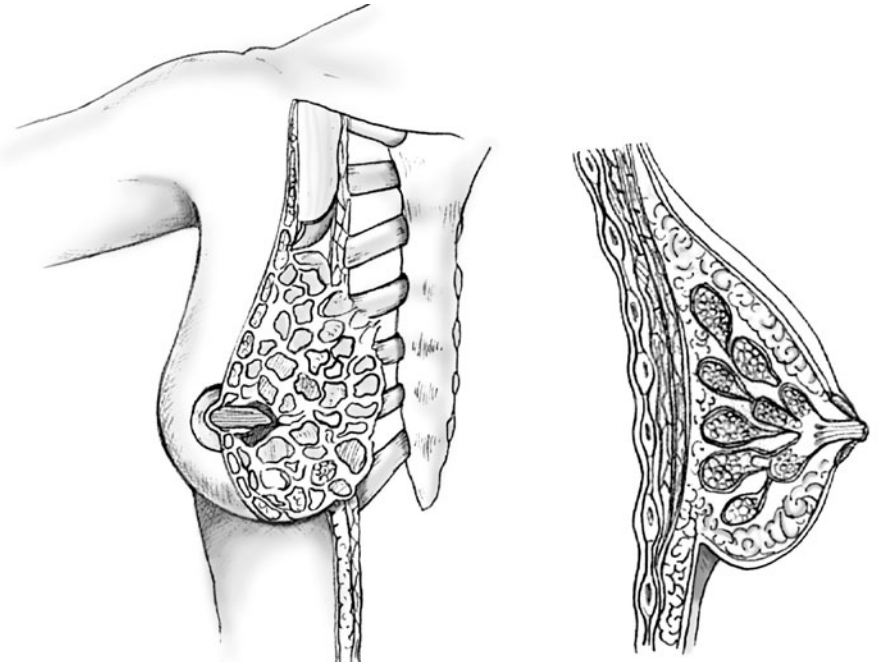

Figure 16-2 Anatomy of the breast. Tangential and cross-sectional (sagittal) views of the breast and associated chest wall.

079_BOOKZ

What is the axillary tail of Spence?	The lateral most portion of the breast that extends into the axilla
What is the clinical significance?	Must be included in mastectomy. Critical to remove in prophylactic mastectomy because patients do not get surveillance postoperatively (reason for only 90% risk reduction after prophylactic mastectomy).
What surgical procedure puts the arterial supply to the breast at risk?	Coronary artery bypass. Internal mammary artery is dissected off the chest wall and distal end is used to bypass coronary artery stenosis.
What nerves are at risk in an axillary lymph node dissection?	• Long thoracic nerve (motor to serratus anterior) • Thoracodorsal nerve (motor to latissimus dorsi) • Intercostobrachial nerve (sensory to upper inner aspect of arm) • Medial pectoral nerve (motor to pectoralis major)
The three levels of lymphatic drainage of the breast are numbered in relation to what structure (see Fig. 16-3)?	Pectoralis minor Level 1—lateral to the pectoralis minor Level 2—along and beneath pectoralis minor Level 3—medial to pectoralis minor
What percentage of the lymph flows through the axilla?	97%
Where does the remainder drain?	Parasternal, along internal mammary
Which quadrants of the breast drain to the axillary lymphatic system?	All quadrants
What are the borders of the axillary space?	Superior—axillary vein Lateral—latissimus dorsi Medial—serratus anterior Posterior—subscapularis Anterior—pectoralis major
What are some probable benign conditions of the breast?	Breast pain, nipple discharge, breast mass, breast infection (discussed in greater detail next)

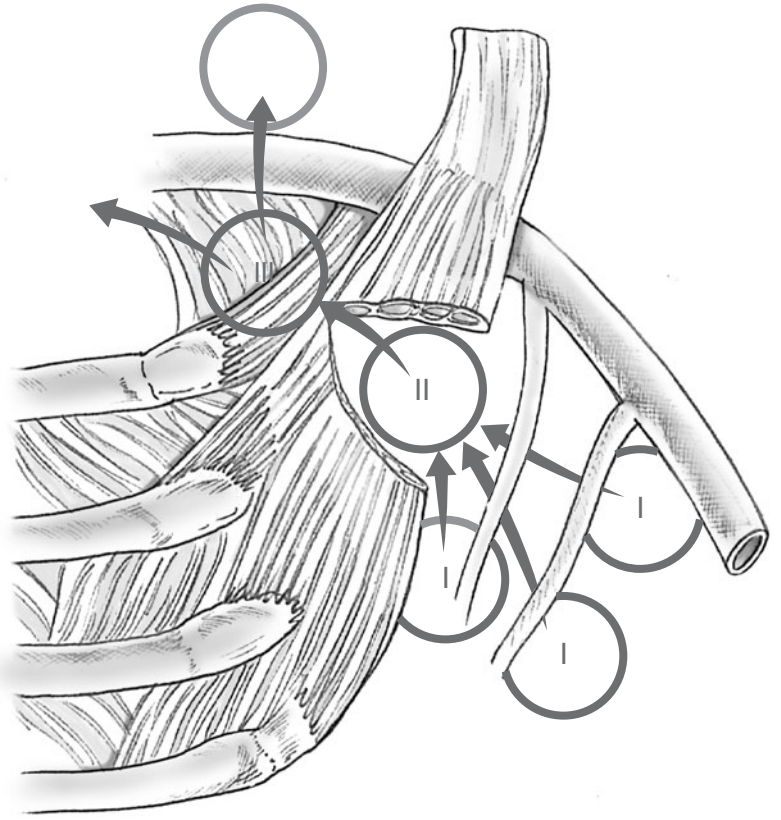

Figure 16-3 Axillary lymph node groups are classified according to their relationship to the pectoralis minor.

BREAST PAIN

What is the most common cause of breast pain?	Cyclic breast pain is associated with menstrual cycle. Pain is rarely associated with underlying cancer. Workup—physical exam, mammogram if >35.
What are two noninfectious causes of noncyclic breast pain?	Fibroadenoma and breast cyst
What are the treatment options in patients with unrelenting breast pain?	Danazol—androgenic side effects Bromocriptine Tamoxifen

What is a rare cause of breast pain that can mimic cancer in appearance?

Mondor disease—thrombophlebitis of the lateral thoracic or superior thoracoepigastric vein. Will feel a cord in the lateral aspect of the breast. Can cause skin dimpling and can sometimes herald an underlying cancer.

Workup—mammogram to rule out cancer

Treament (Tx)—nonsteroidal anti-inflammatory drugs (NSAIDs)

NIPPLE DISCHARGE

What characterizes physiologic nipple discharge?

Milky discharge only upon squeezing the nipple, from multiple ducts, bilateral

What is the pathologic discharge?

Discharge from a single duct, bloody discharge, spontaneous discharge

What studies should be performed on collected nipple discharge?

Send for occult blood if not grossly bloody. 70–85% of discharges associated with cancer contain blood. Do not send for cytology.

What is the most common cause of bloody nipple discharge?

Intraductal papilloma

Workup—ultrasound, mammography, ductal imaging, biopsy

Treatment—terminal duct excision

What are the three most common causes of galactorrhea (discharge from both nipples)?

Pituitary adenoma (prolactinoma), medications, hypothyroidism

BREAST INFECTION

Breast infections are common during what period?

Lactation

Breast abscess is treated with what two modalities?

1. Drainage (via needle aspiration and, frequently, respiration or incision and drainage [I & D]), breast-feeding mothers continue to pump
2. Antibiotics

What are the most common bacteria?

Staphylococcus and *Streptococcus*

What does a warm, erythematous breast in a postmenopausal woman indicate?

Inflammatory breast cancer. Diagnose by skin biopsy. Look for cancer in the dermal lymphatics and tumor emboli.

BREAST MASS

What is the lifetime risk of breast cancer in American women?

1 in 8

What is the differential diagnosis in a woman presenting with breast mass?

- Cancer
- Fibroadenoma
- Abscess
- Fibrocystic change
- Phyllodes tumor
- Breast cyst

What are the grave physical signs of breast cancer?

- Edema of the skin (peau-de-orange)
- Skin ulceration
- Chest-wall fixation
- Axillary LN (lymph node) >2.5 cm in diameter
- Fixed axillary LN

Note: Two or more grave signs = 2%, 5-year survival rate. Due to screening, <10% of patients now have grave signs.

What are the risk factors for invasive breast cancer?

- Age—significantly increases past 40 years
- BRCA 1 or 2 (breast cancer gene 1 or gene 2) mutation
- Proliferative breast disease—LCIS, atypical hyperplasia
- Personal history of breast cancer (1% per year risk of developing another)
- Exposure to ionizing radiation
- Family history—first degree relative premenopausal > postmenopausal
- Nulliparous or age at first childbirth >30
- Hormone replacement therapy for >5 years
- Age at menarche <12
- Age at menopause >55

079_BOOKZ

What are the initial tests for a breast mass in	
A 40-year-old female?	Diagnostic mammography and FNA or core biopsy
A 20-year-old female?	Ultrasound and FNA
What microscopic information is provided in:	
FNA?	Histology
Core biopsy?	Histology and cytology
A 20-year-old female with no risk factors for breast cancer presents with a breast mass measuring 2 cm, found to be cystic on ultrasound. What is the next step in diagnosis/treatment?	Fine needle aspiration. If aspirated to resolution, treatment is complete. If it recurs, excision. Only send aspirate for cytology if bloody or serous. If lesion does not resolve, excision.
What is the risk of cancer in a cystic breast mass?	1%
What does a spongy, well-circumscribed, mobile breast mass in a 20-year-old female indicate?	Fibroadenoma, a benign breast tumor. Diagnose by FNA or core. Follow or excise if enlarging or high risk.
What do "lumpy, bumpy breasts" indicate?	Fibrocystic change. No increased cancer risk.
What are the mammographic findings suggestive of breast cancer?	• Stellate mass • Spiculated mass • Microcalcifications **Note:** Stellate or speculated mass has a 75% chance of malignancy. In contrast, a well-circumscribed mass has a 5% chance.
What are the current screening recommendations for breast cancer?	• Yearly screening mammogram beginning at age 40 • Clinical breast exam every 3 years beginning at age 20, then yearly beginning at age 40.
What group should get earlier screening?	Strong family history—recommendation is 10 years before earliest relative diagnosed with cancer. Caveat—mammograms are very difficult to read in young women due to dense, fibrous breast tissue.

What evidence suggests that mammographic breast cancer screening is a good idea?

- 40% decrease incidence of stage II–IV cancer since instituted
- 30% increase in breast cancer survival

What are the two tumor suppressor genes linked with family history of breast cancer?

BRCA1 and BRCA2. See the following table.

	BRCA1	BRCA2
Lifetime risk of breast cancer	90%	85%
Lifetime risk of ovarian cancer	40%	20%
Chromosome	17q	13q
Inheritance pattern	Autosomal dominant	Autosomal dominant
Type of cancer	Invasive ductal Poorly differentiated ER −	Invasive ductal Well-differentiated ER +
Other associated cancers	Colon Pancreas	Prostate Male breast

What are the options for BRCA carriers?

- Prophylactic mastectomy, oophorectomy
- Screening—clinical breast exam q6 months, mammography q12 months starting at age 25, transvaginal ultrasound, and CA 125 yearly starting at age 25

DCIS

What is ductal carcinoma in situ?

Proliferation of epithelial cells confined to the ducts. By definition, noninvasive. High risk of progression to invasive cancer.

What are the four histologic subtypes of DCIS?

Solid, cribriform, micropapillary, and comedo

How are they divided for prognosis?

Comedo and noncomedo (according to Van Nuys' classification). See the following table.

Van Nuys' Classification of DCIS Subtypes

Class	Characteristics	Local Recurrence	Survival
1	Nonhigh grade Noncomedo	3.8%	93%
2	Nonhigh grade Comedo	11%	84%
3	High-grade Comedo	26.5%	61%

What is the other histologic prognostic indicator? Grade

What is the most common mammographic abnormality seen in DCIS? Microcalcifications

What are the biopsy options in nonpalpable suspicious breast mass?

- Excisional biopsy—gold standard. Ensure a margin of normal tissue (1-cm optimal) to get a curative resection. Need preop needle localization and postop specimen x-ray to confirm abnormality is removed.
- Core biopsy—stereotactic or vacuum assisted.

Define these terms as they apply to DCIS.

Multifocality Two or more foci separated by 5 mm of normal tissue in the same breast quadrant.

Multicentricity DCIS separate focus outside index quadrant.

Microinvasion DCIS with cells through basement membrane exceeding 1 mm in dimension. Upgrades tumor to T1mic, stage from 0 to 1. Ability to metastasize up to 20%. Treat differently than DCIS.

What are the treatment options of uncomplicated DCIS?

- Simple mastectomy—gold standard. No lymph node biopsy or dissection.
- Lumpectomy and radiation. Margin—1 cm, must contain all calcifications.
- Postoperative (selective estrogen receptor modulator) SERM (tamoxifen or raloxifene) for all ER + tumors.

Patient undergoes mastectomy for DCIS. On pathology, invasive cancer is found with negative margins. What is the next step in treatment?	Formal axillary lymph node dissection. This is the reason some do sentinal lymph node dissections for DCIS mastectomies.
What is the risk of new primary after a curative DCIS resection in remaining breast tissue?	Two to five times risk in general population. Same risk as breast cancer survivor.
What is the cutaneous manifestation of DCIS?	Paget's disease of the nipple. Diagnose by skin biopsy. Will find vacuolated cells in rete pegs (Paget cells) and positive CEA staining.
What is the treatment?	Mastectomy

LCIS

What is the most common way to find lobular carcinoma in situ?	Incidental finding on biopsy for another lesion. No mammographic or physical exam findings suggest LCIS.
What defines LCIS histologically?	Intraepithelial proliferation of the TDLU (terminal duct lobular unit)
Is LCIS a precursor to cancer?	No. It is a marker for an increased risk. 8–10 × risk of general population.
What are the steps in patient management after LCIS is found on stereotactic biopsy for calcifications after screening mammography?	1. Bilateral diagnostic mammography 2. Excisional biopsy to rule out concurrent DCIS, invasive cancer
Is it common or uncommon for LCIS to be bilateral?	Common—50–90%
What are the treatment options for LCIS?	1. Selective estrogen receptor modulator (SERM) and breast cancer screening 2. Prophylactic bilateral simple mastectomy **Note:** Remember, do not resect LCIS to get rid of LCIS. Resect all breast tissue because patient is at higher risk for developing invasive ductal carcinoma.

INVASIVE BREAST CANCER

What are the two most common types of breast adenocarcinoma?

1. Infiltrating ductal carcinoma—75%
2. Infiltrating lobular carcinoma—5–10%

Note: All breast cancers arise from terminal ducts.

What are the common sites of metastasis in breast cancer?

Bone, lungs, liver, brain, pleura

What is the most important predictor of survival in invasive breast cancer?

Axillary lymph node status. If negative, 30% chance of recurrence. If positive, 75% chance of recurrence.

What is the lower limit of the diameter of a palpable breast mass?

1 cm

What is the current staging system for breast cancer?

TNM

T:

T1: ≤2 cm in greatest dimension

T2: >2 cm, ≤5 cm

T3 >5 cm

T4: any size with extension into adjacent structures, associated with edema, skin ulceration, satellite skin nodules, peau-de-orange, or inflammatory breast cancer

N:

N0: no regional LN metastasis

N1: metastasis to mobile ipsilateral axillary lymph nodes

N2: fixed or matted ipsilateral axillary lymph nodes or internal mammary LN metastasis without axillary LN metastasis

N3: supraclavicular or infraclavicular LN metastasis or axillary and internal mammary

LN metastasis

M:

M0: no metastasis

M1: distant metastasis

Stage:

Any distant metastatic disease = Stage 4

Stage I: T1 N0

Stage IIA: T0–1 N1, T2 N0

Stage IIB: T2 N1, T3 N0

Stage IIIA: T0–3 N2, T3 N1

Stage IIIB: T4 N0–2

Stage IIIC: any T N3

What is the goal of axillary lymph node dissection in the treatment of breast cancer?

Accurate staging

What is the goal of a sentinel lymph node (SLN) biopsy?

To determine who needs a formal axillary lymph node (ALN) dissection. Whoever has a positive sentinel lymph node needs an axillary lymph node dissection.

What is the complication feared after ALN dissection?

Lymphedema

What are the contraindications for a SLN biopsy?

1. Clinically palpable lymph nodes
2. Stage III disease (need modified radical mastectomy)
3. Prior axillary surgery (obscures drainage)

What are the two substances injected for SLN biopsy?

1. Lymphazurin (blue dye)
2. Radiolabelled colloid

Note: Use gamma probe intraoperatively to find "hot" node, take out all hot and blue nodes.

What are the surgical treatment options for early breast cancer (Stages I and II)?

Breast

1. Breast conservation therapy (lumpectomy) and radiation
2. Mastectomy

Axilla

1. Axillary lymph node dissection
2. SLN biopsy if clinically acceptable (as above)

	Note: Remember, breast resection and radiation is for local control, axillary dissection is for staging and guidance of postop therapy.
When should lumpectomy not be done?	Multifocal disease, pregnancy (cannot get radiation), and cosmetically unacceptable location or size
What two procedures make up a modified radical mastectomy?	Combined mastectomy and axillary lymph node dissection
What are the treatment options for locally advanced breast cancer?	Stage IIIA—two methods a. Neoadjuvant chemotherapy then lumpectomy and axillary lymph node dissection or modified radical mastectomy b. Modified radical mastectomy then adjuvant chemotherapy and then radiation only if tumor >5 cm or four or more LN involved Stage IIIB and C—neoadjuvant then MRM then chest-wall radiation
When is adjuvant chemotherapy indicated?	1. Any positive nodes 2. Any tumor >1cm 3. Any tumor >0.5 cm with adverse prognostic factors on histology (Her2/Nu, ER –, PR –)
When is hormone therapy indicated?	Any hormone receptor + greater than 1 cm. Can be used as single therapy in postmenopausal women with positive nodes. Never use if receptor negative.
What are the major risks associated with tamoxifen?	• DVT (deep venous thrombosis) • PE (pulmonary embolism) • Endometrial cancer
Other than cancer risk reduction and postoperative therapy, what are the medical benefits of tamoxifen?	Increase in bone density and reduction in fractures in postmenopausal women
What is the class of hormone modulator that outperforms SERMs in reduction of recurrence and risk reduction?	Aromatase inhibitors (anastrozole)

What management changes should be made for pregnant patients with breast mass/invasive breast cancer?

- Mammography is not helpful due to breast density.
- Do not perform therapeutic abortion—does not increase treatment success.
- Lumpectomy is contraindicated unless third trimester (cannot get postop radiation unless delayed until after birth).
- SLN biopsy cannot be performed due to use of radiocolloid.
- Chemotherapy is contraindicated in the first trimester.
- No delay in surgery in any trimester.
- Immediate flap reconstruction is contraindicated.

079_BOOKZ

CHAPTER 17

Pediatric Surgery

BASIC PEDIATRICS

What is the blood volume of a pediatric patient?	85 mL/kg
What is the appropriate fluid bolus for a pediatric patient?	20 mL/kg
What is the appropriate volume of packed red blood cells (PRBC) to raise Hb by 1 (equivalent to a "unit" in adults)?	10 mL/kg
In a non-bleeding pediatric patient, what is the normal hemoglobin (Hb) cutoff for transfusion?	Hb <7
What condition will change that number?	Cyanotic congenital heart disease. Keep Hb >10
What is considered adequate urine output for a pediatric patient?	1 mL/kg/h
What is the 4-2-1 rule for calculating maintenance intravenous (IV) fluids for a pediatric patient?	4 mL/h × first 10 kg + 2 mL/h × second 10 kg + 1 mL/h × each additional kg = MIVF (maintenance IV fluids) rate per hour **Note:** MIVF usually D_5 $^1/_4$ to $^1/_2$ NS with 20 mEq KCl/L
What is the rule about enteral vs parenteral feeding?	"If the gut works, use it."
How does the bowel receive its nutrition?	• Small bowel enterocytes—glutamine primarily from gut • Colonocytes—short chain fatty acids primarily from gut

Copyright © 2008 by The McGraw-Hill Companies, Inc. Click here for terms of use.

079_BOOKZ

What are the three main complications associated with total parenteral nutrition (TPN)?

1. Cholestasis—can lead to liver failure
2. Central line complications—infection and, in kids, superior vena cava (SVC) and inferior vena cava (IVC) occlusion
3. Bowel atrophy—leads to breakdown of mucosal barrier

What is the #1 cause of death in kids? Trauma

What is the best indicator of shock in kids? Tachycardia

HEAD AND NECK

What is the most common neck mass in children? Lymph node

What is the concern if enlarged lymph nodes do not improve following 10 days of antibiotics? Lymphoma—do excisional biopsy if no improvement

What if lymph node is fluctuant? Fine-needle aspiration cytology (FNA), culture/sensitivity, appropriate antibiotics. Incision and drainage (I & D) if no improvement.

What are the infectious concerns with chronic lymphadenitis? Tuberculosis (TB), atypical mycobacterium, cat scratch fever

What is a required test before surgery for a neck mass? Chest x-ray (CXR)—Don't know if there is neck or mediastinal involvement—airway can collapse on induction.

A 4-year-old patient has a midline mass that moves up and down with swallowing. It recently became red and painful and patient is running a low-grade fever.

What is the diagnosis? Infected thyroglossal duct cyst

What is the treatment (Tx)? I & D, antibiotics, then interval surgery—Sistrunk operation for thyroglossal remnant—excision of cyst, central portion of hyoid, high ligation of the thyroglossal duct

What is the etiology? Failure of the thyroglossal duct to obliterate completely. Thyroglossal duct is the pathway of migration of developing thyroid tissue. Can have

079_BOOKZ

	residual connection with foramen cecum (back of tongue) and get infected.
What if there was no infection?	Excise with Sistrunk operation. Can have ectopic thyroid tissue which can become malignant. Palpate for thyroid first. If cannot feel, get nuclear medicine (NM) thyroid scan to make sure ectopic thyroid in cyst is not the only thyroid tissue. Will still remove, but will need post-op thyroid replacement.
What is the most common congenital mass in anterior triangle of the neck?	Branchial cleft cyst—second cleft
What is the treatment?	TX—resection, can get infected
What is the course?	Course—lower third along anterior border of sternocleido-mastoid muscle (SCM) through carotid bifurcation, into tonsilar pillar
What is the most common congenital mass of the posterior triangle of the neck?	Cystic hygroma (lymphangioma) • Lymph filled cyst due to congenital disruption of developing lymph vessels • Other locations—axilla, groin, mediastinum
A 1-year-old with a large cystic hygroma in the floor of his mouth extending deep into the neck is having positional difficulty breathing but a patent airway. What is the next step in management?	Percutaneous cyst aspiration
What is the initial treatment of torticollis?	Physical therapy. If this fails, division of SCM.

THORACIC

Congenital diaphragmatic hernia (CDH) occurs more often on which side?	Left (90%)
What are the three types of CDH?	1. Bochdalek—posterolateral, usually located in left hemithorax. 2. Morgagni—anterior, usually in anterior mediastinum. 3. Eventration—central hemithorax, failure of diaphragm to fuse—can be thin membrane that ruptures later in life.

What is the key physical exam finding in CDH?	Scaphoid abdomen
How is the diagnosis established after birth?	CXR showing bowel in chest. Can place nasogastric (NG) or orogastric (OG) before CXR to demonstrate stomach in chest. Can be confused with congenital cystic adenomatoid malformation.
Describe the four ways CDH causes disease?	1. Compression of mediastinum—reduce contralateral lung volume 2. Pulmonary hypertension (HTN)—can result in persistent fetal circulation leading to shunt 3. Hypoplastic ipsilateral lung—nonfunctional 4. Hypoplasia of contralateral lung
What is the mortality?	50%
What approach is used in surgical repair?	Abdominal—subcostal approach. Reduce contents, repair primarily or use prosthetic mesh patch (three-fourths will need prosthetic).
A newborn develops hypoxia, gets CXR showing distended radiolucent left upper lobe blebs with lower lobe atelectasis.	
What is the diagnosis?	Congenital lobar emphysema (CLE)
What is the etiology?	Congenital absence of bronchial cartilage resulting in air trapping, causing distended lung segment compressing the rest of the lung
What is the treatment?	Lobectomy—delayed until several months of age
Name three differential diagnoses of atelectatic segment in newborn?	1. Congenital lobar emphysema (causing adjacent atelectasis) 2. Mucous plugging 3. Congenital cystic adenomatoid malformation
What is the etiology of congenital cystic adenomatoid malformation (CCAM)?	Cystic proliferation of terminal airway **Note:** Pronounced "see kam".
What is the most commonly affected lobe?	Left lower lobe
What is the best imaging study to differentiate CCAM from CDH?	Ultrasound
What is the treatment of CCAM?	Lobectomy

079_BOOKZ

What is pulmonary sequestration?	Pulmonary tissue without pulmonary artery or tracheobronchial connections
What is the arterial supply for a segment of pulmonary sequestration?	Aorta
What are the two kinds of pulmonary sequestration?	Extralobar and intralobar
What is the most commonly affected lobe?	Left lower lobe
What is the most common presentation?	Recurrent respiratory infection (intralobar), extralobar generally are asymptomatic
What is the treatment of pulmonary sequestration?	Lobectomy or segmentectomy
What is a bronchogenic cyst?	A hamartoma—single cyst lined with respiratory epithelium with cartilage and smooth muscle
How do they form?	Embryonic rests of foregut that pinch off during development of tracheobronchial tree
What is the treatment of bronchogenic cyst?	Resection
What is the most common inhaled foreign body?	Peanut
Where does it usually go?	Right mainstem bronchus
What is the acute treatment of inhaled foreign body?	Rigid bronchoscopy, extraction
If foreign body is retained and segment undergoes bronchiectasis, what is the treatment?	Lobectomy—bronchiectasis causes irreversible lung damage.
Where are the three anatomic locations an esophageal foreign body can get stuck (the narrow portions of the esophagus)?	1. At cricopharyngeus muscle 2. At aortic arch 3. At gastroesophageal (GE) junction
What are the symptoms of esophageal foreign body?	Drooling, dysphagia, vomiting
What is the possible sequela of esophageal battery?	Stricture after extraction
A newborn has excessive drooling. On his first feeding in the newborn nursery, he coughs immediately after feeding. The nurse tries again resulting in choking and coughing. Why does she call you?	Concern for tracheoesophageal fistula

079_BOOKZ

What is the best test for esophageal atresia/ tracheoesophageal fistula (EA/TEF)?	Pass OG, get CXR. Will see coiled in esophageal pouch.
What is the cause of tracheoesophageal fistula?	Esophagus and trachea share embryonic origin—failure to separate will result in tracheoesophageal fistula
What are the types of esophageal atresia/ tracheoesophageal fistula?	See Fig. 17-1.

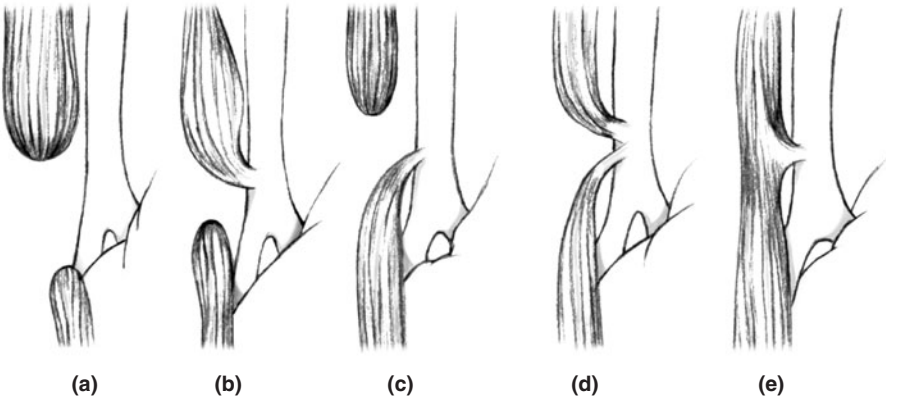

Figure 17-1 Classification of esophageal atresia/tracheoesophageal fistula.

What is the order of most to least common esophageal/tracheoesophageal fistula (EA/TEF) anomalies?	CAEDB (80%, 10%, 8%, 2%, <1%). See Fig. 17-1.
What are the chest/abdominal x-ray (CXR/AXR) findings in type C?	Inability to pass OG, excessive bowel gas
How is this different from a type A?	Will have NO bowel gas with type A.
What is the imaging test commonly needed in a patient with a type E (H-type) TEF?	Barium swallow. Kids present late with recurrent lung infections.
What congenital syndrome is EA/TEF a part of?	VACTERRL—**v**ertebral, **a**norectal, **c**ardiac, **t**racheo**e**sophageal fistula, **r**enal, **r**adial limb
What are the odds of having a cardiac anomaly with EA/TEF?	20%. Always evaluate with echocardiogram.
What is the surgical treatment of EA/TEF?	Right extrapleural thoracotomy

079_BOOKZ

What are the post-op complications?	Early anastomotic leak—take back Late anastomotic leak—antibiotics Strictures—10–20% Gastrooesophageal reflux disease (GERD)

GASTROINTESTINAL

A 6-week-old male has progressive nonbilious projectile vomiting minutes after each feeding and a ravenous appetite. This has been occurring for several days. On physical exam, you palpate an olive-shaped mass in his epigastrium.	
What is the diagnosis?	Hypertrophic pyloric stenosis (HPS).
What is the next step?	Check electrolytes and fluid resuscitation.
What is the laboratory abnormality found with HPS?	Hypochloremic, hypokalemic, metabolic alkalosis
What imaging study is needed if no olive is palpated but HPS is suspected?	Obtain ultrasound—width >3 mm, length >14 mm is positive test
What if the patient has bilious emesis?	This rules out HPS. Concern for migut malrotation, volvulus
What is the surgical treatment?	Pyloromyotomy—open or laparoscopic
A newborn has unrelenting bilious emesis and a nondistended abdomen. Abdominal x-ray shows the "double bubble" sign.	
What is the diagnosis?	Duodenal atresia (see Fig. 17-2)
What is the treatment?	Surgery—resect massively distended proximal end and taper anastomosis to the much smaller distal end
What is the differential diagnosis of a proximal small bowel obstruction?	Duodenal atresia, malrotation, midgut volvulus, duodenal web or stricture, annular pancreas, duodenal duplication cyst
What must be considered if a patient with a suspected duodenal atresia is ill appearing, ie, showing signs of sepsis or has abdominal tenderness?	Midgut volvulus secondary to malrotation

079_BOOKZ

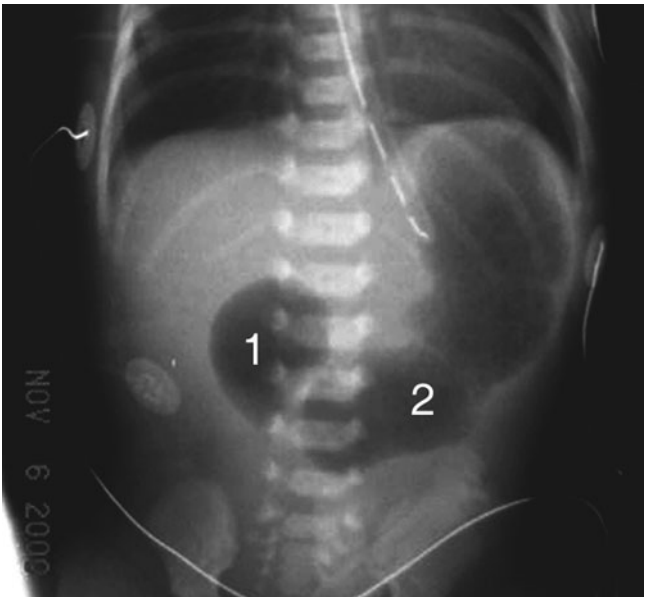

Figure 17-2 Duodenal atresia with classic "double bubble" sign (1) Duodenum (2) Stomach. [*Reproduced, with permission, from Brunicardi CF et al (eds): Schwartz's Principles of Surgery, 8th ed. New York: McGraw-Hill, 2005:1488.*]

What is the cause of intestinal atresia?	Intrauterine vascular accident resulting in a loss of a segment of bowel
What is the differential diagnosis of a distal small bowel obstruction in the newborn period?	Intestinal atresia, microcolon, meconium ileus, Hirschsprung's, small left colon syndrome, imperforate anus
What are the imaging studies to evaluate small bowel obstruction in neonates?	AXR—supine and lateral decubitus positions—cannot tell small bowel from colon in neonates because they do not have haustra or plicae circularis. Barium enema—use in patients with distal obstruction
How is intestinal atresia treated?	Surgical resection and reanastomosis—as with duodenal atresia (see Fig. 17-3)
What is the normal rotation of the midgut when it reenters the abdomen during gestation?	270° counterclockwise

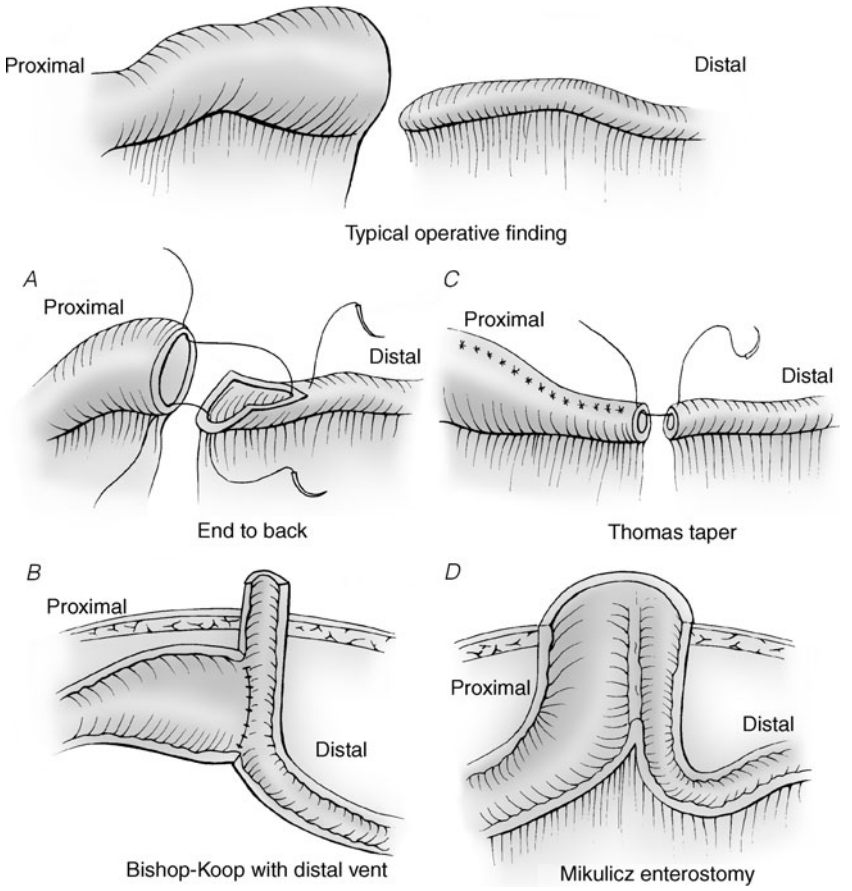

Figure 17-3 Numerous ways to reanastomose large proximal to atrophic distal bowel in intestinal atresia. [*Reproduced, with permission, from Brunicardi CF et al (eds): Schwartz's Principles of Surgery, 8th ed. New York: McGraw-Hill, 2005:1501.*]

What is the anatomic position of the cecum and the duodenum when it does not rotate?

Cecum ends up in the epigastrium
Duodenum remains straight and descends to the right lower quadrant

What are the two problems with malrotation?

1. Obstruction—the band of the peritoneum which normally fixes the cecum in the right lower quadrant (RLQ) is still present and crosses the duodenum, which can lead to obstruction. (Ladd's band).
2. Risk of midgut volvulus.

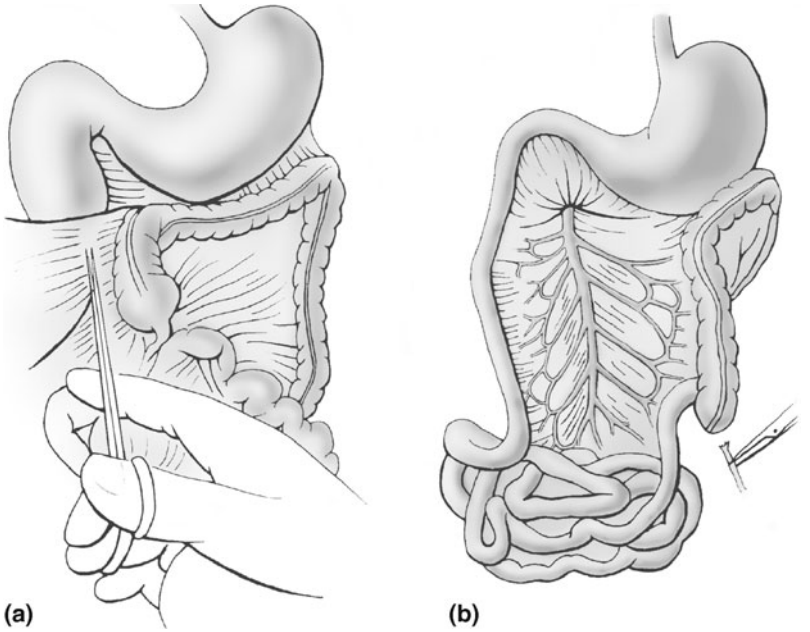

Figure 17-4 Ladd's Procedure for malrotation (a) Lysing of Ladd's bands (b) Appendectomy. [*Reproduced, with permission, from Brunicardi CF et al (eds): Schwartz's Principles of Surgery, 8th ed. New York: McGraw-Hill, 2005:1490.*]

What is the treatment for malrotation?

Ladd's procedure (see Fig. 17-4)

1. Lyse bands between cecum and abdominal wall and between duodenum and terminal ileum
2. Appendectomy

This will result in the duodenum positioning in the right and the cecum in the left upper quadrant.

What if there is volvulus?

Surgical emergency. If necrotic, may have to resect entire midgut—almost all of intestine and some colon. This leads to short gut syndrome.

1. Reduction of volvulus—reduce counterclockwise—"turn back the hands of time."
2. If not ischemic, proceed with Ladd's.
3. If necrotic, must resect.
4. If ischemic but not necrotic, observe for 24 hours and do a second look. Resect or do Ladd's at that point.

What is the earliest sign of volvulus?	Bilious vomiting—as with many other causes of obstruction. Needs a high index of suspicion to diagnose early.
What does AXR show with volvulus?	Paucity of air in entire abdomen with scattered air fluid levels and proximal dilation.
What does upper gastrointestinal (GI) study show when patient has malrotation only?	Duodenojejunal junction on the right
What is the length of intestine needed to prevent short gut syndrome in the neonate?	40 cm
What are the treatment options if patient had a wide small bowel resection and now has short gut syndrome?	1. Total parenteral nutrition (TPN) 2. Bowel lengthening procedures 3. Small bowel transplant
What is meconium ileus?	A patent anus, with failure to pass meconium in the first 48 hours of life
What is a complicated meconium ileus?	Perforated
How does it appear on AXR?	Intra-abdominal or scrotal calcifications—eggshell pattern
What is the treatment?	Surgery—find perforation and resect
What is the AXR finding characteristic of an uncomplicated meconium ileus?	Ground glass appearance in the RLQ
What congenital lung disease results in meconium ileus?	Cystic fibrosis
What is the treatment of meconium ileus?	Irrigation with water soluble contrast past obstruction. Repeat every 12 hours. If not resolved, must irrigate surgically or resect.
What are the important pathologic changes in necrotizing enterocolitis (NEC)?	• Pneumatosis • Patchy areas of thinning • "Bland infarct" with full thickness necrosis
What are the two most important factors in the development of NEC?	1. Prematurity 2. Initiation of enteral nutrition in face of stress
What are the most common necrotic segments in NEC?	Terminal ileum (TI) colon

What are the three Bell stages of NEC?

Stage I—"NEC scare"—formula intolerance with vomiting or increased residuals. Survival, 85%.

Stage II—NEC that is not immediately life threatening—clinically distended, tender, bilious NG output, bloody stools, leukocytosis or leukopenia, bandemia, anterior abdominal wall cellulitis, decreased urine output. Survival, 65%.

AXR—pneumatosis intestinalis (pathognomonic), may have portal venous gas

Stage III—advanced NEC—stage II, then peritonitis

Septic shock, death. Survival, 35%

AXR—pneumoperitoneum

When is it appropriate to operate on a patient with NEC?

Frank peritonitis, abdominal wall cellulitis, fixed mass

What is the nonsurgical treatment of NEC?

1. Stop feedings—bowel rest
2. NG decompression
3. Antibiotics (ABX)
4. Fluid resuscitation
5. TPN

Past the neonatal period, what is the most common cause of pediatric small bowel obstruction?

Intussusception—telescoping of a segment of bowel into another

What is the most common lead point for intussusception?

Terminal ileum—hypertrophic Peyer's patches from viral infection

What age group is most at risk?

6–24 months

What are the other lead points causing intussusception?

Polyp, malignancy, duplication cyst, Meckel's diverticulum

What is the classic presentation?

Paroxysms of crampy abdominal pain, currant jelly stool, palpable elongated mass in right upper quadrant (RUQ)/epigastrium

What is the imaging procedure of choice in a patient with intussusception?

Air contrast enema—therapeutic 60–90% will reduce with this maneuver alone. You'll know you have a reduction when:

1. Air passes past obstruction.
2. Patient's pain subsides (must have both).

079_BOOKZ

What is the treatment if patient has intussusception and peritonitis?	Surgery
A patient has three bouts of intussusception all resolving with air contrast. What is the next step in management?	Contrast study to look for a pathologic cause. Will need operative resection of lead point.
A 7–year-old boy with progressive abdominal pain beginning yesterday with crampy epigastric pain, now with constant, noncrampy RLQ pain complains of anorexia, nausea, and vomiting. WBC 11, T 101. Patient has tenderness in RLQ at McBurney's point, with focal peritonitis.	
What is the diagnosis?	Acute appendicitis
What is the imaging test?	No imaging
What is the management?	Laparoscopic appendectomy
How does management change if patient has had symptoms >2 days, has a high fever, high white blood cell count?	Suspect perforated appendicitis—should image—computed tomography (CT) of abdomen with IV, by mouth per os (PO), rectal contrast
What is the management of perforated appendicitis?	Nihil per os—nothing by mouth (NPO), intravenous fluid (IVF), IV antibiotics, observation
When should a patient with medically managed perforated appendicitis undergo appendectomy?	6–8 weeks (interval appendectomy)
Patient was found to have perforated appendicitis intraoperatively. He is on IV antibiotics post-op. He is now spiking fevers on day 3. What is the problem?	Abscess—CT scan and place percutaneous drain
A 2-year-old patient is found to have periumbilical abdominal pain and tenderness. You suspect appendicitis. Patient undergoes laparoscopy and has a normal appendix but an inflamed mass is found protruding off the antimesenteric border of the ileum, 60 cm from the ileocecal valve.	
What is the diagnosis?	Meckel's diverticulitis
What is the treatment?	Surgical resection

What is Meckel's diverticulum?	Remnant of the omphalomesenteric duct (vitelline duct). A true diverticulum (all layers of bowel wall) that can have gastric, pancreatic, small bowel, colonic mucosa.
What is the most common presentation of Meckel's diverticulum?	Painless rectal bleeding
What is the cause of lower GI bleed in Meckel's diverticulum?	Ulceration of downstream ileal mucosa due to heterotopic gastric mucosa producing acid.
What is the "rule of 2's" for Meckel's diverticulum?	2 years of age—most common time to have symptoms 2 feet from the ileocecal valve—most common location 2% of the population—prevalence
Name two reasons Meckel's can cause bowel obstruction.	1. Omphalomesenteric band—connecting Meckel's to the abdominal wall. 2. Intussusception—Meckel's can be lead point.
A patient has lower GI bleed and you suspect Meckel's. What is the imaging test of choice?	Meckel's scan—nuclear medicine study looking for ectopic gastric mucosa.

ANORECTAL

A newborn has not passed meconium after 48 hours. Anus is patent. Abdominal x-ray shows multiple loops of dilated bowel and air-fluid levels and an empty rectum. Barium enema shows small caliber rectum and dilated proximal colon. What is the next test?	Rectal biopsy to evaluate for Hirschsprung's disease. Rectal biopsy is always necessary to confirm Hirschsprung's.
What is the etiology of Hirschsprung's?	Dysmotile segment of distal colon due to a lack of ganglion cells in the myenteric plexus. Failure of migration of neural crest cells.
What is the treatment of Hirschsprung's?	Surgery—can be accomplished transanally. Must do intraoperative biopsy to confirm location of transition zone.
High or low classification of imperforate anus is based on relationship of fistula compared to what?	Levator ani muscle

What is the embryologic defect?	Failure of descent of the urorectal septum—the level of descent will define the level of the abnormality
What are the associated abnormalities with anorectal malformations (60%)?	VACTERRL: **V**ertebral **A**norectal **C**ardiac **T**racheo**e**sophageal fistula **R**enal **R**adial **L**imb
What is always necessary before repairing an anorectal abnormality?	Spinal ultrasound to look for tethered cord
What is the difference in management of high from low fistula?	High—colostomy then repair at 2 months—posterior sagittal anorectoplasty (PSARP)—divide sphincter, pull through and reapproximate sphincter Low—one stage pull through
What are the complications of pull through for	
High fistula?	Incontinence
Low fistula?	Constipation

JAUNDICE

When does physiologic jaundice typically resolve?	5–7 days
When is jaundice "pathologic"?	2 weeks
What is the differential diagnosis of pathologic jaundice?	1. Obstructive—biliary atresia, choledochal cyst, inspissated bile syndrome 2. Hematologic—ABO incompatibility, Rh incompatibility, spherocytosis 3. Metabolic—inborn errors of metabolism 4. Congenital infection—rubella, syphilis
A 3-week-old presents with jaundice, lack of weight gain, has grey stools. What is the suspected diagnosis?	Obstructive jaundice

079_BOOKZ

After jaundice is confirmed, what is the first imaging test to help differentiate the causes of obstructive jaundice?	Ultrasound
What is the diagnosis if a large dilation of the common bile duct is seen?	Choledochal cyst
What if no dilation is seen?	Biliary atresia (no dilation of intra-or extrahepatic ducts)—obliteration of common duct, cystic duct, hepatic ducts, or gallbladder
What test will confirm the presence of biliary atresia?	Diisopropyl iminoacetic acid (DISIDA) nuclear medicine scan. See liver light up but not intestine.
What are the two surgical options in the treatment of biliary atresia?	Kasai portoenterostomy—resection of biliary tract and Roux-en-Y reconstruction with anasomosis at porta hepatis Liver transplant
What is the risk of untreated biliary atresia?	Liver failure
What is the long-term risk after Kasai repair?	Cholangitis—10-year survival 50%
What is the treatment of choledochal cyst?	Excision (risk of malignant degeneration) and biliary-enteric reconstruction

ABDOMINAL WALL

What are the four embryonic folds that lead to the formation of the abdominal wall?	Cephalic, caudal, two lateral—come together to form umbilical ring
Name the abnormality associated with failure of each fold:	
Cephalic	Absence of sternum
Caudal	Exostrophy of the bladder
Lateral	Omphalocele
Umbilical ring	Umbilical hernia
Before what age is an umbilical hernia likely to close spontaneously?	4 years. After this elective, closure should be offered. Before this, patients can be observed.

079_BOOKZ

Other than age, what is another indication for umbilical hernia repair?	Symptomatic—incarcerated or obstructed
What is the diagnosis of a newborn presenting with chronic clear drainage from umbilicus?	Patent urachus—free connection of bladder and abdominal wall. Treatment is excision.
What is the differential diagnosis of chronic foul smelling umbilical drainage?	Urachal cyst (infected), patent vitelline duct
What is the difference between omphalocele and gastroschisis?	Omphalocele—anterior abdominal wall defect **covered by peritoneum** (but can rupture), umbilical cord goes into sac, caused by failure of embryonic abdominal fold. 60% associated with multiple anomalies. Gastroschisis—anterior abdominal wall defect **not covered by peritoneum—**bowels exposed to amnionic fluid, umbilical cord medial to sac, caused by intrauterine accident. Intestinal atresia only associated anomaly.
What are the changes to bowel the longer it is exposed to amnionic fluid?	Thick, edematous, discolored with exudate
What is the management of gastroschisis?	1. Prophylactic ABX 2. Total parenteral nutrition (TPN) (non-functional bowel) 3. Silastic silo placed 4. Closure attempted within 1 week 5. Prosthetic mesh used if primary repair cannot be accomplished
What is the defect in inguinal hernia?	Patent processus vaginalis (most indirect hernias)
What is the difference between a communicating hydrocele and an inguinal hernia?	No bowel can be felt in the hydrocele, but they are the same defect.
What is the treatment of a noncommunicating hydrocele?	Observation—most will resolve in 12 months
What is the treatment of a communicating hydrocele?	Inguinal hernia repair
What are the indications for repair of an inguinal hernia?	The presence of hernia (ie, fix all hernias)

What is the difference between the repair of an adult and a childhood inguinal hernia?

Adult hernia—need to repair the floor of the inguinal canal

Childhood hernia—closing the patent processus vaginalis only—high ligation of the hernia sac

What is the chance of having a contralateral inguinal hernia?

30%. A common way to find occult hernia is to use a laparoscope through the hernia sac of the hernia that is being repaired to observe contralateral side.

GENITOURINARY

Besides communicating hydrocele and true inguinal hernia, what other condition requires a hernia repair?

Cryptorchidism—undescended testis

What predisposes to cryptorchidism?

Prematurity—present in 30% of premies compared to 1–3% in term (descent occurs in seventh or eighth month)

What are the two sequelae of undescended testes even after repair?

1. Infertility
2. Higher risk of cancer in affected testicle

What is the first line of treatment with *bilateral* cryptorchidism?

Chorionic gonadotropin

What is the treatment of choice for unilateral cryptorchidism?

Orchiopexy before age 2

What is an important role of the surgeon in follow-up care of these patients?

Yearly testicular exam screening for cancer. May teach self-exam when patient is a teenager.

A 1-year-old female presents with tender mass protruding from introitis. On ultrasound, a distended vagina is displacing the bladder.

What is the diagnosis?

Hydrocolpos—accumulated secretions into an obstructed vagina

What are the two causes?

1. Imperforate hymen—treat by simple division
2. Vaginal atresia—treat by mobilization and either primary anastomosis with skin or bowel interposition

079_BOOKZ

What are the four types of ambiguous genitalia?

1. True hermaphroditism—46XX, ovarian and testicular tissue, usually one on each side.
2. Male pseudohermaphroditism—46XY, phenotypic female. Defect in masculinization.
3. Female pseudohermaphroditism—46XX, masculinization of external genitalia.
4. Mixed gonadal dysgenesis—45XO, 46XY mosaic. High incidence of malignancy—gonadoblastoma.

What tissue must be removed in the various disorders?

Male gonadal tissue must always be removed because of risk of malignant degeneration.

ONCOLOGY

What is the differential of a large abdominal/flank mass in children?

Wilms' tumor (nephroblastoma), neuroblastoma

What is the imaging of choice to differentiate the two?

Abdominal CT

What is the surgical treatment of Wilms'?

- Radical nephroureterectomy, if unilateral, plus chemotherapy.
- If bilateral, do chemo first then nephron-sparing resection.

What is the prognosis?

Excellent. >90% cure even with metastatic disease.

Where can you find neuroblastoma?

Adrenals, sympathetic chain—posterior mediastinum, neck, pelvis. Neural crest origin.

In what age group does it present?

Peak incidence at age 2, 80% occur before age 4.

What is the goal of surgery?

Complete resection. Secondary goal is 95% resection with adjuvant chemotherapy.

What is the prognosis?

<30% long-term survival. Most present with advanced diseases.

Tumor with all three embryonic layers?

Teratoma

Mature, immature, and malignant classification is based on maturity of what type of tissue within teratomas?	Nervous
A newborn presents with a large mass extending from the sacrum.	
What is the diagnosis?	Sacrococcygeal teratoma—can be very large (the size of the baby).
What is the treatment?	Wide resection. Treat recurrence with platinum-based chemotherapy.
What are the two malignant liver tumors encountered in childhood?	1. Hepatoblastoma (most common) 2. Hepatocellular
In a child, what is the chance a liver tumor will be malignant?	50%
What is the marker associated with malignant liver tumors?	Alpha fetoprotein—greater in hepatoblastoma
The following are associated with hepatoblastoma, hepatocellular carcinoma, or both.	
Likely multifocal disease	Hepatocellular Ca
Peak incidence before 4 years	Hepatoblastoma
Peak incidence after 10 years	Hepatocellular Ca
Susceptible to chemotherapy	Hepatoblastoma
Painless abdominal mass	Both
Workup includes CT scan, liver biopsy	Both
Survival in 70%	Hepatoblastoma
Survival in 25%	Hepatocellular Ca

079_BOOKZ

CHAPTER 18

Vascular Surgery

What is the:	
First branch of the aorta?	Innominate (brachiocephalic) artery—branches into right subclavian and common carotid arteries
Second branch of the aorta?	Left common carotid artery
Third branch of the aorta?	Left subclavian artery
What is the most common cause of arterial stenosis?	Atherosclerosis
What are five risk factors?	1. Hypertension 2. Smoking 3. Obesity 4. Diabetes 5. Hyperlipidemia
Where do atherosclerotic plaques typically occur in the arteries?	Along arterial bifurcations, due to the stress of turbulent flow
Which four arteries are most commonly affected?	Carotid bifurcation, coronary, iliac, and arteries within the leg
What are the three types of atherosclerotic lesions?	1. Fatty streak: early in life, no affect on hemodynamics 2. Fibrous plaque 3. Complex plaque: ulcerated fibrous plaques that can develop calcium deposits **Note:** Typically the more calcified, the more stable/mature the plaque.
What are five signs/symptoms of atherosclerotic disease?	1. Angina pectoris 2. Postprandial (colicky) abdominal pain 3. Transient ischemic attack 4. Lower extremity claudication 5. Hypertension (hypoperfusion of renal arteries)

Copyright © 2008 by The McGraw-Hill Companies, Inc. Click here for terms of use.

079_BOOKZ

Why does an acute thrombosis of an artery due to plaque rupture require more emergent treatment?	Acute occlusions do not allow time for the development of collateral vessels to maintain distal perfusion.
What defines:	
A true aneurysm?	An aneurysm involving all three layers of the vessel (intima, media, and adventitia)
A false aneurysm?	Also known as pseudoaneurysm—covered only by a fibrous capsule
What are common causes for:	
A true aneurysm?	Atherosclerosis: connective tissue disease (CTD), medial degeneration (ie, Marfan's, atherosclerosis of vasa vasorum), fibromuscular dysplasia)
A false aneurysm?	Trauma, infection (mycotic aneurysm)
What are two types of true aneurysms?	1. Saccular 2. Fusiform
What is one type of false aneurysm?	Pseudoaneurysm **Note:** A "dissecting aneurysm" is a separate entity from aneurysmal disease, although it has similar risk factors and coexists
Where is the most common site of:	
A dissecting aneurysm?	Thoracic aorta
A traumatic aneurysm?	Femoral. Pseudoaneurysm from catheterization of the femoral artery.
A 70-year-old white male presents for routine physical exam when it is noted the patient has a pulsatile abdominal mass.	
What is the next step in diagnosis?	Abdominal ultrasound; however, computed tomography (CT) often used to evaluate size of abdominal aortic aneurysm (AAA) and possible involvement of renal and visceral vessels
At what size is a patient considered a surgical candidate (assuming there are no other comorbidities)?	At ≥5 cm in diameter, an AAA has a 15% annual risk of rupture, elective surgery has ~4% mortality risk.

079_BOOKZ

The abdominal aortic aneurism (AAA) is smaller than the size acceptable for surgical repair. How should this patient be monitored?	Ultrasound every 6–12 months
The patient develops flank pain. What must be ruled out?	Leakage from aneurysm and impending rupture—symptoms are nonspecific and require high index of suspicion (may mimic lumbar disc disease, hernia, diverticulitis, renal calculi, myocardial infarction (MI), pancreatitis, etc)—requires surgery regardless of size. Pain may also result from stretching of retroperitoneal tissues and is associated with ↑ risk of rupture.
Where is the most common site of an abdominal aortic aneurysm?	Inferior to renal arteries/superior to iliac arteries
What is the most common cause?	Degenerative changes, due to loss of elastin, ↑ metalloprotease activity. Often fusiform with areas of saccular outpouching (↑ risk of rupture).
What are two associated risk factors?	Smoking and family history. Aneurysms often occur along with atherosclerosis, although the development and progression cannot be explained completely from atherosclerosis.
How are most AAAs diagnosed?	As incidental findings from abdominal imaging. Often patients are asymptomatic.
Pre-op examination of a patient with AAA should include what two findings?	1. Femoral/distal pulses to evaluate for femoral aneurysms and monitor distal pulses before/after surgery. 2. Carotid bruits. High-grade stenosis will need to be addressed first as hypotension from AAA. Repair may lead to watershed infarcts.
What are two methods of aneurysm repair?	1. Traditional open repair: incise aneurysm, place graft, and suture aneurysm around graft. 2. Aortic endografting: involves endovascular placement of stents.

A patient undergoes elective repair of an AAA. Postop the patient develops abdominal pain and diarrhea, which tests guiac positive. What is the likely diagnosis?

Ischemic colitis

What is the next step in diagnosis?

Often involves the sigmoid colon. Diagnosis with sigmoidoscopy.

How should this be treated?

Resection of any necrotic colon, diverting colostomy and Hartmann pouch. If no areas of necrosis, then supportive treatment: BP support, antibiotics, and follow-up sigmoidoscopy.

Postop from an AAA repair a patient develops bowel/bladder incontinence, paraplegia, and loss of pain/temperature sensation. What is the likely cause of the symptoms?

Spinal cord ischemia. Artery of Adamkiewicz, which typically arises around T8–12. However, can arise in lower lumbar region.

What are three causes of immediate complications from surgical repair of an AAA?

1. Hypotension
2. Embolization
3. Ligation/clamping of artery

Note: In addition to the two cases above, patients may develop MI, acute renal failure, acute leg ischemia, or hemorrhage.

What are two long-term complications AAA repair?

1. Infection of graft
2. Pseudoaneurysm from infection, graft site, or along suture lines

Five years after a patient undergoes surgical repair of an AAA, he is admitted for hypotension requiring pressor support, fever, leukocytosis, abdominal pain, and gastrointestinal (GI) bleed. What must be ruled out given the patient's prior surgical history?

The patient is clearly in septic and possibly hemorrhagic shock.
The source of infection needs to be found. Given the prior history and GI bleed, one must suspect an aortoenteric fistula, from proximal aortic graft eroding the overlying duodenum. Rare, but >50% mortality rate.

What is the next step in diagnosis?

CT scan and endoscopy

What is the treatment?

Antibiotics and graft replacement, and possibly duodenal repair

What are the six P's of acute arterial thrombosis?

Embolization or clamp injury are common causes of post-op acute limb ischemia.
1. Pain
2. Pallor
3. Paralysis

079_BOOKZ

4. Paresthesia
5. Pulselessness
6. Poikilothermia (cold)

What is "blue toe" syndrome?

Distal atheroembolism from proximal disease or following revascularization procedures

What is the most common cause of acute arterial ischemia to the extremities?

Atrial thromboembolization, most commonly from atrial fibrillation. ~80% of emboli originate from left side of heart.

What are five other causes of acute arterial ischemia?

1. Ventricular thrombus (ie, following MI)
2. Valvular disease (rheumatic)
3. Paradoxical emboli (patent foramen ovale)
4. Proximal arterial disease
   - atherosclerosis (aortoiliac)
   - aneurysm
5. Hypercoagulable states (ie, disseminated intravascular coagulation [DIC], heparin-induced thrombocytopenia [HIT])

What are the four pulses that must be checked in the lower extremity in the evaluation of peripheral vascular disease?

1. Femoral
2. Popliteal
3. Dorsalis pedis (DP)
4. Posterior tibialis (PT)

What is the treatment for acute arterial ischemia from thromboembolism?

Anticoagulation (heparin), antiplatelet therapy (asprin), hydration (if profound ischemia to protect kidneys from myoglobinuria) and revascularization

What are three treatments used for revascularization?

1. Thrombolytic therapy
2. Embolectomy
3. Bypass

What are two complications associated with revascularization?

1. Myoglobinuria from tissue necrosis. This is nephrotoxic and treated with intravenous (IV) hydration and urine alkalinization. Diagnosed by heme on urine and absence of red blood cells.
2. Compartment syndrome. Reperfusion leads to swelling of tissue within confined space by the fascial layers causing compression of capillaries and neurological injury. Treatment is with fasciotomy.

079_BOOKZ

What is the major complication of popliteal aneurysms?

Like most peripheral aneurysms, the major complication is embolization leading to limb ischemia or cerebrovascular accident (CVA) in carotid aneurysms.

What are the two criteria for surgical repair on popliteal aneurysms?

>2 cm or evidence of thrombus formation or distal embolization

How are popliteal aneurysms surgically repaired?

With a bypass surgery using the saphenous vein

Note: There is high morbidity with surgical repair of a thrombosed artery since the popliteal artery often thromboses after showering multiple smaller emboli distally (~50% amputation rate).

A patient presents to the emergency department (ED) with acute onset, "tearing" chest pain. On exam, the patient is noted to have a blood pressure (BP) of 200/110 (left arm) and 175/100 (right arm), heart rate 100, and unequal pulses in the right/left arm. What is the likely diagnosis?

Aortic dissection (see Fig. 18-1)

How is the diagnosis confirmed?

CT *with* IV contrast. Angiogram is gold standard and allows for evaluation of aortic regurgitation.

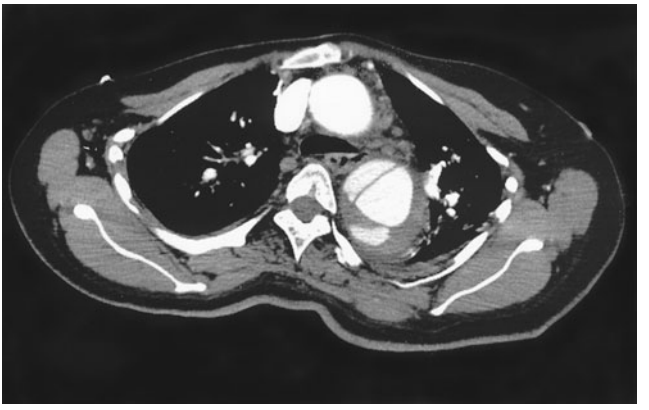

Figure 18-1 Typical appearance of a thoracic aortic dissection. [*Reproduced, with permission, from Brunicardi CF et al (eds): Schwartz's Principles of Surgery, 8th ed. New York: McGraw-Hill, 2005:706.*]

There are two classification schemes for aortic dissection (see Fig. 18-2)—define:	• Stanford classification = type A/B • DeBakey classification = Type I–III
Type A	Ascending—involves ascending aorta (Type I/II).
Type B	Involves descending aorta.
Type I	Involves ascending aorta, aortic arch, and descending aorta (Type A).
Type II	Involves ascending aorta (Type A).
Type III	Involves descending aorta (distal to left subclavian artery). Type III is further classified into: • IIIa: originates distal to left subclavian artery but extends proximally and distally • IIIb: originates distal to left subclavian artery but extends distally

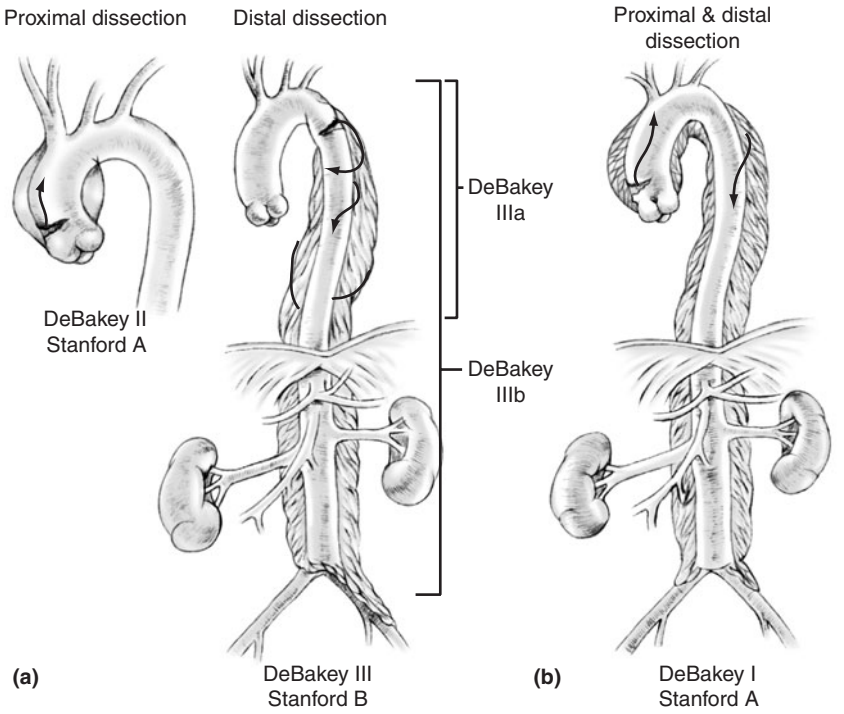

Figure 18-2 Classifications of thoracic aortic dissection.

What type of aortic dissections require emergent surgical intervention?	Type A, although some patients may benefit from medical management such as those with cerebrovascular accident (CVA), mesenteric ischemia, or substantial comorbidities.
Determine the likely cause of the following signs/symptoms involving Type A dissection:	
Dyspnea, diastolic murmur, rales, wide pulse pressure	Aortic valve insufficiency.
ST depression, chest pain, arrhythmia	Dissection involving coronary arteries. May develop MI (the sinoatrial (SA) node is most often supplied by the right coronary artery (RCA)—ischemia to this may lead to ectopic foci).
Jugular venous distention (JVD), hypotension, electrical alternans, low voltage electrocardiogram (ECG)	Pericardial tamponade. Also, muffled heart sounds, pulsus paradoxus.
Cold, painful extremity, weak pulses	Involvement of subclavian artery
Syncope, neurologic deficits	Involvement of carotid arteries
	Note: Ascending dissections are typically a surgical emergency due to the involvement of aortic valve, coronary arteries, and other aortic branches.
How are type B dissections medically treated?	Beta blocker first to control rate (60–80) then nitroprusside if needed to maintain BP 100–120 systolic (monitor for end-organ perfusion [ie, urine output, mental status] and watch for reflexive tachycardia)
What are the indications for surgical intervention of type B dissection?	• Visceral or renal malperfusion. Although recent advances in percutaneous interventions may allow for fenestration of the membrane of the false lumen to restore adequate perfusion. • Aortic rupture • Rapidly expanding aortic diameter • Uncontrolled hypertension • Persistent pain

079_BOOKZ

- Lower extremity ischemia. Dissection may involve the iliac vessels
- Acute dissection superimposed on pre-existing aneurysm

What three arteries are most commonly involved in peripheral vascular disease?

1. Iliac artery
2. Superficial femoral artery (most common site)
3. Tibial artery

Note: Profunda femoral and popliteal arteries can also be affected.

What is the most common symptom of peripheral vascular disease (PVD)?

Leg claudication occurring with activity and relief with rest

Note: Blood often supplied by collateral arteries with rest; however, metabolic demands exceed collateral supply with exertion.

At what percentage of stenosis is blood flow affected?

Approximately 50% reduction in diameter. Below this the artery is able to compensate by expanding total diameter with the plaque to maintain lumen diameter.

What muscle group is typically affected first by peripheral vascular disease?

Typically calf pain (gastrocnemius muscle) as this is supplied by superficial femoral artery. Pain occurs distally to occlusion.

What are the four signs/symptoms of Leriche's syndrome?

1. Lower extremity claudication
2. Muscle wasting of buttocks
3. Impotence
4. Absent femoral pulses

Where is the site of occlusion?

Aortoiliac occlusion

A patient complains of toe pain at night, awakening from sleep. Pain is relieved by hanging the feet over the bed. What is the likely diagnosis?

Ischemic rest pain associated with significant PVD, similar to unstable angina. Rest pain typically localized to distal foot arch as opposed to cramping involving the calf.

Note: Rest pain requires revascularization (~85% will suffer amputation at 5 years if left untreated).

Determine if the following ulcers refer to venous or arterial causes.	
Ulcers associated with pressure points (dorsum foot/toe)	Arterial
Hairlessness	Arterial
Moist granulating base, often large	Venous
Oozes blood when manipulated	Venous
Located around malleoli (medial/lateral)	Venous
Pale skin	Arterial
Surrounding darkening of skin	Venous (hemosiderin deposition)
Pain when supine, relieved with dependency	Arterial
Mild pain relieved by elevation	Venous
Unhealthy granulation tissue, little/no bleeding with manipulation	Arterial
Shallow	Venous
Punched out appearance	Arterial
Associated with edema	Venous
Tissue necrosis associated with severe PVD is referred to as what?	Gangrene
Necrosis associated with purulent discharge or surrounding cellulitis is referred to as what?	Wet gangrene
How is the ankle-brachial index (ABI) measured?	Systolic ankle pressure divided by systolic arm pressure. Systolic ankle pressure determined with Doppler.
Determine the significance of the following ABI values.	
0.9	Normal
0.5	Severe peripheral artery occlusive disease (PAOD) (<0.4 usually consistent with tissue loss)
1.3 or greater	Severe PVD, from noncompliance of calcified arteries
What are three surgical indications for revascularization?	Conditions that are limb-threatening 1. Ischemic rest pain 2. Tissue loss/gangrene 3. Debilitating claudication

079_BOOKZ

What is the first line of management for non-limb-threatening claudication?

Medical management
- Controlling risk factors
- Smoking cessation
- Control diabetes mellitus (DM)
- HTN
- Hyperlipidemia
- Exercise program

Note: Pentoxifylline may be attempted, though of uncertain benefit (↓ blood viscosity via ↑ fibrinogen and platelet aggregation).

What are three procedures used for revascularization?

1. Angioplasty w/wo stent placement. Useful for focal lesions.
2. Endarterectomy. Useful for focal lesions, ie, carotid bifurcation.
3. Bypass. Useful for diffuse disease, ie, lower extremities.

What layers of the vessel are excised in endarterectomy?

Plaque, endothelium, and portion of the media

What are the five indications for amputation of extremity?

1. Contraindications to revascularization surgery
   - Comorbidities
   - No suitable vessel for bypass
   - Extensive gangrene
2. Intractable rest pain
3. Infection/gangrene
4. Trauma with severe nerve/vascular injury
5. Neoplasm

Note: Almost all amputations due to vascular disease is a result of arterial disease, rarely needed for venous disease alone.

A 72-year-old male with a history of MI presents with cramping abdominal pain approximately 1–2 hours after eating and has noticed weight loss. He now has "food fear." What is the likely diagnosis?

Chronic mesenteric ischemia—associated with postprandial abdominal pain, fear of food, and weight loss

What are two treatment options?

Endarterectomy or mesenteric bypass

What must be ruled out?

Malignancy

A 30-year-old female presents with hypertension refractory to medical management with diastolic BP >110. On physical exam, an abdominal bruit is heard. What is the likely diagnosis?

Renal artery stenosis (RAS). Cause of HTN ~5% and most common surgical cause of HTN.

What are the two most common causes?

Atherosclerosis (typically older patients, usually from aortic lesions extending into proximal renal artery) and fibromuscular dysplasia (typically younger females, usually mid to distal artery involvement).

What are four other surgical causes of hypertension?

- Pheochromocytoma
- Cushing's syndrome
- Primary aldosteronism (Conn's syndrome)
- Coarctation of the aorta

What are three tests to diagnose the cause of the hypertension?

- Renal duplex: evaluate renal artery: aorta flow velocities (>3.5 suggests RAS), also allows evaluation of atrophy in the kidneys or presence of solitary kidney.
- Captopril renal scan: positive test if serum renin ↑, also can evaluate renal vein renin ratio, though will be nondiagnostic if bilateral RAS.
- Renal arteriography (gold standard). Can use carbon dioxide to avoid nephrotoxic iodine. CT angiography (CTA) and magnetic resonance angiography (MRA) also used.

What is the first line of therapy in renal artery stenosis (RAS)?

Angiotensin converting enzyme (ACE)-inhibitors or angiotensin receptor blockers (ARBs) if unilateral and renal function not impaired.

What is the recommended treatment for refractory HTN?

Angioplasty with stent placement if atherosclerotic etiology. Endarterectomy and bypass can also be performed, usually with multiple lesions.

079_BOOKZ

When is surgery or angioplasty indicated?	Patients must have anatomic lesion and functional significance, positive captopril scan and significant lesion on angiography or duplex.
A patient with a history of scleroderma presents with bilateral numbness and pallor associated with cold temperatures. What is the likely diagnosis?	Raynaud's phenomenon—a vasospastic disease associated with initial pallor due to vasospasm, then, cyanosis due to the reduced blood flow, and finally rubor as the vessels dilate and cause reactive hyperemia
What is the difference between the disease and the phenomenon?	Raynaud's phenomenon occurs secondary to collagen vascular diseases whereas Raynaud's disease has no association with any systemic disease.
What is the recommended treatment?	For either syndrome—avoidance of medication that may cause vasospasm or reduced cardiac output (oral contraceptives, beta blockers); calcium channel blockers may offer relief.

This page intentionally left blank

CHAPTER 19

Cardiothoracic Surgery

THORACIC

What is the most common chest-wall deformity?	Pectus excavatum (depressed sternum)—surgery indicated for moderate to severe deformities. Mainly cosmetic, but severe deformities may depress pulmonary function.
The mediastinum is divided into four compartments. Determine the contents of each compartment:	The mediastinum comprises the space between the lung fields.
Anterior	Thymus gland, internal mammary artery/vein, lymph nodes
Middle	Pericardium, ascending aorta, superior/inferior vena cava, brachiocephalic artery/vein, trachea, main bronchi with lymph nodes, phrenic nerves, vagus nerve trunks
Posterior	Descending aorta, esophagus, thoracic duct, azygos/hemiazygos veins, lymph nodes
Superior	Aortic arch, brachiocephalic/left common carotid/left subclavian arteries, innominate vein/superior vena cava, thoracic duct, trachea, esophagus, lymph nodes
What is the differential for anterior mediastinal masses?	**"4 T's"** 1. **T**eratoma 2. **T**hymomas 3. **T**hyroid tumor/goiter 4. **T**errible lymphoma

Copyright © 2008 by The McGraw-Hill Companies, Inc. Click here for terms of use.

079_BOOKZ

What is the differential for middle mediastinal masses?	Think **"HABIT"** • **H**ernia/**H**ematoma • **A**neurysm • **B**ronchogenic cyst/duplication cyst • **I**nflammation (sarcoid, histoplasmosis, primary tuberculosis [TB]) • **T**umors = think **"5 L's"** 1. **L**ymph node hyperplasia 2. **L**eiomyoma 3. **L**eukemia 4. **L**ymphoma 5. **L**ung (especially oat cell carcinoma)
What is the differential for posterior mediastinal masses?	Think **neurogenic** causes: • Neuro—fibromas, sarcomas, blastomas • Ganglioneuromas • Pheochromocytomas
A patient with a known history of thymoma presents with progressive weakness, ptosis, diplopia, and difficulty chewing. What is the likely diagnosis?	Myasthenia gravis—a paraneoplastic syndrome known to occur with thymomas
What is the surgical treatment of myasthenia gravis (MG)?	Thymectomy—will improve symptoms in majority of MG patients in presence or absence of thymoma
Determine which lobes of the lung each fissure separates:	
Oblique fissure	Left upper and lower lobe
Major (oblique) fissure	Right lower lobe from upper and middle lobes
Minor (horizontal) fissure	Right upper lobe, middle lobe
The lingula is part of what lobe?	Left upper lobe
Site of main stem bronchi from the trachea is referred to as what?	Carina
A patient requiring prolonged intubation is extubated and quickly develops stridor and dyspnea. What is the likely diagnosis?	Tracheal stenosis—symptoms may occur immediately or may take up to 2 years to present. Typically from pressures caused by overinflated endotracheal tube balloon causing necrosis and scarring.
What is the treatment?	First secure the airway. Then laser ablation or dilatation can be done as

	a temporary measure. Definitive treatment requires resection.
What other condition may mimic the above diagnosis?	Tracheal neoplasm (squamous cell carcinoma from smoking most common); however, may also present with hemoptysis.
Determine the diagnosis for a patient that is postop week 1 for tracheostomy and develops:	
Brief episode of bright red blood from tracheostomy followed by catastrophic bleed the following day	Tracheoinnominate artery fistula
Gastric contents and tube feeds suctioning from airway	Tracheoesophageal fistula
A 50-year-old patient with a history of smoking presents to the emergency room (ER) and is found to have a solitary pulmonary nodule less than 3 cm. What is the likelihood of this lesion being malignant (see Fig. 19-1)?	~50% (20–40% for nonsmokers)
What are the two most common causes of benign nodules?	Infectious granulomas (~80%) and hamartomas (~10%)
What is the next step in diagnosis?	Chest thin-section CT (evaluate location, size, morphology, calcification)
"Popcorn" appearing calcifications suggest what?	Hamartoma—granulomas typically display diffuse, solid, or central calcifications
A lesion with stippled, eccentric, or amorphous calcifications suggest what?	Malignancy
A computed tomography (CT) is performed on the patient and is indeterminate. What is the next step in diagnosis?	Follow-up with CT to measure possible growth of lesion anywhere from 3 months to 1 year depending on size of tumor and risk factors (age, smoking/environmental exposures, family history, etc)
The patient undergoes repeat CT and is shown to have interval growth of lesion. What is the next step in diagnosis?	Biopsy—if there is an effusion, a thoracentesis may be done for cytology • Transthoracic fine-needle aspiration (if peripheral lesion) • Transbronchial biopsy (if central lesion)

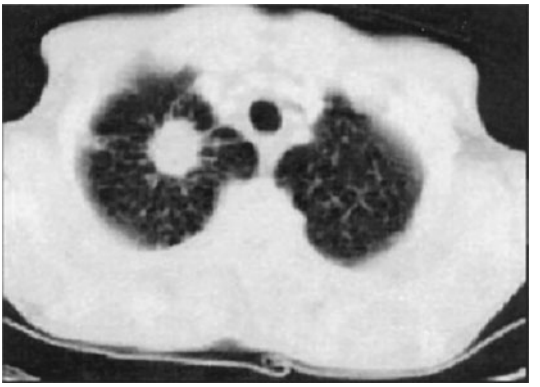

(a)

(b)

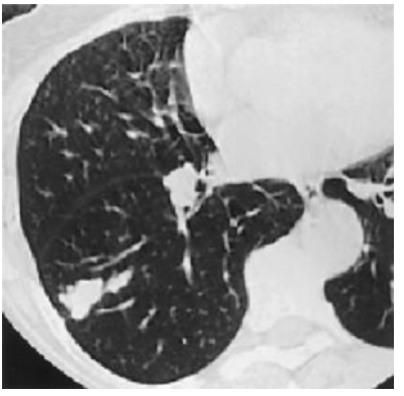

(c)

Figure 19-1 Typical radiographic appearance of malignant lung masses. A: Corona radiata are projections like spokes of a wheel in a malignant appearing mass. B: Large spiculated mass concerning for malignancy. C: Mass with a scalloped border, an intermediate radiographic finding for malignancy. [*Reproduced, with permission, from Brunicardi CF et al (eds): Schwartz's Principles of Surgery, 8th ed. New York: McGraw-Hill, 2005:556.*]

	• Thoracotomy or video-assisted thoracic surgery (VATS) resection if biopsy results are indeterminate or unable to biopsy due to location. Await frozen section, perform lobectomy if cancer, even with clear margins.
What are the three stages of parapneumonic effusions?	1. Uncomplicated: predominately neutrophil effusion associated with pneumonia 2. Complicated: ↑ pleural fluid neutrophils and lactase dehydrogenase (LDH), pleural fluid acidosis, often sterile 3. Empyema: contains purulent material, cultures may be negative but organisms seen on Gram stain
Determine if the following refers to a transudative or exudative effusion:	
Pleural:serum protein <0.5	Transudate
Pleural:serum LDH >0.6	Exudate
Associated with congestive heart failure (CHF), cirrhosis, and nephrotic syndrome	Transudate
Associated with infection, pulmonary infarction, malignancy, or inflammation (chronic transplant dysfunction [CTD], pancreatitis)	Exudate (however, CHF can lead to both an exudate and transudate.) **Note:** Typically, conditions that lead to damage to capillary membranes will cause an exudative effusion.
A patient undergoes a thoracentesis and is diagnosed with an exudative effusion. What additional lab test needs to be performed on the sample?	Cell count and cytology to evaluate for malignancy
A patient undergoes thoracentesis for which a milky fluid is removed. Triglycerides are measured as 115 mg/dL. What is the likely diagnosis?	Chylothorax—a triglyceride level >110 mg/dL has 99% likelihood of fluid being chyle. Triglycerides 50–110 mg/dL need lipoprotein analysis to inspect for chylomicrons or cholesterol crystals for diagnosis.
What are the two most common causes for this condition?	Malignancy (especially lymphoma) and trauma involving the thoracic duct (including iatrogenic [surgery], sarcoidosis, TB, cirrhosis, amyloidosis)

079_BOOKZ

What is the treatment of choice?	Conservative management ~50% heal spontaneously: for trauma/iatrogenic causes may use somatostatin or octreotide and for malignant chylothorax chemoradiation can be used. Low fat diet or total parenteral nutrition (TPN) to decrease flow.
What are four indications for surgery?	Indications for thoracic duct ligation or pleurodesis include: • Postesophagectomy chylothorax (associated with high mortality) • Chyle leak >1L/day for 5 days or leak for 2 weeks • Metabolic complications (ie, electrolyte abnormalities) • Loculated chylothorax
What are the three most common causes of cancer-related deaths in:	
Men?	Lung, prostate, colon/rectum
Women?	Lung, breast, colon/rectum
What is the staging system used for:	
Nonsmall-cell carcinoma?	Tumor, node, metastasis (TNM)
Small-cell carcinoma?	Local vs distant disease
What are four types of nonsmall-cell lung carcinoma?	1. Squamous cell carcinoma (SCC) 2. Adenocarcinoma 3. Bronchoalveolar carcinoma (adenocarcinoma subtype) 4. Large-cell carcinoma
Determine the type of nonsmall-cell lung carcinoma:	
Most associated with cigarette smoking	Squamous cell carcinoma (SCC)
Primarily peripherally located	Adenocarcinoma and large-cell carcinoma (although a significant amount are central)
Presents as a lobar pneumonia with air bronchograms	Bronchoalveolar carcinoma (tumor grows within alveoli, spreading aerogenously)
Associated with lung scaring	Adenocarcinoma
Primarily centrally located	SCC (and small cell carcinoma)

079_BOOKZ

Associated with malignant pleural effusion	Adenocarcinoma—peripheral location most often causes malignant pleural effusion, though often diagnosed incidentally.
Presents with hemoptysis, wheezing, dyspnea, pneumonia	SCC—central location causes hemoptysis and occludes bronchi leading to pneumonia.
Most common primary lung carcinoma	Adenocarcinoma
Match the following paraneoplastic syndromes with the commonly associated lung cancers.	
Libman-Sacks endocarditis	Adenocarcinoma
Syndrome of inappropriate secretion of antidiuretic hormone (SIADH)	Small cell carcinoma
Cushing's syndrome	Small cell carcinoma
Hypercalcemia	Squamous cell carcinoma
Lambert-Eaton syndrome	Small cell carcinoma (if a patient is diagnosed with LES then a workup for lung cancer is indicated, including positron emission tomography [PET] scan)
Gynecomastia	Large cell carcinoma
Thrombophlebitis	Adenocarcinoma
A patient with lung cancer develops pain localized to the shoulder that eventually progresses to involve the small and ring fingers and eventually the patient develops an ipsilateral Horner's syndrome. What is the likely diagnosis?	Pancoast's tumor invading the cervical nerve roots (C8) and sympathetic chain
What is the triad associated with Horner's syndrome?	1. Anhidrosis 2. Ptosis 3. Meiosis
What are the potential complications of lung cancer?	Think **"sphere"** • **S**uperior vena cava (SVC) syndrome • **P**ancoast's tumor • **H**orner syndrome • **E**ndocrine (paraneoplastic)

079_BOOKZ

	• **R**ecurrent laryngeal nerve symptoms • **E**ffusions (pericardial/pleural) **Note:** These are in addition to other complications associated with malignancies (ie, anemia, disseminated intravascular coagulation (DIC), pulmonary embolus (PE), postobstructive pneumonia, etc)
What is the recommended treatment for:	
Nonsmall-cell lung carcinoma?	Depending on the stage and patient comorbidities (ie, pulmonary reserve) surgical resection (lobectomy if tolerated otherwise wedge resection) and adjuvant therapy (chemo and/or radiation)—preop (induction) chemotherapy may also be used.
Small-cell lung carcinoma?	If local, then resection with chemotherapy. However, often metastasized at diagnosis and chemoradiation is the treatment of choice (extremely sensitive).
What is the most common arrhythmia following thoracic surgery?	Atrial fibrillation
What medical therapy reduces risk?	Perioperative beta blockade
A 70-year-old male, who previously worked as a ship builder, presents with worsening dyspnea and nonpleuritic chest pain and recent weight loss. Chest x-ray (CXR) shows parietal thickening and small effusions. What is the likely diagnosis?	Malignant mesothelioma
What exposure is responsible for the development of the patient's diagnosis?	Asbestos
What other occupations are associated with this exposure?	Mechanics, construction, ceramics, railroad workers, and paper mill
Combination with what other exposure greatly increases the risk of developing this diagnosis?	Smoking (although alone, it is not associated with mesothelioma)
What is often required to establish the diagnosis?	Thoracoscopically guided biopsy (cytology of thoracentesis diagnostic ~30%)

079_BOOKZ

What is the recommended treatment?

Associated with very poor prognosis; however, triple therapy often gives best prognosis/palliation
- Chemotherapy: cisplatin (alone or in combination)
- Radiation
- Surgery: pleurectomy, talc sclerosis

What are the two types of pleurodesis?

Chemical and mechanical

Which one is used only with malignant effusions?

Chemical. Since it produces such significant scarring, reoperation in that field is dangerous.

A patient recovering from a stroke begins to develop dyspnea, productive cough, and fever. A chest x-ray is obtained (see Fig. 19-2). What is the likely diagnosis?

Aspiration pneumonia leading to abscess formation. (Aspiration may be secondary to anesthesia, drugs, or alcohol.)

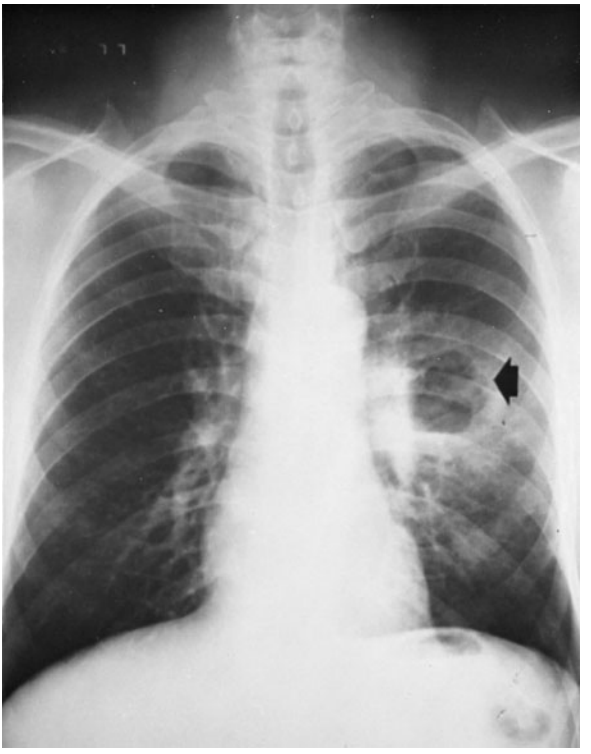

Figure 19-2 Lung abscess. [*Reproduced, with permission, from Brunicardi CF et al (eds): Schwartz's Principles of Surgery, 8th ed. New York: McGraw-Hill, 2005:574.*]

What lobes are most commonly involved?	Right upper lobe (posterior segment) and lower lobe (superior segment) presumably due to less acute angle of right main bronchus
What are the common bacteria found in community-acquired infections?	Streptococci and anaerobes
What are the common bacteria found in hospital-acquired infections?	*Staphylococcus aureus* and aerobic gram-negative bacilli *(Haemophilus influenzae, Pseudomonas aeruginosa, Klebsiella pneumoniae, Proteus* sp, *Escherichia coli)*
If this patient has a history of renal transplant what other organism must be considered?	Fungi (ie, histoplasmosis, *Cryptococcus, Aspergillus*—most common after bone marrow transplant but any immunocompromised patient is predisposed (human immunodeficiency virus [HIV], chemotherapy, transplant)
What diagnosis must be ruled out?	Cavitating lung carcinoma (often via CT or bronchoscopy)
What is the treatment of choice?	Antibiotics: penicillin (piperacillin or ticarcillin), clindamycin—drainage typically occurs via tracheobronchial tree
What are five indications for surgical intervention?	Indications include: • Failure of medical management • Hemorrhage/hemoptysis • Abscess >6 cm • Abscess rupture with empyema • Inability to exclude cavitating carcinoma
What are two surgical options?	Tube thoracostomy/percutaneous drainage or lobectomy (preferred for hemorrhage or pyopneumothorax)
A patient with recurrent pulmonary infections develops dyspnea and productive cough of yellow/green sputum. High-resolution chest CT shows areas dilatation of the airways and honeycombing. What is the likely diagnosis?	Bronchiectasis—dilated airways typically filled with thick purulent material and associated with bronchial artery hypertrophy and anastomoses with pulmonary artery circulation

079_BOOKZ

What are the common causes?

Causes divided into:
- Infection: viral/bacterial pneumonia, mycobacterium, impaired immunity (Kartagener's syndrome, cystic fibrosis (CF), immunoglobulin deficiency [ie, IgA/IgG])
- Inflammation: alpha-1 antitrypsin deficiency, Sjögren's syndrome
- Obstruction: foreign body, tumor

What bacteria commonly colonize these patients?

H. influenzae, *Streptococcus pneumoniae*, *P. aeruginosa*, and nontuberculous mycobacteria

How may one assess the severity of disease?

Spirometry (amount of sputum production also correlates to severity)

What is the treatment of choice?

↑ secretion clearance with chest physiotherapy (percussion, vibration, and postural drainage) and bronchodilators

What are two surgical indications?

Symptoms not responding to medical treatment and large hemoptysis (via hypertrophied bronchial arteries)—surgery involves local resection

CARDIAC

What are two types of prosthetic valves and what are the advantages of each?

1. Mechanical (St. Jude most common [bileaflet]): long durability, ↑ thromboembolic risk
2. Bioprosthesis (primarily porcine xenografts): less durable (~30% failure rate at 10 years), less thrombogenic

A patient presents with worsening dyspnea on exertion, weakness, and palpitations. Physical exam reveals bounding pulses, widened pulse pressure, displaced point of maximal impulse (PMI), S3 gallop, and high-pitched decrescendo diastolic murmur best heard at left third intercostal space. What is the likely diagnosis?

Aortic insufficiency

079_BOOKZ

What are common causes?	Myxomatous degeneration, endocarditis, aortic dissection, rheumatic fever, annuloaortic ectasia
A mid-diastolic, low-pitched rumbling murmur which is best heard at the cardiac apex associated with the above diagnosis is referred to as what?	Austin Flint murmur—caused by the aortic insufficiency impeding the opening of the mitral valve during diastole
What are the surgical indications?	Any symptomatic patient should be considered for surgery, even patients with low ejection fraction (EF) **Note:** Also, patients with depressed LV function are at high risk of sudden cardiac death due to arrhythmias and may benefit from automatic implantable converter-defibrillator (AICD) placement.
A patient presents with worsening dyspnea on exertion. Physical exam reveals an ↑ S_1, followed by S_2 and an opening snap, and diastolic rumble best heard over apex. ECG reveals biphasic P wave in V_1. What is the likely diagnosis?	Mitral valve stenosis—most common symptom is dyspnea and may develop into pulmonary hypertension (HTN) and right heart failure. ECG shows LA enlargement, and physical exam revealed the classic auscultatory findings.
What is the next step in diagnosis?	Echocardiogram
What is the most common cause of this diagnosis?	Rheumatic fever (causing pancarditis and valvulitis leading to fibrosis)
What are four complications if left untreated?	Complications include: • Infection • Worsening heart failure • Embolism • Arrhythmias (ie, atrial fibrillation)
What are the surgical indications?	Moderate (valve area <1.5 cm^2)/severe (valve area <1.0 cm^2) stenosis, development of pulmonary hypertension or embolic events
What are the three surgical options?	Valvuloplasty, commissurotomy, or mitral valve replacement

A patient presents with syncope, angina, and exertional dyspnea. Physical exam reveals an S_4 gallop and low-pitched, crescendo-decrescendo systolic murmur best heard at the right second intercostal space with radiation to the carotid artery. What is the likely diagnosis?	Aortic stenosis (Remember, the acronym "**SAD**": **S**yncope, **A**ngina, **D**yspnea)—any patient who presents with syncope needs a cardiac workup
What are the three most common causes?	Three most common causes are: • Acquired calcific disease (typically in seventh or eighth decade)—most common cause • Biscuspid aortic valve (typically presents in fourth or fifth decade) • Rheumatic heart disease
What is the next step in diagnosis?	Echocardiogram—if patients have a history of CAD or are >55 years of age, then they should also have a coronary angiogram.
What is the treatment of choice for symptomatic patients?	Aortic valve replacement for nearly all symptomatic patients
A patient is found to have the above diagnosis. However, remains asymptomatic. How is this patient treated?	Periodic echocardiogram and surgery if: • Echocardiogram reveals ↑ LV end-diastolic volume, ↓ EF, progressive ↑ transvalvular gradient, valve area <0.8 cm^2, pulmonary HTN, or RV dysfunction with exercise
A patient presents with progressive dyspnea on exertion and orthopnea. Physical exam reveals a holosystolic blowing murmur best heard at the apex with radiation to the axilla. What is the likely diagnosis?	Mitral insufficiency
What is the most common cause?	Myxomatous degeneration (other causes include rheumatic fever, ischemic disease, endocarditis, cardiomyopathy.)
What is the next step in diagnosis?	Echocardiogram
What are the surgical indications?	Surgery is recommended for: • Any symptomatic patients • Asymptomatic patient with LV systolic dysfunction (↑ LV-end diastolic volume, ↓ EF) **Note:** Surgery recommended before patients develop symptoms.

An intravenous (IV) drug user presents with fever, worsening pedal edema, jugular venous distension (JVD), hepatomegaly, and new onset systolic murmur best heard at the lower end of the sternum. What is the likely diagnosis?	Tricuspid insufficiency
What is the next step in diagnosis?	Echocardiogram—preferably transesophageal to evaluate for vegetations as this patient is at high risk for bacterial endocarditis
What is the medical management of this patient?	Antibiotics (coverage for streptococci, staphylococci, and enterococci) and cardiac monitoring (for conduction abnormalities, possibly from abscess eroding into conduction pathways)
What are the surgical indications?	Typically, surgery delayed until fever resolves and cultures are negative (to reduce the risk of seeding the prosthetic valve); however, conduction abnormalities and severe insufficiency (ie, leaflet rupture) indicate emergent surgery
What is the underlying etiology of coronary artery disease?	Atherosclerosis
What are the risk factors?	Family history, hyperlipidemia, smoking, diabetes, HTN, obesity, sedentary lifestyle
What are the ECG manifestations of the following?	
Myocardial ischemia	ST segment depression
Myocardial injury	ST elevation
Myocardial infarction	Q wave
What are the emergency revascularization options in acute MI?	1. Percutaneous coronary intervention (PCI), ie, balloon angioplasty ± stent 2. Thrombolytic therapy
What is *not* an emergency revascularization option?	CABG (coronary artery bypass graft)

079_BOOKZ

What are the three surgical complications of acute MI that develop 4–5 days after initial infarct?

1. Ventricular septal defect (VSD): CHF and pulmonary edema are manifestations. New onset holosystolic murmur. Diagnose with ECHO. Treat first with intraaortic balloon pump then surgical repair. Mortality 10–20%.
2. Papillary muscle rupture: same presentation as VSD. Diagnose with ECHO. Emergent surgical repair. Mortality 10–20%.
3. Left ventricular free wall rupture: cardiogenic shock and cardiac tamponade. Emergent surgical repair. Mortality >50%.

What are the indications for CABG?

Chronic angina, unstable angina, postinfarction angina, asymptomatic patients with reversible ischemia on stress test

What anatomic lesions favor CABG over PCI?

- Left main disease
- Proximal LAD
- Three vessel disease

What are the functional studies used to assess myocardial viability after myocardial infarction (MI)?

PET, thallium scan, magnetic resonance imaging (MRI) viability scan

Why is it necessary to assess viability when deciding on CABG?

If patient has nonviable myocardium, it is not a candidate for CABG.

What conduit should always be used for left anterior descending (LAD) artery revascularization?

Internal mammary artery

What are the other conduit options?

Saphenous vein graft, radial artery, gastroepiploic artery, inferior epigastric artery

What is the risk of using both internal mammary arteries as conduits?

Sternal necrosis

This page intentionally left blank

CHAPTER 20

Transplant

Define the following:	
Autograft	Transfer within the same individual (skin graft)
Isograft	Transfer between genetically identical individuals (identical twins)
Allograft	Transfer between genetically nonidentical individuals of same species
Xenograft	Transfer between different species
Orthotopic graft	Placement of organ in normal anatomic position (cardiac or liver transplant)
Heterotopic graft	Placement of organ in nonanatomic position
Kidney transplants are typically what type of grafts?	Heterotopic allografts
What two types of grafts require immunosuppression?	Allograft and xenograft
When is this not needed?	Corneal transplant (immune-privileged site)
What organ is associated with the highest incidence of rejection?	Small intestine because it has the highest concentration of immunocompetent cells. There is also no good accurate serum test to monitor for rejection.

Copyright © 2008 by The McGraw-Hill Companies, Inc. Click here for terms of use.

079_BOOKZ

Determine whether the following refer to hyperacute, accelerated acute, acute, and/or chronic rejection:	
Mediated by helper T-cells	Acute (mostly cell mediated)
Occurs within the first few days of transplantation	Accelerated acute
Mediated by preformed antibodies (HLA or ABO)	Hyperacute
Graft infarction within 24 hours of transplant	Hyperacute (antibodies attack endothelium which results in thrombi)
Cell mediated and humoral involvement of immune system	Accelerated acute (presensitized by previous exposure to antigens) and chronic
Biopsy shows fibrosis, atrophy, and arteriosclerosis	Chronic
Associated with fever, chills, malaise, and arthralgias	Acute
Avoidable	Hyperacute (crossmatch detects antibodies against ABO or HLA antigens)
Treatable	Acute (~80% is reversible)
Occurs within minutes of reperfusion	Hyperacute
Occurs within first week to months following transplant	Acute
Biopsy demonstrates cellular infiltrate and apoptosis	Acute

What conditions are contraindications for organ/tissue donation?	• Malignancy (except primary brain tumors and small hepatocellular carcinoma)
	• Most chronic medical problems may exclude organ specific transplantation
	  • Heart: severe hypertension (HTN), trauma, coronary artery disease (CAD), advanced age
	  • Lung: trauma, respiratory compromise, pneumonia
	  • Pancreas: diabetes mellitus (DM)
	  • Kidney: severe peripheral vascular disease (PVD), untreated HTN

079_BOOKZ

	• Uncontrolled infection • HCV/HBV/HIV (hepatitis C virus/hepatitis B virus/human immunodeficiency virus) usually avoided • Cardiac arrest resulting in prolonged warm ischemia of organs • Extensive high-risk drug history
Determine the mechanism/effect of action for the following immunosuppressive drugs:	
Corticosteroids	Inhibit leukocytes via ↓ interleukin-1 (IL-1) and interleukin-6 (IL-6) production, lympholysis
OKT3 (monoclonal antibody)	Antibody against pan T-cell receptor CD3—leads to T-cell depletion (OKT**3** = CD**3**)
Mycophenolate mofetil	Inhibit clonal proliferation of T-cells via inhibition of inosine monophosphate dehydrogenase
Cyclosporine	Inhibit T-cell function via inhibiting production of IL-2
Tacrolimus (FK-506)	Inhibit helper T-cell via inhibiting IL-2 production (100× more potent than cyclosporine)
Azathioprine (AZA)	Inhibit clonal proliferation of T-cells via inhibition of nucleic acid synthesis
Antithymocyte globulins	Polyclonal sera to lymphocytes and thymocytes—leads to T-cell depletion
Which medications are used for:	
Maintenance (name five medications)?	Corticosteroids, cyclosporine/tacrolimus, mycophenolate mofetil/azathioprine (AZA)
Antirejection (name two medications)?	Corticosteroids, thymoglobulin
What medication is used to treat acute, severe rejections resistant to steroids?	Thymoglobulin
What two conditions are immunosuppressed patients at increased risk of developing?	1. Infections with opportunistic organisms 2. Malignancy (especially skin, lymphoproliferative, and cervical)

079_BOOKZ

A patient presents with worsening oliguria, fever, and increasing creatinine after the first week of a renal transplant. Ultrasound shows enlarged, hypoechogenic kidney with normal size collecting ducts. What is the likely diagnosis?

Acute rejection (may also have proteinuria)

How is this treated?

Glucocorticoids (antithymocyte globulin if resistant)

What other conditions need to be considered?

Also consider infections, hypovolemia, vascular, urologic, and lymphatic complications:

- Infections: wound, urinary tract infection (UTI), contaminated catheter, pneumonia, viral (hepatitis, cytomegalovirus [CMV], HIV)
- Vascular: renal artery or vein thrombosis, renal artery stenosis
- Urologic: ureteral obstruction/leakage/stenosis, or bladder complications
- Lymphatic: lymphoceles (a perinephric lymph collection that results in mass effect and causes vascular compression)

Note: Any change in renal function following kidney transplant warrants an ultrasound to assess vasculature, collecting ducts, perinephric fluid, and bladder complications.

KIDNEY TRANSPLANTATION

Why is the left kidney preferred for transplantation?

Longer renal vein

In a typical kidney transplant:

Where is the kidney placed?

Extraperitoneal iliac fossa—allows easy access for biopsy (variations exist in pediatrics)

What vessels are the renal artery and vein attached to?

External iliac artery and vein

Where is the ureter attached?

Bladder, although ureter-to-ureter anastomosis can be done

How is vesicoureteral reflux avoided?

By creating a tension-free 1 cm submucosal tunnel of the ureter into the bladder

079_BOOKZ

What is the easiest way to assess kidney graft functioning?

Urine output and serum creatinine

What is the expected urine output following a kidney transplant?

Depends on fluid status pre-op and intra-op. Typically transplanted kidneys undergo a brisk diuresis in which volume status and electrolytes must be monitored.

Why is liberal intraoperative hydration necessary during a renal transplant?

To avoid acute tubular necrosis (ATN), keep central venous pressure [CVP] ~10 mm Hg and systolic BP >120 mm Hg.

What is the most common cause of gradually decreased urine output following a kidney transplant?

Volume status. Other causes include: clogged Foley (debris, clamped), rejection, urinary leak.

Following a kidney transplant a patient, who was noted to have adequate urine output, suddenly developed anuria. What is the likely diagnosis?

Renal artery thrombosis

How is this diagnosed?

Graft ultrasound exam

How is this treated?

Open exploration and thrombectomy

Note: Predisposing factors include: hypotension, rejection, damage to artery, hypercoagulable state.

LIVER TRANSPLANTATION

What are four signs/symptoms that indicate end-stage liver failure?

- Ascites refractory to diuretic control, associated with spontaneous bacterial peritonitis (SBP) and hydrothorax from pleural leaks
- Encephalopathy, often associated with progressive jaundice
- Recurrent variceal hemorrhage, often associated with coagulopathy
- Severe fatigue

What is the most common indication for liver transplant in:

Children?

Biliary atresia

Adults?

Cirrhosis from chronic HCV

Note: Other indications for liver transplant include:
- Hepatitis B virus (HBV)
- Alcoholic cirrhosis
- Primary biliary cirrhosis

- Sclerosing cholangitis
- Autoimmune hepatitis
- Wilson's disease
- α_1-Antitrypsin deficiency
- Budd-Chiari syndrome
- Hemochromatosis

Why are hepatic arterial anastomoses crucial to post-op graft survival?

Bile ducts, unlike liver parenchyma, are dependent on arterial blood to function properly. Careful consideration of variations in anatomy needs to be considered during dissection. Furthermore, the hepatic artery is prone to thrombosis which, if not detected, will cause necrosis of intra-/extrahepatic biliary tree. The liver can function normally on portal venous blood flow.

What is a split liver transplant?

A technique where the lateral segment of the left lobe is used for a child. The remainder of the liver (right lobe and medial left lobe) can be transplanted into an adult.

Following a liver transplant a patient presents with elevated alkaline phosphatase and bilirubin. What is the ERCP or magnetic resonance cholangiogram likely to show?

Intrahepatic biliary strictures, which may occur early or late following transplant, or anastomotic duct stricture

Following a liver transplant a patient's transaminases and bilirubin fail to normalize. What is the likely diagnosis?

Acute rejection. Chronic rejection attacks bile duct epithelium and leads to its destruction ➔ vanishing bile duct syndrome

How would you confirm this diagnosis?

With liver biopsy

Note: Bile ducts are the Achilles tendon of liver transplantation—they are involved in leakage, strictures, and rejection.

Following a liver transplant a patient has severe acidosis, coagulopathy, and profound elevation in transaminases. What is the likely diagnosis?

Primary nonfunction of the liver

How is this treated?

Urgent retransplantation

PANCREAS TRANSPLANTATION

What is the only form of long-term treatment for Type I diabetes mellitus?	Pancreas transplantation (not effective for DM II treatment)
What are three indications for pancreas transplantation?	1. Insulin-dependent diabetes mellitus (IDDM) with end stage renal disease (ESRD) (SPK [simultaneous pancreas kidney] transplant) 2. IDDM with previous kidney transplant (PAK [pancreas after kidney transplant]) 3. IDDM with normal kidney function but with secondary complications (eg, retinopathy, neuropathy, PTA [pancreas transplant alone])
Determine if the following will improve, stabilize, or have no improvement following pancreas transplant:	
Peripheral vascular disease	No improvement
Peripheral neuropathy	Improvement
Infection	No improvement
Retinopathy	Stabilize
In a pancreas transplant:	
Where is the pancreas placed?	Intra-abdominally
How are the endocrine secretions (insulin) managed?	Portal vein is anastomosed to the external iliac vein or IVC for systemic drainage or portal vein is anastomosed to the SMV for portal drainage.
How are the exocrine secretions managed?	Duodenum harvested en bloc w/pancreas is attached to small bowel.
How is pancreatic rejection monitored?	Serum glucose and amylase and lipase
Where is the most common site for injection of islet cells for transplantation?	Portal vein allows intrahepatic engraftment

Following a heart transplant a patient develops hypotension and increased CVP. Chest tube output is noted to have significantly decreased. What is the likely diagnosis?	Cardiac tamponade
Bradycardia following a heart transplant is best treated with what class of medications?	Beta agonists (or pacemaker). Atropine will not work because the heart has been denervated. This also allows for "silent/asymptomatic myocardial infarctions (MIs)."
What is the typical symptom of rejection of heart and lung recipients?	Asymptomatic until advanced
How does rejection manifest in heart and lung transplants?	Manifestation: • Heart: CAD of small vessels (atherosclerotic disease favors large vessels) • Lung: bronchiolitis obliterans (fibrosis of small airways)
How is rejection for the heart and lung monitored?	Surveillance: • Heart: periodic endomyocardial biopsy • Lung: serial CXR, bronchoscopy w/bronchoalveolar lavage (BAL), transbronchial biopsy, and FEV_1
Why are steroids kept at the lowest possible dose following lung transplant?	To avoid breakdown of bronchial anastomosis
What is the most common indication for a:	
Lung transplant?	Chronic obstructive pulmonary disease (COPD)/emphysema
Heart transplant (two reasons)?	Cardiomyopathy and CAD
Heart and lung transplant?	Pulmonary hypertension
Name the pathogens in a patient following lung transplantation.	
Two serious fungal infections?	*Aspergillus* and *Candida*
Most morbid viral infection?	CMV
Bacterial infection in cystic fibrosis?	*Pseudomonas aeruginosa*
What is the major histocompatibility complex (MHC)?	Series of genes that encode molecules used to bind and "present" antigenic peptides—in humans this is referred to as the HLA (human leukocyte antigen) system.

079_BOOKZ

What are the three class I HLA molecules?	HLA-A, -B, and -C
Three class II HLA molecules?	HLA-DR, -DP, and -DQ
What cells express class I HLA molecules?	All nucleated cells
Class II HLA molecules?	Antigen presenting cells (APC)—dendritic cells, B lymphocytes, monocytes
Which class is primarily involved in organ rejection?	HLA class II proteins—class I are involved in processing of viral antigens.
What are the two methods by which HLA proteins initiate rejection?	• Humoral rejection—antibodies react to antigens within the HLA complex (from past exposure or development of antibodies) • Cell mediated (more common)—proliferation of T-lymphocytes after exposure to donor HLA molecules (either from directly reacting to donor HLA molecules or from recipient processing antigens)
What two conditions are needed to cause T-cell activation following antigen stimulation?	1. Binding of T-cell receptor complex (CD3 complex transmits signals to interior of cell) with HLA molecule 2. Antigen independent costimulatory signal (B7 of antigen-presenting cells [APC], CD28 T-cell)
What is the role of CD8 T-cells?	These are cytotoxic T-cells that kill cells that have become infected with a virus or other intracellular pathogen
What is the role of CD4 T-cells?	These aid other cells in the immune system to respond to extracellular sources of infection—they are divided into T_H1 and T_H2
What is the role of CD4 T_H1 cells?	Activate macrophages to phagocytize extracellular pathogens
CD4 T_H2 cells?	Stimulate B-cells to produce antibodies
Histocompatibility testing consists of what three tests?	1. Tissue typing/HLA antigen typing 2. Antibody screening (screen recipient for anti-HLA antibodies) 3. Compatibility test (lymphocyte cross matching)

What are common side effects of steroid use?

- Cushingoid facies/habitus
- Acne
- Glucose intolerance
- Impaired wound healing
- Glaucoma/cataracts
- Opportunistic infections
- Osteoporosis
- Growth retardation (children)

What is the most significant side effect of AZA?

Bone marrow suppression (pancytopenia)

Note: Other side effects include: alopecia, GI disturbances, hepatotoxicity, pancreatitis.

Careful dosage is required for AZA when coadministered with what drug?

Allopurinol—inhibits AZA metabolism/dosage usually reduced by half

What drug causes selective inhibition of lymphocyte proliferation?

Mycophenolate mofetil (MMF) inhibits inosine 5-monophosphate (IMP) dehydrogenase—lymphocytes do not possess salvage pathway and cannot make purines (therefore, does not cause neutropenia or thrombocytopenia).

What is the most significant side effect of mycophenolate mofetil?

Clinically significant leukopenia

Note: Also causes gastrointestinal (GI) effects (vomiting, diarrhea).

What is the most significant side effect of cyclosporine?

Nephrotoxicity. Has vasoconstrictor effect on renal vasculature. Immediately post-transplant, it may exaggerate poor graft function. In the long-term it may cause interstitial fibrosis and renal failure.

Note: Other side effects include hirsutism, gingival hyperplasia, hepatotoxicity, neurotoxicity (histamine [HA], tremor, seizure), hyperglycemia.

What other medication has similar side effects to cyclosporine?

Tacrolimus—Both are calcineurin inhibitors, inhibiting transcription factors (preventing IL-2 production) following stimulation of TCR.

- MMF and AZA inhibit lymphocyte proliferation after antigen recognition

079_BOOKZ

What two immunosuppressive medications have been associated with posterior reversible encephalopathy syndrome (PRES) syndrome?	Cyclosporine and tacrolimus (other causes of PRES include hypertensive encephalopathy, renal failure, and eclampsia)
What are the signs/symptoms of PRES?	Acute-onset headache, altered mental status, cortical blindness, and seizures
What are the imaging characteristics with:	
CT?	Bilaterally symmetric low attenuation in the posterior parietal and occipital lobes
MRI?	Hyperintensity on T2-weighted images (revealing edema) in the same distribution
What are the two proposed mechanisms of PRES?	Two suggested mechanisms: • Cerebral vasospasm with resulting ischemia • Breakdown in cerebrovascular autoregulation with ensuing interstitial extravasation of fluid
How is PRES treated?	Control of blood pressure and seizures, discontinuation or reduction in dose of immunosuppressive drugs in post-renal transplant cases, and regular hemodialysis in uremic patients
What is the most serious side effect of OKT3?	Pulmonary edema (noncardiogenic)—do not fluid overload at time of treatment.
What is the cause of this side effect?	Release of cytokines from T-cell destruction—also causes encephalopathy, nephrotoxicity, aseptic meningitis; fever, chills and headache (most common)

079_BOOKZ

This page intentionally left blank

CHAPTER 21

ENT

ANATOMY

What are the borders of the anterior triangle of the neck and its four subunit triangles?

Anterior triangle: anterior border of sternocleidomastoid angle of mandible midline

1. Carotid triangle: superior belly of omohyoid, posterior belly of digastric, sternocleidomastoid muscle (SCM)
2. Muscular triangle: SCM, superior belly of omohyoid, midline
3. Submental triangle: midline, anterior belly of digastric, hyoid
4. Submandibular triangle: mandible, anterior and posterior bellies of the digastric

What are the borders of the posterior triangle of the neck?

Posterior triangle: posterior border of SCM, clavicle, trapezius

What is the most commonly injured nerve in neck surgery?

Spinal accessory nerve

What are the structures sacrificed in a radical neck dissection?

In addition to removing cervical lymph node levels I–V, the SCM, internal jugular, and cranial nerve (CN) XI are sacrificed (see Fig. 21-1).

What is a modified radical neck dissection (RND)?

A neck dissection which takes cervical lymph node levels I–V but leaves the functional anatomic structures taken in RND.

What is a selective neck dissection?

A neck dissection which removes lymph node levels selectively based on the tumor location and type. For example, levels I–III would be a selective neck dissection, regardless of what anatomic structures are taken.

Copyright © 2008 by The McGraw-Hill Companies, Inc. Click here for terms of use.

079_BOOKZ

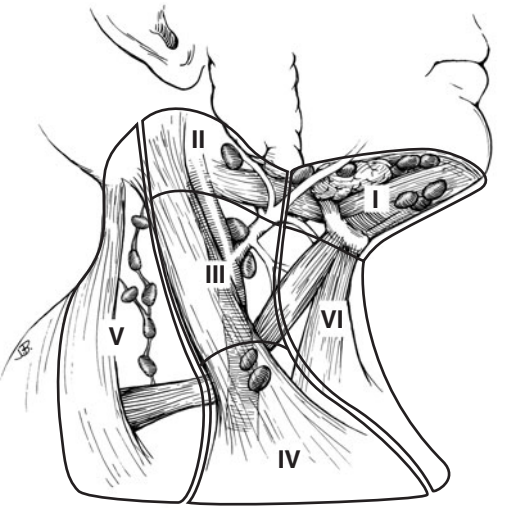

Figure 21-1 Cervical lymph node levels. These are not separated by fascial planes. [*Reproduced, with permission, from Brunicardi CF et al (eds): Schwartz's Principles of Surgery, 8th ed. New York: McGraw-Hill, 2005:534.*]

When is neck dissection necessary in head and neck cancers?	1. Palpable lymph node with known oropharyngeal or thyroid primary. 2. Head and neck primary >2 cm (T2). Risk of occult lymph node (LN) metastasis 20%.

CANCER

What is by far the most common type of head and neck cancer?	Squamous cell carcinoma
What is the most common location of squamous cell carcinoma of the head and neck (see Figs. 21-2, 21-3, 21-4)?	Lower lip
What are the two main risk factors for the development of head and neck cancer?	1. Tobacco—smoking and smokeless 2. Alcohol There is a synergistic relationship
What is a risk factor of tonsillar carcinoma?	Human papillomavirus (HPV)
What is a risk factor of lip carcinoma?	Sunlight exposure
Invasion of what structures necessitates post-op radiation therapy in head and neck cancer?	Extracapsular spread, perineural spread, vascular invasion
A 2-cm neck mass in a 40-year-old adult has what chance of being malignant?	80%

079_BOOKZ

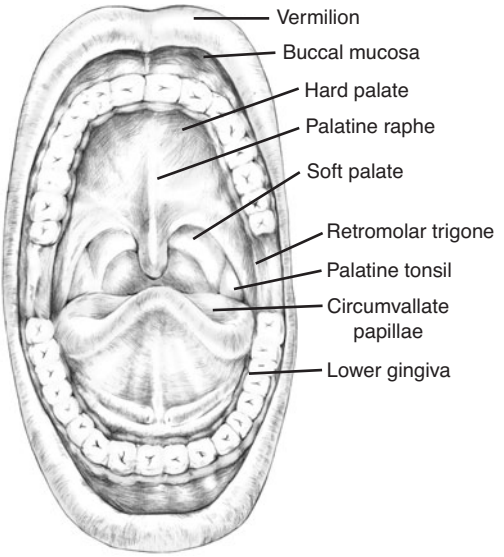

Figure 21-2 Oral cavity structures.

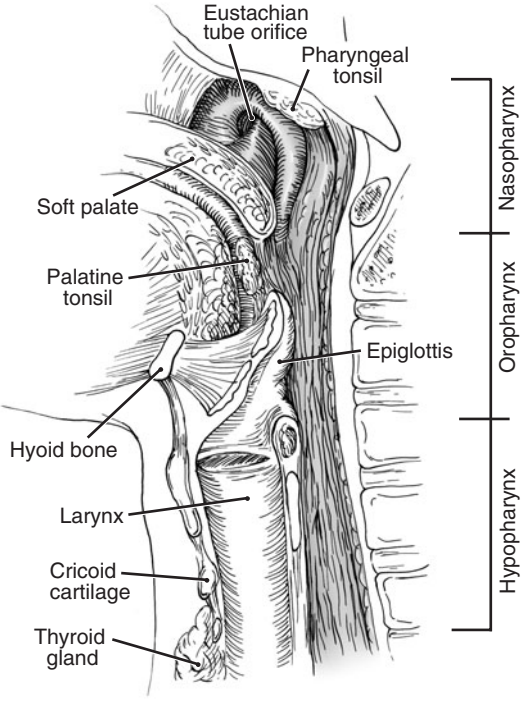

Figure 21-3 Relationship of nasopharynx, oropharynx, hypopharynx, and associated structures. [*Reproduced, with permission, from Brunicardi CF et al (eds): Schwartz's Principles of Surgery, 8th ed. New York: McGraw-Hill, 2005:525.*]

079_BOOKZ

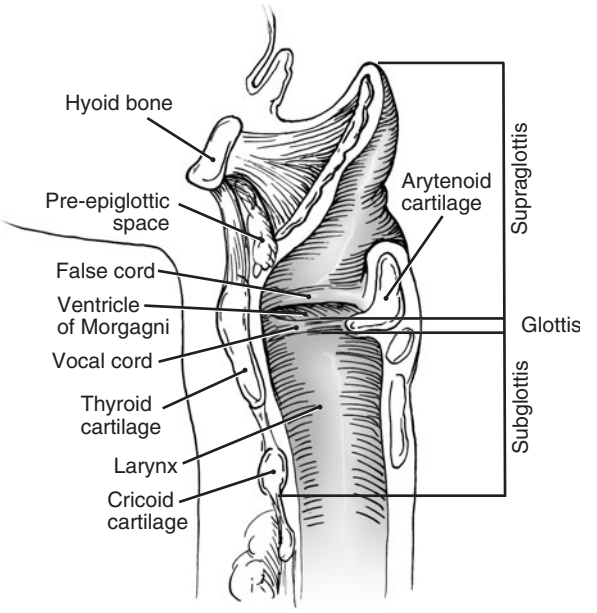

Figure 21-4 Structures of the larynx. [*Reproduced, with permission, from Brunicardi CF et al (eds): Schwartz's Principles of Surgery, 8th ed. New York: McGraw-Hill, 2005:527.*]

What is the workup of a neck mass with unknown primary?

1. Physical exam, search for primary lesion. Antibiotics if thought to be reactive.
2. Fine needle aspiration (FNA) if no resolution with antibiotics.
3. Bronchoscopy, endoscopy, laryngoscopy, CT scan of neck and chest.
4. Excisional biopsy with possible modified radical lymph node dissection.
5. If adenocarcinoma, possible lung, breast, GI origin.
6. If squamous cell, and no primary found, ipsilateral medical radical neck dissection (MRND), radiation therapy, ipsilateral tonsillectomy.

What is the most common malignant neck mass in children and young adults?

Lymphoma

What is the differential of a neck mass in children?

1. Reactive lymph node: Most common by far.
2. Branchial cleft cyst : Second (most common) and third can have

draining sinus on anterior border of SCM. Treat with excision.

3. Thyroglossal duct cyst: Midline, moves with swallowing. Remnant of embryologic migration path of the thyroid. Treat with Sistrunk procedure.
4. Cystic hygroma: Mobile, fluid filled lymphatic malformation. Can be massive and have deep space involvement.
5. Lymphoma.

SALIVARY GLANDS

What are the three major salivary glands?

1. Parotid
2. Submandibular
3. Sublingual

Salivary gland tumors are most common in which gland?

Parotid (85%). Most benign—pleomorphic adenoma most common.

Chance of submandibular or sublingual gland tumor being malignant?

50%

Chance of minor salivary gland tumor being malignant?

>75%

Superficial parotidectomy is indicated for what type of tumor?

Benign. Malignant should have total parotidectomy.

Total parotidectomy is indicated for locoregional control of what type of head and neck cancer?

Squamous cell carcinoma of the anterior external auditory canal

What is the initial treatment of suppurative parotitis?

IV fluids and antibiotics, promotion of salivation. Drainage only if not improving with conservative treatment.

What nerve must be avoided in a parotidectomy?

Facial nerve. If involved in tumor, must sacrifice. May graft with good chance of return.

INFECTIONS

What are the three types of ear infections?

External, middle, or inner ear (otitis externa, otitis media, labyrinthitis)

What is the most common causative organism in otitis externa?

Pseudomonas aeruginosa

What is the treatment of otitis externa?	Antibiotic drops, keeping dry
What is malignant otitis externa?	Refractory external auditory canal infection. Classic physical exam finding is granulation tissue. Can involve soft tissues and osteomyelitis of the temporal bone.
What are the clinical features?	Otalgia for >1 month Purulent otorrhea >1 week Cranial neuropathies
What is the treatment?	IV antibiotics Surgical debridement if no improvement
What are the complications?	Osteomyelitis of skull base Meningitis Brain abscess Death
What are the three most common causative organisms in otitis media?	1. *Streptococcus pneumoniae* 2. *Haemophilus influenzae* 3. *Moraxella*
What is the initial treatment of acute otitis media?	Amoxicillin or sulfa
Why do children get recurrent otitis media as opposed to adults?	Underdeveloped eustachian tube
What are the indications for myringotomy and pressure-equalization (PE) tube placement in the management of otitis media?	1. Conductive hearing loss due to chronic effusion 2. Effusion present >3 months 3. Frequent episodes of acute otitis media 4. Intra- or extracranial complication of otitis media
What is the treatment of tympanic membrane (TM) perforation due to otitis media?	Observation. The perforation helps with drainage and will heal spontaneously most of the time. If nonhealing, perform tympanoplasty.
What medications need to be avoided in patients with PE tubes or perforation?	Topical aminoglycosides because they are ototoxic.
What is a cholesteatoma?	Epidermoid inclusion cyst of the middle ear that is a result of chronic otitis media. Can cause destruction of mastoid bone or ossicle damage (conductive hearing loss).

079_BOOKZ

What is the concern in a patient with labyrinthitis?	Impending meningitis
What is the treatment of mastoiditis associated with otitis media?	1. Incision and drainage of mastoid 2. Antibiotics 3. Myringotomy and tube placement
A 20-year-old patient presents 1 week after an upper respiratory infection (URI) with unilateral facial droop.	
What is the diagnosis?	Bell's palsy "idiopathic" facial paralysis
What is the etiology?	Herpes virus
What is the treatment?	Steroids, antivirals, time. >90% will resolve spontaneously.
What is the most common type of infectious pharyngitis?	Viral URI
How is the diagnosis of bacterial pharyngitis made?	Rapid antigen test (rapid *Strep*) Pharyngeal culture
What are the remote sequelae of streptococcal pharyngitis?	1. Rheumatic fever 2. Glomerulonephritis 3. Scarlet fever
What are the three types of abscesses that are a sequelae of bacterial pharyngitis?	1. Peritonsillar 2. Retropharyngeal 3. Parapharyngeal
Which type of abscess threatens the airway?	Retropharyngeal. This is an airway emergency. Intubate before drainage. Drain through posterior pharyngeal wall.
Which abscess is associated with poor dentition and poses a risk of "carotid blowout"?	Parapharyngeal abscess. Drain through the skin of the lateral neck, avoid vascular structures, and leave drain in place.
What is the treatment of a peritonsillar abscess?	Needle aspiration or surgical drainage
What are the indications for tonsillectomy for bacterial pharyngitis?	• >3 infections per year • Recurrent peritonsillar abscess • Airway compromise
Adenotonsillar hypertrophy is implicated in what two sleep disorders?	1. Obstructive sleep apnea (OSA) 2. Upper airway resistance syndrome (UARS)
What is the etiology of acute bacterial sinusitis?	URI leads to obstruction of sinus ostium and bacterial proliferation.

What are the indications for surgery in the setting of acute bacterial sinusitis?	• Orbital cellulitis or abscess • Meningitis or intracranial abscess
What imaging study can help diagnose chronic sinusitis?	Computed tomography (CT) shows mucosal thickening or sinus opacification.
What procedure is necessary in confirming the diagnosis of chronic sinusitis and evaluating for anatomic lesions?	Nasal endoscopy. Look for purulence at ostia which is diagnostic of sinusitis, anatomic lesions such as deviated septum or polyps.
What are the indications for surgery in chronic sinusitis?	• Failure of intensive medical therapy—3–6 weeks of antibiotics, oral steroids, nasal irrigations • Fungal sinusitis
What is the treatment for invasive fungal sinusitis?	Aggressive debridement and intravenous (IV) antifungals. Usually immunocompromised or diabetic patients. Poor prognosis.

TRAUMA

Primary closure of the eyelid can be accomplished when what portion of its width is missing?	One-fourth
What is the key stitch in primary eyelid closure?	Aligning the grey line (conjunctival border)
Primary closure of the lip can be accomplished when what portion of its width is missing?	One-third
What is the key stitch in primary lip closure?	Aligning the vermilion border. Two-layer closure.
In ear lacerations, what deep structure needs to be approximated?	Cartilage
Hematoma of the ear must be drained to prevent what complication?	Cauliflower ear
Should parotid duct injury be ligated or repaired?	Always repair to prevent painful atrophy of the gland and cosmetic deformity. Repair over stent and leave in place.
What is the most common facial fracture?	Nasal fracture
What must be ruled out in every nasal fracture?	Septal hematoma. If found, must be evacuated.
What is the risk of missed injury?	Septal wall necrosis

079_BOOKZ

What are the treatment options for mandibular fractures (see Fig. 21-5)?

1. Mandibulomaxillary fixation (also known as intermaxillary fixation [IMF], arch bars, "wiring")
2. Open reduction, internal fixation

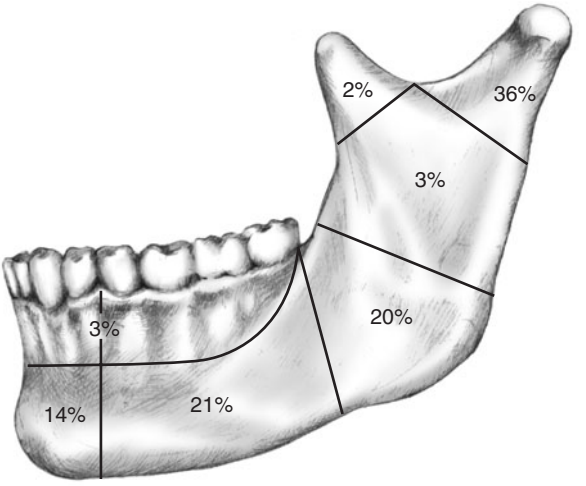

Figure 21-5 Distribution of mandibular fracture.

What is the goal of a mandibular reduction?

Occlusion to get the jaw in the anatomic location for the alignment of teeth. In edentulous patients, this is less important.

What is the best radiograph for mandibular fracture assessment?

Panorex film, which is a panoramic x-ray. Facial CT can substitute, but not as good. Plain film can show fractures, but anatomic details are poor.

Lower-lip numbness with mandibular fracture suggests what?

Alveolar nerve damage. Assess pre-op, can be damaged during manipulation.

What is the commonly injured nerve in a zygoma fracture?

Branches of cranial nerve (CN) V (loss of sensation). Function returns in majority of cases.

What is an orbital blowout fracture?

Herniation of periorbital fat or extraocular muscle into the maxillary sinus.

What finding is an indication for urgent repair?

Muscle entrapment: disconjugate extraocular movement or inability to move eye by grabbing muscle attachments with forceps (forced duction test)

Describe the three LeFort midface fracture patterns (see Fig. 21-6).

1. LeFort I—transverse fracture along the alveolus
2. LeFort II—through the nasofrontal buttress, medial wall of orbit and infraorbital rim, through the zygomaxillary articulation
3. LeFort III—"craniofacial disjunction"—frontomaxillary, frontozygomaticomaxillary, frontonasal disruption

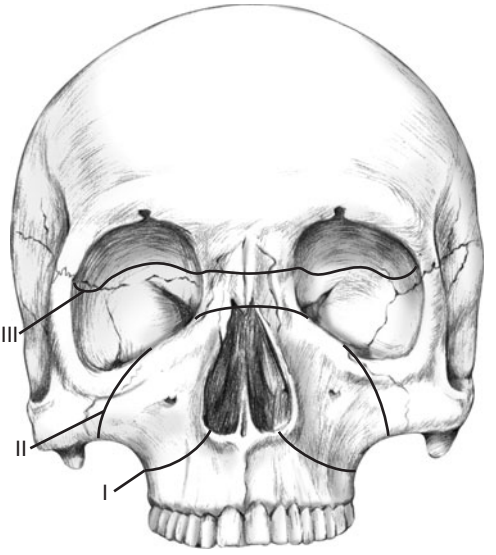

Figure 21-6 LeFort midface fracture classification.

What is the best way to screen for a midface fracture on physical exam?

Thumb in patient's mouth on hard palate and pull.

Best imaging study for facial fracture other than mandible?

Facial CT scan

Temporal bone fracture is associated with what two complications?

1. Facial nerve injury (20–50% depending on fracture pattern)
2. CSF leak

079_BOOKZ

TRACHEOSTOMY

What are the indications for tracheostomy?	• Upper airway obstruction • Perioperative airway management • Prolonged intubation in ICU setting (7–14 days cutoff) • Airway resection
What are the main complications of tracheostomy?	• Pneumothorax • Pneumomediastinum • Bleeding • Tracheomalacia • Tracheal stenosis • Tracheoinnominate fistula • Tracheoesophageal fistula
What is the emergency airway of choice in adults?	Cricothyroidotomy
When does a cricothyroidotomy need to be converted into a formal tracheostomy?	If airway is thought to be necessary for longer than 5–7 days

079_BOOKZ

This page intentionally left blank

CHAPTER 22

Bariatric Surgery

What is the calculation used to determine body mass index (BMI)?	BMI = mass (kg)/height^2 (m^2)
What is a normal BMI?	19–25
What is the BMI definition of:	
Obesity?	>30
Morbid obesity?	>40
What are the indications for bariatric surgery?	• BMI >40 • BMI >35 with significant comorbidities • Must have failed supervised nonsurgical weight loss program
What are the common "comorbidities" of obesity?	• Type II diabetes • Hypertension (HTN) • Obstructive sleep apnea • Dyslipidemia • Osteoarthritis
What are the cancers with higher risk in obesity?	Colon, prostate, breast, uterine
What is pickwickian syndrome?	The combination of obstructive sleep apnea (OSA) and obesity hypoventilation syndrome. Both are due to excess weight on respiratory system producing a restrictive pulmonary defect. Weight reduction is curative.
What is the most effective long-term treatment of morbid obesity?	Bariatric surgery

Copyright © 2008 by The McGraw-Hill Companies, Inc. Click here for terms of use.

079_BOOKZ

What are the two mechanisms of action of bariatric procedures?	Malabsorptive, which decreases functional length of small bowel. Restrictive, which is by creating a small neogastric pouch.
What is the gut hormone associated with high levels in obesity that decreases when bypassing the distal stomach?	Ghrelin
What is the current gold standard bariatric procedure?	Roux-en-Y gastric bypass (usually performed laparoscopically) (see Fig. 22-1)
On what bariatric principle is this procedure based?	Mainly restrictive, but also some degree of malabsorption

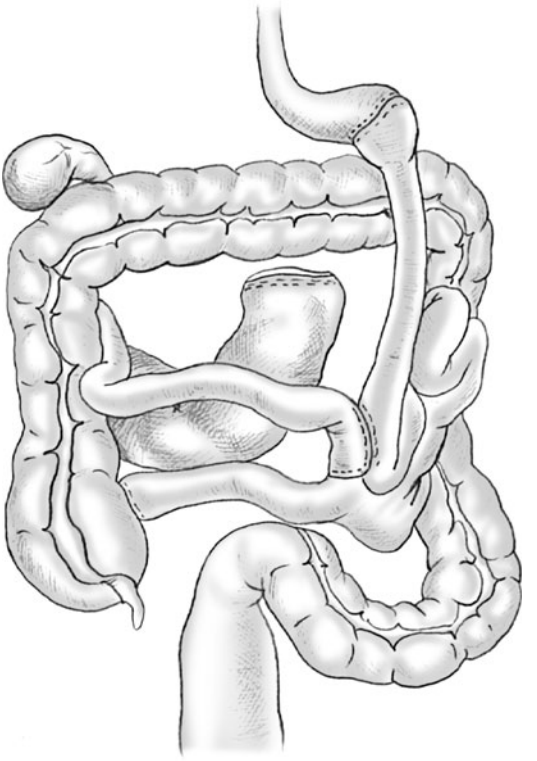

Figure 22-1 Roux-en-Y gastric bypass procedure. Jejunum is transected 30–40 cm distal to the ligament of Treitz. The roux limb is created by measuring 45–150 cm distal to that point and then creating a jejunojejunostomy. Gastric pouch is created based on the lesser curvature of the stomach to be 10–30 mL in volume. Proximal roux limb is then reanastomosed to the pouch.

079_BOOKZ

How do you remember which is the "roux" limb?	R**oux** is where the f**oo**d goes.
What is the "Y" limb often called?	The biliopancreatic limb (BP limb).
What are the major complications of gastric bypass?	Short-term: • Anastomotic leak • Obstruction • Pulmonary embolism Long-term: • Protein malnutrition • Vitamin B_{12} deficiency • Calcium, vitamin D deficiency • Iron deficiency anemia • Incisional hernia in open • Internal hernia • Marginal stomal ulcer • Stomal stenosis • Gallstones
How does early dumping syndrome improve weight loss in Roux-en-Y gastric bypass patients?	• Dumping syndrome is brought on by highly refined carbohydrate meals, especially sweets. • Results in behavioral modification through aversion to foods that cause dumping, reinforcing good eating habits.
What is the most feared complication in gastric bypass?	Anastomotic leak. Occurs in 5% of cases.
What are the signs/symptoms?	**Tachycardia,** tachypnea, fever, hiccups, leukocytosis
How is it diagnosed?	Emergent upper GI exam with water-soluble contrast radiograph
How is it treated?	If contained, percutaneous draining and antibiotics. If not contained, reexploration.
What is a common alternative to Roux-en-Y gastric bypass?	Laparoscopic adjustable gastric band (lap band) (see Fig. 22-2).

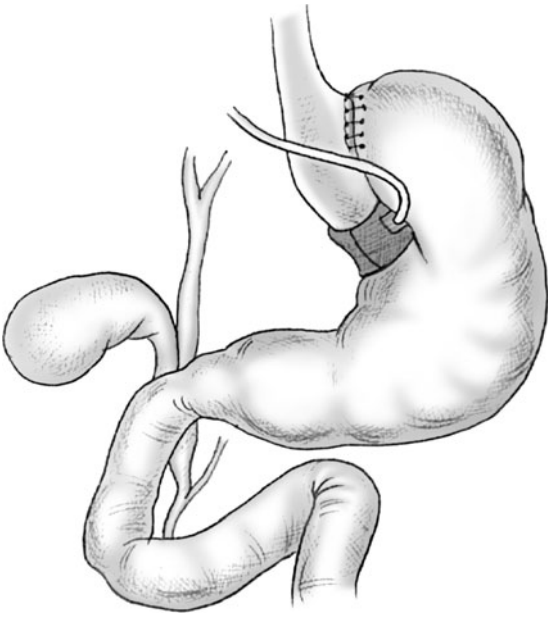

Figure 22-2 Inflatable silastic ring fitted around upper stomach and inflation port tunneled to subcutaneous fat. Size of pouch should be 20 mL.

Why is it better than other gastroplasty procedures?	• Reversible. • Adjustable—gastric pouch often dilates in gastroplasty, can inflate ring to compensate for this.
What are the complications of this procedure?	• Increased gastroesophageal reflux disease (GERD) symptoms • Erosion into fundus • Slippage of band • Failure of weight loss 15–20% of patients
Which is better at maintaining long-term weight loss: gastric bypass or lap band?	Gastric bypass
What is the bariatric procedure popular in the 1970s that now should be reversed?	Jejunoileal bypass, due to a high rate of malnutrition and other complications such as renal stones and cirrhosis

079_BOOKZ

CHAPTER 23

Urology

ANATOMY AND MALFORMATIONS

What feature of the renal arteries makes the kidneys susceptible to infarction?	They are end arteries. Without collateral arterial supply, the renal arteries are the sole blood supply to the kidneys.
Which veins drain into the left renal vein?	Adrenal vein and gonadal vein
Where does the adrenal and gonadal vein drain on the right side?	Inferior vena cava (IVC)
Does the ureter go over or under the common iliac vessels?	Over
What is the difference in urethral sphincter mechanisms between men and women?	Men have a more redundant sphincter mechanism with an internal and external sphincter which consists of smooth and striated muscle while women have no internal sphincter and rely on coaptation of the urethral mucosa and a striated external sphincter.
What are the common causes of hydronephrosis?	Obstruction (stone, stricture, extrinsic compression, neurogenic) Vesiculoureteral reflux (1%) (suspect in pediatric patients with recurrent urinary tract infections (UTIs) to prevent renal scarring) Ureteral duplication (1–2% of population)
What is the most common cause of hematuria or urinary tract infection (UTI) in a post-op patient?	Indwelling Foley catheter with trauma on insertion

Copyright © 2008 by The McGraw-Hill Companies, Inc. Click here for terms of use.

079_BOOKZ

Define cystitis.	Inflammation of the bladder
What are common causes?	1. Bacterial 2. Nonbacterial (culture negative): • Infectious (viral, fungal, chlamydial, mycobacterial) • Noninfectious—(chemical, radiation, autoimmune) • Interstitial—describes chronic cystitis where no etiology can be found
What is/are the common cause(s) of cystitis among:	
Women?	Ascending infection from poor hygiene, sexual activity, pregnancy/postpartum
Men?	Usually associated with urologic pathology: • Obstruction: benign prostatic hyperplasia (BPH)/cancer, posterior urethral valves (more common in children) • Urine stasis: neurogenic bladder • Foreign body: Foley, calculus • Persistent/inadequately treated infection: prostatitis
What is the concern in pediatric patients with pyelonephritis or recurrent UTI?	Congenital vesiculoureteral reflux
What is the most useful test to evaluate this?	Voiding cystourethrogram
What are the most common organisms causing cystitis?	Fecal flora: ***Escherichia coli***, *Proteus, Klebsiella, Enterobacter*
What are the common symptoms associated with cystitis?	Dysuria, ↑ frequency/urgency, incontinence, hematuria, suprapubic pain, cloudy/foul smelling urine
How does pyelonephritis present?	The above symptoms + **fever**/chills and costovertebral tenderness
What two laboratory tests are most commonly used to diagnose cystitis?	Urine culture and urinalysis. The diagnosis can be made with a demonstration of pyuria (defined as white blood cell [WBC] >10 WBC/mm^3), nitrites, bacteriuria, leukocyte esterase)

079_BOOKZ

What is evaluated to determine adequacy of test?	Presence of squamous epithelial cells signify a contaminated sample
What additional finding may be seen indicating pyelonephritis?	White blood cell casts
What is the definition of a complicated UTI?	Bacterial infection that occurs as a result of structural/anatomic abnormalities Examples—bladder neck obstruction (benign prostatic hyperplasia [BPH]), catheter, stone
What is the definition of an uncomplicated UTI?	Spontaneous bacterial colonization of the urinary tract; much more common in females
What is the treatment of:	
Acute bacterial cystitis?	Females: 3 days of antibiotics—nitrofurantoin, trimethoprim-sulfamethoxazole, or ciprofloxacin Males: 7 days, usually complicated UTI
Pyelonephritis?	Fluoroquinolones (particularly those excreted renally) or parenteral regimens (aminoglycoside) × 3 weeks if severely ill **Note:** Remember, males require further workup to rule out urologic pathology.
What are the complications of UTI?	• Struvite calculus • Pyelonephritis • Renal papillary necrosis—sloughing of renal papillae, associated with diabetics • Perinephric abscess, diagnosis (dx) with computed tomography (CT) or ultrasound (US). Treat with percutaneous drainage and antibiotics.
A patient with an indwelling catheter (or intermittent self-cath) is found to have asymptomatic bacteriuria. What is the correct treatment?	Hydration and increased bladder emptying to prevent urine stasis. Colonization is common in these patients and antibiotics are not needed if asymptomatic.
What type of patient requires treatment of asymptomatic bacteriuria?	Pregnant patients due to the risk of premature labor

A febrile patient with dysuria, low back pain, and a tender, firm, and indurated prostate likely presents with what?	Acute bacterial prostatitis
Why should a rectal exam be performed with caution in patients presenting with acute bacterial prostatitis?	Vigorous massage of prostate may cause bacteremia and septicemia. **Note:** Urethral instrumentation (Foley) should also be avoided—place suprapubic catheter instead.
What are the four types of prostatitis?	1. Acute bacterial (fever) 2. Chronic bacterial (most common) 3. Nonbacterial (routine culture negative) 4. Prostatodynia
What two laboratory tests are helpful in differentiating the types of prostatitis?	Urine culture ([+] acute/chronic bacterial) and expressed prostatic secretions
What is measured in the expressed prostatic sections (EPS)?	White blood cell count
Which type will have a negative value?	Prostatodynia
What is prostatodynia?	Complaints consistent with prostatitis but no signs of prostatic inflammation (negative culture, negative EPS). Often stress related and may have a psychological component.
What are common bacteria associated with bacterial prostatitis in:	
Men <35 years of age?	*Chlamydia trachomatis* and gram-negative organisms
Men >35 years of age?	Bacterial prostatitis: gram-negative organisms same as in UTI (*Escherichia coli, Enterobacter, Serratia, Pseudomonas, Enterococcus,* and *Proteus* species)
What are common organisms involved in nonbacterial prostatitis?	*C. trachomatis*, *Ureaplasma* species, (also consider *Mycobacterium tuberculosis, Coccidioides, Histoplasma,* and *Candida)*
How are the four types of prostatitis treated?	1. Acute: trimethoprim/sulfamethoxazole (TMP/SMX) × 30 days or fluoroquinolone × 30 days 2. Chronic: same as in acute but extend treatment to 6 weeks

079_BOOKZ

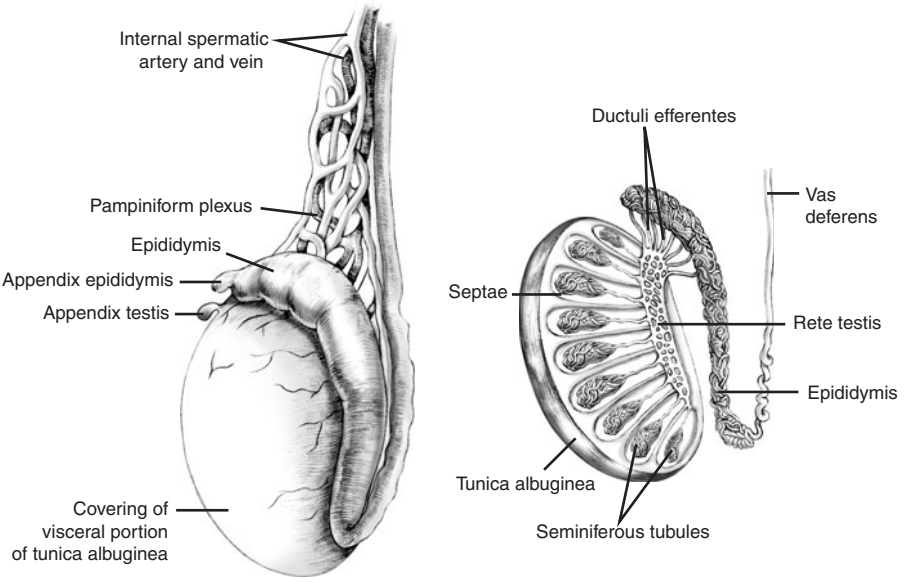

Figure 23-1 Testis, epididymis, and vas deferens. [*Reproduced, with permission, from Brunicardi CF et al (eds): Schwartz's Principles of Surgery, 8th ed. New York: McGraw-Hill, 2005:1521.*]

3. Nonbacterial: doxycycline × 6 weeks
4. Prostatodynia: stress reduction

A 20-year-old male presents with a swollen, tender testicle, warm, erythematous scrotal skin, with pain radiating to the flank following an episode of heavy lifting. What is the likely diagnosis?

Acute epididymo-orchitis, which is flank pain from thickened/painful spermatic cord. Reactive hydrocele often accompanies inflammation (see Fig 23-1).

What are the common organisms involved in the infection?

- Younger males, usually STDs (*C. trachomatis, Neisseria gonorrhoeae*)
- Older males usually concomitant UTI or prostatitis (fecal flora)

What is the treatment?

Bed rest (avoid sexual/physical activity), analgesia, antibiotics (determined by urine culture)

Note: Remember to treat the partner when STDs are the cause.

A patient presents with hematuria, intense back pain radiating to the groin, dysuria, and alkaline urine. What is the likely diagnosis?

Urolithiasis

What other diagnoses should be considered?

Appendicitis, diverticulitis, small bowel obstruction (SBO), ovarian torsion, ectopic pregnancy

What is the male:female ratio of urolithiasis in:	
Adult patients?	4:1
Pediatric patients?	3:2
Match the following descriptions with the likely etiology (calcium oxalate, struvite, uric acid, cystine stones):	
Patient receiving chemotherapy	Uric acid stones (also associated with gout), due to high purine turnover
Hexagonal crystals	Cystine stones
Associated with urease-producing bacteria (eg, *Proteus*)	Struvite (also associated with *Klebsiella, Pseudomonas, Staphylococcus* that produce alkaline urine)
Account for ~75% of urolithiasis	Calcium oxalate
Associated with type I renal tubular acidosis (RTA)	Calcium oxalate (type I RTA is a defect in hydrogen secretion)
Inherited defect in renal tubule	Cystine (causes loss of **c**ystine, **o**rnithine, **l**ysine, **a**rginine = COLA)
Radiolucent stones	Uric acid
Excessive absorption (gastrointestinal [GI]) or secretion (kidney)	Calcium oxalate
What are the common imaging modalities used to diagnose nephrolithiasis?	• Kidney, ureter, and bladder (KUB): only useful for radiolucent stones • Renal ultrasound (US): in pregnant women • Noncontrast CT: gold standard • Intravenous pyelogram (IVP): no longer test of choice
What are the two indications for emergent surgical intervention?	1. Fever: indicates obstructing calculi associated with infected urine causing pyohydronephrosis (potential for sepsis) 2. Renal insufficiency: usually ↑ BUN (blood urea nitrogen)/Cr (creatinine) in solitary kidney **Note:** Consider surgery in cases with severe pain or prolonged course.
What are four surgical procedures employed for treating nephrolithiasis?	1. Percutaneous nephrostomy tube: for pyohydronephrosis or removal of large calculi.

079_BOOKZ

2. Transurethral endoscopic manipulation: best for more distal calculi.
3. Open surgical removal: nephrolithotomy, partial nephrectomy.
4. Extracorporeal shock wave lithotripsy (ESWL): uses different external sources of energy to pulverize stones directed under fluoroscopic or ultrasound guidance. May use with alpha or calcium channel blockers to relax ureters and facilitate stone passage.

What are absolute contraindications to extracorporeal shock wave lithotripsy (ESWL)?

- Acute UTI/sepsis
- Coagulopathy/antiplatelet medication
- Pregnancy
- Uncorrected distal obstruction

What three conditions warrant analysis of composition of calculi?

1. Nephrolithiasis in young patients (<40 years)
2. Multiple calculi
3. Recurrent calculi

What is the treatment for the following calculi:

Struvite? Eradication of infection: usually *Proteus,* with antibiotics and often surgical removal of stone required

Uric acid? Alkalinization of urine: potassium citrate or sodium bicarbonate, allopurinol if hyperuricemia is present

Cystine? Treat with ESWL/surgery and dissolution (*N*-acetylcysteine). Prevent with hydration and alkalinization of urine, may also use D-penicillamine to bind cystine.

Calcium oxalate/phosphate?

Renal tubular acidosis (RTA) Alkalinization of urine (potassium citrate)

Renal hypercalciuria Thiazide diuretics (absorb calcium from urine), restrict sodium and protein, hydration

Absorptive hypercalciuria Orthophosphates (bind Ca in GI tract), low Ca diet

What are the following symptoms of each condition caused by benign prostatic hyperplasia (BPH) with bladder outlet obstruction (BOO):	
Obstruction?	Hesitancy, weakened urine stream, urinary retention, suprapubic pain, overflow incontinence, straining, intermittency
Irritation (detrusor instability from obstruction)?	Urgency/urge incontinence, ↑ frequency, nocturia
What are common causes of BOO in:	
Men?	BPH, prostate cancer, urethral stricture, bladder calculi
Women?	Urethral stenosis/trauma, cystourethroceles (uncommon)
How is BPH diagnosed?	1. Digital rectal exam (DRE): Evaluate for size and irregularities. 2. Measurement of prostate specific antigen (PSA). 3. Urinalysis (UA) and urine culture: evaluate for prostatitis or presence of hematuria. 4. BUN/Cr: evaluate for any renal impairment from obstruction. 5. Postvoid residual: normal is to have no residual. 6. Transrectal ultrasound and biopsy if suspicious for prostate cancer.
What is the normal volume (in grams) of the prostate?	20 g
Above what volume do patients typically experience symptoms?	40 g **Note:** 1 finger pad ~20 g, therefore, most asymptomatic men have ≤ 2 finger widths.

PROSTATE CANCER

What are the risk factors for prostate cancer?	1. >Age 2. African American race

What is the most common type of prostate cancer?	Adenocarcinoma (95%)
What is the most common anatomic region for prostate cancer?	Peripheral zone. BPH is most common in transition zone.
How do you grade a prostate cancer on biopsy?	Gleason grading system—Grade ranges from 1(low)–5(high) based on differentiation. Gleason score is the sum of the most common and second most common Gleason grades found (2–4 is low-grade, 5–7 is moderate, 8–10 is high).
What are the diagnostic tests for prostate tumors?	• Digital rectal exam (DRE): feel for increased size with nodularity. (BPH is symmetric enlargement.) • Prostate specific antigen (PSA: serum serine protease increases in cancer but also in prostatitis and ejaculation. Normal is <4 ng/mL.) • Transrectal ultrasound (TRUS): can image prostate size and nodularity. Used to guide biopsy. • Prostate biopsy: several punch biopsies taken transrectally. Risks are bleeding (rectal, urinary, or ejaculatory) and infection.
Who should be screened for prostate cancer?	American cancer society (ACS) recommends yearly screening with PSA and DRE for: • All men > age 50 with 10 years of life expectancy • Black men > age 45 • Men with family history (first degree relative with prostate cancer younger than age 70) > age 45
Who should get prostate biopsy?	• One time PSA >7 ng/mL • Two consecutive PSA values (separated by 2 weeks) >4 and <7 • Increase by average or 0.75 ng/mL/year based on three consecutive years • Patients with palpable nodule with exclusion of other causes (prostatitis)

When prostate cancer is found on biopsy, what other tests need to be performed for staging?	• CT of abdomen and pelvis: Look for lymph node (LN) metastasis, extraprostatic extension. • TRUS (transrectal ultrasound): can also look for extraprostatic extension. • Radionucleotide bone scan: bone metastasis is common in prostate cancer. Should only be ordered if high volume tumor (>1.5 cm) or PSA >15 ng/mL.
Is metastasis prostate cancer bone osteoblastic or osteoclastic?	Osteoblastic
What is the most common operation for prostate cancer?	Radical retropubic prostatectomy (RRP)
What is the first-line therapy for metastatic prostate cancer?	Androgen ablation therapy (surgical or medical)

TESTICULAR CANCER

What is the age group most affected by testicular cancer?	20–35
What is the biggest risk factor for testicular cancer?	Cryptorchidism (undescended testis), risk present even after surgical orchiopexy.
What are the types of testicular tumors?	Nongerm cell tumors, 5% • Sertoli cell tumors • Leydig cell tumors Germ cell tumors, 95% • Seminomatous • Nonseminomatous (embryonal carcinoma, teratoma, choriocarcinoma, yolk sac tumors)
Alpha-fetoprotein (AFP) is a marker for which types of testicular cancer?	Yolk sac, embryonal carcinoma, teratoma
Beta human chorionic gonadotropin (βhCG) is a marker for which types of testicular cancer?	Seminoma and choriocarcinoma
What is the other marker used to follow seminoma postorchiectomy?	Follicle stimulating hormone (FSH)
What is the survival rate for testicular cancer?	>90%

079_BOOKZ

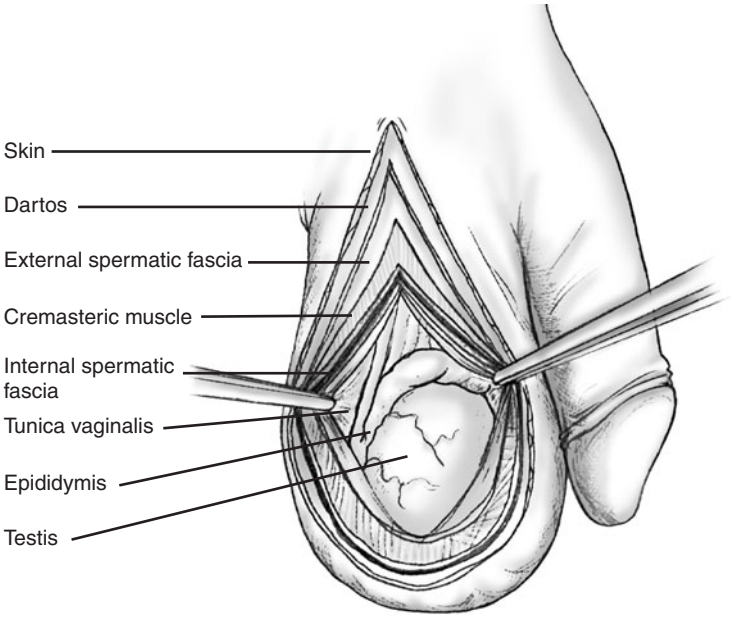

Figure 23-2 The testicle and its surrounding layers.

What is the diagnostic evaluation when a testicular mass is discovered on physical exam (see Fig. 23-2)?

- Scrotal ultrasound: if nodular, tumor is confirmed, proceed with further testing.
- CT of chest, abdomen, pelvis to look for LN and distant metastasis.
- Radical orchiectomy: best diagnostic test.

Why perform radical orchiectomy using the inguinal, not scrotal approach?

Testes lymphatic drainage is para-aortic, scrotal drainage is inguinal. If approach is scrotal, risk of inguinal metastases. Never perform trans-scrotal biopsy.

BLADDER CANCER

What are the risk factors for bladder cancer?

- Smoking
- Cyclophosphamide treatment history
- Pelvic irradiation
- Occupational exposures
- Chronic inflammation—indwelling catheters
- Schistosomiasis history

What are the symptoms of bladder cancer?	• Painless hematuria (85%) • UTI symptoms
What is the best diagnostic test if bladder cancer is suspected?	Cystourethroscopy and biopsy. Most cancers are then treated endoscopically.
What is the most common type of bladder cancer?	Transitional cell carcinoma (90%)
What is the indication for metastatic workup in a patient with bladder cancer?	Evidence of muscular involvement
What does this include?	• CT chest/abdomen/pelvis • Bone scan
What stages of bladder cancer can be treated endoscopically?	Carcinoma in situ (CIS), Ta, T1 (see Fig. 23-3)
What is the recurrence rate of superficially treated bladder cancer?	70% in 5 years. Patients should undergo endoscopic surveillance for this reason.

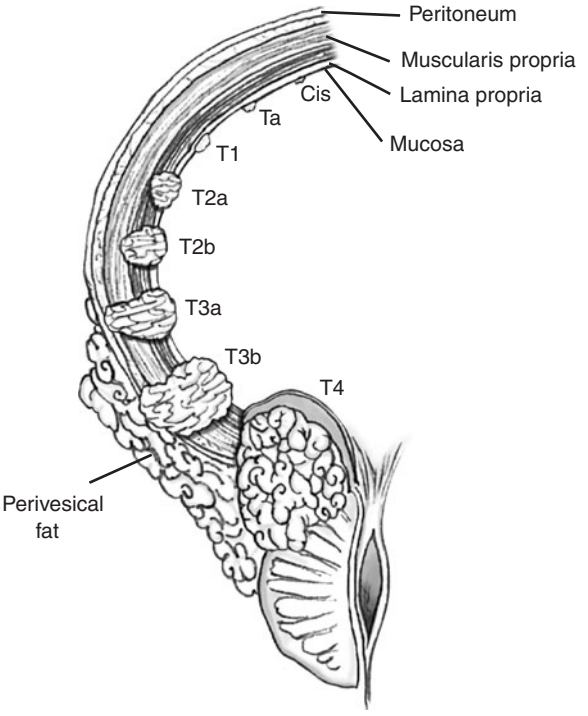

Figure 23-3 Staging of bladder cancer. T stage determined by depth of invasions: Cis = carcinoma in situ; Ta = mucosa; T1 = lamina propria; T2a = superficial bladder muscle; T2b = deep bladder muscle; T3a = perivesical fat (microscopic); T3b = perivesical fat (gross); T4 = adjacent structures such as prostate, rectum, or pelvic sidewall.

What is the treatment for invasive, nonmetastatic bladder cancer?

Radical cystectomy ± lad

Renal Cell Carcinoma

What are the most common presenting symptoms associated with renal cell carcinoma?

- None. Most renal cell carcinomas are detected incidentally by CT or US for different etiology.
- Classic triad is flank pain, hematuria, and palpable mass (only found in 10% of patients).

What is the most significant risk factor for renal cell carcinoma?

Smoking

What paraneoplastic processes can accompany renal cell carcinoma?

- Hypertension, due to increased renin
- Erythrocytosis, due to increased erythropoietin
- Hepatic dysfunction (Stouffer syndrome): nonmetastatic
- Hypercalcemia
- Fevers, constitutional symptoms: due to pyrogen production

What is the initial workup of a patient with the classic triad of flank pain, hematuria, and palpable mass?

Dedicated renal CT with pre- and postcontrast imaging.

- Enhancing solid renal mass has a 90% chance of being renal cell carcinoma (see Fig. 23-4).

After imaging, what is the next step in suspected renal cell carcinoma?

Surgery if no metastases are found and tumor is resectable. Do not biopsy. Biopsy has a high false-negative rate.

What are the surgical options?

1. Radical nephrectomy. Classic gold standard. Can be laparoscopic or open. Consists of taking kidney, ipsilateral adrenal, and all fat contained in Gerota's fascia.
2. Simple nephrectomy. Usually performed with comparable cure rates to radical nephrectomy.
3. Partial nephrectomy. Can be used if tumor <4 cm in diameter.

What is the "surgical" cure rate?

With localized disease (stages I and II), cure rates with nephrectomy are 75%.

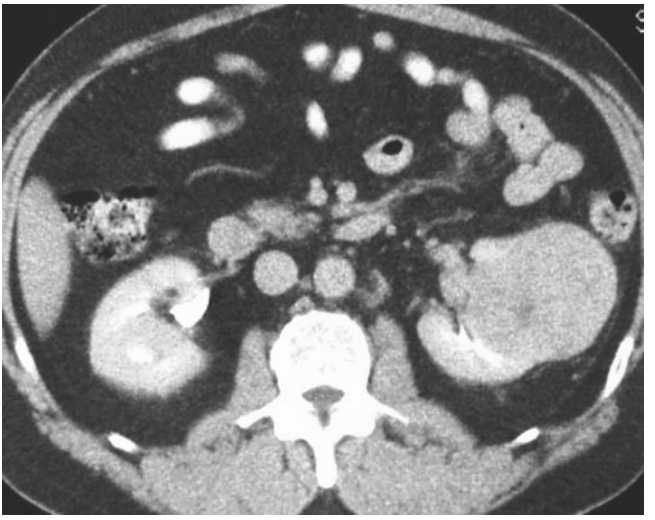

Figure 23-4 CT scan with IV contrast demonstrating an enhancing, solid mass of the left kidney. [*Reproduced, with permission, from Brunicardi CF et al (eds): Schwartz's Principles of Surgery, 8th ed. New York: McGraw-Hill, 2005:1531.*]

What is the treatment for metastatic renal cell carcinoma?

- Immunotherapy is the only proven treatment methodology. No cure expected but response rates in 15–30% of patients can be seen.
- Palliative nephrectomy/angioembolization can be helpful for severe hemorrhage, pain, or paraneoplastic syndrome.

INCONTINENCE

What are the different types of urinary incontinence?

- Stress: incontinence associated with sudden increases in intra-abdominal pressure—coughing, laughing, exercise. A result of urethral/pelvic descent common in postmenopausal gravid women.
- Urge: abnormal involuntary bladder contractions. Can be due to neurologic insult (detrusor hyperreflexia) or bladder irritation (detrusor instability).
- Total: continuous leakage of urine due to fistula. Usually a result of pelvic surgery (75%).

	• Overflow: due to outlet obstruction (prostate) or atonic bladder. • Mixed: stress and urge commonly coexist.
What is the most common type of urinary incontinence in:	
A man?	Overflow incontinence
A woman?	Stress incontinence
What is the study of choice in each type of incontinence?	
Stress	Q tip test: Q tip inserted into urethra and patient instructed to bear down. >30º change is positive test. Then urodynamic testing.
Urge	UA: Bladder infection most common cause. Treat underlying cause. If UA normal or incontinence persists after treatment, then urodynamic testing.
Total	Cystoscopy
Overflow	Postvoid residual: bladder ultrasound or catheterization after attempt at voiding
What is the treatment of each type of incontinence?	
Stress	Medical (estrogen supplements); surgical (urethral sling or anterior pelvic repair to reposition urethra)
Urge	Treat underlying cause or irritation; if idiopathic medical (anticholinergics); surgical (implanted pelvic nerve stimulator)
Total	Surgical fistula repair
Overflow	BPH—medical therapy (eg, alpha adrenergic blockers) or surgical therapy (eg, transurethral resection of the prostate [TURP])—Atonic bladder (intermittent straight catheterization)

079_BOOKZ

What neurologic lesion(s) causes the following syndromes?

Detrussor hyper-reflexia (hypertonic neurogenic bladder)	Upper motor neuron (suprasacral) lesions: like other muscles, upper motor neuron lesions result in spasticity.
Detrussor areflexia (atonic bladder)	Lower motor neuron lesions (sacral spinal cord, nerve roots, cauda equina): like other muscles, lower motor neuron lesions will result in flaccidity.
Detrussor sphincter dyssynergia (DSD)	Supraspinal lesions

UROLOGIC TRAUMA

What is the best physical sign of renal injury in the setting of trauma?	Gross hematuria (95% of patients with kidney laceration) **Note:** All patients with gross or microscopic hematuria in the setting of blunt trauma should have abdominal CT to rule out renal injuries.
What is the mechanism of injury of a renal pedicle avulsion in blunt trauma?	Rapid deceleration injury. Organ whiplash causes sheer injury at the fixed point.
What are the operative indications for a kidney laceration?	• Unstable patient • Grade V lesions (renal pedicle avulsion or shattered kidney) • Expanding or pulsatile retroperitoneal hematoma • Requirement of > three units of blood/day (ongoing blood loss)
What is the most common cause of bladder and urethral injury in blunt trauma?	Pelvic fracture
What are the three physical signs that are characteristic of a urethral injury?	Blood at meatus, scrotal hematoma, high riding prostate on rectal exam
Why is this important in trauma?	It is a relative contraindication to placing a Foley catheter in the acute setting
What is the initial study of choice if urethral injury is suspected?	Retrograde urethrogram (RUG)

CHAPTER 24

Neurosurgery

BASICS

Determine the location of the following within the brain:	
Executive functioning	Frontal lobe
Decision making	Frontal lobe
Restraint of emotions	Frontal lobe
Motor strip	Precentral gyrus (frontal lobe)
Sensory strip	Postcentral gyrus (parietal lobe)
Broca's area	Posterior inferior frontal lobe (usually the left side)
Spatial orientation	Parietal lobe
Wernicke's area	Posterior superior temporal lobe (usually the left side)
Emotion	Amygdala (temporal lobe)
Memory	Hippocampus (temporal lobe)
Modulation of movement	Basal ganglia (caudate, putamen, globus pallidus)
Visual cortex	Occipital lobe (although optic radiations (Meyer's loops) course through the temporal lobe)
Lesions of the thalamus result in what type of deficits?	Purely sensory
Internal capsule?	Purely motor Strokes that involve the internal capsule often involve areas of the homunculus supplied by different vessels (ie, leg and arm).

Copyright © 2008 by The McGraw-Hill Companies, Inc. Click here for terms of use.

079_BOOKZ

What is the major motor tract?	Corticospinal
What are the two major sensory tracts?	Spinothalamic (pain/temperature) and medial lemniscus (light touch/proprioception/vibration)
Determine where each tract decussates:	
Dorsal column medial leminscus	Lower medulla
Spinothalamic	Level of entry into the spinal cord
Corticospinal	Brainstem–spinal cord (cervicomedullary) junction
Hemisection of the spinal cord is referred to as what syndrome?	Brown-Séquard syndrome
What are the findings (below the lesion) in this syndrome?	• Ipsilateral loss of motor and light touch below level of lesion • Contralateral loss of pain sensation below level of lesion

LESION

Localization

Vermian lesions of the cerebellum lead to what deficit?	Truncal ataxia
What do lateral/hemispheric cerebellar lesions cause?	Incoordination/intention tremor in extremities
Do cerebellar lesions lead to contralateral or ipsilateral deficits?	Ipsilateral deficits
Will the patient demonstrate a positive Romberg sign?	No, with cerebellar defects they will sway with/without the eyes open. Two-thirds of the following must be intact to maintain balance or else a patient will have a positive Romberg's sign: vision, vestibular sense and proprioception.
What structure makes cerebrospinal fluid (CSF)?	Choroid plexus
Where is this located?	Lateral ventricles (body, trigone, inferior horn); foramen of Monro; roof of third ventricle; roof of fourth ventricle

What foramen connects the lateral and third ventricles?	Foramen of Monro
What foramen connects the third and fourth ventricles?	Cerebral aqueduct (of Sylvius)
What foramen connects the fourth ventricle and subarachnoid space?	Foramen of luschka (lateral) and foramen of magendie (midline)—drain
What is the most sensitive indicator of hydrocephalus?	Enlargement of temporal horns of lateral ventricles. Also, look for bowing of the corpus callosum.
Diffuse enlargement of the ventricular system suggests what type of hydrocephalus?	Communicating hydrocephalus. Fourth ventricle may be normal size due to confinement in posterior fossa.
Where does the obstruction lie in communicating hydrocephalus?	Arachnoid granulations within the subarachnoid space
What are the two most common causes of communicating hydrocephalus?	1. Subarachnoid hemorrhage 2. Meningitis **Note:** Result in "clogging" (reabsorption) of the "drains" (arachnoid granulations) and, rarely, from overproduction of CSF.
What are common causes of noncommunicating (obstructive) hydrocephalus?	• Aqueductal stenosis • Colloid cyst, which occlude foramen of Monro • Chiari malformation (Type I–IV) • Tumors
What are the signs/symptoms of hydrocephalus?	Cognitive deterioration, nausea/vomiting, headache/neck pain, ataxia, vision changes (blurry vision from optic nerve compression/palsy from sixth nerve compression), drowsiness
What is the treatment for hydrocephalus?	Treat underlying cause such as subarachnoid hemorrhage (SAH), meningitis, tumor, etc. However, decrease CSF production with lasix or diamox and treat with repeated lumbar punctures (LPs) or shunt placement to decrease intracranial pressure (ICP).

Normal pressure hydrocephalus is determined by the following:	Typically patients >60 years old
Three signs	Enlarged ventricles, normal opening pressure, absence of papilledema
Three symptoms	Gait ataxia, dementia, incontinence (wet, wacky, wobbly)
Determine the location of the lesion:	
Left hemiplegia	Right hemispheric lesion
Decorticate posturing	Deep cerebral/thalamic lesion
Decerebrate posturing	Midbrain or pontine lesion
General flaccidity	Medullary lesion
What is the Monro-Kellie doctrine?	States that the cranial vault is a fixed volume and any increase of mass in that volume will increase pressure (see Fig. 24-1).

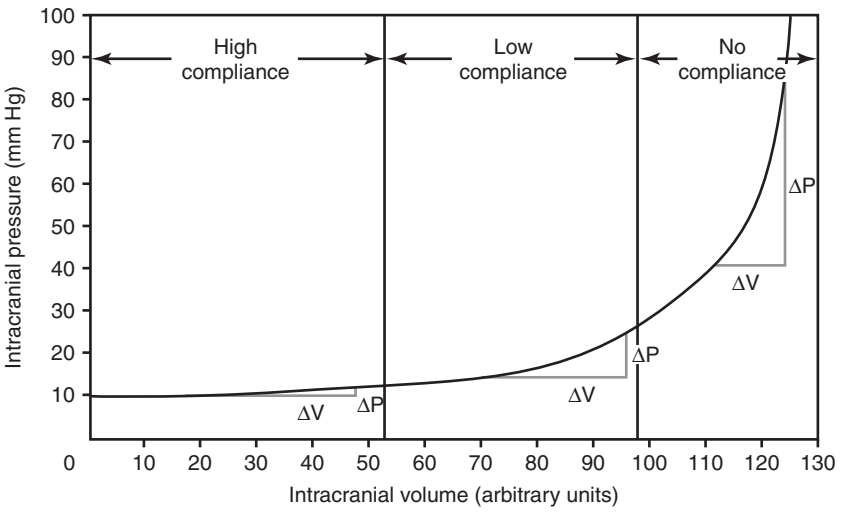

Figure 24-1 Relationship of intracranial volume and intracranial pressure. Notice the exponential relationship after compensatory mechanisms fail.

What range is considered to be normal intracranial pressure (ICP)?	4–14 mm Hg
What are three mechanisms that may raise ICP?	Increase in the volume of contents within the cranial vault: **Blood**: extravasation or vasodilation (hyperemia)

	CSF: hydrocephalus, which produces too much CSF or inadequate drainage **Brain**: edema, tumor, abscess
What range is considered normal cerebral perfusion pressure (CPP)?	70–100 mm Hg
How is CPP calculated?	CPP = MAP – CP
Autoregulation of cerebral blood flow (CBF) occurs over what range of mean arterial pressure (MAP)?	50–150 mm Hg
ICP that passively follows MAP suggests what?	Vasoparalysis (loss of autoregulation causes vessels to become maximally dilated) • A ↓ in MAP results in ischemic watershed areas of the brain causing ↑ permeability of blood-brain barrier (BBB) to crystalloids and worsening brain edema, thus ↑ ICP.
How can blood pressure be increased in hypotensive traumatic brain injury patients?	Use of vasopressors and isotonic colloid solutions. Avoid hypotonic solutions, 5% dextrose in water or Lactated Ringer's (LR) solution as these will ↑ cerebral edema.
A 25-year-old obese female presents with episodic blurring of the vision and nonspecific headaches that worsen with bending over. physical exam reveals papilledema. Head computed tomography (CT) is reported as normal. LP is performed which shows elevated opening pressure. What is the likely diagnosis?	Pseudotumor cerebri (idiopathic intracranial hypertension). Suspected cause due to increased resistance at arachnoid granulations.
What must be ruled out—what test should be ordered?	Dural sinus thrombosis, diagnosed with magnetic resonance venography (MRV) (contrast/noncontrast CT may detect thrombosis). More common with hypercoagulable state (pregnancy, factor V Leiden, etc).
What complication arises if untreated?	Increased ICP leads to optic nerve atrophy and progressive loss of vision.
What medical tx is available?	Reduction of ICP with acetazolamide (short-term high dose steroids may also be beneficial.)

The patient develops progressive visual field loss with medical management. What are two surgical options?

Lumboperitoneal (or ventriculoperitoneal) shunt and optic nerve fenestration

Note: Also test for systemic lupus erythematosus (SLE) (or other connective tissue diseases) and Lyme disease as these are associated with intracranial hypertension (ICH).

What are the two types of cerebral edema?

1. Vasogenic
2. Cytotoxic

What is each associated with?

- Vasogenic: most common, blood brain barrier (BBB) breakdown. Associated with tumor, trauma, infection, hypertonicity.
- Cytotoxic: preservation of BBB. Associated with infarction.

What are signs/symptoms of increased intracranial pressures (ICP)?

- Headache.
- Nausea/vomiting.
- Mental status changes.
- Papilledema causes loss of visual acuity.
- Sixth nerve palsy.
- Bulging fontanel (pediatric patients).

Note: Signs/symptoms are related to the rate of edema formation, not necessarily the amount of edema present.

What is Cushing's triad?

Classic presentation of ↑ ICP (although late manifestation, indicates irreversible neurologic changes)

- Hypertension (HTN)
- Bradycardia
- Irregular respirations (bradypnea)

Note: As ICP ↑, the brain attempts to autoregulate cerebral blood flow (CBF) by ↑ MAP.

How is ICP measured?

- Opening pressure via lumbar puncture (remember to rule out space occupying lesions with head CT!)
- Subarachnoid bolt
- Ventriculostomy
- Intraparenchymal monitoring

079_BOOKZ

How is an acute increase in ICP managed?

- Secure airway and ↑ ventilation. (Obtunded patients have ↓ respiratory drive causing hypoxia, vasodilation, and worsening ICP—maintain $PaCO_2$ ~35 mm Hg.)
- Elevate head of bed (HOB) to promote venous drainage.
- Mannitol (max serum 300 mOsm/L—monitor and treat possible hypotension with fluid replacement to maintain cerebral perfusion pressure >70 mm Hg).
- Hypertonic saline (2–3% for goal serum Na of 145–155).
- Seizure prophylaxis (ie, levetiracetam).
- Monitor body temperature. (Patients may become poikilothermic and cannot regulate temperature.)
- Second-tier options for refractory ICP:
  - Barbiturates (monitor with daily head CT, Swan-Ganz [for cardiosuppression], and cultures [may not develop leukocytosis with infection])
  - Hypothermia (↓ metabolism)
  - Hyperventilation ($PaCO_2$ <30 mm Hg)
  - Decompressive craniectomy
  - Hypertensive therapy

An obtunded patient with hypertension has given a head CT which demonstrates a hemorrhage in the posterior fossa causing mass effect and compression of the fourth ventricle. How should this patient be treated?

Emergent ventriculostomy (intraventricular catheter) and suboccipital craniectomy—because the volume in the posterior fossa is small, lesions causing mass effect need emergent neurosurgical evaluation to avoid herniation that may rapidly occur.

Determine the likely herniation (see Fig. 24-2):

Most common, usually involves cingulate gyrus, often clinically silent although may have lower extremity weakness or loss of bladder control

Subfalcine/cingulate herniation (may compress and cause infarction along anterior cerebral artery [ACA] territory)

079_BOOKZ

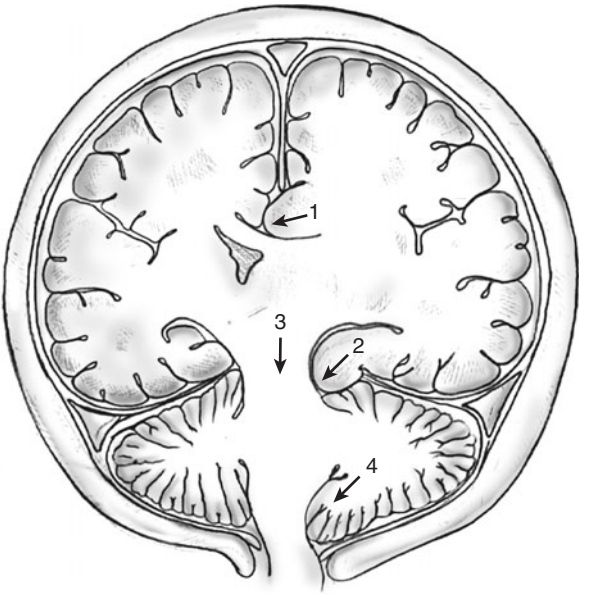

Figure 24-2 Schematic drawing of brain herniation patterns. 1. Subfalcine herniation. The cingulate gyrus shifts across midline under the falx cerebri. 2. Uncal herniation. The uncus (medial temporal lobe gyrus) shifts medially and compresses the midbrain and cerebral peduncle. 3. Central transtentorial herniation. The diencephalon and midbrain shift caudally through the tentorial incisura. 4. Tonsillar herniation. The cerebellar tonsil shifts caudally through the foramen magnum.

Ipsilateral mydriasis, abnormal external oblique muscle (EOM), ipsilateral hemiparesis, contralateral homonymous hemianopia	Transtentorial (uncal or central) herniation (compression of posterior cerebral artery (PCA) causes visual field defects, compression of cranial nerve (CN) III causes mydriasis and abnormal EOM, compression of crus cerebri causes hemiparesis (corticospinal tract), may compress aqueduct of Sylvius causing hydrocephalus
Often caused by posterior fossa mass effect or lumbar puncture, presents as sudden or progressive cardiorespiratory arrest, hypertension, irregular respiratory rate, bradycardia	Transtentorial herniation (classic triad)

Coma, fixed and dilated pupil(s), decerebrate posturing	Cerebellar tonsillar herniation (compress cardiac and respiratory center in medulla, may result in a Cushing's response)
Where are Duret hemorrhages located?	Midbrain and upper pons
What are they associated with?	Transtentorial herniation—caused by stretching of the upper branches of the basilar artery as the midbrain descends
Determine the location of the lesion based on the following respiratory patterns:	
Slow, gasping pattern with prolonged inhalation?	Pons (apneusis)
Irregular pattern of grouped respiration	Medulla (cluster breathing)
Posthyperventilation apnea	Forebrain (normally after hyperventilation respiration resumes at a regular rate with a lower tidal volume)
Rapid, deep respiration?	Midbrain (central neurogenic hyperventilation)
Rapid clustering of breathing with constant, shallow tidal volumes, alternating with periods of apnea?	Medulla (Biot's breathing)—stroke or herniation (uncal or tentorial)
Rapid clustering of breathing with crescendo/decrescendo tidal volumes, alternating with periods of apnea?	Bihemispheric lesions or lesions in the basal ganglia (Cheyne-Stokes—can be found in strokes, head injury/tumor, congestive heart failure (CHF), opiate overdose, altitude sickness)
Rapid, deep breathing (similar to central neurogenic hyperventilation) also occurs in what condition?	Severe diabetic or uremic acidosis
What is this breathing pattern?	Kussmaul's respiration (metabolic acidosis is partially corrected by the respiratory alkalosis.)

Determine the location of the lesion based on pupillary examination:	
Pinpoint (1 mm), ocular bobbing	Pons
Fixed 4–5 mm (midrange), midposition	Midbrain
Dilated (6 mm +), wandering eye movements	Cortex
Constricted (2–3 mm), down and inward	Basal ganglia
Horner's with preserved response to light, downbeat nystagmus	Medulla
What is "locked in" syndrome?	Syndrome associated with complete paralysis of voluntary muscles; however, vertical eye movements and blinking are often preserved
What are two causes?	Central pontine myelinolysis (correction of long standing hyponatremia quickly) and pontine stroke (proximal or middle portion of basilar artery)
Where is the lesion/what area is spared?	Infarction/demyelination of the basis pontis—the tegmentum is spared preserving consciousness and vertical eye movements
Cerebral contusions at the site of impact are what type of injury?	Coup injury
Cerebral contusions opposite the site of impact are what type of injury?	Contrecoup injury
Determine the area of injury with:	
Decerebrate posturing	Extensor posturing occurs w/ disinhibited spinocerebellar tone from injury between midbrain and pons
Decorticate posturing	Flexor posturing occurs with deep cerebral or thalamic lesions
A restrained passenger of a motor vehicle accident arrived at the emergency room unconscious. Head CT at the time of arrival was normal; however, the patient remains in a persistent vegetative state. What is the likely diagnosis?	Diffuse axonal injury—DAI (associated with deceleration injuries)

079_BOOKZ

What would be the next step in diagnosis?	Magnetic resonance imaging (MRI)—characteristic findings are multifocal white matter abnormalities (Unlike multiple sclerosis [MS], DAI typically will not involve the spinal cord.)
A patient is found unconscious. What are the common conditions associated with altered level of consciousness?	**V**ascular occlusions/hemorrhage (emboli/MI, thrombosis/PE, cerebral hemorrhage usually presents as acute onset coma, SAH may not have any change in consciousness), *shock* (cardiogenic, septic, hemorrhagic, etc) • Central nervous system **i**nfections (eg, encephalitis, meningitis) (cerebral abscess presents similarly to neoplasm/expanding mass) • **I**ntracranial **n**eoplasms (progressive course) • **M**etabolic disorders (eg, **diabetes mellitus/hypoglycemia**, uremia, poisoning/medication/drug (opiate), electrolyte imbalance (often cause arrhythmia), hypoxia/hypercapnia), status epilepticus **Note: V**ery **I**mportant **N**eurologic **M**ishaps
Determine the following type of skull fractures:	
Multiple fractures creating fragments of bone	Comminuted fracture
Fractured fragment is displaced inward	Depressed fracture
Single break in the skull without splintering, depression, or distortion of bone	Linear fracture (may cause sutural diastasis, epidural hematoma, or venous sinus thrombosis if it runs through a suture, vascular channel, or venous sinus groove, respectively)
Fracture associated with disruption of overlying skin	Compound/open fracture
Multiple fracture lines radiating from a point	Stellate fracture

Which two fractures typically require surgical intervention?	Compound (thorough debridement to prevent infection/abscess) and depressed fractures (to reapproximate fragment and evaluate for lacerations of the dura, brain, or vessels)
What complication is associated with depressed skull fractures?	Posttraumatic epilepsy (more common if patient looses consciousness >2 h, dural tear is present, and has seizures within the first week of injury)
Determine location of fracture:	
Hematotympanum	Petrous ridge fracture
Periorbital ecchymosis and subconjunctival hemorrhage	Anterior basal fracture (cribriform plate if associated with rhinorrhea)
Ecchymosis behind the ear	Basilar fracture (ecchymosis behind the ear known as Battle's sign) may also be associated with otorrhea.
How can one quickly determine if CSF is mixed with blood?	Ring-halo sign: a drop of fluid is placed on a gauze. If CSF is present it will form a double ring (dark center containing blood components and light halo of CSF).
What laboratory test is used to confirm the presence of CSF?	Beta-transferrin
Presence of CSF rhinorrhea or otorrhea indicates what type of injury?	Dural injuries
How is this treated?	>90% basilar fractures heal spontaneously with 1–2 weeks of head of bed elevation (prophylactic antibiotics for select patient group, ie, previous sinus surgery or preexisting sinusitis)—surgery may be needed for CSF leaks from the anterior skull base.
Determine the location of the hematoma following injury to:	
Aneurysm	SAH
Bridging veins between dura and cortical tissue	Subdural hematoma

Small perforating arteries	Intraparenchymal (intracranial) hemorrhage
Meningeal artery	Epidural hematoma (most often middle meningeal artery following fracture of temporal bone)
Arteriovenous malformation	Intraparenchymal (although intraventricular or SAH can occur.)
Determine the hemorrhage (SAH, epidural, acute subdural, or chronic subdural) based on the following signs/symptoms.	
Immediate, transient loss of consciousness followed by a lucid interval that progressively deteriorates	Epidural hematoma (although less than 20% develop these classic signs.)
Noncontrast CT shows concave (crescentic) hyperdensity	Acute subdural hematoma
Progressive: headache, personality changes (often confused with dementia), or hemiparesis/plegia	Chronic subdural hematoma
Sudden onset severe headache (thunderclap headache), photophobia, low back pain, neck stiffness	SAH (low back pain, photophobia, and neck stiffness indicate meningeal irritation) although physical exam may be normal
Noncontrast CT shows convex (lenticular) density	Epidural hematoma
History of severe headaches	SAH (may have history of herald headaches before sentinel bleed—often from saccular aneurysms)
Noncontrast CT shows concave (crescentic) hypodensity	Chronic subdural hematoma (50% have bilateral hematomas)—during subacute phase (48–72 h) lesion may be isodense and missed on noncontrast CT, therefore contrast enhanced CT or MRI is recommended
Hyperdensity within the cisterns, sylvian fissure, ventricles, or sulci	SAH—Findings may be subtle! (Look for blood in the dependent portions of the head during CT: sylvian fissures, temporal horns of lateral ventricles, and interpendicular fossao)

A patient is suspected to have a subarachnoid hemorrhage. Noncontrast head CT is negative for any acute bleed and does not demonstrate mass effect. What is the next step to determine diagnosis?

Lumbar puncture if no mass effect. Remember to collect multiple tubes of CSF, during a "traumatic tap" the blood will clear in the last tube as compared to the first. In an SAH the blood in the CSF will remain constant. 15% of head CTs may be negative.

After SAH is found on CT, what imaging study must be done?

Four vessel angiography, to image the vertebrals and carotids to evaluate for aneurysm

What are the two modes of treating cerebral aneurysms?

1. Open surgical: more definitive, use in young patients who can tolerate.
2. Interventional radiology coiling to thrombose aneurysm: use in older patients with comorbidities or patients with saccular type aneurysms.

A 40-year-old who presented with SAH is doing well 1 day after coiling of a cerebral aneurysm. She suddenly develops difficulty speaking, facial droop, and hemiparesis.

What is the diagnosis?

Cerebral artery vasospasm (middle cerebral artery [MCA] distribution in this case)

What is the treatment?

Cerebral angiogram and intra-arterial calcium channel blocker or papaverine

What is the preventative treatment?

Prophylactic calcium channel blocker

Intraparenchymal hemorrhages are most often associated with what two conditions?

- Hypertension
- Amyloid angiopathy

Note: Other causes include: arteriovenous malformations (AVMs), aneurysms, tumors, fungal infections, venous thrombosis, hemorrhagic conversion of ischemic infarct, bleeding disorders, anticoagulation therapy, vasculitis.

Where are the three common locations for a hypertensive hemorrhage?

- Basal ganglia
- Thalamus
- Pons

Hemorrhages from amyloid angiopathy typically occur in what part of the brain?

Along small cortical vessels causing superficial, lobar hemorrhages

079_BOOKZ

How are intraparenchymal hemorrhages managed?	Depends on etiology, however, most managed medically (control blood pressure, coagulation defects, seizures, ICP)
What two conditions require urgent surgical intervention?	1. Hemorrhages leading to significant mass effect 2. Infratentorial hemorrhages (due to high probability of herniation)
Determine the type of vascular malformation:	
Dilated blood vessels without intervening normal brain	Cavernous angiomas
Dilated capillary tufts with intervening normal brain	Telangiectasia (presence of normal tissue separates this from cavernous angiomas)
Shunts between arteries and veins without intervening normal brain	Arteriovenous malformation (although any vascular malformation can be symptomatic the higher flow rates with AVM can produce seizures, hemorrhages, or a vascular steal phenomenon.)
Venous network with intervening normal brain	Venous angioma
A 25-year-old patient presents with worsening level of consciousness, headache, and hypertension. A noncontrast head CT demonstrates an acute intraparenchymal hemorrhage. What is the likely etiology?	Drug abuse (eg, cocaine) or vascular malformation **Note:** In a young patient also consider trauma, tumor (metastasis, glioblastoma multiforme [GBM], oligodendroglioma), fungal infection (if immunocompromised), bleeding diathesis (coagulopathy, sickle cell), postpartum vasculopathy, or eclampsia.
What is a temporary (<24 h) neurologic deficit from occlusive vascular disease?	TIA (transient ischemic attack)
What is the deficit that resolves within 1 day—1 week?	RIND (reversible ischemic neurologic deficit)
What is the permanent deficit?	CVA (cerebrovascular accident)
What are the most common causes of ischemic stroke?	Embolic occlusion. Therefore, search for potential sources during ischemic strokes and thrombosis, which occur typically in small vessels.

What are common sources of emboli causing ischemic strokes?	• Heart: atrial fibrillation, dilated cardiomyopathy, hypokinetic left ventricle (especially following MI), myxoma, valvular vegetations (mitral stenosis, prosthetic valves, endocarditis), paradoxical emboli (patent foramen ovale) • Extracranial arteries: atheromatous aortic arch or carotid bifurcations
Determine the artery occluded in the following ischemic strokes:	
Ipsilateral: limb ataxia, facial sensory loss, Horner's syndrome/ contralateral—body sensory loss/ dysarthria, dysphagia	Posterior inferior cerebellar artery (PICA) (lateral medullary syndrome/Wallenberg's syndrome)
Contralateral homonymous hemianopsia, dyslexia	PCA
Contralateral lower extremity weakness, personality changes	ACA
Contralateral face and arm weakness/numbness, language deficits	Middle cerebral artery (MCA) (language deficits if stroke is on dominant hemisphere)—absence of aphasia may indicate an internal capsule infarction.
In a suspected stroke, what imaging study should be performed immediately?	Noncontrast head CT to differentiate between ischemic or hemorrhagic stroke
What blood test should be performed?	Blood glucose as hypoglycemia can mimic stroke and hyperglycemia is associated with a worse prognosis. Also, check a coagulation panel and a platelet count for possible thrombolytic therapy.
What are the goals of treating a patient with ischemic stroke?	1. Maintain perfusion to the ischemic penumbra (watershed zone) by allowing elevated blood pressure. 2. Reopen the occluded vessel. 3. Prevent further episodes.
Why is heparin avoided in large hemispheric ischemic strokes or strokes due to endocarditis?	High incidence of hemorrhagic conversion

What are the contraindications to tPA (tissue plasminogen activator) tx?

- sx onset >3 h. Always determine when deficits began.
- Blood pressure (BP) > (systolic) 185 or (diastolic) 110
- Prior intracranial hemorrhage
- Major surgery in past 2 weeks
- Gastrointestinal (GI) or genitourinary (GU) hemorrhage in past 3 weeks
- Platelet <100,000 mm^3
- Arterial puncture in past week
- Seizure at stroke onset
- Recent MI
- International normalized ratio (INR) >1.7
- Improving sx

What is the recommended BP to maintain perfusion in the penumbra in patients who cannot receive tPA?

160–180 mm Hg systolic BP

What is the recommended IV fluid?

NS (normal saline). Do not give glucose as this permits anaerobic metabolism creating local lactic acidosis, thereby injuring the penumbra.

What are the surgical indications for hemorrhagic stroke?

- Infratentorial hemorrhage, which has a high likelihood for herniation
- Significant mass effect

What surgery is indicated?

Decompressive craniectomy in addition to controlling the bleeding

SPINAL CORD INJURIES

Hypotension and bradycardia following a spinal cord injury (SCI) to the cervicothoracic junction indicates what?

Injury to the sympathetic chain leading to neurogenic shock

Note: Remember, any patient with assumed injury to the spine should be assumed to have multiple foci of injuries along the spine.

How is neurogenic shock treated?

Volume resuscitation and pressors. Monitor for intact sympathetic innervation and always secure airway in neurologically impaired patients as they have increased risk of aspiration and may develop irregular breathing patterns and hypoventilation.

Following placement of a Foley catheter a patient becomes anxious and complains of headache and blurry vision. The patient's face becomes flushed and he begins sweating. Bradycardia and a significant increase in blood pressure are noted along with piloerection and pallor within the extremities. What is the likely diagnosis?	Autonomic dysreflexia
Explain these findings.	After spinal shock, spinal cord injuries above major splanchnic sympathetic outflow (T5) regain autonomic reflexes. Noxious stimuli below the injury causes stimulation of sympathetic nervous system. Inhibitory outflow from cerebrum cannot cross SCI, although parasympathetic outflow from the vagus causes bradycardia. The result is HTN and sympathetic effects below the SCI and parasympathetic effects above the SCI.
Determine the characteristic neurologic deficits for the following four patterns of SCI:	
Complete SCI	Total loss of motor and sensory function below level of injury, from vertebral subluxation injuries
Hemisection of spinal cord	Results in Brown-Séquard's syndrome
Anterior SCI	Paralysis and loss of pain and temperature sensation—anterior cord syndrome from loss of spinothalamic and corticospinal tracts, from disc herniation or ischemia from anterior spinal artery occlusion
Central SCI	Upper extremity > lower extremity deficits, varying degrees of numbness > weakness, from transient compression of cord by ligamentum flavum buckling during hyperextension

079_BOOKZ

What are the boundaries of the three columns of the spine (see Fig. 24-3)?

1. Anterior column—anterior longitudinal ligament to anterior two-thirds of the vertebral bodies
2. Middle—posterior one-third of the vertebral bodies to posterior longitudinal ligament
3. Posterior—posterior to the posterior longitudinal ligament

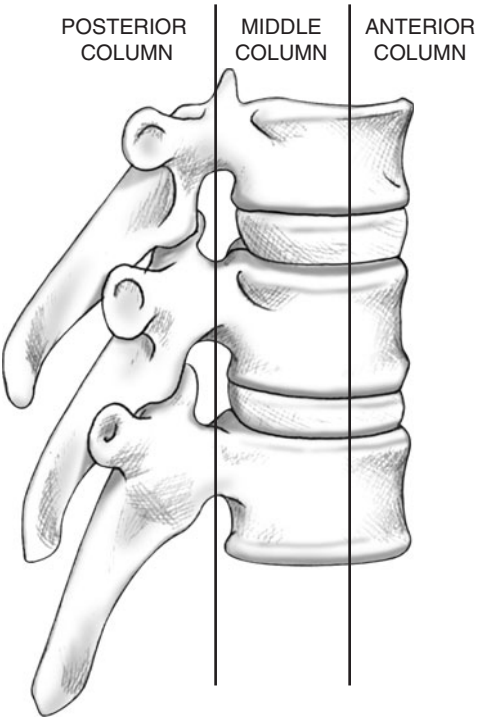

Figure 24-3 Structural columns of the spine.

What is the most important distinction that must be made with any spine injury?

Stable vs unstable

What two structural elements can be injured to produce an unstable spine?

Bones and ligaments

What are the three rules of unstable spine fractures?

1. Two or more columns injured is an unstable spine.
2. Bones heal, ligaments don't. While nondisplaced fractures can be treated nonoperatively, ligament injuries require fixation.
3. Neurologically symptomatic spine injuries are always unstable.

What are common complications of spinal injuries?

- Pressure ulcers.
- Ileus, which can last as long as 2 weeks. Feeding during this time can result in aspiration.
- Deep vein thrombosis (DVT). Treat with compression boots and/or sub-q heparin.
- Cholecystitis.
- Renal stones, which may lead to pyelonephritis and renal failure.

PERIPHERAL NERVE INJURIES

Define the following peripheral nerve injuries:

Neurapraxia	Temporary failure without axonal injury. No degeneration occurs.
Axonotmesis	Disruption of axons and myelin with intact surrounding connective tissue. Undergoes proximal and distal/Wallerian degeneration.
Neurotmesis	Disruption of axons and surrounding connective tissue. Ability to regenerate depends on the extent of connective tissue damage and undergoes proximal and distal/Wallerian degeneration.

How quickly will a repaired peripheral nerve regenerate its axons along the nerve?

1 mm/day. This can be tested on physical exam by doing a Tinel's test: tapping nerve tract with examiners finger produces electric shock sensation at level of growth.

Following a burn injury or SCI, why should succinylcholine be avoided as a paralytic?

Succinylcholine is a depolarizing agent. Nerve regeneration transiently increases the number of end plates, causing an increase in the incidence of malignant hyperthermia and hyperkalemia.

How should injuries to peripheral nerves be managed?

Electromyography 4-weeks postinjury, which allows time for Wallerian degeneration and axonal regeneration.

079_BOOKZ

- Observe if function is improving.
- Surgery if no improvement in function.
  - Observe if intra-op electrical study reveals conduction.
  - Nerve anastomosis if no conduction is revealed.

Anastomosis under tension will not heal. Why is the sural nerve harvested to bridge the gap?

It carries only sensory information and leaves a minor deficit when resected.

What is the order of the brachial plexus (see Fig. 24-4)?

"**R**andy **T**ravis **D**rinks **C**old **B**eers."

1. **R**oots: from anterior rami of 5 spinal nerves (C5-8, T1)
2. **T**runks: from merging of roots
   - Superior/upper: C5, C6
   - Middle: C7
   - Inferior/lower: C8, T1
3. **D**ivisions: trunks divide = 6 divisions

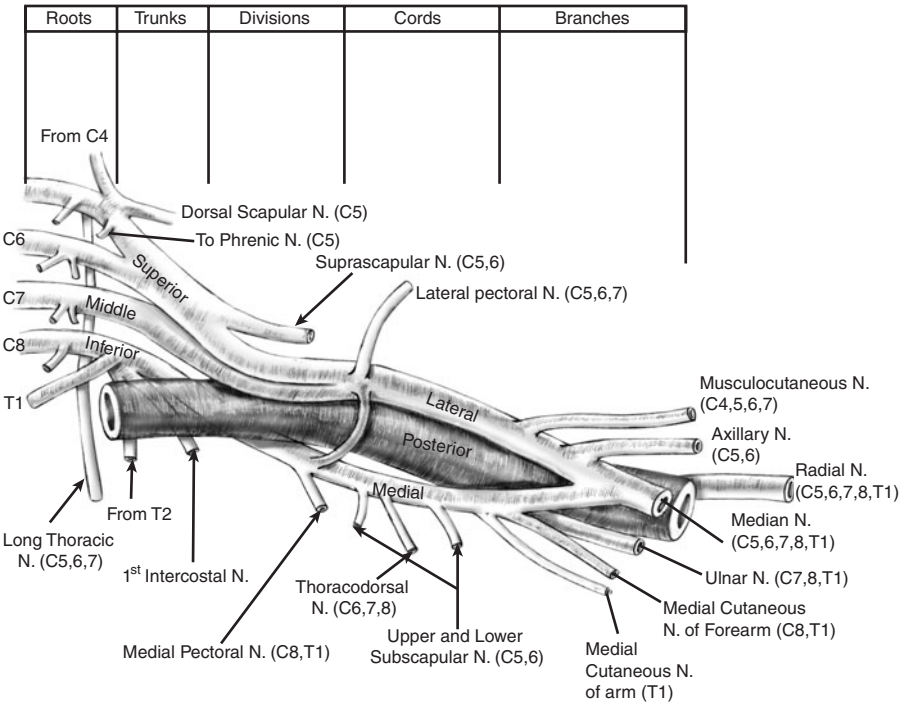

Figure 24-4 Organization of the brachial plexus. [*Reproduced, with permission, from Brunicardi CF et al (eds): Schwartz's Principles of Surgery, 8th ed. New York: McGraw-Hill, 2005:1725.*]

- Anterior—of upper/middle/lower trunks
- Posterior—of upper/middle/lower trunks

4. **C**ords: regrouping of divisions = 3 cords—named w/ respect to axillary artery
   - Posterior: from posterior divisions (C5-T1)
   - Lateral: from anterior upper/middle (C5-C7)
   - Medial: continued lower trunk (C8-T1)
5. **B**ranches: 5 major branches:
   - Radial nerve—C5-T1
   - Axillary—C5-C6
   - Median—C8-T1
   - Ulnar—C8-T1
   - Musculocutaneous—C5-C7

Determine the nerve affected with the following scenarios:

Injury typically occurs w/ humerus fractures, improper crutch use, or improper positioning during sleep ("Saturday night palsy") and presents w/ wrist drop.	Radial nerve. May also have tricep weakness in addition to wrist drop if injury is proximal.
Numbness involving the fourth and fifth fingers, worsened by golf or tennis.	Ulnar nerve. Usual sites of compression are at the wrist or elbow.
A 30-year-old female presents with complaints of arm and hand paresthesia that worsens at night. On exam there is supraclavicular tenderness, mild weakness, and paresthesia along the ulnar distribution. What is the likely diagnosis?	Thoracic outlet syndrome. Three causes: 1. Neurogenic: typically involves lower nerve roots (C8, T1) along ulnar distribution; associated with paresthesia (worse at night), mild weakness. Most common. 2. Venous: subclavian vein obstruction. Pain worsens with activity, edema/cyanosis of extremity, dilated neck veins. 3. Arterial: subclavian artery obstruction. Diminished pulses, pallor, pain, etc.
What imaging test should be done?	X-ray: look for cervical ribs or bands. Also vascular studies (angiogram/duplex) and electromyogram (EMG).

079_BOOKZ

What symptoms need urgent care? What is the tx?	Vascular (venous and arterial). Patient may need heparinization, thrombectomy, and/or surgical exploration.
A patient develops leg pain when walking. Upon further questioning the patient states the pain has progressively gotten worse over the last year, describes a dermatomal distribution, and relief with resting, sitting, or leaning forward. What is the likely cause of pain?	Neurogenic claudication usually from degenerative lumbar stenosis that causes compression of the cauda equina. Vascular claudication typically involves a stocking distribution, quickly resolves with rest, and is associated with pale, cold feet. Hair loss may also be present.
A patient with a history of lung cancer presents with low back pain and decreased sensation in both thighs. Also, the patient complains of difficulty urinating and has recently developed urinary incontinence. A Foley is placed which drains 500 cc urine. What is the likely diagnosis?	Cauda equina syndrome. Can be caused by any mass lesion pressing on cauda equina such as herniated disc, epidural abscess or hematoma, tumor/lymphoma, sarcoid. Typical s/s include saddle type sensory loss, back pain, bowel incontinence, overflow urinary incontinence.
What is the tx?	Inflammatory conditions, use steroids; tumors, use steroids and radiation. Surgery may be used for decompression if needed.
How is the level of consciousness evaluated?	Glasgow Coma scale (Table 24-1)
What is measured to determine the score?	Three components: • Motor • Verbal • Eye-opening
What is the minimum score possible?	Scores range from 3 to 15. Coma is defined as GCS <8.

Table 24-1 Glasgow Coma Scale[a]

Motor Response (M)	Verbal Response (V)	Eye-Opening Response (E)
Obeys commands 6	Oriented 5	Opens spontaneously 4
Localizes to pain 5	Confused 4	Opens to speech 3
Withdraws from pain 4	Inappropriate words 3	Opens to pain 2
Flexor posturing 3	Unintelligible sounds 2	No eye opening 1
Extensor posturing 2	No sounds 1	
No movement 1		

[a]Add the three scores to obtain the Glasgow Coma Scale score, which can range from 3 to 15. Add "T" after the GCS if intubated and no verbal score is possible. For these patients, the GCS can range from 2T to 10T. [*Reproduced, with permission, from Brunicardi CF et al (eds): Schwartz's Principles of Surgery, 8th ed. New York: McGraw-Hill, 2005:1613.*]

079_BOOKZ

Describe the following levels of consciousness:	
Responds to noxious stimuli only	Stuporous/obtunded
Awake and oriented	Alert
Easily aroused and able to maintain arousal	Lethargic
Not responsive to noxious stimuli	Comatose
Easily aroused though requires stimuli to maintain arousal	Somnolent

CNS TUMORS

What are the two most common causes of cancer in the pediatric population?	1. Leukemia 2. Brain tumor, which is the most common solid tumor encountered **Note:** Brain tumors occur along a bimodal distribution with peaks around 5 and 50 years of age.
Tumors arising in patients younger than 15 years of age typically occur in what area of the brain?	Infratentorial (70%)
Patients older than 15 years of age?	Supratentorial (70%)
What is the most common central nervous system (CNS) neoplasm?	Metastatic lesions comprise ~50% of all CNS neoplasms.
What are the most common primary CNS neoplasms?	1. Glioma: ~60% of primary CNS neoplasms (astrocytoma most common) 2. Meningioma: ~20% (although many are asymptomatic and undiagnosed.) 3. Pituitary adenoma: ~10%
Supratentorial lesions typically present with what sx?	Focal neurologic deficits (limb weakness, visual field deficit, seizure, headache)
What are the typical sx for infratentorial lesions?	Increased ICP from hydrocephalus (compress fourth ventricle)—headache, nausea, vomiting, diplopia
What are the two most common sources for cerebral metastases?	1. Lung (especially small cell) 2. Breast, followed by kidney, GI, and melanoma

079_BOOKZ

Where is the most common location for cerebral metastases?

Gray-white junction, followed by cerebellum and meninges

Metastases to the meninges lead to what condition?

Leptomeningeal carcinomatosis (also known as carcinomatous meningitis), most common among breast cancer

What are common complications of meningeal metastases?

- ↑ ICP/hydrocephalus (obstruct CSF)
- Infarction (invading local vessels)
- Cranial nerve palsies or radiculopathies, due to invasion of brain/spinal cord
- Seizures, due to altered local metabolism

What is the characteristic appearance of metastases on CT/MRI (postcontrast)?

Round, multiple, and well circumscribed

What does enhancement of lesions postcontrast suggest?

Breakdown of BBB: a general rule is more aggressive tumors form fenestrated capillaries, while low-grade neoplasms have normal capillaries and, therefore, will not enhance. However, highly vascular low-grade neoplasms may show enhancement.

How can one distinguish if a tumor is arising from within the brain or outside the brain on an imaging study?

Look for "white matter buckling." Lesions outside the brain typically cause the white matter to indent from the mass effect. Exceptions arise in cases where extensive white matter edema is present. Intraparenchymal lesions typically expand the white matter and blur the gray-white junction.

What is the significance of a large amount of edema surrounding a tumor?

Amount of edema is typically associated with the rate of growth of a tumor ➔ large amount of edema = fast growing tumor

What are the four types of glial cell tumors?

1. Astrocytoma (glioma often used to refer specifically to astrocytoma)
2. Oligodendroglioma
3. Ependymoma
4. Choroid plexus papilloma

What is a grade IV astrocytoma?

Glioblastoma multiforme (GBM), which account for ~60% of astrocytomas. Grades I/II are low-grade astrocytoma, grade III is anaplastic astrocytoma.

What radiographic feature is needed to diagnosis a GBM?	Necrosis, which is only present with GBM
What two tumors may spread across the corpus callosum?	1. GBM 2. CNS lymphoma
What is the most common astrocytoma found in children?	Pilocytic astrocytoma
Tumors arising within the optic nerve or chiasm are associated with what genetic condition?	Neurofibromatosis 1. Other common locations for pilocytic astrocytomas include the frontal lobe, hypothalamus, and cerebellum.
What astrocytoma commonly arises superficially in the temporal lobes of children?	Pleomorphic xanthoastrocytoma, which may appear malignant as they can involve the leptomeninges
What is the common sx of these tumors?	Seizures
What astrocytoma arises from the lining of the ventricular walls and is common in tuberous sclerosis?	Subependymal giant-cell astrocytoma
What complication results from this tumor?	Obstructive hydrocephalus
What are three low-grade (grade I) astrocytomas?	1. Pilocytic astrocytoma 2. Pleomorphic xanthoastrocytoma 3. Subependymal giant-cell astrocytoma
How are these treated?	Surgical excision: subependymal giant-cell astrocytoma. Tx needed when symptomatic (hydrocephalus). Because these tumors are slow growing and well circumscribed, surgical resection is often curative
What is the tx for grade III/IV astrocytomas?	Surgical resection followed by radiotherapy and chemotherapy
A tumor containing calcium is observed on imaging. What is the most likely diagnosis?	Astrocytoma (~25% calcify)
What is the most likely tumor to calcify?	Oligodendroglioma (calcifies pathologically in 100%/seen 70% on imaging)—a calcified tumor is more commonly an astrocytoma due to the higher prevalence
What is a mixed glioma?	An oligodendroglioma that contains astrocytic components (unique among children—more often found in cerebellum)

079_BOOKZ

What is the tx for oligodendroglioma?	As in astrocytomas, oligodendrogliomas are graded I–IV. Surgical resection is preferred for all tumors, followed by chemotherapy and radiation for anaplastic (III) and GBM (IV) resulting from oligodendrogliomas.
Where is the most common place for oligodendrogliomas to present?	Cerebral hemispheres, particularly the frontal lobe
What is the most common presenting sx?	Seizures
Determine the type of glioma based on pathological findings:	
Perivascular pseudorosettes	Ependymoma
"Fried egg" appearance—dense nucleus with clear cytoplasm, contains calcium	Oligodendroglioma
Pleomorphism, mitoses, necrosis	GBM (grade IV astrocytoma)
Where are the most common locations for an ependymoma in:	
Children?	Infratentorial
Adults?	Supratentorial and spinal canal (anywhere along the cord—cervical-lumbar and involving the conus medullaris) **Note:** sx depend on location of tumor.
What is the tx for ependymomas?	Chemotherapy, radiation (typically sensitive) steroids, and surgery
Prognosis is dependent on what factor?	Extent of resection which may be difficult due to adherence to surrounding brain (This is independent of histologic grade.)
What is the most common intracranial tumor in the first year of life?	Choroid plexus papilloma/carcinoma (although rare overall, accounting for <1% of all intracranial tumors)
What is the most common location for choroid plexus papilloma in:	
Children?	Lateral ventricles
Adults?	Fourth ventricle

What are the two complications of choroid plexus papillomas?	1. Hydrocephalus (obstructive or excess production (in children)—↑ ICP and lead to macrocephalus 2. Intraventricular hemorrhage (highly vascular tumors)
How are choroid plexus papillomas treated?	Surgical excision (curative)
A patient presents with disequilibrium, tinnitus, and sensorineural hearing loss. What tumor is associated with these sx?	Schwannoma
What is the likely lesion?	Vestibular or cochlear nerve (also known as—acoustic neuroma) arising at cerebellopontine angle
A mutation in which chromosome predisposes to this tumor?	Chromosome 22
What genetic condition is associated with this tumor?	Neurofibromatosis II (often associated with bilateral acoustic neuromas or schwannomas involving other cranial nerves)
How is this tumor treated?	Surgical resection, radiation, or observation
What two tumors may have similar presentation?	Meningiomas and epidermoid cysts
What is the most common extraaxial tumor?	Meningioma
What two conditions are these tumors associated with?	• Neurofibromatosis Type II • Radiation (latency varies with dosage)
A female patient presents with complaints of headache and menstrual irregularities. Visual field testing reveals a bitemporal hemianopsia. Laboratory data is significant for secondary hypothyroidism. What is the likely diagnosis?	Pituitary adenoma (specifically macroadenoma, >10 mm)—these tumors, like other tumors, typically present in 1 of 3 ways: (1) mass effect causing compression of optic chiasm and compression of pituitary stalk causing hypopituitarism; (2) bleed (pituitary apoplexy)—mimics an SAH; (3) secretory—can express one or more hormones causing endocrinopathies (typically microadenomas)
What hormones can be affected?	Increase or decrease of prolactin, corticotropin, thyrotropin, growth hormone, and gonadotropin (FSH/LH)

079_BOOKZ

What type of tumor is treated medically? What is the medication?	Prolactinoma. Treat with bromocriptine (dopamine agonist)
When is surgery indicated?	Prolactinomas not responding to medical therapy, tumors causing mass effect, or to correct endocrinopathies
A 10-year-old child presents with headache and visual field deficits. A CT of the head reveals a calcified suprasellar cyst. What is the likely diagnosis?	Craniopharyngioma
What is this typically derived from?	Remnant of Rathke pouch
What is the tx of choice?	Surgical removal; however, associated with high recurrence (20%). If partial resection, then radiotherapy recommended
What are eight common posterior fossa tumors and who are most likely to have them?	1. Metastases/lymphoma (adults primarily) 2. Hemangioblastoma (adults primarily and associated with von Hippel-Lindau syndrome) 3. Acoustic neuroma (adults primarily) 4. Meningioma (adults primarily) 5. Medulloblastoma (children primarily) 6. Ependymoma (children primarily) 7. Cystic cerebellar astrocytoma (children primarily) 8. Brainstem glioma (children primarily)

This page intentionally left blank

CHAPTER 25

Orthopedics

BASICS

Name the two types of bone growth.

1. Endochondral ossification: most bones form this way
2. Intramembranous ossification

What are the three zones of growing long bone (see Fig. 25-1)?

1. Epiphysis: growth plate
2. Metaphysis: mostly cancellous bone
3. Diaphysis: hard, lamellar bone

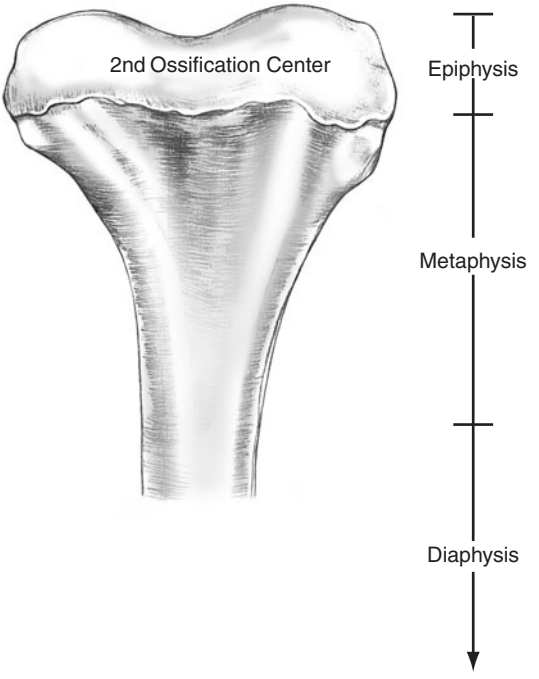

Figure 25-1 The three regions of developing bone.

Copyright © 2008 by The McGraw-Hill Companies, Inc. Click here for terms of use.

079_BOOKZ

Describe the function of each cell type:

Osteoblasts	Produce bone. Become osteocytes trapped in bone matrix. "Osteo**b**lasts **b**uild bone."
Osteoclasts	Resorb bone. Multinucleated. "Osteo**c**lasts **c**onsume bone."
When does bone mass begin to decline?	Age 30. Significant drop off at menopause accounting for the difference in osteoporosis rates in elderly men and women.

Define the following bone disorders:

Osteopenia	Radiographically less bone mineral than expected
Osteoporosis	>2.5 SD (standard deviations) below mean of bone mass per unit volume when compared to age matched control
Osteomalacia	Metabolic inadequate bone mineralization
What are the two types of callus formed in bone healing?	1. Soft callus: fibrocartilage bridge between fracture ends. 2. Forms after 3–4 days. Hard callus: mineralized soft callus, which is stable to bear weight at 6–8 weeks. Appears healed on radiographs.
Where does articular cartilage get its nutrients from?	Synovial fluid (articular cartilage is avascular)
How does articular cartilage heal?	It usually doesn't. Fibrocartilage is only deposited if there is a full thickness tear with subchondral bone involvement. Articular cartilage is finite, stops being produced in late teens, wears away, and is not regenerated.

ORTHOPEDIC EMERGENCIES

Every motor vehicle crash (MVC) trauma evaluation should include what films?	1. Lat C-spine 2. Anteroposterior (AP) chest 3. AP pelvis
What is the injury priority mantra in the multitrauma victim?	"Life before limb before cosmetics"

079_BOOKZ

What should the primary and secondary survey physical exams include from an orthopedic standpoint?	Primary: palpation of spine for step offs, rocking pelvis for stability assessment, ensuring cervical collar Secondary: palpation and inspection of all long bones, joints, hands, and feet
Patient has sustained a tibia/fibula fracture 4 h ago. His leg is swollen and tense. He is unable to sense you touching him in between his first and second toes on that side. On passive extension, he has the new finding of excruciating pain.	
What must be ruled out?	Compartment syndrome
What are the 5 P's of this disorder?	Pallor, poikilothermia (cold), pain on passive extension, paresthesia, pulselessness
What test is used to confirm the diagnosis?	Compartment pressure measurement with needle transduction
Above what pressure is compartment syndrome confirmed?	30 mm Hg. More sensitive way to determine is with compartment perfusion pressure (CPP). CPP = diastolic pressure—compartment pressure. <30 mm Hg is considered an indication for surgery.
What are the four fractures that predispose to compartment syndrome?	Tibia, supracondylar humerus, calcaneus, crush of hand
What are the four compartments of the lower extremity below the knee?	Anterior, lateral, posterior, deep
What operation treats compartment syndrome?	Fasciotomy (see Fig. 25-2)
Besides fracture, what other injuries are associated with compartment syndrome?	Vascular reperfusion injury, soft tissue crush injury, electrical injury, prolonged tourniquet time
A patient with a posterior knee dislocation develops the symptoms of compartment syndrome—pallor, pulselessness, poikilothermia, paresthesia, pain on passive extension—but over the course of a few minutes. Pulses were previously strong.	
What is the diagnosis?	Popliteal artery injury.

079_BOOKZ

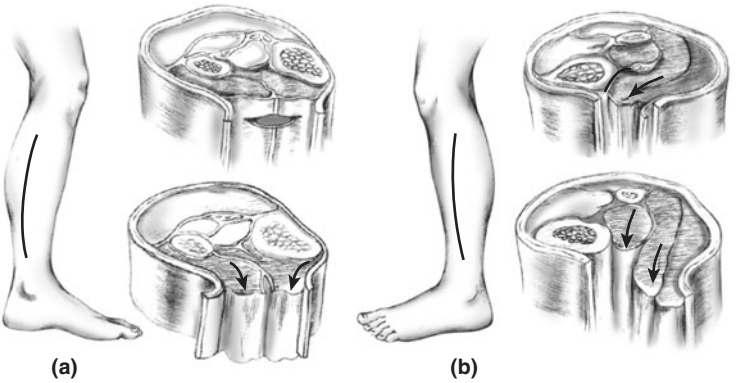

Figure 25-2 The two-incision, four-compartment fasciotomy. For trauma patients, both the skin and fascia should be incised for the entire length of the compartment. (a) To facilitate identification of both the anterior and lateral compartments, a small transverse incision is used to find the fascial raphe between the two compartments. (b) In order to decompress the deep flexor compartment, the soleus muscle must be detached from the tibia. Care must be taken not to injure the distal popliteal neuromuscular bundle, which lies immediately beneath the soleus muscle in the proximal leg. [*Reproduced, with permission, from Brunicardi CF et al (eds): Schwartz's Principles of Surgery, 8th ed. New York: McGraw-Hill, 2005:179.*]

What is the imaging procedure?	Angiogram.
What is the treatment?	Patient will need operative repair. Intimal flap, and thrombosis is likely.
What fractures are associated with vascular injuries?	Knee dislocation: popliteal injury Distal femur Proximal tibia Supracondylar humerus
After what duration of time is it very likely that an extremity with a vascular injury will require amputation?	>6 h
After what duration of time is it very likely that an open fracture will develop osteomyelitis if not irrigated?	>6 h
What is the definition of an open fracture?	Any fracture exposed to the outside environment
How are open fractures graded?	Grade I: low energy, <1 cm defect Grade II: modest energy, >1 cm defect

079_BOOKZ

	Grade III: high energy, >10 cm A: no vascular injury, soft tissue coverage B: no vascular injury, exposed bone C: vascular injury
What antibiotics should be started for a patient with an open fracture while he/she is waiting for surgery?	Grade I and II cefazolin (Ancef), Type III add gentamycin and penicillin G
Besides washout, what are the other basic principles of open fracture management?	1. Early fracture stabilization—usually with external fixation. 2. Complete debridement—may require multiple washouts. 3. Never primarily close wounds. 4. Vascularized soft tissue coverage of exposed bone, tendon, and nerves ("white structures").
What are the three bones that make up the pelvis?	Two innominate bones and the sacrum form the ring. Commonly fractured portions are the superior and inferior rami and the acetabulum.
What physical exam maneuver is used to assess the pelvis?	"Rocking" to assess for stability
What are the three types of pelvic fractures?	Type A: stable Type B: rotationally unstable, vertically stable Type C: rotationally and vertically unstable
What is the initial radiograph used to screen for pelvic fracture?	AP pelvis
What is the best imaging study to evaluate the bony pelvis?	Pelvic CT
What is the risk in unstable pelvic fractures?	Retroperitoneal bleed
Is bleeding from pelvic fracture more commonly arterial or venous?	Venous, 80%
What is the initial tx of an unstable pelvic fracture?	Sheet wrapping
What is the early tx of an unstable pelvic fracture with unexplained hemorrhage?	External fixation (if anatomically amenable)

079_BOOKZ

What is the tx of ongoing hemorrhage after pelvic fixation?	Angiography and embolization of bleeding vessel
What would lead you directly to angiography before external fixation?	Arterial extravasation seen on pelvic CT
You perform exploratory laparotomy due to hypotension and progressive abdominal distension on a patient with multiple injuries including unstable pelvic fracture following MVC. You find no blood in the abdomen, but you notice a retroperitoneal hematoma tracking from the pelvis. Do you:	
Close the abdomen?	Yes, and take the patient to angiography.
Explore the hematoma?	Do not open pelvic hematomas. Exploration and packing leads to more bleeding.
What are the three hollow organs commonly injured with pelvic fractures?	Rectum: Always do rectal exam. Vagina: Always do vaginal exam. Urethra: Always do RUG (retrograde urethrogram) before placing Foley.

FRACTURE

Describe the following fracture patterns (see Fig. 25-3):	
Segmental	Long bone broken in two places
Comminuted	Multiple bone fragments in fracture. Occurs in higher energy fracture.
Spiral	Fracture pattern associated with twisting motion
Oblique	Oblique in the same plane—differs from spiral in that spiral is multiplanar and oblique.
Transverse	Fracture directly across long axis
What is the most common long bone fracture?	Clavicle
What is the tx for a nondisplaced clavicle fracture?	Sling for 6 weeks

079_BOOKZ

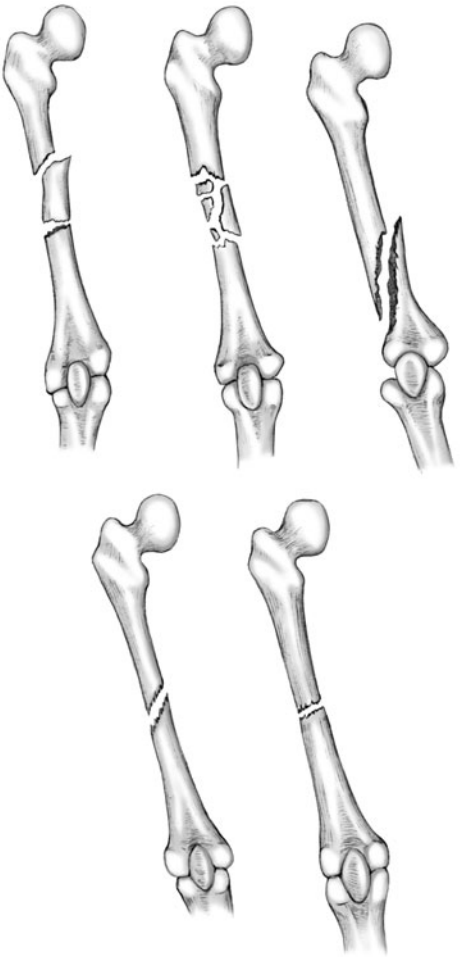

Figure 25-3 Fracture patterns: top—segmental, comminuted, spiral; bottom—oblique, transverse.

What is the risk in a distal humerus fracture?	Radial nerve
If injured, what is the chance of recovery?	Recovery is the rule—injury is apraxia.
What is the tx of a distal 1/3 humerus fracture?	ORIF (open reduction internal fixation)
What is a Galeazzi's fracture?	Distal radial shaft with dislocation of the radioulnar joint. ORIF to treat.

What is a Monteggia's fracture?	Proximal ulnar fracture and dislocation of the radial head. ORIF to treat.
What is a Colles' fracture?	Distal radius fracture. "Dinner fork" deformity. Associated with ulnar styloid fx. Closed reduction and casting is tx.
Pain at anatomic snuff box?	Scaphoid fracture—can have no radiographic evidence
What is the risk with displaced scaphoid fracture?	Nonunion and avascular necrosis—blood supply is tenuous. If displaced >1 mm, needs operative repair. >2 mm risk of ligament damage.
What is the empiric tx of a scaphoid fracture?	Thumb spica cast and repeat radiograph in 10–14 days. Alternatively, immediate MRI.
Knee impact on car dashboard during a head-on collision causes what type of fracture?	Acetabular fracture
What are the two potential sequelae of a displaced acetabular fracture?	1. Avascular necrosis of the femoral head: the ligamentum teres contains the blood supply of the femoral head. 2. Posttraumatic arthritis: this is an intra-articular fracture.
An 80-year-old falls from a standing position onto her side. The extremity is shortened and she is unable to bear weight on that side. She has an externally rotated foot. She has pain on rotational motion (+ log roll). What are the two common fractures?	Femoral neck and intertrochanteric fracture. They occur with equal frequency.
What is the tx of a hip fracture?	Internal fixation is indicated in almost all hip fractures—elderly population, allows early ambulation.
What are the complications in femoral shaft fracture?	1. Vascular injury with hypovolemic shock: thigh can hold 3 L of blood 2. Embolic marrow (fat embolism): can cause/worsen acute respiratory distress syndrome (ARDS)
What is the tx of a closed femoral shaft fracture?	Internal fixation with reamed, locked, intramedullary (IM) nail—allows early ambulation (previously treated with bedrest and traction).

079_BOOKZ

What is the risk with tibial shaft fracture?	Compartment syndrome
What are the bones that can be broken in an ankle fracture?	Lateral malleolus, medial malleolus, or both

DISLOCATION

What is the most common type of shoulder dislocation?	Anterior—95%. Reduce with external rotation.
What nerve is at risk in anterior shoulder dislocation?	Axillary nerve—supplies sensation over deltoid, motor to deltoid muscle
What is the associated muscle injury?	Rotator cuff tear
What conditions are associated with a posterior dislocation?	Seizure and electrocution
A 20-year-old patient was involved in a car accident. His hip is adducted, flexed, internally rotated. Is this an anterior or posterior dislocation?	Posterior—most common
What is the complication if not reduced promptly?	Avascular necrosis of femoral head—associated with acetabular fracture
What nerve is at risk?	Sciatic
What is the posture in an anterior hip dislocation?	Abduction, external rotation (think opposite of posterior)
What artery is at risk?	Femoral
List the four complications of knee dislocation.	1. Vascular injury: popliteal artery 2. Peroneal nerve palsy: foot drop 3. Posterior tibial nerve avulsion: anesthetic foot can lead to amputation 4. Ligament injury
What test needs to be done after knee dislocation regardless of physical exam?	Angiogram—high risk of vascular injury (1/3)
What is the tx of an ankle dislocation?	Open reduction with ligament repair—almost always open fracture/dislocation
What joint is dislocated if the foot is at a right angle to the ankle?	Subtalar joint

LIGAMENT AND TENDON INJURIES

Anterior drawer test of the knee is used to test what ligament?	Anterior cruciate ligament (ACL)
Posterior drawer test of the knee is used to test what ligament?	Posterior cruciate ligament (PCL)
What are the other ligaments of the knee?	Medial and lateral collateral ligaments
What two injuries result in the inability to initiate knee extension with the knee flexed at 90°?	Quadriceps disruption, patellar tendon disruption
What is the Tx?	Surgical repair
A 35-year-old is playing a pickup game of basketball. He feels a sharp pain in his calf and hears a pop. On physical exam, he has decreased plantar flexion on the affected side and fullness of his calf. When you squeeze the calf, there is no plantar deviation of the foot (+ Thompson's sign).	
What is the diagnosis?	Achilles tendon disruption
What is the tx?	Surgery or cast immobilization

OSTEOMYELITIS

What is osteomyelitis?	Bone infection
What is the cutoff for acute vs chronic osteomyelitis?	3 months
What is the most common cause of osteomyelitis?	Secondary—due to open fracture
What is the most common primary cause of osteomyelitis?	Hematogenous spread
What is the most common organism causing osteomyelitis in the following populations:	
Neonates	*Staphylococcus aureus*
Children 2–5	*Haemophilus, Streptococcus, plus Staphylococcus*
Adults	*S. aureus*
Sickle cell	*Salmonella*
Diabetic	*Pseudomonas aeruginosa*

079_BOOKZ

What are the x-ray findings of osteomyelitis?	"Sequestrum" of necrotic bone surrounded by "involcrum" of reactive bone
What imaging tests can confirm osteomyelitis?	Tagged WBC scan (nuclear medicine), bone scan, or MRI
What laboratory tests are abnormal in osteomyelitis?	↑WBC, ↑↑ESR (often >100), ↑CRP
What is the tx of acute osteomyelitis?	Incision and drainage (I & D) or aspiration if abscess, 6 weeks of IV antibiotics
What is the tx of chronic osteomyelitis?	Open debridement of necrotic bone and soft tissue, flap coverage, long-term antibiotics

ARTHRITIS

Define pyogenic (septic) arthritis.	Infection in joint space
What are the clinical clues in diagnosing pyogenic arthritis?	Fever, chills, joint pain, swelling, redness, tender on range of motion
What must be done if pyogenic arthritis is suspected?	Joint aspiration—pyogenic arthritis defined by >50K WBCs, 90% neutrophils. Also, obtain Gram stain and culture.
What is the tx of pyogenic arthritis?	Due to the poor blood supply of the joint space, these infections must be drained. Surgical drainage of hip and knee—open or arthroscopy. Shoulder and ankle can undergo repeat aspiration. Drainage is followed by IV antibiotics for 2–4 weeks.
Why does pyogenic arthritis need to be recognized and treated early?	Risk of cartilage destruction
What are the three most common organisms?	1. *S. aureus* 2. *Streptococcus* 3. *Gonococcus*
What is the differential diagnosis of a warm, tender joint with effusion?	Inflammatory arthritis—gout, pseudogout, rheumatoid arthritis, ankylosing spondylitis, rheumatic fever
What is the most common type of noninflammatory arthritis?	Osteoarthritis—chronic arthritis of progressive degenerative loss of articular cartilage

What is the most common type of inflammatory arthritis?	Rheumatoid arthritis—inflammatory condition which leads to the destruction of joints
Why is it important to separate these two conditions?	Rheumatoid arthritis can be treated with immunomodulator disease modifying agents
The following are characteristics of rheumatoid arthritis or osteoarthritis:	
Knee, most common joint affected	Osteoarthritis
Obesity predisposing factor	Osteoarthritis
Distal interphalangeal (DIP) joint never involved	Rheumatoid arthritis
Occurs in one-fourth of the population >60	Osteoarthritis
Nighttime pain	Osteoarthritis
Morning stiffness	Rheumatoid arthritis
Soft joint nodules	Rheumatoid arthritis
DIP involvement	Osteoarthritis
80% have + rheumatoid factor	Rheumatoid arthritis
Treated with steroids	Rheumatoid arthritis
Can be associated with vasculitis, pericarditis, pulmonary sx	Rheumatoid arthritis
What is the typical x-ray appearance of osteoarthritis?	1. Loss of articular cartilage—joint space narrowing 2. Osteophytes 3. Subchondral cyst
What is the typical x-ray appearance of rheumatoid arthritis?	1. Loss of articular cartilage 2. Osteopenia 3. Periarticular erosions
What is the tx of a joint crippled by arthritis?	Total joint replacement
What is important in the pre-op workup of a patient with longstanding rheumatoid arthritis that can prevent a crippling complication?	C spine film. RA patients can have unstable spine and extension of neck during intubation—can lead to spinal cord injury.

079_BOOKZ

MISCELLANEOUS DISORDERS

An 50-year-old white male with limitation of extension of his fourth and fifth digits of his hand. On exam, you find contracture bands on his palm that limit passive extension.

What is the diagnosis?	Dupuytren's contracture
What is the etiology?	Proliferation of the palmar fascia of the hand
What is the tx?	Surgical excision of the palmar fascia to release contracture

An 18-year-old patient with a swollen, red, middle finger. The finger is held in mild flexion. There is intense pain on passive extension and tenderness and swelling along the tendon sheath.

What is the diagnosis?	Flexor tenosynovitis: infection tracking along flexor tendon sheath
What is the tx?	Elevation, splinting, IV antibiotics. Surgical drainage if not prompt improvement

A 30-year-old typist presents with numbness of fingertips, pain, and tingling in hands. Positive Tinel's sign.

What is the diagnosis?	Carpal tunnel syndrome
What is the etiology?	Median nerve compression by the transverse carpal ligament
What is the test to confirm diagnosis?	EMG with nerve conduction study
What is the tx?	Trial of nighttime splinting, but carpal tunnel release (release of transverse carpal ligament) is definitive therapy.

Indication for ORIF of a metacarpal fracture?	"Scissoring" or crossing of fingers on flexion: functional displacement of fracture

What is and how do you treat the following disorders of the distal phalanx?

Paronychia	Soft tissue infection along the fingernail: incision and drainage
Felon	Soft tissue infection of the fingertip: incision and drainage

What are the four muscles of the rotator cuff?	**S**upraspinatus, **I**nfraspinatus, **T**eres minor, **S**ubscapularis "**SITS**"
What is "fight bite"?	Laceration over metacarpophalangeal (MCP) joint caused by tooth puncture. Requires copious irrigation. Consider the joint space violated, risk of septic arthritis.

ORTHOPEDIC TUMORS

What is the most common type of bone tumor?	Metastasis
What are the top five tumors that metastasize to bone?	1. Breast 2. Prostate 3. Lung 4. Kidney 5. Thyroid
Which cancers are blastic in bone?	Breast and prostate
Which cancers are lytic in bone?	Breast, lung, melanoma, renal, thyroid
Which are mixed?	Breast, lung
What is the palliative tx of bone metastasis?	Local radiation decreases fracture rate
What if the lesion causes pain on ambulation?	If pain with ambulation or involves >1/3 of the cortex, offer prophylactic internal fixation
What is a pathologic fracture?	A fracture that is secondary to another illness that resulted in bone weakening (opposed to stress fracture from overuse of normal bone).
What is the most common "primary" bone tumor?	Multiple myeloma: plasma cell malignancy, not including staging of musculoskeletal tumors.
Which can you biopsy after only a plain film x-ray—benign or malignant bone tumors?	Benign. Malignant-appearing tumors must be evaluated with MRI to determine the best approach for biopsy.
Where is the most common site of metastasis in primary bone tumors?	Lungs
What is needed for staging in a patient with a malignant appearing primary bone tumor?	Chest CT, bone scan in addition to MRI

079_BOOKZ

What are the rules of musculoskeletal biopsy?

1. All biopsy incisions should be along the long axis of the extremity.
2. Biopsy incision and needle tracts should be placed so they can be taken en bloc with the mass on resection.
3. Take as little cortex as necessary to decrease risk of pathologic fracture.
4. Biopsy through muscle belly to decrease chance of intermuscular plane seeding.
5. Stay away from neurovascular structures.

What are the most common locations for bone tumors (see Fig. 25-4)?

Sites of maximal bone growth: epiphysis, metaphysis, areas of remodeling

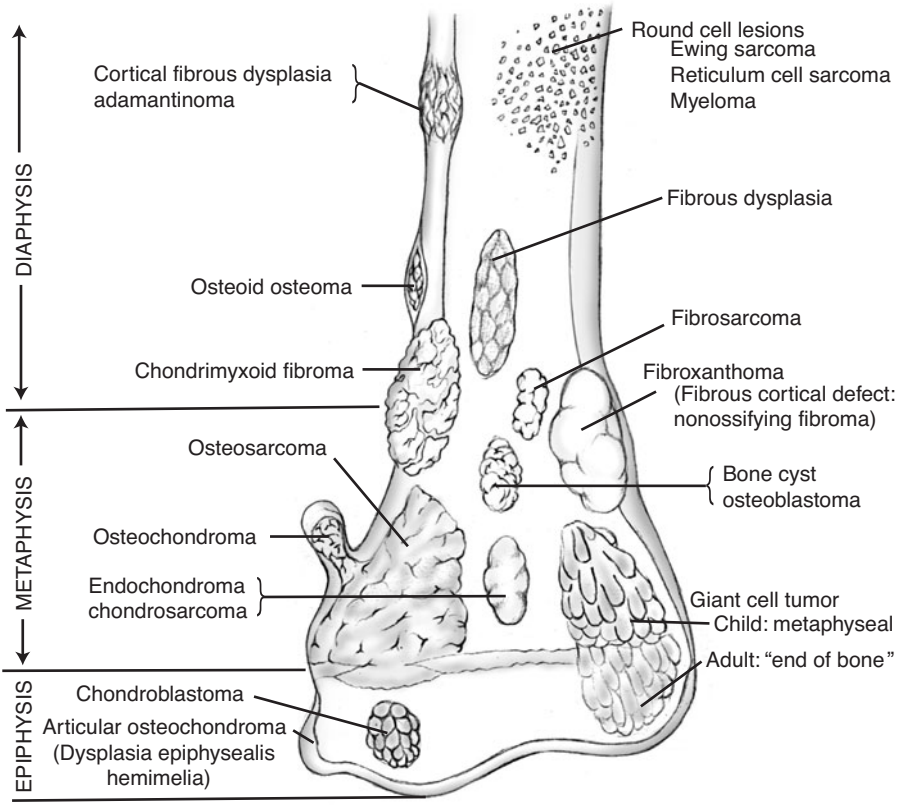

Figure 25-4 Locations of various tumors found in bone depicted on the distal femur.

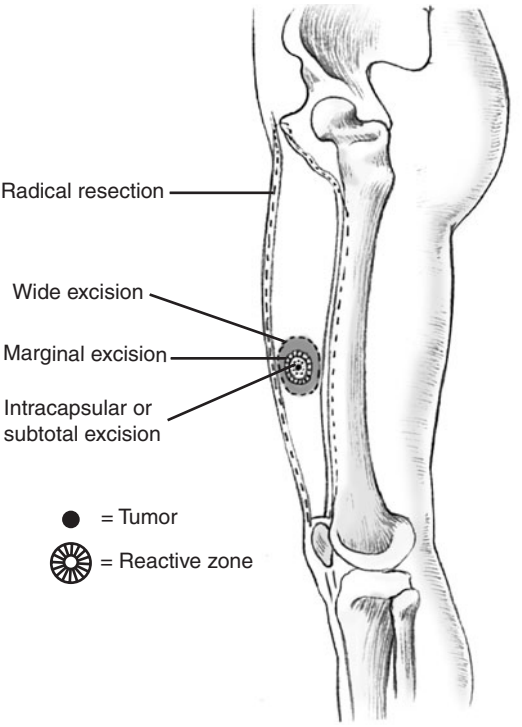

Figure 25-5 Types of bone and soft tissue resection.

What are the four types of resection with respect to margin (see Fig. 25-5)?

1. Intracapsular: leaves macroscopic disease: used only for benign lesions
2. Marginal: may leave microscopic disease: removal through reactive zone
3. Wide: removes tissue beyond reactive zone
4. Radical: removal of all bone, muscle, joint involved in tumor and reactive zone

Describe whether the following bone tumors are benign or malignant; the type of bone most affected; most common age group; sx; x-ray appearance; and tx:

Osteoid osteoma

Benign, bone forming

Long bones

	Age: <30 Sx: local pain, treat with aspirin X- ray: <1 cm lucent nidus with surrounding reactive cortical thickening Tx: observation, regression typical in 5–10 years. Surgery if pain not controlled.
Osteoblastoma	Benign, bone forming Spine Age: children and young adults Sx: none X-ray: lytic and blastic, >1 cm, no reactive thickening Tx: observation. Surgery if painful.
Osteosarcoma	Malignant Most common primary bone malignancy (less common than multiple myeloma [MM]) Distal femur, 52%, proximal tibia, 20%, proximal humerus, 9% Age: 10–25 Sx: nocturnal pain, mass, or swelling X-ray: blastic, Codman's triangle—periosteum raised off bone by tumor mass, sunburst appearance Tx: neoadjuvant chemotherapy, wide resection (limb salvage), reconstruction, which is better than amputation and chemotherapy **Note:** Preoperative workup: Chest CT (pulmonary metastasis), bone scan (bone metastases), regional MRI for operative planning.
Osteochondroma	Benign Long bones (metaphysis) Age: children Sx: none X-ray: exophytic fragment of growth plate Tx: excise if painful or pressing on adjacent structures

Enchondroma	Benign Small bones of hands and feet Age: 10–50 Sx: pain or pathologic fracture X-ray: lytic "popcorn calcifications" with surrounding reactive sclerosis Tx: curettage and bone grafting
Chondroblastoma	Benign Epiphyseal, long bones Age: first or second decade of life Sx: pain, joint effusion, contractures X-ray: lytic with calcification at epiphysis Tx: curettage and bone graft
Chondrosarcoma	Malignant Pelvis, femur, tibia Age: 20–60 Sx: pain X-ray: intramedullary calcification, cortical destruction Tx: wide excision, limb salvage. Resistant to chemotherapy and radiation
Unicameral bone cyst	Benign Metaphysis of humerus, femur, radius, calcaneus, or tibia Age: children Sx: painless, can have pathologic fracture X-ray: "fallen fragment sign," lytic, expansile, well marginated Tx: Methylprednisone intraosseous injection 70–90% effective in kids. If persists, curettage and BG.
Aneurysmal bone cyst	Benign Long bones Age: children and young adults Sx: painless, can have pathologic fracture X-ray: expansive lysis of bone

079_BOOKZ

	Tx: wide resection and BG, pre-op embolization (cystic lesion with large vascular spaces)
Ewing's sarcoma	Malignant
	Diaphysis of long bones, spine, pelvis
	Age: 5–15 years
	Sx: night pain, fever, weight loss, large soft tissue mass
	X-ray: bone lysis and periosteal reaction, permeation; adjacent soft tissue mass
	Imaging: chest and abdominal CT, bone scan to evaluate for metastasis
	Tx: radiation, chemotherapy, wide resection. Young children get amputation, radiation results in irreversible damage of growth plate.
	Prognosis: 75% at 5 years
Histiocytic lymphoma	Metastatic
	Diaphysis of long bones
	Age: 20–40 years
	Sx: pathologic fracture, palpable local or distant lymph node (LN)
	X-ray: looks like Ewing's
	Tx: radiation and chemo, possible resection
Giant cell tumor (osteoclastoma)	Benign, less commonly malignant
	Proximal tibia, distal and proximal femur, distal radius
	Age: young adults
	Sx: pain and pathologic fx
	X-ray: purely lytic, well circumscribed
	Tx: curettage and fill defect with cement
Why not use radiation therapy?	Radiation can turn benign to malignant.

Chordoma	Malignant: low-grade Sacrococcygeal or occipitocervical Etiology: embryonic notochord remnant Age: older adults Sx: mass, pain, neurologic symptoms, Late pulmonary metastasis X-ray: solitary midline lesion with bone destruction, may have soft tissue component (get MRI) Tx: surgery (limited by location) and radiation

PEDIATRIC ORTHOPEDICS

What hip disorder must be routinely screened for in newborns?	Developmental dysplasia of the hip (DDH)
What is Barlow's test?	Flexed hip at 90°, push, will feel clunk
What is Ortolani's test?	Flexed hip at 90°, abduct the hip, feel clunk
How is DDH treated?	Pavlik's harness
What are the two possible disorders in a 12-year-old with hip pain, knee pain, and limp?	1. Slipped capital femoral epiphysis (SCFE)—displacement of the femoral head metaphysis 2. Legg-Calvé-Perthes disease (LCP) —osteonecrosis of the proximal femoral epiphysis
How are these two disorders separated?	X-ray
What is the tx of each?	1. SCFE is treated with lag screw—do not reduce, can cause osteonecrosis 2. LCP can be treated with physical therapy for ROM plus surgery or bracing
A 13-year-old boy has chronic pain over both tibial tuberosities.	
What is the diagnosis?	Osgood-Schlatter disease
What is the cause?	Traction on the insertion of the quadriceps muscle on the tibial tuberosity
What is the tx?	Physical therapy, stretching of quadriceps

079_BOOKZ

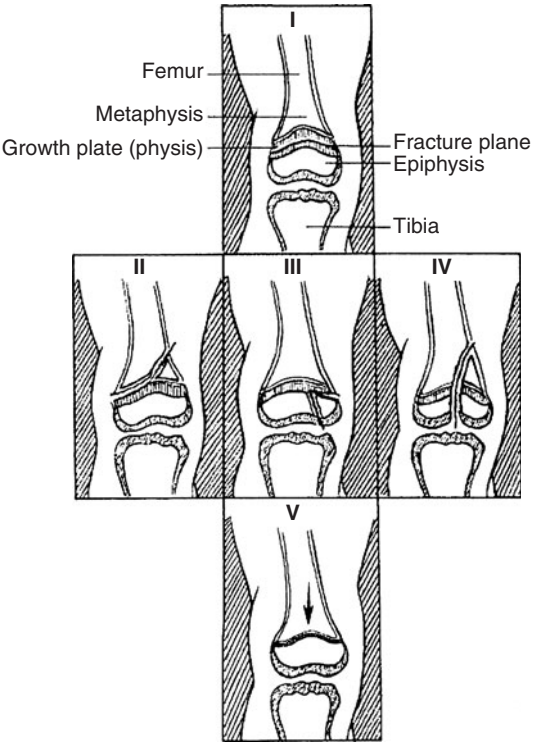

Figure 25-6 Salter-Harris classification of epiphyseal fractures. [*Reproduced, with permission, from Knoop KJ, Stack LB, Storrow AB (eds): Atlas of Emergency Medicine. New York: McGraw-Hill, 2002.*]

What is the Salter-Harris classification of pediatric long bone fractures?	Pediatric fractures involving the epiphysis (see Fig. 25-6)
Which Salter-Harris fractures need operative repair?	III, IV, V
What needs to be considered in children with spiral fractures?	Child abuse

This page intentionally left blank

CHAPTER 26

Clinical Vignettes

CLINICAL VIGNETTE 1

A 65-year-old Caucasian male with a history of alcoholism presents to the emergency department (ED) with sudden onset coffee-ground emesis, dark tarry stool, lightheadedness, and shortness of breath (SOB). The patient was evaluated 1 week ago for unrelated symptoms and was found to have hemoglobin (Hb) 13, blood urea nitrogen (BUN) 18, and creatinine (Cr) 1.0. Today the patient has Hb 7, BUN 84, Cr 1.2, and platelets are within normal limits (WNL). Physical exam reveals temperature 98.9°F, BP 105/80, pulse 102, positive orthostatics, ascites, and spider angiomata. Rectal exam reveals significant amount of soft stool that is guaiac positive.

What is the first step in management of this patient?

Remember the ABCs. The patient has a secure airway and is breathing spontaneously, however, is at increased risk for aspiration and must be monitored. Next, you must establish access with two large bore intravenous catheters (IVs).

In evaluating this patient for admission, where should this patient be triaged—the medical floor or intensive care unit (ICU)?

Clearly this patient has a significant drop in his Hb and is demonstrating signs of developing shock (↓ BP, ↑ HR, orthostatic). This patient should be admitted to the ICU immediately. Remember, in an acute bleed, the Hb may not accurately reflect the amount of blood loss—use patient's vital signs as an indication of blood loss and this patient has at least 20% volume loss.

Copyright © 2008 by The McGraw-Hill Companies, Inc. Click here for terms of use.

079_BOOKZ

What is the differential diagnosis?

Given the history and presentation of hematemesis, melena, and azotemia, the patient likely has an upper gastrointestinal (GI) bleed. Causes include:

- Esophageal/gastric varices
- Peptic ulcer disease (PUD)
- Erosive gastritis/esophagitis
- Mallory-Weiss tear
- Neoplasm
- Angiodysplasia

Note: Ruptured esophageal varices are the most likely given the patient's history of alcoholism with signs of cirrhosis.

What is the next step in diagnosis?

Nasogastric (NG) lavage, although a negative lavage does not exclude an upper GI bleed.

What two lab tests need to be ordered with this patient?

1. Coagulation test (prothrombin time (PT)/partial thromboplastin time (PTT)/international normalized ratio (INR)) given the history of cirrhosis
2. Type and cross for blood transfusion

NG lavage reveals bright red blood. How should this patient be managed?

This patient requires supportive care including blood transfusion, correction of any coagulation abnormalities, and IV fluids (IVFs). Also, this patient needs urgent esophagogastroduodenoscopy (EGD) for variceal ligation or sclerotherapy.

What medication is used to control bleeding?

Octreotide/somatostatin—causes vasoconstriction, thereby decreasing portal pressures.

What class of medication is used to prevent bleeding?

Nonselective beta-adrenergic blockers (eg, propranolol)

The patient undergoes EGD for whichever actively bleeding varices are discovered and ligated. However, the patient continues to have active bleeding and becomes hemodynamically unstable. What is the next step in management?

1. Aggressive volume resuscitation with packed red blood cells and cystalloid
2. Luminal tamponade (Sengstaken-Blakemore tube). Follow closely for associated complications including asphyxiation, aspiration, and esophageal rupture.

079_BOOKZ

Following removal of the Sengstaken-Blakemore tube the patient resumes bleeding. What is the next step in treatment?

TIPS (transjugular intrahepatic portosystemic shunt) procedure. However, this is associated with a high incidence of hepatic encephalopathy and is often used as a bridge for a liver transplant. This has significantly reduced the need for surgical ligation of varices or portocaval shunting.

CLINICAL VIGNETTE 2

A 65-year-old white male with a history of smoking and rheumatoid arthritis presents to the ED complaining of sudden onset nausea, with coffee-ground emesis, dark tarry stool, lightheadedness, SOB, and shoulder pain. The patient was evaluated 1 week ago for unrelated symptoms and was found to have a white blood cell (WBC) 8, Hb 13, BUN 18, and Cr 1.0. Today the patient has a WBC 13, Hb 7, BUN 84, Cr 1.2, and platelets are within normal limits. Physical exam reveals temperature 102°F, BP 105/80, pulse 102, and a rigid abdomen that is diffusely tender with rebound tenderness. Rectal exam reveals significant amount of soft stool that is guaiac positive.

What is the next step in management?

Remember, ABC's. Secure the airway and place two large bore IVs.

What radiographic test is needed?

Upright abdominal x-ray to evaluate free air under the diaphragm.

What is the likely diagnosis?

This patient appears to have signs of an upper GI bleed and peritonitis, most likely as a result perforated peptic ulcer and may be developing hemorrhagic and/or septic shock.

What are the risk factors for this diagnosis?

- *Helicobacter pylori* infection (especially duodenal ulcers)
- Corticosteroids/NSAID
- Alcohol
- Tobacco
- Carcinoma (always rule out carcinoma in gastric ulcers)
- Zollinger-Ellison (recurrent ulcers typically involve second/third part of duodenum)

Abdominal x-ray returns and shows presence of free air under the diaphragm. What is the next step in management?

The presence of pneumoperitoneum confirms the diagnosis of a perforated viscus. This patient needs emergent exploratory laparotomy for plication (oversewn ulcer) and/or acid-reducing procedure (truncal vagotomy and pyloroplasty or proximal gastric vagotomy).

What is the medical management of patients with nonperforated, hemorrhagic ulcer?

NG decompression/lavage, proton pump inhibitor (PPI), endoscopy, supportive therapy (blood transfusion)

What are the surgical indications for hemorrhagic duodenal ulcer?

- Hemorrhage unresponsive to endoscopic control
- Repeat hospitalization for hemorrhagic ulcer
- Perforation
- Gastric outlet obstruction
- Lack of therapeutic endoscopist or available blood products

CLINICAL VIGNETTE 3

A 70-year-old African American female with a history of lower left quadrant abdominal pain and persistent atrial fibrillation presents to the ED with sudden onset lightheadedness, SOB, and bright red blood per rectum. The patient was evaluated 1 week ago for URI (upper respiratory infection) symptoms and was found to have a WBC 10, Hb 13, BUN 18, Cr 1.0, INR 2.3 and was discharged home on antibiotics. Today, the patient has a WBC 8, Hb 7, BUN 20, Cr 1.2, platelets are within normal limits, and INR is 5. Physical exam reveals temperature 98.9°F, BP 105/80, pulse 102, positive orthostatics, and benign abdominal exam. Rectal exam reveals bright red stool on exam glove.

What is the next step in diagnosis?

This patient needs to have an NG lavage. Although a negative result does not exclude an upper GI bleed, given the symptoms and lab values, an upper GI source would be less likely.

NG lavage is performed and is negative for blood. What is the differential diagnosis?

This patient is presenting with a GI bleed. This is likely of lower GI origin given the signs/symptoms (painless bleeding, hematochezia) and lack of azotemia or positive lavage; however, a brisk upper GI

079_BOOKZ

bleed may mimic a lower GI bleed and must be excluded. Causes for lower GI bleed include:
- *Diverticulosis.*
- *Angiodysplasia.*
- Colitis.
- Meckel's diverticula.
- Fistula (aortoenteric).
- Ischemic bowel.
- Inflammatory bowel disease (IBD).
- Colon cancer.
- Distinguishing between diverticulosis and angiodysplasia is difficult, especially in the elderly where both are common.

What is the likely cause for the patient's elevated INR? How can this be corrected?

The patient has a history of persistent atrial fibrillation and is likely on coumadin. The recent use of antibiotics decreased intestinal absorption of vitamin K and may have interfered with the P450 metabolism of coumadin, thereby raising the effectiveness/ therapeutic levels of coumadin. The elevated INR can be corrected immediately with the transfusion of fresh frozen plasma (FFP). Vitamin K may also be given, but will take days to have an effect on the INR.

The patient's airway is secure and two large bore IVs are placed. What is the next step in management?

This patient needs type and cross of FFP and red blood cells (RBCs) for transfusion. ~80% of patients with hemorrhage due to diverticulosis or angiodysplasia will have spontaneous resolution.

How can the physician assess the adequacy of resuscitation?

Monitor urinary output

The patient is treated and follow-up hemoglobin is stable. What is the next step in management?

This patient needs to have a colonoscopy after rapid purging with GoLYTELY. Patient can then be treated with thermal contact modalities or epinephrine injections.

The patient is stable and undergoes endoscopic evaluation and no source of bleeding is found; however, the patient continues to require blood transfusions. What is the next step in identifying the source of bleeding?

- Push enteroscopy, which allows visualization of proximal jejunum.
- Sonde enteroscopy involves fiberoptic scope that is pulled through intestines by peristaltic motion and pulled out allowing visualization; however, lacks biopsy or therapeutic ability.
- ^{99}Tc-tagged RBC scan (bleeding must be >1 mL/min) usually if above two endoscopic techniques fail.

In patients with persistent severe bleeding where EGD and colonoscopy fail to identify a source of bleeding, what is the next step in diagnosis/management?

Angiography—allows intra-arterial injection of vasoconstrictors (vasopressin) or selective embolization. This is often performed after an attempt at localizing the bleeding with ^{99}Tc-tagged RBC scan.

What are the surgical indications for GI bleed?

- Hemodynamically unstable for diagnostic study.
- Above diagnostic techniques fail to identify a source of bleeding.

Note: Intraoperative enteroscopy performed during exploratory laparotomy/laparoscopy: if source of bleeding is identified to colon segmental colectomy; otherwise, subtotal colectomy if negative pan-intestinal endoscopy with evidence of colonic bleed.

CLINICAL VIGNETTE 4

A 60-year-old white female presents to the ED with complaints of two day worsening lower left quadrant (LLQ) abdominal pain associated with nausea, nonbilious/nonbloody emesis, constipation, and fever. Physical exam reveals a patient in significant distress, temperature of 102°F, stable vital signs, soft-/nondistended abdomen with decreased bowel sounds and pain to palpation, greatest over LLQ without rebound, guarding, or costovertebral angle (CVA) tenderness. No abdominal masses are palpated. Rectal exam is normal with negative stool guaiac.

What is the differential diagnosis?

- Diverticulitis
- Ischemic/infectious colitis
- Malignancy
- Irritable bowel disease (IBD)
- Nephrolithiasis/pyelonephritis

079_BOOKZ

What is the imaging test of choice?

CT abdomen and pelvis—Administration of by mouth (per os, PO), IV, and rectal contrast vary from institution. None are absolutely necessary to diagnose diverticulitis; however, IV contrast is useful in enhancing abscesses, fistulas, or other differentiating diagnoses that mimic diverticulitis.

The patient undergoes radiographic examination that shows pericolic fat stranding, bowel wall thickening, and diverticula. Exam is negative for intra-abdominal mass or pneumoperitoneum. What is the likely diagnosis?

The patient's signs/symptoms and CT findings are classic for uncomplicated diverticulitis. Typically, this is caused by a fecalith causing obstruction leading to swelling and micro-/macroperforation.

How should this patient be managed?

In uncomplicated diverticulitis patients should be managed with:

- Pain control (IV morphine).
- Bowel rest.
- NG tube if ileus is present.
- Intravenous fluid (IVF); nothing by mouth (NPO)
- Broad spectrum IV antibiotics (metronidazole and fluoroquinolone or second and third generation cephalosporin, or monotherapy with piperacillin/tazobactam, ampicillin/sulbactam. Remember to collect blood cultures prior to initiating antibiotic therapy.

72 h after admission the patient remains febrile with persistent leukocytosis and severe pain. On physical exam, you notice the patient now has a palpable LLQ abdominal mass without rebound or guarding. What is the next step in diagnosis?

This patient has not shown any clinical improvement and has developed a new mass, likely an abscess. This needs to be evaluated with repeat abdominal CT.

Radiographic results return with presence of a 4 cm abdominal abscess. There is no evidence of pneumoperitoneum. What is the next step in treatment?

Treatment of abscesses <2 cm may be attempted with parenteral antibiotics. However, in this patient CT-guided percutaneous drainage should be attempted.

079_BOOKZ

The patient improves and is discharged, however, returns with recurrent urinary tract infection (UTI). Upon questioning you discover the patient has noticed air bubbles in her urine and malodorous urine with debris. What is the likely diagnosis?

Pneumaturia suggests colovesical fistula (most common fistula associated with diverticulitis) but may also be caused by *Clostridium* or yeast infection. However, the presence of malodorous urine with debris suggests fecaluria, which is pathognomonic for colovesical fistula.

What are the surgical indications for diverticulitis?

- Recurrent (two or more episodes) diverticulitis, especially if requiring hospitalization
- Consideration after first episode if diverticulitis in very young patient or immunocompromised—these patient populations have a high incidence of complicated diverticulitis
- Inability to exclude colon carcinoma
- Intractable pain
- Complicated diverticulitis
  a. Abscess formation (if inaccessible or reoccurs after percutaneous drainage)
  b. Obstruction
  c. Peritonitis/perforation
  d. Fistula formation

What is the recommended surgery in:

Urgent/emergent cases?

In urgent/emergent conditions, temporary diverting colostomy and Hartmann procedure—primary reanastomosis not recommended for unprepared bowel due to the high risk for infection. Care must be taken as inflammation may increase the risk of damaging the ureters during mobilization of sigmoid colon.

Nonurgent cases?

If refractory or fistula formation the patient can undergo bowel preparation; therefore, sigmoid colectomy with primary anastomosis may be attempted.

Why is colonoscopy not recommended during acute episode of diverticulitis?

There is a high risk of bowel perforation.

079_BOOKZ

A patient is treated for uncomplicated diverticulitis and does well. After discharge from the hospital what is the recommended follow-up?

She should undergo colonoscopy in 4–6 weeks to rule out malignancy as this can mimic diverticulitis (complicated or uncomplicated).

CLINICAL VIGNETTE 5

A 35-year-old Caucasion female presents to the ED with complaints of anorexia followed by abdominal pain over the past 12 h. The patient describes the onset of abdominal pain initially located over periumbilical area and dull in nature; however, has progressed to right lower quadrant (RLQ) and is now "knife-like" in nature and associated with nausea and nonbilious/nonbloody emesis. During this time, the patient states she had two episodes of nonbloody diarrhea without relief in abdominal pain. Patient is sexually active and last menstrual period (LMP) was 1 month ago. Physical exam reveals a patient in moderate distress, temperature of 100.5°F and stable vital signs. Abdominal exam reveals soft, nondistended abdomen with decreased bowel sounds and pain to palpation, greatest over RLQ with rebound tenderness. Rectal exam was normal with negative stool guaiac. Blood tests show WBC 12,000 with left shift. Liver function test (LFT), amylase, and lipase are within normal limits. Urinalysis (UA) showed 3 RBCs, 8 WBCs, negative casts/nitrite/leukocyte esterase.

What additional lab test needs to be ordered?

β-hCG (human chorionic gonadotropin)—pregnancy should always be excluded in patients of child-bearing age before diagnostic/therapeutic procedures are performed or medications are administered.

What is the differential diagnosis?

The differential diagnosis is extensive and includes:

- Appendicitis
- Cholecystitis
- Gastroenteritis
- Gynecological:
  a. Pelvic inflammatory disease (PID)/tubo-ovarian abcess (TOA)
  b. Ectopic pregnancy
  c. Ovarian torsion/ruptured cyst (testicular torsion)
  d. Endometriosis
  e. Degenerating uterine fibroid
  f. Salpingitis (epididymitis)
- Irritable bowel disease (IBD)
- Diverticulitis (can occur anywhere within the intestines)
- Urolithiasis/pyelonephritis
- Strangulated bowel (hernia)

079_BOOKZ

- Obstructing colon carcinoma
- Intussusception (children)
- Urinary tract infection (UTI)

The β-hCG is negative. Based on the patient's presentation what is the likely diagnosis?

This is a classical presentation of appendicitis with anorexia preceding vague abdominal pain that progresses to sharp localized pain at McBurney's point, rebound tenderness, fever, and leukocytosis (developing over acute/subacute time frame). However, many patients will have variations of this presentation (eg, children, elderly, pregnant, retrocecal appendix, malrotation); therefore, appendicitis should *always* be considered in acute abdomen. Appendicitis should not be ruled out based on urinalysis (UA) or urologic symptoms.

What are five causes of this diagnosis?

All causes result in lumen obstruction causing increased distention and pressure leading to ischemia and eventually necrosis:

1. Hypertrophied lymphoid tissue
2. Fecalith
3. Foreign body
4. Parasite
5. Tumor (carcinoid)

What is the next step in management?

The diagnosis of appendicitis can be made on history and physical and requires emergent appendectomy (a 20% false-positive rate for appendectomy is accepted). Prior to surgery the patient should have correction of electrolytes, blood cultures, and IV antibiotics. For cases where appendicitis is highly suspected, radiographic studies are not necessary, although in practice, patients who present with RLQ pain typically have imaging studies.

If the patient above presented with RLQ abdominal pain associated with guarding and rebound tenderness, WBC 19,000, and temperature of 102°F what would be the next step in diagnosis?

The patient in question has a history suggestive of appendiceal rupture. Rupture should be suspected if temperature >102°F and leukocytosis >18,000. Often patients will display localized tenderness, unless the walling-off

079_BOOKZ

process is ineffective, then they will display generalized peritonitis. Imaging of choice is institution dependent, however:

- Contrast enhanced CT abdomen/pelvis to evaluate for abscess formation (male or nonpregnant patients)
- Ultrasound (US) typically reserved for pregnant patients or children to minimize radiation exposure

What is the treatment for appendiceal rupture?

Patient should be continued on antibiotics until fever and leukocytosis resolves. If abscess is present, this may be managed with percutaneous drainage. Elective appendectomy should be performed in 6–8 weeks following acute event.

079_BOOKZ

This page intentionally left blank

Index

Page numbers followed by a *t* or *f* indicate that the entry is included in a table or figure.

A
AAA. *See* abdominal aortic aneurysm
abdomen
  mass of, in Crohn's disease, 41
  trauma to
    evaluation of, 171
    intraperitoneal, 166
    laparotomy for, 169
    management of, 169*f*
    multiple, 169
    retroperitoneal, 166, 167
    surgical exploration in, 169
    zones of, 166–167
abdominal aortic aneurysm (AAA), 253–254
abdominal compartment syndrome, 170, 183
ABG. *See* arterial blood gas
ABI. *See* ankle brachial index
abscess(es)
  airway and, 299
  amebic, 99, 100
  anorectal, 59, 60
  appendicitis and, 34
  aspiration pneumonia and, 273–274, 273*f*
  crypt, in ulcerative colitis, 41
  hepatic, 97
  in pediatrics, 243
  peritonsillar, 299
  pyogenic, 99, 100
  treatment of, 203
  tuboovarian, appendicitis *vs.*, 33
abuse, child, fractures and, 375
ACC. *See* adrenal cortical carcinoma
accessory spleens, 63, 63*f*
  idiopathic thrombocytopenic purpura and, 72
  imaging of, 73
acetabular fracture, 362
acetylcholine, from vagus nerve, 18, 19*f*
achalasia, 2
  barium swallow of, 5, 5*f*
  carcinoma and, 5
  causes of, 5
  treatment for, 5–6
Achilles tendon disruption, 364
acid burn, 196
acidemia, 185
acidosis, small bowel obstruction and, 39
actinic keratosis, 207
acute abdomen, 49
Acute Physiology and Chronic Health Evaluation (APACHE II), 119
  prognostic factors using, 120
acute renal failure (ARF), 186
  intrinsic, 186, 187
Addison's disease, 146–147
adenocarcinomas, 317
  dysphagia and, 11
  gastric, 26, 27
  of lung, 270, 271
  small bowel tumors, 43
adenoma tubular polyp, 54
  malignant transformation of, 54
adenoma villous polyp, 54
adenomatous gastric polyp, 26
adenotonsillar hypertrophy, 299
adhesions, small bowel obstruction and, 36, 51
adrenal cortex, layers of, 131
adrenal cortical carcinoma (ACC), 149
adult respiratory distress syndrome (ARDS), 162, 186
airway
  abscess and, 299
  surgical, 153
  in trauma patient, 153
airway obstruction, 158
  in burns, 193
alanine aminotransferase/aspartate aminotransferase (AST/ALT), bile duct obstruction and, 103
albendazole, for hydatid cysts, 99
alcoholic cirrhosis
  esophageal varices and, 96
  hematemesis and, 13

Copyright © 2008 by The McGraw-Hill Companies, Inc. Click here for terms of use.

079_BOOKZ

alcoholism
head cancer and, 296
Mallory-Weiss tear and, 13
neck cancer and, 296
pancreatitis and, 118
peptic ulcer disease and, 13
withdrawal of, 120
aldosterone
in cirrhosis, 91
release of, 131
alkali burn, 196
alkaline phosphatase, bile duct obstruction and, 103
alkaline reflux gastritis, 25
allograft, 281
allopurinol, 290
alpha-fetoprotein, hepatocellular carcinoma and, 89
Altemeier tumor, 112
alveolar nerve, damage to, 301
ambiguous genitalia, 248
amebic abscesses, 99, 100
amniotic fluid, bowel and, 247
ampicillin/sulbactam, for peritonitis, 50
AMPLE history, 151
ampulla of Vater, 102, 102*f*, 115, 115*f*
amputation
of extremities, 261
necrotic toe and, 206
sarcoma and, 210
vascular injury and, 358
amrinone, 184
amylase, bile duct obstruction and, 103
anabolic steroid use, hepatic adenoma and, 88
anal cancer
human papilloma virus and, 62
obstructed defecation and, 61
anal fissures, 59
treatment of, 59
anal stenosis, 59
anastomotic leak, 307
anastrozole, 229
anatomic sniff box, pain at, 362
androgen ablation therapy, 318
anemia
cold antibody related, 68–69
Cooley's, 67
Coombs' negative hemolytic, 68
Coombs' positive hemolytic, 68
idiopathic autoimmune hemolytic, 69
iron deficiency, 69
macrocytic, 17
megaloblastic, small bowel and, 31
pernicious, 17
warm antibody related, 68, 69
aneurysmal bone cyst, 372–373
aneurysms, 252
cerebral, 338
popliteal, 256
angiodysplasia, 48
gastrointestinal bleeding and, 48
angle of His, 1
ankle
dislocation of, 363
fracture of, 363
ankle brachial index (ABI), 173, 260
annular pancreas, 116, 117*f*
anorectal abscess, 59, 60
antithymocyte globulins, 283
antrectomy
peptic ulcer disease and, 21
reconstructions after, 22–24, 22–24*f*
anxiety, hyperparathyroidism and, 145
aorta, branches of, 1, 3*f*, 251
aortic dissection, 256–259
appearance of, 256*f*
DeBakey classification of, 257, 257*f*
Stanford classification of, 257, 257*f*
aortic insufficiency, 275–276
aortic stenosis, 276–277
aortic transection, treatment of, 163
aortic valve insufficiency, 258
aortoiliac occlusion, 259
APACHE II. *See* Acute Physiology and Chronic Health Evaluation
APC tumor suppressor, adenoma and, 54
aponeurosis, 75
appendectomy, 34, 35*f*
appendicitis
abscess formation in, 34
ages for, 32
cause of, 31
cholecystitis *vs.*, 108
complicated (perforated), 34
diagnosis of, 33
etiologies of, 32
females and, 33
imaging and, 34
labs for, 34
pain and, 32, 33
patient position in, 33
in pediatrics, 243
peritoneal signs in, 33

signs/symptoms of, 33
treatment for, 34, 35*f*
viral/bacterial illness and, 32
appendix
carcinoid tumor of, 34
inflammation of. *See also* appendicitis
vermiform, 31
APUD system (amine precursor uptake and decarboxylation), tumors in, 35
ARDS. *See* adult respiratory distress syndrome
ARF. *See* acute renal failure
arrhythmias
defibrillation and, 187
myocardial contusions and, 163
arterial blood gas (AGB), respiratory distress and, 185
arterial injury
hard signs of, 173
soft signs of, 173
arterial insufficiency ulcer, 206, 260
arterial ischemia, to extremities, 255
arterial stenosis, 251
arterial thrombosis, 254–255
artery(ies)
of breast, 217, 219
of colon, 45, 46*f*
of duodenum, 16*f*
of esophagus, 1, 3*f*
of liver, 87
of pancreas, 16*f*
of pancreas tail, 116
of pancreatic head, 116, 117*f*
of spleen, 16*f*, 65
of stomach, 15, 16*f*
of thyroid gland, 127
arthritis, 365–366
articular cartilage, 356
asbestos, 272–273
ascites
causes of, 95
etiology of, 96
treatment of, 96
aspiration pneumonia, abscess formation and, 273–274, 273*f*
AST/ALT. *See* alanine aminotransferase/aspartate aminotransferase
astrocytoma, 349, 350
atherosclerosis, 251, 262, 278
atonic bladder, 324
atrial fibrillation, 187–188, 272
Auerbach's plexus. *See* myenteric plexus
autograft, 281
autonomic dysreflexia, 342
axial flap, 214, 214*f*
axillary lymph nodes dissection, 219
axillary tail of Spence, 219
axonotmesis, 344
AZA. *See* azathioprine
azathioprine (AZA), 283

B

backwash ileitis, 41
bacteria, of colon, 45
Bacteroides fragilis
of colon, 45
peritonitis and, 49
banding, cirrhotic esophageal variceal bleeding and, 14
bariatric surgery, 305–308
Barium swallow, of achalasia, 5, 5*f*
Barrett's esophagus, 10
cancer and, 10–11, 10*f*
Bassini repair, of hernias, 78, 78*f*
Beck's triad, 159, 182
Bell stages, of necrotizing enterocolitis, 242
Bell's palsy, 299
Belsey Mark IV, gastroesophageal reflux disease and, 9
benign prostatic hyperplasia (BPH), 316
bezoar, 26
bile duct obstruction
alanine aminotransferase/aspartate aminotransferase and, 103
alkaline phosphatase and, 103
amylase and, 103
direct bilirubin and, 103
indirect bilirubin and, 103
urobilinogen and, 103
bile, lipids in, 103
bile salts, 103
biliary colic, 104
biliary disease, imaging studies in, 105
biliary-type epithelium, 97
bilious emesis, 237
Billroth I, 22, 22*f*
Billroth II, 23, 23*f*
bird beak, 5
bladder, cancer of, 319–321
staging of, 320*f*
bladder outlet obstruction (BOO), 316

bleeding
arterial, 173
hemorrhoids and, 58
periurethral, 171
prolonged, small bowel and, 31
venous, control of, 173
volume replacement solution for, 155
blind loop syndrome, 25
blood donation, 154
blood sugar, in cirrhosis, 91
blood volume
body weight and, 154
in pediatric surgery, 231
blue toe syndrome, 255
Blumer's shelf, metastatic gastric cancer and, 27
BMI. *See* body mass index
body mass index (BMI), 305
body weight, blood volume and, 154
Boerhaave's syndrome, 164–165
causes of, 13
esophageal perforation and, 12
presentation of, 13
bone growth, 355
bone tumors, 368–374
aneurysmal bone cyst, 372–373
chondroblastoma, 372
chondrosarcoma, 372
chordoma, 373
enchondroma, 372
Ewing's sarcoma, 373
giant cell tumor, 373
histiocytic lymphoma, 373
location of, 369, 369*f*
metastasis and, 368
osteoblastoma, 371
osteochondroma, 371
osteoclastoma, 373
osteoid osteoma, 370–371
osteosarcoma, 371
resection of, 370, 370*f*
unicameral bone cyst, 372
BOO. *See* bladder outlet obstruction
botulism toxin, endoscopic intrasphincteric injection of, for achalasia, 5
bowel movements
in Crohn's disease, 41
in ulcerative colitis, 41
bowel, obstruction of. *See* large bowel obstruction; small bowel obstruction
BPH. *See* benign prostatic hyperplasia
brachial cleft cyst, in pediatrics, 233
brachial plexus, organization of, 345–346, 345*f*
brain herniation, 331–333, 332*f*
brain tumor, pediatric, 348
BRCA1, 224
BRCA2, 224
breast(s)
arterial supply to, 217, 219
axillary lymph nodes dissection in, 219
benign conditions of, 219
cancer of, 222–224
invasive, 227–230
ductal carcinoma in situ, 224–226
infection of, 221–222
lobe of, 217, 218*f*
lobular carcinoma in situ, 226
lymphatic drainage of, 219, 220*f*
masses of, 222–224
cystic, 223
differential diagnosis of, 222
nipple discharge, 221
pain of, 220–221
cancer *vs.*, 221
support of, 217, 218*f*
tissue of, 217
estrogen and, 217
progesterone and, 217
breath sounds, diminished/unilateral, 153
Broca's area, in brain, 325
bromocriptine, for breast pain, 220
bronchial artery, 1, 3*f*
bronchial tree, injury to, diagnosis of, 164
bronchiectasis, 274–275
bronchoalveolar carcinoma, 270
bronchogenic cyst, 235
brown tumor, 145
Brown-Séquard syndrome, 326
burn(s)
acid, 196
airway obstruction in, 193
alkali, 196
area classification of, 191, 192*f*
chemical, 196
classification of, 189
clinical appearance of, 191*t*
Curling's ulcer and, 21
electrical, 197
escharotomy for, 195, 196*f*
fascial excision, 198

frostbite, 197–198
healing time of, 191*t*
hydrofluoric acid, 197
infection and, 195
inhalation injury, 193
Jackson classification of, 191
LD50 (lethal dose in 50%), 193
lightning strike, 197
multisystem trauma and, 193
re-epithelialization and, 189, 190*f*
rule of 9's and, 191–192
shock and, 194, 195
skin graft, 199
skin layers and, 189
stress ulcers and, 21
tangential excision, 198
tetanus immune globulin and, 195
tetanus toxoid booster and, 195
treatment for, 193, 198–199
wound excision and, 198

C
CA. *See* cancer antigen
CABG. *See* coronary artery bypass graft
calcitonin, 131, 140
thyroid carcinoma and, 140
calcium channel blockers
for achalasia, 5
for afterload reduction, 185
calcium oxalate/phosphate calculi, 315
calculi, 315
callus formation, in bone healing, 356
cancer
of bladder, 319–321
staging of, 320*f*
of breast, 222–224
invasive, 227–230
breast pain *vs.*, 221
gastric, 26, 27
of head, 296
inflammatory breast, 222
of lips, 296
of lungs, 270, 271–272
of neck, 296
neck dissection and, 294
of prostate, 316–318
of skin, 207
basal cell, 207
melanoma, 208–209
squamous cell, 207
testicular, 318–319
of tonsils, 296
cancer antigen (CA), 126
caput medusae, 93
carbon monoxide poisoning, 193–194, 194*t*
carbuncle, 204
carcinoid tumors
of appendix, 34
diagnosis of, 36
serotonin hormone and, 36
small bowel, 43
cardiac output, 178
cardiac tamponade, 158, 182, 287
cardiac output decrease and, 158
causes of, 158
management of, 159
pericardiocentesis for, 159
cardiogenic shock, 154, 177, 179, 181
causes of, 158
signs of, 158
carina, 266
carotid blowout, 299
carotid pulse, systolic blood pressure of, 154
carpal tunnel syndrome, 367
catecholamines, 131
cauda equina syndrome, 347
caudate lobe, of liver, 85, 86*f*
cauliflower ear, 300
caustic ingestion, 165
cavernous hemangioma, characteristics of, 87–88
CCAM. *See* congenital cystic adenomatoid malformation
C-cells, 128, 139
CD4 T_H1 cells, 289
CD4 T_H2 cells, 289
CD8 T-cells, 289
CDH. *See* congenital diaphragmatic hernia
cellulitis, 203
central nervous system tumors, 348–353
central venous catheter, 187
central venous pressure (CVP), 178
elevation of, false, 179
cerebral aneurysms, 338
cerebral artery vasospasm, 338
cerebral contusions, 334
cerebral edema, 330
cerebral perfusion pressure (CPP), 329
cerebrospinal fluid, choroid plexus and, 326
cervical spine, injury to, 173–174

079_BOOKZ

Chagas disease, 5
Charcot's triad, 106, 107
chemical burns, 196
chemotherapy
  adjuvant, 229
  systemic, melanoma and, 209
chest tube, for hemothorax, 159, 160*f*
chest wall, deformity of, 265
chief cells, 17
child abuse, fractures and, 375
cholangiocarcinoma, 112
cholangitis, 106
  diagnosis of, 107
  symptoms of, 110
cholecystectomy, 108*f*
  for cholecystitis, 108
  for gallstones, 105
cholecystitis, 106
  appendicitis *vs.*, 108
  characteristics findings in, 105
  cholecystectomy for, 108
  complications of, 107
  diagnosis of, 107
  gangrenous, 109
  inflammation and, 107
  laparoscopic techniques, 109*f*
cholecystokinin, 103
choledochal cysts, 113, 113*f*
  in pediatrics, 245
choledocholithiasis, 106
  diagnosis of, 107
  symptoms of, 110
cholelithiasis, 106
cholesteatoma, 298
cholesterol, bile and, 103
cholesterol stones, 103
chondroblastoma, 372
chondrosarcoma, 372
chordoma, 373
choriocarcinoma, 318
chorionic gonadotropin, 248
choroid plexus papilloma/carcinoma, 351–352
chronic mesenteric ischemia, 261
chylothorax, 269–270
ciprofloxacin, for peritonitis, 50
cirrhosis, 90–96
  alcoholic. *See* alcoholic cirrhosis
  aldosterone in, 91
  blood sugar in, 91
  causes of, 90–96
  complications of, 91
  drug metabolism in, 91
  estrogen in, 91
  liver size in, 91
  prothrombin time in, 91
  serum cholesterol in, 91
  signs of, 91
  testosterone in, 91
  transaminases levels in, 91
cirrhotic esophageal variceal bleeding, treatment of, 14
claudication, non-limb-threatening, 261
CLE. *See* congenital lobar emphysema
cleft lip/palate, 215–216
clindamycin, for peritonitis, 50
Clostridium difficile, pseudomembranous colitis and, 50
Clostridium perfringens, cholecystitis and, 107
cold antibody related anemia, 68–69
colic
  biliary, 104
  pain and, 50
  patient position with, 49
colitis, pseudomembranous, 50
Colles fracture, 362
colon
  aerobic bacteria of, 45
  anaerobic bacteria of, 45
  arterial supply of, 45, 46*f*
  cancer of
    arterial supply resection and, 56
    in Crohn's disease, 41
    gastrointestinal bleeding and, 48
    lab tests for, 56
    left-sided, 55
    lymph node involvement in, 55
    right-sided, 55
    staging of, 55
    treatment of, 55
    in ulcerative colitis, 41
  diverticular disease of, 47
  intraperitoneal parts of, 45
colon cutoff sign, 119
colorectal carcinoma
  risk factors for, 53
  screening for, 55
colovesical fistulas, 61
comminuted fracture, 335, 360, 361*f*
community acquired pneumonia, 186
compartment syndrome, 357, 358*f*
compound/open fracture, 335
condyloma acuminata, 205
  obstructed defecation and, 61

079_BOOKZ

congenital cystic adenomatoid malformation (CCAM), 234
congenital cysts, 97
congenital diaphragmatic hernia (CDH), 233–234
congenital lobar emphysema (CLE), 234
Conn's syndrome, 145–146
Cooley's anemia, 67
Coombs' negative hemolytic anemia, 68
Coombs' positive hemolytic anemia, 68
Coombs' test, 68
Cooper's ligament, 76
  repair of, of hernias, 79, 79*f*
corkscrew esophagus. *See* diffuse esophageal spasm
corneal transplant, 281
coronary artery bypass graft (CABG), 278, 279
coronary blood flow, 181
coronary vein. *See* left gastric vein
corticosteroids, 283
  shock and, 157
coupe injury, 334
coupling, thyroid hormone production and, 129
Courvoisier's sign, 106–107, 125
CPP. *See* cerebral perfusion pressure
craniopharyngioma, 353
craniosynostosis, 216, 216*f*
cricopharyngeus muscle, 1
cricothyroidotomy, 153–154, 303
criminal nerve of Grassi, 16, 26
Crohn's disease, 40
  appendicitis *vs.*, 34
  extraintestinal manifestations of, 42
  gastrointestinal tract involvement in, 40
  inflammation and, 40
  signs/symptoms of, 41
  spread pattern in, 41
crypt abscesses, in ulcerative colitis, 41
cryptorchidism, 248, 318
Cullen's sign, 118, 167
Curling's ulcer, 21
Cushing's disease, 147, 148
Cushing's syndrome, 146, 147, 148, 149, 271
Cushing's triad, 330
Cushing's ulcer, 21
CVP. *See* central venous pressure
cyanide. *See* thiocyanate toxicity
cyclosporine, 283, 290
cyst(s)
  choledochal, 113, 113*f*
  congenital, 97
  cutaneous, 206–207
  hepatic, 97–100
  hydatid, 97, 98
  neoplastic, 97
  simple, 97
cystadenomas, 98
cystic fibrosis, 241
cystic fluid, 99
cystic hygroma, in pediatrics, 233
cystic thyroid mass, 139
cystine calculi, 315
cystitis, 310–311

D

D cells, 17
danazol, for breast pain, 220
DCIS. *See* ductal carcinoma in situ
DDH. *See* developmental dysplasia of hip
de Quervain's thyroiditis, 134, 135
death
  of children, 232
  in congenital diaphragmatic hernia, 234
  lightning strike and, 197
  lung cancer and, 270
  necrotizing soft tissue infection and, 204
  from tension pneumothorax, 161
DeBakey classification, of aortic dissection, 257, 257*f*
decision making, in brain, 325
deep partial thickness burns, 189, 191, 198
defecation, obstructed, 61
defibrillation, arrhythmias and, 187
dehydration, fistulas and, 62
dentate line, 57, 57*f*
depressed fracture, 335
dermoid cyst, 206, 207
detrusor areflexia, 324
detrusor hyperreflexia, 324
detrusor sphincter dyssynergia (DSD), 324
developmental dysplasia of hip (DDH), 374
diabetic acidosis, 333
diabetic foot ulcer, 206
diagnostic peritoneal lavage (DPL), 168
diaphragm, free air under, 21

diaphragmatic constriction point, 1
diarrhea
  in Crohn's disease, 41
  fistulas and, 62
  in ulcerative colitis, 41
DIC. *See* disseminated intravascular coagulation
diffuse esophageal spasm, 2, 3, 4*f*
diffusely infiltrating gastric cancer, 27
digital rectal exam, 47
direct bilirubin, bile duct obstruction and, 103
dislocation(s)
  of ankle, 363
  of hip, 363
  of knee, 363
  of shoulder, 363
dissecting aneurysm, 252
disseminated fungal infection, 157
disseminated intravascular coagulation (DIC), thrombocytopenic purpura and, 72
distal humerus, fracture of, 361
distal ileitis, in ulcerative colitis, 41
distal rectum, blood supply to, 45
diverticular bleeding, 48
diverticular disease
  of colon, 47
    etiology of, 47
  sigmoidoscopy for, 49
diverticulitis, 48, 60
  appendicitis *vs.*, 34
  complications of, 49
  laparotomy in, 49
  treatment of, 49
diverticulosis, 47
  gastrointestinal bleeding and, 48
  presentation of, 47
  signs/symptoms of, 47
  treatment for, 47
DO_2. *See* oxygen delivery
dobutamine, for postmyocardial infarction cardiogenic shock, 184
dopamine concentration, dependence of, 184
double bubble sign, 237, 238*f*
double duct sign, 103
DPL. *See* diagnostic peritoneal lavage
drop metastases, metastatic gastric cancer and, 27
drug abuse, 339
drug metabolism, in cirrhosis, 91
DSD. *See* detrusor sphincter dyssynergia
ductal carcinoma in situ (DCIS), 224–226
dumping syndrome
  early, 24
  late, 25
duodenal atresia, 237, 238*f*
duodenum, 29
  arterial supply of, 16*f*
  blood supply to, 29
  ulcers of
    gastrinoma and, 26
    Helicobacter pylori and, 20
    symptoms of, 20
Duplex ultrasound, in extremity trauma, 173
Dupuytren's contracture, 367
Duret hemorrhages, 333
Duval procedure, for chronic pancreatitis, 123
dyspepsia, peptic ulcer disease and, 20
dysphagia
  gastroesophageal reflux disease and, 11
  Nissen fundoplication and, 9
dysplastic nevi, melanoma and, 208

E

ears
  infection of, 297–298
  trauma to, 300
EA/TEF. *See* esophageal atresia/tracheoesophageal fistula
ecchymoses, 67
Echinococcus granulosus, hydatid cysts and, 98
ectopic adrenocortical tissue, 132
ectopic pregnancy, appendicitis *vs.*, 33
EDVI. *See* end diastolic volume index
EGD. *See* esophagogastroduodenoscopy
electrical burns, 197
ELM. *See* extraperitoneal laparoscopic repair
embryonal carcinoma, 318
emotional restraint, in brain, 325
encephalopathy, hepatic. *See* hepatic encephalopathy
enchondroma, 372
end diastolic volume index (EDVI), 178
endarterectomy, 261
endochondral ossification, 355
endoscopic pneumatic dilation, for achalasia, 6

079_BOOKZ

endoscopic retrograde cholangiopancreatogram (ERCP), 106
endoscopy
chronic gastritis and, 20
gastric cancer and, 27
gastroesophageal reflux disease and, 6
peptic ulcer disease and, 20
end-stage liver failure, 285
enteric nervous system
Meissner's plexus and, 29
myenteric plexus and, 29
enteroclysis, small bowel tumors and, 43
enterocutaneous fistulas, 61
enteroenteral fistulas, 61
ependymoma, 351
epidermal burns, 189, 191
epidermal cyst, 206
epididymo-orchitis, 313
epinephrine, for shock, 184
epithelialization, wound healing and, 201
epithelium
gastric, 36
pancreatic, 36
EPS. *See* expressed prostatic sections
ERCP. *See* endoscopic retrograde cholangiopancreatogram
escharotomy, for burns, 195, 196*f*
Escherichia coli
cholecystitis and, 107
of colon, 45
peritonitis and, 49
esophageal atresia/tracheoesophageal fistula (EA/TEF), 235–236, 236*f*
esophageal battery, 235
esophageal hiatus, 1
esophageal varices, 13–14, 93, 96
esophagogastroduodenoscopy (EGD), gastrointestinal bleed and, 14
esophagram, gastroesophageal reflux disease and, 6
esophagus
arterial arrangement of, 2
arteries of, 1, 3*f*
constriction points of, 1
foreign body of, 235
injury to, 164–165, 176
layers of, 1
leiomyomas of, 12
lower, 1
lymphatic arrangement of, 2
malignant carcinoma of, 11
neoadjuvant therapy for, 11
surgical approach for, 11–12, 12*f*
motility disorders of, 2, 3
perforation of, 12
regions of, 1
rupture of, 13
upper, 1
venous arrangement of, 2
estrogen
breast tissue and, 217
in cirrhosis, 91
ESWL. *See* extracorporeal shock wave lithotripsy
EtOH ingestion, acute gastritis and, 20
Evan's syndrome, 71
Ewing's sarcoma, 373
executive functioning, in brain, 325
expressed prostatic sections (EPS), 312
extracorporeal shock wave lithotripsy (ESWL), 315
extraperitoneal laparoscopic (ELM) repair, of hernias, 83, 83*f*
extremities
amputation of, 261
arterial atresia to, 255
trauma of, 173
exudate effusion, 269
eyelid, trauma to, 300

F

face, fracture of, 300
fasciotomy, 357, 358*f*
FAST scan. *See* focused abdominal sonography for trauma scan
felon, 367
female pseudohermaphroditism, 248
females, appendicitis and, 33
femoral hernia, 76
femoral neck fracture, 362
femoral pulse, systolic blood pressure of, 154
femoral shaft fracture, 362
FENa. *See* fractional excretion of sodium
FHN. *See* focal nodular hyperplasia
fibroadenoma, 223
fight bite, 368
fine needle aspiration (FNA), 138
for breast mass, 223
first degree burns. *See* epidermal burns
fistula *in ano*, 60, 61

079_BOOKZ

fistulas, 60, 61–62
causes of, 61
closing of, 61
colovesical, 61
in Crohn's disease, 41
enterocutaneous, 61
enteroenteral, 61
symptoms of, 62
vesicovaginal, 61
Fitz-Hugh-Curtis syndrome, 85
FK-506 (tacrolimus), 283
flail chest, 158, 162
flank pain, 253
flaps. *See specific flap*
flexor tenosynovitis, 367
fluid bolus, 155
in pediatric surgery, 231
FNA. *See* fine needle aspiration
focal nodular hyperplasia (FNH), 88–89
focused abdominal sonography for trauma (FAST) scan, 167, 168
Foley catheter, 309
urine output and, 172
follicle stimulating hormone (FSH), 318
follicular carcinoma, thyroid cancer and, 139
follicular cells, 128
folliculitis, 204
foot, ulcers of, 206
foramen of Magendie, 327
foramen of Winslow, stomach and, 17, 18*f*
foramina of Luschka, 327
foramina of Monroe, 327
foreign body, esophageal, 235
fourth degree burns, 189
fractional excretion of sodium (FENa), 186
fracture(s)
acetabular, 362
ankle, 363
child abuse and, 375
Colles, 362
distal humerus, 361
of face, 300
femoral neck, 362
femoral shaft, 362
Galeazzi, 361
of hip, 362
intertrochanteric, 362
of larynx, 164
of long bone, 360
of mandible, 301, 301*f*
metacarpal, 367
of midshaft femur, 173
Monteggia, 362
of nose, 300
open, 358–359
orbital blowout, 301
pathologic, 368
patterns of, 360, 361*f*
of pelvis, 172, 324, 359
of ribs, 162–163
scaphoid, 362
of skull, 335–336
temporal bone, 302
tibial shaft, 363
zygoma, 301
free flap, 215
Frostberg inverted-3 sign, 119
frostbite, 197–198
FSH. *See* follicle stimulating hormone
FTSG. *See* full thickness skin graft
full thickness burns, 189, 191
full thickness skin graft (FTSG), 213
fungating gastric cancer, 27
furuncle, 204
fusiform aneurysm, 252

G

G cells, gastrin from, 17, 18, 19*f*
G6PD. *See* glucose-6-phosphate dehydrogenase
galactorrhea, 221
Galeazzi fracture, 361
gallbladder
cholecystokinin and, 103
perforation of, 110
gallbladder cancer, 112
gallstone ileus, 111
gallstone pancreatitis, 121
gallstones
cholecystectomy for, 105
oral contraceptives and, 104
radiolucent, 105
radiopaque, 105
risk factors for, 104
small bowel and, 30–31
symptoms of, 104
types of, 103–104
gamma-glutamyltranspeptidase (GGT), 103
gangrene, 260
gangrenous cholecystitis, 109

079_BOOKZ

Gas-bloat syndrome, Nissen fundoplication and, 9
gastric acid, secretion of, 18, 19*f*
gastric bypass, 306–307
gastric cancer
  classifications of, 27
  metastatic spread of, 27
  risk factors of, 27
  treatment of, 27
  weight loss and, 26
gastric polyps, 26
gastric tumors, 26
gastric ulcers
  acid hypersecretion and, 20
  Helicobacter pylori and, 20
  symptoms of, 20
  types of, 19
gastric varices, 93
gastrin, from G cells, 17, 18, 19*f*
gastrinomas, 26, 126
gastritis
  acute, causes of, 20
  alkaline reflux, 25
  chronic, types of, 20
  stress-related, 20, 21
gastroesophageal reflux disease (GERD), 2
  24-hour pH test, 6
  Barrett's esophagus and, 10
  complications of, 6
  diagnostic tests for, 6
  dysphagia and, 11
  nonsurgical treatment for, 6
  risk factors for, 6
  surgical complications of, 10
  surgical treatment of, 9
  symptoms of, 6
gastrointestinal stromal tumor (GIST), 210
gastrointestinal (GI) tract
  bleeding of, 48, 49
    causes of, 48
  innervation to, 29
  malabsorption and, 30
  Meckel's diverticulum, 36
  tumors of, 42–43
    hamartoma, 43
    hemangioma, 43
    leiomyomas, 43
    location, 42
    patient presentation of, 42
    treatment of, 43
gastroschisis, 246–247
GCS. *See* Glasgow Coma Scale
genital warts. *See* condyloma acuminate
genitalia, ambiguous, 248
GERD. *See* gastroesophageal reflux disease
GGT. *See* gamma-glutamyltranspeptidase
ghrelin, 306
GI. *See* gastrointestinal tract
giant cell tumor, 373
giant hairy nevus, 219
GIST. *See* gastrointestinal stromal tumor
Glasgow Coma Scale (GCS), 151–152, 152*t*, 347, 347*t*
Gleason grading system, 317
glial cell tumors, 349
glioma, 348
Glisson's capsule, 85
glucagonoma, 126
glucose-6-phosphate dehydrogenase (G6PD), splenectomy and, 73
goiters, 133
Goodsall's rule, 60, 60*f*
grafts. *See specific graft*
Graham patch, perforated ulcer and, 24, 25*f*
gram negative bacilli, peritonitis and, 49
granulomas, in Crohn's disease, 41
Graves disease, 134, 135
Grey-Turner's sign, 118, 167
gross hematuria, 324
group A streptococci, spleen and, 66
Grynfelt's hernia, 77
GSW. *See* gun shot wound
gun shot wound (GSW), 171
gynecomastia, 271

H

Haemophilus influenzae type B, spleen and, 66
hamartomas, 43, 54, 267
hamburger sign, appendicitis and, 33
hard signs, of arterial injury, 173
Hashimoto's thyroiditis, 134, 135
HCC. *See* hepatocellular carcinoma
head
  cancer of, 296
  injuries to
    Cushing's ulcer and, 21
    stress ulcer and, 21
heart transplant, 288

Helicobacter pylori
diagnosis of, 20
duodenal ulcers and, 20
gastric ulcers and, 20
treatment of, 20
Heller myotomy, for achlasia, 6, 7*f*
hemangioma, 43
cavernous
characteristics of, 87–88
in pediatrics, 211
hematemesis, 45
hematochezia, 47
hematoma, 336
hemolytic uremic purpura
hemolytic uremic syndrome and, 72
pathology of, 71
platelet transfusions and, 70
prognosis of, 71
treatment of, 71
hemolytic uremic syndrome (HUS), thrombocytopenic purpura and, 72
hemorrhages, 337–339
treatment of, 155
hemorrhagic shock, vasoconstrictors in, 155
hemorrhagic stroke, 341
hemorrhoidectomy, 58
hemorrhoids, 93
causes of, 58
signs/symptoms of, 58
treatment of, 58
types of, 58
hemothorax, 158, 159
surgical indications for, 160
symptoms of, 159
treatment of, 159, 160*f*
hepatic abscesses, 97
hepatic adenomas
anabolic steroid use and, 88
CT scan findings of, 88
liver function tests and, 88
oral contraceptives and, 88
treatment of, 88
hepatic cysts, 97–100
hepatic encephalopathy
diagnosis of, 95
signs/symptoms of, 95
treatment of, 95
hepatobiliary iminodiacetic acid scan (HIDA), 105
hepatoblastoma, 90, 249, 250
hepatocellular carcinoma (HCC), 89, 250
alpha-fetoprotein and, 89
diagnosis of, 90
prognosis of, 90
hepatorenal syndrome (HRS), 91, 92
hereditary spherocytosis, 67
splenectomy and, 73
hernia(s)
femoral, 76
Grynfelt's, 77
incarceration, 75
incisional, 77
inguinal, 247
Littre's, 77
obesity and, 77
pantaloon, 76
Petit's, 77
presentation of, 77
reducible, 75
repair of, 78–83
Bassini, 78, 78*f*
Cooper's ligament, 79, 79*f*
extraperitoneal laparoscopic, 83, 83*f*
with intraperitoneal onlay mesh, 83
laparoscopic, 82–83
Lichtenstein, 81, 81*f*
Marcy, 80, 80*f*
McVay's, 79, 79*f*
Shouldice, 81, 82*f*
totally extraperitoneal, 83, 83*f*
transabdominal pre-peritoneal, 82
Richter's, 75
sliding, 75
small bowel obstruction and, 36, 51
Spigelian, 77
strangulation, 75
strangulation and, 77
umbilical, 246
ventral, 77
Hesselbach's triangle, 76
heterotopic graft, 281
hiatal hernias
reflux and, 6
repair of, 6
types of, 6, 8*f*
HIDA. *See* hepatobiliary iminodiacetic acid scan
hidradenitis suppurativa, 205

hip
dislocation of, 363
fracture of, 362
Hirschsprung's disease, 244
histamine, 18, 19*f*
histiocytic lymphoma, 373
HIV. *See* human immunodeficiency virus (HIV)
horizontal mattress skin closure, 211, 212*f*
hormone therapy, invasive breast cancer and, 229
Horner syndrome, 271
HPS. *See* hypertrophic pyloric stenosis
HPV. *See* human papilloma virus
HRS. *See* hepatorenal syndrome
human immunodeficiency virus (HIV), idiopathic thrombocytopenic purpura and, 71
human papilloma virus (HPV)
anal cancer and, 62
tonsillar carcinoma and, 296
HUS. *See* hemolytic uremic syndrome
hydatid cysts, 97, 98
albendazole for, 99
hydrocele, 76
hydrocephalus, 327–328, 350
hydrochloric acid, 17
hydrocolpos, 248
hydrofluoric acid burn, 197
hydronephrosis, 309
hyperaldosteronism, 146
hypercalcemia, 143, 271
symptoms of, 144–145
hypercarbia, 153
hyperchloremic acidosis, 155, 195
hyperglycemia, 180
hyperparathyroidism, 140, 143
anxiety and, 145
hyperplastic gastric polyp, 26, 54
hypersplenism, 66
diagnosis of, 67
hypertensive hemorrhage, 338
hyperthyroidism, 129, 130
causes of, 133
hypertonic neurogenic bladder, 324
hypertrophic pyloric stenosis (HPS), 237
hypertrophic scar, 206
hypertrophied anal papilla, 59
hypoadrenal shock, 157
hypocalcemia, 197
hypogastric plexus, parasympathetic innervation and, 29
hypopharynx, structures of, 295*f*
hypothalamic-pituitary-thyroid axis, 4*f*
hypothyroidism, 130, 136
hypovolemic shock, 154, 177, 183
classes of, 155*t*, 180
hypoxia, 153
pulmonary contusion and, 162

I

IBD. *See* inflammatory bowel disease
ICP. *See* intracranial pressure
ICU. *See* intensive care unit
idiopathic autoimmune hemolytic anemia, 69
idiopathic thrombocytopenic purpura (ITP), 70
accessory spleen and, 72
characteristics of, 70
human immunodeficiency virus and, 71
intravenous immunoglobulin in, 71
platelet transfusions in, 71
ileum
blood supply to, 29
jejunum *vs.*, 29, 30*f*
ileus, 39
causes of, 39
meconium, 241
treatment for, 39, 52
impermeable bag, splenectomy and, 73
incarceration hernia, 75
incisional hernia, 77
incontinence, 322–324
indirect bilirubin, bile duct obstruction and, 103
infectious granulomas, 267
inferior mesenteric artery, 45
inferior phrenic artery, 1, 3*f*
inferior thyroid artery, 1, 3*f*
infiltrating carcinoma, 5
inflammatory arthritis, 365
inflammatory bowel disease (IBD)
ages for, 40
anal fissure and, 59
Crohn's disease, 40
medical management of, 42
smoking and, 42
surgical indications for, 42
ulcerative colitis, 40

inflammatory breast cancer, 222
inflammatory polyp, 54
ingestion
  airway maintenance in, 165
  alkaline esophageal damage in, 165
  caustic, 165
inguinal hernia, 247
inguinal masses. *See* hernia(s)
inhalation injury, burns and, 193
injury. *See* trauma
insulinoma, 126
intensive care unit (ICU), ventilatory acquired pneumonia and, 186
interferon, melanoma and, 209
internal iliac artery, 45
intertrochanteric fracture, 362
intestinal atresia, 238, 239*f*
intra-abdominal hypertension, 170
intracranial pressure (ICP), 328–331
intraductal papilloma, 221
intramembranous ossification, 355
intraparenchymal hemorrhages, 338
intraperitoneal onlay mesh (IPOM), for hernias, 83
intravenous immunoglobulin (IVIG), in idiopathic thrombocytopenic purpura, 71
intrinsic factor, 17
intubation, 153
  burns and, 193
intussusception, 242–243
  treatment of, 53
iodide trapping, thyroid hormone production and, 129
iron deficiency anemia, 69
irritable bowel syndrome, 40
ischemic colitis, 254
ischemic stroke, 339–340
islet cell neoplasms, 126
isograft, 281
isolated limb perfusion, for transit metastatic melanoma, 209
ITP. *See* idiopathic thrombocytopenic purpura
IVIG. *See* intravenous immunoglobulin
Ivor Lewis esophagectomy, esophageal carcinoma and, 11

J
Jackson classification, of burns, 191
jaundice, 245
  cholangiocarcinoma and, 112
jejunum
  blood supply to, 29
  ileum *vs.*, 29, 30*f*

K
Kasai repair, 246
keloid scar, 206
kidney
  injury to, 172
  laceration of, 324
kidney stones, small bowel and, 31
kidney transplants, 284–285
  heterotropic allografts and, 281
Killian's triangle, 3
Klatskin's tumor, 112
Klebsiella pneumoniae, cholecystitis and, 107
knee, dislocation of, 173, 363
Kras oncogene, adenoma and, 54
Krukenberg's tumor, metastatic gastric cancer and, 27
Kulchitsky cells, carcinoid tumor and, 34
Kupffer cells, 85
Kussmaul's respiration, 333
Kussmaul's sign, 159

L
labyrinthitis, 299
Lactated Ringer's (LR), 155
lactation, breast infections and, 221
lacunar ligament, 76
Ladd's procedure, 240, 240*f*
Lambert-Eaton syndrome, 271
lap band, 307, 308*f*
laparotomy
  for abdominal trauma, 169
  in diverticulitis, 49
large bowel obstruction (LBO), symptoms of, 52
large-cell carcinoma, 270
larynx
  fracture of, 164
  structures of, 295*f*
latissimus dorsi myocutaneous flap, 215
LBO. *See* large bowel obstruction
LCIS. *See* lobular carcinoma in situ
LCP. *See* Legg-Calve-Perthes disease
LeFort midface fracture patterns, 302, 302*f*
left gastric artery, 1, 3*f*

left gastric vein, 1, 2*f*
left renal vein, 309
left supraclavicular lymph node, metastatic gastric cancer and, 27
Legg-Calve-Perthes disease (LCP), 374
leiomyomas
  of esophagus, 12
  of small bowel, 43
leiomyosarcomas, small bowel tumors, 43
leptomeningeal carcinomatosis, 349
Leriche syndrome, 259
LES. *See* Lower esophageal sphincter
lesser sac, stomach and, 17, 17*f*
leukemia
  anal fissure and, 59
  pediatrics and, 348
level of consciousness, 151
  altered, 152
  evaluation of, 347–348
LFTs. *See* liver function tests
Libman-Sacks endocarditis, 271
Lichtenstein repair, of hernias, 81, 81*f*
ligament of Treitz, 29
ligaments, injury to, 364
ligamentum teres. *See* round ligament
lightning strike, 197
linear fracture, 335
lingula, 266
linitis plastica. *See* diffusely infiltrating gastric cancer
lipoma, 209
lips
  cancer of, 296
  trauma to, 300
Littre's hernia, 77
liver
  arterial supply of, 87
  caudate lobe of, 85, 86*f*
  cirrhosis of. *See* cirrhosis
  cystic fluid collections in, 97
  hepatocellular carcinoma, 89
  ligaments of, 86, 86*f*
  lobes of, 85
    anemic abscesses and, 100
  resection of, 89
  transplant, 89, 285–286
  tumors of, 87. *See also* hepatic adenomas
    metastatic, 89
  venous supply to, 87
liver function tests (LFTs), hepatic adenoma and, 88
lobular carcinoma in situ (LCIS), 226
locked in syndrome, 334
long bone, 355, 355*f*
  fracture of, 360
lower esophageal sphincter (LES), 1
  achalasia and, 2
  diffuse esophageal spasm, 2
  failure of, 9
  obesity and, 6
  relaxation of, 5
  scleroderma and, 2
LR. *See* Lactated Ringer's
lumbar puncture, 338
lumpectomy, 229
  ductal carcinoma in situ and, 225
lungs
  cancer and, 270, 271–272
  fissures of, 266
  masses of, malignant, 268*f*
  transplant, 288
lymphadenitis, in pediatrics, 232
lymphedema, 228
lymphoid polyps, 54
lymphoma
  in pediatrics, 232, 296
  small bowel tumors, 43

M

macrocytic anemia, 17
major histocompatibility complex (MHC), 288
malabsorption
  causes of, 31
  fistulas and, 62
  gastrointestinal tract and, 30
  symptoms of, 31
  treatment of, 31
male pseudohermaphroditism, 248
malignant fibrous histiocytoma, 210
malignant mesothelioma, 272–273
Mallory-Weiss syndrome, 12
  presentation of, 12
  treatment of, 12
Mallory-Weiss tear, alcoholism and, 13
malrotation, 239–240
mammogram, breast cancer and, 223
mandible, fractures of, 301, 301*f*
manometry, gastroesophageal reflux disease and, 6
Marcy repair, of hernias, 80, 80*f*
Marjolin's ulcer, 206

mastectomy, 224
ductal carcinoma in situ and, 225, 226
latissimus dorsi myocutaneous flap for, 215
transverse rectus abdominis myocutaneous flap for, 215, 215*f*
mastoiditis, 299
McBurney's point, 32, 32*f*
McKeown esophagectomy, esophageal carcinoma and, 12
McVay's repair, of hernias, 79, 79*f*
mechanical ventilation, respiratory failure and, 185
Meckel's diverticulum, 36, 243–244
complications of, 36
diagnosis of, 36
treatment of, 36, 37*f*
Meckel's scan, for Meckel's diverticulum, 36, 244
meconium ileus, 241
mediastinitis, 165
esophageal perforation and, 13
mediastinum
division of, 265
mass of, 265–266
medullary carcinoma, thyroid cancer and, 139
medullary thyroid cancer (MTC), 140
megaloblastic anemia, small bowel and, 31
Meissner's plexus, enteric nervous system and, 29
melanoma, 208–209
melena, 47
memory, in brain, 325
MEN I, 26
meningioma, 348, 352
meningococcus, spleen and, 66
mesenteric ischemia, 50–51
mesenteric venous thrombus, 51
metacarpal fracture, 367
metaiodobenzylguanidine (MIBG) scan, 150
metronidazole
for peritonitis, 50
for pseudomembranous colitis, 50
MG. *See* myasthenia gravis
MHC. *See* major histocompatibility complex
MIBG. *See* metaiodobenzylguanidine scan
microcalcifications, ductal carcinoma in situ and, 225
micrognathia, 216
microinvasion, in ductal carcinoma in situ, 225
midshaft femur, fracture of, 173
milrinone, 184
misoprostol, 21
mitral insufficiency, 277
cardiogenic shock and, 181
mitral valve stenosis, 276
mixed glioma, 350
mixed gonadal dysgenesis, 248
mixed hiatal hernia, 6, 8*f*
mixed incontinence, 323
mixed stones, 103, 104
mixed venous oxygen saturation (SvO_2), 178
Mondor disease, 221
monoclonal antibody (OKT3), 283
Monro-Kellie doctrine, 328, 328*f*
Monteggia fracture, 362
morbid obesity, 305
motor strip, in brain, 325
motor vehicle accidents, 356
movement modulation, in brain, 325
MTC. *See* medullary thyroid cancer
multicentricity, in ductal carcinoma in situ, 225
multifocality, in ductal carcinoma in situ, 225
Murphy's sign, 106, 107
myasthenia gravis (MG), 266
mycophenolate mofetil, 283, 290
myenteric plexus, enteric nervous system and, 29
myocardial contusions, 163
arrhythmias and, 163
myocardial infarction, 278
myocardial injury, 278
myocardial ischemia, 278
myoglobinuria, urine output and, 197
myringotomy, 298

N

nasopharynx, structures of, 295*f*
NEC. *See* necrotizing enterocolitis
neck
cancer of, 296
dissection of, cancer and, 294
nerve injury in, 293
radical neck dissection, 293, 294*f*

selective neck dissection, 293
trauma to, 173–176
cervical spine injury and, 173–174
penetrating, 174–176, 174*f*, 175*f*
triangles of, 293
necrotic toe, 206
necrotizing enterocolitis (NEC), 241–242
necrotizing soft tissue infection, 204
neoplastic cysts, 97
nephrolithiasis, 314–315
nerves, of thyroid gland, 127
neurapraxia, 344
neuroblastoma, 249
neurogenic shock, 154, 177, 182, 341
signs of, 156
spinal cord, lesions of, 156
treatment of, 156–157
neuropathy, small bowel and, 31
neurotmesis, 344
newborn. *See* pediatric(s)
NG lavage, gastrointestinal bleed and, 13
nipple discharge, 221
Nissen fundoplication, gastroesophageal reflux disease and, 9
nitrates, for achalasia, 5
nitroprusside, for afterload reduction, 185
non-hemorrhagic shock, 156–158
non-small-cell lung carcinoma, 270, 272
nonsteroidal anti-inflammatory drug (NSAID)
acute gastritis and, 20
ulcers and, 21
nose, fracture of, 300
NSAID. *See* nonsteroidal anti-inflammatory drug

O

obesity, 305
hernias and, 77
lower esophageal sphincter and, 6
oblique fracture, 360, 361*f*
obstipation, 51
obstructive shock, 154, 177, 182
obstructive sleep apnea (OSA), 299
obturator sign, appendicitis and, 33
octreotide-labeled nuclear medicine scan, gastrinomas and, 26
odynophagia, esophageal carcinoma and, 11
OKT3 (monoclonal antibody), 283
oligodendroglioma, 350–351
oliguria, 180
omphalocele, 246–247
open fracture, 358–359
open pneumothorax. *See* pneumothorax, open
open reduction internal fixation (ORIF), 361, 367
OPSI. *See* overwhelming postsplenectomy infection
oral cavity, structures of, 294*f*
oral contraceptives
gallstones and, 104
hepatic adenoma and, 88
orbital blowout fracture, 301
orchiectomy, 319
orchiopexy, for cryptorchidism, 248
organ of Zuckerkandl, 132
organification, thyroid hormone production and, 129
organ/tissue donation, 282–283
ORIF. *See* open reduction internal fixation
oropharynx, structures of, 295*f*
orthopedics. *See also* bone tumors
emergency in, 356–360
pediatric, 374–375
orthotopic graft, 281
OSA. *See* obstructive sleep apnea
Osgood-Schlatter disease, 374
Osler-Weber-Rendu, 43
osteitis fibrosa cystica, 145
osteoarthritis, 365, 366
osteoblastoma, 371
osteoblasts, 356
osteochondroma, 371
osteoclastoma, 373. *See also* brown tumor
osteoclasts, 356
osteoid osteoma, 370–371
osteomalacia, 356
osteomyelitis, 358, 364–365
ulcer, infection of, 206
osteopenia, 356
small bowel and, 31
osteoporosis, 356
osteosarcoma, 371
otitis externa, 297–298
otitis media, 298
ovary, metastatic gastric cancer and, 27
overflow incontinence, 323
overwhelming postsplenectomy infection (OPSI), 66
oxygen debt, 177
oxygen delivery (DO_2), 178
oxygen uptake (VO_2), 178

P
p53 tumor suppressor, adenoma and, 54
pad sign, 119
Paget's disease, ductal carcinoma in situ and, 226
pain
  abdominal
    in Crohn's disease, 41
    in ulcerative colitis, 41
  at anatomic snuff box, 362
  appendicitis and, 32, 33
  of breasts, 220–221
  colic and, 50
  of flank, 253
  hemorrhoids and, 58
  of peritoneum, 50
  sacrococcygeal swelling and, 57
pANCA. *See* positive antineutrophil cytoplasmic autoantibody
Pancoast tumor, 271
pancreas
  arterial supply of, 16*f*
  cancer of, 124–125
  tail of, arterial supply of, 116
  transplant of, 286–287
pancreas divisum, 115, 116*f*
pancreatectomy, for chronic pancreatitis, 123
pancreatic acinar cells, 103
pancreatic head, arterial supply of, 116, 117*f*
pancreatitis
  acute
    alcoholism and, 118
    causes of, 118
    complications of, 121
    diagnosis of, 118
    etiology of, 118
    severity of, 118
    surgical management of, 120
    treatment of, 120
  chronic, 123
  gallstone, 121
  severe
    cardiopulmonary function and, 120
    prognosis of, 120
pantaloon hernia, 76
papillary carcinoma, thyroid cancer and, 139
paradoxical motion
  cause of, 162
  treatment for, 162
paraesophageal hiatal hernia, 6, 8*f*
paralytic ileus, 52
parapneumonic effusions, 269
parasympathetic innervation
  sources of, 29
  stomach and, 16
parathyroid glands, 142
  blood supply of, 142
parathyroidectomy, indications for, 144
parietal cells, 17
Parkland formula, 194–195
paronychia, 367
parotid duct, trauma to, 300
parotidectomy, 297
pathologic fractures, 368
Pavlik harness, 374
PE. *See* pressure-equalization tube
PEA. *See* pulseless electrical activity
pectus excavatum, 265
pediatric(s)
  abscesses in, 243
  brachial cleft cyst in, 233
  brain tumor, 348
  choledochal cysts in, 245
  cystic hygroma in, 233
  jaundice in, 245
  leukemia, 348
  lymphadenitis in, 232
  lymphoma in, 232, 296
  orthopedics, 374–375
  plastic surgery in, 215–216
    cleft lip/palate, 215
    craniosynostosis, 216, 216*f*
    micrognathia, 216
    palate, primary, 215
    palate, secondary, 215
  pyelonephritis in, 310
  soft tissue of
    port wine stain, 211
    sarcoma in, 210
    soft tissue of, 210–211
      giant hairy nevus, 210
      hemangioma, 211
    vascular malformations, 211
  thyroglossal duct cyst in, 232–233
  urinary tract infections in, 310
pelvic inflammatory disease (PID), appendicitis *vs.*, 33
pelvis, fracture of, 172, 324, 359
pepsinogen, 17

079_BOOKZ

peptic ulcer disease (PUD), 19
alcoholism and, 13
dyspepsia and, 20
endoscopy and, 20
surgery of, 21
treatment of, 21
percutaneous transhepatic cholangiogram (PTC), 105–106
percutaneous transluminal angioplasty/stent, mesenteric ischemia and, 51
perforated ulcer, treatment for, 24, 25*f*
perianal disease, in Crohn's disease
pericardiocentesis, for cardiac tamponade, 159
pericystic calcification, 98
peripheral nerve, injury to, 344–348
peripheral tissue perfusion, 179
peripheral vascular disease (PVD), 259
peritoneum, pain of, 50
peritonitis
antibiotic treatment of, 50
microorganisms and, 49
patient position with, 49
signs/symptoms of, 33, 49
peritonsillar abscess, 299
periurethral bleeding, 171
pernicious anemia, 17
Petit's hernia, 77
Peutz-Jeghers, 43, 54
P/F ratio, 186
pharyngitis, 299
pharyngoesophageal constriction point, 1
pheochromocytoma, 140, 149–150
phlegmon, 49
phospholipids, 103
pickwickian syndrome, 305
PID. *See* pelvic inflammatory disease
pigment stones, 103, 104
pilar cyst. *See* trichilemmal cyst
pilocytic astrocytoma, 350
pilonidal disease, 57
piperacillin/tazobactam, for peritonitis, 50
pituitary adenoma, 221, 348, 352
PKD. *See* pyruvate kinase deficiency
plastic surgery
axial flap in, 214, 214*f*
flap's pedicle in, 214
free flap in, 215
latissimus dorsi myocutaneous flap, 215
pediatric, 215–216
cleft lip/palate, 215
craniosynostosis, 216, 216*f*
micrognathia, 216
palate, primary, 215
palate, secondary, 215
random flap in, 213, 213*f*
scar contracture bands, 214
skin closure in, 211, 212*f*
skin grafts in, 212
surgeon role in, 211
tissue defects and, 212
transverse rectus abdominis myocutaneous flap, 215, 215*f*
platelet transfusions, 70
in idiopathic thrombocytopenic purpura, 71
thrombocytopenic purpura and, 70
pleomorphic xanthoastrocytoma, 350
pleural cavity, blood collection in, 159
pleurodesis, 273
Plummer's disease, 137
Plummer-Vinson syndrome, 11
pneumoperitoneum, 171
pneumothorax
open, 158, 161
treatment for, 161
tension, 158, 161, 182
chest x-ray and, 161
death from, 161
diagnosis of, 161
treatment of, 161
poisoning, carbon monoxide, 193–194, 194*t*
polycystic kidney disease, 98
polycystic liver disease, 98
polyps
adenoma, 54
benign, 54
hamartoma, 54
hyperplastic, 54
inflammatory, 54
malignancy potential of, 54
retrosigmoid, 53
polysaccharide encapsulated bacterial infection, spleen, removal of, 66
polysplenia, 65
popliteal aneurysms, 256
popliteal artery injury, 357–358
port wine stain, in pediatrics, 211

portal hypertension, 92
esophageal varices, 96
portosystemic shunt and, 1, 2*f*
treatment of, 94
portal triad, 101, 101*f*
portosystemic collaterals, 92
portosystemic shunts, vessels of, 93, 93*f*
positive antineutrophil cytoplasmic autoantibody (pANCA), in ulcerative colitis, 41
posterior fossa tumors, 353
postgastrectomy syndromes, 24–25
posttraumatic epilepsy, 336
pouch of Douglas, metastatic gastric cancer and, 27
Poupart's ligament, 75
PPI. *See* proton pump inhibitor
pregnancy, ectopic, appendicitis *vs.*, 33
pre-renal azotemia, 186
pressure-equalization (PE) tube, 298
progesterone, breast tissue and, 217
propylthiouracil (PTU), for Graves disease, 135
prostaglandins, gastric mucosa, acid and, 19
prostate cancer, 316–318
prostatitis, 312
prothrombin time, in cirrhosis, 91
proton pump inhibitor (PPI), gastroesophageal reflux disease and, 6
pruritus, cholangiocarcinoma and, 112
pseudoaneurysm, 163
pseudocyst
complications of, 121, 121*f*, 122*f*
treatment for, 121
pseudomembranous colitis, 50
pseudopolyps, 54
in ulcerative colitis, 41
pseudotumor cerebri, 329–330
psoas sign, appendicitis and, 33
psychiatric disorders, irritable bowel syndrome and, 40
PTC. *See* percutaneous transhepatic cholangiogram
PTU. *See* propylthiouracil
PUD. *See* peptic ulcer disease
Puestow procedure, for chronic pancreatitis, 123
pulmonary capillary wedge pressure, 178, 179
pulmonary contusion, 162
hypoxia and, 162
treatment for, 162
pulmonary sequestration, 235
pulmonary vascular resistance (PVR), 178
pulseless electrical activity (PEA), 188
pulsion diverticula, 3
pulsus paradoxus, 159
PVD. *See* peripheral vascular disease
PVR. *See* pulmonary vascular resistance
pyelonephritis, 311
pediatric, 310
pyloromyotomy, 237
pyoderma gangrenosum, 205
pyogenic abscesses, 99, 100
pyogenic arthritis, 365
pyramidal lobe, 133
pyruvate kinase deficiency (PKD), splenectomy and, 73

R

radial pulse, systolic blood pressure of, 154
radical neck dissection (RND), 293, 294*f*
radical retropubic prostatectomy (RRP), 318
radioactive iodine uptake (RAIU), 133
radioiodine (I-131 or I-123), 133
RAIU. *See* radioactive iodine uptake
random flap, 213, 213*f*
Ranson's criteria, 119
prognostic factors using, 119
rapid shallow breathing index (RSBI), 186
RAS. *See* renal artery stenosis
Raynaud's phenomenon, 263
reconstructive ladder, tissue defects and, 212
rectal prolapse, obstructed defecation and, 61
rectum, injury to, 171
recurrent laryngeal nerve (RLN), 127
reducible hernia, 75
re-epithelialization, burns and, 189, 190*f*
reflux, hiatal hernias and, 6
renal artery stenosis (RAS), 262–263
renal artery thrombosis, 285
renal cell carcinoma, 321–322, 322*f*
renal contusion, 172
respiratory acidosis, 185
resuscitation
of bleeding trauma patient, 183
endpoints of, 177
retrograde urethrogram (RUG), 324
revascularization, 255, 260
revised trauma score (RTS), 152

079_BOOKZ

Reynold's pentad, 106, 107
rhabdomyosarcoma, 210
rheumatoid arthritis, 365–366
ribs, fractures of, 162–163
Richter's hernia, 75
Riedel's thyroiditis, 134, 138
right lower quadrant (RLQ), appendicitis pain and, 32
ring-halo sign, 336
RLN. *See* recurrent laryngeal nerve
RLQ. *See* right lower quadrant
RND. *See* radical neck dissection
rotator cuff
  muscles of, 367
  tear of, 363
round ligament, of liver, 86, 87
roux-en-Y gastric bypass, 306–307, 306*f*
roux-en-Y gastrojejunostomy, 24, 24*f*
Rovsing's sign, appendicitis and, 33
RRP. *See* radical retropubic prostatectomy
RSBI. *See* rapid shallow breathing index
RTS. *See* revised trauma score
RUG. *See* retrograde urethrogram
rule of 2's, 36
rule of 9's, burns and, 191–192

S

SAAG. *See* serum ascites:albumin gradient ratio
saccular aneurysm, 252
sacrococcygeal swelling, pain and, 57
sacrococcygeal teratoma, 249
salivary glands, 297
Salter-Harris classification, 375
sarcoma, 209–210
SBO. *See* small bowel obstruction (SBO)
SBP. *See* spontaneous bacterial peritonitis
scaphoid fracture, 362
scaphoid/navicular abdomen, 170
scar
  hypertrophic, 206
  keloid, 206
  strength of, 201
scar contracture bands, 214, 214*f*
SCC. *See* squamous cell carcinoma
SCFE. *See* slipped capital femoral epiphysis
Schatzki's rings, 11
Schwannoma tumor, 352
SCI. *See* spinal cord, injury to
scleroderma, 2
sclerotherapy, cirrhotic esophageal variceal bleeding and, 14
sebaceous cyst. *See* dermoid cyst
seborrheic keratosis, 207
second degree burns. *See* deep partial thickness; superficial partial thickness burns
segmental fracture, 360, 361*f*
seizures, 350, 351
selective neck dissection, 293
seminoma, 318
Sengstaken-Blakemore tube, cirrhotic esophageal variceal bleeding and, 14
sensory strip, in brain, 325
sentinel loop sign, 119
sentinel lymph node biopsy, 228
sentinel tag, 59
septal hematoma, in nasal fracture, 300
septal wall necrosis, 300
septic shock, 154, 177, 180–181
  signs of, 157
serotonin hormone, carcinoid tumor and, 36
serum ascites:albumin gradient (SAAG) ratio, 96
serum cholesterol, in cirrhosis, 91
sexually transmitted disease (STD)
  anal fissure and, 59
  epididymo-orchitis and, 313
sheet graft, 199
sheet wrapping, 359
shock
  blood loss for, 154
  burns and, 194, 195
  cardiogenic, 154, 177, 179, 181
    causes of, 158
    signs of, 158
  classification of, 177
  corticosteroids and, 157
  epinephrine for, 184
  hemorrhagic, vasoconstrictors in, 155
  hypoadrenal, 157
  hypovolemic, 154, 177, 183
    classes of, 155*t*, 180
  neurogenic, 154, 177, 182
    signs of, 156
    spinal cord, lesions of, 156
    treatment of, 156–157
  non-hemorrhagic, 156–158
  obstructive, 154, 177, 182
  patent evaluation with, 180

shock (*Cont'd.*):
in pediatrics, 232
septic, 154, 177, 180
signs of, 157
states of, 154, 177
traumatic, 154, 177, 183
vasodilatory, 181
shoulder, dislocation of, 363
Shouldice repair, of hernias, 81, 82*f*
SIADH. *See* syndrome of inappropriate secretion of antidiuretic hormone
sickle cell anemia, splenectomy and, 67, 73
sigmoidoscopy, for diverticular disease, 49
simple cysts, 97
simple interrupted skin closure, 211, 212*f*
sinusitis, 299–300
Sister Mary Joseph's node, metastatic gastric cancer and, 27
Sistrunk operation, for thyroglossal duct cyst, 132
skin grafts, 212–213
for burns, 199
full thickness, 213
sheet, 199
split thickness, 213
skin infections, 203–205
skin lesions
actinic keratosis, 207
basal cell carcinoma, 207
cancer, 207
melanoma, 208–209
seborrheic keratosis, 207
skull, fractures of, 335–336
sliding hernia, 75
sliding hiatal hernia, 6, 8*f*
slipped capital femoral epiphysis (SCFE), 374
small bowel
bleeding, prolonged, 31
duodenum and, 29
gallstones and, 30–31
kidney stones and, 31
large *vs.*, 52
leiomyomas, 43
malignancy, presentation of, 42
megaloblastic anemia and, 31
neuropathy and, 31
osteopenia and, 31
resection of, 30
steatorrhea and, 31
tumors of, 43
viability of, during surgery, 39
wound healing, poor, 31
small bowel obstruction (SBO)
acidosis and, 39
adhesions and, 36, 51
causes of, 36–37, 51
characteristics of, 38
complete, 37, 38, 52
hernias and, 36, 51
ileus, 52
imaging of, 38, 38*f*
medical management for, 38
partial, 37, 38, 52
NG tube clamp in, 39
physical exam and, 37
symptoms of, 37, 51
treatment of, 52
small intestine, layers of, 30, 30*f*
smoking
abdominal aortic aneurysm and, 253
bladder cancer and, 319
head cancer and, 296
inflammatory bowel disease and, 42
neck cancer and, 296
pancreatic cancer and, 125
wound healing and, 201
sodium retention, 180
soft signs, of arterial injury, 173
soft tissue tumors, 209–210
lipoma, 209
sarcoma, 209–210
somatostatin, 17, 18, 19*f*
gastrinomas and, 26
somatostatinoma, 126
spatial orientation, in brain, 325
spectrin, 67
sphincter of Oddi, 102, 102*f*
spigelian hernia, 77
spinal accessory nerve, 293
spinal cord
injury to, 341–344
ischemia, 254
lesions of, neurogenic shock and, 156
spinal shock. *See* neurogenic shock
spine, structural columns of, 343*f*
spiral fracture, 360, 361*f*
spleen
accessory, 63, 63*f*
idiopathic thrombocytopenic purpura, 72
imaging of, 73

arterial supply of, 16*f*, 65
hematologic functions of, 65
immunologic functions of, 65–66
infection of, 66
ligaments of, 64, 64*f*
microcirculations of, 66
portal vein of, 65
pulp in, 66
removal of, 66
ribs and, 65
splenectomy
ages for, 72
complications of, 72
for Coombs' positive hemolytic anemia, 69
glucose-6-phosphate dehydrogenase and, 73
for hereditary spherocytosis, 67
hereditary spherocytosis and, 73
impermeable bag and, 73
laparoscopic, 72
open, 72
pre-op, 72
pyruvate kinase deficiency and, 73
sickle cell anemia and, 67, 73
for splenic vein thrombosis, 65
splenic vein thrombosis and, 73
for thalassemia, 68
thalassemia and, 73
thrombotic thrombocytopenic purpura and, 73
splenic flexure, blood supply to, 45
splenic vein thrombosis, 65
risk factors for, 65
splenectomy and, 73
splenomegaly, hypersplenism *vs.*, 66
splenopexy, for wandering spleen, 64
split thickness skin graft (STSG), 213
spontaneous bacterial peritonitis (SBP), 96
squamous cell carcinoma (SCC), 270, 271, 296
Stanford classification, of aortic dissection, 257, 257*f*
STD. *See* sexually transmitted disease
steatorrhea, small bowel and, 31
stellate fracture, 335
sternal necrosis, 279
stomach
anatomic regions of, 15, 15*f*
arterial supply of, 15, 16*f*
fluid production of, 39
foramen of Winslow and, 17, 18*f*
lesser sac and, 17, 17*f*
parasympathetic innervation and, 16
sympathetic innervation and, 16
vagus nerve and, 16
strangulation hernia, 75
Streptococcus faecalis, cholecystitis and, 107
streptococcus group D, peritonitis and, 49
Streptococcus pneumoniae, spleen and, 66
stress
acute gastritis and, 20, 21
incontinence, 322, 323
ulcers and, 21
string sign, in Crohn's disease, 41
stroke volume, 179
struvite calculi, 315
STSG. *See* split thickness skin graft
subcutaneous emphysema, in penetrating neck trauma, 176
subcuticular skin closure, 211, 212*f*
subependymal giant-cell astrocytoma, 350
submucosal plexus. *See* Meissner's plexus
succinylcholine, 344
sucralfate, gastric mucosa injury and, 21
superficial partial thickness burns, 189, 191, 198
superior mesenteric artery, 45
suppurative cholangitis, 110
SvO_2. *See* mixed venous oxygen saturation
SVR. *See* systemic vascular resistance
Swan-Ganz catheter, 179
sympathetic innervation, stomach and, 16
synchronized cardioversion, 188
syndrome of inappropriate secretion of antidiuretic hormone (SIADH), 271
systemic vascular resistance (SVR), 178
systolic blood pressure, of pulses, 154

T

TACE. *See* transarterial chemoembolization
tachycardia, 180
in pediatrics, 232
tacrolimus (FK-506), 283, 290
tamoxifen, 229
for breast pain, 220
TAPP. *See* transabdominal pre-peritoneal repair
TB. *See* tuberculosis
TDC. *See* thyroglossal duct cyst

technetium radionucleotide scan, for accessory spleens, 73
technetium-99m pertechnetate (^{99m}Tc), 133
temporal bone fractures, 302
tendons, injuries to, 364
tenesmus, 47
tension pneumothorax. *See* pneumothorax, tension
TEP. *See* totally extraperitoneal repair
teratoma, 249, 318
testicles, 319*f*
testicular cancer, 318–319
testosterone, in cirrhosis, 91
tetanus immune globulin (TIG), burns and, 195
tetanus toxoid booster (Td), burns and, 195
thalamus, lesions of, 325
thalassemia, 67–68
  splenectomy and, 73
thiocyanate toxicity, 185
third degree burns. *See* full thickness burns
thoracic constriction point, 1
thoracic outlet syndrome, 346–347
thorax, trauma to
  airway obstruction, 158
  cardiac tamponade, 158
  flail chest, 158
  hemothorax, 158
  open pneumothorax, 158
  tension pneumothorax, 158
three-hole esophagectomy. *See* McKeown esophagectomy
thrombocytopenia, 67
  causes of, 69–70
thrombocytopenic purpura (TTP)
  clinical features of, 71
  disseminated intravascular coagulation and, 72
thromboembolism, 255
thrombophlebitis, 271
thrombotic thrombocytopenic purpura, splenectomy and, 73
thymoglobulin, 283
thyroglobulin, 139
thyroglossal duct cyst (TDC), 132
  in pediatrics, 232–233
thyroid gland, 128*f*
  arterial supply to, 127
  cancer of, 134, 139
    types of, 139
  hormone production, 129
  imaging of, 133
  nerves of, 127
thyroid lobectomy, 141
thyroid storm, 136
thyroidectomy
  subtotal, 135–136
  total, 140, 141
thyroiditis, 133
thyrotoxicosis, 129
TIA. *See* transient ischemic attack
tibial shaft fracture, 363
TIG. *See* tetanus immune globulin
TIPS. *See* transjugular intrahepatic portacaval shunt
tissue plasminogen activator (tPA), 341
TNM. *See* tumor, node, metastases
TOA. *See* tuboovarian abscess
tonsillectomy, 299
tonsils, cancer of, 296
torticollis, 233
total incontinence, 322, 323
total parenteral nutrition (TPN), 232
total thyroidectomy, 140, 141
totally extraperitoneal (TEP) repair, of hernias, 83, 83*f*
Toupet fundoplication, gastroesophageal reflux disease and, 9
toxic megacolon, in ulcerative colitis, 41
toxic multinodular goiter, 137
tPA. *See* tissue plasminogen activator
TPN. *See* total parenteral nutrition
trachea
  neoplasm of, 267
  stenosis of, 266
tracheoesophageal fistula, 267
tracheoinnominate artery fistula, 267
tracheostomy, 303
TRAM. *See* transverse rectus abdominis myocutaneous flap
transabdominal pre-peritoneal (TAPP) repair, of hernias, 82
transarterial chemoembolization (TACE), 90
transhiatal esophagectomy, esophageal carcinoma and, 11
transient ischemic attack (TIA), 339
transit metastatic melanoma, isolated limb perfusion for, 209
transitional cell carcinoma, of bladder, 320

transjugular intrahepatic portacaval shunt (TIPS), 94–95, 94*f*
cirrhotic esophageal variceal bleeding and, 14
transplants
corneal, 281
heart, 288
kidney, 284–285
heterotropic allografts and, 281
liver, 89, 285–286
lungs, 288
organ/tissue donation in, 282–283
pancreas, 286–287
rejection of, 280, 281, 284
small intestine, 281
transsphenoidal microadenomectomy, for Cushing's disease, 148
transudate effusion, 269
transverse fracture, 360, 361*f*
transverse rectus abdominis myocutaneous (TRAM) flap, 215, 215*f*
trauma
to abdomen
evaluation of, 171
intraperitoneal, 166
laparotomy for, 169
management of, 169*f*
multiple, 169
retroperitoneal, 166, 167
surgical exploration in, 169
zones of, 166–167
to ears, 300
of extremity, 173
of eyelid, 300
of lips, 300
to neck, 173–176
cervical spine injury and, 173–174
penetrating, 174–176, 174*f*, 175*f*
to parotid duct, 300
in pediatrics, 232
of thorax
airway obstruction, 158
cardiac tamponade, 158
flail chest, 158
hemothorax, 158
open pneumothorax, 158
tension pneumothorax, 158
urologic, 324
trauma patient
agitation in, 153
airway of, 153
bleeding, resuscitation of, 183
immunosuppressed, 157
level of consciousness in, 151
multisystem injury, 151
operating room resuscitation of, 155
three-step approach to, 151
traumatic diaphragmatic rupture, 164
traumatic shock, 154, 177, 183
triangle of Calot, 102
trichilemmal cyst, 206
tricuspid insufficiency, 277–278
Trousseau's sign, 125
TTP. *See* thrombocytopenic purpura
tuberculosis (TB), anal fissure and, 59
tuboovarian abscess (TOA), appendicitis *vs.*, 33
tumor, node, metastases (TNM), 55, 227–228, 270
tumors. *See specific tumor*
24-hour pH test, gastroesophageal reflux disease and, 6
tympanic membrane, perforation of, 298

U
UARS. *See* upper airway resistance syndrome
UC. *See* ulcerative colitis
ulcer(s)
arterial insufficiency, 206, 260
in Crohn's disease, 41
Curling's, 21
Cushing's, 21
diabetic foot, 206
duodenal
Helicobacter pylori and, 20
symptoms of, 20
of foot, 206
gastric
acid hypersecretion and, 20
gastrinoma and, 26
Helicobacter pylori and, 20
symptoms of, 20
types of, 19
Marjolin's, 206
nonsteroidal anti-inflammatory drug and, 21
perforated, treatment for, 24
stress-related, 21
in ulcerative colitis, 41
venous stasis, 206, 260
ulcerating gastric cancer, 27

ulcerative colitis (UC), 40
distal ileitis in, 41
extraintestinal manifestations of, 42
gastrointestinal tract involvement in, 40
inflammation and, 40
signs/symptoms of, 41
spread pattern in, 41
umbilical hernia, 246
umbilicus, metastatic gastric cancer and, 27
unicameral bone cyst, 372
upper airway resistance syndrome (UARS), 299
uremic acidosis, 333
ureters, injury to, 172
urethral sphincter, mechanisms of, 309
urethral transaction, 171
urge incontinence, 322, 323
uric acid calculi, 315
urinary tract infections (UTIs), 311
fistulas and, 62
pediatric, 310
urine output
burn shock and, 195
Foley catheter and, 172
in kidney transplant, 285
myoglobinuria and, 197
normal, 179
in pediatric surgery, 231
urobilinogen, bile duct obstruction and, 103
urolithiasis, 313–314
urologic trauma, 324
UTI. *See* urinary tract infections

V

VACTERL. *See* vertebral, anorectal, cardiac, tracheoesophageal fistula, renal, radial limb
vagotomy
incomplete, 26
peptic ulcer disease and, 21
proximal gastric, 21
selective, 21
total, 21
truncal, 22
vagus nerve
acetylcholine from, 18, 19*f*
parasympathetic innervation and, 29
stomach and, 16
Van Nuys classification, 225
vancomycin
for peritonitis, 50
for pseudomembranous colitis, 50
VAP. *See* ventilator acquired pneumonia
vascular malformations
in pediatrics, 211
types of, 339
vasoconstriction, 180
vasodilatory shock, 181
venous stasis ulcer, 206, 260
ventilator acquired pneumonia (VAP), 186
ventral hernia, 77
ventriculostomy, 331
vermian lesions, 326
vermiform appendix, 31
vermillion border, 300
vertebral, anorectal, cardiac, tracheoesophageal fistula, renal, radial limb (VACTERRL), 236, 245
vertical mattress skin closure, 211, 212*f*
vesicoureteral reflux, 284
vesicovaginal fistulas, 61
VIP-oma, 126
Virchow's node, metastatic gastric cancer and, 27
visual cortex, in brain, 325
vitamin B_{12} deficiency. *See* pernicious anemia
vitelline duct, 36
VO_2. *See* oxygen uptake
volume resuscitation, esophageal varices and, 13
volvulus, 52–53, 240–241

W

wandering spleen, 64
warm antibody related anemia, 68, 69
weight loss
in Crohn's disease, 41
gastric cancer and, 26
hepatocellular carcinoma and, 89
pancreatic cancer and, 125
Wernicke's area, in brain, 325
Whipple procedure, for chronic pancreatitis, 123, 124*f*, 125–126
Wilms tumor, 249
wound(s)
closing of, 202
contamination of, 202–203
healing of

079_BOOKZ

delayed/impaired, 201
small bowel and, 31
epithelialization and, 201
phases of, 201
reapproximation, 202*f*
scar strength, 201
infection of
signs of, 203
superficial, 203

X
xenograft, 281

Y
yolk sac, 318

Z
Zenker's diverticula, 3, 4*f*
Zollinger-Ellison syndrome, 26
zona fasciculata, 131
zona glomerulosa, 131
zona reticularis, 131
Z-plasty, for scar contracture bands, 214, 214*f*
zygoma fracture, 301