International Journal of Infectious Diseases 158 (2025) 107981

Contents lists available at ScienceDirect

International Journal of Infectious Diseases

journal homepage: www.elsevier.com/locate/ijid

Medical Imagery

# Cytologic bloom: A candidal garden in a Pap smear

Wubshet Assefa Tesema[#,*], Tsion Tigabu mekonnen[#], Mihret Aregahegne Tesfamichael

*Swiss Diagnostics Ethiopia, Pathology Department, Addis Ababa, Ethiopia*

ARTICLE INFO

*Article history:*
Received 26 May 2025
Revised 8 July 2025
Accepted 9 July 2025

*Keywords:*
Cervical candidiasis
Sheesh kebab pattern
Liquid-based cytology
Pathart

During a routine cervical cancer screening of a 44-year-old woman, a visually remarkable presentation of fungal organisms morphologically consistent with *Candida* spp. was identified by liquid-based cytology. Microscopic examination revealed numerous branching pseudohyphae intricately associated with squamous epithelial cells, producing characteristic "sheesh kebab" configurations—fungal filaments aligned with epithelial cells resembling skewers—which collectively create a flower-like appearance (Figure 1) [1,2]. These formations are well-recognized and commonly documented morphological patterns in cervical cytology specimens with candidal infection, reflecting a distinct host–pathogen interaction influenced by fungal adhesion molecules and the local microenvironment [3,4]. Adhesion of *Candida* spp. to epithelial cells is a critical step facilitating colonization, biofilm formation, and immune evasion by masking fungal antigens and modulating host immune responses [4,5]. Although reactive perinuclear halos were observed in some squamous cells, no evidence of intraepithelial lesion or cytologic atypia was detected. This case highlights the diagnostic significance of such cytomorphologic structures in routine Pap smears, as well as their educational and visual appeal in illustrating host–fungal interactions [6].

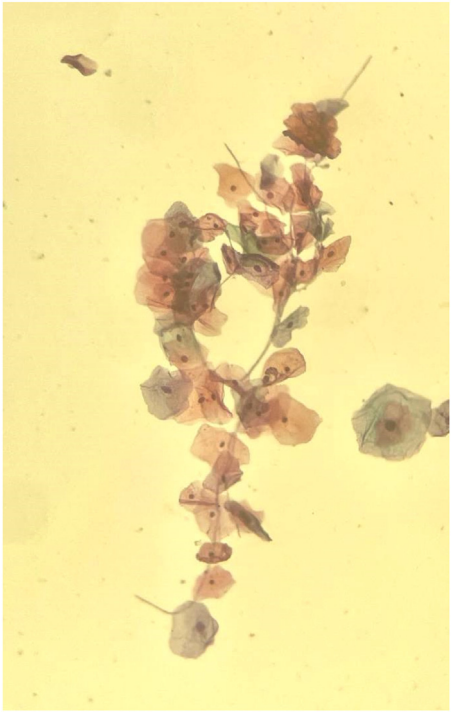

**Figure 1.** "Cytologic bloom" in a Pap smear: squamous cells impaled on branching Candida pseudohyphae, forming a sheesh kebab and flower-like pattern. 400× total magnification, Pap stain.

* Corresponding author.
*E-mail address:* Wubossassefa@yahoo.com (W.A. Tesema).
# Wubshet Assefa Tesema and Tsion Tigabu mekonnen contributed equally to this work.

https://doi.org/10.1016/j.ijid.2025.107981
1201-9712/© 2025 The Author(s). Published by Elsevier Ltd on behalf of International Society for Infectious Diseases. This is an open access article under the CC BY-NC-ND license (http://creativecommons.org/licenses/by-nc-nd/4.0/)

## Declarations of competing interest

The author have no competing interests to declare.

## Funding

This research did not receive any specific grant from funding agencies in the public, commercial, or not-for-profit sectors.

## Ethical approval and informed consent

This study has been approved by the Research Ethical Review Committee of Swiss Diagnostics Ethiopia (SDE 01/05/25). The laboratory procedure was done with the essence of beneficence and the data kept confidential.

## Author contributions

WT, TM, and MT contributed equally, and approved the final manuscript.

## Availability of data and materials

Supporting data for the current study are available from the corresponding author upon reasonable request.

## References

[1] Cengiz T, Toka Özer T, Kılınç F, Selimoğlu R, Yılmaz H. Candida albicans infection of cervix and comparison of Pap smear and culture in diagnosis. *Clin Exp Obstet Gynecol* 2020;**47**:253–6. doi:10.31083/j.ceog.2020.02.5193.
[2] PathologyOutlines.com. Cervix HF. Fungal infections, https://www.pathologyoutlines.com/topic/cervixcytologyfungi.html; 2025 [accessed 21 May 2025].
[3] Cibas ES, Ducatman BS. *Cytology: diagnostic principles and clinical correlates*. 5th ed. Amsterdam: Elsevier; 2020.
[4] Richardson JP, Ho J, Naglik JR. Candida–epithelial interactions. *J Fungi (Basel)* 2018;**4**:22. doi:10.3390/jof4010022.
[5] Moyes DL, Naglik JR. Mucosal immunity and Candida albicans infection. *Clin Dev Immunol* 2011;**2011**:346307. doi:10.1155/2011/346307.
[6] Kamal MM. The Pap smear in inflammation and repair. *CytoJournal* 2022;**19**:29. doi:10.25259/CMAS_03_08_2021.