Check for updates

Received: 24 July 2023 | Revised: 15 September 2023 | Accepted: 9 October 2023

DOI: 10.1002/ccr3.8106

Clinical Case Reports Open Access WILEY

CASE REPORT

Pulmonary thromboembolism as a rare complication of *Plasmodium vivax* malaria: A case report

Gashaw Solela[1] | **Merga Daba**[2] | **Zerubabel Getahun**[2] | **Yared Getachew**[2] | **Dejene Girma**[3]

[1]Department of Internal Medicine, Yekatit 12 Hospital Medical College, Addis Ababa, Ethiopia

[2]Department of Internal Medicine, College of Health Sciences, Addis Ababa University, Addis Ababa, Ethiopia

[3]Department of Internal Medicine, St. Paul's Hospital Millennium Medical College, Addis Ababa, Ethiopia

Correspondence
Gashaw Solela, Department of Internal Medicine, Yekatit 12 Hospital Medical College, Addis Ababa, Ethiopia.
Email: gashawsol@gmail.com

Key Clinical Message

Low threshold is required to suspect complications of *Plasmodium vivax* malaria. Pulmonary thromboembolism, though rare, should be considered as its complication in the presence of unexplained and sudden onset shortness of breath.

Abstract

The hypercoagulable complications of malaria typically manifest in the microvasculature. However, there are several cases of intracranial venous thrombosis caused by *Plasmodium falciparum* and *Plasmodium vivax* malaria, and there was one case report of pulmonary thromboembolism (PTE) due to *P. falciparum*. A 30-year-old Ethiopian male patient presented with sudden onset of shortness of breath for 3 days. He had also high-grade fever, chills, and rigors associated with loss of appetite and fatigue of similar duration. He was from malaria endemic area. He had a pulse rate of 108 beats per minutes, respiratory rate of 32 breaths per minute, oxygen saturation of 82% with atmospheric air and temperature of 38.9°C. Further examination revealed accentuation of pulmonary component of second heart sound. Complete blood count revealed mild anemia and peripheral blood film showed trophozoites of *P. vivax*. Pulmonary CT angiography showed filling defects in the right and left pulmonary arteries. The patient was diagnosed to have *P. vivax* malaria complicated by PTE. He was managed with intranasal oxygen, antimalarial agent, and anticoagulation. Upon serial evaluations on the third week and second month of follow up, he did not have complaints and physical examination was non-remarkable. Malaria is a protozoan disease with high mortality and morbidity. For a long time, severe cases of malaria were thought to be mostly caused by *P. falciparum*. However, recent evidences have shown a paradigm shift and we should remember that *P. vivax* can also cause severe malaria and this can be complicated by hypercoagulable conditions including PTE.

KEYWORDS

malaria, *Plasmodium vivax*, pulmonary thromboembolism

This is an open access article under the terms of the Creative Commons Attribution-NonCommercial-NoDerivs License, which permits use and distribution in any medium, provided the original work is properly cited, the use is non-commercial and no modifications or adaptations are made.
© 2023 The Authors. *Clinical Case Reports* published by John Wiley & Sons Ltd.

1 | INTRODUCTION

The 2022 World Malaria Report published by the World Health Organization showed that there were 247 million malaria cases and 619,000 deaths in 84 malaria endemic countries. In the African region, there were 234,000 malaria cases and 593,000 deaths in 2021. This region accounted for approximately 95% of cases and 96% of malaria deaths.[1] Malaria is caused by infection with a protozoan parasite of the genus *Plasmodium* and is transmitted by female *Anopheles* mosquitoes.[2]

For a long time, it was believed that *Plasmodium vivax* malaria is a benign disease with no life threatening complications, but sometimes it can cause serious problems such as severe anemia and acute respiratory distress syndrome.[3] Falciparum malaria can cause changes in the coagulation cascade, including disseminated intravascular coagulation. Hypercoagulable states due to malaria usually occur in the microvasculature. However, there are several cases of intracranial venous thrombosis due to *Plasmodium falciparum* and *P. vivax* malaria[4–6] and there was also one case report of pulmonary thromboembolism (PTE) due to *P. falciparum*.[7]

To the best of our knowledge, there have not been case reports of *P. vivax* malaria associated with PTE; however, *P. vivax* has been reported to cause acute lung injury and other serious complications.[8] Here, we present the case of a 30-year-old Ethiopian male patient who was diagnosed to have *P. vivax* malaria with PTE.

2 | CASE PRESENTATION

A 30-year-old Ethiopian male patient presented with sudden onset of shortness of breath for 3 days. He had also high-grade fever, chills, and rigors associated with loss of appetite and fatigue of similar duration. He was from malaria endemic area of the country. Otherwise, he had no self or family history of thrombotic disorder, no history of recent surgery or trauma and no known chronic medical illness.

Upon physical examination, he had blood pressure of 100/70 mmHg, pulse rate of 108 beats per minutes, respiratory rate of 32 breaths per minute and body temperature of 38.9°C. His oxygen saturation was 82% with atmospheric air improving to 92% with 3 L/min of oxygen support through nasal cannula. Further examination revealed accentuation of pulmonary component of second heart sound. Otherwise, there were no pertinent positive findings on the other systems.

Upon investigations, complete blood count revealed mild anemia with hemoglobin of 11 g/dL (reference range: 12–16 g/dL) and normal white blood cell and platelet counts. Renal and liver function tests were within normal ranges. Peripheral blood film showed trophozoites of *P. vivax* with amoeboid cytoplasm and large chromatin dot (Figure 1). ECG was remarkable for sinus tachycardia, right ventricular strain pattern, and S1T3Q3 pattern (Figure 2). Pulmonary CT angiography showed filling defects in the right and left pulmonary arteries (Figure 3) with dilatation of inferior vena cava, right atrium, and right ventricle (Figure 4). D-dimer was not determined because it was not readily available. He was not investigated for inherited thrombophilia, since the cause of the PTE is thought to be the possible hypercoagulable state related to the *P. vivax* infection. But, the patient was counseled on the need of such investigations if he is going to have any recurrence of venous thromboembolism (VTE) in the future.

After the patient was diagnosed to have *P. vivax* malaria, he was started on chloroquine phosphate, which was taken for a total of 3 days (1000 mg on Day 1 and Day 2 followed by 500 mg on Day 3) with paracetamol 1000 mg PO as required. The cause of the respiratory distress was not initially clear and with the impression of acute respiratory distress syndrome to rule out PTE, he was put on intranasal oxygen maintaining at 3 L/min and was started on anticoagulation with unfractionated heparin 5000 IU IV stat followed by 17, 500 SC BID. Pulmonary CT angiography was done subsequently and the presence

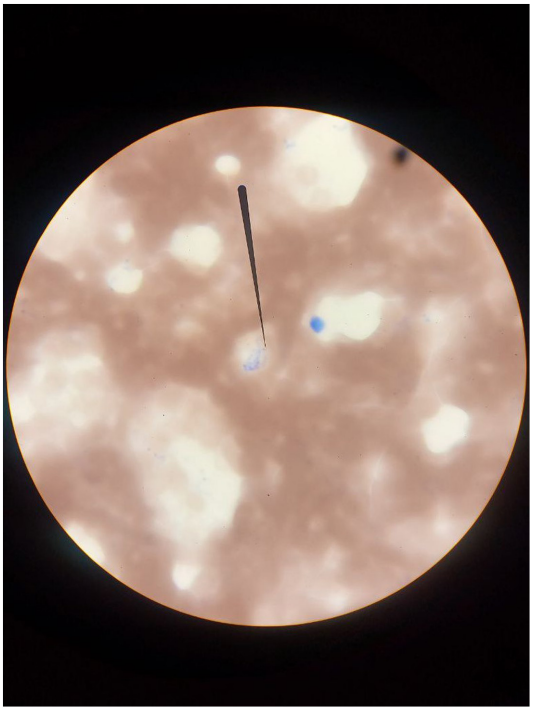

FIGURE 1 Trophozoites of *Plasmodium vivax* with amoeboid cytoplasm and large chromatin dot.

20500904, 2023, 11, Downloaded from https://onlinelibrary.wiley.com/doi/10.1002/ccr3.8106 by EBMG ACCESS - ETHIOPIA, Wiley Online Library on [26/10/2023]. See the Terms and Conditions (https://onlinelibrary.wiley.com/terms-and-conditions) on Wiley Online Library for rules of use; OA articles are governed by the applicable Creative Commons License

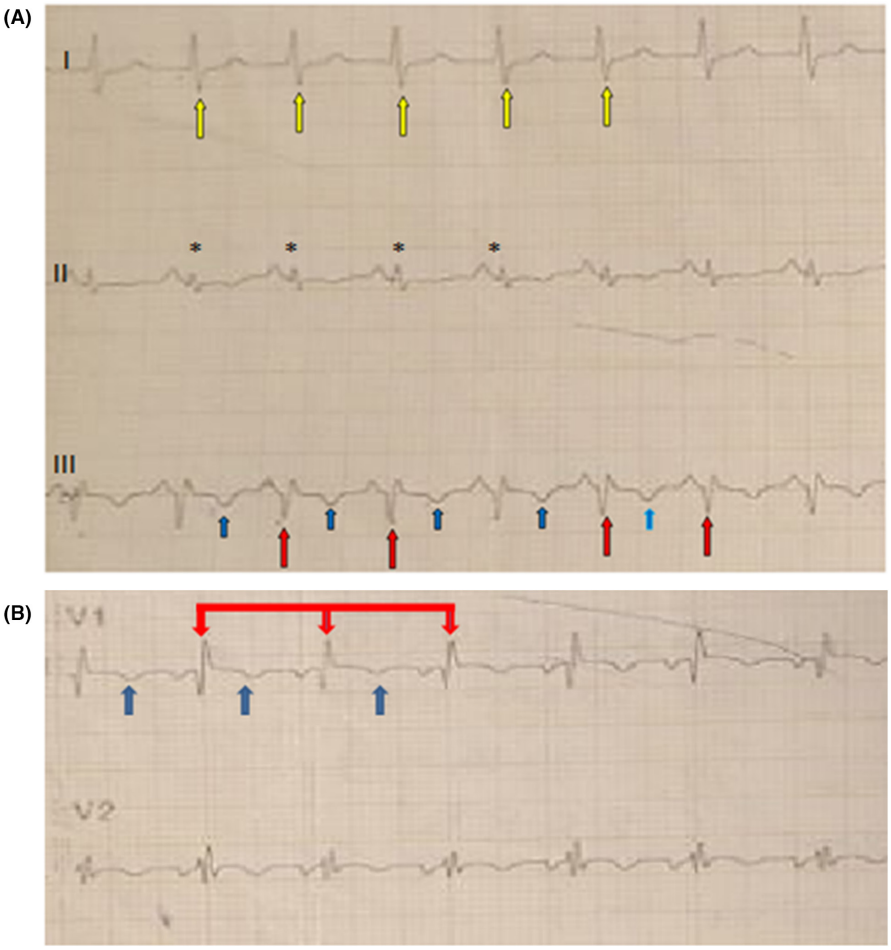

FIGURE 2 (A) There was S1 (yellow), Q3 (red), T3 (blue) pattern on limb leads with sinus tachycardia (short RR intervals shown with the star). (B) Right ventricular strain pattern (dominant R waves and T wave inversion) was seen on V1 and incomplete RBBB pattern seen in V2.

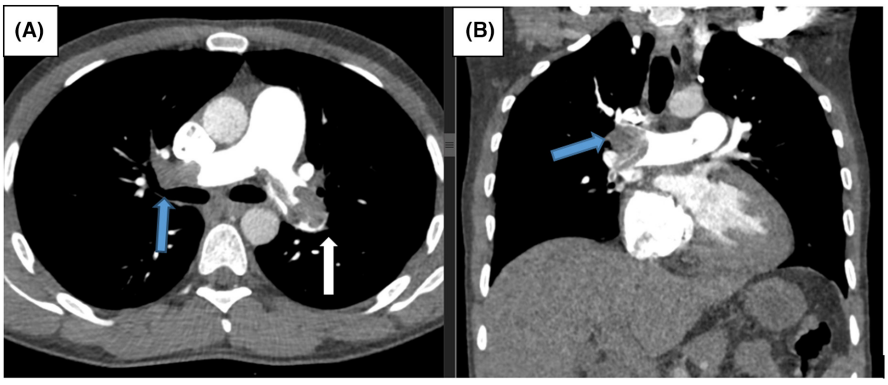

FIGURE 3 Axial (A) and coronal (B) sections pulmonary CT angiography showed filling defects in the right (blue arrows in A and B) and left pulmonary arteries (white arrow in A).

of PTE was confirmed. The final working diagnosis was *P. vivax* malaria complicated with PTE. On the third day after initiation of the antimalarial and anticoagulation therapy, the patient showed significant improvement and he started to maintain his oxygen saturation with atmospheric air. Finally, he was discharged with rivaroxaban to be taken at a dosage of 15 mg PO twice a day for a total of 21 days and then 20 mg PO once daily. Upon serial evaluations on the third week and second month of follow up, he did not have complaints and physical examination was non-remarkable.

3 | DISCUSSION

The five species of *Plasmodium* that cause malaria in humans are *P. falciparum*, *P. vivax*, *Plasmodium ovale*, *Plasmodium malariae*, and *Plasmodium knowlesi*. *P. falciparum* causes the highest disease burden, followed by *P. vivax*.[9,10] Severe malaria is usually caused by *P. falciparum*; however, severe malaria and even death can occur in patients infected with *P. vivax*.[3,11]

The traditional thought that *P. vivax* malaria is a benign disease is changing, and severe *P. vivax* malaria has been

20500904, 2023, 11, Downloaded from https://onlinelibrary.wiley.com/doi/10.1002/ccr3.8106 by EBMG ACCESS - ETHIOPIA, Wiley Online Library on [26/10/2023]. See the Terms and Conditions (https://onlinelibrary.wiley.com/terms-and-conditions) on Wiley Online Library for rules of use; OA articles are governed by the applicable Creative Commons License

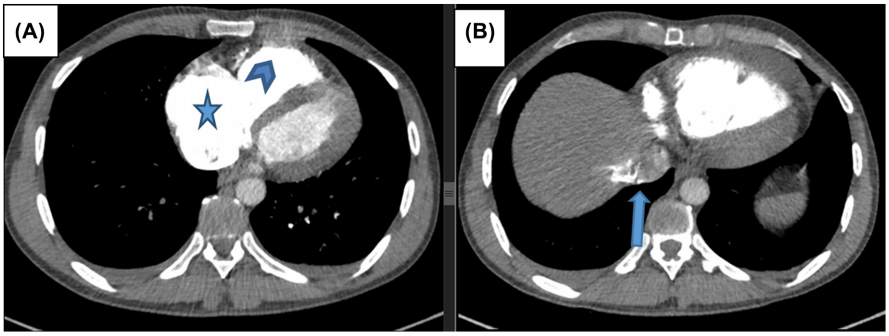

FIGURE 4 Axial sections pulmonary CT angiography (A and B) showed dilatation of right atrium (star in A) and right ventricle (arrowhead in A) with dilatation of IVC and reflux of contrast to hepatic veins (blue arrow in B).

reported in recent years. Reported serious manifestations include liver dysfunction, cerebral malaria, severe anemia, severe thrombocytopenia, respiratory distress, disseminated intravascular coagulation, renal dysfunction, hypoglycemia, generalized seizures, shock, hemoglobinuria, metabolic acidosis, and death.[12] In addition, pulmonary manifestations of malaria infection can include subclinical impairment of lung function, such as impaired alveolar ventilation, reduced gas exchange, and increased pulmonary phagocytic activity. Acute respiratory distress syndrome has been seen in patients with *P. vivax* and *P. ovale* infections.[8,13]

Three cases of intracranial venous thrombosis (a case of cerebral venous thrombosis and two cases of sagittal sinus thrombosis) caused by *P. falciparum* and *P. vivax* have been reported from India. Two of the three patients had mixed *Plasmodium faciarum* and *vivax* infection. A hypercoagulable state secondary to severe malaria is thought to have been the cause of this rare and potentially fatal complication.[4] In addition, there were additional case reports of cerebral venous thrombosis in patients with *P. vivax* malaria among patients from India[5] and there was a case report of sagittal sinus thrombosis associated with severe *P. vivax* malaria in a patient from Columbia.[6]

There was only a case report of massive pulmonary embolism caused by disseminated intravascular coagulation due to severe *P. falciparum* malaria.[7] In contrast to this case report, our patient had *P. vivax* malaria and no evidences of disseminated intravascular coagulation. Although the pathogenesis of PTE in our patient remained unclear, it may be related to a hypercoagulable condition with a pathophysiological mechanism similar to that of *P. falciparum* malaria.[4]

Patients are considered to be in hypercoagulable states if they have laboratory abnormalities or clinical conditions that are associated with increased risk of thrombosis or if they have recurrent thrombosis without recognizable predisposing factors.[14] Testing for thrombophilia including antithrombin III deficiency, protein C, protein S deficiency, antiphospholipid antibodies, and lupus anticoagulant may be considered in patients with VTE, particularly if they are young (<50 years), have no identifiable risk factors, have recurrent episodes and have a strong family history of the disorder.[15,16] Though our patient was young, he had no recurrent VTE; he had no family history of similar disorder, and there was an underlying possible hypercoagulable state, which is *P. vivax* infection. Hence, he did not require work up for thrombophilia.

4 | CONCLUSION

Malaria is a protozoan disease with high mortality and morbidity. For a long time, severe cases of malaria were thought to be mostly caused by *P. falciparum*. However, recent evidences have shown a paradigm shift and we should remember that *P. vivax* can also cause severe malaria and this can be complicated by hypercoagulable conditions including PTE.

AUTHOR CONTRIBUTIONS

Gashaw Solela: Conceptualization; data curation; formal analysis; resources; validation; writing – original draft; writing – review and editing. **Merga Daba:** Conceptualization; data curation; writing – original draft. **Zerubabel Getahun:** Data curation; resources; writing – original draft. **Yared Getachew:** Data curation; resources; writing – original draft. **Dejene Girma:** Data curation; resources; writing – original draft.

ACKNOWLEDGMENTS

The authors would like to thank the patient for approving the publication of his case details.

FUNDING INFORMATION

There was no specific grant received from any funding agency in the public, commercial, or not for profit sectors.

CONFLICT OF INTEREST STATEMENT

The authors declared no potential conflicts of interest.

DATA AVAILABILITY STATEMENT

The data that support this case report are available from the corresponding author upon reasonable request.

20500904, 2023, 11, Downloaded from https://onlinelibrary.wiley.com/doi/10.1002/ccr3.8106 by EBMG ACCESS - ETHIOPIA, Wiley Online Library on [26/10/2023]. See the Terms and Conditions (https://onlinelibrary.wiley.com/terms-and-conditions) on Wiley Online Library for rules of use; OA articles are governed by the applicable Creative Commons License

ETHICS STATEMENT

The case report meets ethical guidelines and adheres to the local legal requirements.

CONSENT

The patient gave an informed written consent for the publication of his case details and accompanying images.

ORCID

Gashaw Solela https://orcid.org/0000-0002-2233-9270
Yared Getachew https://orcid.org/0009-0009-6374-2216

REFERENCES

1. World Health Organization. World malaria report 2022. World Health Organization 2022.
2. Cox FE. History of the discovery of the malaria parasites and their vectors. *Parasit Vectors*. 2010;3(1):5. doi:10.1186/1756-3305-3-5
3. Anstey NM, Russell B, Yeo TW, Price RN. The pathophysiology of vivax malaria. *Trends Parasitol*. 2009;25:220-227. doi:10.1016/j.pt.2009.02.003
4. Krishnan A, Karnad DR, Limaye U, Siddharth W. Cerebral venous and dural sinus thrombosis in severe falciparum malaria. *J Infect*. 2004;48(1):86-90. doi:10.1016/s0163-4453(03)00130-0
5. Agarwal A, Murali S, Warrier A, et al. Cerebral venous thrombosis as a complication of *Plasmodium vivax* malaria: a report of 2 cases. *Ann Indian Acad Neurol*. 2022;25(3):549-551. doi:10.4103/aian.aian_996_21
6. Pinzón MA, Pineda JC, Rosso F, Shinchi M, Bonilla-Abadía F. *Plasmodium vivax* cerebral malaria complicated with venous sinus thrombosis in Colombia. *Asian Pac J Trop Med*. 2013;6(5):413-415. doi:10.1016/S1995-7645(13)60050-4
7. Musoke C, Ssendikadiwa C, Babua C, Schwartz JI. Severe falciparum malaria associated with massive pulmonary embolism. *Ann Afr Med*. 2014;13(1):47-49.
8. Tan LK, Yacoub S, Scott S, Bhagani S, Jacobs M. Acute lung injury and other serious complications of *Plasmodium vivax* malaria. *Lancet Infect Dis*. 2008;8(7):449-454. doi:10.1016/S1473-3099(08)70153-1
9. McGready R, Wongsaen K, Chu CS, et al. Uncomplicated *Plasmodium vivax* malaria in pregnancy associated with mortality from acute respiratory distress syndrome. *Malar J*. 2014;13:191.
10. Sato S. *Plasmodium*—a brief introduction to the parasites causing human malaria and their basic biology. *J Physiol Anthropol*. 2021;40:1. doi:10.1186/s40101-020-00251-9
11. Guerra CA, Gikandi PW, Tatem AJ, et al. The limits and intensity of *Plasmodium falciparum* transmission: implications for malaria control and elimination worldwide. *PLoS Med*. 2008 Feb;5(2):e38. doi:10.1371/journal.pmed.0050038
12. Rahimi BA, Thakkinstian A, White NJ, Sirivichayakul C, Dondorp AM, Chokejindachai W. Severe vivax malaria: a systematic review and meta-analysis of clinical studies since 1900. *Malar J*. 2014;13:481. doi:10.1186/1475-2875-13-481
13. Autino B, Corbett Y, Castelli F, Taramelli D. Pathogenesis of malaria in tissues and blood. *Mediterr J Hematol Infect Dis*. 2012;4(1):e2012061.
14. Schafer AI. The hypercoagulable states. *Ann Intern Med*. 1985;102(6):814-828. doi:10.7326/0003-4819-102-6-814
15. Stavros V. Konstantinides and others, 2019 ESC guidelines for the diagnosis and management of acute pulmonary embolism developed in collaboration with the European Respiratory Society (ERS): the task force for the diagnosis and management of acute pulmonary embolism of the European Society of Cardiology (ESC). *Eur Heart J*. 2020;41(4):543-603.
16. Middeldorp S, Nieuwlaat R, Baumann Kreuziger L, et al. American Society of Hematology 2023 guidelines for Management of Venous Thromboembolism: thrombophilia testing. *Blood Adv*. 2023;bloodadvances-2023010177. doi:10.1182/bloodadvances.2023010177

How to cite this article: Solela G, Daba M, Getahun Z, Getachew Y, Girma D. Pulmonary thromboembolism as a rare complication of *Plasmodium vivax* malaria: A case report. *Clin Case Rep*. 2023;11:e8106. doi:10.1002/ccr3.8106

20500904, 2023, 11, Downloaded from https://onlinelibrary.wiley.com/doi/10.1002/ccr3.8106 by EBMG ACCESS - ETHIOPIA, Wiley Online Library on [26/10/2023]. See the Terms and Conditions (https://onlinelibrary.wiley.com/terms-and-conditions) on Wiley Online Library for rules of use; OA articles are governed by the applicable Creative Commons License