Open Access
Stechnolock Journal of Case Reports
CASE REPORT

An Ingested Foreign Body Causing Fistulous Tract with Abdominal Wall in a Psychiatric patient: Case Report

Muleta MB*[1], Ariaya A[1], Suga Y[1], Nagassa T[1], Haileselassie E[1], Worku S[2] and Berhanu E[2]

[1]Department of Surgery, St. Paul's Hospital Millennium Medical College, Ethiopia
[2]Department of Psychiatry, St. Paul's Hospital Millennium Medical College, Ethiopia

***Corresponding Author:** Bekele Muleta MB, MD, Associate Professor of Surgery, Department of Surgery, St. Paul's Hospital Millennium Medical College, Ethiopia, Tel: +251923794505, E-mail: mahtemebekele@gmail.com

Citation: Muleta MB, Ariaya A, Suga Y, Nagassa T, Haileselassie E, et al. (2021) An Ingested Foreign Body Causing Fistulous Tract with Abdominal Wall in a Psychiatric patient: Case Report. Stechnolock J Case Rep 2: 1-5

Copyright: © 2021 Muleta MB. This is an open-access article distributed under the terms of Creative Commons Attribution License, which permits unrestricted use, distribution, and reproduction in any medium, provided the original author and source are credited.

ABSTRACT

Background: The majority of foreign bodies ingested transit through the gastrointestinal system without any complications. Perforations are uncommon and if any usually results peritonitis. We present a case of gastric perforation secondary to ingestion of a sharp foreignbody (Nail). That forms fistulous tract with lateral abdominal wall, requiring surgical intervention.

Case presentation: A 41-years old known psychiatric male patient for the last 20 years brought to the hospital by his family with protrusion of foreign body (Nail) from inside out in his right upper abdomen, which was associated with abdominal pain and low grade fever. The pertinent physical finding was on abdomen, a large nail that perforated right upper quadrant fromin-out, with surrounding skin indurations and minimal discharge, but no GI content coming through the tract. Exploratory laparotomy done and the tract between stomach and abdominal wall disrupted, the nail removed from stomach, the stomach perforation, trimmed and repaired.

Psychiatric evaluation performed, patient diagnosed with chronic Schizophrenia and managedwith medication and psychosocial support.

Conclusion: Mentally unstable patients should be kept in close observation as they have highertendency to ingest foreign bodies. Early recognition and intervention is the key to avoid morbidity and mortality.

Keywords: Foreign Body; Ingestion of Foreign Body; Foreign Body Causing Fistula; Foreign Bodyin Psychiatry

Background

Ingestion of foreign body frequently seen in clinical practice, but such ingestions are relatively uncommon in adults. Many ingested objects go unnoticed and are never brought to the attention of a physician. Of those documented foreign bodies, 80-90% is passed spontaneously and another10-20 % is removed endoscopically. Probably less than one percent cause perforationand require surgical intervention. In most of these cases perforation is found in lower ileal and cecal regions. In less than 2% stomach is involved. Foreign body ingestion can be intentional especially in patients with intellectual disabilities or psychiatric disorders [1-3].

We present a case of 41 years old known psychiatric patient presented to our hospital with foreign body perforation of the stomach forming a fistulous tract. The case discussed withmanagement and review of literatures

Case report

A 41-years old known psychiatric male patient for the last 20 years brought to the hospital by his family with protrusion of foreign body (Nail) from inside out in his right upper abdomen, which was associated with abdominal pain and low grade fever. This patient was on follow up atone of psychiatric Hospital here in Addis Ababa, but he lost from follow up and living on street since 6months. Otherwise no complaint of abdominal distension or vomiting.no cough, chest pain or shortness of breath.

On physical examination all vital signs were with in normal range with pulse rate of 84beat/minute, BP of 110/80mmhg, RR of 18, Temperature 36.3. The pertinent finding was onabdomen, a large nail that perforated Right upper quadrant from in-out, with surrounding skin indurations and minimal discharge, but no GI content coming through the tract (Figure 1). On palpation has slight tenderness over right flank and right upper quadrant; otherwise has no signof fluid collection or organomegally.



Figure 1: Nail perforating the right flank from in-out with surrounding skin scaling and indurations

Laboratory investigation revealed WBC 18600/L, Hematocrit of 31.4% Platelet 690,000, Creatinine 0f 0.73mg/dl, Urea of 43.9mg/dl, Liver function test with in normal range. Plain abdominal x-ray showed multiple intra-abdominal foreign bodies including nail and coin likeradiopaque substances (Figure 2).

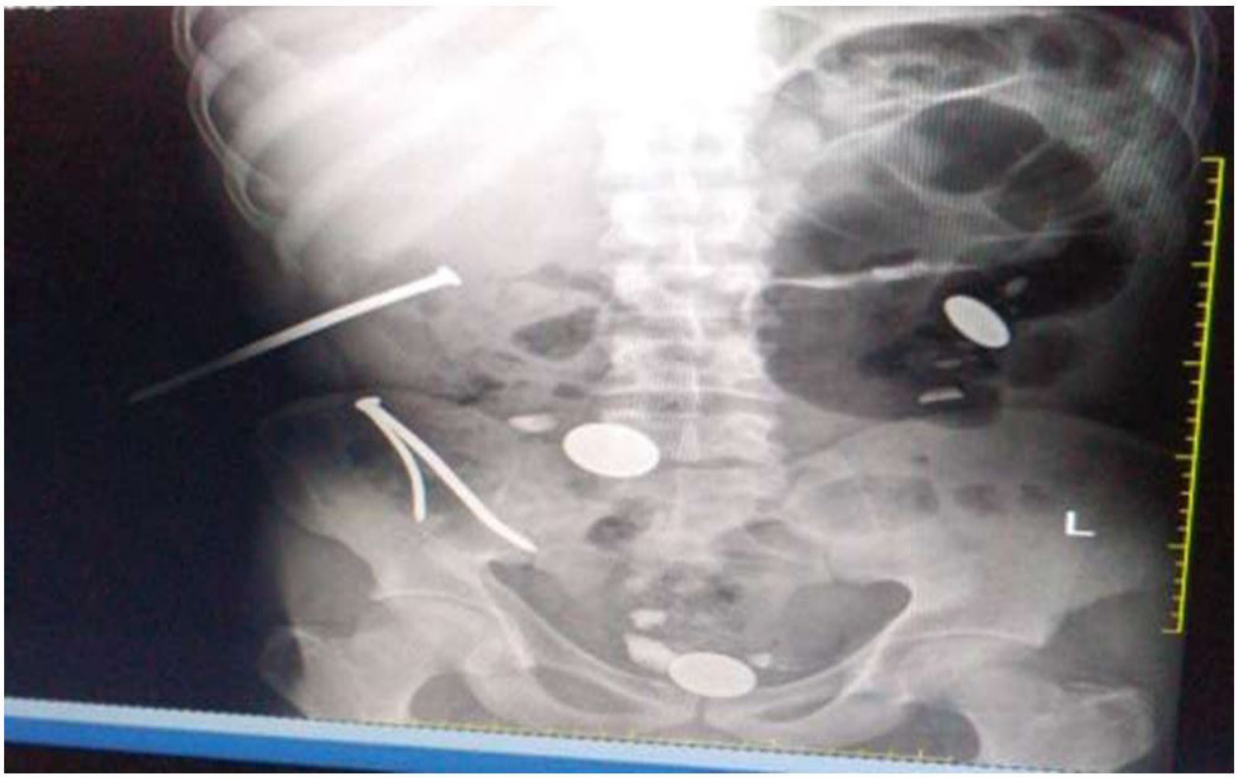

Figure 2: Plain abdominal X-ray:-showing three intra-abdominal nails and multiple circular (coinlike) intra-abdominal radio-opaque materials

With the above diagnosis the patient was admitted and taken to operating Theater (OR), abdomen entered via midline surgical incision. Intra op finding was; - A big nail perforating antrum of stomach and fixing the stomach to right lateral abdominal wall forming a well formedfistula tract, no gross contamination of peritoneum. There were another two nail palpable in the ascending colon with multiple round foreign body palpable in the large colon (Figure 3).

Explorative laparotomy done and the tract between stomach and abdominal wall disrupted, the nail removed from stomach, the stomach perforation, trimmed and repaired. Two nail in the ascending colon, milked up in to ilium, enterotomy done and removed. Other foreign body left inplace and abdomen closed layer by layer.

Though other foreign body left in GIT, the patient didn't develop sign of obstruction and he haduneventful post-operative course. In the subsequent days, psychiatry department consulted and patient evaluated.

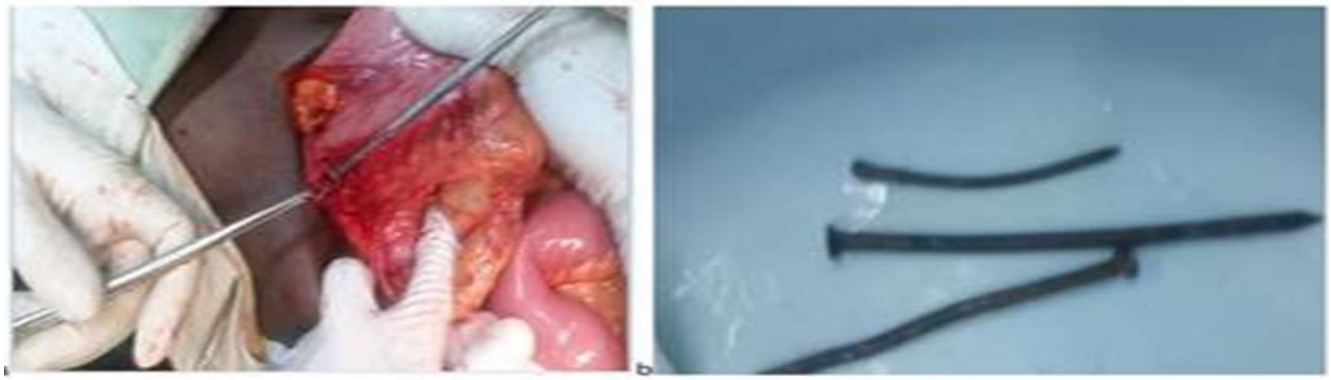

Figure 3: Intera-operative pictures **(a)** Picture showing fistula tract (site of nail perforation) that connect antrum of stomach to lateral abdominal wall; **(b)** Removed nails from the gastrointestinaltract

Psychiatric history taken mainly from the brother, Brother reported his illness started while he was a little child. He used to talk alone as if he is answering to someone; and he talks things which are not understood by others. He was also suspicious towards his families and neighbours and at times used to be physically and verbally aggressive, for which he had multiple admission to a psychiatric hospital in Addis Ababa (details not known). He usually isolates himself, has poor self-care and usually spends much of his time wondering on the street, collecting garbage and chewing khat (leftovers of others). He discontinued his follow up 15 yrs. back and was living on the street since then. Chews khat and smokes cigarette significantly

Physical examination revealed that general appearance he dressed with a hospital pyjama, looksthe stated age, lean body built, long nails and beard, looks acutely sick looking, poor eye contact,is not much cooperative. Has psychomotor retardation, otherwise No tics or tremor. He has decreased in rate and volume speech, only moans for himself.it was difficult to assess his mood. His affect evaluation showed acutely sick looking, constricted and stable and thought process with derailment and loosening of association, content wise difficult to assess for delusions.

Preoccupation/ suicide and aggression risk. It was difficult to assess perception and insight. Hehad poor judgment.

Assessment was Schizophrenia (chronic), khat and nicotine use disorder, severe functional impairment, poor social support, and poor treatment adherence. With the above assessment he was put on Supportive psychotherapy to both patient and his families. Psycho-education about his illness, need for adherence to follow up medication (medication side effect), risperidone 2 mgPer ose noct and Link to psychiatry outpatient department after discharge. Patient discharged andcontinues follow up at Psychiatry clinic

Discussion

Ingested foreign body perforation in the adult population can be secondary to involuntary accidental or an intentional ingestion [1-5]. Predisposing factors include patient with dentures,patient with history of psychosis and alcohol abuse, and jail inmates [2,3]. A definite preoperative history of foreign body ingestion is rare as highlighted in the above case.

The majority of objects, however, pass through the gastrointestinal system without any sequelae [5-7]. Common site of perforation includes distal ileum, Sigmoid colon, or rectum. Patients with foreign perforation in stomach, duodenum, and large bowel are more likely to present with longer, more innocuous clinical picture with chronic symptoms such as abdominal mass or abscess and are usually apyrexia with normal white cell count when compared to those with perforation in the small bowel [1,7,8]. Our patient had low grade fever and leucocystosis. Gastric perforations are the rare site and usually involve the antrum. After gastric perforation, patients will develop either hepatic abscess or peritonitis. There is no report of gastric perforationcausing fistulus tract to the abdominal wall. Diagnostic methods include x-rays, ultrasonograohy, CT scan and endoscopy [4,6,9,10]. The proper treatment for these cases could be endoscopy, laparascopic surgery or laparatomy, depending on the presence of complications. Abdominal plain x-ray confirmed multiple foreign bodies and laparatomy with removal of foreign body, gastric repaire and enterotomy was done in our case.

Conclusion

Mentally unstable patients should be kept in close observation as they have highertendency to ingest foreign bodies. Early recognition and intervention is the key to avoid morbidity and mortality.

References

1. Mehran A, Podkameni D, Rosenthal R (2005) Gastric perforation secondary to ingestion of a sharp foreign body. JSLS 9: 91.

2. Palese C, Al-Kawas FH (2012) Repeat Intentional Foreign Body Ingestion: The Importance of a Multidisciplinary Approach. Gastroenterology & Hepatology 8.

3. Te Wildt BT, Tettenborn C, Schneider U, Ohlmeier MD, Zedler M, Zakhalev R, et al. (2010) Swallowing Foreign Bodies as an example of Impulse Control Disorder in a Patient with Intellectual Disabilities: A CASE REPORT. Psychiatry 7.

4. Steenvoorde P, Moues CM, Viersma JH (2002) Gastric perforation due to the ingestion of a hollow toothpick: report of a case. Surg Today 32: 731-3.

5. Dugger K, Lebby T, Brus M (1990) Hepatic abscess resulting from gastric perforation of a foreign object. Am J Emerg Med 8: 323-5.

6. Porcu A, Dessanti A, Feo CF (1999) Asymptomatic gastric perforation by a toothpick. Dig Surg 16: 437-8.

7. Velitchkov NG, Grigorov GI, Losanoff JE (1996) Ingested foreign bodies of the gastrointestinal tract: retrospective analysis of 542 cases. World J Surg 20: 10015.

8. Lam PY, Marks MK, Fink AM, Oliver MR. Woodward A (2001) Delayed presentation of an ingested foreign body causing gastric perforation. J Pediatr Child Health 37: 303-4.

9. Glick WA, Simo KA, Swan RZ (2012) Pyogenic hepatic abscess secondary to endolumenal perforation of an ingested foreign body. J Gastrointest Surg 16: 885.

10. Goh BK, Chow PK, Quah HM (2006) Perforation of the gastrointestinal tract secondary to ingestion of foreign bodies. World J Surg 30: 372-7.