Research Square

Preprints are preliminary reports that have not undergone peer review.
They should not be considered conclusive, used to inform clinical practice,
or referenced by the media as validated information.

Ileoileal knotting a rare cause of double loop small bowel obstruction, diagnostic and intraoperative challenge at Ethiopian Leku district hospital,sidama region, April 2023 ,case report

Asfaw Kibret(Senior integrated Emergency surgery profesional Specialist) (aserkibret@gmail.com)
Leku Hospital,Sidama rgional state,Ethiopia

Case Report

Keywords: closed loop obstruction,gangreneous bowel,emergency surgical officers,ileoileal-knotting

Posted Date: April 27th, 2023

DOI: https://doi.org/10.21203/rs.3.rs-2777908/v4

License: This work is licensed under a Creative Commons Attribution 4.0 International License.
Read Full License

Abstract

Background: Intestinal obstruction is common cause for abdominal surgeries. Among the causes for intestinal obstruction ileal knotting is the unusual and rare cause with very few case reports in the globe and in Ethiopia. Almost all cases were intraoperative surprises. We report a case of strangulated closed small bowel loop obstruction caused by ileoileal knotting at distal ileum near to ileocecal junction, its diagnostic and management challenges and the role of the "**Integrated Emergency surgical officers(IESO)"** for early emergency surgical interventions in district primary hospitals in Ethiopia where there is scarce general specialist surgeon.

Case presentation: Here we discuss a 78yrs old male Ethiopian patient presented to our district hospital with sign symptoms of strangulated small bowel obstruction and exploratory laparatomy was done with intraoperative surprise of ileoileal knot with gangrenous closed loop obstruction at ileocecal junction. The gangrenous segment was resected and ileo-ascending colon anastomosis was done.The post operative stay was uneventful and patient discharged on his 7th post operation date.

Conclusion: Here we present this case to highlight difficulty of preoperative diagnosis and the need of high index of suspicion as well as the management challenges of resection anastomosis when the knot is near to ileocecal junction and the undeniable role of emergency surgical officers for early interventions of such emergency cases who need early interventions.

Introduction

Intestinal obstruction is common cause of acute abdomen which needs emergency surgery among which Small bowel obstruction is the commonest. There are different causes of SBO which includes primary volvulus,hernias,adhesions,intussusceptions and intestinal knotting.Intestinal knotting are the rare causes for bowel obstructions.Ileosigmoid knotting is the commonest and ileoileal knotting is the unusual and only reported in few cases.(1,3)

District hospitals in Ethiopia are primary level hospitals and usually the surgical unit is lead by Integrated Emergency surgical officers (IESO) who is dully known in Ethiopia and the IESO is a postgraduate professional trained for 3yrs and authorized to do emergency obstetrics, gynecologic and emergency general surgeries. It was task shifting professional license allowing to do emergency surgeries in district Ethiopian hospitals where there is scarce physician specialists.(2)

According to reports showing the clinical performance of IESOs there are numerous emergency surgeries has been doing in each day in district hospitals in Ethiopia. Emergency laparatomies are the common procedures done and SBO is the commonest one during emergency bowel surgeries.Adomen is a "Pandora's box" till it is opened which later comes with intraoperative surprises specially in developing country like Ethiopia where there is no essential diagnostic imaging in district hospitals. In this article we present a 78yrs old male patient who presented with signs and symptoms of small bowel obstruction and

diagnosed intraoperatively to have double loop obstruction secondary to ileoileal knotting. We will present the diagnostic and intraoperative challenges of the case.(2)

Case Presentation

This is 78yrs old male farmer presented to Leku district hospital emergency department with history of abdominal pain of 28hrs duration. The pain was central and intermittent colicky type initially. He had also associated history of repeated bilious type vomiting. He had history of failure to pass feces and flatus since the last one day before his presentation to hospital, later he develops abdominal distention and the pain becomes persistent and generalized. He had no any history of previous abdominal surgery, no history of abdominal trauma. He has no history of diagnosed hypertensive, cardiac and diabetes mellitus diseases.

Upon presentation on his physical examinations he was acute sick looking with vital signs of BP=90/50mmgh,PR=129bpm,RR=23br/min,T=36.9,Pso2=96% at atmospheric air.He had dry tongue and dry bucal mucosa,with little eye sunckening.On abdominal examination he had distended abdomen ,hyper tympanic on percussion,there was direct tenderness over his abdomen upon palpation,on Digital rectal examination the rectum was empty. CBC and blood group,were determined with the result of WBC=12.4,HCT=28.3,PLT=258 ,BG=BgRh=O+,Erect abdominal X-ray was sent and showed dialated small bowel loops with multiple air fluid levels.(Fig.1)

Based on the above findings with presumed diagnosis of generalized peritonitis secondary to Strangulated SBO secondary to small bowel volvulus,exploratory laparatomy was decided and the patient resuscitated by 3bags of normal saline.NG tube was inserted,broad spectrum parentral antibiotics was started.Lastely with preoperative vital signs of BP=110/60,PR=102bpm,RR=23br/min,Pso2=96%,UOP =200ml/1hr,ansthesia team was consulted for preoperative ansthesia evaluation and evaluated.then taken to OR.Under general ansthesia the patient abdomen has been opened via the midline incision. Upon entery to the general peritoneal cavity there was offensive dark hemorrhagic fluid estimated to be 800ml.There were dialated small bowel loops and gangreneous segment was at the distal ileum near to ileocecal junction(ICJ) with ileoileal knotting causing closed loop strangulated obstruction.(Fig.2).Then the knotted bowel was tried to be unraveled but it was difficult.Later it was found that ligating and resecting the gangreneous bowel mesenteric vessels was accessable for proximal resection of the gangreneous part of the bowel loops and controlled decompression was done.Then after decompresinon the bowel ends tied and this enables to unravel and exposed the distal end of the gangreneous segment which also has been resected.The distal aspect of the bowel was near the ICJ which made end to end ileoileal anastomosis difficult.Then ileo ascending colon side to side anastomosis was done in two layers using 2-0 vicryl.Intraoperatively the patient was hypotensive and managed.Finally the general peritoneal cavity was lavaged by warm saline and abdomen closed layer by layer.Patient transferred to recovery stable,and the post operative course was uneventful,sips was started on 3rd post operative date and soft regular diet on the next day,discharged stable on 7th post operation date.

Discussion

Intestinal obstruction is common cause for emergency surgery and small bowel obstruction is the leading cause for it. There are many causes for SBO.The common causes for SBO in the world and in our country are small bowel volvulus, adhesions, hernia and intussusceptions. Bowel knots are the unusual causes for bowel obstruction among others ileo-ileal knotting are the rarest reported causes for SBO.In my knowledge and review only 14 such cases were reported worldwide and only 3 cases in Ethiopia all of which were managed in specialized hospitals and managed by specialist physicians.(1,2,3) But in our case it was managed in one of our district hospital in Ethiopia and the leading surgeon was IESO who is a holder of MSc in integrated emergency surgery,dully known in Ethiopia and licensed to do obstetrics,gynecology and general surgical emergencies. For last 10yrs IESOs in Ethiopia were performing tremendous emergency surgical activities in primary health institutions in the country where still the physician specialists are scarce. (2)

Surgical scholars well described abdomen as “Pandora box” which is most time difficult to speculate what is in unless it is opened specially in developing setups where there is no sophisticated diagnostic imagings like standard ultrasounds and CT scan.

Most of the time intestinal knotting is diagnosed intraoperatively.Preoperative diagnosis is very difficult and almost impossible.Ileoileal knotting present like most other small bowel obstruction cases and has no typical or classic sign and symptoms to it except rapid progression to bowel strangulation due to its closed loop obstruction natures. Early operative intervention is mandatory after vigorous resuscitation ,nasogastric decompression and broad spectrum parental antibiotics.Emergency laparatomy should be performed through the midline incision and meticulous exploration of the bowel should be performed. Specific intervention depends on the site of the obstructed knot, the viability of the bowel loops,the length of distal bowel segment away from Ileocecal junction. The choice of operative technique includes careful unraveling the knot if both loops are viable, performing enblock resection if it is found gangrenous and easily accessible the distal and proximal segments. In articles controlled decompression and untie the knot is also suggested. But this may have risk of spillage peritoneal contamination.However,in our case the knot was at distal ileum near to ICJ difficult to enblock resection at distal segment initially the mesentery is ligated and resected and proximal segment crushed resected after control decompression, the decompressed bowel end is tied by sure and easily the knot released and unraveled,the distal part accessed near to ICJ,then ileo ascending anastomosis was done.(4,5,6.7,8)

Conclusion

Ileoileal bowel knotting is a rare cause for SBO but it should be among the differentials, it needs high index of suspicion. Its specific operative management depends on the bowel segment accesablity,viability and site of obstruction and mesentery resection and resection of the proximal segment to decompress is possible if the distal is not accessible and if it is near to ICJ.Emergency

surgical officers also have undeniable role in the surgical intervention of cases which need emergency operations

Declarations

Ethical approval-written consent was taken for the procedure per the institution guideline and informed consent was taken from the patient and his relative attendants to publish the finding and also to use his X-ray result and intraoperaitve findings(taken by camera) in the manuscript.

Competing interest-no competing interest.

Authors contribution- me as corresponding author and ESO did the operation, prepare the manuscript.

Funding –no funding.

Availability of data and materials-the patient data and materials are available in the institution (the hospital) data room.

References

1.Engida Abebe, Biruhtesfa Asmare, Abebe Addise, Ileo-ileal knotting as an uncommon cause of acute intestinal obstruction, *Journal of Surgical Case Reports*, Volume 2015, Issue 8, August 2015, rjv102, https://doi.org/10.1093/jscr/rjv102

2.Gobeze AA, Kebede Z, Berhan Y, Ghosh B. Clinical Performance of Emergency Surgical Officers in Southern Ethiopia. Ethiop J Health Sci. 2016 Sep;26(5):463-470. doi: 10.4314/ejhs.v26i5.8. PMID: 28446852; PMCID: PMC5389061.

3.Fekadu G, Tolera A, Beyene Bayissa B, Merga BT, Edessa D, Lamessa A. Epidemiology and causes of intestinal obstruction in Ethiopia: A systematic review. SAGE Open Medicine. 2022;10. doi:10.1177/20503121221083207

4. Kanamori, K., Koyanagi, K., Hara, H. *et al.* Small bowel obstruction caused by a true ileo-ileal knot: a rare case successfully treated by prior ligation of mesenteric vessels. *surg case rep* **7**, 195 (2021). https://doi.org/10.1186/s40792-021-01276-7

5. Ann R Coll Surg Engl 2020; 102: 571–576 doi 10.1308/rcsann.2020.0122

6. Mohammed, Y., Tesfaye, K. Ileoileal knotting: a rare cause of intestinal obstruction: a case report. *J Med Case Reports* **15**, 397 (2021). https://doi.org/10.1186/s13256-021-02910-6

7. Sohail M, Alyson T, Sim SK, Nik Azim NA. Intestinal knotting: A case report and brief literature review. Med J Malaysia. 2020 Sep;75(5):606-608. PMID: 32918439.

8. Taniguchi K, Iida R, Watanabe T, Nitta M, Tomioka M, Uchiyama K, Takasu A. Ileo-ileal knot: a rare case of acute strangulated intestinal obstruction. Nagoya J Med Sci. 2017 Feb;79(1):109-113. doi: 10.18999/nagjms.79.1.109. PMID: 28303069; PMCID: PMC5346628.

Figures



Figure 1

Erect abdominal x-ray with dialated small bowel loops and multiple air-fluid levels

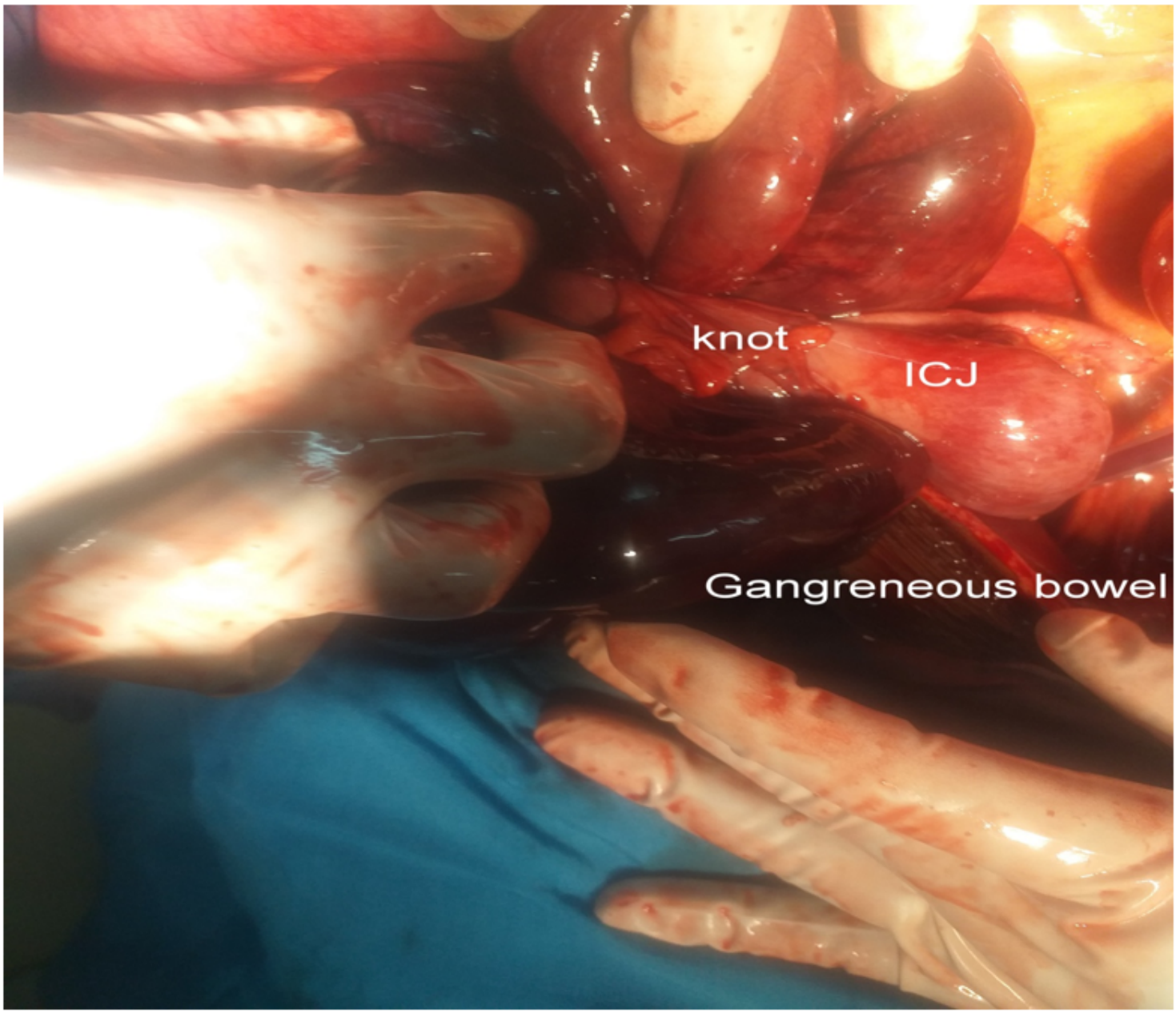

Figure 2

The intra operative finding showing the knot,the non viable segment and dialated small bowel loops