Female Reproductive System

Dr. Yared T.

The female reproductive system consists

- **Ovaries**
- **Oviducts** (uterine tubes)
- **Uterus**
- **Vagina**
- **External genitalia**

Functions

- Produce female gametes (**oocytes**)
- Provide the environment for **fertilization**
- Hold the **embryo** during its complete development through the fetal stage until birth
- Produce steroidal sex **hormones** that control organs of the reproductive system and influence other organs of the body

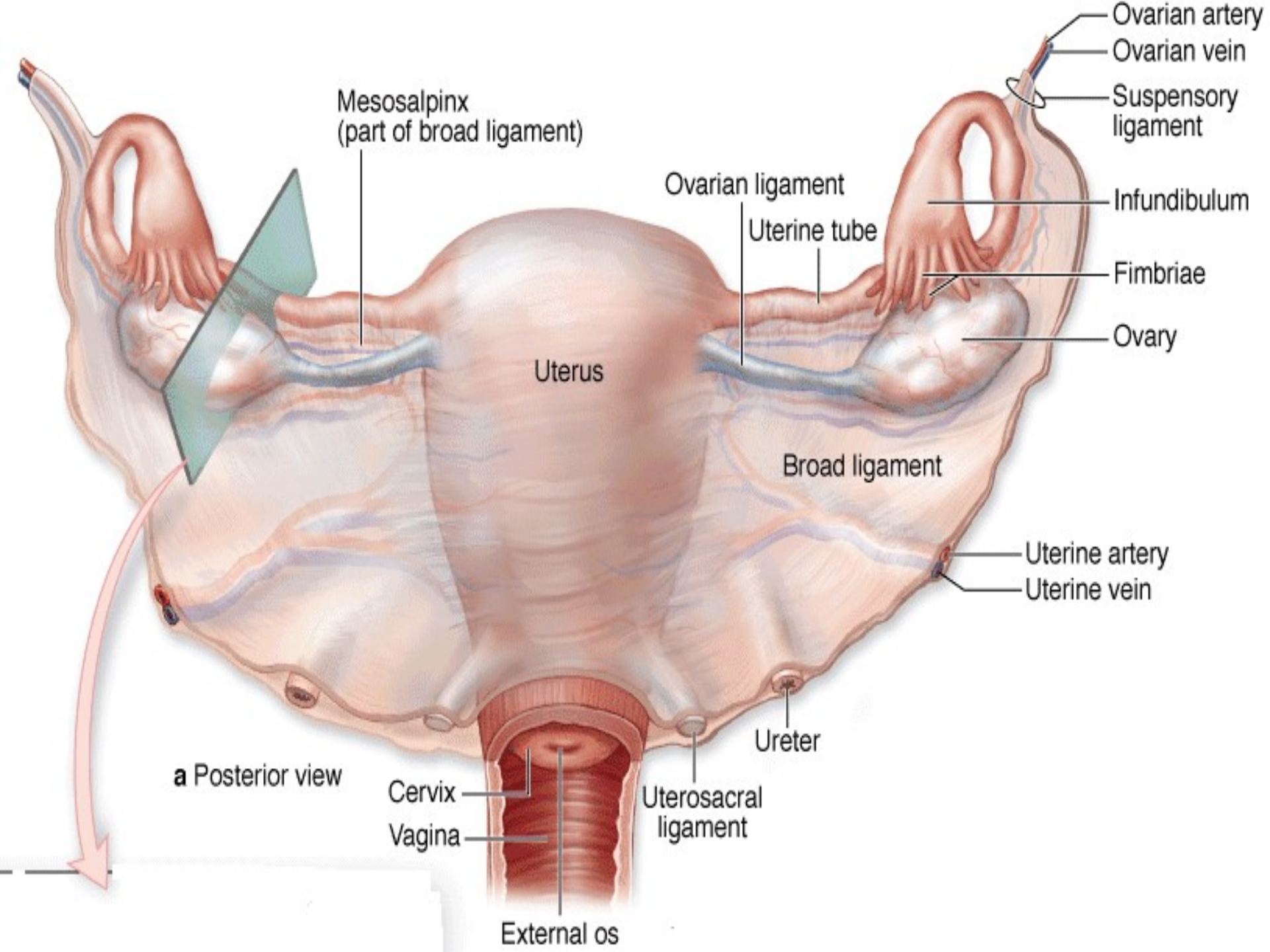
Ovarian artery
Ovarian vein
Suspensory ligament
Mesosalpinx (part of broad ligament)
Ovarian ligament
Uterine tube
Infundibulum
Fimbriae
Ovary
Uterus
Broad ligament
Uterine artery
Uterine vein
Ureter
a Posterior view
Cervix
Vagina
Uterosacral ligament
External os

Ovaries

- Ovaries are **almond-shaped** bodies
- approximately 3 cm long, 1.5 cm wide, and 1 cm thick
- located close to the lateral wall of the pelvis, in a recess called the **ovarian fossa**
- **suspensory ligament** of the ovary connect ovary to the lateral wall of the pelvis
- **ligament of the ovary connect** each ovary to the uterus

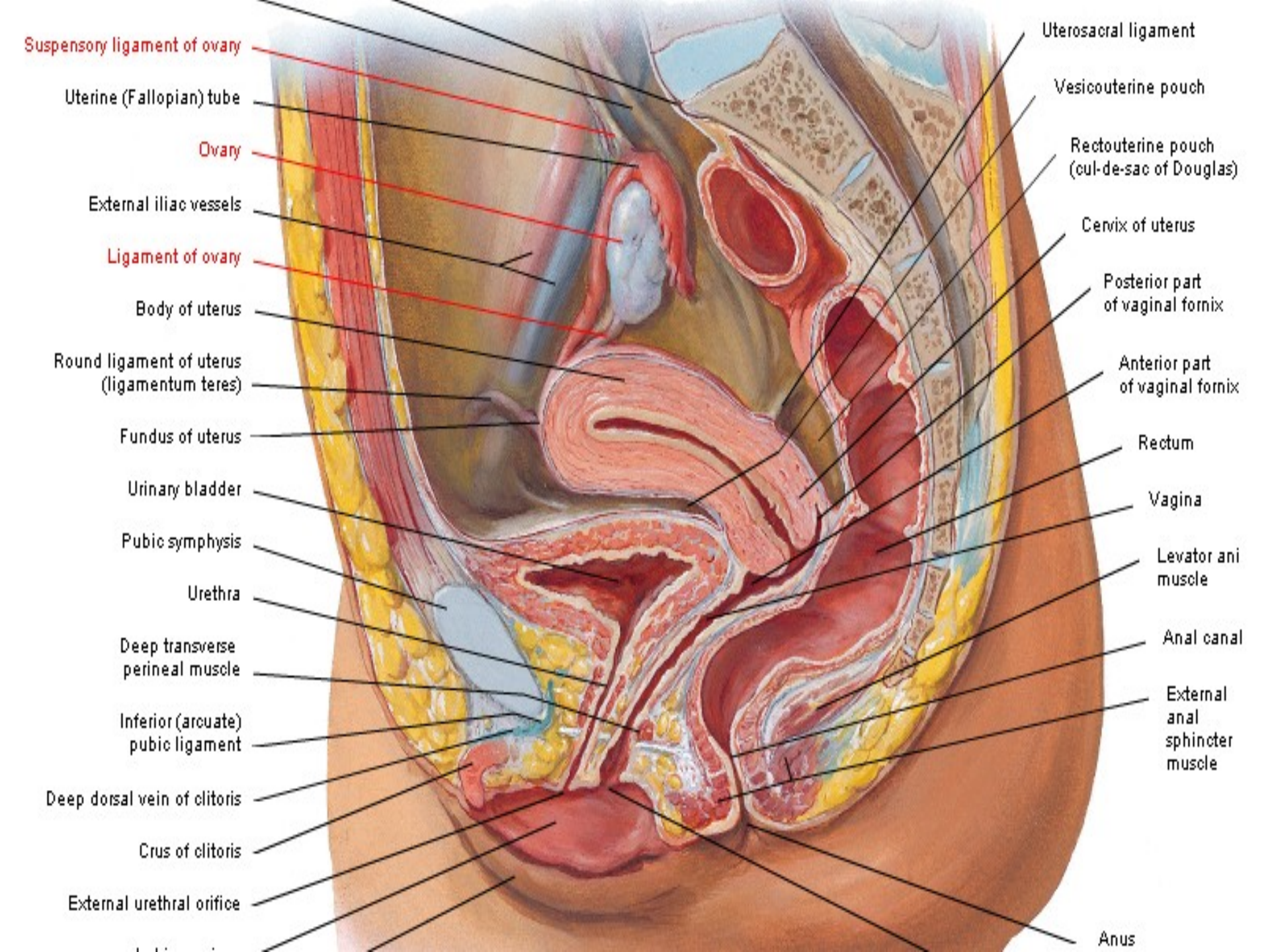
Suspensory ligament of ovary
Uterine (Fallopian) tube
Ovary
External iliac vessels
Ligament of ovary
Body of uterus
Round ligament of uterus (ligamentum teres)
Fundus of uterus
Urinary bladder
Pubic symphysis
Urethra
Deep transverse perineal muscle
Inferior (arcuate) pubic ligament
Deep dorsal vein of clitoris
Crus of clitoris
External urethral orifice
Uterosacral ligament
Vesicouterine pouch
Rectouterine pouch (cul-de-sac of Douglas)
Cervix of uterus
Posterior part of vaginal fornix
Anterior part of vaginal fornix
Rectum
Vagina
Levator ani muscle
Anal canal
External anal sphincter muscle
Anus

Regions of ovary

Cortex

- External region, make up most of the ovary
- connective tissue stroma and many **ovarian follicles**

Medulla

- Internal part of the ovary
- connective tissue and blood vessels
- **no sharp limits** between the 2 regions

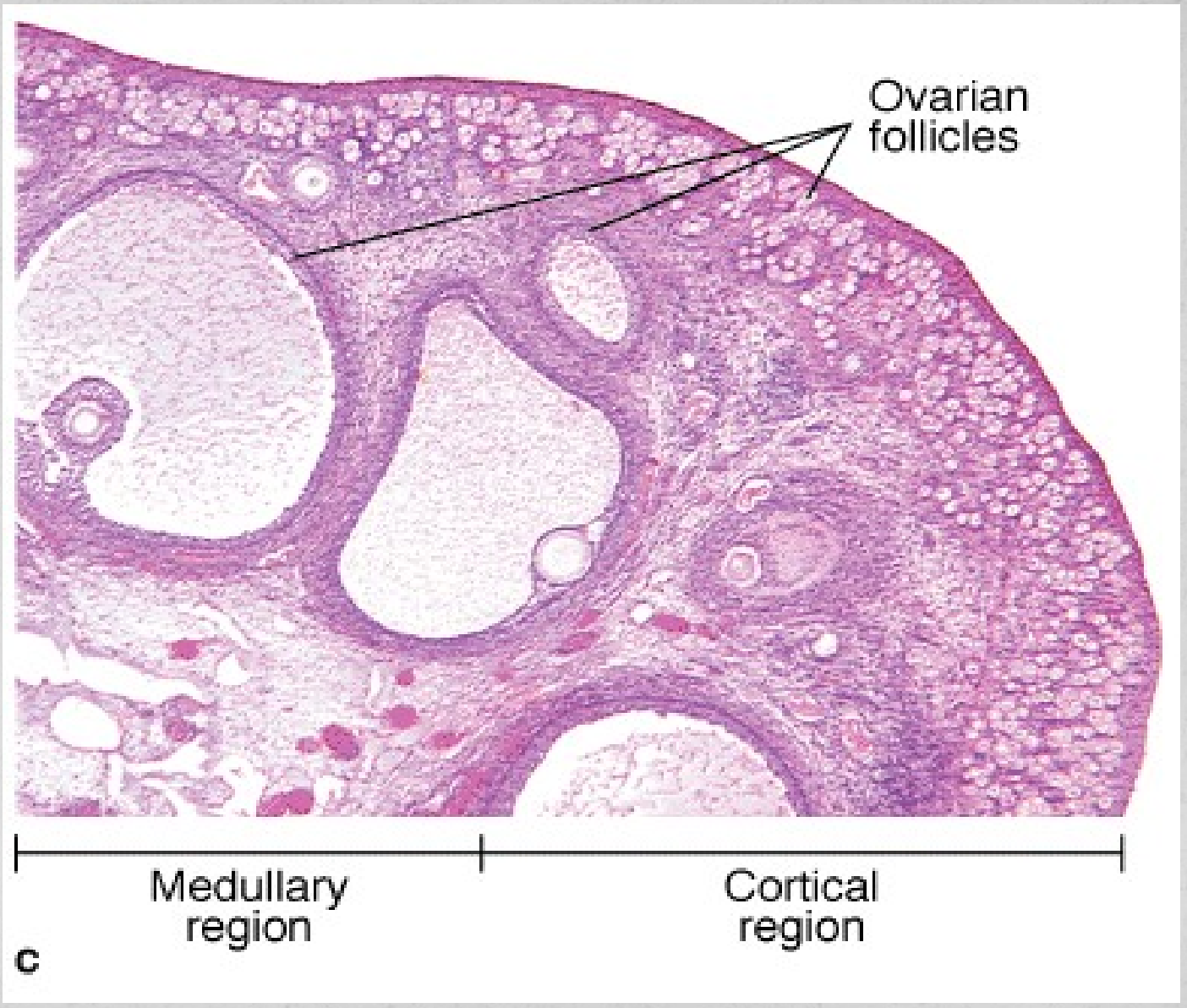
Ovarian follicles
Medullary region
Cortical region
c

Vessels and nerves

Artery

- **abdominal aorta**
- Also supply the **uterine tube**.

Veins

- right ovarian vein ascends to the **IVC**,
- left ovarian vein drains into the **left renal vein.**

Lymphatic Drainage

- To the aortic lymph nodes in the lumbar region.

Nerve

- Follow ovarian vessels from the **ovarian plexus**.
- supply the ovaries, broad ligaments, and uterine tubes.
- The **parasympathetic** fibres from the **vagus** nerves

Uterine tubes

- Also called oviducts
- two muscular tubes with considerable mobility
- measuring about 12 cm in length
- The uterine tubes carry oocytes from the ovaries and sperm cells from the uterus to the fertilization site in the ampulla of the uterine tube

Regions of oviduct

Infundibulum

- Funnel-shaped end
- Has fringe of fingerlike extensions called fimbriae

Ampulla

- The longest and expanded area where **fertilization** normally occurs

Isthmus

- Narrow region nearer the uterus

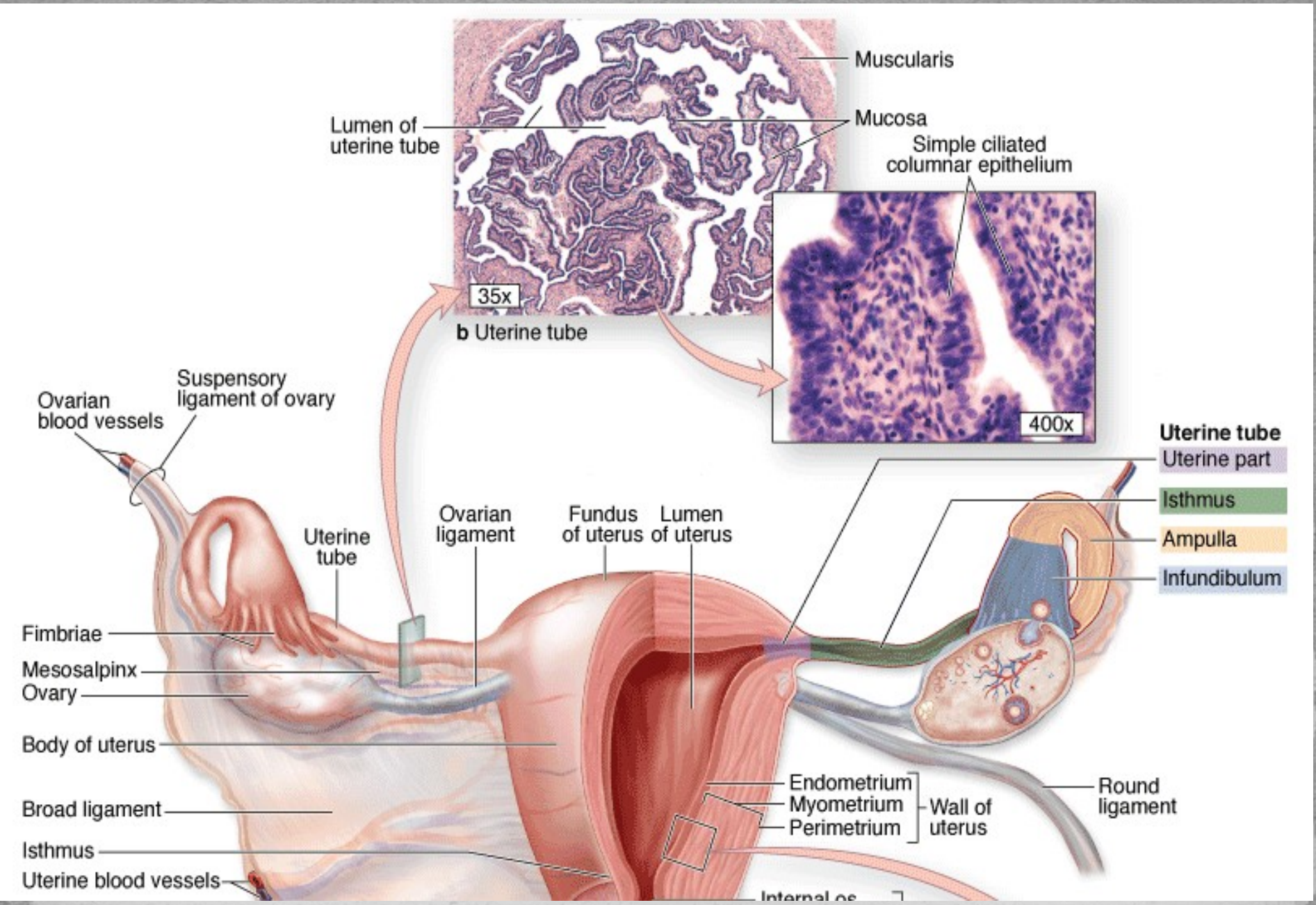
Muscularis
Lumen of uterine tube
Mucosa
Simple ciliated columnar epithelium
35x
400x
b Uterine tube
Suspensory ligament of ovary
Ovarian blood vessels
Uterine tube
Ovarian ligament
Fundus of uterus
Lumen of uterus
Uterine tube
Uterine part
Isthmus
Ampulla
Infundibulum
Fimbriae
Mesosalpinx
Ovary
Body of uterus
Broad ligament
Isthmus
Uterine blood vessels
Endometrium
Myometrium
Perimetrium
Wall of uterus
Round ligament

Uterus

- The uterus is a **pear-shaped** organ with thick, muscular walls
- superior area between the uterine tubes is called the **fundus**
- Uterus ends in a lower cylindrical structure, the **cervix**, **internal os** and cervical canal
- Supported by the set of ligaments and mesenteries

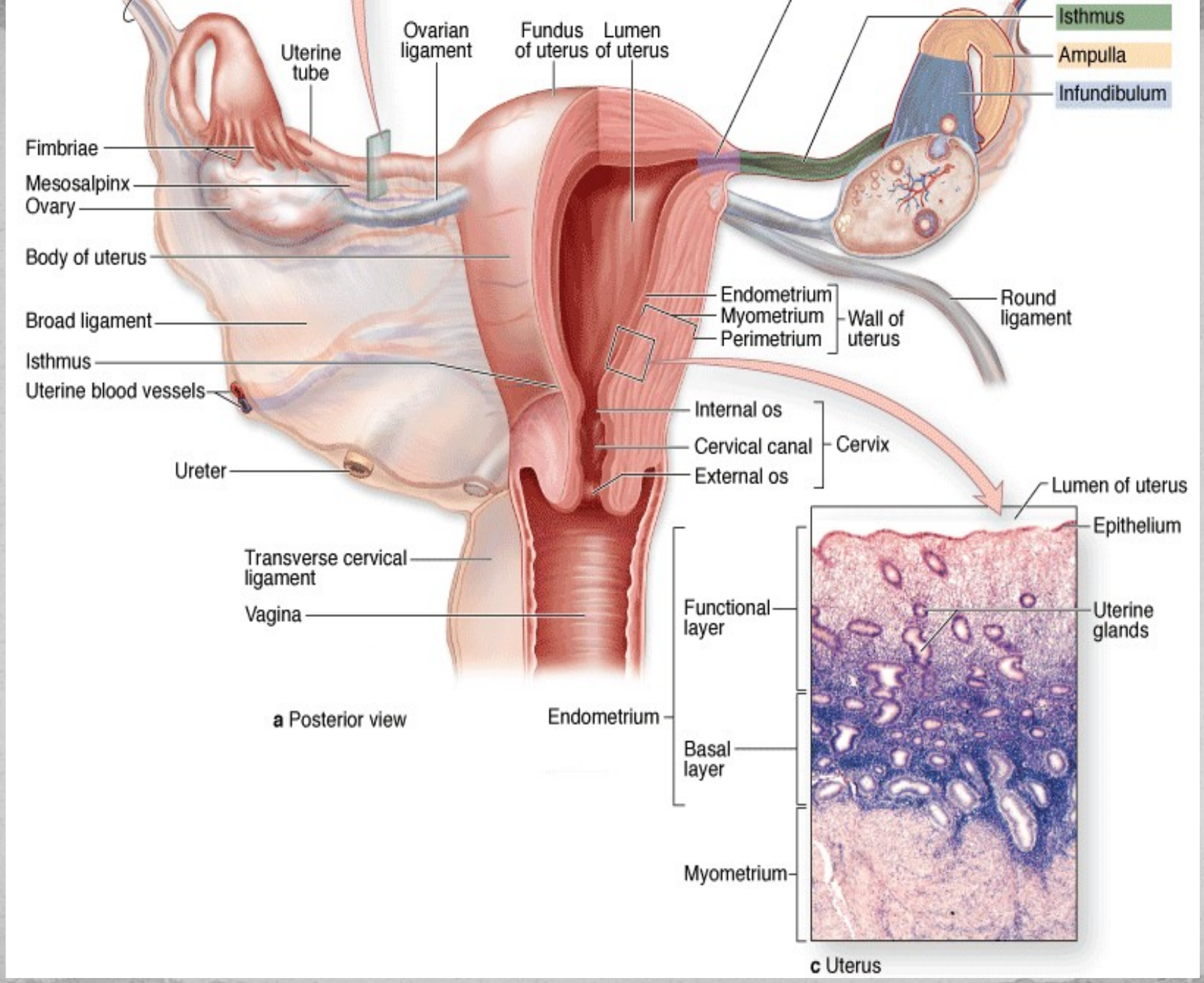
Isthmus
Ampulla
Infundibulum
Uterine tube
Ovarian ligament
Fundus of uterus
Lumen of uterus
Fimbriae
Mesosalpinx
Ovary
Body of uterus
Broad ligament
Isthmus
Uterine blood vessels
Ureter
Transverse cervical ligament
Vagina
Endometrium
Myometrium
Perimetrium
Wall of uterus
Round ligament
Internal os
Cervical canal
External os
Cervix
a Posterior view
Lumen of uterus
Epithelium
Uterine glands
Functional layer
Basal layer
Endometrium
Myometrium
c Uterus

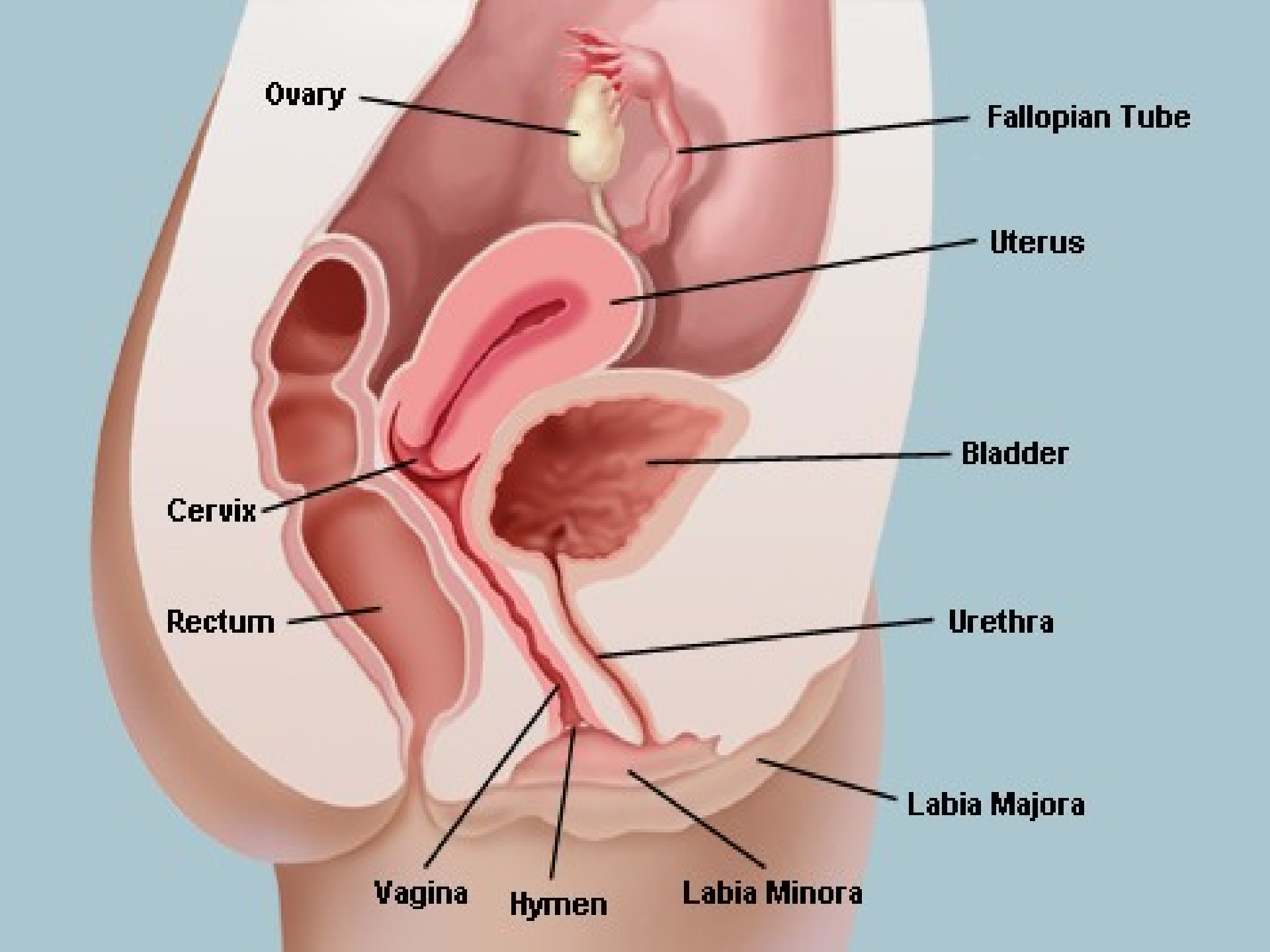
Ovary
Fallopian Tube
Uterus
Bladder
Cervix
Rectum
Urethra
Labia Majora
Vagina
Hymen
Labia Minora

Uterine layers

- The uterine wall has **three major layers**
- The three layers are continuous with their counterparts in the uterine tubes

Perimetrium

- Outer connective tissue layer

Myometrium

- highly vascular **smooth muscle**
- The thickest tunic of the uterus

Endometrium

- Mucosa lined by simple columnar epithelium
- can be subdivided into two zones

1. **basal layer**

- adjacent to the myometrium

2. The **superficial functional layer** (or functionalis)

- richer in ground substance



Ampulla of uterine tube
Infundibulum of uterine tube
Isthmus of uterine tube
Fundus of uterus
Fimbriae of uterine tube
Infundibulum of uterine tube
Suspensory ligament
Uterine (fallopian) tube
Ovary
Ovarian ligament
Uterine cavity
Endometrium
Myometrium
Perimetrium
Broad ligament
Body of uterus
Internal os
Ureter
Isthmus
Cervix of uterus
Uterosacral ligament
Cervical canal
External os
Lateral fornix
Vagina
Rugae

Vessels and nerves

Artery

- The blood vessels supplying functional layer of endometrium **slough** of periodically the during menses
- uterine arteries, branches of the internal iliac arteries
- Also supplies the cervix and vagina

Vein

- The uterine veins, drain into the **internal iliac vein**

Lymphatic Drainage

- aortic lymph nodes, external iliac lymph nodes, superficial inguinal lymph nodes and internal iliac and sacral lymph nodes.

Nerve

- inferior hypogastric plexus, uterovaginal plexus.
- Parasympathetic fibres are from the pelvic splanchnic nerves (S2-4), and sympathetic fibres are from the above plexus

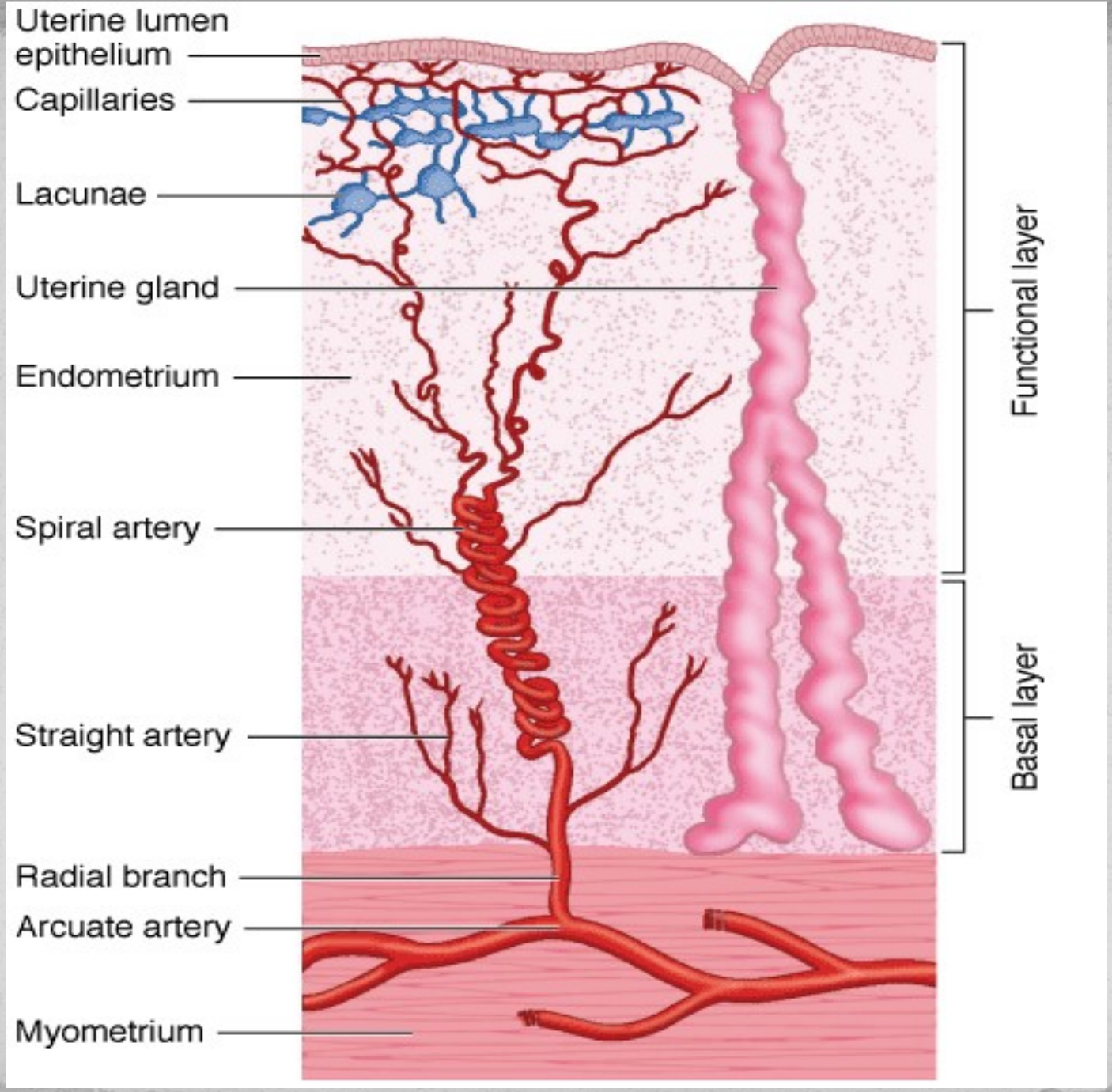
Uterine lumen
epithelium
Capillaries
Lacunae
Uterine gland
Endometrium
Spiral artery
Straight artery
Radial branch
Arcuate artery
Myometrium
Functional layer
Basal layer

Uterine cervix

- The cervix is the lower, more **cylindrical** part of the uterus
- The region of the cervix where the endocervical canal opens into the vagina is called the **external os**
- exocervical mucosa has **stratified squamous epithelium**
- endocervix is a **simple columnar epithelium**
- A distinct junction, or **transformation zone**, occurs between the two epitheliums

Vagina

- female organ of **copulation**
- fibromuscular tube or sheath lined with stratified squamous epithelium.
- It extends from the cervix of the uterus to the vestibule of the vagina.
- In the anatomical position, the vagina descends **anteroinferiorly**.

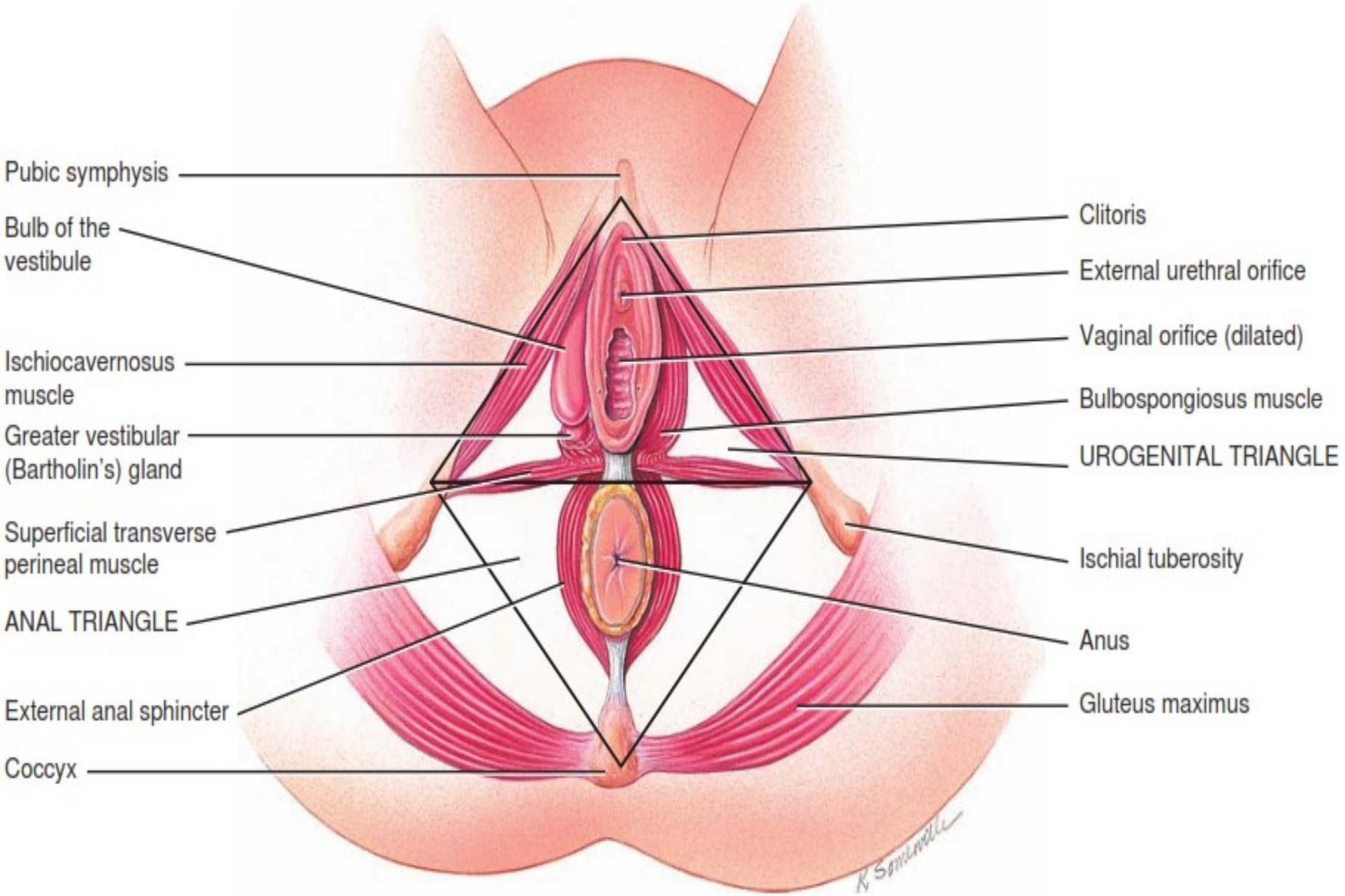

Inferior view

- The vaginal recess around the cervix is called the **fornix**
- posterior part of the fornix is the deepest and is related to the **rectouterine pouch**
- The wall of the vagina lacks glands
- consists of three layers: mucosa, muscular layer, and adventitia

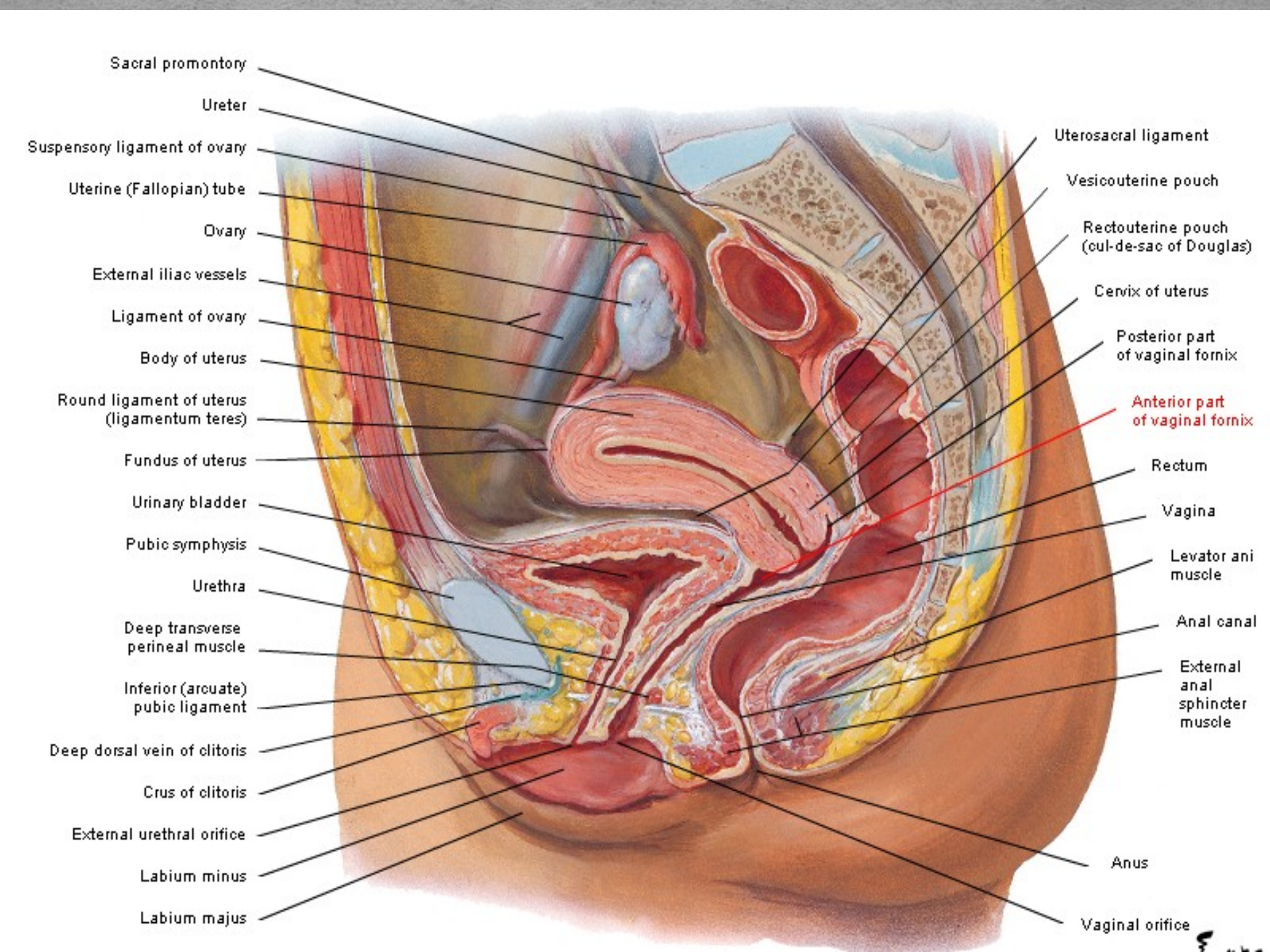
Sacral promontory
Ureter
Suspensory ligament of ovary
Uterine (Fallopian) tube
Ovary
External iliac vessels
Ligament of ovary
Body of uterus
Round ligament of uterus (ligamentum teres)
Fundus of uterus
Urinary bladder
Pubic symphysis
Urethra
Deep transverse perineal muscle
Inferior (arcuate) pubic ligament
Deep dorsal vein of clitoris
Crus of clitoris
External urethral orifice
Labium minus
Labium majus
Uterosacral ligament
Vesicouterine pouch
Rectouterine pouch (cul-de-sac of Douglas)
Cervix of uterus
Posterior part of vaginal fornix
Anterior part of vaginal fornix
Rectum
Vagina
Levator ani muscle
Anal canal
External anal sphincter muscle
Anus
Vaginal orifice

Vessels and nerves

Artery

- vaginal artery branch of the uterine artery.
- The internal pudendal artery and vaginal branches of the middle rectal artery

Vein

- vaginal venous plexuses
- Drainage is into the internal iliac veins.

Lymphatic drainage

- internal and external iliac lymph nodes
- superficial inguinal lymph nodes.

Nerve

- from the uterovaginal plexus.
- inferior hypogastric plexus and the pelvic splanchnic nerves.
- pudendal nerve.

Vulva

- The term vulva or pudendum refers to the external genitals of the female
- The following components comprise the vulva:

1. Mons pubis

- elevation of adipose tissue covered by skin and coarse pubic hair
- From the mons pubis, two longitudinal folds of skin, the **labia majora and labia minora**

graphic Atlas of
ond Edition,

ternal genitals

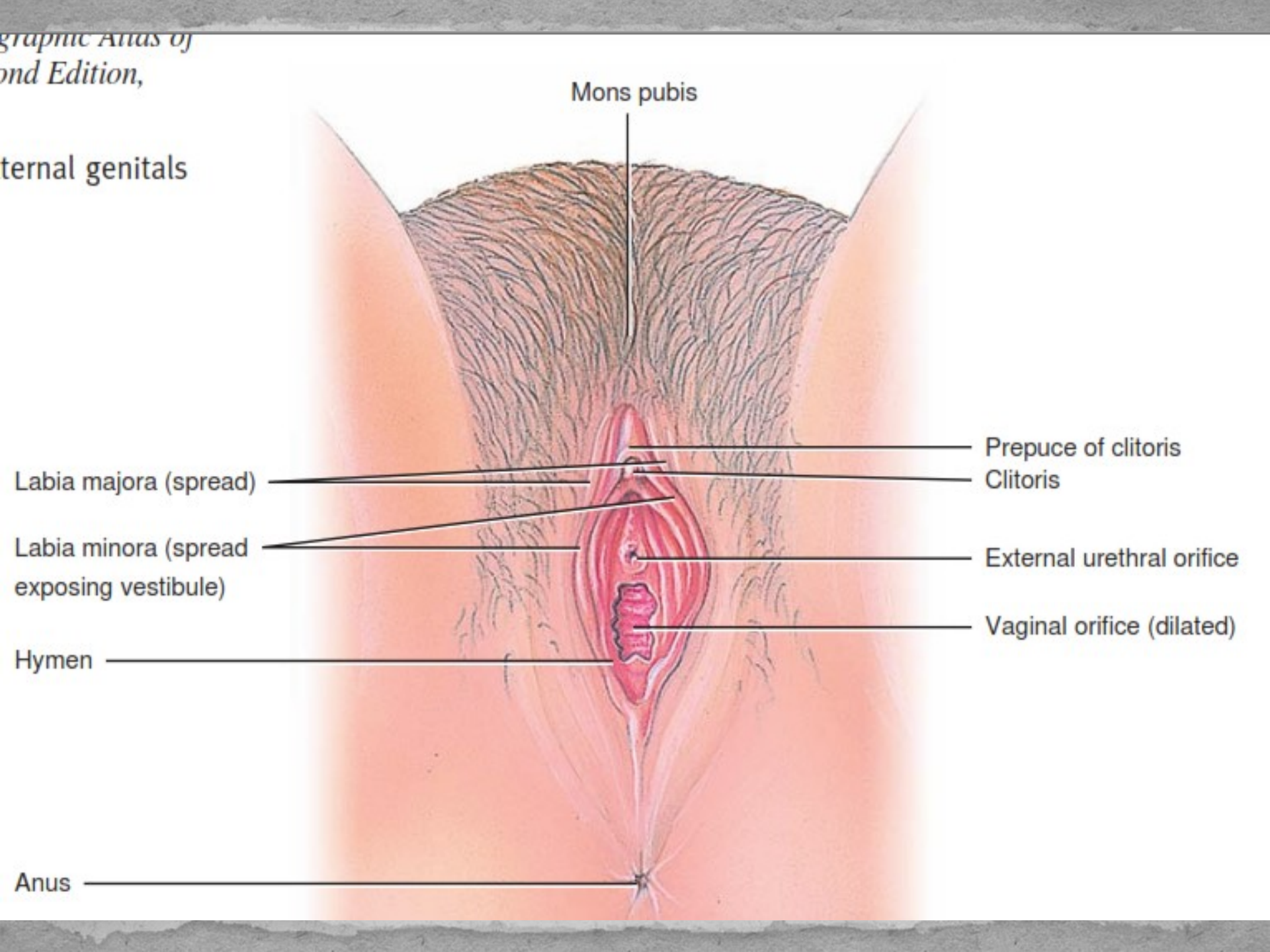

2. Labia majora

- Contain, hair, adipose tissue, sebaceous (oil) glands, and apocrine sudoriferous (sweat) glands.

3. Labia minora

- devoid of pubic hair and fat
- have few sudoriferous glands, many sebaceous glands.

4. **Clitoris**

- is a small cylindrical mass
- Composed of two small erectile bodies, the corpora cavernosa

5. **Vestibule**

- The region between the labia minora

Vestibule contain

- **Hymen**: borded the vaginal orifice,
- **Vaginal orifice**: the opening of the vagina
- **External urethral orifice**: opening of the urethra
- **ducts** of glands: On either side of the external urethral orifice, paraurethral (Skene’s) glands
- On either side of the vaginal orifice, greater vestibular (Bartholin’s) glands

Thank You!