## Resource view

| | |
|---|---|
| Resource name | RADIOLOGY IN DENTISTRY |
| Resource description | This is a lecture on radiology in dentistry. |
| Resource content | |

# RADIOLOGY

## Contents:

1. Characteristics and properties of X-rays
2. Features and requirements of an X-ray Tube
3. Dental X-ray generating equipment
4. Radiograph Film
5. Radiograph processing method and solutions
6. Radiation Regulation
7. Radiation Safety
8. Radiograph Taking Technique
9. Types of Radiograph- Intra Oral and Extra Oral
10. Radiograph Faults
11. Localisation Technique- SLOB Rule

### Some of the characteristics and properties of X-rays are:

- They travel in straight lines at the speed of light.
- They affect photographic film by producing a hidden image made visible by processing.

- They cause certain substances to fluoresce (glow).
- They cause irritation of living cells and, in large amounts, can cause necrosis (death) of the cells, a fact that necessitates caution in using X-rays.

## Main features and requirements of an X-ray tube

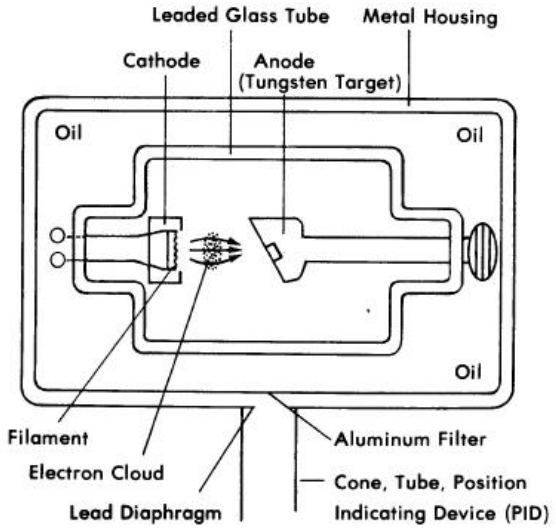


- The *cathode* (negative) consists of a heated *filament* of tungsten that provides the source of electrons.
- The *anode* (positive) consists of a ***TARGET*** (a small piece of tungsten) set into the angled face of a large *copper block* to allow efficient removal of heat.
- A *focusing device* aims the stream of electrons at the *focal spot* on the target.
- A high-voltage (kilovoltage,kV) connected between the cathode and anode accelerates the electrons from the negative filament to the positive target. This is sometimes referred to as kVp or kilovoltage peak
- A current (milliamperage, mA) flows from the cathode to the anode. This is a measure of the quantity of electrons being accelerated.
- A surrounding *lead casing* absorbs unwanted X-rays as a radiation protection measure since X-rays are emitted in all directions. Surrounding *oil facilitates* the removal of heat.

Definition of terms used in X-ray interactions

• *Scattering* • change in direction of a photon with or without a loss of energy

• *Absorption* • deposition of energy, i.e. removal of energy from the beam

• *Attenuation* • reduction in the intensity of the main X-ray beam caused by absorption and scattering
Attenuation = Absorption + Scattering

• ***Ionization*** • removal of an electron from a neutral atom producing a negative ion (the electron) and a positive ion (the remaining atom).

## Classification of the biological effects

The biologically damaging effects of ionizing radiation are classified into three main categories:

• **Somatic DETERMINISTIC effects**

• **Somatic STOCHASTIC effects.**

• **Genetic STOCHASTIC effects**.

## The somatic effects are further subdivided into:

• *Acute* or *immediate* effects • appearing shortly after exposure, e.g. as a result of large whole body doses

• *Chronic* or *long-term* effects • becoming evident after a long period of time, the so- called *latent period* (20 years or more), e.g. leukaemia.

**SOMATIC DETERMINISTIC EFFECTS:**

these are the damaging effects to the body that will DEFINITELY result from a specific high dose of radiation such

as skin reddening or cataract formation. usually a threshold dose exists below which there will be no effect.

**SOMATIC STOCHASTIC EFFECTS:**
these effects are the ones which MAY develop.

their development is random and depends on the laws of chance or probability for example : leukemia or tumors.

there is no threshold in these effects and the chances are carried on with each radiation exposure.

the severity of the damage is not related to the side of the dose

**GENETIC STOCHASTIC EFFECTS:**
mutation can be caused by radiation or any other external factors.

radiation to the DNA of the sperm or egg can lead to an abnormality within the offspring however there is no certainty of these effects due to which genetic effects are always stochastic effects.

**EFFECTS ON THE UNBORN CHILD:**
the developing fetus is particularly sensitive to the effects of radiation during the 2 - 9th week after conception (organogensis)

| X-RAY EXAMINATION | ESTIMATED RISK OF FATAL CANCER | EFFECTIVE DOSE (microsievets) |
|---|---|---|
| Dental intraoral | 1 in 20,000,000 | <2 |
| Dental panoramic tomography | 1 in 1,000,000 | 3-24 |
| Skull (PA) | 1 in 670,000 | |
| Skull (Lat) | 1 in 2,000,000 | <6 |

The biological effects of ionising radiation can be extremely damaging.

- *Somatic deterministic effects* predominate with **high** doses of radiation, while *somatic stochastic effects* predominate with **low** doses.
- Dental radiology employs low doses and the risk of stochastic effects is very small.
- The various important dose-reduction and dose-limitation measures that are therefore necessary to keep all exposures ***as low as reasonably practicable* (ALARP), for both patients and for dental staff**

**Dental X-ray generating equipment**

They all consist of three main components:
- A tubehead
- Positioning arms
- A control panel and circuitry.

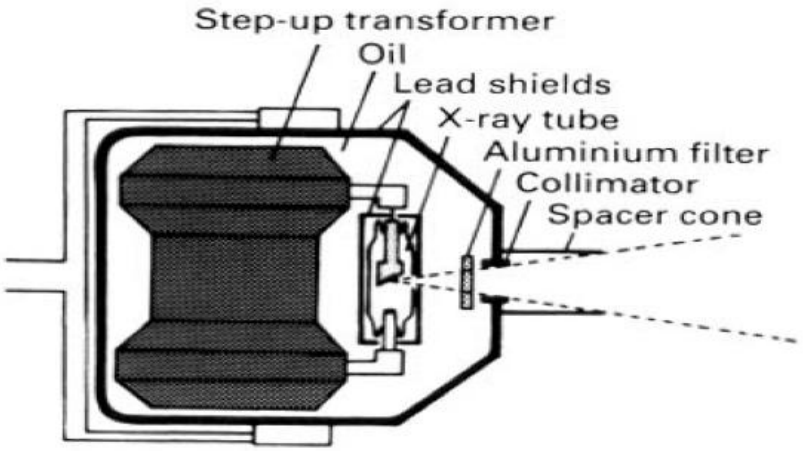


**Fig. 5.3** Examples of adaptors/collimators designed to

- The *glass X-ray tube,* including the filament, copper block and the target
- The *step-up transformer* required to step-up the mains voltage of 240 volts to the high voltage (kV) required across the X-ray tube
- The *step-down transformer* required to step- down the mains voltage of 240 volts to the low voltage current required to heat the filament
- A *surrounding lead shield* to minimize leakage
- *Surrounding oil to* facilitate heat removal
- *Aluminium filtration* to remove harmful low- energy (soft) X-rays
- The *collimator* – a metal disc or cylinder with central aperture designed to shape and limit the beam size to a rectangle (the same size as intraoral film) or round with a maximum diameter of 6 cm
- The *spacer cone* or *beam-indicating device (BID)* – a device for indicating the direction of the beam and setting the ideal distance from the focal spot on the target to the skin. The legal focus to skin (fsd) distances are:
- 200 mm for sets operating above 60 kV
- 100 mm for sets operating below 60 kV
- There are several designs of spacer cone available, varying in shape, material and length, as well as adaptors to change the shape of the emerging X-ray beam




**Fig. 5.3** Examples of adaptors/collimators designed to change the shape of the beam from circular to rectangular. **A** Siemens Heliodent collimator, **B** Dentsply's Universal collimator.

## Image receptors

The usual image receptor used in dentistry is radiographic film. There are two basic types:

- *Direct-action* or *non-screen* film (sometimes referred to as *wrapped* or *packet* film).

- *Indirect-action* or *screen* film, so-called because it is used in combination with *intensifying screens* in a *cassette.*

**Direct-action (non-screen) film**

used for intraoral radiography

**INTRAORAL FILM SPEED CLASSIFICATION**

| FILM SPEED GROUP | SPEED RANGE (Reciprocal roentgens) |
|---|---|
| C | 6-12 |
| D | 12-24 |
| E | 24-48 |
| F | 48-96 |

## Sizes

Various sizes of film are available, although only three are usually used routinely

- 31 x 41 mm **?** for periapicals and
- 22x35mm **?** bitewings
- 57 x 76 mm **?** for occlusals.

The contents of a film packet.

1. The outer wrapper. -made of non- absorbent paper or plastic and is sealed to prevent the ingress of saliva.
2. The film.
3. The sheet of lead foil. Prevents **?**

- Some of the residual radiation that has passed through the film from continuing into the patient's tissues
- Scattered secondary radiation, from X-ray photon interactions within the tissues

1. The protective black paper -The black paper on either side of the film is there to protect the film from:

- Light
- Damage by fingers while being unwrapped
- Saliva, which may leak into the film packet.

## The radiographic film

The radiographic film comprises of four basic components:

- A *plastic base* made of clear, transparent cellulose acetate which acts as a support for the emulsion but does not contribute to the final image
- A thin layer of *adhesive* that fixes the emulsion to the base
- The *emulsion* on **both** sides of the base **?** this consists of silver halide (usually bromide) crystals embedded in a gelatin matrix. The X-ray

photons *sensitize* the silver halide crystals that they strike and these sensitized silver halide crystals are later reduced to visible black metallic silver in the developer (see later)

- A *protective layer* of clear gelatin to shield the emulsion from mechanical damage.

# *Important points to note*

- The side of the packet that faces towards the X-ray beam has either a pebbled or a smooth surface and is usually white.
- The sheet of lead foil contains an embossed pattern so that should the film packet be placed the wrong way round, the pattern will appear on the resultant radiograph. This enables the cause of the resultant underexposed pale film to be easily identified.

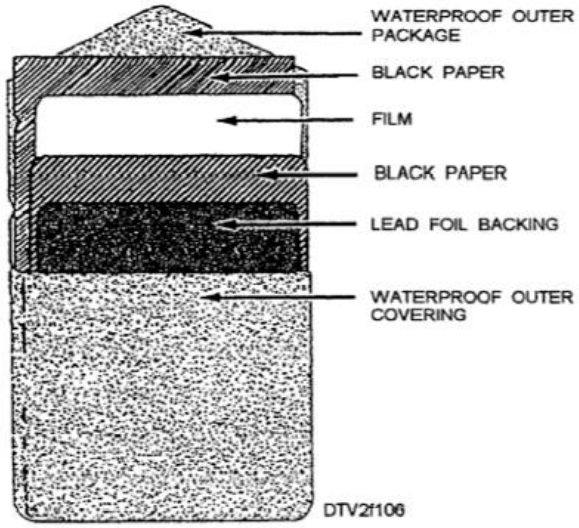


**Figure 1-6.—Partially unwrapped periapical film.**

## Indirect-action film

### Uses

Film/screen combinations are used as image detectors whenever possible because of the reduced dose of radiation to the patient (particularly when very fine image detail is not essential). The main uses include:

**• Extraoral projections, including:**

• Oblique lateral radiographs

• All skull radiographs

- Dental panoramic tomographs
- All routine medical radiography
- **The intraoral, vertex occlusal radiograph**

### Indirect-action film construction

The following important points should be noted:

- There is no orientation *dot* embossed in the film so some form of additional identification is required, e.g. metal letters, L or R placed on the outside of the cassette or electronic marking

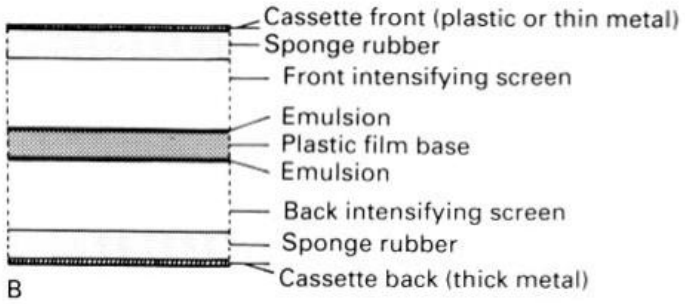


## Processing theory

**Stage 1:Development**
The **sensitized** silver halide crystals in the emulsion are converted to black metallic silver to produce the *black/grey* parts of the image.

**Stage 2:Washing**
The film is washed in water to remove residual developer solution.

**Stage 3: Fixation**
The **unsensitized** silver halide crystals in the emulsion are removed to reveal the *transparent* or *white* parts of the image and the emulsion is hardened.

**Stage 4:Washing**
The film is washed thoroughly in running water to remove residual fixer solution.

**Stage 5: Drying**
The resultant *black/white/grey* radiograph is dried.

## Practical processing methods

There are three practical processing methods available:

- Manual or wet processing
- Automatic processing
- Using self-developing films.

### *Manual processing*

Manual processing is usually carried out in a *dark- room.,* the general requirements of which should include:

- Absolute light-tightness
- Adequate working space
- Adequate ventilation
- Adequate washing facilities
- Adequate film storage facilities
- Safelights positioned 1.2m from the work

surfaces with 25 W bulbs and filters suitable for the type of film being used

### *Manual processing cycle*

1. The exposed film packet is unwrapped and the film clipped on to a hanger.

2. The film is immersed in DEVELOPER and agitated several times in the solution to remove air bubbles and left for about 5 minutes at 20C.

3. The residual developer is rinsed off in water for about 10 seconds.

4. The film is immersed in FIXER for about 8-10 minutes.

5. The film is washed in running water for about 10-20 minutes to remove any residual fixer. 6. The film is allowed to dry in a dust-free atmosphere.

## The typical constituents of developer solution and their functions:-

| CONSTITUTENTS | FUNCTIONS |
|---|---|
| Phenidone | Helps bring out the image |
| Hydroquinone | Builds contrast |
| Sodium sulphite | Preservative- reduces oxidation |
| Potassium carbonate | Activator- governs the activity of the developing agents |
| Benzotriazole | Restrainer- prevents fog and controls the activity of the developing agents |
| Gluteraldehyde | Hardens the emulsion |
| Fungicide | Prevents bacterial growth |
| Buffer | Maintains pH (7+) |
| Water | Solvent |

**The typical constituents of fixer solution and their functions :-**

| CONSTITUENTS | FUNCTIONS |
|---|---|
| Ammonium thiosulphate | Removes unsensitized silver halide crystals |
| Sodium sulphite | Preservative • prevents deterioration of the fixing agent |
| Aluminium chloride | Hardener |
| Acetic acid | Acidifier • maintain pH |
| Water | Solvent |

## *Important points to note regarding development*

• The alkaline developer solution should be made up to the concentration recommended in the manufacturer's instructions.

• The developer solution is oxidized by air and its effectiveness decreased. Solutions should be used for no more than 10-14 days.

• If the development process is allowed to continue for too long, more silver will be deposited than was intended and the radiograph will be too dark. Conversely, if there is too short a development time the radiograph will be too light.

• Development TIME (in fresh solutions) is dependent on the TEMPERATURE of the solution. The usual value recommended is 5 minutes at 20°C.

• If the temperature is too high, development is rapid, the film may be too dark and the emulsion may be damaged. If the temperature is too low, development is slowed and a pale film will result.

## *Important points to note regarding fixing*

• Fixer solution should be made up to the concentration recommended by the manufacturer. It is an acid solution so contamination with developer should be avoided.

• Films should ideally be fixed for doubling the *clearing time.* The clearing time is how long it takes to remove the unsensitized silver halide crystals. Total fixing time is usually 8-10 minutes.

• Films may be removed from the fixer after 2-4 minutes for *wet* viewing but should be returned to the fixer solution to complete fixing.

• Inadequately fixed films may appear greenish yellow or milky owing to residual emulsion. In time these films may discolour further, becoming brown.

## *Automatic processing cycle*

The cycle is the same as for manual processing except that the rollers squeeze off any excess developing solution before passing the film on to the fixer, eliminating the need for the water wash between these two solutions.

### *Advantages*

The main advantages include:

• Timesaving•dry films are produced in about 5 minutes

• The need for a darkroom is often eliminated

• Controlled, standardized processing conditions are easy to maintain

• Chemicals can be replenished automatically by some machines.

### *Disadvantages*

The main disadvantages include:

- Strict maintenance and regular cleaning are essential; dirty rollers produce marked films
- Some models need to be plumbed in
- Equipment is relatively expensive
- Smaller machines cannot process large extraoral films.

# Self-developing films

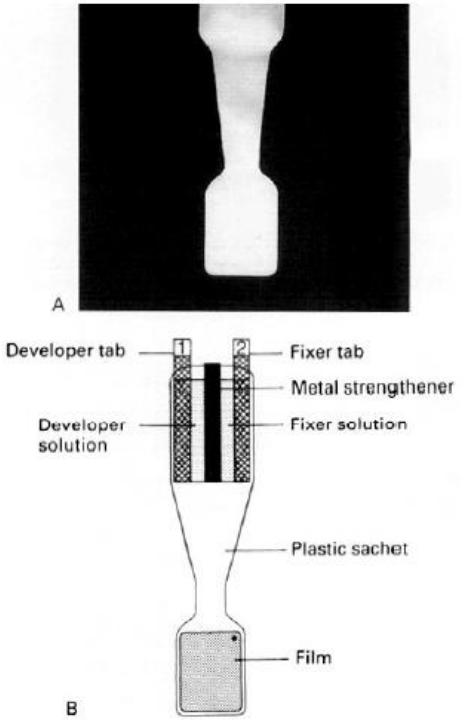


## *Advantages*

The main advantages include:

• No darkroom or processing facilities are needed.

• Time saving • the final radiograph is ready in about a minute.

## *Disadvantages*

The main disadvantages include:

- Poor overall image quality
- The image deteriorates rapidly with time, there is no lead foil inside the film packet
- The film packet is very flexible , easily bent these films are difficult to use in positioning holders

- Relatively expensive.

## Ionising Radiation (Medical Exposure) Regulations 2000 (IRMER 2000)

### General points

1.These regulations are concerned with the safety of patients.

2.They replace the Ionising Radiation (Protection of Persons Undergoing Medical Examination or Treatment) Regulations 1988.

3.New positions of responsibility are defined, namely:
 the employer the referrer the practitioner the operator.

**4.** ***Duties of the Practitioner, Operator and Referrer.***

- ***The referrer:*** a registered doctor or dentist or other health professional entitled to refer a patient to a *practitioner* for a medical exposure. The *referrer* is responsible for supplying the *practitioner* with sufficient information to justify an appropriate exposure.
- ***The practitioner:*** a registered doctor or dentist or other health professional entitled to take responsibility for a medical exposure. The *practitioner* must be adequately trained to take decisions and the responsibility for the justification of every exposure.
- ***The operator:*** the person conducting any practical aspect of a medical exposure. Practical aspects include:

1. patient identification
2. positioning the film, patient or X-ray tubehead , setting the exposure parameters
3. pressing the exposure switch to initiate the exposure
4. processing films
5. clinical evaluation of radiographs
6. exposing test objects as part of the QA programme.

7 . Justification of individual medical exposures.

All doses must be kept as low as reasonably practicable (**ALARP**) consistent with the intended purpose.

- Clinical evaluation and report in patients records for all films
- Rectangular collimation, with minimum skin to focus distance as follows:- <60kV=10cm, >60kv= 20cm
- Use of fastest film consistent with good diagnostic(ISO speed E or faster)
- Routine use of film holder

- avoiding repetition- minimum targets for radiographic quality
-

| Rating | Percentage of radiograph taken |
|---|---|
| 1 | Not less than 70% |
| 2 | Not greater than 20% |
| 3 | Not greater than 10% |

| Rating | Quality | Basis |
|---|---|---|
| 1 | Excellent | No errors of exposure, positioning or processing |
| 2 | Diagnostically expectable | Some errors of exposure, positioning or processing, but which do not detract from diagnostic utility of the radiograph |
| 3 | Unacceptable | errors of exposure, positioning or processing render radiograph unacceptable |

6.*Equipment.* The keeping and maintenance of an up-to-date inventory of each item of equipment is required and should include:

- name of manufacturer, model number
1. serial number or other unique identifier
2. year of manufacture
3. year of installation.

7. *Adequate training and continuing education. Operators* and *practitioners* must have received adequate training and must undertake continuing education and training after qualification.

8. *Lead protection.* There is no justification for the routine use of lead aprons for patients in dental radiography. Thyroid collars, should be used in those few cases where the thyroid may be in primary beam.

RADIOGRAPHIC ADUITS SHOULD BE DONE EVERY 12 MONTHS TO ASSESS THE QUALITY OF XRAYS BEING TAKEN WITH THE HELP OF QUALITY RATING:

RISK ASSESSMENT SHOULD BE DONE EVERY 5 YEARS WITH THE HELP OF RPA (radiation protection advisor )

## Radiation workers

Radiation workers are those people who are exposed to radiation during the course of their work. The ICRP further divides these workers into two subgroups depending on the level of occupational exposure:

- Classified workers
- Non-classified workers.

The previous annual dose limits and those currently in force under the Ionising Radiations Regulations 1999

| | Old dose limits | New dose limits |
|---|---|---|
| Classified workers | 50 mSv | 20 mSv |
| Non classified workers | 15 mSv | 6 mSv |
| General public | 5 mSv | 1 mSv |

Classified workers
- Receive high levels of exposure to radiation at work (if Local Rules are observed this is highly unlikely in dental practice).
- Require compulsory personal monitoring.
- Require compulsory annual health checks.

Non-classified workers (most dental staff)
- Receive low levels of exposure to radiation at work (as in the dental surgery).
- The annual dose limits are 3/10 of the classified workers' limits. Provided the Local Rules are observed, all dental staff should receive an annual effective dose of considerably less than the limit of 6 mSv. Hence, the regulations suggest the setting of 'Dose Constraints'. These represent the upper level of individual dose that should not be exceeded in a well-managed practice and for dental radiography the following recommendations are made:

1 msv or employees directly involved with the radiography (operators)
0.3 msv for employees not directly involved with the radiography and for members of the general public.

**Main methods of monitoring and measuring radiation dose**

There are three main devices

1. Film badges-

- They consist of a blue plastic frame containing a variety of different metal filters and a small radiographic film which reacts to radiation
- They are worn on the outside of the clothes, usually at the level of the reproductive organs, for 1-3 months before being processed
- They are the most common form of personal monitoring device currently in use.

2. Thermoluminescent dosimeters (TLD)

a. Badge

a. Extremity monitor

**Radiation Protection Adviser (RPA).**

A suitably trained RPA must be appointed in writing and consulted it could be an expert in radiation protection and will be able to advise on compliance with the Regulations and all aspects of radiation protection, including advice on:

- controlled and designated areas for all radiation equipment
- installation of new or modified X-ray equipment
- periodic examination and testing of engineering controls, safety features and warning signals
- systems of work

• risk assessment

• contingency plans • staff training

• assessment and recording of doses received by patients

• quality assurance (QA) programmes.

**Radiation Protection Supervisor (RPS).**

An RPS• usually a dentist or senior member of staff in the practice

• should be appointed to ensure compliance with IRR99 and the Local Rules.

The RPS must be adequately trained, should be closely involved with the radiography and have the authority to adequately implement their responsibilities.

## PERIAPICAL RADIOLGRAPH

*Periapical radiography* describes intraoral techniques designed to show individual teeth and the tissues *around the apices.*

The main clinical indications for periapical radiography include:

- Detection of apical infection/inflammation
- Assessment of the periodontal status
- After trauma to the teeth and associated alveolar bone

*Assessment of the presence and position of unerupted teeth

- Assessment of root morphology before extractions
- During endodontics
- Preoperative assessment and postoperative appraisal of apical surgery
- Detailed evaluation of apical cysts and other lesions within the alveolar bone
- Evaluation of implants postoperatively.

**Radiographic techniques**

The anatomy of the oral cavity does not always allow all these ideal positioning requirements to be satisfied. In an attempt to overcome the problems, two techniques for periapical radiography have been developed:

• The paralleling technique

• The bisecting angle technique.

**Paralleling technique**

**Theory**

1. The film packet is placed in a holder and positioned in the mouth **parallel** to the long axis of the tooth under investigation.

2. The X-ray tube head is then aimed at right angles (vertically and horizontally) to both the tooth and the film packet.

3. By using a film holder with fixed film packet and X-ray tubehead positions, the technique is reproducible.

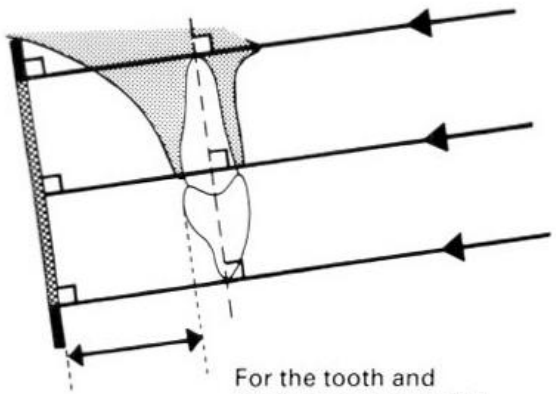

For the tooth and the film to be parallel they have to be positioned some distance apart

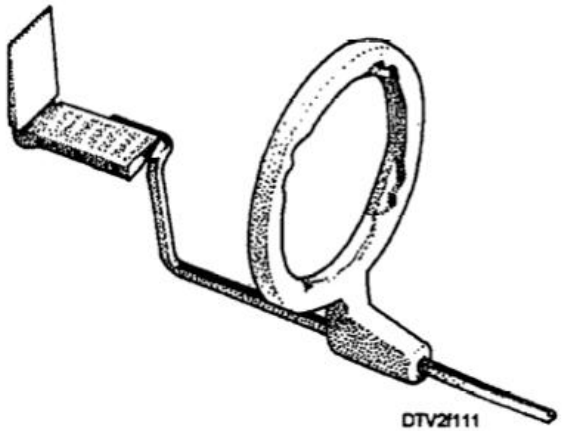


**Figure 1-11.—Assembled anterior paralleling device.**

The holder and film packet are placed in the mouth as follows:

**a.** ***Maxillary incisors and canines*** **�** the film packet is positioned sufficiently posteriorly to enable its height to be accommodated in the vault of the palate

**b.** ***Mandibular incisors and canines*** **�** the film packet is positioned in the floor of the mouth,approximately in line with the lower canines or first premolars

**c.** ***Maxillary premolars and molars*** **�** the film packet is placed in the midline of the palate, again to accommodate its height in the vault of the palate

**d.** ***Mandibular premolars and molars*** **�** the film packet is placed in the lingual sulcus next to the appropriate teeth.

## Bisecting angle technique

**Theory**

1. The film packet is placed as close to the tooth under investigation as possible without bending the packet.

2. The angle formed between the long axis of the tooth and the long axis of the film packet is assessed and mentally bisected.

3. The X-ray tube head is positioned at right angles to this bisecting line with the central ray of the X-ray beam aimed through the tooth apex.

4. Using the geometrical principle of similar triangles, the actual length of the tooth in the mouth will be equal to the length of the image of the tooth on the film.

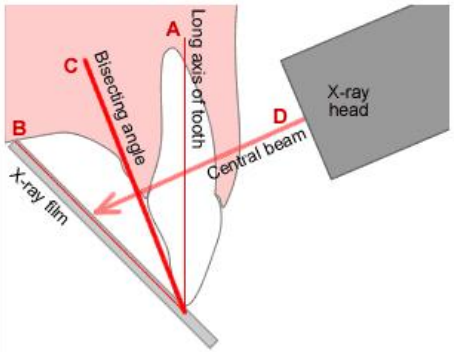

## Positioning difficulties often encountered in periapical radiography

Placing the film packet intraorally in the *textbook- described positions* is not always possible.The radiographic techniques described earlier often need to be modified.The main difficulties encountered involve:

- Mandibular third molars
- Gagging
- Endodontics
- Edentulous alveolar ridges
- Children
- Patients with disabilities

# Bitewing radiography

The main clinical indications include:

- Detection of dental caries
- Monitoring the progression of dental caries
- Assessment of existing restorations
- Assessment of the periodontal status.

# Positioning techniques

There are two main techniques available:

- Using a tab attached to the film packet and aligning the X-ray tube head by eye
- Using a film packet holder with beam-aiming device to facilitate the positioning and alignment of the X-ray tubehead.

## Ideal exposure factors

The clinical reasons for taking a bitewing radiograph should determine the exposure factors that are used, for example:

- *Assessment of caries and restorations* films should be well exposed and show good contrast to allow differentiation between enamel

and dentine and to allow the enamel – dentine junction (EDJ) to be seen.

– *Assessment of periodontal status* – films should be under-exposed to avoid ***burnout*** of the thin alveolar crestal bone.

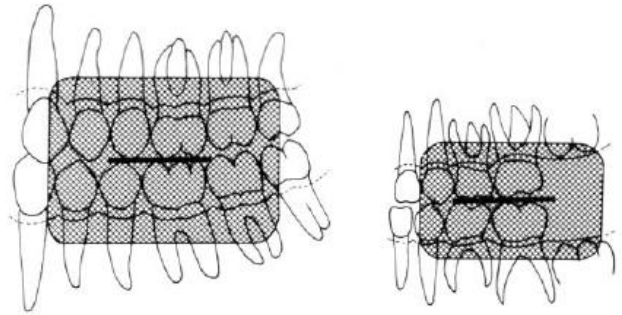

A Adult horizontal bitewing B Child horizontal bitewing

## Occlusal radiography

Occlusal radiography is defined as those intraoral radiographic techniques taken using a dental X-ray set where the film packet (5.7 x 7.6 cm) or a small intraoral cassette is placed in the occlusal plane.

### Maxillary occlusal projections

- Upper standard occlusal (standard occlusal)
- Upper oblique occlusal (oblique occlusal)
- Vertex occlusal (vertex occlusal).

## Mandibular occlusal projections

- Lower 90– occlusal (true occlusal)
- Lower 45 – occlusal (standard occlusal)
- Lower oblique occlusal (oblique occlusal)

#### Upper standard occlusal

The main clinical indications include:

- Periapical assessment of the upper anterior teeth, especially in children
- Detecting the presence of unerupted canines, supernumeraries and odontomes
- As the midline view, when using the parallax method for determining the bucco/palatal position of unerupted canines
- Evaluation of the size and extent of lesions such as cysts or tumours in the anterior maxilla
- Assessment of fractures of the anterior teeth and alveolar bone. It is especially useful in children following trauma because film placement is straightforward.



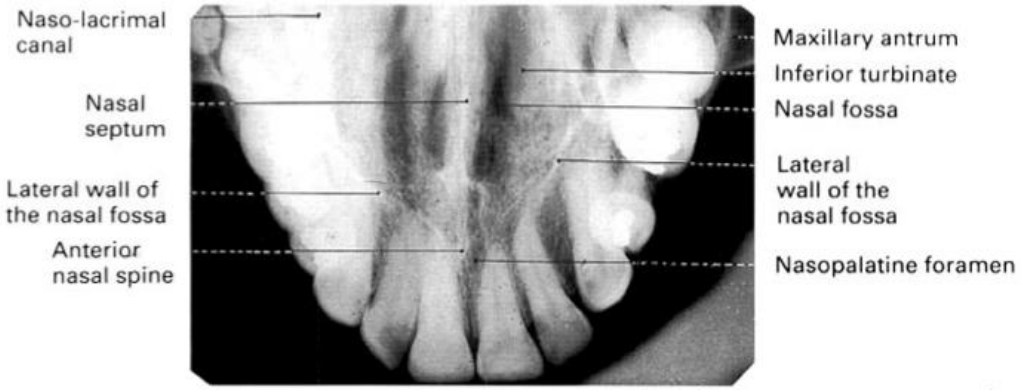


- The patient is seated with the head supported and with the occlusal plane horizontal and parallel to the floor and is asked to support a protective thyroid shield.
- The film packet, with the white (pebbly) surface facing uppermost, is placed flat into the mouth on to the occlusal surfaces of the lower teeth. The patient is asked to bite together gently. The film packet is placed centrally in the mouth with its long axis crossways in adults and anteroposteriorly in children.
- The X-ray tubehead is positioned above the patient in the midline, aiming downwards through the bridge of the nose at an angle of 65°-70° to the film packet

# Upper oblique occlusal

**Main clinical indications**

- Periapical assessment of the upper posterior teeth, especially in adults unable to tolerate periapical films
- Evaluation of the size and extent of lesions such as cysts, tumours or osteodystrophies affecting the posterior maxilla
- Assessment of the condition of the antral floor
- As an aid to determine the position of roots displaced inadvertently into the antrum during attempted extraction of upper posterior teeth
- Assessment of fractures of the posterior teeth and associated alveolar bone including the tuberosity.

The X-ray tubehead is positioned to the side of the patient's face, aiming downwards through the cheek at an angle of 65°-70° to the film, centring on the region of interest

**Note:** If the X-ray tubehead is positioned too far posteriorly, the shadow cast by the body of the zygoma will obscure the posterior teeth.

**Vertex occlusal**

To obtain this view the X-ray beam has to pass through a considerable amount of tissue, delivering a large dose of radiation to the patient.

**Main clinical indication**

° Assessment of the bucco/palatal position of unerupted canines.

The X-ray tubehead is positioned above the patient, in the midline, aiming downwards through the vertex of the skull. The main beam is therefore aimed approximately down the long axis of the root canals of the upper incisor teeth

**Disadvantages**

- There is a lack of detail and contrast on the film
- The primary X-ray beam may be in direct line with the reproductive organs.
- A relatively long exposure time
- There is direct radiation to the pituitary gland and the lens of the eye.
- If the X-ray beam is positioned too far anteriorly, superimposition of the shadow of the frontal bones may obscure the anterior part of the maxilla.

## Lower 90° occlusal

**Main clinical indications**

- Detection of the presence and position of radiopaque calculi in the submandibular salivary ducts
- Assessment of the bucco-lingual position of unerupted mandibular teeth
- Evaluation of the bucco-lingual expansion of the body of the mandible by cysts, tumours or osteodystrophies
- Assessment of displacement fractures of the anterior body of the mandible in the horizontal plane.

**Technique and positioning**

1. The film packet, with the white (pebbly) surface facing downwards, is placed centrally into the mouth, on to the occlusal surfaces of the lower teeth, with its long axis crossways. The patient is asked to bite together gently.

2. The patient *then* leans forwards and *then* tips the head backwards as far as is comfortable, where it is supported.

3. The X-ray tubehead, with circular collimator fitted, is placed below the patient's chin, in the midline, centring on an imaginary line joining the first molars, at an angle of 90° to the film




## Lower 45° occlusal

**Main clinical indications**

- Periapical assessment of the lower incisor teeth, especially useful in adults and children unable to tolerate periapical films
- Evaluation of the size and extent of lesions such as cysts or tumours affecting the anterior part of the mandible
- Assessment of displacement fractures of the anterior mandible in the vertical plane.



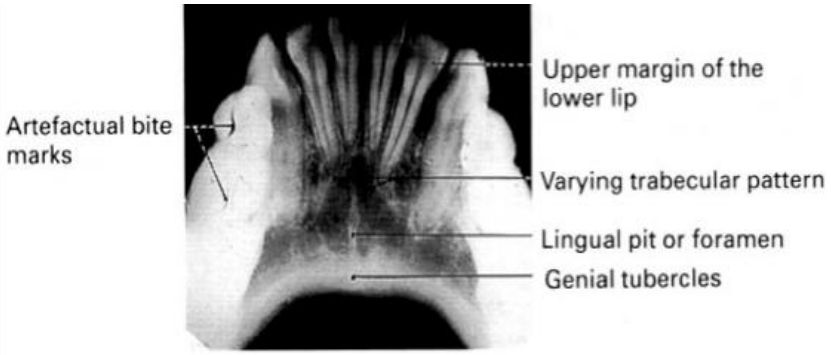


**Lower oblique occlusal**

**Main indications**

- Detection of radiopaque calculi in a submandibular salivary gland
- Assessment of the bucco-lingual position of unerupted lower wisdom teeth
- Evaluation of the extended expansion of cysts, tumours or osteodystrophies in the posterior part of the body and angle of the mandible.

**Oblique lateral radiography**

Oblique lateral radiographs are extraoral views of the jaws that can be taken using a dental X-ray set

Lateral radiographs of the head and jaws are divided into:

- True laterals- The film and the sagittal plane of the patient's head are parallel and the X-ray beam is perpendicular to both of them.
- Oblique laterals-The film and the sagittal plane of the patient's head are **not** parallel. The X-ray beam is aimed perpendicular to the film but is *oblique* to the sagittal plane of the patient.
- Bimolars (two oblique laterals on one film)- Bimolar is the term used for the radiographic projection showing oblique lateral views of the right and left sides of the jaws on the different halves of the **same** radiograph.

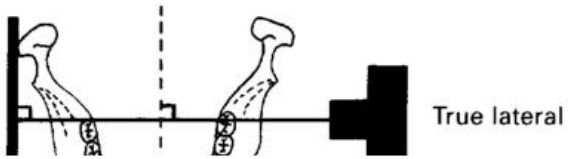

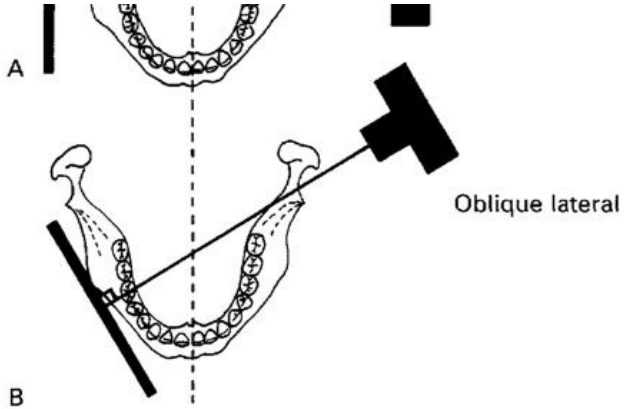


**Fig. 11.2** Diagrams showing what is meant by the terms *true* and *oblique* lateral.

**BIMOLAR XRAY**

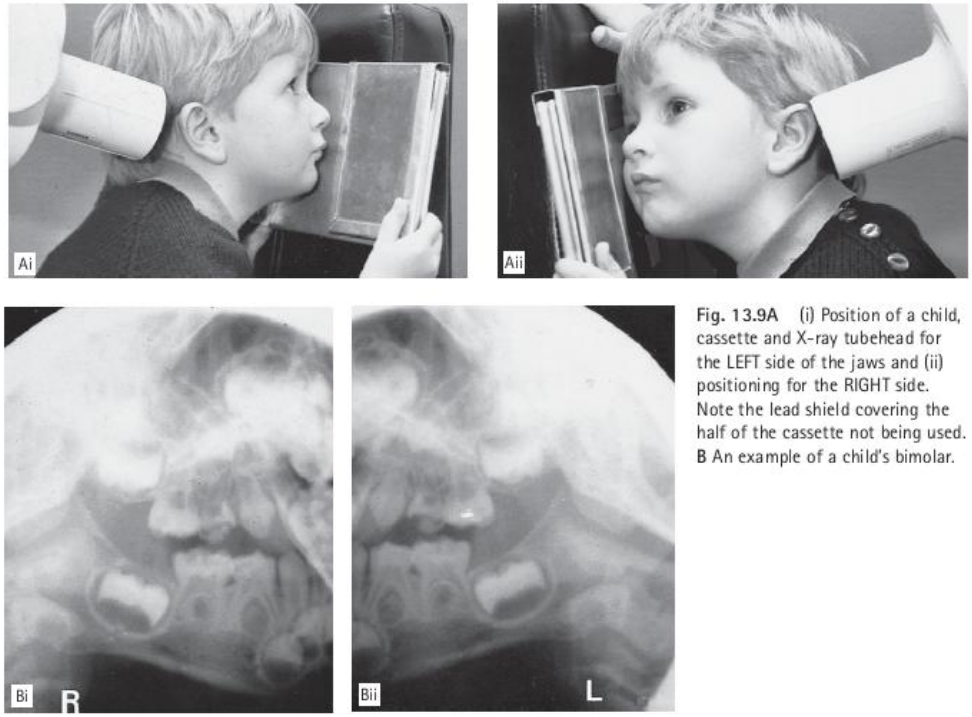


Fig. 13.9A (i) Position of a child, cassette and X-ray tubehead for the LEFT side of the jaws and (ii) positioning for the RIGHT side. Note the lead shield covering the half of the cassette not being used. B An example of a child's bimolar.

Main indications

- Assessment of the presence and/or position of unerupted teeth
- Detection of fractures of the mandible
- Evaluation of lesions or conditions affecting the jaws including cysts, tumours, giant cell lesions, and osteodystrophies
- As an alternative when intraoral views are unobtainable because of severe gagging or if the patient is unable to open the mouth or is unconscious

- As specific views of the salivary glands or temporomandibular joint.

**TABLE 11-1**
***Technical Aspects of Extraoral Radiographic Projections and Resultant Images***

| | Lateral Ceph | SMV | Waters | PA Ceph | Reverse Towne | Oblique Lateral Body | Oblique Lateral Ramus |
|---|---|---|---|---|---|---|---|
| Patient placement | Film parallel to midsagittal plane | Canthomeatal line parallel to film | Canthomeatal line at 37° with film | Canthomeatal line at 10° with film | Canthomeatal line at −30° with film | Film in contact with cheek at molar area | Film in contact with cheek at ramus area |
| Central beam | Beam perpendicular to film | Beam perpendicular to film | Beam perpendicular to film | Beam perpendicular to film | Beam perpendicular to film | Beam aims at the molar-premolar area | Beam aims at the ramus area |
| Diagram of patient placement |  | | | | | | |
| Illustration of patient placement |  | | | | | | |
| Skull view |  | | | | | | |
| Resultant image |  | | | | | | |

**Main maxillofacial/skull projections**

- Standard occipitomental (0◆OM)
- 30◆ occipitomental (30◆ OM)
- Postero anterior of the skull (PA skull) sometimes referred to as occipitofrontal (OF)
- Postero-anterior of the jaws (PA jaws)
- Reverse Towne's
- Rotated postero-anterior (rotated PA )
- True lateral skull
- Submento-vertex (SMV)

- Transcranial
- Transpharyngeal.

## Standardoccipitomental (0OM)

**Main indications**

- Investigation of the maxillary antra detecting the following middle third facial fractures:

  LeFort I

  Le Fort II

  Le Fort III

  Zygomatic complex

  Naso-ethmoidal complex

  Orbital blow-out

  Coronoid process fractures

- Investigation of the frontal and ethmoidal sinuses
- Investigation of the sphenoidal sinus (projection needs to be taken with the patient's mouth open).

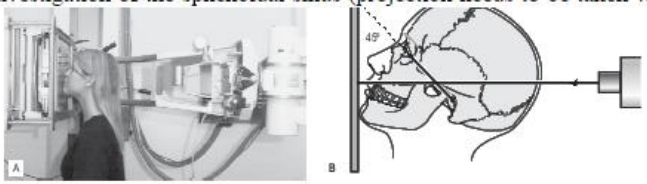


Fig. 14.5A Positioning for the standard OM projection – the patient is in the *nose–chin* position and the X-ray beam is horizontal. B Diagram of the positioning – the radiographic baseline is at 45° to the image receptor, and the X-ray beam is horizontal.






## 30° occipitomental (30° OM)

### Main indications

- Detecting the following middle third facial fractures:
  - LeFort I
  - Le Fort II
  - Le Fort III
- Coronoid process fractures.

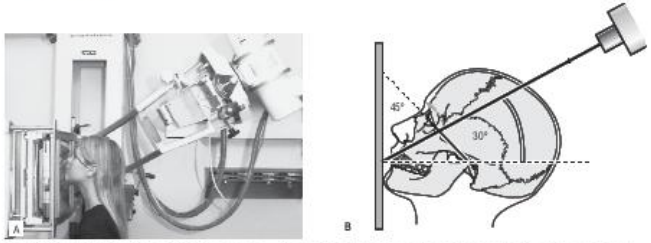


Fig. 14.7A Positioning for the 30° OM projection — the patient is in the *nose–chin* position and the X-ray beam is aimed downwards at 30°. B Diagram of the positioning — the radiographic baseline is at 45° to the image receptor, and the X-ray beam is aimed downwards at 30°.

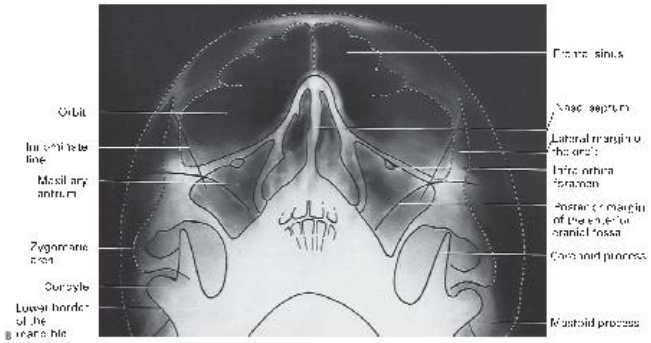


Fig. 14.8B The same radiograph with the major anatomical features drawn in.

## Postero-anterior of the skull (PA skull)

### Main indications

- Fractures of the skull vault
- Investigation of the frontal sinuses
- Conditions affecting the cranium, particularly:
  - Paget's disease
  - multiple myeloma
  - hyperparathyroidism
- Intracranial calcification.

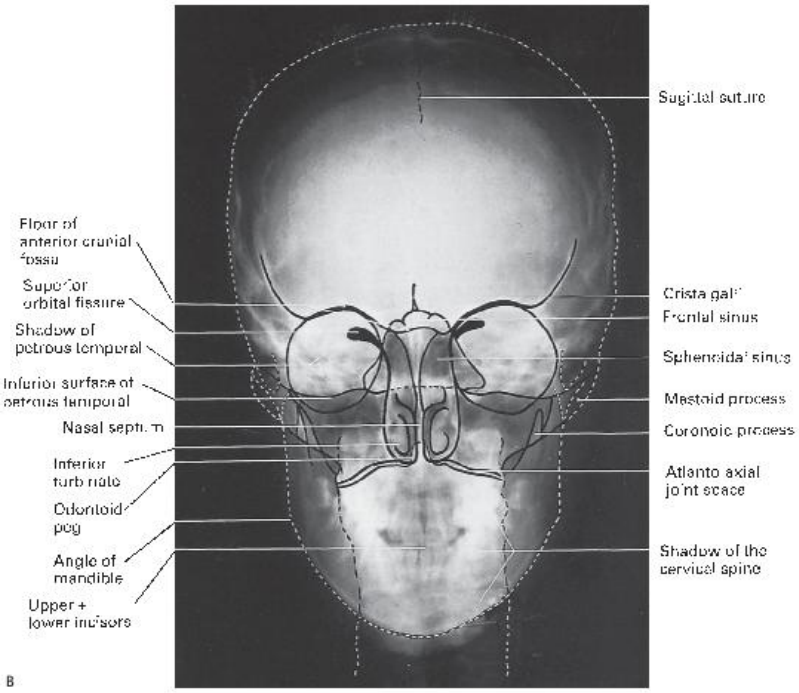


Fig. 14.10B The same radiograph with the major anatomical features drawn in.

**Postero-anterior of the jaws (PAjaws/PA mandible)**

**Main indications**

- Fractures of the mandible involving the following sites:
  - Posterior third of the body
  - Angles
    - Rami
    - Low condylar necks
- Lesions such as cysts or tumours in the posterior third of the body or rami to note any medio-lateral expansion
- Mandibular hypoplasia or hyperplasia
- Maxillofacial deformities.

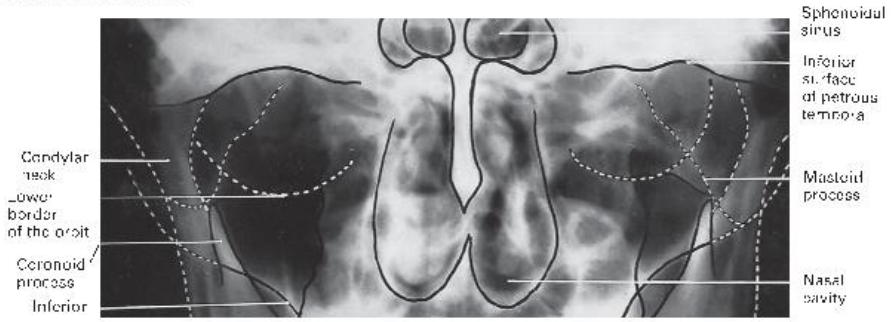

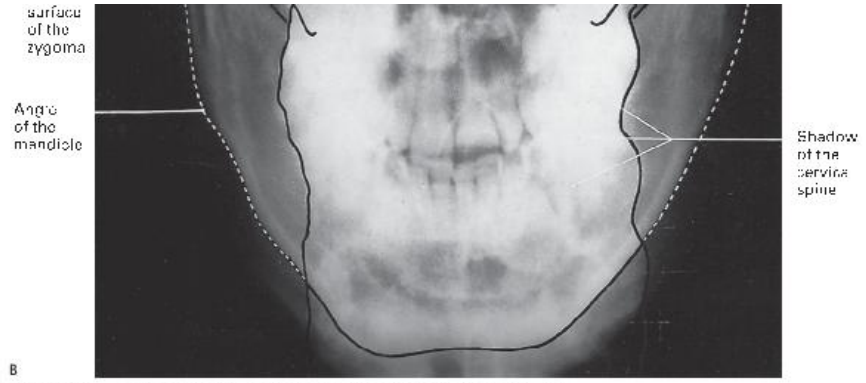


Fig. 14.12B The same radiograph with the major anatomical features drawn in.

**Reverse Towne's**

**Main indications**

- High fractures of the condylar necks
- Intracapsular fractures of the TMJ
- Investigation of the quality of the articular surfaces of the condylar heads in TMJ disorders
- Condylar hypoplasia or hyperplasia.

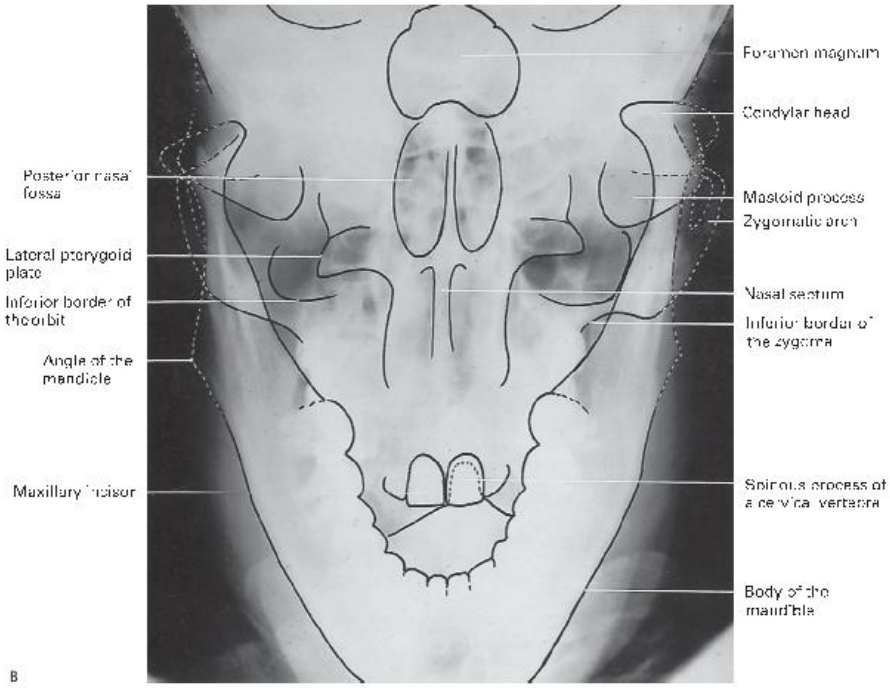


Fig. 14.14B The same radiograph with the major anatomical features drawn in.

## Rotated postero-anterior (Rotated PA)

**Main indications**

- Stones/calculi in the parotid glands
- Lesions such as cysts or tumours in the ramus to note any medio-lateral expansion
- Submasseteric infection  to note new bone formation.

B Diagrams of the positioning (i) from the side, normal head position and the X-ray beam horizontal, (ii) from above, 10° rotation of the head to the side of interest and the X-ray beam aimed along the side of the face.

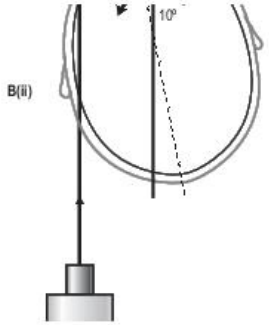


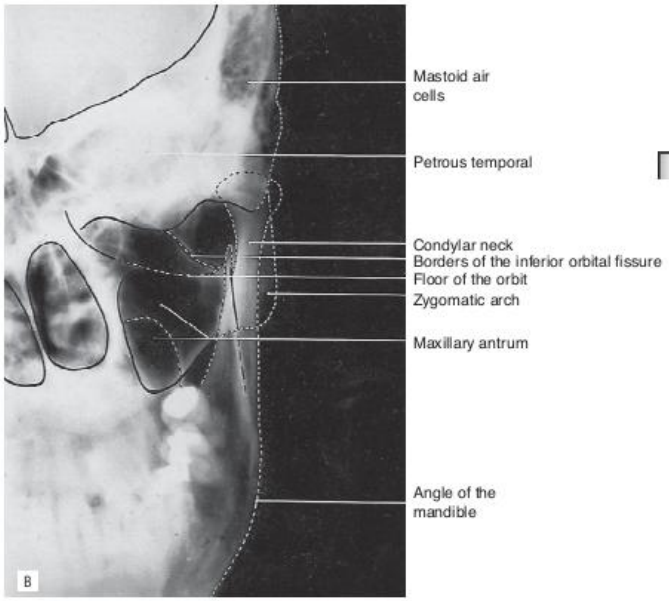


Fig. 14.16B The same radiograph with the major anatomical features drawn in.

## True lateral skull

**Main indications**

- Fractures of the cranium and the cranial base
- Middle third facial fractures, to show possible downward and backward displacement of the maxillae
- Investigation of the frontal, sphenoidal and maxillary sinuses
- Conditions affecting the skull vault, particularly:
  Paget's disease

  multiple myeloma

  Hyperparathyroidism
- Conditions affecting the sella turcica, such as:
  - tumour of the pituitary gland in acromegaly.



Fig. 14.18A An example of a true lateral skull radiograph.

### Submento-vertex (SMV)

**Main indications**

- Destructive/expansive lesions affecting the palate, pterygoid region or base of skull
- Investigation of the sphenoidal sinus
- Assessment of the thickness (medio-lateral) of the posterior part of the mandible before osteotomy
- Fracture of the zygomatic arches  to show these thin bones the SMV is taken with reduced exposure factors.



Fig. 14.20A An example of a well-exposed submentovertex radiograph.

# Dental panoramic tomography

***Dental panoramic tomography*** **has become a very popular radiographic technique in dentistry. The main reasons for this include:**

- All the teeth and their supporting structures are shown on one film
- The technique is reasonably simple
- The radiation dose is relatively low, particularly with modern DC units with rare-earth intensifying screens **?** the dose is equivalent to about **three to four periapical radiographs.**

The major drawback the image quality is inferior to that of intraoral (periapical and bitewing) radiographs and interpretation is more complicated.

In the **UK,** the *Selection Criteria in Dental Radiography* booklet recommends a dental panoramic tomograph (DPT) in general dental practice in the following circumstances:

- As part of an orthodontic assessment where there is a clinical need to know the state of the dentition and the presence/absence of teeth
- To assess bony lesions or an unerupted tooth that are too large to be demonstrated on intraoral films
- Prior to dental surgery under general anaesthesia
- As part of an assessment of periodontal bone support where there is pocketing greater than *5* mm
- Assessment of third molars, at a time when consideration needs to be given to whether they should be removed or not.

In addition, in dental hospitals DPTs are also used to assess:

- Fractures of all parts of the mandible except the anterior region
- Antral disease**?**particularly to the floor, posterior and medial walls of the antra
- Destructive diseases of the articular surfaces of theTMJ
- Vertical alveolar bone height as part of pre-implant planning.

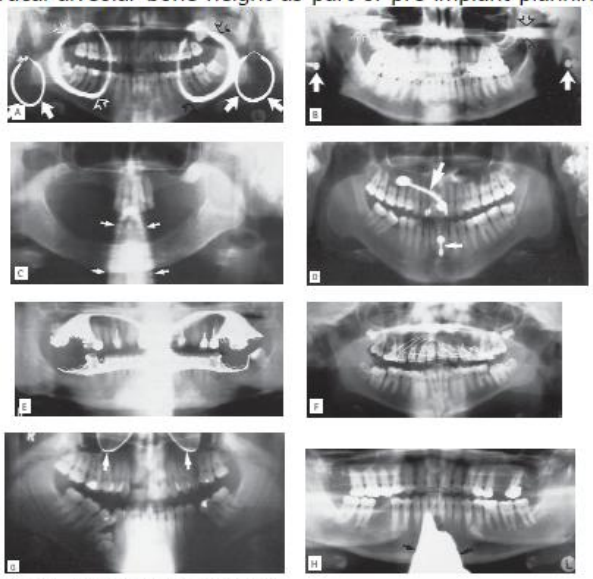

Fig. 17.24 Examples of common patient preparation errors.
A Failure to remove large ring-shaped earrings – note each earring casts two shadows, one real (in focus, solid arrows) and one ghost (blurred, open arrows). The ghost shadow of the LEFT earring is marked with white open arrows, that of the RIGHT earring with black open arrows.
B Failure to remove stud earring, real shadows (solid arrows) with ghost shadows (open arrows).
C Failure to remove a necklace – blurred ghost shadow (arrowed).
D Failure to remove piercing in the tongue (large arrow) and lower lip (small arrow).
E Failure to remove upper and lower metallic partial dentures.
F Failure to remove an upper orthodontic appliance.

G Failure to remove spectacles (arrowed).
H Inappropriate use of a protective lead apron – too high on the neck casting a dense radiopaque shadow (arrowed) over the anterior part of the mandible.

# CONE BEAM CT

Low dose cone beam CT technology has recently been developed specifically for use in the dental and maxillofacial regions and is rapidly establishing itself as the imaging modality of choice in many clinicaly situations. It is also referred to as digital volume tomography.

## DIFFERENT VIEWS OF CONE BEAM CT

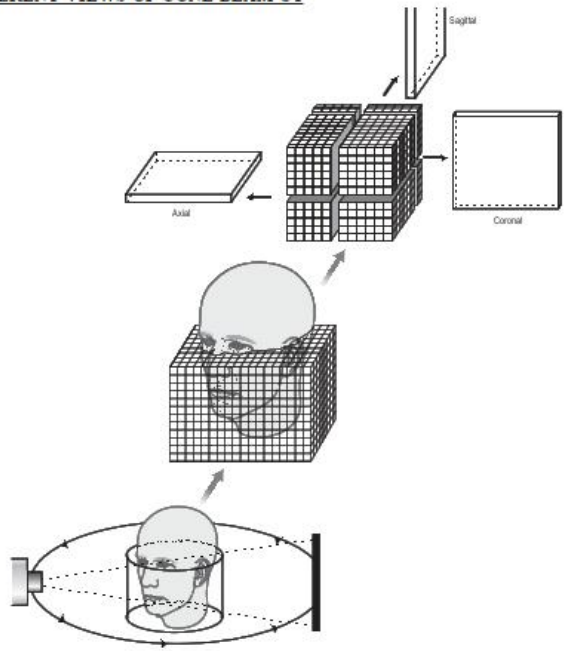


Fig. 19.9 Diagram showing the basic concept of cone beam CT. A cone-shaped X-ray beam is used which orbits once around the patient obtaining information in a cylindrical volume. The patient's maxillofacial skeleton is positioned within the cylinder and is divided up into tiny cubes or voxels. Computer manipulation (multiplanar reconstruction) of the data obtained allows separate images in the sagittal, coronal and axial planes to be created.



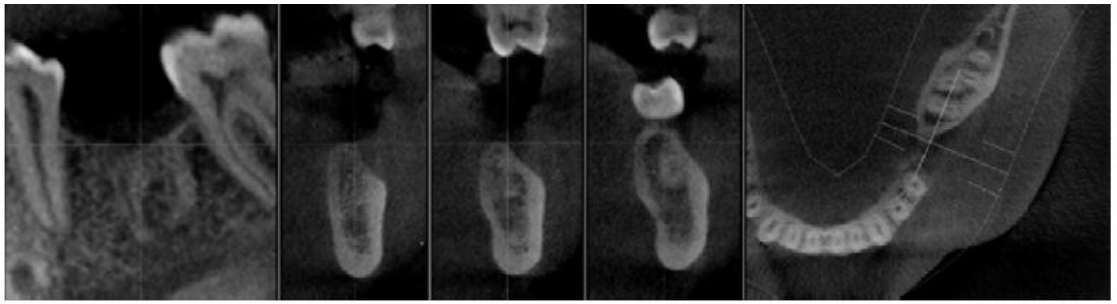

Fig. 19.12 An example of the Galileos (Sirona, Germany) monitor screen showing panoramic, three dimensional skull as well as sagittal, transaxial and axial images. (Kindly provided by Mr Jochen Kusch and siCAT).

**INDICATIONS:**

nvestigation of all conditions affecting the mandible or maxilla including cysts, tumours, giant cell lesions and osseous dysplasias

- Investigation of the maxillary antra

Investigation of the TMJ

- Implant assessment
- Orthodontic assessment
- Localization of unerupted teeth or odontomes
- Assessment of lower third molars and identification of the relationship with the ID canal
- Investigation of fractures of the mandible or middle third of the facial skeleton
- Multiplanar imaging of the teeth, periapical and periodontal tissues with the high resolution scanner.

**Advantages**

- Multi-plane imaging and manipulation allowing anatomy/pathological conditions to be viewed in different planes.

Low radiation dose.

- Very fast scanning time.
- Relatively inexpensive and affordable compared to medical CT.
- Compatible with implant and cephalometric planning software.

**Disadvantages**

- Patient has to remain absolutely stationary.
- Soft tissues not imaged in detail.
- Computer constructed panoramic images are not directly comparable with conventional panoramic radiographs  particular care is needed in their interpretation.
- Metallic objects, such as fillings, may produce streak or star artefacts as with medical CT.
- Facilities not yet widely available.

# Radiographic Faults

Table 15.1 Summary of common positioning errors in central panoramic tomography and the resulting faults on the film.

| Positioning error | Film Fault |
|---|---|
| Patient too far from the film | Anterior teeth magnified in width and out of focus |
| Patient too close to the film | Anterior teeth narrowed and out of focus |
| Patient positioned asymmetrically (head turned to left or right) | Posterior teeth enlarged on the side and reduced on the other |
| Patient chin positioned too high or too low | Distortion in the shape of the mandible and the anterior teeth out of focus |
| Patient still wearing earrings, jewellery, dentures or orthopedic appliance | Artefactual shadows of the offending object. |
| Failure to instruct the patient to keep still through the cycle | Vertical or horizontal distortion of the part of the image being produced at the time of the movement |

Operator positioning errors

## Typical positioning faults for Intraoral radiographic include:

1. Incorrect placement of the X-ray tube head producing:
   - Elongation
   - Foreshortening
   - Superimposition/overlapping
   - *Coning off* or *cone cutting*

1. Incorrect placement of the film packet:
   - Back to front, image of the lead foil evident (film also too pale)
   - Inadvertently used twice, double exposure (film also too dark)
   - Not covering the area of interest

| Reason for rejection | Possible causes | | Remedy to each particular fault |
|---|---|---|---|
| | General | Particular | |
| Film too dark | Processing fault (overdevelopment) | Developer concentration too high | Dilute or change chemicals |
| | | Development time too long | Adjust as necessary |
| | | Development temperature too high | Adjust as necessary |
| | Excessive X-ray | Incorrect exposure setting | Adjust and repeat examination |
| | | Faulty timer on X-ray | Arrange service and repair old X-ray set |
| | | Thin patient tissues | Decrease exposure and repeat |
| | Fogged film | Light leak in dark room | Check and correct |
| | | Faulty safe lighting | Inspect self light visually, coin test and correct any fault detected |
| | | Old film stock | Discard film |
| | | Poor film storage | Discard film and re-assess storage facilities |
| | | Light leak in cassette | Check hinges and catches and |

| | | | |
|---|---|---|---|
| | | | repair or replace if required |
| Film too pale | Processing fault (underdevelopment) | Overdiuted developer<br>Inaccurate development time<br>Developer temperature too low<br>Exhausted developer<br>Developer contaminated by fixer | Change chemicals<br>Adjust as necessary<br>Adjust as necessary<br>Change chemicals<br>Change chemicals |
| | Inadequate X-ray exposure | Incorrect timer settings<br>Faulty timer on X-ray set<br>Excessive thickness of patient tissues | Adjust and repeat<br>Arrange service and repair old X-ray set.<br>Increase exposure and repeat |
| Inadequate or low contrast | Technique error | Film back to front | Adjust and repeat |
| | Processing faults | Overdevelopment (plus dark films)<br>Underdevelopment (plus pale films)<br>Developer contaminated by fixer<br>Indicate fixation time (films opaque, milky sheen)<br>Fixer exhausted (films opaque, milky sheen) | Check development time / temperature relationship<br>As above<br>Change chemicals<br>Adjust as necessary<br>Change fixer solution |
| | Fogged film | See above | See above |
| Unsharp image | Technique error | Patient movement<br>Excessive bending of the film packet during exposure | Assess and instruct patient carefully<br>Adjust and repeat |
| | Technique error | Poor patient positioning (in panoramic radiography) | Greater care in positioning and full use of positioning aids |
| | Cassette error | Poor film/screen error<br>Incorrect intensifying screen speed | Check cassette and repair or replace if necessary<br>Change screens |
| | Excessive X-ray exposure | Incorrect exposure settings for thin object causing burn-out | Decrease exposure settings and repeat |
| Film marked | Handling fault | Film packet bend<br>Careless handling in dark room | Careful chemical handling<br>Check chemical tanks and adjust |
| | Processing faults | Chemical spots<br>Insufficient chemicals to allow full immersion of film<br>Automatic roller marks<br>Patient biting too hard on the film<br>Dirt on intensifying screens | Careful chemical handling<br>Check chemical tanks and adjust<br>Clean processor<br>Instruct patient correctly and repeat<br>Clean screens regularly |
| Poor positioning | Film pack incorrectly positioned | Film back to front (plus pale film)<br>Not covering area of interest<br>Film used twice (plus dark film) | Use film holders for intraoral radiography when possible<br>As above<br>Greater care in film handling |
| | X-ray tube-head incorrectly positioned | Too sleep and angle producing foreshortening<br>Too shallow an angle producing elongation | Use beam-aiming devices when possible<br>As above |
| | Patient incorrectly positioned | Patient incorrectly placed (In panoramic unit) | Greater care in positioning and full use of positioning aids |



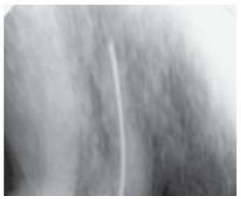

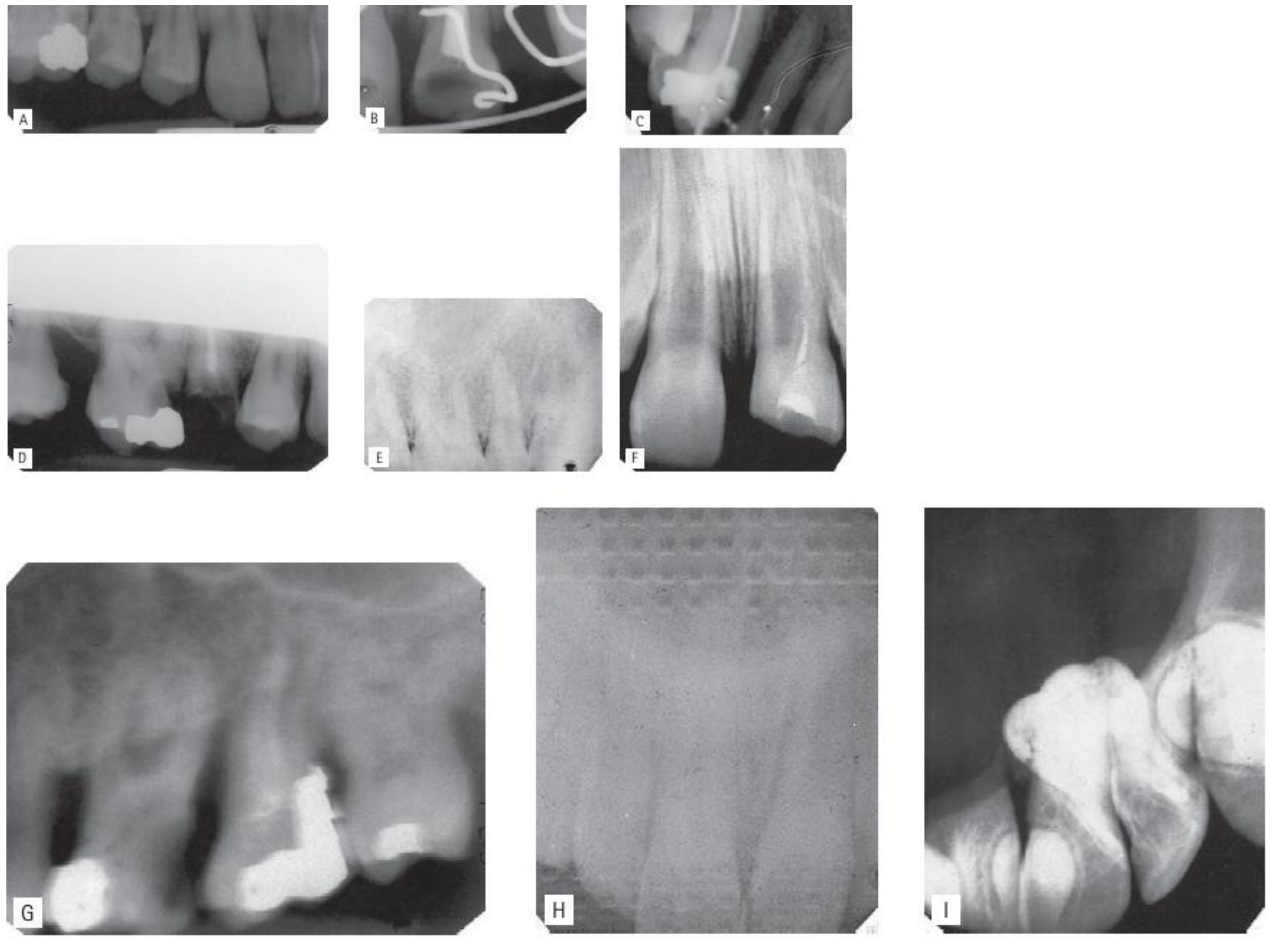


**Fig. 10.44** A selection of patient preparation and positioning (radiographic technique) errors.
**A** Image receptor not positioned sufficiently apically to cover the area of interest – apices and periapical tissues not shown.
**B** Failure to remove an orthodontic appliance.
**C** Image receptor positioned incorrectly and bent during exposure – image geometically distorted.
**D** Failure to align the X-ray tubehead correctly in the vertical plane – *coning off* of the superior part of the image.
**E** X-ray tubehead positioned at too steep an angle in the vertical plane – foreshortening and geometrical distortion of the image.
**F** X-ray tubehead positioned at too shallow an angle in the vertical plane – elongation and geometrical distortion of the image.
**G** Failure to instruct the patient to remain still – image blurred as a result of movement.
**H** Image receptor (film packet) incorrectly placed back to front – pattern of the lead foil is evident.
**I** Image receptor (film packet) inadvertently used twice – double exposure.

# Localization Techniques

- Use to locate the position of a tooth of object in the jaws
- X-ray is 2-dimentional image of 3-dimentional structure; does not show the depth of the structure.

-Buccal-Object Rule

**Buccal Object aka ﷺSLOB Ruleﷺ**

| | |
|---|---|
| S = SAME<br>L = LINGUAL | ﷺ If the structure or object seen in the second X-ray appears to move in the ***same*** direction as the reference object, item is positioned in the ***lingual*** |
| O = OPPOSITE<br>B = BUCCAL | ﷺ If the structure or object seen in the second move in the ***opposite*** direction as the reference object, item is positioned on the ***buccal*** |

**Same * Lingual**

**Opposite * Buccal**

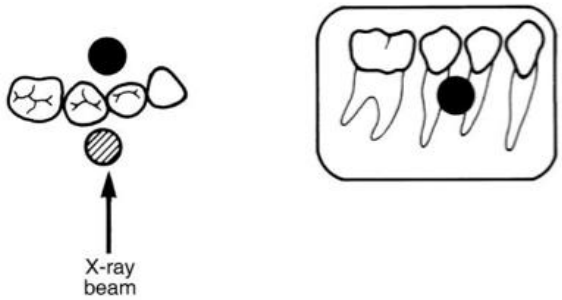


**A**

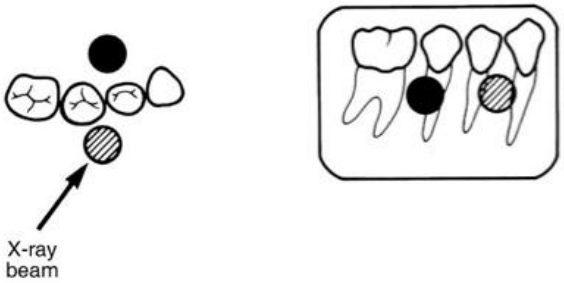

B

(Redrawn from Haring JI, Lind LJ: Radiographic interpretation for the dental hygienist, Philadelphia, 1993, Saunders.)

## SLOB Rule

- When two radiographs are compared, the object that lies to the l*ingual* appears to have moved in the same direction as the reference object, and the object that lies to the *buccal* appears to have moved to opposite direction as the reference object.

**XRAY REVIEWS FOR PATIENTS**

**high caries children- 6 months**

**moderate risk children- 12 months**

**low risk children- 12 to 18 months**

**high risk adults - 6 months**

**moderate risk adults- 12 months**

**low risk adults - 2 year interval**

**XRAYS FOR DIFFERENT BPE SCORES**

**0- 2- no xrays**

**3- bitewings**

**4 - IOPA**

**PRINCIPAL SOURCES AND FURTHER READING:**

-Selection Criteria for Dental Radiography -FGDP(UK) 3rd edition

-Eric Whites book on radiology

-Clinical Problem solving -Odell

-BDA advice sheet for radiology

-chapter 17 of Oxford handbook of clinical sciences

| | |
|---|---|
| Resource start date | 2014-09-18 16:44 |
| Resource end date | 2024-09-18 16:44 |

Back



Copyright © 2013 SamsonPLAB:All Rights Reserved Web Design Company Flick Media Ltd