samara University

College of medical and health science

Department of nursing

By Muhammad siraj

Learning objectives

At the end of this unit the students will be able to:

Discussions of Anatomy and physiology of the skin

Assessing a client with skin problem

Caring for a patient with inflammatory and allergic conditions of the skin Caring for a patient with bacterial skin infections

Caring for a patient with fungal skin infections

Caring for a patient with viral skin disease

Anatomy of the skin

- The skin is the largest organ of the body.
- It has three main parts (Layers). These are:-

  I. Epidermis (Epidermal layer) :- made of stratified squamous epithelium in four sub layers.

  - it also contains specialized cells like keratinocytes, melanocytes, langerhan cells, and dendritic cells(merkel cell)…

Cont…

II. Dermis (Dermal layer) :-has two parts, papillary dermis and reticular dermis.

- it contains sebaceous gland, sweat gland, hair follicule, and neurovascular structures.

III. Subcutaneous tissue

- Beneath the dermis is a subcutaneous (subQ) layer (also called hypodermis) which attaches the skine to underlying tissue and organs.

Epidermis

1. Stratum basale
2. Stratum spinosum
3. Stratum granulosum
4. Stratum lucidum:- the only thick skines
5. Stratum corneum

Dermis

Papillary layer

Reticular layer

Cont...

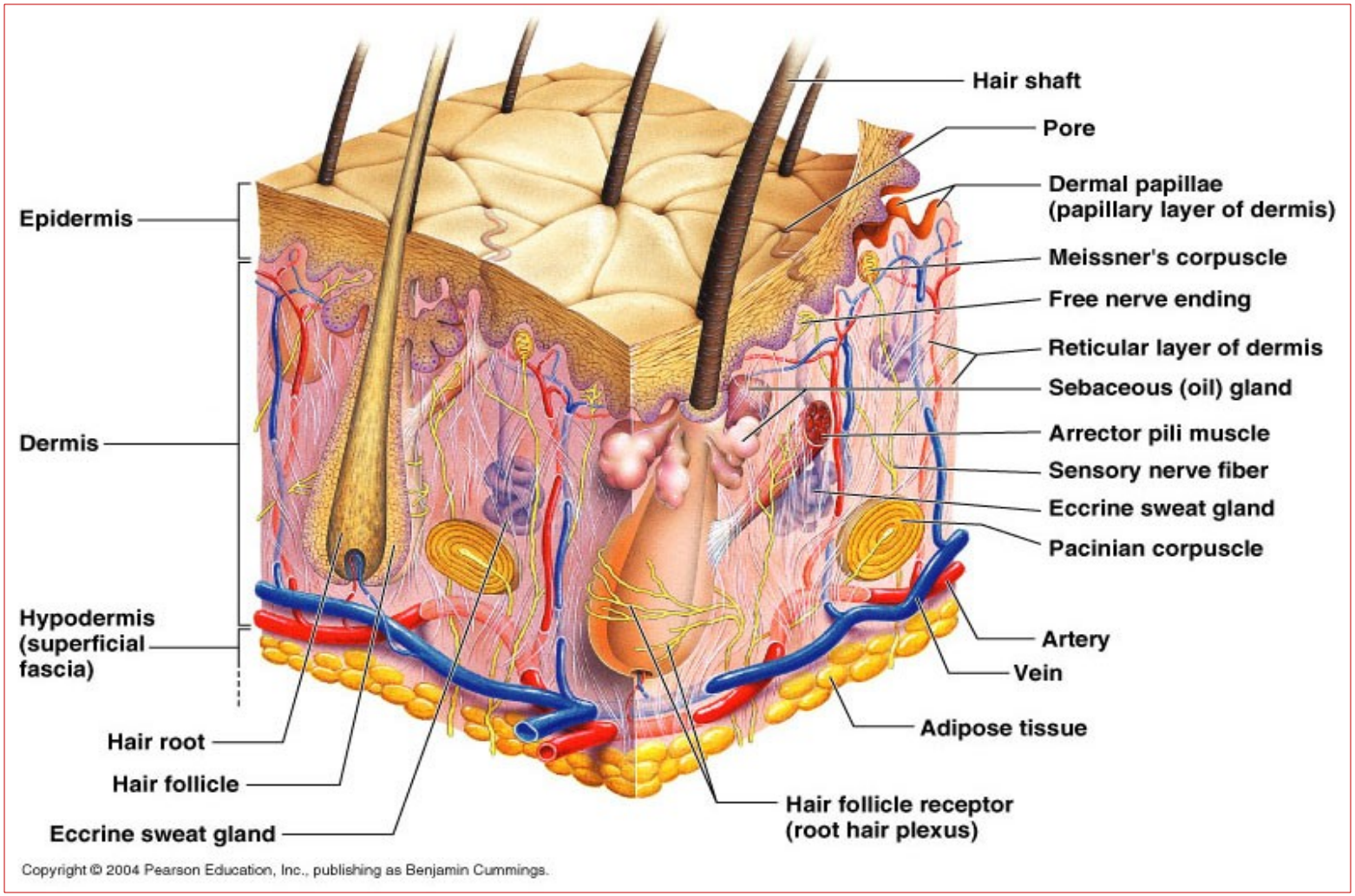
Hair shaft
Pore
Dermal papillae
(papillary layer of dermis)
Meissner's corpuscle
Free nerve ending
Reticular layer of dermis
Sebaceous (oil) gland
Arrector pili muscle
Sensory nerve fiber
Eccrine sweat gland
Pacinian corpuscle
Artery
Vein
Adipose tissue
Hair follicle receptor
(root hair plexus)
Epidermis
Dermis
Hypodermis
(superficial
fascia)
Hair root
Hair follicle
Eccrine sweat gland
Copyright © 2004 Pearson Education, Inc., publishing as Benjamin Cummings.

Physiological functions of skin

- Regulates body temperature.
- Prevents loss of essential body fluids, and penetration of toxic substances.
- Protection of the body from harmful effects of the sun and radiation.
- Excretes toxic substances with sweat.

Cont…

- Immunological function mediated by Langerhans cells ,and mechanical support.
- Sensory organ for touch, heat, cold, socio-sexual and emotional sensations.
- Vitamin D synthesis from its precursors under the effect of sunlight and introversion of steroids.

Physical Assessment

Inspection and palpation constitute the chief procedures in examining the skin

The room be well lighted and warm

General appearance of skin

Include an assessment of Color, redness, temperature, Texture, the presence of edema

Cont…

Inspection

I. the color of the skin

a. Pallor

Causes

Temporary loss of Hgb(a red protein containing iron responsible for transporting oxygen in the blood of vertebrates.)

Persistent anemia , vasoconstriction

b. Redness

Causes

Fever , inflammation , flushing , sun burn , over heating, extreme exertion

c. Cyanosis: bluish discoloration of the skin and mucus membrane due to poor circulation or inadequate oxygenation of the blood.

Can be central/peripheral

Central - lips , oral mucosa , finger nail

Peripheral - hand , feet

Cont…

d . Jaundice - yellowish discoloration of skin and mucus membrane.

Can be seen over Sclera, palpebral conjunctiva, lips, dorsum of tongue and skin

Cont…

May results from

Destruction of RBC--excessive bilirubin in the b/d

Liver disease

e. Caratenemia

Yellow discoloration over the palm but not conjunctiva

f. Pigmentation

Hypo pigmentation - scar

dispigmentation-loss of skin color e.g. vitiligo(whitish patches)

Hyper pigmentation – chloasms(large brown patches)

Cont…

Lesion:

Location : Flexor /extensor, exposed area / hidden area

distribution : localized / generalize, Symmetrical / asymmetrical ,

Arrangement : linear, clustered , annular(ring shaped) , aciform(needle shaped)

ii. Lesions and Rash

Rashes – are temporary eruptions of the skin, such as these associated with childhood disease, heat rash diaper rash, or drug- induced eruptions.

Lesion- usually refers to a traumatic or pathologic less of normal tissue continuity structure, or function.

Cont…

- Rashes and lesions may range in diameter from fraction of a millimeter (as in petechae) to many centimeters (as in decubitus ulcer, or pressure ulcer). They may be blanched (white), redden (erythematous), hemorrhagic or purpuric (blood containing),

Types of skin lesion

Skin lesion can be described as primary lesion or secondary lesion.

I. Primary lesions

Primary lesions occur in previously normal skin and they are the characteristics of the disease itself. Primary lesions can be classified as follows

1. circumscribed, flat , no palpable lesion

Result from changes in color of skin

Include:

Macula – small, less than 5 mm in diameter discoloration of the skin e.g. Freckle, petechiea

Cont…

Patch – larger than 5 mm in diameter. E.g. – vitiligo

2. **Palpable, elevated, solid masses**

Plaque – A flat, elevated surface larger than 0.5cm, often formed by the coalescence of pa

pule. e.g. - psoriasis, tenia capties.

Nodule -0.5 – 2cm often deeper and firmer than papule, growth of tissue is usually in the form of swelling .

Cont…

Tumor – larger than 2 cm

Wheal – A somewhat irregular, relatively transient, superficial area of localized skin edema. E.g. Mosquito bite, hive

3. Fluid - filledCircumscribed superficial elevations of the skin

Formed by accumulation of fluid in a cavity within the skin layers. Include

Vesicles –up to 0.5cm, filled with serous fluid – e.g. Herpes simplex

Cont…

Cyst - a tumor that contain semisolid or liquid materials. e.g. Sebaceous cyst

Bulla – greater than 0.5 cm filled with serous fluid e.g. 2nd degree burn

Pustule- filled with pus. E.g., acne, impetigo, carbuncle

II .Secondary lesions

Result from changes in primary lesions or may occur from external causes like in case of trauma. Secondary lesions have the following forms

Loss of skin surface

Erosion – loss of the superficial epidermis. E.g. moist are after rapture of a vesicle as in chickenpox

Ulcer- A deeper loss of skin surface may bleed and scar. E.g. - stasis ulcer of venous insufficiency ,syphilitic chancre

Cont…

Fissure – A linear crack in the skin. E.g. - Athlete’s foot, anorectal fissure

Material on the skin

Crust – the dried residue of serum, pus or blood

Scale – A thin flakes of exfoliated (dead layers) epidermis. E.g. - dandruff, psoriasis

Dermatitis

Dermatitis is inflammation of skin caused by inappropriate and often harmful **response of the immune system to foreign body** when if comes in contact or introduced to the body.

Etiology: - allergenic substances (dust, pollen)

Chemicals, sun, certain drugs, foods

Pathophysiology

- Most allergens (trigger factors) substance induce either type one reaction or type four reaction of hypersensitivity

Cont…

Type - 1 reaction

is an immediate and the reaction begins with in minutes of exposure to an antigen

mediated by IgE (antibody)

Previous exposure IgE Produced re-exposure Ag A b Complex activate cellular reaction chemical mediators released

Activate nutrophillis, microphages, Lysozome Enzymes and results in **tissue damage**

Con….

Type - IV (delayed Hypersensitivity)

occurs in **24/72 hrs after exposure** to an allergen

mediated by sensitized T cells and macrophages

an example of this reaction is the effect of tubercle antigen or **(PPD)**

Contact dermatitis results from exposure to allergen such as cosmetics , Topical drugs

Previous exposure T- cells sensitized re-exposure to the same antigen the sensitized T cells release lympokines stimulate macrophages lysozyme released by macrophages **Damage to the surrounding tissue**

Con...

Sign and symptoms

- itching , burning , erythematic , skin lesions (vesicles) , edema followed by weeping, crusting and finally drying up and peeling of the skin .

Types of dermatitis

1. Contact dermatitis
2. Atopic dermatitis
3. Seborrhcic dermatitis
4. Nummular dermatitis
5. Stasis dermatitis

1. Contact dermatitis

Cause: external agents

Allergens**:**



- Synthetics
- Industrial chemicals
- Drugs e.g. Sulfanilamide penicillin
- Metals (especially nickel and chromate)

Irritant :

Chemicals: acids alkalis solvents detergents and oils

Mechanical: wool or glass fibers

Biological: urine, feces, and toxins from insects or aquatic plants

Cont…

Characteristics

Site and pattern of lesions depend on exposure pattern e.g. Linear, angular

Itaching is a major symptom

Dx: clinical

Mgt

Weeping vesicular lesions are treated with **aluminum acetate** (dameboro soak) applied 1-2 times a day

Topical corticosteroids (mild to potent range) are applied to the affected site 2 times/ day for approximately 2 weeks

2. Atopic dermatitis

Cause

Hypersensitivity reaction, **hereditary**

Exacerbating factors

- Sudden changes in climate (temp or humidity)
- Exercise
- Psychological stress
- Fibers wool, nylon, fur
- Detergents
- Perfume





Cont…

Characteristics

Itching is a major symptoms

Lesions caused by scratching

Occurs early during childhood and resolve or become less severe during 2-3 years old ages

Most pts have history of a topic disease like ***asthma, rhinitis and hay fever, and FHx of topic diseases.***

Dx: clinical

Mgt

Topical corticosteroids

Systemic therapy for sever form of the problem

Systemic antihistamines at night when itching is more intense

Pt education

3. Seborrhcic dermatitis

- **Seborrheic dermatitis** is a common, chronic disorder, characterized by greasy scales overlying.
- The most common location is in the scalp where it may be recognized as severe dandruff and On the face, **seborrheic dermatitis** affects the eyebrows, eyelids, glabellas, and naso labial folds. Scaling of the external auditory canal is common in seborrheic dermatitis.

Cont..

Cause:

The cause is unknown but **overgrowth of yeast** organisms (pitrisporum orbicular) on the skin likely with genetic and environmental influences is st stulated





Cont…

Characteristics

Commonly occurs at the **hairy areas**: scalp, eyebrows, face, central chest, and sometimes genital skin folds

Symptoms often **worse in the winter** months

Inflammatory changes produce the characteristics symptoms of redness and greasy scales.(E.g. Dandruff)

FHx may be found

Dx: clinical

Cont…

Mgt

Severe to moderate scalp seborrhea derma it is treated with

- Tar
- Selenium
- zinc

Ketokenazole shampoo Apply twice weekly for 2- 4 wks

More significant scalp involvement may require topical corticosteroids

Facial areas are treated with low potency topical corticosteroids/ topical antifungal agents.

4. Nummular dermatitis

Cause- unknown

Characteristics

Lesion are characteristically **4-10 cm**, erythematous and coin shaped

Itching may be severe

Commonly affect the **dorsum of the hand and the extensor surface** of the lower extremities

Cont…

Dx: clinical

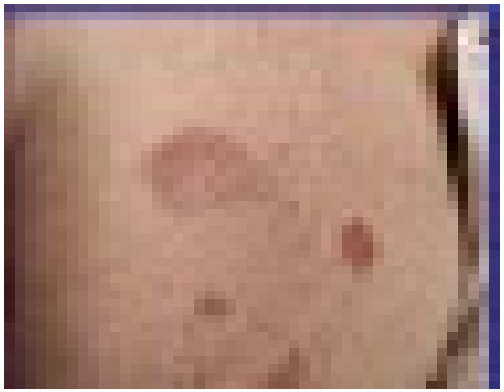

Mgt

Hydrating skin with moisturizing lotions

Topical corticosteroids

Tar products

5. Stasis dermatitis

Cause: Altered circulation

C/m

- Brawny skin discoloration
- Edema
- Itching may or may not occur
- Lesions may develop form trauma/ scratching

Dx: clinical

Mgt

Prevention of constriction of circulation to the extremities

Treating edema with elevation, compression stocking

Topical corticosteroids for eczematous changes

Domeboro soaks for weeping lesions.

Cont…

Supporting managements for dermatitis

avoid offending (probable cause) materials

cool water compress

Nursing Responsibility

assess and manage a patient with dermatitis

focus on education

act on preventing and decreasing the reaction process

Promoting public awareness about allergies is a key nursing goal in facilitating early and accurate Dx

Cont…

Dx: clinical

Mgt

Prevention of constriction of circulation to the extremities

Treating edema with elevation, compression stocking

Topical corticosteroids for eczematous changes

Domeboro soaks for weeping lesions.

Hydrating skin with moisturizing lotions

Ketokenazole shampoo Apply twice weekly for 2- 4 wks

Supporting managements for dermatitis

avoid offending (probable cause) materials

cool water compress

Cont…

Nursing Responsibility

assess and manage a patient with dermatitis

focus on education

act on preventing and decreasing the reaction process

Promoting public awareness about allergies is a key nursing goal in facilitating early and accurate Dx

Giving nursing care for patient with acne

Define - is a common **follicular disorder** affecting susceptible sebaceous gland (a small gland in the skin which secrets a lubricating oily matter ‘sebum’ into hair follicles to lubricate the skin and hair) most commonly found on face, neck and upper trunk.

- It is a self limited disorder
- Primarily affects teenagers and young adults, it affects an estimated 85% of the pop ^{n} b/n 12 & 35 yrs old, more marked at puberty & during adolescence

Etiology

appears to be multiple reflecting an interplay of genetic , hormonal and bacteria's factors.

Classification of acne

Grade - I - Non inflammatory acne -- open and closed comedones (white heads /blackhead).
Grade - II - early inflammatory acne -- Presence of comedones and papules (obstructed follicles).
Grade III- Moderate localized inflammatory acne **--** Pustules or larger more inflamed papules.
Grade IV -Sever more generalized acne **--** Cystic, nodular lesions.



Acne

PATHOGENESIS

During childhood, the sebaceous glands are small and virtually non-functioning.

During puberty, androgen stimulates sebaceous gland, causing them to enlarge and to secrete a natural oil, sebum.

There by sebum released by sebaceous gland blocking of the follicular orifice by retention of sebum and keratinous materials form small cyst called comedones.

Presence of lipophlic yeasts and bacteria with in the comedowns release free fatty acid from sebum and cause inflammation within the cyst.

Rupture of the cyst Cause inflammatory foresight body reaction.

Clinical manifestations

Comedones - the initial lesion of acne

- **Closed Comedones** (white heads) are obstructive lesions formed from impacted lipids or oils and keratin that plug the dilated follicles
  - Are the precursors of inflammatory lesion of acnes?
  - May evolve in to open Comedones
  - Contents are not easily expresses
- **Open Comedones** -
  - Are termed as black heads
  - The colour of black head is due to the accumulation of lipid , bacteria ,and epithelial debris

Medical Management

Topical Therapy

Benzyl peroxide

have anti bacterial effect

Depress sebum production

2.5 - 5% Gel once daily at bed time

Vitamin A acid

used to clear the keratin plugs from pilosebaceous duct

speed up cellular turn over

forces out comedones

Prevents occurrence of new comedones

Cont…

Topical ABTS

Suppress the growth of bacteria (propionobacterium acne)

Decrease comedones , papules , pustules

Topical preparations containing clindamycin, erythromycin , meclocycline , or TTC hydrochloride

Cont…

Surgical mgt

incision and drainage

extraction of comedone content

cryotherapy (cold)

Dermabrasion (removal of superficial layer of skin with abrasive tool.

Nursing intervention

patient education on home health care

Development of self acceptance

Acne rosacea

Is an inflammatory disorder predominantly affecting the central face.

Is a follicular eruption of the skin with both a vascular and acne component

It affects 30 to 50 years olds, women more than men, but men tends to have more severe manifestations

Etiology

The cause is unknown

Risk factors / predisposing factors

Familial predisposition

Poor health status

Triggering factors

Heat

Cold

Wind

Sunlight

Spicy foods

Alcohol





Clinical features

Begins with erythema over the central face, cheeks and nose

Flushing and blushing are classic symptom

Papules, pustules, cysts, telangectasias(dialation of capillaries) ensues

If prolonged leads to rninophyma (irregular, bulbous thickening of the skin of the distal part of the nose)

Cont..

Dx: clinical

Mgt

Topical/ oral antibiotics for severe and moderate problem

Laser surgery for telangectasias and rhinophyma

Patient/ Family education on

The disease and its treatment

Triggers and their avoidance

Avoidance of alcohol based products

Caring for a patient with psoriasis

psoriasis Is a chronic non infections inflammatory disease of the skin in which the production of epidermal cells occurs at a rate that is approximately six to nine times faster than normal.





© Elsevier 2004. Habif: Clinical Dermatology 4E - www.clinderm.com

Psoriasis

Cont…

Etiology

appears to be a **hereditary** defect that cause over production of keratin(a fibrous protein forming the main stractural constituent of hair, feathers.)

the primary defect is unknown

trigger factors

Specific genetic make up + environmental stimuli

Hormonal changes , stress , seasonal changes

Occur at any age but common b/n 10- 40

PATH PHYSIOLOGY

Rapid division of cells in the basal lager of the skin

Newly formed cells move so rapidly to the skin surface (epidermal tissue)

Profuse scales or plaques become evident at epidermal tissue of the skin

The psoriatic epidermal cell may travel to the stratum corneum skin surface) and cast of in 3 to 4 days (normal 26-28 days)

Prevent normal events of cell maturation and growth

- Prevent formation of the normal protective layer of the skin

Medical management

- **Topical.**
- **Intralesional therapy**
- **Systemic therapy**
- **Oral retinoid**

NSG interventions

- Develop self - acceptance
- administer antibacterial agents as prescribed
- Apply warm soaks to ease discomfort
- Teach the patient about the case

providing nursing care for a patient with eczema

Eczema is an **intense inflammation of layers of epidermis** in which case the ulcer extends deeper in to the dermis thus discharging pus usually stained with blood

Etiology: S cocci. For infected ty



Eczema

Types

1. **Infantile Eczema** - is a clinical manifestation of atopic dermatitis during infancy. Consist of severely itchy, erythematic papular or papule - vesicular lesions w/c appears **bilaterally on the checks** and spread to other parts of the body
2. **Nummular Eczema** - consisting of recurrent eruptions of itchy, papule - vesicular lesion which are grouped in to **discoid patches** and are located almost symmetrically on the extensor aspects of the **upper and the lower extremities.**

.

Cont…

Secondary infection is common with phyogenic(pus producing) organisms

common in children & young adults

some patients suffer from recreant attacks of asthma

3. Eczema vaccinatum - if atopic children are given **small pox vaccination** when they are having active disease there is risk of **generalized eruption** called eczema vaccinatum

Cont…

Diagnosis: Achieved by full History taking and physical examination (clinical)

Management – antibiotics(systemic) are used if it drains pus

- Oral penicillin (Ampicilin , amoxicillin)
- Cloxacilin or clindamycine

Caring for a patient with bacterial skin infections

giving nursing care for a patient with follicular disorders

1. **Folliculitis**

Definition: Folliculitis is a postural **swelling in the hair follicle** caused by infection, chemical, irritation or trauma. **S. aurous** are the most common gram negative bacteria causing the infection.

G-ve bacteria such a pseudomonas can infect patients receiving long term antibiotics or those who use hot tub.

Predisposing factors

Chronic illness

Mechanical irritation

Hot tub use

Infection in close contact



Folliculitis

Clinical manifestation

Lesions may be superficial or deep. Deeper form of lesions produces a more severe inflammation.

Single or multiple papules or pustules appear close to the hair follicles

Commonly seen in beard area of men who shaved and on women’s legs. Other areas include axillae, trunk, and buttock.

Management

Non drug treatment

-The initial treatment is to avoid shaving. If this is not possible, a hand brush may be used to dislodge the hair mechanically

-Aggressive hygiene with antimicrobial cleanser and soaps

Thorough cleansing with antibacterial soap and water twice daily

Drug treatment

Topical

Mupirocin 2% in 15gm pack 2-3x/day 7-10 days

Systemic

First line

Cloxacillin, 500mg po gld for 7-10 days children 50-100 mg/kg/day in and divided doses for 7-10 days

Alternative

Erythromycin 250 – 500mg po fid for 10 days children 30-50mg/Kg/day in and divided doses for 7-10 days

2. Furuncles/ boils

it is infection of hair follicle that **involve the dermis**. It is an extension form of Folliculitis.

A painful and indurate swelling appears which gradually extends. After two days the center softens discharging pus and in majoring of cases the condition then subsides.

Boils are most common on the back of the neck associated with over work, worry, debility

E.g. - Sty on the eye (an inflamed swelling on the edge of an eyelid)

Perineal abscess

External auditory miatus (no space for pus accumulation so become pain full)

Cont…

Diagnosis: Clinical (Hx + P/E)

Medical management

oral cloxalillin , flucloxacillin - 1st line drugs

cephalosporin and erythromycin are also effective

Supportive management

improve the general health of the patient

washing the surrounding skin twice a day with suitable disinfectant

bed rest is advised for a patient who have boils on the perineum or in the anal region

Special precautions must be taken with boils on the face b/c the skin area drains directly in to cranial venues sinuses. Sinus thrombosis with total pyemia has been known.

3. Carbuncle

A subcutaneous abscess usually formed by a confluent infection of **multiple hair follicles.**

Etiology staphylococcus is the most frequent causative microorganism.

Clinical manifestation

Similar to that of boil

fluctuant mass

edema

Common at the back of the neck

Cont…

Diagnosis Clinical

Medical management

similar to that of boils

Penicillin

drainage of abscess

Treatment of abscess is always by incision and drainage

Impetigo

Impetigo is a superficial skin infection with staphylococci, streptococci or both .

It is highly infectious and usually affects children. Impetigo is characterised by blisters that rupture and coalesce to become covered with a honey-coloured crust.

Treatment is directed at washing the affected areas
and applying topical anti-staphyloccocal treatments, and broad spectrum
oral antibiotics if streptococcal infection is implicated



giving nursing care for a patient with fungal skin infection(mycosis).

mycosis is infestation of fungus.

Etiology - Dermatophytes

- live on keratinous structures
- infect the epidermis (stratum corneum only) , the hair and the nails.
- Dermatophytes responsible for human infection belongs to three genera

1. Microspores
2. Trichophyton
3. Epidermophyton

Cont...

Some of these dermatophytes live only on the **humans (antrophillic)**; others infect mainly some pet animals, doges, cats, horses **(Zoophiles);** and few dermatophytes live in the **soil (geophilc).**

Thus man can get the infection, either from other infected Individuals or animals or from the soil

Types of mycosis

1. Ring worm of the feet (athlete's feet) tinea pedis)
2. Ring worm of the body (tinea corporis)
3. Ring worm of the Scalp (tinea capitis)
4. Ring worm of the nails (tinea ungium or onychomycosis)
5. Ring worm of the groin (tinea cruris)

Type and location	clinical manifestation	treatment
Tinea capitis (Ring worm of scalp)	• Contagious • Common in children • Round patches of redness and scaling • Small pustules or papules at edges • Hair brittle; breaks easily at scalp.	Giriseofulvin shampoo hair 2-3x/wk
Tinea cooperies (ringworm of body)	• Begins with erythematic • macula • advance to papules / vesicles • lesions found in clusters	- Ketoconazol - Girisofulvin
Tinea cruris (ring worm of groin)	• Pruritus with small red scaly • patches • Extend to circular plagues • with elevated scaly or • vesicular borders	**mild** :Topical med n - Clotrimazol - miconazol **Sever** : systemic - oral grisofluvin
Tinea pedis (ring worm of feet) Tinea ungium (ring worm of nails)	• pruritus • affect soles of feet Space b/n toe • inflamed vesicles (acute) • Scaly , dusky or red rash (chronic) ▪ Common toenails ▪ Associated with chronic feet infection ▪ nails thicken crumble easily , & lack luster ▪ Whole mail may be destroyed	**Acute infections** :soak with saline , potassium solution , -Topical miconazol, clotrimazol **Resistant** - Griseofulvin. long term therapy (6 month - 1yr) **Supportive management** -Advice the patient to have reserve socks -Advice the patient to keep his feet clean and dry

Cont…

Encourage the patient to wear sandals

-Encourage the patient to use cotton made socks

- Griseofulvin
- miconazol
- Clotrimazol
- Nystatin

providing care for a patient with viral skin diseases

TYPES OF VIRAL SKIN DISEASES

I. Verrucea (warts)
II. Molluscum contagious
III. Herpes zoster
IV. Herpes simplex

Verucae (warts)

- Occur when there is infection of the skin by HPV
- The virus grows only on the human skin
- Source of infection is other infected individuals
- Commonly seen in children
- Adults develops immunity against this virus
- Infectivity of the virus is very low
- A causal contact is unlikely to result infection

cont...

- The virus enters the skin through **microscopic abrasions** and remains limited to the epidermis
- Clinically the lesions manifest in a verity of forms , but
- All types of lesions are asymptomatic
- Pt may have any number of lesion (from one - hundred)
- Individuals with depression of the cell mediated immunity due to lymphomas, AIDS, Rx with immuno- suppressive drugs are more likely to have a large number of warts.

Cont…

Diagnosis - clinical

Treatment - none of the antiviral drugs available of or are effective against warts. **Cyto destructive chemical**

1st line

Iodine 2-3 x weeks for 1-2 weeks

Alternative

Retinoic acid 2x/day in add to cry other apynor

Silver nitrate + potassium nitrate weekly for 2-3x

Surgery

Curettage

Cryo theropy

•

2. Malluscum contagious

Caused by pox virus

Gets implanted on the skin by contact with other infected individual

Common in children

Incubation period 2-8Wks

Manifests as asymptomatic ,pearly white /pink ,smooth surface 2-10mm size papules

Large lesions tend to become umblicated in the center

Cont…

As old lesions heal spontaneously in 1-2wks ,the new lesions can continue to appear by out inoculation

Widely disseminated lesions may occur with suppressed cell mediated immunity

When pre a transmitted by sexu



Molluscum contagiosum

Cont…

Diagnosis --Clinical+ lab (gram stain) histopathology

Rx- similar to warts

Cytodestructive chemical

first line

Iodine 2-3 x weeks for 1-2 weeks

Alternative

Retinoic acid 2x/day in add to cry other apynor

Silver nitrate + potassium nitrate weekly for 2-3x

Cont…

Surgery

Curettage

Cryotheropy

Note: sexual part hers should also be examined and treated folliculitis

3. Herpes zoster

Definition: herpes zoster, also called shingles, is an infection caused by zoster virus



Herpes zoster

Cont…

Etiology: varicella-zoster virus (VZV)

Pathophysiology

Primary infection: transmission is most likely to occur by **the respiratory rout** resulting in chickenpox manifested by vesicles involving the cornium and dermis, with degenerative changes characterised by ballooning, the presence of giant cells, and eosiniphilc intranuclear inclusions. Occurs in individual who are partially immune to this virus.

Recurrent infection: the mechanism of VZV that results in herpes zoster infection is unknown, presumably, the virus infect the dorsal root ganglia during chickenpox, where it remains

Cont…

Clinical feature

Manifested as Eruption consists of grouped, tense vesicles

Or even bulla

Limited to a single neural segment as is unilateral

Involvement of thoracic segment is very common

Less commonly may occur on upper or lower extremities

Trigeminal nerve is commonly affected - corneal ulceration

Less commonly the 7th& 8th cranial nerves affected ----

Facial palsy & deafness-- ram say hunt syndrome

Cont...

Dx- Clinical The presence of grouped vesicles and bulla on the background of edematous and erythematic skin

Appearance of lesions one side of vertebrae

Association with severe pain

The presence of grouped vesicles and bulla on the background of edematous and erythematic skin

Appearance of lesions one side of vertebrae

Association with severe pain

Unilateral involvement of a neural segment is very diagnostic of HZ

Cont…

Rx- heal in a wk or so even if no treatment is given

Calamine lotion- for patient comfort

Bathing and washing with soap

If ulcerated topical / systemic ABTS.

Acyclovir 200mg po 5X/ day for 5 days or 5 mg/kg iv TId for 7 days

Topical acyclovir 5x/d in mild cases or in addition to systemic therapy in severe form

Broad spectrum antibiotics

(TTC, amoxicillin) to avoid 2^0 infect

Prednisone 15-30 mg/day for post herpetic neuralgia

4. Herpes simplex

A relatively common infectious disorder affecting the skin (MUCUS MEMBRANE) is herpes simplex virus (HSV)



Herpes simplex

Cont…

PATHOPHYSIOLOGY

HVS enters the cell through mucosal membrane or abraded skin. Once the virus enters a cell, it begins to produce **vesicles** (initial infection).

The initial infection may be symptomatic or sub clinical depending on the dose of the virus, its virulence, and the host’s resistance.

On entry the virus is transported intraaxonally to the ganglia and contagious neural tissue.

Cont…

The virus then spread to other mucosal skin surfaces through centrifugal migration of infectious virons via peripheral sensory nerve.

This mode of spread helps explain the large surface area involved, the high frequency of new lesions distant from the initial crops of vesicles that is characteristics of **primary infection.**

Cont…

After the active infection resolves, the viral particles maintain themselves in sensory nerve ganglia.

On reactivation by some stimuli, cold, fever, menses stress, or trauma, the viral particles released and they retrace their journey down the nerve to the skin and there they multiply and new lesions occur resulting in **recurrent infection**

Cont…

C/M

4.1. **Primary HS**-occurs w/n the pt exposed to the virus for the first time Site of the initial lesion depends on place of entry of the virus.

The Manifest as gingivitis(inflammation of the gums), stomatitis(inflammation of mucous membrane of the mouth) , banalities (all parts) , Volvo - virginities

The lesion consists of multiple, small superficial ulcers with sever inflammation in the region & acute patch.

Persist for one/two wks the subsides spontaneously

Cont…

4.2. Recurrent HS

- Under certain circumstances- reactivated - recurrent infection
- Genital herpes transmitted by sexual contact
- Patient with immuno- suppression- disseminated a

Dx – Identification of the virus

Association with fever

Pustular vesicles with amblication of the center

Cont…

- Systemic antibiotics for secondary bacterial infections

RX-Topical

Genitian violet 1% 2-3 x /days

Top cal acyclovir 5x day

System

Acyclovir 200mg po 5xdaily for 5-7 days

children < 2year half adult dose

>2 year adult dose





Muhammad siraj